

ARTICLE

Morphological and paleoradiological studies of Pott's disease cases

János Balázs^{1*}, Péter Gábor Zádori², Csaba Vandulek³, Erika Molnár¹, Brigitta Ósz¹, Zsolt Bereczki¹, László Paja¹, András Palkó⁴, Ottó Fogas⁵, Albert Zink⁶, Andreas Nerlich⁷, György Pálfi¹

¹Department of Biological Anthropology, University of Szeged, Szeged, Hungary

²Health Center of the Kaposvár University, Kaposvár, Hungary

³University of Pécs, Faculty of Health Science, Department of Radiography

⁴Department of Radiology, University of Szeged, Szeged, Hungary

⁵Móra Ferenc Museum, Szeged, Hungary

⁶Institute for Mummies and the Iceman, EURAC Research, Bolzano, Italy

⁷Division of Paleopathology, Institute of Pathology, Academic-Teaching Hospital Munich-Bogenhaus, Germany

ABSTRACT Two human thoracolumbar spine remains showing angular kyphosis have been investigated. Both skeletons come from medieval Hungary; one of them was recovered from the skeletal material of Szeged Castle and the other one from the cemetery of Nyárlőrinc. Both cases show serious bone deformities; on account of a chronic pathological process, several vertebral bodies have been destroyed and have collapsed resulting in a gibbus. Because of the specific character of the lesions, the diagnosis of vertebral tuberculosis (TB) could be rendered probable even after the initial macroscopic observations. As for the spine from Nyárlőrinc, the diagnosis of TB was confirmed by a molecular test too. A comparative paleoradiological analysis has also aided our diagnosis. The radiological picture is consistent with characteristics of Pott's disease in both cases.

Acta Biol Szeged 59(2):211-216 (2015)

KEY WORDS

comparative analysis
medieval Hungary
paleoradiology
Pott's disease
tuberculosis

Introduction

Paleoradiology studies bioarcheological materials using modern imaging techniques, such as X-ray radiography, computed tomography (CT), magnetic resonance imaging (MRI), and micro-CT (Chhem and Brothwell 2008; Kristóf 2015; Zádori 2015).

Paleoradiological methods provide us with direct insight into the internal structures of the examined object. Using medical imaging techniques, we can visualize those hidden alterations, which otherwise could only be exposed by post mortem destruction or intentional cutting. The non-invasive nature of these imaging techniques facilitates far better possibilities for exploring and saving important historic or prehistoric human remains and other items of cultural heritage. The use of paleoradiological methods has a particular importance in paleopathology of mummified remains (*e.g.* Chhem and Brothwell 2008; Kustár et al. 2011; Coqueugniot et al. 2015)

The availability of CT scanners since the early 1970's and the continuous development of CT imaging techniques in the subsequent decades provided improving visualization of the anatomy and of paleopathological lesions in mummies and in ancient skeletal remains. Today the latest generation of CT scanners with three-dimensional (3D) and surface rendering capabilities can create realistic 3D reconstructions (Chhem and Brothwell 2008).

Three-dimensional imaging techniques have become a very important tool in the field of paleopathology. 3D analyses are in fact the only efficient way to visually reconstruct processes involved in pathological bone changes. As for tuberculosis (TB), the 3D analysis brings additional and original information: it facilitates virtual reconstruction of the initial location and aspect of the infectious process, its extension to the bone and its possible diffusion to the surrounding tissues as well (Dutour and Coqueugniot 2012; Paja et al. 2012; Coqueugniot et al. 2015).

Despite their non-destructive nature, radiological studies are unfortunately still underutilized and not part of the investigation routine for ancient bones.

The aim of our study is to demonstrate the efficiency of paleoradiological methods in support of preliminary diag-

Submitted November 25, 2015; Accepted December 12, 2015

*Corresponding author. E-mail: janos.balazs@gmail.com

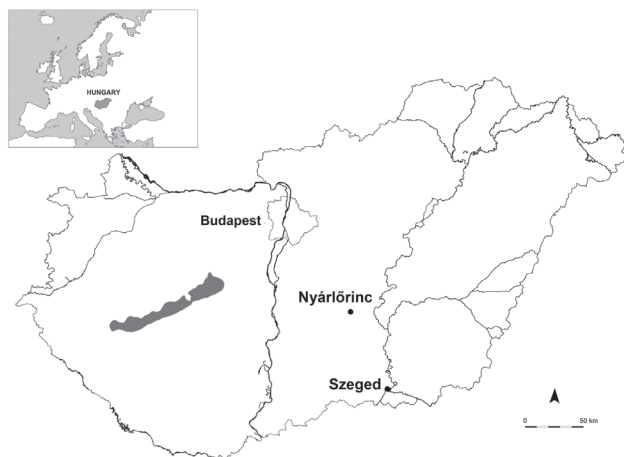

Figure 1. The location of Nyárlőrinc and Szeged in the map of Hungary.

noses of TB in two osteoarcheological cases coming from medieval Hungary.

Materials and Methods

Two human thoracolumbar spine remains showing angular kyphosis have been investigated for this study. Both skeletons come from medieval graveyards located in southern Hungary (Fig. 1). One of them was recovered from the skeletal material of Szeged-Vár (Szeged Castle, grave no. 483, 20-40 yrs, female) (Ósz et al. 2009) and the other one from the cemetery of Nyárlőrinc (grave no. 82, 20-40 yrs, female) (Balázs et al. 2005; Marcsik et al. 2006, 2009).

The archeological excavation at the ruins of Szeged Castle started in 1999 (Horváth 2009; Ósz et al. 2009). In the centre of the castle the remains of a gothic church were found dating back to the first half of the 14th century AD. A burial area of very high density was found around and inside the building. The first period of use spanned from the foundation to 1543, but after the Turkish Occupation in Hungary it was in use again from 1686 to 1713. The excavation continued in 2007, and up to now almost 1000 graves and several other objects (ossuaries, crypts) have been recovered.

Nyárlőrinc is a town of medium-size in the area called Danube-Tisza interfluvium. The first archeological excavation in and around the medieval church in the former village centre has been started in 1982 (Balázs et al. 2005). As a result of the 11-year-long excavation project, 541 graves were unearthed. Although the earliest archeological layer found in the site is from the Early Árpadian Age (11th century AD), but graves from were not present in the material. The earliest graves date

back to the 12th century AD, and the cemetery was utilized until the 16th century AD.

Both skeletal series were subjected to general paleopathological examination (Balázs et al. 2005; Ósz et al. 2009). Because of the specific character of the observed lesions in both cases, the diagnosis of tuberculosis could be rendered probable even after the initial macroscopic observations (Pálfi et al. 1999; Ortner 2003). In order to support this diagnosis, a specific paleoradiological analysis has been carried out in both cases (Panuel et al. 1999).

The computer tomography (CT) examinations were performed using a Siemens Somatom Emotion 6 multislice spiral CT device. Bone window axial images were obtained at 1.25 mm slice thickness. Based on the primary data and the axial CT images secondary multiplanar (MPR) and volume rendering technique (VRT) reconstructions were performed for better visualization.

Results

Szeged-Vár 483

Seven vertebral segments (T8 – L2) are fused. Vertebral bodies and the posterior elements are both ankylosed. Costovertebral joints are not involved in the fusion (sz et al. 2009). The five caudal segments (T10 – L2) of the affected spinal region have collapsed, and because of the wedge-shaped vertebral bodies severe angular kyphosis (Pott's gibbus) developed with an angulation of about 90 degrees (Fig. 2a, 2b).

CT images revealed the internal characteristics of the vertebral bodies and narrowing of the spinal canal. At the maximum of the kyphotic deformity the borders of the vertebral bodies cannot be properly differentiated and the bone structure is abnormal. Diameter of the spinal canal is narrowed to 11 mm at this site. The intervertebral foramina are also narrowed, the facet articulations are ankylotic. An asymmetrical calcified paravertebral mass is also visible near the lower-mid spinal segments, mainly on the left side in conjunction with the vertebrae (Fig. 2c, 2d).

Nyárlőrinc 82

The most significant morphological feature of the spine is the complete fusion of 8 vertebral segments (T10 – L5) and the strong angular kyphosis (Fig. 3a, 3c). The body of T9 is almost completely destroyed; the remnants are V shaped and present considerable loss of height. Both the endplates and the sides of vertebral bodies have irregular surfaces (Fig. 3b).

The radiological examination revealed, that body height is well preserved in L4 – L5, but the bodies of the other six affected vertebrae (T10 – L3) are destroyed and collapsed

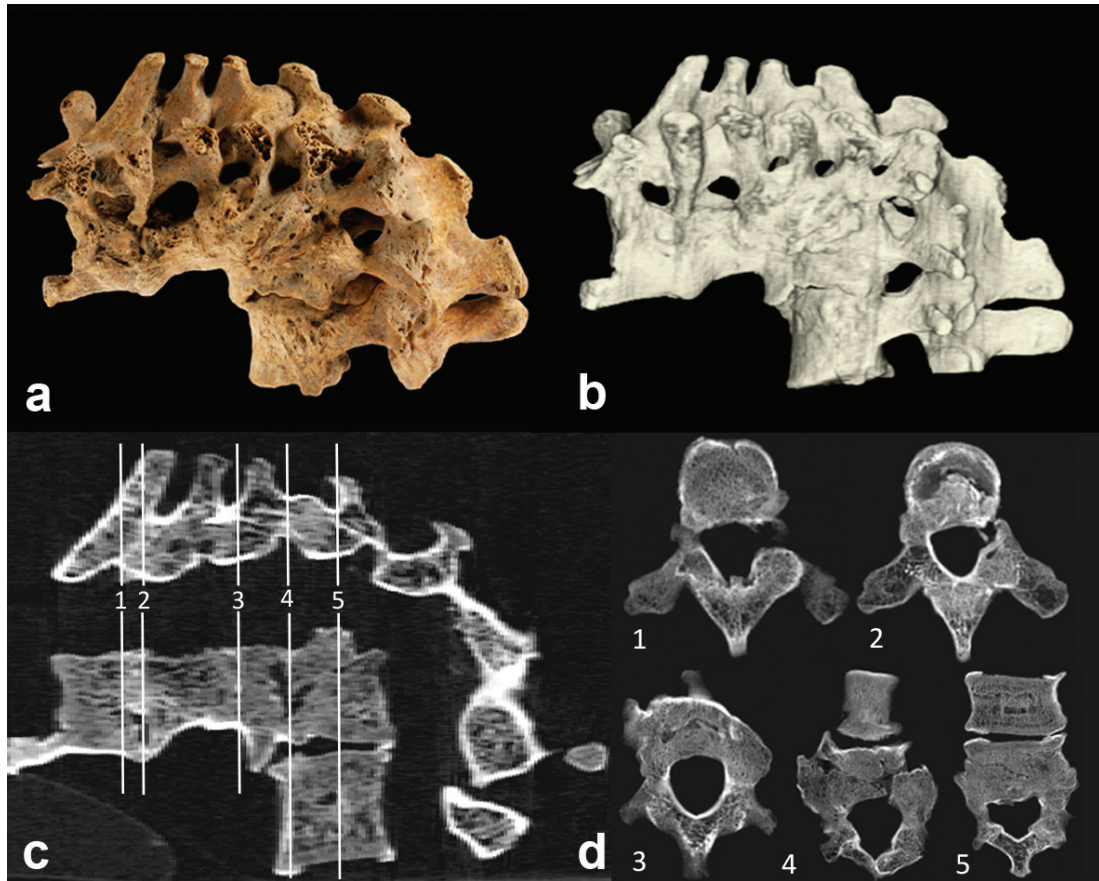


Figure 2. Advanced stage Pott's disease. Morphological picture, 3D reconstruction and CT images of the thoracolumbar spine remains from the Szeged-Vár cemetery (Grave 483). a: macromorphological picture of the spine. b: CT-based 3D (VRT) reconstruction of the spine remains. c-d: lateral view (MPR) CT images of the thoracolumbar spine and separated images of the affected vertebrae.

with anterior and central dominance. The vertebral bodies show anterior wedging, narrowing and forming dorsal kyphotic prominence of the spine as a gibbus. The angulation is approximately 90 degrees. As the lesions are very serious, vertebral bodies cannot be differentiated from each other. At the maximum of the angulation, a 7 mm wide irregular calcification is present on the dorsal upper edge of the vertebral body that narrows the spinal canal down to 10 mm in diameter. The foramina are narrowed, the facet articulations are ankylotic. Vertebrae L3 and L4 are not completely fused, the endplates facing each other are irregular with sclerotic rims. The anterior part of T10–L4 vertebral bodies is highly irregular with sclerotic bony defects (Fig. 3a-c).

Discussion

Tuberculosis has a great antiquity. It is accepted and fre-

quently cited in medical literature that TB of the spine is probably one of the earliest pathologies to have affected mankind (Garg and Somvanshi 2011). Human paleopathology aided by paleoradiology furnishes direct evidence to support this statement. The earliest human skeletal evidence of vertebral tuberculosis is more than ten thousand years old (Baker et al. 2015). From Hungary, a seven thousand years old spectacular spinal TB was reported a few years ago (Köhler et al. 2012), and its tuberculous infection was also proved recently by molecular techniques (Pósa et al. 2015a). From more recent archeological periods, especially from the middle ages an invaluable dataset is available containing morphologically, radiologically and molecularly confirmed paleopathological TB cases from the Carpathian Basin (*e.g.*, Pálfi et al. 1999; Marcsik et al. 2006, 2009; Hajdu et al. 2012; Pósa et al. 2015a, 2015b).

Vertebral tuberculosis is among the most common forms of skeletal tuberculosis and constitutes about 50% of all cases of typical skeletal tuberculosis in the reported series (Tuli

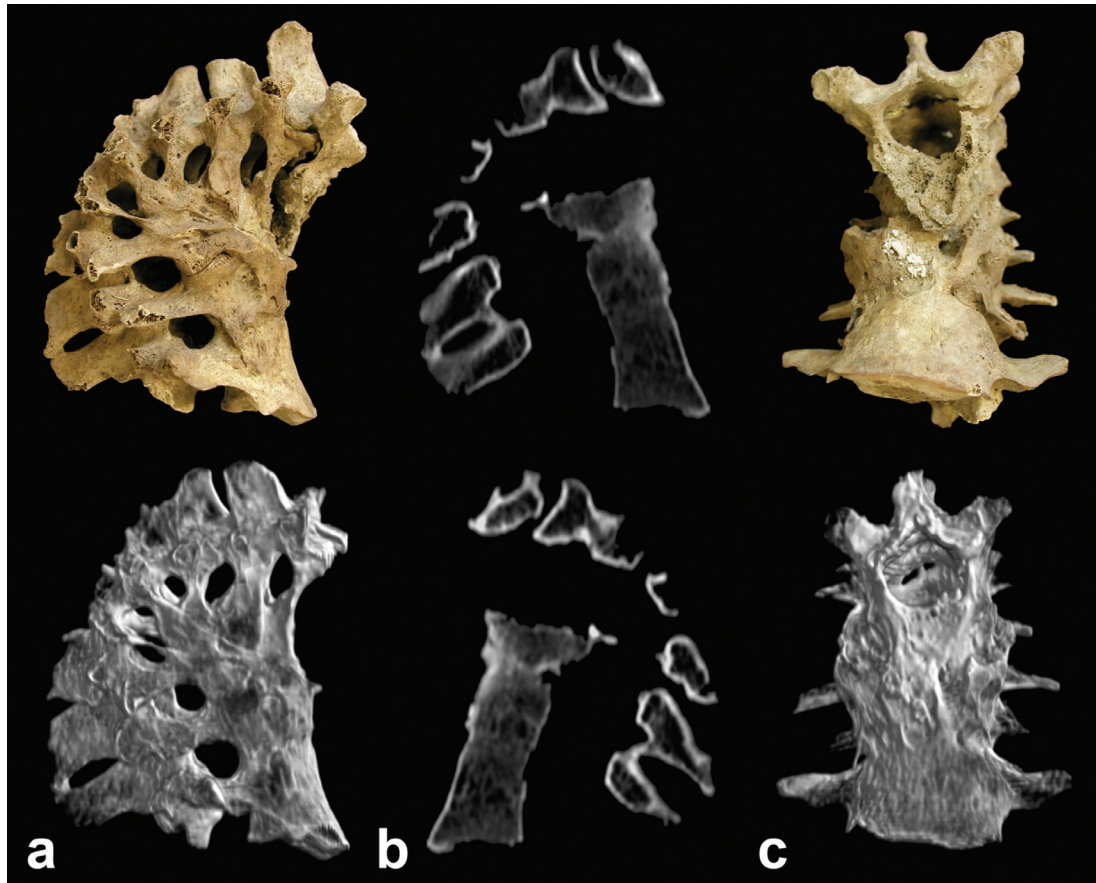


Figure 3. Advanced stage Pott's disease. Morphological pictures, CT images and 3D reconstructions of the thoracolumbar spine remains from the Nyárlőrinc medieval cemetery (Grave 82).

a: lateral view macromorphological and 3D (VRT) reconstruction images showing complete bony ankylosis of 8 vertebrae.

b: lateral view (MPR) CT images showing severe dorsal kyphosis.

c: anterior view macromorphological and 3D (VRT) reconstruction images of the affected spinal region.

1995). The predilection for spinal disease may be explained by the fact that the vertebrae are extremely well vascularized, even in adulthood, which facilitates bacterial colonization of the bones through the blood stream. Spinal TB is most frequently located in the lower thoracic and lumbar spine. Most cases of tuberculous bone and joint disease are isolated to one area, but multifocal disease has also been described (Agrawal et al. 2010). The cavitations observed in vertebral tuberculosis usually begin in the inferior or anterior portion of the vertebral body, near an intervertebral disc. The process ultimately destroys the entire body and may result in its collapse and fusion with the adjacent bodies causing the typical angulation (gibbus) of the spine. This condition indicates longstanding bone tuberculosis (Ortner 2003). In juvenile skeletons the variability of vertebral TB lesions is high and was probably higher in pre-antibiotic periods (Pálfi et al. 2012).

During the retrospective diagnosis of tuberculosis we have limited possibilities. After recognizing macroscopically vi-

sible osteological lesions suggesting tuberculosis we can use radiology, histology and molecular biology to strengthen the diagnosis. This paper focused on macromorphological and radiological studies.

The radiological picture of advanced stage tuberculous cases usually shows the following pattern: radiolucent lesions of variable size within the vertebral body, narrowing of the disc space, collapse of the vertebral body, and ultimately an acute kyphosis centred on the collapsed vertebra (Chhem and Brothwell 2008).

In our cases the morphological picture of the lesions is consistent with the characteristics of TB-related severe kyphosis (Pott's gibbus). Both cases show serious bone deformities: several vertebral bodies have been destroyed and have collapsed resulting in a gibbus. These lesions refer to a longstanding, chronic pathological process, induced most probably by tuberculosis.

The existence of a calcified, paravertebral mass involving

the lower-mid segment of the gibbus in the Szeged-Vár 483 case and the sclerotic bony defects on the anterior part of the T10-L4 vertebrae in the Nyárlőrinc 82 case raise the suspicion of concomitant soft tissue infection.

Spinal tuberculosis is still the most common cause of severe kyphosis in many parts of the world. Radiological reports of contemporary tuberculous cases provide good opportunity for comparison with advanced stage osseous tuberculosis cases in archeological series. The radiological picture of the two medieval Hungarian skeletons shows great similarity with modern clinical cases of severe Pott's disease (Jain et al. 2010; Rajasekaran 2012).

According to modern medical literature neurological complications (paraplegia or quadriplegia) and osseous deformities are the most dreadful complications of spinal TB (e.g., Agrawal et al. 2010; Jain et al. 2010; Garg and Somvanshi 2011; Rajasekaran 2012). Neurological complications can develop both in the active and the healing stage of the disease. When patients develop a kyphosis of 60 degrees or more in the dorsal or dorsolumbar spine they are also likely to develop late onset paraplegia (Tuli 1995; Marcsik et al. 1999). In our cases, narrowing of the spinal canal at the kyphosis and decreased size of the intervertebral foramina may have caused some neurological complication. However, in the absence of any skeletal changes referring to Pott's paraplegia (e.g., atrophy of the lower limb bones) this hypothesis cannot be confirmed.

Previous paleomicrobial analysis proved the presence of mycobacterial DNA in one of the affected vertebrae of the Nyárlőrinc Pott's disease case supporting the diagnosis of tuberculosis (Balázs 2005; Zink et al. 2007). In the other case molecular biological analysis was not performed yet. However, the great similarity in the morphological and radiological appearance of the pathological lesions between our two cases, moreover the similarity of radiological images of contemporary advanced stage tuberculosis cases and these two archeological samples allow us to set up the diagnosis of advanced stage chronic spinal tuberculosis in both specimens.

As a conclusion, we can state that the paleoradiological examination brought great benefits to the diagnosis in terms of showing the inner structures of pathological bones. The archived radiological data will also provide us a great opportunity to create virtual or printed 3D reconstruction of the pathological bones in the future.

Acknowledgements

The support of the OTKA Grants 78555, NN 78696 and that of TÁMOP-4.2.2/B-10/1-2010-0012 is greatly acknowledged.

References

- Agrawal VR, Patgaonkar P, Nagariya SP (2010) Tuberculosis of spine. *J Craniovert Jun Spine* 101:74-85.
- Baker O, Lee OY, Wu HH, Besra GS, Minnikin DE, Llewellyn G, Williams CM, Maixner F, O'Sullivan N, Zink A, Chamel B, Khawam R, Coqueugniot E, Helmer D, Le Mort F, Perrin P, Gourichon L, Dutailly B, Pálfi G, Coqueugniot H, Dutour O (2015) Human tuberculosis predates domestication in ancient Syria. *Tuberculosis* 95(Suppl 1):S4-S12. DOI: 10.1016/j.tube.2015.02.001.
- Balázs J (2005) Paleopatológiai vizsgálatok egy XII-XVI. századi széria (Nyárlőrinc Hangár út) leletein. MSc Thesis. University of Szeged, Szeged, Hungary [*in Hungarian*].
- Balázs J, Bölkei Z, V Székely G (2005) A Nyárlőrinc-Hangár utcai széria embertani feldolgozásának eredményei. *Cumania* 21:57-82 [*in Hungarian*].
- Chhem RK, Brothwell DR, eds. (2008) *Paleoradiology. Imaging Mummies and Fossils*, Springer Verlag, Berlin-Heidelberg.
- Coqueugniot H, Dutailly B, Desbarats P, Boulestin B, Pap I, Szikossy I, Baker O, Montaudon M, Panuel M, Karlinger K, Kovács B, Kristóf LA, Pálfi G, Dutour O (2015) Three-dimensional imaging of past skeletal TB: From lesion to process. *Tuberculosis* 95(Suppl 1):S73-S79. DOI: 10.1016/j.tube.2015.02.004.
- Dutour O, Coqueugniot H (2012) Contribution of 3D reconstructions to the paleopathology of tuberculosis. In Pálfi G, Bereczki Z, Molnár E, Dutour O, eds., *ICEPT-2 The Past and Present of Tuberculosis: a multidisciplinary overview on the origin and evolution of TB*. JATE Press, Szeged, 45.
- Garg RK, Somvanshi DS (2011) Spinal tuberculosis: A review. *J Spinal Cord Med* 34:440-454.
- Hajdu T, Donoghue HD, Bernert Z, Fóthi E, Kővári I, Marcsik A (2012) A case of spinal tuberculosis from the middle ages in Transylvania (Romania). *Spine* 37(25):E1598-601.
- Horváth F (2009) A short history of the excavations in the Castle and the Castle-Church of Szeged. In Pálfi G, Molnár E, Bereczki Z, Pap I, eds., *Des lésions du passé aux diagnostics modernes*, Szeged University Press, 66-67.
- Jain AK, Dhammi IK, Jain S, Mishra P (2010) Kyphosis in spinal tuberculosis – Prevention and correction. *Indian J Orthop* 44(2):127-136.
- Köhler K, Pálfi G, Molnár E, Zalai-Gaál I, Osztás A, Bánffy E, Kirinó K, Kiss K, Mende BG (2012) A Late Neolithic case of Pott's disease from Hungary. *Int J Osteoarchaeol* 24(6):697-703.
- Kristóf LA (2015) *Paleoradiológia: non-invazív módszertani lehetőség a történeti antropológiában*. PhD Thesis. Uni-

- versity of Szeged, Szeged, Hungary [in Hungarian].
- Kustár Á, Pap I, Végvári Z, Kristól LA, Pálfi G, Karlinger K, Kovács B, Szikossy I (2011) Use of 3D virtual reconstruction for pathological investigation and facial reconstruction of an 18th century mummified nun from Hungary. *Yearbook of Mummy Studies* 1:83-95.
- Marcsik A, Molnár E, Ősz B, Donoghue H, Zink A, Pálfi G (2009) Adatok a lepra, tuberculosis és syphilis magyarországi paleopatológiájához. *Folia Anthropol* 8:5-34 [in Hungarian].
- Marcsik A, Molnár E, Szathmáry L (2006) The antiquity of tuberculosis in Hungary: the skeletal evidence. *Mem. Inst. Oswaldo Cruz* 101(2):67-71.
- Marcsik A, Szentgyörgyi R, Gyetvai A, Finnegan M, Pálfi G (1999) Probable Pott's paraplegia from the 7th-8th century A.D. In Pálfi G, Dutour O, Deák J, Hutás I, eds., *Tuberculosis Past and Present*, Szeged, 333-336.
- Ortner DJ (2003) Infectious diseases: tuberculosis and leprosy. In Ortner DJ, ed., *Identification of Pathological Conditions in Human Skeletal Remains*. Academic Press, San Diego, 227-271.
- Ősz B, Hajnal K, Marcsik A, Fogas O, Horváth F, Zádori P, Kelemen K, Vandulek C, Schultz M, Márk L, Molnár E, Pálfi G (2009) Preliminary report on the paleopathological research of the skeletal material from the Szeged medieval castle excavation. *Acta Biol Szeged* 53(2):125-138.
- Paja L, Coqueugniot H, Dutour O, Willmon R, Farkas GL, Palkó A, Pálfi G (2012) Knee ankyloses associated with tuberculosis from the medieval Hungary – differential diagnosis based on medical imaging techniques. *Int J Osteoarchaeol* 25(3):352-360.
- Pálfi G, Bereczki Z, Ortner DJ, Dutour O (2012) Juvenile cases of skeletal tuberculosis from the Terry Anatomical Collection (Smithsonian Institution, Washington, D.C., USA). *Acta Biol Szeged* 56(1):1-12.
- Pálfi G, Dutour O, Deák J, Hutás I, eds. (1999) *Tuberculosis: Past and Present*. TB Foundation - Golden Book Publisher, Szeged-Budapest, 608.
- Panuel M, Portier F, Pálfi G, Chaumoitre K, Dutour O (1999) Radiological differential diagnosis of skeletal tuberculosis. In Pálfi G, Dutour O, Deák J, Hutás I, eds., *Tuberculosis: Past and Present*. Golden Book – Tuberculosis Foundation, Budapest-Szeged, 227-234.
- Pósa A, Maixner F, Mende BG, Köhler K, Sola C, Dutour O, Masson M, Molnár E, Pálfi G, Zink A (2015a) Tuberculosis in Late Neolithic-Early Copper Age human skeletal remains from Hungary. *Tuberculosis* 95(Suppl 1):S18-S22. DOI: 10.1016/j.tube.2015.02.011.
- Pósa A, Frank M, Sola C, Bereczki Z, Molnár E, Masson M, Lovász G, Wicker E, Perrin P, Dutour O, Zink A, Pálfi G (2015b) Tuberculosis infection in a late-medieval Hungarian population. *Tuberculosis* 95(Suppl 1):S60-S64. DOI: 10.1016/j.tube.2015.02.010.
- Rajasekaran S (2012) Kyphotic deformity in spinal tuberculosis and its management. *Int Orthopaed* 36:359-365.
- Tuli SM (1995) Severe kyphotic deformity in tuberculosis of the spine. *Int Orthopaed* 19:327-331.
- Zádori PG (2015) *Komputertomográfias képalkotás speciális felhasználása a humán paleoradiológia területén*. PhD Thesis. University of Pécs, Pécs, Hungary. [in Hungarian]
- Zink AR, Molnár E, Motamedi N, Pálfi G, Marcsik A, Nerlich AG (2007) Molecular history of tuberculosis from ancient mummies and skeletons. *Int J Osteoarchaeol* 17:380-391.