

ARTICLE

Analysis of urinary cathepsin C for diagnosing Papillon-Lefèvre syndrome*

Yveline Hamon^{1#20}, Monika Legowska^{2§}, Patricia Fergelot^{3**§}, Sandrine Dallet-Choisy^{1#}, Louise Newell⁴, Lise Vanderlynden^{1#}, Ali Kord Valeshabad⁵, Karina Acrich⁶, Hadi Kord⁷, Tsamakidis Charalampos⁴, Fanny Morice-Picard⁸, Ian Surplice⁴, Jerome Zoidakis⁹, Karen David⁶, Antonia Vlahou⁹, Shivanna Ragnunatha¹⁰, Nikoletta Nagy¹¹, Katalin Farkas¹¹, Márta Széll¹¹, Beate Schacher¹², Maurizio Antonio Battino¹³, Abdullah Al Farraj Aldosari¹⁴, Xinwen Wang¹⁵, Yang Liu¹⁶, Sylvain Marchand-Adam^{1#}, Adam Lesner², Elodie Kara¹⁷, Sevil Korkmaz-Icöz¹⁸, Celia Moss⁴, Peter Eickholz¹², Alain Taieb⁸, Salih Kavukcu¹⁹, Dieter E. Jenne²⁰, Francis Gauthier^{1#} and Brice Korkmaz^{1#}

¹INSERM U-1100 “Centre d’Etude des Pathologies Respiratoires”, 37032 Tours, France; [#]Université François Rabelais, 37032 Tours, France; ²Faculty of Chemistry, University of Gdansk, 80-952, Gdansk, Poland; ³CHU Bordeaux, Hôpital Pellegrin, Service de Génétique Médicale, Centre de Référence des Anomalies du Développement Embryonnaire, 33076 Bordeaux cedex, France; ^{*}Université de Bordeaux, Laboratoire Maladies Rares: Génétique et Métabolisme, EA 4576, Bordeaux, France; ⁴University of Illinois at Chicago 1905 W Taylor Street, Suite 215 Chicago, IL 60608; ⁶Metropolitan Hospital Center, Medical Genetics Clinic, New York, NY, USA; ⁷Department of Dermatology, Golestan University of Medical Sciences, Gorgan 4934174515, Iran; ⁸Centre de Référence pour les Maladies Rares de la Peau, Service de Dermatologie Adulte et Pédiatrique, CHU de Bordeaux, 33076 Bordeaux cedex and INSERM U-1035, University of Bordeaux; ⁹Biotechnology Division, Biomedical Research Foundation, Academy of Athens, Greece; ¹⁰Department of Dermatology, Venereology, and Leprosy, Sri Siddhartha Medical College, Tumkur, India; ¹¹Department of Medical Genetics, University of Szeged, MTA SZTE Dermatological Research Group, Department of Dermatology and Allergology, University of Szeged, Szeged, Hungary; ¹²Department of Periodontology, Johann Wolfgang Goethe-University Frankfurt, Theodor-Stern-Kai 7, 60596, Frankfurt, Germany; ¹³Dept Clinical Sciences, Università Politecnica delle Marche, Ancona, Italy and Centre for Nutrition & Health, Universidad Europea del Atlantico, Santander, Spain; ¹⁴Director of Dental Implant and Osseointegration Research Chair, Department of Prosthetic, College of Dentistry, College of Dentistry, King Saud University, Riyadh, Kingdom of Saudi Arabia; ¹⁵Department of Oral Medicine and Periodontology, School of Stomatology, The Fourth Military Medical University, 710032 Xi’an, Shaanxi, China; ¹⁶Department of Periodontology PLA 309 Hospital, Beijing, China; ¹⁷Repropharm, Centre INRA-Tours, Domaine de l’Orfrasière, 37380 Nouzilly, France; ¹⁸Department of Cardiac Surgery, University of Heidelberg, 69120 Heidelberg, Germany; ¹⁹Dokuz Eylül University, School of Medicine, Department of Pediatrics, Division of Pediatric Nephrology, İzmir, Turkey; ²⁰Comprehensive Pneumology Center, Institute of Lung Biology and Disease (iLBD), German Center for Lung Research (DZL), 81377 Munich, and Max Planck Institute of Neurobiology, 82152 Planegg-Martinsried, Germany.

§Equal contribution

*Running Title: Urinary CatC and PLS Diagnostic

To whom correspondance should be addressed: B. Korkmaz, “Centre d’Etude des Pathologies Respiratoires”, INSERM U-1100, Université François Rabelais, Faculté de Médecine, 37032, Tours, France. Phone: (0033) 2 47 36 62 53; Fax: (0033) 2 47 36 60 46; E-mail: brice.korkmaz@inserm.fr

Abstract

Papillon-Lefèvre (PLS, OMIM: 245000) is a rare disease characterized by severe periodontitis and palmoplantar keratoderma. It is caused by mutations in both alleles of the cathepsin C (CatC) gene which completely abrogate the proteolytic activity of this cysteine protease. A genetic analysis most often is unaffordable or unavailable to establish an early rapid diagnosis of PLS. In this study, we tested the hypothesis that active CatC is constitutively excreted and can be easily traced in the urine of normal subjects. If true, its absence in the urine of PLS patients would be an early, simple, reliable, low cost and easy diagnostic technique. All 75 urine samples from healthy control subjects (aged 3 months to 80 years) contained proteolytically active CatC and its proform as revealed by kinetic analysis and immunochemical detection. From the urine samples of 31 patients with a PLS phenotype, 29 contained neither proteolytically active CatC nor the CatC antigen so that the PLS diagnosis was confirmed. CatC was detected in the urine of the other two patients, but genetic analysis revealed no loss-of-function mutation in the CatC gene indicating that they suffer from a PLS-like syndrome but not from PLS. Urinary test strips impregnated with a sensitive, easy detectable CatC substrate in conjunction with a CatC capture antibody may now be designed to allow any laboratory worldwide to establish a reliable diagnosis of PLS and monitoring disease predisposition soon after birth.

Keywords: Papillon-Lefèvre Syndrome (PLS), diagnostic method, cathepsin C, inherited disorder, urine analysis,

Abbreviations: CatC, cathepsin C; PLS, Papillon-Lefèvre syndrome, APN, aminopeptidase N; AMC, aminomethylcoumarin

INTRODUCTION

Papillon-Lefèvre syndrome (PLS, OMIM: 245000) is a rare inherited autosomal recessive disorder characterized by palmoplantar hyperkeratosis and an early and severe periodontitis, causing loss of both the primary and permanent teeth. The prevalence of PLS is 1 to 4 cases per million people and the carrier rate is 2 to 4 per 1000. There is no gender predilection but parental consanguinity has been reported in more than 50% of cases^{1,2}. Palmoplantar keratoderma may be visible at birth or 1 to 2 months thereafter, but generally, keratoderma and periodontitis develop in parallel between the 6th month and the 4th year of life of the patient, and often coincide with the eruption of the first teeth³. Other symptoms can also occur such as mental retardation, intracranial calcifications, recurrent skin infections, hyperhidrosis and liver abscesses^{2,4}. The disease-causing gene, cathepsin C (CatC) (*CTSC*)^{5,6} is located on chromosome 11q14-21⁷⁻⁹. To date, 75 mutations have been reported for PLS patients, of which 68% were homozygous for one dysfunctional allele. Fifty percent of homozygous mutations were missense, 25% nonsense, 23% frameshift, and 2% were other types of mutations¹⁰. In addition to the classic form of PLS, 6 cases with late-onset periodontal disease and/or late-onset palmoplantar-lesions were reported¹¹. Haim-Monk syndrome, allelic to PLS has been described in a Jewish community in India, with arachnodactyly, acroosteolysis and onychogryphosis as additional features¹³. The diagnosis of PLS is based on clinical signs and is generally confirmed by exon sequencing. This latter procedure, however, has several drawbacks, the relatively high costs in comparison to the low socio-economic status of the patients from countries with frequent intrafamilial marriages, the uncertain interpretation of rare benign mutations and/or the unavailability of an appropriate platform for DNA preparation and sequence analysis^{14,15}.

CatC, also known as dipeptidyl peptidase I (DPPI, EC 3.4.14.1) is a lysosomal cysteine exopeptidase belonging to the papain superfamily of cysteine peptidases¹⁶. The gene encoding CatC spans over 46 kb (NM_001814.4) and contains seven exons^{6,17}. Functional CatC is a tetrameric enzyme consisting of four identical subunits linked together by non covalent bonds with a total molecular mass of approximately 200 kDa. Each subunit is composed of three polypeptide chains: a N-terminal fragment or exclusion domain (~13 kDa), a heavy chain (~23 kDa) and a light chain (~7 kDa)¹⁸. CatC subunits are synthesized as single chain pro-enzymes of about ~60 kDa that can be rapidly processed during biosynthesis in certain cell types. Processing and complete maturation requires the removal of a 15 kDa internal propeptide and intramolecular cleavages by other proteases¹⁹. The regulation of this

processing however is still unknown. CatC is expressed mostly in the lung, spleen, kidney, liver and myeloid cells like neutrophils, macrophages and their precursors¹⁷. It has an important role in the activation of various granular serine proteinases from neutrophils (elastase-like proteinases), mast cells, cytotoxic T-lymphocytes and natural killer cells²⁰.

We have recently shown that a proteolytically active CatC is secreted by activated neutrophils in lung fluids from patients with chronic inflammatory lung diseases, which makes it a marker of neutrophilic lung inflammation (Hamon et al., *in preparation*)¹. We also observed that proCatC, but not the mature protease, was secreted by bronchial epithelial cells (Hamon et al., *in preparation*) and that MCF-7 epithelial cells secrete both mature and proCatC (*unpublished*). In the present study, we hypothesize that urinary tract and/or renal epithelial cells also produce CatC constitutively in healthy individuals; if true, CatC should be absent in the urine of PLS patients, and monitoring CatC in the urine could be utilized as an early, simple, reliable, low cost diagnostic technique for PLS.

MATERIALS AND METHODS

Reagents

Recombinant CatC and aminopeptidase N (APN) were from Unizyme Laboratories (Hørsholm, Denmark) and R&D systems (Lille, France), respectively. AntiCatC antibodies were used in this study included: the mouse monoclonal anti-CatC Ab (Ab1) (Santa Cruz Biotechnology, Heidelberg, Germany), the goat polyclonal anti-CatC Ab (Ab2) (R&D Systems) and the goat polyclonal anti-CatC (Ab3) (Everest Biotech, Oxforshire, UK). The mouse monoclonal anti-APN Ab was from Santa Cruz Biotechnology. Gly-Phe-AMC was from Enzyme Systems Products (Illkirch, France) and H-Ala-AMC was supplied by Bachem (Weil am Rhein, Germany). The cysteine protease inhibitor E-64c ((2S,3S)-*trans*-Epoxy succinyl-L-leucylamido-3-methylbutane)) was from Sigma-Aldrich (St Louis, MO, USA) and the specific inhibitor of CatC, Thi-Phe-CN ((β -2-thienyl)-L-alanyl-L-phenylalanine nitrile) was provided by Dr Lesner (University of Gdansk, Poland). EDTA or Ethylenediaminetetraacetic acid was from Merk (Darmstadt, Germany) and the specific inhibitor of APN, bestatin was from Santa Cruz (Heidelberg, Germany).

Urine collection

¹ Neutrophilic mature cathepsin C is generated by a multi-step proteolytic process and secreted by activated cells during inflammatory lung diseases.

Urine samples were collected from 31 PLS patients from European countries (France, Germany, UK, Hungary, Italy and Turkey), Asian Countries (China, India, Iran, Saudi Arabia) and from the USA. The 75 healthy volunteers were from France and Iran. The study protocol was approved by the Comité de Protection des Personnes, CPP OUEST-1, Tours, France, and informed consent was obtained from each individual prior to enrollment. Demographics and clinical data from patients are summarized in **Table I**. After centrifugation (3000 g, 15 min) at 4°C to eliminate cells and debris, the urine supernatants were concentrated 20 or 120 times using Vivaspin 15R concentrators (molecular mass cutoff, 10 kDa; Sartorius, Goettingen, Germany) and store at 4°C.

Western blotting analysis

Briefly, urine samples were electrophoretically separated on a 10% SDS-PAGE in reducing conditions for CatC analysis and in non-reducing conditions for APN analysis, and then transferred to a nitrocellulose membrane (Amersham Biosciences, Uppsala, Sweden). After saturation, membranes were incubated with anti-CatC Abs (Ab1 and Ab3 diluted 1:500; Ab2 diluted 1:1000) or with anti-APN mAb (diluted 1:500). After washing, membranes were incubated with peroxidase-conjugated anti-mouse IgG (diluted 1:10000) or anti-goat IgG Abs (diluted 1:20000) (Sigma-Aldrich), when appropriate. Bound Abs were detected by chemiluminescence (ECL Plus Western Blotting Kit Detection Reagents, GE Healthcare, UK) according to the manufacturer's instruction.

Enzyme assays

Assays were carried out at 37°C in 50 mM sodium acetate, 30 mM NaCl, 1 mM EDTA, 2 mM DTT, pH 5,5 for CatC and in 50 mM Tris, pH 7 for APN. Proteolytic activity was measured using 5 µL of urine supernatants with 30 µM Gly-Phe-AMC in a total volume of 60 µL for CatC or with 50 µM H-Ala-AMC in a total volume of 100 µL for APN (excitation wavelength = 340 nm, emission wavelength = 460 nm; Spectramax Gemini (Molecular Devices, Sunnyvale, CA, USA)). The presence of CatC in urine was controlled incubating urine samples with the selective CatC inhibitor Thi-Phe-CN²³ prior to substrate addition. Recombinant CatC and APN were used as controls, respectively. For some experiments, urine samples were preincubated with 100 µM E64c, 5 µM Thi-Phe-CN, 5 mM EDTA or 100 µM bestatin for 30 min at 37°C prior the measurement of the proteolytic activity.

Cell culture

Human urinary bladder cancer T24 and T24M cells (Biotechnology Division, Biomedical Research Foundation, Academy of Athens, Greece) were cultured in McCoy's 5A Medium with L-glutamine (Ozyme, Saint Quentin en Yvelines, France) supplemented with or without 10% fetal calf serum (FCS) at 37 °C. Madin-Darby Canine Kidney Epithelial Cells (MDCK) were cultured in Eagle's Minimum Essential Medium supplemented with or without 10% fetal calf serum (FCS) at 37 °C. Cells were lysed in PBS containing 0.5% nonidet P-40 (IGEPAL 630), and after centrifugation (10000 g, 15 min at 4°C), the lysate was stored at -20°C. Cell supernatants were concentrated 30 times using Vivaspin 15R concentrators (molecular mass cutoff, 10 kDa; Sartorius). Proteins in lysates and in supernatants were quantified with a bicinchoninic acid assay (BCA) (Thermo Scientific, Rockford, IL, USA).

Genetic investigations

Patient's genomic DNA and when available parents DNA was extracted from EDTA blood samples with the automated method EVO[®]100 ReliaPrep (Tecan, Promega).

PCR and sequencing reaction: The *in vitro* amplification and sequencing of all *CTSC* exons and intron–exon boundaries were performed as described in ²¹ with minor modifications: sequencing was carried out using Big Dye Terminator v3.1 on a 3500xL Dx Genetic Analyzer (Applied Biosystems, ThermoFisher St Aubin, France). The *in silico* analysis of missense mutations and the database queries were conducted through the Alamut Interface (Alamut[®] Visual v2.3, interactive biosoftware, Rouen, France)). Mutations were described in accordance with the *CTSC* cDNA sequence GenBank NM_001814.2 and HGVS recommendations.

Deletion search was performed using custom array CGH: custom microarrays (8 × 60K) were designed with e-array web software (Agilent Technologies, CA) using the Similarity Score Filter in order to select highly specific probes. A total of 3141 probes were distributed: about one probe every 100 bp in the *CTSC* gene and 50 Kb around the gene then one probe every 350 bp in the 300 Kb regions apart. DNA was labelled (cyanine 3 or cyanine 5) using the Sure Tag DNA labeling kit from Agilent Technologies and hybridized onto the microarrays according to the manufacturer's instructions. DNA was analyzed in comparative genomic hybridization experiments with fluorochrome swapping, in a trio along with DNA from two subjects not affected by the PLS. Scanning of the microarrays was performed using a G2565CA scanner (Agilent Technologies). Data analysis was carried out with softwares from

Agilent Technologies, namely Feature Extraction 10.7.3.1 and Agilent Genomic Workbench 6.0.130.24.

RESULTS

Pro and mature CatC in urine of healthy subjects

We first screened 20-fold concentrated urine samples from 75 healthy individuals of various ages ranging from 3 months to 80 years for the presence of CatC. Using three different commercial antibodies (Ab1, Ab2, Ab3) to CatC we found that Ab1 and Ab3 recognized two different epitopes of the heavy chain whereas Ab2 recognized one epitope in the propeptide region. We observed two immunoreactive bands with an apparent molecular mass of ~23 kDa and ~60 kDa in 100% of the urine samples. These bands corresponded to the heavy chain of mature CatC and to proCatC respectively (**Figure 1**). The presence of pro and mature CatC did not vary with the timepoint of urine sampling, with the age and sex of the donor (**Figures 2A&B**). All of the 75 urine samples hydrolyzed the CatC substrate Gly-Phe-AMC and all peptidic activities were fully inhibited by the CatC nitrile inhibitor Thi-Phe-CN (**Figure 2C**). Based on the rate of hydrolysis of Gly-Phe-AMC by recombinant CatC, we estimated the concentration of active CatC to be in the 1-10 nanomolar range in normal urine. We did not observe any pro or mature CatC in plasma by immunoblotting (*data not shown*). Plasma-derived CatC, moreover, would hardly be expected to cross the kidney filtration barrier because of its large tetrameric Mr of ~200 kDa. We found however that human bladder cells (T24/T24M) and canine kidney epithelial cells (MDCK) produced and secreted proCatC but not the mature protease (*not shown*). To learn whether proCatC is converted into active CatC in urine, we compared the ratio between proCatC and fully processed and active CatC in a urine sample before and after a 24h incubation time at 37°C. No change in this ratio was observed strongly suggesting that proCatC processing active proteinases do not occur in urine (*data not shown*).

CatC in urine of patients with a PLS phenotype

31 urine samples were collected from clinically diagnosed or suspected PLS patients from different European, American and Asian countries (**Table I**). Urine samples were centrifuged upon receipt, concentrated (x120) and analyzed for the presence and activity of CatC as described for control subjects (**Figure 3A**). A sequencing-based PLS diagnosis was previously established for 21 patients allowing the identification of either nonsense, frameshift

or missense mutations in the *CTSC* gene (**Table I**). In spite of the greater concentration of PLS urine samples (x120 vs x20 in controls) no pro or active CatC was detected in any of these patients whatever the type of mutation was (**Table I**). We used the measurement of aminopeptidase N activity as a positive control to check the quality of the urine sample (*data not shown*). Of the 10 remaining patients whose PLS diagnosis was only based on clinical features (**Table I**) eight had no pro or mature CatC in their urine and we confirmed the PLS diagnosis by a genetic analysis allowing detection of the mutation (**Table I, Figure 3**). The other two patients, however, had pro and mature CatC in their urine. The first patient was a 20-year-old Turkish boy (P#30) who presented the classical dental and dermatologic characteristics of PLS²⁴. He also had a bilateral, hypertrophic-looking corneal leukoma and was suspected to suffer from PLS but no genetic analysis had been performed so far. A detailed genetic analysis was therefore performed, but no mutation of the CatC gene was found indicating that he did not suffer from classical PLS. The second CatC positive patient was a 16-year-old French teenager (P#31) who presented anomalies of deciduous teeth and had developed a palmoplantar psoriasiform skin changes with tapered distal phalanges as observed in Haim-Munk syndrome (**Figure 4A&B**). Again, the genetic analysis did not reveal a loss-of-function mutation in the CatC gene but one homozygous *CTSC* polymorphism. Urinary CatC activity was fully inhibited by the specific CatC inhibitor Thi-Phe-CN (*data not shown*). At least one of these polymorphisms came from his father but his mother presented a periodontitis and anomalies of deciduous teeth (**Figure 4C**). The urine of the mother also contained pro and mature CatC (**Figure 4D**). Mature CatC was present in a lysate of white blood cells from the son and his mother, and it compared with that of a healthy subject. Further, proteolytically active elastase-like proteases were present in white blood cell lysates indicating that functional CatC was present in cells and tissues (*data not shown*).

DISCUSSION

Clinical signs of the classical PLS become apparent by the age of one to five years when dry, scaly patches appear on the skin of palms and soles, and severe inflammation starts to affect the surrounding gingiva and bone of primary teeth, leading to their rapid loss. The genetic etiology of PLS has been clearly established but it still remains unclear why a lack of CatC activity leads to specific dermatological lesions and severe destructive periodontitis on the long run. A plausible explanation for the development of chronic periodontitis is the deficiency of the antimicrobial peptide LL-37 in the gingiva, allowing for infection with *A.*

actinomycetemcomitans and the development of severe periodontal disease²⁵. Proteinase 3 and possibly other neutrophil serine proteases release this peptide or similar peptides like FALL-39 from a precursor molecule after neutrophil activation. All these serine proteases together with CatC are missing in PLS patients. On the other hand, mutations in completely different genes may induce a PLS-like syndrome with similar dermatological lesions and destructive periodontitis, but may be very different with regard to co-morbidities and optimal treatment regimens²⁶. Several sporadic cases with a PLS-like clinical phenotype have been reported in the literature (refs) and two examples of a PLS-like syndrome have been included in this study. Because of the variable manifestations of the classical PLS syndrome, its overlap with other clinical entities and the potential occurrence of mild forms of PLS, gene-related functional and biochemical assays are of high value for the diagnosis of PLS and may help to discover atypical cases of PLS that otherwise cannot be discerned by exon sequencing alone. PLS may be underdiagnosed and more prevalent than documented at present²⁷.

CatC is expressed as a pro-proteinase by epithelial and myeloid cells and their precursors and is activated by a multistep mechanism possibly involving several proteinases^{5,17,22}. Thus pro- and/or mature CatC may be constitutively present in a variety of cells and tissues including renal and/or bladder epithelial cells. Here we evaluated the hypothesis that urine from healthy and diseased persons is in fact a reliable source of pro- or active CatC that can be easily characterized and analyzed for by enzymatic and/or immunochemical methods. In this study, we found that the absence of active CatC and its proform in the urine was a strong and reliable indicator for PLS and of great value for the early diagnosis of PLS. Absence of urinary CatC protein or activity was always associated with loss-of function-mutations in the CatC gene. By contrast 100% of our urine samples from control subjects of any age and gender contained measurable amounts of active CatC. The easy availability of large volumes of urine is advantageous from multiple perspectives in comparison to saliva or gingival crevicular fluids which only contain very little quantities of CatC activity in healthy subjects (ref). The implementation of an early treatment regimen can clearly stop the progression of periodontitis and skin lesions and can improve the quality of life of a PLS patient as highlighted in a recent case report²⁸. Demonstrating the absence of urinary CatC activity soon after birth and before the outbreak of clinical symptoms can be used as a screening procedure for PLS in populations with a high frequency of intra-familial marriages and in individuals who are closely related to a PLS patient. A test based on the absence of urinary CatC activity will allow to clearly distinguish between patients having loss-of-

function mutations in their *CTSC* gene, including PLS and Haim-Munk syndrome, and other patients with a PLS-like phenotype who suffer from another, so far unidentified syndrome.

REFERENCES

1. Gorlin RJ, Sedano H, Anderson VE. The Syndrome of Palmar-Plantar Hyperkeratosis and Premature Periodontal Destruction of the Teeth. A Clinical and Genetic Analysis of the Papillon-Lefevre Syndrome. *The Journal of pediatrics* 1964;65:895-908.
2. Haneke E. The Papillon-Lefevre syndrome: keratosis palmoplantaris with periodontopathy. Report of a case and review of the cases in the literature. *Human genetics* 1979;51:1-35.
3. Dhanrajani PJ. Papillon-Lefevre syndrome: clinical presentation and a brief review. *Oral surgery, oral medicine, oral pathology, oral radiology, and endodontics* 2009;108:e1-7.
4. Almuneef M, Al Khenazian S, Al Ajaji S, Al-Anazi A. Pyogenic liver abscess and Papillon-Lefevre syndrome: not a rare association. *Pediatrics* 2003;111:e85-8.
5. Hart TC, Hart PS, Bowden DW, et al. Mutations of the cathepsin C gene are responsible for Papillon-Lefevre syndrome. *Journal of medical genetics* 1999;36:881-7.
6. Toomes C, James J, Wood AJ, et al. Loss-of-function mutations in the cathepsin C gene result in periodontal disease and palmoplantar keratosis. *Nature genetics* 1999;23:421-4.
7. Fischer J, Blanchet-Bardon C, Prud'homme JF, et al. Mapping of Papillon-Lefevre syndrome to the chromosome 11q14 region. *European journal of human genetics : EJHG* 1997;5:156-60.
8. Hart TC, Bowden DW, Ghaffar KA, et al. Sublocalization of the Papillon-Lefevre syndrome locus on 11q14-q21. *American journal of medical genetics* 1998;79:134-9.
9. Laass MW, Hennies HC, Preis S, et al. Localisation of a gene for Papillon-Lefevre syndrome to chromosome 11q14-q21 by homozygosity mapping. *Human genetics* 1997;101:376-82.
10. Nagy N, Valyi P, Csoma Z, et al. CTSC and Papillon-Lefevre syndrome: detection of recurrent mutations in Hungarian patients, a review of published variants and database update. *Molecular genetics & genomic medicine* 2014;2:217-28.
11. Pilger U, Hennies HC, Truschneegg A, Aberer E. Late-onset Papillon-Lefevre syndrome without alteration of the cathepsin C gene. *Journal of the American Academy of Dermatology* 2003;49:S240-3.
12. Khan FY, Jan SM, Mushtaq M. Papillon-Lefevre syndrome (PLS) without cathepsin C mutation: A rare early onset partially penetrant variant of PLS. *The Saudi dental journal* 2014;26:25-8.
13. Noack B, Gorgens H, Hoffmann T, et al. Novel mutations in the cathepsin C gene in patients with pre-pubertal aggressive periodontitis and Papillon-Lefevre syndrome. *Journal of dental research* 2004;83:368-70.
14. Keskin-Yildirim Z, Simsek-Derelioglu S, Kantarci M, Yilmaz Y, Buyukavci M. Papillon-Lefevre syndrome: report of three cases in the same family. *The Turkish journal of pediatrics* 2012;54:171-6.
15. Kord Valeshabad A, Mazidi A, Kord Valeshabad R, et al. Papillon-lefevre syndrome: a series of six cases in the same family. *ISRN dermatology* 2012;2012:139104.
16. Rawlings ND, Barrett AJ. Evolutionary families of peptidases. *The Biochemical journal* 1993;290 (Pt 1):205-18.
17. Rao NV, Rao GV, Hoidal JR. Human dipeptidyl-peptidase I. Gene characterization, localization, and expression. *The Journal of biological chemistry* 1997;272:10260-5.
18. Dolenc I, Turk B, Pungercic G, Ritonja A, Turk V. Oligomeric structure and substrate induced inhibition of human cathepsin C. *The Journal of biological chemistry* 1995;270:21626-31.
19. Muno D, Ishidoh K, Ueno T, Kominami E. Processing and transport of the precursor of cathepsin C during its transfer into lysosomes. *Archives of biochemistry and biophysics* 1993;306:103-10.
20. Pham CT, Ley TJ. Dipeptidyl peptidase I is required for the processing and activation of granzymes A and B in vivo. *Proceedings of the National Academy of Sciences of the United States of America* 1999;96:8627-32.
21. Jouary T, Goizet C, Coupry I, et al. Detection of an intragenic deletion expands the spectrum of CTSC mutations in Papillon-Lefevre syndrome. *The Journal of investigative dermatology* 2008;128:322-5.

22. Tye CE, Pham CT, Simmer JP, Bartlett JD. DPPI may activate KLK4 during enamel formation. *Journal of dental research* 2009;88:323-7.
23. Methot N, Rubin J, Guay D, et al. Inhibition of the activation of multiple serine proteases with a cathepsin C inhibitor requires sustained exposure to prevent pro-enzyme processing. *The Journal of biological chemistry* 2007;282:20836-46.
24. Saatci P, Arli AO, Demir K, Saatci AO, Kavakcu S. Corneal involvement in Papillon-Lefevre syndrome. *Journal of pediatric ophthalmology and strabismus* 2006;43:167-9.
25. Eick S, Puklo M, Adamowicz K, et al. Lack of cathelicidin processing in Papillon-Lefevre syndrome patients reveals essential role of LL-37 in periodontal homeostasis. *Orphanet journal of rare diseases* 2014;9:148.
26. Shanavas M, Chatra L, Shenai P, Kumar S, Bilahari N, Balakrishnan S. Partial expression of the Papillon-Lefevre syndrome. *Journal of the College of Physicians and Surgeons--Pakistan : JCPSP* 2014;24 Suppl 3:S230-2.
27. Jose J, Bartlett K, Salgado C, Gutierrez NM. Papillon-Lefevre Syndrome: Review of Imaging Findings and Current Literature. *Foot & ankle specialist* 2014.
28. Raganatha S, Ramesh M, Anupama P, Kapoor M, Bhat M. Papillon-Lefevre syndrome with homozygous nonsense mutation of cathepsin C gene presenting with late-onset periodontitis. *Pediatric dermatology* 2015;32:292-4.

FIGURE LEGENDS

Figure 1: CatC in urine from healthy subjects. Immunoblots of 20 fold-concentrated samples of urine collected from healthy control subjects, using different anti-CatC antibodies; Ab1 recognizes an epitope on the heavy chain (**A**); Ab2 is directed to the propeptide region (**B**); Ab3 binds to another epitope on the heavy chain of CatC (**C**). Recombinant CatC was used as a control (left lane).

Figure 2: Continuous presence of CatC in urine from healthy children and adults. (**A**) Immunoblots of 20 fold-concentrated samples of urine collected from healthy children at the age of 3 months (3 mo), 1 year (1 yr) and 3 years (3 yr) compared to a healthy adult, using anti-CatC Ab1. (**B**) Immunoblots of 20 fold-concentrated samples of urine collected at different times of the day from one healthy woman and one healthy man, using anti-CatC Ab1. Recombinant CatC was used as a control. (**C**) CatC activity in 20 fold-concentrated urines from 50 healthy control subjects using the fluorogenic substrate Gly-Phe-AMC (30 μ M) and its inhibition by E64c (100 μ M) and Thi-Phe-CN (5 μ M).

Figure 3: Absence of CatC in urine from a PLS patient. (**A**) Protocol for analysis of urinary CatC. After receipt of PLS samples, urines were centrifuged to eliminate cells and debris, and then concentrated 120 times, six times more than the urine of healthy subjects, to analyze the presence and the proteolytic activity of CatC as described in the materials and methods section. Immunoblots of 20 fold-concentrated samples of urine collected from two healthy control subjects (controls Ct1 and Ct2) and of 120 fold-concentrated samples of urine collected from one representative PLS patient (P#23), using anti-CatC Ab1 (**B**), Ab2 (**C**) and Ab3 (**D**). Recombinant CatC was used as a control. (**E**) CatC activity in 20 fold-concentrated urines from one healthy control subject (Ct1) and of 120 fold-concentrated samples of urine collected from one representative PLS patient (P#23) using the fluorogenic substrate Gly-Phe-AMC (30 μ M).

Figure 4: Presence of CatC in urine from an atypical French patient without CTSC mutation. (**A**) Pedigree of suspected 16 yr-old individual (P#31) with suspected PLS. (**B**) The dermatological and dental features of the patient (P#31) and his mother. (**C**) Immunoblotting analysis with anti-CatC Ab1 of 120 fold-concentrated urines from the patient (P#31) compared to 20 fold-concentrated urines from a healthy control subject (Ct). (**D**) Western blotting of white blood cell lysates from the P#31 patient, his mother and a healthy control subject (Ct) using anti-CatC Ab1. Recombinant CatC was used as a control.

TABLE I
Demographic and clinical data of patients with a PLS phenotype

Patients	Ethnicity	Gender	Age	Clinical manifestations	Mutation	Urinary CatC	
						Pro CatC	Mature CatC
P#1	French	F	55	Palmoplantar hyperkeratosis, severe periodontitis	c.96T>G ^(a) (p.Y32X) Nonsense	-	-
P#2	Indian	M	15	Transgradient palmoplantar keratoderma, periodontitis	c.912C>A ⁽¹⁾ (p.Y304X) Nonsense	-	-
P#3	Hungarian	F	4	Palmoplantar hyperkeratosis, periodontitis	c.681delCATACAT ⁽²⁾ (p.T188fsX199) Frameshift	-	-
P#4	Hungarian	F	13	Palmoplantar hyperkeratosis, severe periodontitis	c.681delCATACAT ⁽²⁾ (p.T188fsX199) Frameshift	-	-
P#5	Pakistani	F	14	Palmoplantar hyperkeratosis, periodontitis	(p.W433L) ⁽³⁾ Missense	-	-
P#6	Pakistani	M	9	Palmoplantar hyperkeratosis, periodontitis, cerebral abscess	c.815G>C ⁽⁴⁾ (p.R272P) Missense	-	-
P#7	Pakistani	M	15	Palmoplantar hyperkeratosis, periodontitis	c.815G>C (p.R272P) Missense	-	-
P#8	Pakistani	F	15	Transgradient palmoplantar keratoderma, periodontitis	c.815G>C (p.R272P) Missense	-	-
P#9	Italian	F	42	Palmoplantar hyperkeratosis, severe periodontitis	c.1141delC ⁽⁵⁾ (p.L381fsX393) Frameshift	-	-
P#10	Hungarian	F	12	Palmoplantar hyperkeratosis, severe periodontitis	c.901G>A ⁽⁶⁾ (p.G301S) Missense	-	-
P#11	Hungarian	F	4	Palmoplantar hyperkeratosis, severe periodontitis	c.901G>A ⁽⁶⁾ (p.G301S) Missense	-	-
P#12	Erythrean	M	12	Palmoplantar hyperkeratosis, severe periodontitis, Tinea capitis	c.755A>T ⁽⁷⁾ (p.Q252L) Missense	-	-
P#13	Erythrean	M	15	Palmoplantar hyperkeratosis, severe periodontitis	c.755A>T ⁽⁷⁾ (p.Q252L) Missense	-	-
P#14	Moroccan	M	19	Mild palmoplantar hyperkeratosis, severe periodontitis	c.854C>T ⁽⁸⁾ (p.P285L) Missense	-	-
P#15	Moroccan	M	35	Palmoplantar hyperkeratosis, severe periodontitis, edentulous by now	c.854C>T ⁽⁸⁾ (p.P285L) Missense	-	-
P#16	German	F	24	Palmoplantar hyperkeratosis, severe periodontitis, edentulous by now	c.566-572Del ⁽⁹⁾ (T189FS199X) Frameshift	-	-
P#17	German	M	48	Severe palmoplantar hyperkeratosis, late onset of	comp. heterozygous ⁽¹⁰⁾	-	-

				severe periodontitis (22 years of age), liver abscess	c.322A>T/c.436delT (p.K108X/p.S146fs153X) ⁽¹⁰⁾ Nonsense / Frameshift		
P#18	German	M	27	Palmoplantar hyperkeratosis, severe periodontitis	comp. heterozygous ⁽¹⁰⁾ c.947T>G (p.L316R) c.1268G>C (p.W423S) Missense	-	-
P#19	Chinese	M	22	Palmoplantar psoriasiform appearance, severe periodontitis	c.394 C>G ⁽¹¹⁾ (p.R132G) Missense	-	-
P#20	Chinese	M	22	Palmoplantar psoriasiform appearance, severe periodontitis	c.394 C>G ⁽¹¹⁾ (p.R132G) Missense	-	-
P#21	Mauritian	M	5	Palmoplantar hyperkeratosis, severe periodontitis	n.i	-	-
P#22	Mauritian	F	15	Palmoplantar hyperkeratosis, severe periodontitis	n.i	-	-
P#23	Puerto Rican	F	31	Palmoplantar hyperkeratosis, severe periodontitis	c.116G>C ^(a) (p.W39S) Missense	-	-
P#24	Persian	F	33	Palmoplantar hyperkeratosis, severe periodontitis	c.815G>C ^(a) (p.R272P) Missense	-	-
P#25	Persian	M	9	Palmoplantar hyperkeratosis, severe periodontitis	c.815G>C ^(a) (p.R272P) Missense	-	-
P#26	Persian	M	4	Palmoplantar hyperkeratosis, severe periodontitis	c.815G>C ^(a) (p.R272P) Missense	-	-
P#27	Saudi arabian	M	17	Palmoplantar hyperkeratosis, severe periodontitis	c.815G>C ^(a) (p.R272P) Missense	-	-
P#28	Saudi arabian	M	24	Palmoplantar hyperkeratosis, severe periodontitis	c.815G>C ^(a) (p.R272P) Missense	-	-
P#29	Pakistanian	M	3	Palmoplantar hyperkeratosis, severe periodontitis	n.i	-	-
P#30	Turkish	M	20	Palmoplantar hyperkeratosis, severe periodontitis, corneal leukoma	No mutation ^(a)	+	+
P#31	French	M	16	Palmoplantar psoriasiform appearance, anomalies of deciduous teeth with no net periodontitis	No mutation ^(a)	+	+

P#12 and P#13 / P#14 and P#15 are brothers
P#3 and P#4 are sisters

P#24, P#25 and P#26 are in the same family

(a)/identified in this work

(1) Ragunatha et al., 2014

(2) Farkas et al., 2013

(3)

(4) Kanthimathinathan et al., 2013

(5) Bullon et al., 2013

(6)

(7) Schacher et al., 2006

(8) Noack et al., 2008

(9) Rüdiger et al., 1999

(10) Noack et al., 2008

(11) Xinwen et al., 2015

FIGURE 1

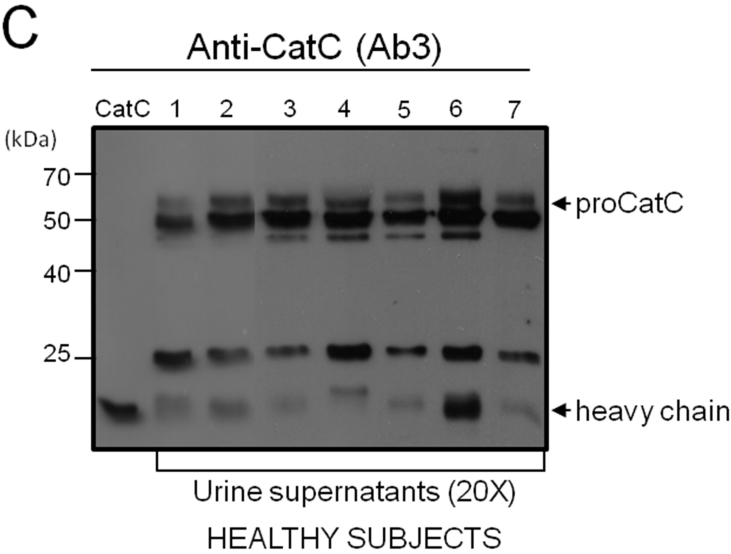
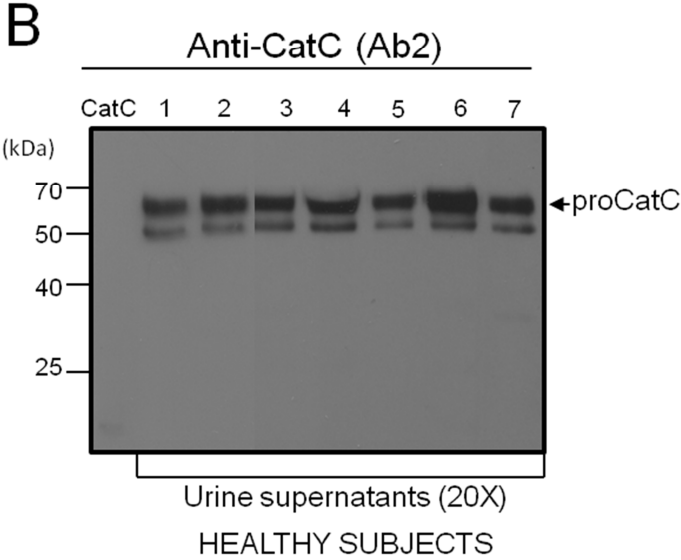
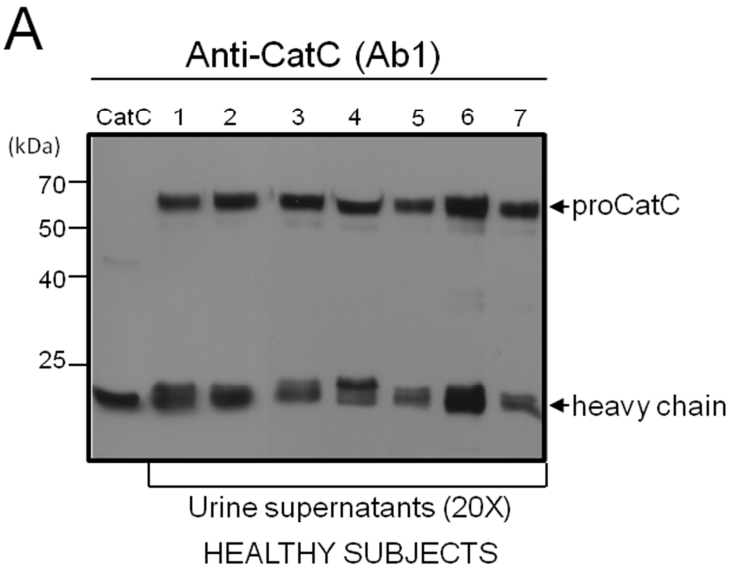


FIGURE 2

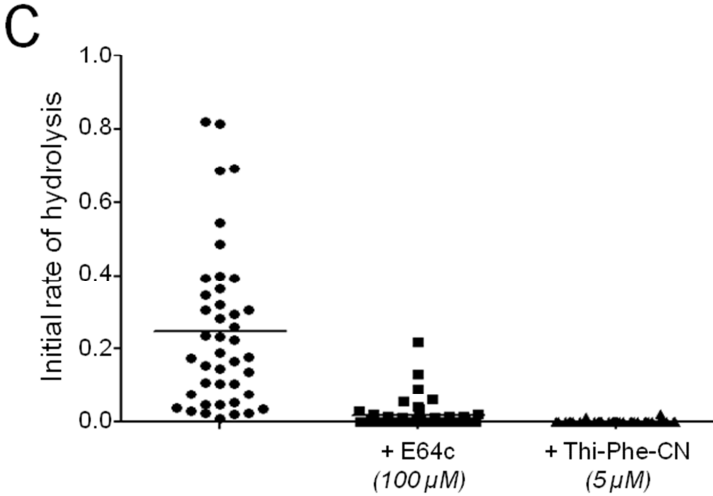
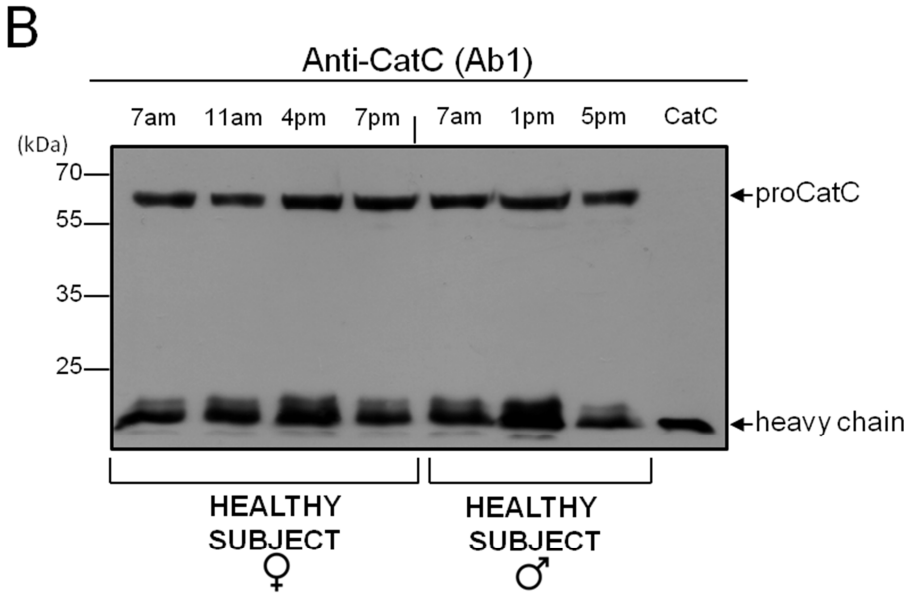
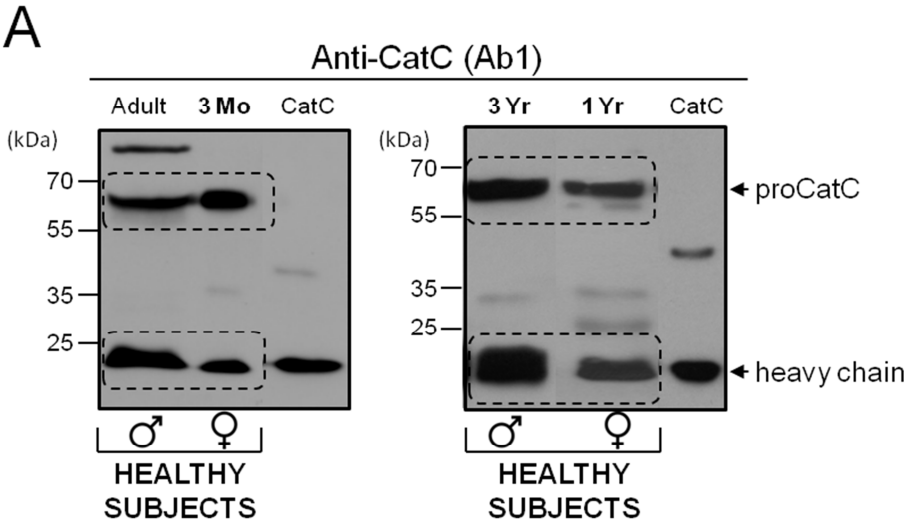


FIGURE 3

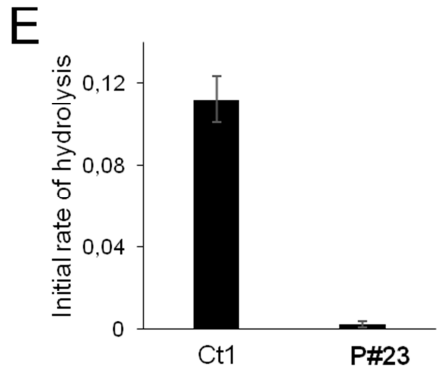
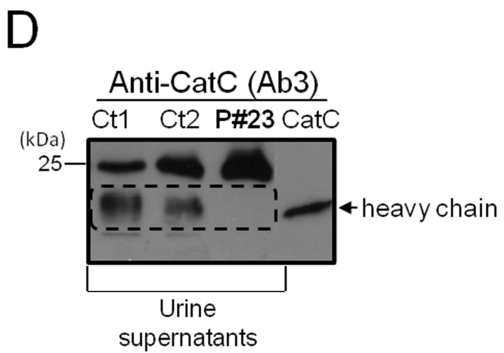
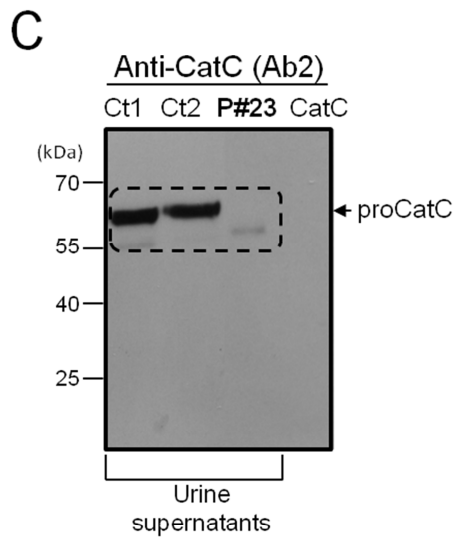
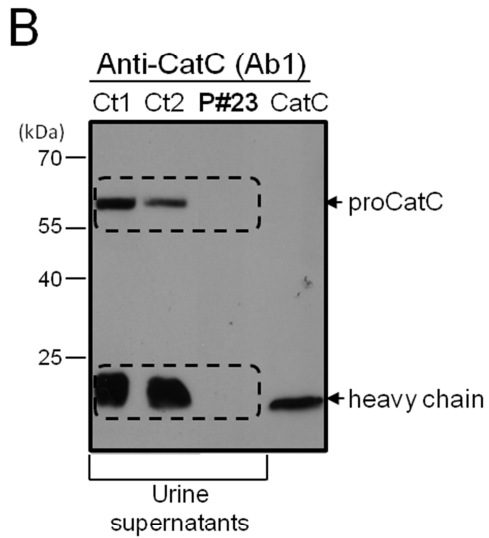
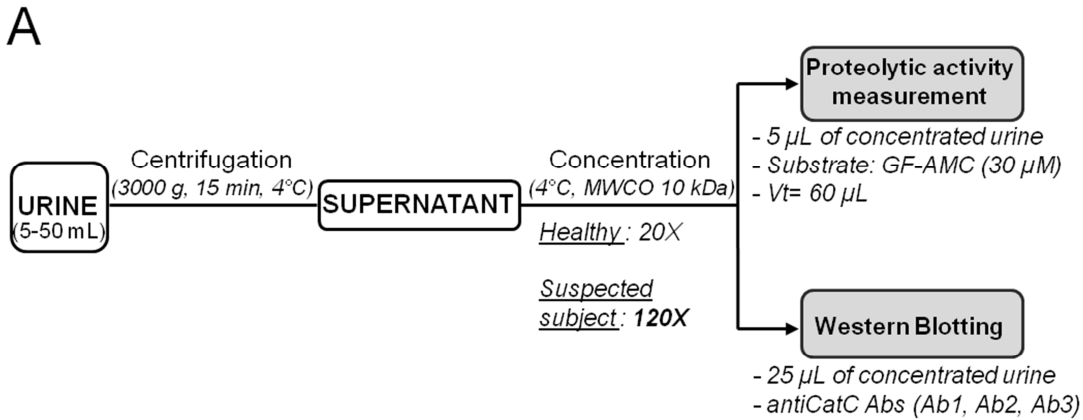


FIGURE 4

