



Contents lists available at ScienceDirect

IDCases

journal homepage: www.elsevier.com/locate/idcr

Case Report

Zika virus infections imported from Brazil to Portugal, 2015



L. Zé-Zé^{a,b,*}, M.B. Prata^c, T. Teixeira^d, N. Marques^c, A. Mondragão^d, R. Fernandes^d,
J. Saraiva da Cunha^c, M.J. Alves^a

^a Centro de Estudos de Vectores e Doenças Infecciosas, Instituto Nacional de Saúde Dr. Ricardo Jorge, Águas de Moura, Portugal

^b Biosystems & Integrative Sciences Institute, University of Lisbon, Faculty of Sciences, Campo Grande, Lisbon, Portugal

^c Serviço de Doenças Infecciosas, Centro Hospitalar e Universitário de Coimbra, Coimbra, Portugal

^d Unidade de Doenças Infecciosas/Serviço de Medicina Interna, Centro Hospitalar de Vila Nova de Gaia/Espinho, Vila Nova de Gaia, Portugal

ARTICLE INFO

Article history:

Received 14 March 2016

Received in revised form 30 March 2016

Accepted 30 March 2016

Available online

Keywords:

Zika virus

Arbovirus

Imported cases

ABSTRACT

Zika virus is an emerging arbovirus transmitted by *Aedes* sp. mosquitoes like the Dengue and Chikungunya viruses. Zika virus was until recently considered a mild pathogenic mosquito-borne flavivirus with very few reported benign human infections. In 2007, an epidemic in Micronesia initiated the turnover in the epidemiological history of Zika virus and more recently, the potential association with congenital microcephaly cases in Brazil 2015, still under investigation, led the World Health Organization (WHO) to declare a Public Health Emergency of International Concern on February 1, 2016.

Here, we present the clinical and laboratory aspects related to the first four imported human cases of Zika virus in Portugal from Brazil, and alert, regarding the high level of traveling between Portugal and Brazil, and the ongoing expansion of this virus in the Americas, for the threat for Zika virus introduction in Europe and the possible introduction to Madeira Island where *Aedes aegypti* is present.

© 2016 The Authors. Published by Elsevier Ltd. This is an open access article under the CC BY-NC-ND license (<http://creativecommons.org/licenses/by-nc-nd/4.0/>).

Introduction

Zika virus (ZIKV) is a member of the Spondweni serocomplex within the genus *Flavivirus* firstly isolated in 1947 from a sentinel rhesus monkey in Zika Forest, Uganda [1]. There are two main lineages of ZIKV, the African and the Asian lineages [2,3].

ZIKV was until recently considered a mildly pathogenic mosquito-borne flavivirus with very few reported human cases of self-limiting acute febrile illnesses most often with maculopapular rash, headache, arthralgia, myalgia and conjunctivitis [4–6]. In 2007, after an epidemic in Micronesia [7,8] the geographic range of ZIKV expanded dramatically. In 2013–2014, through an outbreak in French Polynesia a link relating ZIKV infections with the increased incidence of Guillan-Barré syndrome and other neurological complications was assumed mainly in regions with previous dengue epidemics [9,10]. The potential association with congenital microcephaly cases in Brazil 2015 [11,12], still under investigation, raise several questions, that undoubtedly increase public health awareness to ZIKV, and led the WHO declaration, considering “the

recent cluster of microcephaly cases and other neurological disorders reported in Brazil, following a similar cluster in French Polynesia” a Public Health Emergency of International Concern on February 1, 2016 [13]. As most pathogenic flavivirus, only a small percentage of ZIKV cases (estimated to be about 25%) are symptomatic [8], and transmission via transfusion of infected blood or organs donations, or sexual transmission, remains a risk.

Here we report four cases of patients with Zika infection, diagnosed in Portugal, shortly after returning from Brazil. In June 2015, Zika virus infection was serologically detected for the first time in a couple returning from Ceará state and in the end of 2015, Zika virus was detected in the urine samples of two patients after visiting Rio de Janeiro and Espírito Santo states.

Case presentation

Cases 1 and 2

In June 2015, a Portuguese couple in their sixties with no past medical history, traveled to northeast Brazil (Ceará State) on holidays for two weeks. At midstay (day 1 of illness) both developed fever (38.3 °C) and arthralgias. The fever lasted for three days, responding to acetaminophen and ibuprofen. Arthralgias were located in the hands, wrists and ankles, lasting till admission. At day 4, they complained of macular rash with no pruritus,

* Corresponding author at: Centro de Estudos de Vectores e Doenças Infecciosas, Instituto Nacional de Saúde Dr. Ricardo Jorge, Avenida Liberdade 5, 2965-575 Águas de Moura, Portugal. Tel.: +351 265938295; fax: +351 265912155.

E-mail address: libia.zeze@insa.min-saude.pt (L. Zé-Zé).

predominantly on the lower limbs in the woman, and on the trunk in the man. Both reported anorexia with weight loss and the man felt asthenic.

Upon admission in Portugal, on day 11 of illness, they both appeared sick and tired with dry mucosae and lower extremity rashes below the knee. The laboratory findings in the hospital were within normal limits, except for C-reactive protein 10.6 mg/L (norm: <5 mg/L) and slightly elevated aminotransferase, ALT 58 U/L for the man and 52 U/L for the woman (norm: 4–50 U/L). Specific diagnostic was requested for Dengue, Zika and Chikungunya viruses. Serology was IgM positive for Zika virus in both patients. The patients recovered without complications.

Case 3

A 62 year old Brazilian woman, with a past medical history of systemic lupus erythematosus, fibromyalgia, cardiomyopathy and hyperuricemia who had lived in Portugal for the last 15 years, developed fever, myalgias and arthralgias on November 22 2015 after a month trip to Rio de Janeiro and Espírito Santo states (southeast Brazil). The next day, she developed a maculopapular

rash, more prominent on the forearms and thighs with mild conjunctival hyperemia. In the ER, on the fourth day of illness, she was afebrile and hemodynamically stable. Basic laboratory workup did not revealed leukopenia, thrombocytopenia or abnormal liver enzymology. The fever continued for eight days in total, with bi-daily peaks. The rash remained from the second to the sixth day of illness, as well as myalgias. Differential serological diagnosis was requested for *Trypanosoma* sp., Chikungunya, Dengue and Zika viruses. The serology (ELISA) for *Trypanosoma* sp. was negative. Real-time PCR in urine and IgG serology were positive for Zika virus.

The patient had only symptomatic treatment with paracetamol and full recovery without sequel. She kept her long term medication with chloroquine sulphate, digoxin, candesartan, carvedilol, furosemide, trazodone, duloxetine and alopurinol.

Case 4

A 57 year old Portuguese man, with no past medical history, presented on December 7 2015 complaining of chills, generalized asthenia and myalgia and rash, one day after returning from Rio de Janeiro after a 10 day stay. The study in the hospital revealed

Table 1

Characteristics of the four imported cases of Zika virus infections based on epidemiological, clinical and virological data.

	Case 1	Case 2	Case 3	Case 4
Epidemiological data				
Gender	Male	Female	Female	Male
Age	61 years	59 years	62 years	57 years
Date of return	26 Jun. 2015	26 Jun. 2015	22 Nov. 2015	6 Dec. 2015
Onset of symptoms	19 Jun. 2015	19 Jun. 2015	22 Nov. 2015	7 Dec. 2015
Clinical data				
Fever	3 days	3 days	8 days	5 days
Arthralgia	Hands, wrists and ankles	Hands, wrists and ankles	Discrete	–
Myalgias	No	No	Yes	Generalized
Skin rash	Maculopapular: trunk	Maculopapular: lower limbs	Maculopapular: forearms and thighs	Maculopapular: generalized
Anorexia	Yes	Yes	No	No
Asthenia	Yes	No	No	Yes
Conjunctivitis	No	No	Yes	No
Leucopenia	No	No	No	No
Thrombocytopenia	No	No	No	126 000/μL
Elevated liver enzymes	ALT 58 U/L	ALT 52 U/L	No	No
Viral investigation				
1st sample (days post onset)				
Zika virus				
RT-PCR blood	–	–	NS	–
RT-PCR urine	NS	NS	+(Ct = 34.76)	+(Ct = 34.57)
IgM ^a	+128	+64	–	–
IgG ^b	+512	+512	+262,144	–
Dengue virus				
RT-PCR blood	–	–	NS	–
RT-PCR urine	NS	NS	–	–
IgM	–	–	–	–
IgG	+64	+256	+131,072	–
Chikungunya virus				
RT-PCR blood	–	–	–	–
RT-PCR urine	NS	NS	NS	ND
IgM	–	–	–	–
IgG	–	–	–	–
2nd sample (days post onset)				
Zika virus				
IgM	+64	+32	NS	+32
IgG	+1024	+512	NS	–
Dengue virus				
IgM	–	–	NS	+16
IgG	+64	+128	NS	–
3rd sample (days post onset)				
Zika virus				
IgM	NS	NS	NS	+32
IgG	NS	NS	NS	+64
Dengue virus				
IgM	NS	NS	NS	–
IgG	NS	NS	NS	–

(+) positive; (–) negative; Ct: cycles threshold; ND: not determined; NS: not sampled.

^a IgM cut-off value 16.

^b IgG cut-off value 32.

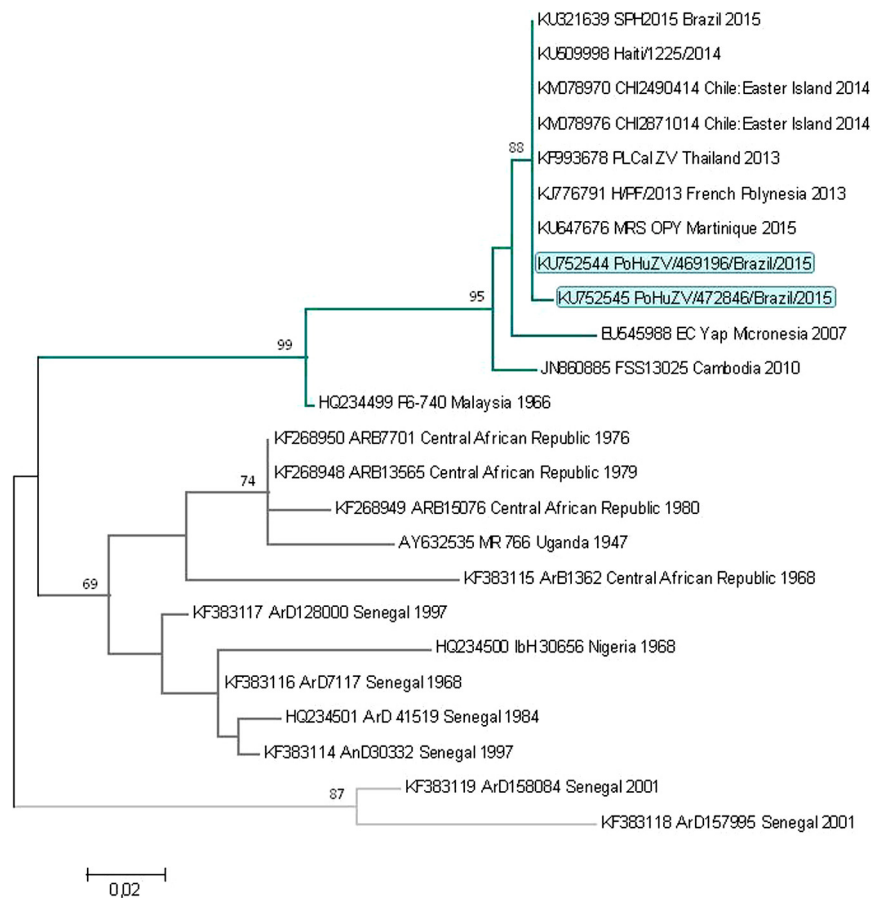


Fig. 1. Maximum likelihood phylogeny of Zika virus sequences imported from Brazil to Portugal, 2015. Maximum-likelihood phylogenetic tree was inferred based on partial non-structural protein (NS5) nucleotide sequences (205 bp) by using Molecular Evolutionary Genetics Analysis (MEGA) version 6 software. Distance matrices were calculated using Kimura two-parameter model with invariant sites. Bootstrap values obtained from 1000 replicate trees are shown for key nodes. Scale is shown at the bottom as substitutions per site. The Asian cluster is shown in blue and the African clusters as dark and light gray. The sequences derived from the imported cases of Zika virus are highlighted in blue.

thrombocytopenia (126 000/ μL), without leukopenia or abnormal liver enzymology. Real-time PCR was positive for Zika virus in the urine sample.

The patient received supportive treatment, improving clinically to symptoms free.

Previous flavivirus infections and vaccination against flaviviruses (yellow fever, tick-borne encephalitis and Japanese encephalitis viruses) were not reported by any of the patients. The data of these four imported cases to Portugal is summarized in Table 1.

Molecular and serologic diagnostics

In the National Institute of Health, sera samples were tested by immunofluorescent assay (IFA) in-house (IgG and IgM) for Zika virus (ZIKV), Dengue (DENV) and Chikungunya viruses (CHIKV) (Table 1). The presence of immunoglobulins specific to other flaviviruses, such as yellow fever (YFV), tick-borne encephalitis (TBEV) and West Nile (WNV) viruses was also tested by IFA and all assay results were negative for IgM and presented cross-reaction signals in IgG.

Nucleic acids were extracted from 400 μL of ethylenediaminetetraacetic acid (EDTA) blood samples and 900 μL urine samples using NucliSens easyMAG platform (BioMérieux). The presence of ZIKV RNA was checked by real-time RT-PCR [14] and conventional reverse transcription-polymerase chain reaction (RT-PCR) using

Zika specific primers [15] and pan-flavivirus primers [16] targeting the non-structural protein 5 (NS5) gene. The presence of DENV and CHIKV RNA was checked by real-time PCR as reported previously [16], and by conventional RT-PCR [17], respectively. For cases 1 and 2, Zika RT-PCR was negative (conventional and real time RT-PCR) on blood samples collected on day 13 post onset of disease. For cases 3 and 4, real time RT-PCR and conventional RT-PCR were positive in urine samples on day 8 and 9 post onset, respectively. The nested-PCR fragments (overlapping NS5, 205 bp) was sequenced bi-directionally and submitted to GenBank (accession numbers KU752544 and KU752545). Similarity searches were made within the GenBank data set using the basic local alignment search tool (BLAST) BLASTN algorithm [18]. Maximum likelihood analysis was performed with Kimura two-parameter model with invariant sites using Mega version 6 software [19]. The robustness of the nodes was tested by 1000 bootstrap replications.

Discussion

In the reported cases 1 and 2, although not confirmed by molecular detection, the compatible clinical criteria, the presence of IgM only for ZIKV, and the observed seroconversion (although not with a four-fold or greater change antibody titers in paired sera) proves the detection of two primary flavivirus infections. Zika virus infection in case 3 was evident by the positive urine sample by PCR identified as belonging to the Asian lineage (Fig. 1). This was

the first analyzed PCR positive sample in the laboratory and the only ZIKV strain previously worked (MR 766) belongs to the African lineage, ruling out any possibility of PCR contamination. Besides the molecular diagnosis, the serological results with high positive IgG values (262,144 for ZIKV and 131,072 for DENV; cut-off = 32) and negative IgM titers (cut-off = 16), strongly suggest a secondary infection by ZIKV after a probable primary DENV infection. Cross-reaction IgG antibody titers were much lower for other flaviviruses (4096 for YFV, TBEV and WNV). In case 4 the first sample, RT-PCR for ZIKV was positive in urine (9 days post onset) and negative in blood. Seroconversion was observed in the second and third samples, firstly by only IgM positive detection (11 days post onset) followed by IgG detection (52 days post onset).

Clinicians' awareness in including Zika virus, along with dengue and chikungunya viruses in differential diagnoses to patients with febrile syndromes and rash with compatible travel history is vital to enhanced vigilance and promptly detect ZIKV imported cases. On the other hand, as previously noted [20], although imported Zika infection in returned travelers is usually mild, the possibility of sexual transmission and the eventual association with several congenital malformations and microcephaly, still under investigation, raises concern among pregnant and fertile female travelers. Proper advice regarding diagnosis should be provided to pregnant women, as proper perinatal care to all who test positive for Zika virus.

Conclusion

The rapid and ongoing spread of ZIKV in the Americas and South Pacific increases the ZIKV importation in the EU and the risk of autochthonous transmission in regions where *Aedes* mosquitoes are established. In Portugal, this risk is increased given the historical relations between Portugal and Brazil with high trade and travel. Madeira Island is the only region in the EU with established population of *Aedes aegypti* where it was detected for the first time in 2004. In 2012 a dengue outbreak was reported in Madeira [16] most likely imported from Venezuela that is also one of the countries with ongoing Zika outbreak.

The potential epidemiological association of ZIKV infection with severe complications in regions with previous DENV epidemics as Madeira Island and the future increase of imported Zika cases to Europe urge to enhance vector surveillance and awareness among health professionals in this region.

Conflict of interests

The authors declare that there is no conflict of interests regarding the publication of this article.

Consent

Verbal consent was obtained from all the patients and written consent can be provided upon request, however no identifying information or images were used in this case report.

Acknowledgements

None.

References

- [1] Dick GW, Kitchen SF, Haddock AJ. Zika virus I. Isolations and serological specificity. *Trans R Soc Trop Med Hyg* 1952;46(5):509–20.
- [2] Haddock AD, Schuh AJ, Yasuda CY, Kasper MR, Heang V, Huy R, et al. Genetic characterization of Zika virus strains: geographic expansion of the Asian lineage. *PLoS Negl Trop Dis* 2012;6(2):e1477. <http://dx.doi.org/10.1371/journal.pntd.0001477>.
- [3] Faye O, Freire CC, Iamarino A, Faye O, de Oliveira JV, Diallo M, et al. Molecular evolution of Zika virus during its emergence in the 20(th) century. *PLoS Negl Trop Dis* 2014;8(1):e2636. <http://dx.doi.org/10.1371/journal.pntd.0002636>.
- [4] Simpson DI. Zika virus infection in man. *Trans R Soc Trop Med Hyg* 1964;58:335–8.
- [5] Filipe AR, Martins CM, Rocha H. Laboratory infection with Zika virus after vaccination against yellow fever. *Arch Gesamte Virusforsch* 1973;43:315–9.
- [6] Olson JG, Ksiazek TG, Suhandiman, Triwibowo. Zika virus, a cause of fever in Central Java, Indonesia. *Trans R Soc Trop Med Hyg* 1981;75:389–93.
- [7] Lanciotti RS, Kosoy OL, Laven JJ, Velez JO, Lambert AJ, Johnson AJ, et al. Genetic and serologic properties of Zika virus associated with an epidemic, Yap State, Micronesia, 2007. *Emerg Infect Dis* 2008;14(8):1232–9. <http://dx.doi.org/10.3201/eid1408.080287>.
- [8] Duffy MR, Chen TH, Hancock WT, Powers AM, Kool JL, Lanciotti RS, et al. Zika virus outbreak on Yap Island, Federated States of Micronesia. *N Engl J Med* 2009;360(24):2536–43. <http://dx.doi.org/10.1056/NEJMoa0805715>.
- [9] Oehler E, Watrin L, Larre P, Leparc-Goffart I, Lestere S, Valour F, et al. Zika virus infection complicated by Guillain-Barré syndrome—case report, French Polynesia, December 2013. *Euro Surveill* 2014;19(9). <http://dx.doi.org/10.2807/1560-7917.ES2014.19.9.20720>.
- [10] Ios S, Mallet HP, Leparc Goffart I, Gauthier V, Cardoso T, Herida M. Current Zika virus epidemiology and recent epidemics. *Med Mal Infect* 2014;44(7):302–7. <http://dx.doi.org/10.1016/j.medmal.2014.04.008>.
- [11] Pan American Health Organization, World Health Organization. Regional Office for the Americas. Epidemiological alert: neurological syndrome, congenital malformations, and Zika virus infection. Implications for public health in the Americas [Internet]. Washington: World Health Organization; 2015. http://www.paho.org/hq/index.php?option=com_docman&task=doc_download&Itemid=&gid=32405&lang=en [accessed 22.12.16].
- [12] Broutet N, Krauer F, Riesen M, Khalakdina A, Almiron M, Aldighieri S, et al. Zika virus as a cause of neurologic disorders. *N Engl J Med* 2016. <http://dx.doi.org/10.1056/NEJMp1602708>. March 9.
- [13] Heymann DL, Hodgson A, Sall AA, Freedman DO, Staples JE, Althabe F, et al. Zika virus and microcephaly: why is this situation a PHEIC? *Lancet* 2016; 387(1020):719–21. [http://dx.doi.org/10.1016/S0140-6736\(16\)00320-2](http://dx.doi.org/10.1016/S0140-6736(16)00320-2).
- [14] Faye O, Faye O, Diallo D, Diallo M, Weidmann M, Sall AA. Quantitative real-time PCR detection of Zika virus and evaluation with field-caught Mosquitoes. *Virology* 2013;10(1):311. <http://dx.doi.org/10.1186/1743-422X-10-311>.
- [15] Balm MND, Lee CK, Lee HK, Chiu L, Koay ESC, Tang JW. A diagnostic polymerase chain reaction assay for Zika virus. *J Med Virol* 2012;84:1501–5. <http://dx.doi.org/10.1002/jmv.23241>.
- [16] Alves MJ, Fernandes PL, Amaro F, Osorio H, Luz T, Parreira P, et al. Clinical presentation and laboratory findings for the first autochthonous cases of dengue fever in Madeira island, Portugal, October 2012. *Euro Surveill* 2013; 18(6). pii=20398.
- [17] Parola P, de Lamballerie X, Jourdan J, Rovey C, Vaillant V, Minodier P, et al. Novel Chikungunya virus variant in travelers returning from Indian Ocean Islands. *Emerg Infect Dis* 2006;12(10):1493–9. [http://dx.doi.org/10.1016/S0140-6736\(16\)00320-2](http://dx.doi.org/10.1016/S0140-6736(16)00320-2).
- [18] Altschul SF, Madden TL, Schäffer AA, Zhang J, Zhang Z, Miller W, et al. Gapped BLAST and PSI-BLAST: a new generation of protein database search programs. *Nucleic Acids Res* 1997;25:3389–402.
- [19] Tamura K, Stecher G, Peterson D, Filipski A, Kumar S. MEGA6: Molecular Evolutionary Genetics Analysis version 6.0. *Mol Biol Evol* 2013;30(12):2725–9. <http://dx.doi.org/10.1093/molbev/mst197>.
- [20] Goorhuis A, von Eije KJ, Douma RA, Rijnberg N, van Vugt M, Stijns C, et al. Zika virus and the risk of imported infection in returned travellers: implications for clinical care. *Travel Med Infect Dis* 2016;14:13–5. <http://dx.doi.org/10.1016/j.tmaid.2016.01.008>.