

Received Date : 11-Jan-2013

Revised Date: 25 Jan 2013

Finally Revised Date : 07-Mar-2013

Accepted Date : 13-Mar-2013

Article type : A

Overexpression of the Insulin-like growth factor 1 receptor (IGF-1R) is associated with malignancy in familial pheochromocytomas and paragangliomas.

María Celia Fernandez M.Sc.¹, Ayelen Martin M.Sc.¹, Marcela Venara MD PhD¹, María Luján Calcagno M.Sc.³, Gabriela Sansó PhD¹, Silvina Quintana M.Sc.², Héctor E. Chemes MD PhD¹, Marta Barontini MD PhD¹ and Patricia A. Pennisi PhD¹.

1. Centro de Investigaciones Endocrinológicas CEDIE-CONICET. Hospital de Niños Dr. R. Gutierrez, Gallo 1360 C1425EFD, Buenos Aires, Argentina.

2. Laboratorio de Biología Molecular. Fares Taie Instituto de Análisis. Rivadavia 3343 - Mar del Plata, CP7600. Provincia de Buenos Aires, Argentina

3. Cátedra de Matemática, Facultad de Farmacia y Bioquímica. Universidad de Buenos Aires. Junin 956, C1113AAD, Buenos Aires, Argentina.

This article has been accepted for publication and undergone full peer review but has not been through the copyediting, typesetting, pagination and proofreading process, which may lead to differences between this version and the Version of Record. Please cite this article as doi: 10.1111/cen.12205

© 2013 Blackwell Publishing Ltd

Accepted Article

Correspondence: Patricia A. Pennisi, PhD. CEDIE-CONICET. Hospital de Niños "Dr. Ricardo Gutiérrez". Gallo 1360. C1425EFD, Buenos Aires, Argentina. TE. +54 11 4963 5931 ext 121; FAX: +54 11 4963 5930. Email:ppennisi@cedie.org.ar

Short Title: IGF-1R expression in pheochromocytoma/paraganglioma

Key Words: IGF-1 receptor, pheochromocytoma, paraganglioma, metastasis, immunohistochemistry.

Declarations of Interests: all authors involved in this study declare that there is no conflict of interest that could be perceived as prejudicing the impartiality of the research reported.

ABSTRACT

Context: Pheochromocytomas and paragangliomas (pheo/pgl) are neuroendocrine tumors derived from chromaffin cells. Although mostly benign, up to 26% of pheo/pgl will undergo malignant transformation. Reliable histological signs to differentiate benign pheo/pgl from malignant tumors are currently lacking. Increased IGF-1R expression has been shown during progression to metastatic phenotypes of several types of cancer. Objective: to analyze the distribution and expression of the IGF-1R in pheo/pgl of different genetic origin and degree of malignancy. Measurements: we studied the expression of the IGF-1R protein by immunohistochemistry, in 40 primary tumors from patients with pheo/pgl from different genetic etiology (11/29 metastatic/non-metastatic disease). Results: We found a strong association

between increased expression of IGF-1R and malignant behavior regardless the age at diagnosis and the genetic etiology. IGF-1R labeling was mostly weak in primary tumors from patients with non-metastatic pheo/pgl. Conversely, intense IGF-1R labeling was predominant in cases of pheo/pgl with confirmed metastatic disease. The risk of metastases was 11.7 times higher if tumor IGF-1R labeling was intense independently of age at diagnosis. The probability of remaining free of metastases was higher in patients with pheo/pgl scored weak for IGF-1R at 60 months and more than two fold higher at 120 months of follow-up than in patients with intense IGF-1R labeling in their primary tumors. Conclusions: Our results strongly suggest that IGF-1R is associated with malignancy in familial pheo/pgl and that IGF-1R expression in the primary tumor might be a useful tool to detect those patients harboring pheo/pgl that have an increased risk of metastasis.

INTRODUCTION

Pheochromocytomas (pheo), that derive from chromaffin cells in the adrenal medulla, and paragangliomas (pgl), that arise from extra-adrenal chromaffin tissue, are tumors that synthesize, store, metabolize and secrete catecholamines.

For a long time pheo/pgl were considered mostly as sporadic tumors, and hereditary in only about 10% of patients ¹. Familial pheo/pgl can appear as part of the Multiple Endocrine Neoplasia type 2 syndrome (MEN2) A or B, caused by mutations of the protooncogene *RET* ²; the von Hippel-Lindau disease (VHL), caused by mutations of the suppressor *VHL* gene ³; or more rarely, neurofibromatosis type I ⁴. Also, the appearance of pheo/pgl has been described in another neuroendocrine related disease, the Familial neck and head Paraganglioma, caused by mutations at the D, B, A and C subunits of the succinate dehydrogenase (*SDHD*, *SDHB*, *SDHA* and *SDHC*) ⁵. More recently, germline mutations of the novel transmembrane-encoding gene

FP/TMEM127, SDHAF2, KIF1B beta and MAX genes have been described in familial and sporadic pheo/pgl⁶⁻⁹.

Although mostly benign, up to 26% of pheo/pgl tumors have been reported as malignant¹⁰. Malignancy in pheo/pgl is assessed based on the appearance of distant metastasis where the chromaffin tissue is normally absent¹¹. The greater risk of malignancy has been reported in extra-adrenal sympathetic pgl¹⁰. Moreover, SDHB-related sympathetic pgl has shown to bear the highest risk for malignancy, representing more than 50% of malignant pheo/pgl reported¹². Several arguments are in favor of an implication of epithelial-mesenchymal transition (EMT) in pheochromocytoma and paraganglioma malignancy. EMT is a physiologic process that normally contributes to the development of the embryo and may contribute to the development of certain pathological conditions such as fibrosis and cancer¹³. A recent study also revealed that EMT is specifically induced in succinate dehydrogenase subunit B (SDHB)-related metastatic tumors¹⁴.

Insulin-like growth factors 1 and 2 (IGF-1 and IGF-2) are insulin related polypeptides that play an important role in both, regulation of cell proliferation and inhibition of programmed cell death¹⁵. Alterations in the expression of IGF-1 and IGF-2 and their type 1 receptor (IGF-1R) in tumor cells as well as their relevance in tumor growth have been demonstrated in different cancer types. Using a murine pheochromocytoma cell line (MPC cells) and a Liver-IGF-1-Deficient (LID) mouse model that has a 75% reduction in circulating IGF-1 levels, we have recently provided insight into the critical role of the IGF-1/IGF-1R circuit in maintaining tumor phenotype and survival of already transformed pheochromocytoma cells and its requirement for the initial establishment of these tumors¹⁶.

Increased IGF-1R expression has been shown during progression to metastatic phenotypes of

several types of cancer¹⁵. The role of the IGF family ligands, has also been shown in some experimental models with regard to the induction of EMT. Recently, it was also shown that constitutively active IGF-1R causes cell transformation and EMT in a normal epithelial breast cell line, which is significant, as relatively few oncogenes, when expressed alone, have been shown to cause in vivo tumorigenic potential in MCF10A cells¹⁷.

Based on these evidences, we hypothesize that IGF-1R expression is higher in malignant compared to benign familial pheo/pgl. To test this hypothesis, we analyzed, by immunohistochemistry, the expression of IGF-1R in primary tumors from patients harboring pheo/pgl of different genetic origin and degree of malignancy.

PATIENTS AND METHODS

Experimental Design: We performed a cohort study in a tertiary pediatric hospital in Buenos Aires, Argentina. Eligible patients were all index cases with a diagnosis of pheo/pgl referred to the Centro de Investigaciones Endocrinológicas, Hospital de Niños Ricardo Gutiérrez, from January 1985 to December 2011, from whom paraffin embedded tissue from primary tumors was available for immunohistochemistry and clinical charts with follow-up after the diagnosis were accessible. Exclusion criteria were insufficient or low quality tumor tissue in the paraffin blocks, and diagnosis of metastasis not confirmed by scintigraphy or histology.

The protocol was approved by the Ethical Committee of the Hospital de Niños Ricardo Gutiérrez, and conducted according to the Ethical Principles for Medical Research Involving Human Subjects of the World Medical Association Declaration of Helsinki. Patients, parents or legal guardians were informed, and signed an informed consent.

Exposure and outcome measures: Intensity of IGF-1R immunohistochemical labeling was scored as weak when the staining was more intense than that of the normal adrenal medulla but less intense than that of the normal adrenal cortex processed on the same slide, or as intense when it was similar to that observed in the normal adrenal cortex processed on the same slide, in at least one area.

Malignant disease was defined as the presence of pheo/pgl at sites distant from the primary tumor where the chromaffin tissue is normally absent, according to the World Health Organization¹⁸. All other cases were considered as benign, including patients with recurrences, defined as the reappearance of disease in the former primary tumor localization, after complete tumor eradication and normalization of biochemical tests.

Data sources: Clinical records were examined to obtain standard demographic data and information on presenting signs and symptoms, metastatic disease or recurrences. The diagnosis of pheo/pgl was made on the basis of laboratory determinations of urinary and/or plasma catecholamines and their metabolites¹⁹ and confirmed by histology after surgery. No patient underwent cortex-sparing surgery. Follow-up was performed annually, involving physical examination and urinary catecholamine measurements. Diagnosis of metastasis or recurrences was ascertained in the presence of the biochemical and clinical features by imaging and functional studies (scintigraphy) for localization and histological confirmation. Hepatic metastases were always confirmed by histology.

Samples from the primary tumors were evaluated for IGF-1R labeling by 2 observers blinded to the clinical diagnosis, and given an alphanumeric code to assure patient's confidentiality. For each sample, tumor immunohistochemistry was compared in the same slide with normal adrenal tissue obtained from autopsy within 3 hours after death to avoid overt autolysis and deterioration of immunoreactivity and/or receptor protein.

IGF-1R Immunohistochemistry: Tumor samples were fixed in 10% neutral formaldehyde and paraffin embedded; 5- μ m thick sections were stained with hematoxylin and eosin. Each slice of tumor was mounted on charged glass slides along with normal adrenal tissue, as an internal control and for comparative purposes. Sections were dewaxed in xylene, rehydrated, and endogenous peroxidase blocked with 3% H₂O₂. Antigen retrieval was carried out in a microwave oven for 3 min in 0.01 M (pH = 6.0) citrate buffer. Nonspecific binding was blocked with Tris-buffered saline containing 1% bovine serum albumin. The rabbit polyclonal primary antibody against the IGF-1R (1:500 in Tris-buffered saline) was from Santa Cruz (Santa Cruz, CA, USA)²⁰. Antibody-antigen binding was detected using appropriate biotinylated secondary antibodies followed by addition of peroxidase-conjugated streptavidin (Ready-to-use streptavidin-peroxidase LSAB+System-HRP DAKO, Carpinteria, CA, USA). Sites of peroxidase activity were demonstrated using 3,3'-diaminobenzidine (Liquid DAB+, DAKO, Carpinteria, CA, USA). Slides were counterstained with hematoxylin for 30 sec. The cellular distribution of IGF-1R was assessed using an optic microscope.

IGF-1R RNA expression analyses. Total RNA from snap frozen tissues conserved at -80°C corresponding to tumors classified by immunohistochemistry as weak (n=6) or intense (n=5) for IGF-1R labeling was isolated using the Trizol reagent (Invitrogen Life Technologies, CA, USA) according to the manufacturer's protocol and digested with DNase (Qiagen, Hilden, Germany). Complementary DNA (cDNA) was synthesized using a reaction mixture containing 1 μ g of total RNA, random hexamers and the MMLV reverse transcriptase (Invitrogen Life Technologies, CA, USA), following the procedure suggested by the manufacturer. Negative controls omitting the RNA or the reverse transcriptase were included and tested in the PCR procedure. Complementary DNA of all 11 specimens were subjected to quantitative Real time PCR assays (qRT-PCR) using EvaGreen as intercalating dye. The qRT-PCR was performed in a Rotor Gene 6000 cycler. In all cases, experiments were done in duplicate. Negative controls for cDNA synthesis and PCR procedures were included in all cases. *Primer specificity:* a Rotor-Gene 6000 melting curve analysis was performed, which for both

Accepted Article

primer sets resulted in single product-specific melting curves. Gel electrophoresis and a melting curve analysis of PCR products showed that no primer-dimers were generated during the runs. The levels of IGF-1R were studied and β -actin was selected as housekeeping gene. The total expression ratio of IGF-1R was tested for significance by a randomization test implemented in the relative expression software tool (REST) (www.gene-quantification.info)²¹, which is an Excel-based application for group wise comparison and statistical analysis of relative expression results in qRT-PCR. The corresponding qRT-PCR efficiency for each gene was determined with the slope of a linear regression model, according to the equation: $E = 10[-1/\text{slope}]$.

Genetic studies: Genetic studies were performed to determine the presence of mutations in von Hippel-Lindau (*VHL*), ret proto-oncogene (*RET*) and succinate dehydrogenase subunits B and D (*SDHB* and *SDHD*) genes. *VHL*, *RET*, *SDHB* and *SDHD* genes were amplified from genomic DNA of peripheral blood cells. DNA was isolated by the SDS proteinase K method. The regions encoding for exon 1, 2, and 3 of the *VHL* gene, 10, 11, 13, 14, 15 and 16 of the *RET* proto-oncogene, 1 to 8 of the *SDHB* gene, and 1 to 4 of the *SDHD* gene were amplified by PCR using sets of specific primers. To characterize the point mutations, nucleotide sequences of PCR products were analyzed using direct sequencing ABI 3700 fluorescence sequencer (Applied Biosystems). Sequences results were analyzed by direct comparison with reference sequences or by the use of the Mutation Surveyor software. Appropriate positive and negative controls were included. No gross deletions were tested for the *VHL* gene.

Statistical Analysis: Sample size calculation was performed to establish the least number of specimens to be evaluated in order to detect a difference in the proportion of cases with malignant evolution between intense and weak IGF-1R labeling. Using a bilateral test, a sample size of 9 specimens per group was considered sufficient to detect a difference with a 99% confidence level and a 90% power, based on an estimated proportion of 10% malignancy evidenced at 5 yr of follow-

up in cases with weak labeling and 90% malignancy in cases with intense labeling. For categorical variables, cross tabulations were analyzed using the χ^2 test when applicable. Otherwise, the Fisher's Exact Test was chosen. Kaplan Meier survival plots were constructed to determine whether the expression of IGF-1R influenced tumor metastasis. Log rank (Cox Mantel) test was applied to compare survival functions. Cox regression analysis was used to adjust for confounders such as age at diagnosis or genetic diagnosis (VHL, MEN2, SDH or none), and validated by the Maximum Likelihood Test. All p-values were two sided and probabilities less than 0.05 were considered significant. SPSS 18.0 software (SPSS, Chicago, IL, USA) was used for all statistical analysis.

RESULTS

Forty specimens, corresponding to 40 patients with a median age at diagnosis of 16 years (range 4-70 years) were analyzed. Sixteen patients harbored VHL disease, 10 had familial SDH mutation-related tumors (9 SDHB and 1 SDHD) and 8 MEN 2 (6 MEN2A and 2 MEN2B). The remaining 6 patients had negative genetic studies. Malignant disease was confirmed in 11 of the 40 patients. In 3 out of 40 patients recurrences were documented.

Table 1 shows individual demographic features of all 40 patients: genetic etiology, gender, age at diagnosis, tumor localization, presence and location of metastasis, recurrences, time to metastasis or recurrences, time of follow-up (months), survival status and IGF-1R score.

IGF-1R expression was assessed by immunohistochemistry in the 40 specimens, all of which showed a diffuse positive labeling (Figure 1). Panel A shows a representative microphotograph of a tumor with an intense labeling, similar to that observed in the normal adrenal gland cortex (panel C, c). Panels B shows a tumor with weak labeling, similar to that observed in the normal medulla (panels C and D, m). Also IGF-1R expression was analyzed by qRT-PCR in the 11 specimens from which snap frozen tissue was

available. There was a 2.35-fold increase in the relative expression of IGF-1R ($p < 0.05$) in intense tumors ($n=5$) compared to weak tumors ($n=6$), reinforcing the immunohistochemistry score.

The distribution of the IGF-1R labeling of all 40 processed specimens according to the diagnosis of metastatic or non-metastatic disease is summarized in Table 2. IGF-1R labeling was mostly weak in primary tumors from patients with non-metastatic pheo/pgl. Conversely, intense IGF-1R labeling was predominant in cases of pheo/pgl with confirmed metastatic disease (Pearson χ^2 8.976, $p=0.004$). Time free of metastases was longer in patients harboring tumors with weak IGF-1R labeling (267 months, 95% CI 228 - 306) than in patients with tumors showing intense IGF-1R labeling (107 months, 95% CI 66-148, Mantel-Cox Log rank test 8.91, $p = 0.003$, Figure 2). Also, the probability of remaining free of metastases was higher in patients with pheo/pgl scored weak for IGF-1R at 60 months and more than two fold higher at 120 months of follow-up [absolute risk 0.91 (95%CI 0.74-1.000)] than in patients with intense IGF-1R labeling in their primary tumors [absolute risk 0.59 (95% CI 0.37 - 0.81) and 0.39 (95% CI 0.13-0.67), respectively]. The risk of metastases was 11.7 times higher if tumor IGF-1R labeling was intense (Hazard Ratio 11.7 95%IC 1.59-91.9, $p = 0.019$) independently of age at diagnosis (Cox regression).

Diagnostic sensitivity of intense IGF-1R labeling for metastatic disease was 0.91 (10/11 patients) while specificity was 0.62 (18/29 patients without metastatic disease).

Analysis of IGF-1R expression according to the genetic etiology showed an intense IGF-1R labeling in specimens from all 9 patients with SDHB mutation-related tumors. Five of them, with 5 or more years of follow-up, had documented metastases. Two of these patients died from causes related to the pheo. In contrast, tumors from patients with VHL disease were mostly weak (8 out of 13) for IGF-1R labeling and benign. In this group, only 1 out of 5 patients with intense IGF-1R labeling in the tumor had pgl and metastatic disease. For MEN2, 2 out of 8 patients had tumors with an intense IGF-1R

labeling and presented metastatic disease. Of the remaining 6 tumors that showed a weak labeling for IGF-1R, all but one were from patients with non-metastatic disease.

Four tumors from patients with negative genetic tests were intense for IGF-1R labeling, and two of these patients had metastatic disease and died from causes related to the pheo.

All 3 patients with recurrent pheo, belonged to the VHL group; 2 patients had tumors with weak IGF-1R labeling and one of them died (case #15) from causes unrelated to the pheo. The third case (case #4) had a tumor with intense IGF-1R labeling and died from causes related to the pheo.

DISCUSSION

Our data show that intense IGF-1R labeling in primary pheo/pgl was associated with almost 12 fold increased risk of metastases, regardless the age at diagnosis and genetic background. As already reported, malignancy was more frequently found in tumors from SDHB patients. Conversely, weak IGF-1R labeling was more prevalent in tumors from VHL patients, who showed a more benign outcome.

Although increased expression of the IGF-1R has been associated with worse prognosis in several types of cancer, some reports have shown otherwise, in particular regarding breast and prostate cancer^{22;23}, where a decreased expression of the IGF-1R is observed in malignant lesions compared to the normal epithelium. Recently, it has been showed that the IGF-1R expression in benign human pheo cells is higher than in normal adrenal medulla²⁴. The present study is the first to report a significant overexpression of the IGF-1R in primary human pheo/pgl with malignant behavior compared to benign tumors. In our series, 10 out of 11 tumors from patients with documented metastases showed an intense IGF-1R labeling. Moreover, a worse outcome of pheo/pgl patients was associated with intense IGF-1R expression levels as is shown by Kaplan Meier analysis. Conversely, patients with weak IGF-1R tumor labeling have 1.5 times the probability to remain free of metastasis at 5 years after surgery than

those with intense IGF-1R tumor labeling and more than twice this probability at 10 years after surgery.

At present the only treatment for pheo/pgl is surgery. Besides, there are no histological features to definitively identify or predict the outcome of pheo/pgl patients. Malignant behavior can be currently defined only by the appearance of metastasis. Several markers, such as COX and Bcl2, MIB-1, p53, VEGF and SNAIL among others ²⁵⁻²⁹, or histological features (PASS score) ³⁰ have been proposed as potential predictors of malignancy of pheo/pgl, but results have been inconclusive. For example, SNAIL expression had a 100% sensitivity of detecting the malignant tumors. However, by this method, the specificity was only 56%. A recent report ³¹ proposed methoxytyramine as a new biomarker of metastatic pheochromocytoma and paraganglioma, with a calculated diagnostic sensitivity of only 57%, but with a specificity of 85%. In our study, IGF-1R expression had 91% sensitivity of detecting malignant tumors, while the specificity was 62%. While the majority of cases have a long follow-up period, there are some with only short follow-up. Thus, the absence of malignancy in these cases cannot be taken for granted. However, this bias would tend to decrease the difference in the proportion of intense labeling between malignant and benign cases and to decrease the diagnostic specificity. In fact, in 6 of 10 cases with high intensity and no documented metastases, the follow-up is less than 5 yr. A longer follow-up eventually detecting more malignant cases would increase the proportion of true positives. Therefore, our analysis is conservative and does not overestimate our conclusions.

One limitation of this study is that our series has a large proportion of young patients, probably due to the fact that familial cases usually present at younger ages. However, it should be noted that our patients were all index cases that guided the familial studies and not selected from screening programs. Furthermore, we used a Cox regression analysis to adjust for age at diagnosis, which allowed us to rule out the age at diagnosis as a confounding variable in the analysis. Another peculiarity of our study is the high proportion of malignant cases in patients with MEN2, probably due

to a disproportionate referral of patients with metastases to our center. Since our objective was not to estimate the prevalence of malignancy in subjects with MEN2, our sample of MEN2 patients was small (8 cases), thus inadequate to make such estimation.

Overexpression of IGF-1R promotes neoplastic growth³² and absence of the IGF-1R has been shown to prevent malignant transformation³³. IGF-1R expression is regulated by a variety of factors, including tumor suppressor genes, transcription factors and other growth factors. VHL protein can inhibit the activity and the expression of the IGF-1R in normal or tumoral renal cell lines^{34;35}. *VHL* and *SDHB/D* inactivation both result in Hypoxia Inducible Factors deregulation³⁶, leading to the activation of the hypoxic response, even in normoxic conditions. Although some patients harboring mutations in *VHL* and *SDHB/D* develop pheo/pgl, there are significant clinical differences as well as different patterns of gene expression between these two groups of patients³⁷. Mutations of the *SDH* subunits are associated with a higher incidence of extra-adrenal pheo, and malignancy is frequent in *SDHB* but rare in *VHL* associated pheo¹². Accordingly, in our group of patients with *SDH* mutations tumors were mostly extra-adrenal, malignant and were associated with an intense labeling for the IGF-1R, and tumors from our group of *VHL* patients were mostly benign and had a positive weak staining for the IGF-1R. The mechanisms responsible for enhanced IGF-1R expression in pheo/pgl associated to hereditary syndromes and other malignancies are still unclear. Overexpression of the IGF-1R in our group of pheo/pgl was related to malignancy irrespective of the genetic etiology. This suggests that mechanisms other than those related to the development of pheo/pgl in these syndromes are responsible for the higher expression of the IGF-1R in the subset of malignant tumors.

Our results strongly suggest that immunolabeling for the IGF-1R is associated with malignancy in familial pheo/pgl and might be a useful tool to predict the adverse outcome of pheo/pgl patients.

Furthermore, although future research is needed, our work supports the IGF-1/IGF-1R circuit as an attractive molecular target for the treatment of malignant pheo/pgl.

Funding: This work has been supported by the Ministerio de Ciencia y Tecnología (Mincyt, Anpcyt, Grant number PICT06-01002, awarded to PP); and by the Consejo Nacional de Investigaciones Científicas y Tecnológicas (CONICET) Argentina (Grant number PIP08-1905 awarded to PP).

Acknowledgements: we thank Mr. Eduardo Dascal and Ms. Gabriela Gutierrez Moyano for their expert technical assistance. We particularly thank Dr. Rodolfo Rey and Dr. Selva Cigorruga for their critical reading and revision of the manuscript.

FIGURE LEGENDS

Figure 1: Immunostaining for IGF-1R in benign and malignant pheo/pgl. Paraffin embedded tumor biopsies were processed for IHC, along with normal adrenal gland, using a specific antibody against IGF-1R. (A) Representative malignant tumor showing intense labeling for IGF-1R similar to the adrenal cortex (*c*) showed on control tissue depicted on (D). Benign tumors (B) showed weak labeling for the IGF-1R comparable to that observed in normal adrenal medulla (*m* in C and D). *c*. adrenal cortex; *m*: adrenal medulla.

Figure 2: Time free of metastasis in patients with pheo/pgl according to the IGF-1R labeling in their primary tumors. W: Weak IGF-1R labeling; I: Intense IGF-1R labeling. Censored: a “Censored” case is a patient that did not have the event (metastasis) until the last recorded time of follow-up (indicated with a vertical dash).

REFERENCE LIST

- (1) Elder, E.E., Elder, G., Larsson, C. (2005) Pheochromocytoma and functional paraganglioma syndrome: no longer the 10% tumor. *J Surg Oncol* **89**, (3),pp. 193-201.
- (2) Mulligan, L.M., Marsh, D.J., Robinson, B.G., Schuffenecker, I., Zedenius, J., Lips, C.J., et al. (1995) Genotype-phenotype correlation in multiple endocrine neoplasia type 2: report of the International RET Mutation Consortium. *J Intern Med* **238**, (4),pp. 343-346.
- (3) Bender, B.U., Gutsche, M., Glasker, S., Muller, B., Kirste, G., Eng, C., et al. (2000) Differential genetic alterations in von Hippel-Lindau syndrome-associated and sporadic pheochromocytomas. *J Clin Endocrinol Metab* **85**, (12),pp. 4568-4574.
- (4) Bausch, B., Borozdin, W., Neumann, H.P. (2006) Clinical and genetic characteristics of patients with neurofibromatosis type 1 and pheochromocytoma. *N Engl J Med* **354**, (25),pp. 2729-2731.
- (5) Kantorovich, V., King, K.S., Pacak, K. (2010) SDH-related pheochromocytoma and paraganglioma. *Best Pract Res Clin Endocrinol Metab* **24**, (3),pp. 415-424.
- (6) Burnichon, N., Briere, J.J., Libe, R., Vescovo, L., Riviere, J., Tissier, F., et al. (2010) SDHA is a tumor suppressor gene causing paraganglioma. *Hum Mol Genet* **19**, (15),pp. 3011-3020.
- (7) Comino-Mendez, I., Gracia-Aznarez, F.J., Schiavi, F., Landa, I., Leandro-Garcia, L.J., Leton, R., et al. (2011) Exome sequencing identifies MAX mutations as a cause of hereditary pheochromocytoma. *Nat Genet* **43**, (7),pp. 663-667.
- (8) Yao, L., Schiavi, F., Cascon, A., Qin, Y., Inglada-Perez, L., King, E.E., et al. (2010) Spectrum and prevalence of FP/TMEM127 gene mutations in pheochromocytomas and paragangliomas. *JAMA* **304**, (23),pp. 2611-2619.
- (9) Yeh, I.T., Lenci, R.E., Qin, Y., Buddavarapu, K., Ligon, A.H., Leteurtre, E., et al. (2008) A germline mutation of the KIF1B beta gene on 1p36 in a family with neural and nonneural tumors. *Hum Genet* **124**, (3),pp. 279-285.
- (10) Eisenhofer, G., Bornstein, S.R., Brouwers, F.M., Cheung, N.K., Dahia, P.L., de Krijger, R.R., et al. (2004) Malignant pheochromocytoma: current status and initiatives for future progress. *Endocr Relat Cancer* **11**, (3),pp. 423-436.
- (11) Linnoila, R.I., Keiser, H.R., Steinberg, S.M., Lack, E.E. (1990) Histopathology of benign versus malignant sympathoadrenal paragangliomas: clinicopathologic study of 120 cases including unusual histologic features. *Hum Pathol* **21**, (11),pp. 1168-1180.
- (12) Waguespack, S.G., Rich, T., Grubbs, E., Ying, A.K., Perrier, N.D., Ayala-Ramirez, M., et al. (2010) A current review of the etiology, diagnosis, and treatment of pediatric pheochromocytoma and paraganglioma. *J Clin Endocrinol Metab* **95**, (5),pp. 2023-2037.
- (13) Polyak, K., Weinberg, R.A. (2009) Transitions between epithelial and mesenchymal states: acquisition of malignant and stem cell traits. *Nat Rev Cancer* **9**, (4),pp. 265-273.
- (14) Loriot, C., Burnichon, N., Gadessaud, N., Vescovo, L., Amar, L., Libe, R., et al. (2012) Epithelial to mesenchymal transition is activated in metastatic pheochromocytomas and paragangliomas caused by SDHB gene mutations. *J Clin Endocrinol Metab* **97**, (6),p. E954-E962.

- (15) Samani, A.A., Yakar, S., LeRoith, D., Brodt, P. (2007) The role of the IGF system in cancer growth and metastasis: overview and recent insights. *Endocr Rev* **28**, (1),pp. 20-47.
- (16) Fernandez, M.C., Venara, M., Nowicki, S., Chemes, H.E., Barontini, M., Pennisi, P.A. (2012) Igf-I regulates pheochromocytoma cell proliferation and survival in vitro and in vivo. *Endocrinology* **153**, (8),pp. 3724-3734.
- (17) Kim, H.J., Litzenger, B.C., Cui, X., Delgado, D.A., Grabner, B.C., Lin, X., et al. (2007) Constitutively active type I insulin-like growth factor receptor causes transformation and xenograft growth of immortalized mammary epithelial cells and is accompanied by an epithelial-to-mesenchymal transition mediated by NF-kappaB and snail. *Mol Cell Biol* **27**, (8),pp. 3165-3175.
- (18) Lloyd RV, Tischler AS, Kimura N et al. (2004) Tumours of the adrenal gland. In: DeLellis RA, Lloyd RV, Heitz PU, Eng C, eds. WHO Classification of Tumours, Pathology & Genetics of Tumours of Endocrine Organs. Lyon, France: IARC Press;:136-138.
- (19) Eisenhofer, G., Goldstein, D.S., Stull, R., Keiser, H.R., Sunderland, T., Murphy, D.L., et al. (1986) Simultaneous liquid-chromatographic determination of 3,4-dihydroxyphenylglycol, catecholamines, and 3,4-dihydroxyphenylalanine in plasma, and their responses to inhibition of monoamine oxidase. *Clin Chem* **32**, (11),pp. 2030-2033.
- (20) Hellowell, G.O., Turner, G.D., Davies, D.R., Poulosom, R., Brewster, S.F., Macaulay, V.M. (2002) Expression of the type 1 insulin-like growth factor receptor is up-regulated in primary prostate cancer and commonly persists in metastatic disease. *Cancer Res* **62**, (10),pp. 2942-2950.
- (21) Pfaffl, M.W., Horgan, G.W., Dempfle, L. (2002) Relative expression software tool (REST) for group-wise comparison and statistical analysis of relative expression results in real-time PCR. *Nucleic Acids Res* **30**, (9),p. e36.
- (22) Schnarr, B., Strunz, K., Ohsam, J., Benner, A., Wacker, J., Mayer, D. (2000) Down-regulation of insulin-like growth factor-I receptor and insulin receptor substrate-1 expression in advanced human breast cancer. *Int J Cancer* **89**, (6),pp. 506-513.
- (23) Tennant, M.K., Thrasher, J.B., Twomey, P.A., Drivdahl, R.H., Birnbaum, R.S., Plymate, S.R. (1996) Protein and messenger ribonucleic acid (mRNA) for the type 1 insulin-like growth factor (IGF) receptor is decreased and IGF-II mRNA is increased in human prostate carcinoma compared to benign prostate epithelium. *J Clin Endocrinol Metab* **81**, (10),pp. 3774-3782.
- (24) Fottner, C., Minnemann, T., Kalmbach, S., Weber, M.M. (2006) Overexpression of the insulin-like growth factor I receptor in human pheochromocytomas. *J Mol Endocrinol* **36**, (2),pp. 279-287.
- (25) Cadden, I.S., Atkinson, A.B., Johnston, B.T., Pogue, K., Connolly, R., McCance, D., et al. (2007) Cyclooxygenase-2 expression correlates with pheochromocytoma malignancy: evidence for a Bcl-2-dependent mechanism. *Histopathology* **51**, (6),pp. 743-751.
- (26) de Krijger, R.R., van der Harst, E., van der Ham, F., Stijnen, T., Dinjens, W.N., Koper, J.W., et al. (1999) Prognostic value of p53, bcl-2, and c-erbB-2 protein expression in pheochromocytomas. *J Pathol* **188**, (1),pp. 51-55.
- (27) Favier, J., Plouin, P.F., Corvol, P., Gasc, J.M. (2002) Angiogenesis and vascular architecture in pheochromocytomas: distinctive traits in malignant tumors. *Am J Pathol* **161**, (4),pp. 1235-1246.
- (28) Hayry, V., Salmenkivi, K., Arola, J., Heikkila, P., Haglund, C., Sariola, H. (2009) High frequency of SNAIL-expressing cells confirms and predicts metastatic potential of pheochromocytoma. *Endocr*

Relat Cancer **16**, (4),pp. 1211-1218.

- (29) van der Harst, E., Bruining, H.A., Jaap, B.H., van der Ham, F., Dinjens, W.N., Lamberts, S.W., et al. (2000) Proliferative index in pheochromocytomas: does it predict the occurrence of metastases? *J Pathol* **191**, (2),pp. 175-180.
- (30) Thompson, L.D. (2002) Pheochromocytoma of the Adrenal gland Scaled Score (PASS) to separate benign from malignant neoplasms: a clinicopathologic and immunophenotypic study of 100 cases. *Am J Surg Pathol* **26**, (5),pp. 551-566.
- (31) Eisenhofer, G., Lenders, J.W., Siegert, G., Bornstein, S.R., Friberg, P., Milosevic, D., et al. (2012) Plasma methoxytyramine: a novel biomarker of metastatic pheochromocytoma and paraganglioma in relation to established risk factors of tumour size, location and SDHB mutation status. *Eur J Cancer* **48**, (11),pp. 1739-1749.
- (32) Baserga, R. (2005) The insulin-like growth factor-I receptor as a target for cancer therapy. *Expert Opin Ther Targets* **9**, (4),pp. 753-768.
- (33) Baserga, R. (1995) The insulin-like growth factor I receptor: a key to tumor growth? *Cancer Res* **55**, (2),pp. 249-252.
- (34) Sivakumar, R., Koga, H., Selvendiran, K., Maeyama, M., Ueno, T., Sata, M. (2009) Autocrine loop for IGF-I receptor signaling in SLUG-mediated epithelial-mesenchymal transition. *Int J Oncol* **34**, (2),pp. 329-338.
- (35) Yuen, J.S., Cockman, M.E., Sullivan, M., Protheroe, A., Turner, G.D., Roberts, I.S., et al. (2007) The VHL tumor suppressor inhibits expression of the IGF1R and its loss induces IGF1R upregulation in human clear cell renal carcinoma. *Oncogene* **26**, (45),pp. 6499-6508.
- (36) Maxwell, P.H. (2005) A common pathway for genetic events leading to pheochromocytoma. *Cancer Cell* **8**, (2),pp. 91-93.
- (37) Pollard, P.J., El-Bahrawy, M., Poulosom, R., Elia, G., Killick, P., Kelly, G., et al. (2006) Expression of HIF-1alpha, HIF-2alpha (EPAS1), and their target genes in paraganglioma and pheochromocytoma with VHL and SDH mutations. *J Clin Endocrinol Metab* **91**, (11),pp. 4593-4598.

Table 1: Demographic data of pheo/pgl patients.

Patient case	Genetic Etiology	Gender	Age at diagnosis	Location	Met	Rec	Time to Met/Rec	Follow up months	Status	IGF-1R score
1	VHL	M	4	A B	No	No		144	Alive	W
2	VHL	M	6	A B	No	Yes	96	172	Alive	W
3	VHL	F	7	A U	No	No		60	Alive	I
4	VHL	F	7	A B	No	Yes	48	60	D (Tumor)	I

5	VHL	M	8	A B	No	No		288	Alive	W
6	VHL	M	9	A B	No	No		60	Alive	W
7	VHL	F	12	A U	No	No		54	Alive	I
8	VHL	M	12	A B	No	No		48	Alive	I
9	VHL	M	14	A B	No	No		238	Alive	W
10	VHL	M	14	A U	No	No		36	Alive	W
11	VHL	F	15	A U	No	No		36	Alive	W
12	VHL	F	16	A U	No	No		108	Alive	I
13	VHL	M	24	A U	No	No		48	Alive	W
14	VHL	M	29	A B	No	No		60	Alive	W
15	VHL	F	47	A B	No	yes	24	96	D*	W
16	VHL	M	70	PGL	Yes	No	72	72	D(Tumor)	I
17	SDHB	M	8	A B	Yes	No	48	96	Alive	I
18	SDHB	M	10	PGL	No	No		108	Alive	I
19	SDHB	F	13	PGL	No	No		108	Alive	I
20	SDHB	M	14	PGL	No	No		36	Alive	I
21	SDHB	F	14	PGL	Yes	No	6	84	Alive	I
22	SDHB	F	16	PGL	No	No		30	Alive	I
23	SDHB	F	38	PGL	Yes	No	24	120	D (Tumor)	I
24	SDHB	F	45	PGL	Yes	No	30	96	Alive	I
25	SDHB	F	47	PGL	Yes	No	9	96	D (Tumor)	I
26	SDHD	M	28	PGL	No	No		120	Alive	W
27	MEN 2A	F	25	A B	No	No		120	Alive	W
28	MEN 2A	M	25	A U	Yes	No	60	264	Alive	W
29	MEN 2A	F	27	A B	No	No		132	Alive	W
30	MEN 2A	F	32	A B	Yes	No	74	156	Alive	I
31	MEN 2A	F	43	A B	No	No		36	Alive	W

32	MEN 2A	M	50	A B	No	No		48	Alive	W
33	MEN 2B	M	26	A B	No	No		48	Alive	W
34	MEN 2B	M	42	A B	Yes	No	48	48	D**	I
35	Neg	F	12	PGL	Yes	No	24	132	D (Tumor)	I
36	Neg	F	13	PGL	No	No		24	Alive	I
37	Neg	F	13	A U	No	No		204	Alive	I
38	Neg	F	32	A U	No	No		36	Alive	W
39	Neg	F	33	A U	Yes	No	12	204	D (Tumor)	I
40	Neg	F	64	A U	No	No		36	Alive	W

M: male; F: Female; Met: Metastasis; Rec: Recurrences D: Dead. *Death unrelated to the tumor (Pancreatic Tumor) ** Death immediately after surgery.

Location: A; Adrenal, B: Bilateral; U: unilateral; PGL: extraadrenal paraganglioma.

IGF-1R score: I: Intense; W: weak.

Table 2: Distribution of IGF-1R labeling in primary tumors from patients with pheo/pgl according to malignancy.

Pheo/pgl	Weak	Intense
Non-metastatic	62.1 % (18/29) ^a	37.9 % (11/29)
Metastatic	9.1% (1/11)	90.9 % (10/11)

a: p value <0.01 χ^2 =8.561.

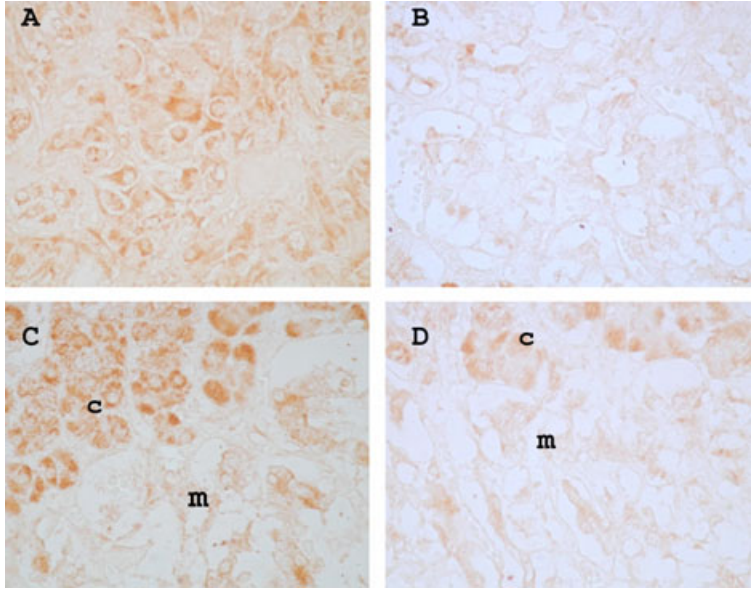


Figure 2

