




Simultaneous PET/MRI assessment of response to cytotoxic and hormone neo-adjuvant chemotherapy in breast cancer: a preliminary report

Valeria Romeo¹  · Massimiliano D'Aiuto² · Giuseppe Frasci² · Massimo Imbriaco¹ · Emanuele Nicolai³

Received: 11 December 2016 / Accepted: 21 December 2016 / Published online: 30 December 2016
© Springer Science+Business Media New York 2016

Abstract The aim of this study was to assess the response to cytotoxic and hormone neo-adjuvant chemotherapy in four patients with locally advanced breast cancer by simultaneous PET/MRI. Four patients with locally advanced breast cancer underwent simultaneous PET/MRI of the breast using a 3 T Biograph mMR before and after neo-adjuvant chemotherapy (two patients were treated with hormone-therapy and two patients were treated with cytotoxic chemotherapy). Morpho-structural tumoral features and tumor size were assessed; area value, metabolic (SUV and MTV) and functional (ADC, K_{trans} , V_e , k_{ep} and iAUC) data were obtained by positioning regions of interest. A comparison of all parameters between the pre- and post-treatment PET/MRI examinations and between the two different therapeutic schedules was assessed. In patients treated with cytotoxic chemotherapy and classified as PR, there was a significant reduction of post-treatment morphological, metabolic and functional parameters. In a

patient treated with hormone therapy, classified as SD, there was an increase of all post-treatment perfusion parameters, a substantially stable ADC value and a poor reduction of lesion size and of maximum SUV (SUV_{max}) values; the last patient, treated with hormone therapy and classified as PR, showed a significant reduction of lesion size and SUV_{max} values with a reduction of perfusion parameters and substantially stable ADC values. Multi-parametric evaluation with simultaneous PET/MRI could be a useful tool to assess the response to cytotoxic and hormone neo-adjuvant chemotherapy in patients with breast cancer. Future studies in a larger cohort of patients are warranted to confirm the results of this preliminary study.

Keywords Simultaneous PET/MRI · Breast cancer · Neo-adjuvant chemotherapy

Introduction

Positron emission tomography/magnetic resonance imaging (PET/MRI) is emerging as a powerful tool in the assessment of response to treatment in oncologic patients, with the possibility to simultaneously collect morphologic, metabolic and functional parameters (diffusion and perfusion parameters) [1]. Since its high contrast resolution in breast tissue, the use of MRI in combination with PET is a promising imaging technique for the evaluation of breast tumor extension, nodal involvement, for the detection of distant metastasis and for treatment monitoring [2, 3]. Moreover, preliminary studies suggest that simultaneous ^{18}F -FDG and DCE MRI may aid in the assessment of breast tumor aggressiveness and metastatic potential [4].

✉ Valeria Romeo
valeria.romeo@unina.it

Massimiliano D'Aiuto
m.daiuto@istitutotumori.na.it

Giuseppe Frasci
g.frasci@istitutotumori.na.it

Massimo Imbriaco
mimbriaco@hotmail.com

Emanuele Nicolai
e.nicolai@sdn-napoli.it

¹ Department of Advanced Biomedical Sciences, University Federico II of Naples, Via S. Pansini, 5, 80123 Naples, Italy

² Breast Department, National Cancer Institute of Naples IRCCS "G. Pascale", Naples, Italy

³ IRCCS SDN, Naples, Italy

In this short and preliminary report we specifically evaluated the morphological, metabolic and functional parameters in two groups of four patients with locally advanced breast cancer before and after neo-adjuvant chemotherapy (two patients were treated with hormone-therapy, while the other two patients were treated with cytotoxic chemotherapy), in order to assess the response to treatment and to compare the behavior of such parameters between the two groups.

Materials and methods

Patient population

Four patients underwent simultaneous PET/MRI of the breast 2 h after ^{18}F -FDG injection using a 3 T Biograph mMR (Siemens Healthcare, Erlangen, Germany) with a four-channel breast coil, before and after neo-adjuvant chemotherapy. Of these, two patients were treated with cytotoxic chemotherapy (Group 1), while the other two patients were treated with hormone-therapy (Group 2). Post-treatment evaluation was conducted at the end of the second cycle of cytotoxic chemotherapy and after 2 months from the beginning of hormone therapy. Clinical and histological post-surgical data for each patient are reported in Table 1; in particular, there were two invasive ductal carcinoma (IDC), one invasive lobular carcinoma (ILC) and one invasive ductal/lobular carcinoma. The study was approved by our Institutional Review Board and informed consent was obtained from all individual participants included in the study.

PET/MRI acquisition

A dose of 401 ± 35 MBq of ^{18}F -FDG was injected depending on patient's body weight. After an uptake period 80 ± 16 min, patients underwent PET/MRI examination.

PET/MRI was performed on the Biograph mMR (Siemens Healthcare, Erlangen, Germany). This system consists of a 3T MRI scanner featuring high-performance

gradient systems (45 mT/m) and a slew rate of 200 T/m/s. The coils, patient table and cables have been redesigned for PET/MRI in order to minimize their attenuation and, thus, to allow unimpaired PET acquisition with the coils in place. A fully functional PET system, equipped with the avalanche photodiode technology, is embedded into the magnetic resonance gantry. The PET scanner has a spatial resolution of 4.1 mm (FWHM) at 1 cm and of 5.0 mm (FWHM) at 10 cm from the transverse FOV and a sensitivity of 11.72 kcps/MBq at the center of the FOV. Bed position was established in order to get a full coverage of the breast region. After a correct positioning had been ensured, the combined PET/MRI acquisition started. First, a coronal 2-point Dixon 3-dimensional volumetric interpolated breath-hold T1-weighted MRI sequence was acquired and used for the generation of attenuation maps and for anatomic allocation of the PET results. The software of the MRI scanner automatically generated four different images: T1-weighted in-phase, T1-weighted out-of-phase, water-only and fat-only. Simultaneously with the start of the Dixon MRI sequence, PET acquisition started ensuring correct temporal and regional correspondence between MRI and PET data. The PET data acquisition occurred during the entire MR acquisition time, taking delayed acquisition times and radioactive decay into account.

MRI-based attenuation correction

For attenuation correction of the PET data from the PET/MR scanner, attenuation maps generated on the basis of the Dixon MRI sequence were applied. The attenuation maps were generated on the basis of the 2-point Dixon MRI sequences. This approach has recently been demonstrated to provide results comparable to those of conventional attenuation correction by low-dose CT [5]. The procedure has been implemented in the post-processing software of the scanner and operates automatically. The Dixon fat- and water-weighted images were used to create an attenuation map with four distinct tissue-classes: background, lungs, fat and soft tissue. The lungs were identified by connected-

Table 1 Patient population

Patient	Age	Location	Histological type	Grade	ER (%)	PG (%)	Ki67 (%)	HER2 (%)	NAC
1	54	Left	IDLC	G3	90	75	20	0	Cytotoxic
2	36	Right	IDC	G3	85	<1	20	3+	Cytotoxic
3	42	Right	IDC	G2	90	90	5	0	Hormone
4	76	Left	ILC	G2	85	30	10	0	Hormone

IDLC invasive ductal/lobular carcinoma, *IDC* invasive ductal carcinoma, *ILC* invasive lobular carcinoma, *ER* estrogen receptor, *PG* progesterone receptor, *NAC* neo-adjuvant chemotherapy

component analysis of the air in the inner part of the body. By application of a morphologic closing filter, virtual air artifacts induced by the absence of an MRI signal in cortical bone, heart and aorta (because of blood flow) were corrected. Attenuation of the PET signal caused by instrumentation such as the patient bed and the fixed MRI coils is automatically integrated into the attenuation maps.

MR acquisition

The MRI protocol was performed with a dedicated breast coil, including:

- Axial and coronal STIR (repetition time, echo time, inversion time TR/TE/TI = 4220/61/220 ms);
- Axial diffusion-weighted imaging (DWI), a single-shot echo planar 2d SPAIR (TR/TE = 9900/69 ms) using three b values: 0, 500 and 800 s/mm².
- Perfusion (DCE) studies were obtained with intravenous administration of paramagnetic contrast agent (Magnevist, Bayer, Berlin, Germany) 0.2 ml/kg, a flow rate of 3.5 ml/s, after two pre-contrast transaxial T1Vibe with flip angles of 15 and 2 degrees followed by a t1vibe_tra_dynamic (TR/TE = 5.37/1.78 ms) with 50 measurements. Additionally, an axial isovolumetric VIBE FAT SAT axial and axial FFE FAT SAT T1 (TR/TE = 8.7/4.3 ms) were acquired.

Data processing and multiparametric analysis

PET data obtained on PET/MR scanner were processed with reconstruction and correction algorithms. Emission data were corrected for randoms, dead time, scatter and attenuation. A 3-dimensional attenuation-weighted ordered-subsets

expectation maximization iterative reconstruction algorithm (AW OSEM 3D) was applied with three iterations and 21 subsets, Gaussian smoothing of 4 mm in full width at half maximum and a zoom of 1.

Two radiologists experienced in breast imaging (16 and 8 years experience), and one nuclear medicine specialist (16 years experience) evaluated PET/MRI images in consensus. Response to treatment was assessed according to the RECIST and PERCIST criteria [6, 7] and classified as complete response (CR), partial response (PR), stable disease (SD) or progression disease (PD). Lesion size was measured considering the maximum lesion diameter (mm), while the tumoral area (cm²) was quantified by positioning regions of interest (ROIs) over the tumoral lesions in the major diameter lesion slice; post-contrast T1-weighted and STIR-weighted images were utilized to assist in the breast tumor outline.

In PET images, regional tracer uptake was quantified by positioning ROIs over the tumoral lesions at the level of maximum extension to obtain 2D maximal and mean standardized uptake values (SUV_{max} 2D, SUV_{mean} 2D); 3D maximal and mean standardized uptake values (SUV_{max} 3D, SUV_{mean} 3D, MTV) were obtained by positioning a volume-of-interest (VOI) over the tumoral lesions with a threshold of 30% of the maximum signal intensity (MTV 30).

Tumor detection, tumoral extension and infiltration of neighboring structures were assessed mainly on MR dynamic sequences. Subsequently, the DCE-MR images were transferred for post-processing to a workstation running commercially available software for tissue perfusion estimation (Tissue 4D, Siemens Medical Systems, Germany). After motion correction and registration of the pre- and post-contrast acquisitions, T1 mapping was automatically performed and a freehand region-of-interest

Table 2 Pre- and post-treatment morphological, metabolic and perfusion parameters

Parameter	Cytotoxic neo-adjuvant chemotherapy				Hormone neo-adjuvant chemotherapy			
	Pt 1 Pre-treat	Pt 1 Post-treat	Pt 2 Pre-treat	Pt 2 Post-treat	Pt 3 Pre-treat	Pt 3 Post-treat	Pt 4 Pre-treat	Pt 4 Post-treat
Tumor size (mm)	82	40	37	28	45	38	74	36
Tumor area (cm ²)	27.18	6.58	4.83	3.25	12.78	11.6	13.3	6.36
SUV _{max} 2D (KBq/ml)	34	8.76	12	2.67	12	10	15.5	3.17
SUV _{max} 3D	42.2	12.7	12.1	2.67	15.1	12	5.76	1.88
MTV (cm ³)	92.12	9.58	26.45	21.5	26.45	15.98	24.68	19.56
ADC _{mean}	0.70	1.19	0.66	2.09	1.03	0.9	1.01	0.99
K _{trans} mean	123	77	598	51	133.8	181	50.14	35.44
V _e mean	242	339	233.76	138.33	317	372	186.85	459
Kep mean	92.7	23.32	119.5	28.77	43.49	49.33	30.48	12.53
iAUC mean	518	204	552.94	35.2	237.13	366	143.35	115.52

Pre-treat pre-treatment, *Post-treat* post-treatment, *SUV* standard uptake volume, *MTV* metabolic tumor volume, *ADC* apparent diffusion coefficient, *iAUC* initial area under the concentration curve

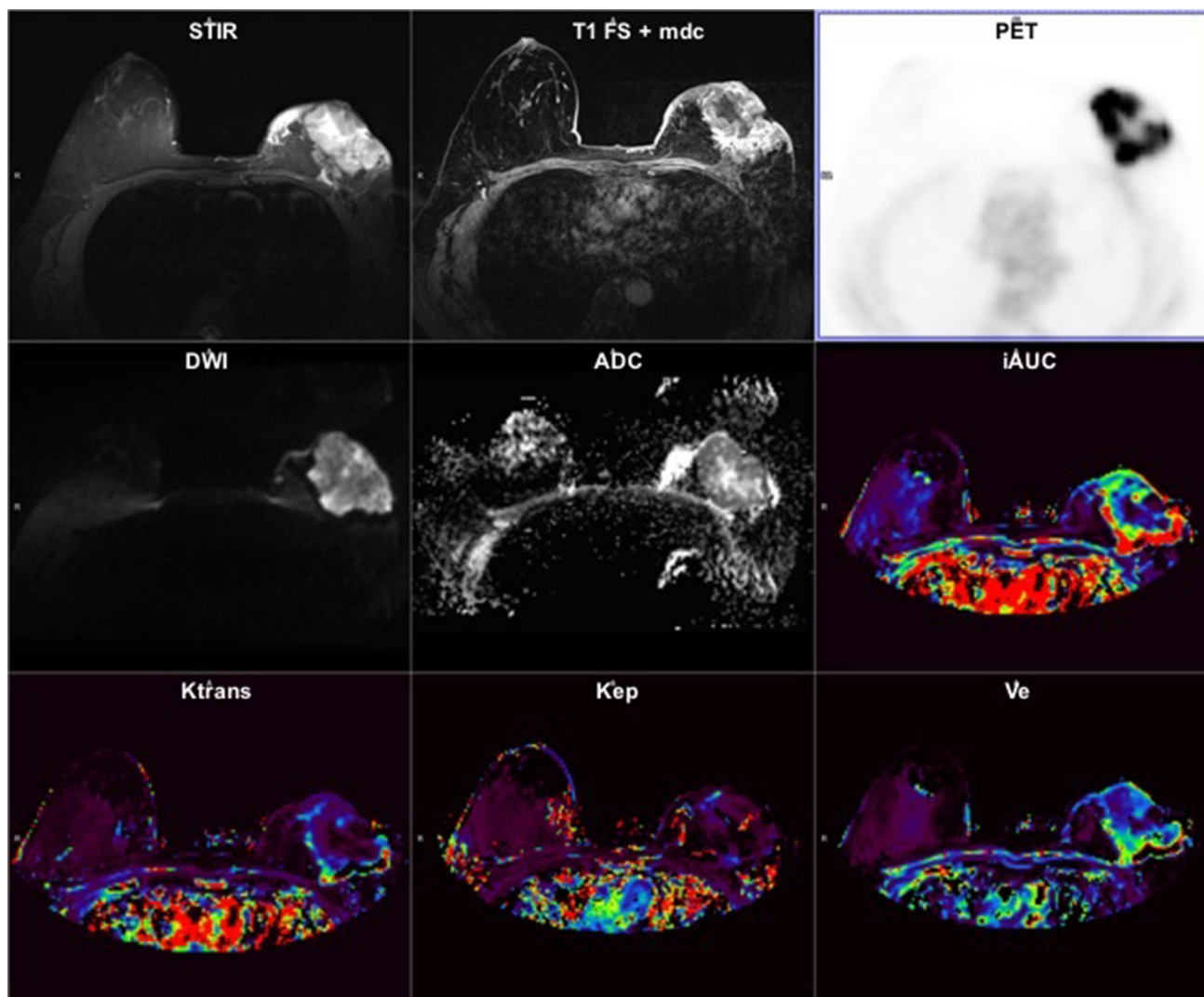


Fig. 1 Multiparametric evaluation of morphological (STIR and T1 FS + mdc), metabolic (PET) and functional (DWI, ADC, iAUC, K_{trans} , k_{ep} , V_e) parameters in a 54-year old female (Pt 1) with an infiltrating ductal/lobular carcinoma of the left breast before cytotoxic

chemotherapy. A large tumoral mass with significant post-contrast enhancement, increase of 18FDG uptake, restricted diffusivity and increased perfusion is appreciated

(ROI) was plotted around the tumor including the neighboring structures. The pharmacokinetic modeling was based on a two compartment pharmacokinetic model proposed by Toft and Kermod [8] that allows the calculation of the following parameters: the influx volume transfer constant between vascular and extravascular/extracellular space (EES) (K_{trans}), the efflux rate constant between vascular and EES (k_{ep}), the fractional volume of EES (V_e) and the initial area under the concentration curve (iAUC), defined as a measure of the total amount of contrast agent delivered to and retained within the tumor during the stated time period. Arterial input function (AIF) was related to gadolinium dose injected and was modeled by a bi-exponential function using an intermediate mode provided by the software. For the subsequent tumor ROI

analysis, PET/MRI datasets (PET acquisition, axial T1 post-contrast and axial STIR sequences, axial ADC map and single perfusion maps for K_{trans} , V_e , k_{ep} and iAUC) were evaluated into a unified measurements framework customized into Syngo.via software platform (Siemens Medical Solutions) allowing a visual comparison of the multiparametric data. AIF was calculated positioning a ROI in the ascending aorta at the level of the right pulmonary artery. Freehand ROI area value, referred as the tumor size in the major diameter lesion slice, was extracted for each patient. For multiparametric comparisons, the ROI outline was following drawn with same position and extent on each map to automatically extract maximum and mean values for each parameter (SUV_{max} and SUV_{mean} for the PET; ADC_{max} and ADC_{mean} for the

diffusion; K_{trans} , V_e , k_{ep} , and iAUC, respectively, max and mean for perfusion maps).

Since the small sample size, no statistical analysis was performed and a direct comparison of the pre- and post-treatment values for each patient and between the two groups of patients treated with the two different therapeutic schedules was carried out.

Results

A total of four lesions were observed on pre- and post-treatment PET/MR examinations. Mean size of lesions was 59 mm (range 37–82 mm). Three cases (patients 1, 2 and 4) were classified as PR according to both RECIST (lesion size) and PERCIST (SUV_{mean} values) criteria. In patient 3,

there was a less pronounced reduction of tumor size (maximum diameter and tumor area) and 18-FDG uptake, consistent with SD. In detail, in patients 1 and 2, treated with cytotoxic chemotherapy and classified as PR, there was a significant (>30%) post-treatment reduction of lesion size, SUV_{max} values, perfusion parameters (except for V_e mean) and a valuable increase of ADC values. In patient 3, treated with hormone therapy and classified as SD, there was an increase of all post-treatment perfusion parameters, a substantially stable ADC value and a poor reduction of lesion size and SUV_{max} values (<30%); patient 4, treated with hormone therapy and classified as PR, showed a significant reduction of lesion size (>30%) and SUV_{max} values with a reduction of perfusion parameters (except for V_e mean) and substantially stable ADC values.

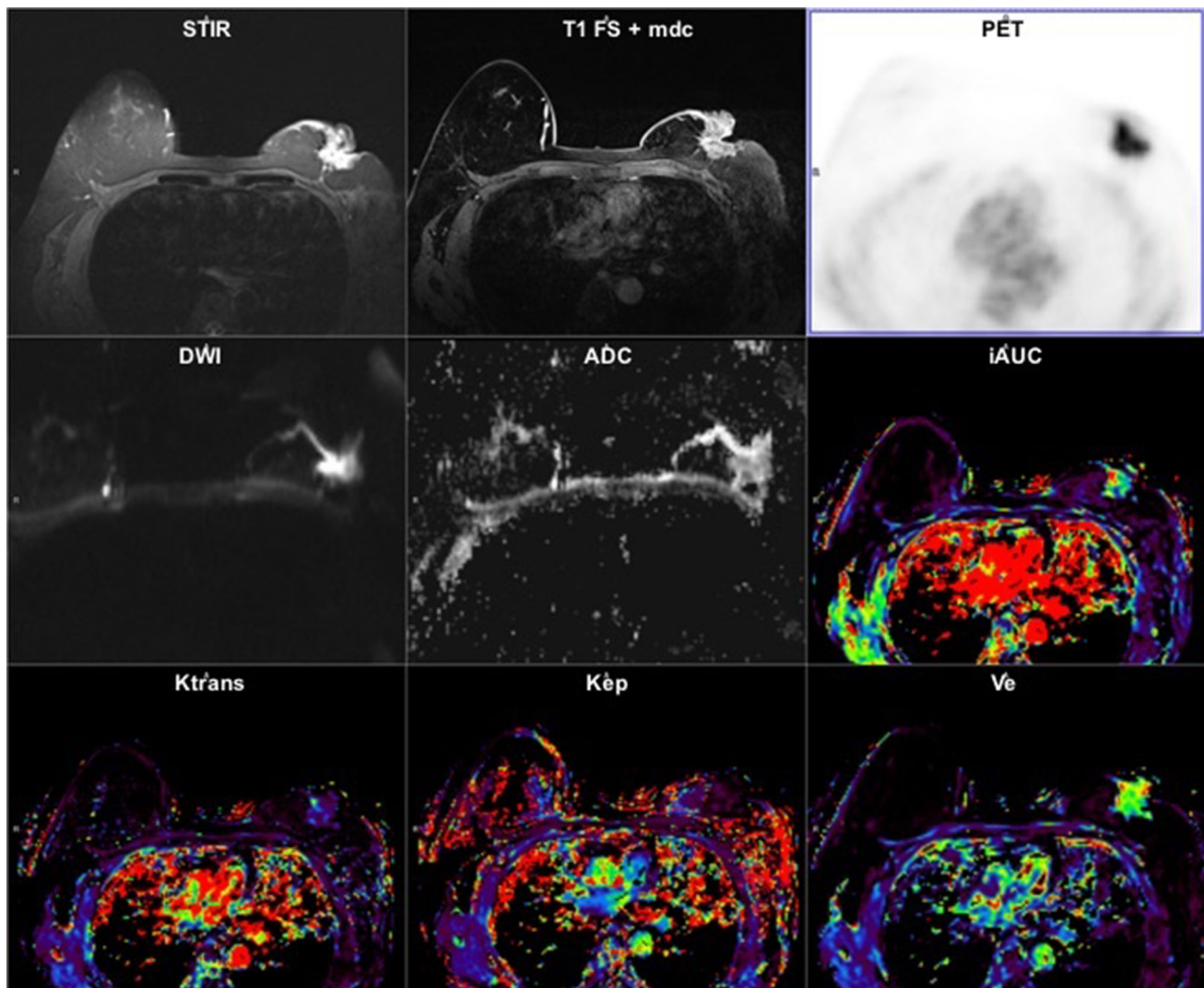


Fig. 2 Multiparametric evaluation of morphological (STIR and T1 FS + mdc), metabolic (PET) and functional (DWI, ADC, iAUC, K_{trans} , k_{ep} , V_e) of the same patient reported in Fig. 1 (Pt 1) after the

second cycle of cytotoxic chemotherapy. A significant reduction of tumor volume, FDG uptake, perfusion and an increased diffusivity are now detected compared to the pre-treatment evaluation

All the values of pre- and post-treatment morphological, metabolic and perfusion parameters for each patient are showed in Table 2.

Examples of pre- and post-treatment multiparametric analysis are, respectively, illustrated in Figs. 1 and 2.

Discussion

A previous paper has shown the value of pre-treatment DWI, DCE MRI parameters (K_{trans}) and 18F-FDG PET/CT measure SUV_{mean} as significant predictors for short-term response, assessed after two cycles of cytotoxic neo-adjuvant chemotherapy in breast cancer [9].

Of note, imaging of tumor glucose metabolism with ^{18}F -fluorodeoxyglucose (^{18}F -FDG) has gained widespread use to study the biological activity of tumor and overall prognosis of oncological patients [10]. ADC diffusion parameter provides microstructural information at the cellular level revealing area of restricted diffusivity, expression of high cell density; it has been demonstrated that diffusion technique can detect microstructural changes (increase in ADC values) before tumor size reductions are seen [11]. DCE parameters (iAUC, K_{trans} , K_{ep} and V_e) provide information about tumoral microvasculature, such as tissue perfusion, capillary permeability and integrity, and they are considered as promising biomarkers to monitor the effect of therapies that affect tumoral vascularization [12].

In our study we have evaluated the clinical value of simultaneously acquired PET/MRI morphological, metabolic and functional parameters (i.e., SUV_{max} , SUV_{mean} , MTV, ADC, iAUC, K_{trans} , K_{ep} and V_e) in a group of four patients for the assessment of response to neo-adjuvant cytotoxic chemotherapy and hormone therapy. In particular, we observed a significant reduction of post-treatment iAUC, K_{trans} and K_{ep} values and an increase of post-treatment ADC values in the two patients who underwent cytotoxic chemotherapy (Pts 1 and 2). A less pronounced but always significant reduction of the same parameters was observed in patient 4 (PR). Conversely, we have not observed the same changes of both diffusion and perfusion post-treatment values in patient 3, classified as SD; in particular, the substantially stable ADC values and the paradoxical increase of all perfusion parameters were probably related to the poor response to treatment. The less pronounced reduction of ADC and perfusion parameters in patient 4, compared to patients 1 and 2, could reflect the different mechanism of action of the 2 therapeutic schedules. A possible hypothesis could be the more direct cytotoxic effect of standard chemotherapy compared to hormone therapy resulting in

cell death with following reduction in cell density and/or release of pro-angiogenic cytokines. Conversely, hormone therapy, determining an indirect effect on cell proliferation by the inhibition of estrogen receptors, could have a less pronounced effect on cell density and especially on neoangiogenesis.

In conclusion, our preliminary results suggest that multiparametric evaluation with simultaneous PET/MRI could be a useful tool to assess the response to cytotoxic and hormone neo-adjuvant chemotherapy in patients with breast cancer. Future studies in a larger cohort of patients are warranted to confirm the results of this study and to further evaluate the role of pharmacokinetic modeling in simultaneous PET/MRI imaging.

Compliance with ethical standards

Conflict of interest The authors declare that they have no conflict of interest.

Ethical standards All procedures performed in studies involving human participants were in accordance with the ethical standards of the institutional and/or national research committee and with the 1964 Helsinki Declaration and its later amendments or comparable ethical standards.

Informed consent Informed consent was obtained from all individual participants included in the study.

References

- Rosenkrantz AB, Friedman K, Chandarana H, et al. Current status of hybrid PET/MRI in oncologic imaging. *AJR Am J Roentgenol*. 2016;206(1):162–72.
- Ho AM, Kalantari BN. PET/MRI: a new frontier in breast cancer imaging. *Breast J*. 2016;22(3):261–3.
- Tabouret-Viaud C, Botsikas D, Delattre BM, et al. PET/MR in breast cancer. *Semin Nucl Med*. 2015;45(4):304–21.
- Margolis NE, Moy L, Sigmund EE, et al. Assessment of aggressiveness of breast cancer using simultaneous 18F-FDG-PET and DCE-MRI: preliminary observations. *Clin Nucl Med*. 2016;41(8):e355–61.
- Eiber M, Martinez-Möller A, Souvatzoglou M, et al. Value of a Dixon-based MR/PET attenuation correction sequence for the localization and evaluation of PET-positive lesions. *Eur J Nucl Med Mol Imaging*. 2011;38(9):1691–701.
- Eisenhauer EA, Therasse P, Bogaerts J, et al. New response evaluation criteria in solid tumours; Revised RECIST guideline (version 1.1). *Eur J Cancer*. 2009;45(2):228–47.
- O JH, Lodge MA, Wahl RL. Practical PERCIST: a simplified Guide to PET response criteria in solid tumors 1.0. *Radiology*. 2016;280(2):576–84.
- Tofts PS, Kermode AG. Measurement of the blood-brain barrier permeability and leakage space using dynamic MR imaging. 1. Fundamental concepts. *Magn Reson Med*. 1991;17(2):357–67.
- Tateishi Y, Miyake M, Nagaoka T, et al. Neoadjuvant chemotherapy in breast cancer: prediction of pathologic response with PET/CT and dynamic contrast-enhanced MR imaging—prospective assessment. *Radiology*. 2012;263(1):53–63.

10. Weber WA, Schwaiger M, Avril N. Quantitative assessment of tumor metabolism using FDG-PET imaging. *Nucl Med Biol.* 2000;27(7):683–7.
11. Xu QG, Xian JF. Role of quantitative magnetic resonance imaging parameters in the evaluation of treatment response in malignant tumors. *Chin Med J.* 2015;128(8):1128–33.
12. Yankeelov TE, Lepage M, Chakravarthy A. Integration of quantitative DCE-MRI and ADC mapping to monitor treatment response in human breast cancer. *Magn Reson Imaging.* 2007;25(1):1–13.