

## Claire Grimwood<sup>1</sup>, Véronique Despert<sup>2</sup>, Isabelle Jeru<sup>3</sup> and Véronique Hentgen<sup>1</sup>

<sup>1</sup>French Reference Center for Autoinflammatory Diseases, Department of Pediatrics, Centre Hospitalier de Versailles, Le Chesnay, <sup>2</sup>Service de médecine de l'enfant et de l'adolescent, CHU de Rennes - Hôpital Sud, Rennes and <sup>3</sup>Laboratoire de génétique moléculaire, Hôpital Saint Antoine, Université Pierre et Marie Curie, Paris, France

Revised version accepted 6 March 2015

Correspondence to: Véronique Hentgen, French Reference Center for Autoinflammatory Diseases, Department of Pediatrics, Centre Hospitalier de Versailles, 177 rue de Versailles, 78150 Le Chesnay, France.

E-mail [vhentgen@ch-versailles.fr](mailto:vhentgen@ch-versailles.fr)

## References

- 1 Lachmann HJ, Papa R, Gerhold K, *et al.* The phenotype of TNF receptor-associated autoinflammatory syndrome (TRAPS) at presentation: a series of 158 cases from the Eurofever/EUROTRAPS international registry. *Ann Rheum Dis* 2014;73:2160–7.
- 2 Ter Haar N, Lachmann H, Özen S, *et al.* Treatment of autoinflammatory diseases: results from the Eurofever Registry and a literature review. *Ann Rheum Dis* 2013;72:678–85.
- 3 Drewe E, McDermott EM, Powell PT, Isaacs JD, Powell RJ. Prospective study of anti-tumour necrosis factor receptor superfamily 1B fusion protein, and case study of anti-tumour necrosis factor receptor superfamily 1A fusion protein, in tumour necrosis factor receptor associated periodic syndrome (TRAPS): clinical and laboratory findings in a series of seven patients. *Rheumatol Oxf* 2003;42:235–9.
- 4 Gattorno M, Pelagatti MA, Meini A, *et al.* Persistent efficacy of anakinra in patients with tumor necrosis factor receptor-associated periodic syndrome. *Arthritis Rheum* 2008;58:1516–20.
- 5 Piram M, Koné-Paut I, Lachmann HJ, *et al.* Validation of the Auto-Inflammatory Diseases Activity Index (AIDAI) for hereditary recurrent fever syndromes. *Ann Rheum Dis* 2014;73:2168–73.
- 6 Bodar EJ, Kuijk LM, Drenth JPH, *et al.* On-demand anakinra treatment is effective in mevalonate kinase deficiency. *Ann Rheum Dis* 2011;70:2155–8.

*Rheumatology* 2015;54:1751–1753

doi:10.1093/rheumatology/kev242

Advance Access publication 23 June 2015

### First report of *FIP1L1-PDGFR $\alpha$* -positive eosinophilic granulomatosis with polyangiitis

SIR, Eosinophilic granulomatosis with polyangiitis (EGPA, Churg–Strauss syndrome) is a rare systemic ANCA-associated vasculitis with a pathogenesis probably mediated by Th2-polarized responses [1, 2]. Recently, imatinib mesylate has proved effective in EGPA [3, 4], suggesting a possible pathogenic role for tyrosine kinases.

Tyrosine kinases encoded by fusion genes (e.g. *FIP1L1-PDGFR $\alpha$* ) are important in the pathogenesis of hypereosinophilic syndrome (HES), whose clinical features are often similar to those of EGPA. The *FIP1L1-PDGFR $\alpha$*  fusion gene, when found, is considered to rule out EGPA while supporting a diagnosis of primary HES [5]. Here, we describe the first case of a patient with EGPA carrying the *FIP1L1-PDGFR $\alpha$*  rearrangement and discuss whether this finding is relevant in the differential diagnosis between HES and EGPA.

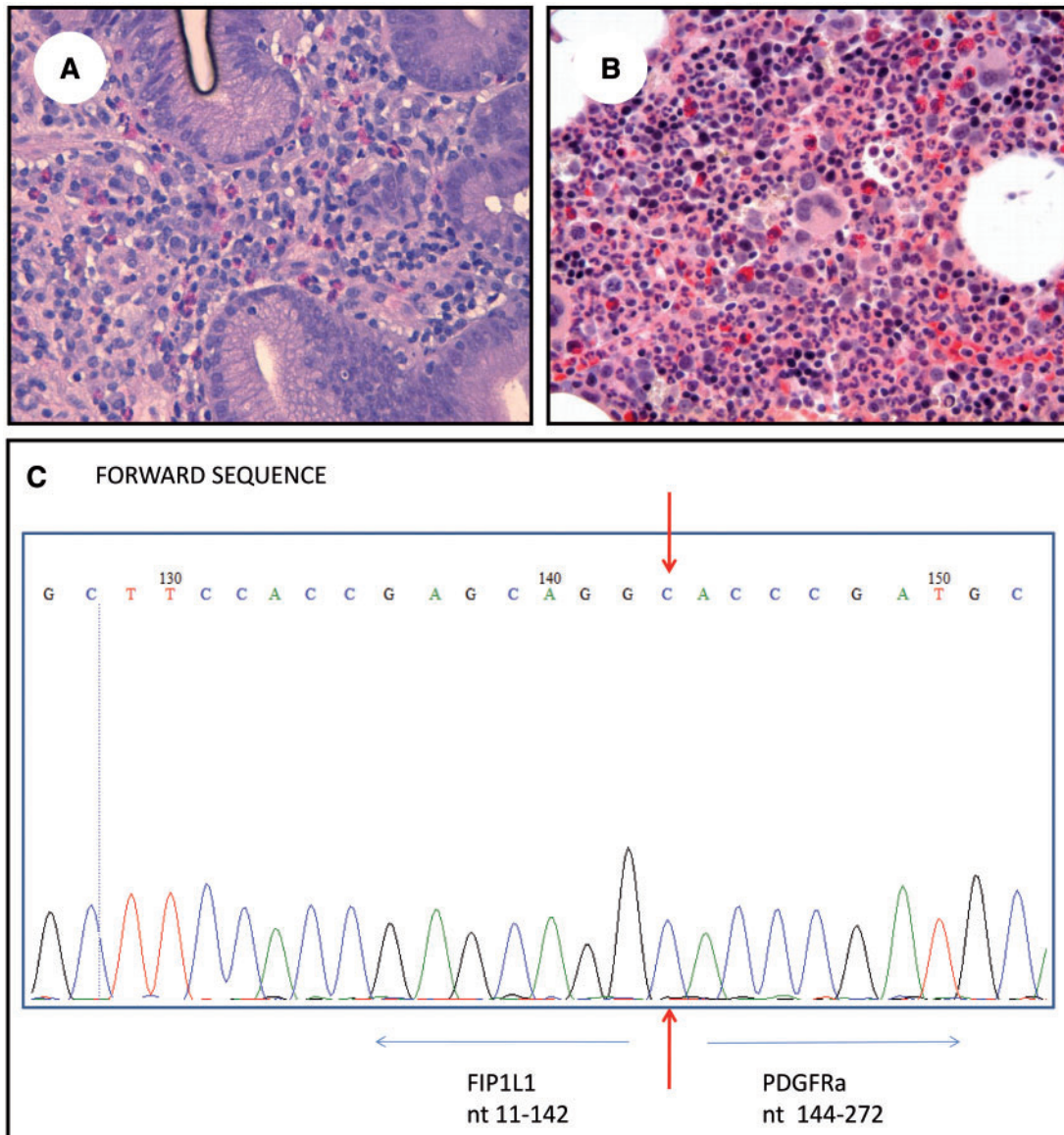
A 41-year-old woman was admitted to our unit for fever and severe asthma. One month earlier she had been diagnosed with EGPA in a neurology unit because she had mononeuritis multiplex with wrist and foot drop, asthma, nasal polyposis and rhinosinusitis, bloody diarrhoea, peripheral eosinophilia and P-ANCA positivity, which tested anti-MPO by ELISA (>100 EU/ml, normal <10). Endoscopy had revealed gastric erosions, with histological evidence of eosinophil-rich inflammation of the lamina propria (Fig. 1A). The patient received a pulse of 6-methylprednisolone (125 mg/day for 3 days), followed by oral prednisone and i.v. immunoglobulins (400 mg/kg/day for 5 days), with good clinical response. The off-label treatment with rituximab was approved by the AOU Careggi Hospital ethics committee, and informed consent was obtained.

On admission to our unit, she was taking 10 mg/day prednisone; laboratory tests showed persistent eosinophilia (5590/mm<sup>3</sup>) and mild anaemia (haemoglobin 10.2 g/dl). MPO-ANCA positivity was confirmed. Given the persistence of eosinophilia despite ongoing steroid therapy, bone marrow biopsy was also performed, and showed mild eosinophilic hyperplasia, without atypias (Fig. 1B). Moreover, we searched for *FIP1L1-PDGFR $\alpha$*  using a nested RT-PCR and for *FIP1L1-PDGFR $\beta$*  and *-FGFR1* fusion genes using FISH. This analysis revealed the presence of the *FIP1L1-PDGFR $\alpha$*  rearrangement (Fig. 1C; patient characteristics and details of the genetic analysis are reported in supplementary Table S1, available at *Rheumatology* Online).

The patient resumed 1 mg/kg/day prednisone, which induced symptom remission; however, epigastric pain, myalgia, neuropathy and blood hypereosinophilia flared when prednisone was tapered below 20 mg/day. Therefore, we added rituximab (1000 mg on days 0 and 15). The patient had a rapid clinical response, and the eosinophil count also normalized. Six months later, while taking 5 mg/day prednisone, she was asymptomatic, with a normal eosinophil count.

To the best of our knowledge, the *FIP1L1-PDGFR $\alpha$*  fusion gene has never been described in EGPA. To assess the frequency of this finding in EGPA, we conducted an exploratory analysis of the *FIP1L1-PDGFR $\alpha$*  fusion gene in 11 additional consecutive patients with systemic EGPA (detailed data are reported in supplementary Table S1, available at *Rheumatology* Online), all of whom tested negative. Nevertheless, we believe that our finding has potential pathogenic and clinical implications. Together with previous reports showing the efficacy

Fig. 1 Histological findings and Sanger sequencing image



(A) Gastric biopsy: an eosinophil-rich inflammatory infiltrate is observed in the lamina propria (haematoxylin and eosin,  $\times 40$ ). (B) Bone marrow biopsy: mild hyperplasia of the eosinophilic granulocyte series, without atypias; the other cellular lineages are normal (haematoxylin and eosin,  $\times 40$ ). (C) Sanger sequencing image of the patient (#1) who carried the *FIP1L1*-*PDGFR $\alpha$*  rearrangement.

of imatinib in EGPA [3, 4], it highlights the possible role of tyrosine kinases in EGPA pathogenesis. The exact mechanisms through which such kinases drive eosinophilia are still unclear [6]. Also, the presence of a *FIP1L1*-*PDGFR $\alpha$*  rearrangement cannot be considered an exclusive hallmark of HES/chronic eosinophilic leukaemia, and it may fail in distinguishing such conditions from EGPA. Finally, the presence of such a fusion gene in EGPA could help to identify an albeit very small proportion of patients who theoretically benefit from tyrosine-kinase inhibitors.

Given the severe disease presentation, our patient would probably have warranted a combined treatment with glucocorticoids and immunosuppressants, whereas she received only glucocorticoids. Upon disease relapse, we decided to use rituximab rather than CYC essentially because of the young age of the patient. The excellent response we observed is in line with recent reports demonstrating the efficacy of rituximab in refractory EGPA [7, 8]; interestingly, rituximab in EGPA has been shown to reduce the production of IL-5, probably by inhibiting B- to T-cell crosstalk [8].

## Rheumatology key message

- The *FIP1L1-PDGFR $\alpha$*  fusion gene, previously thought to be positive only in hypereosinophilic syndromes, can also be found in eosinophilic granulomatosis with polyangiitis.

## Acknowledgements

The authors wish to thank Dr Armando Rossi and Dr Giulia Raugi for having provided the images of gastric and bone marrow histology, and Dr Maria Letizia Urban for her help in the preparation of the figures. G.E. and A.V. equally reviewed the literature and prepared the manuscript. E.S., Roberto Marconi, A.M.V., V.C., L.E. and D.P. revised the manuscript. P.Z. and Roberto Marasca tested the *FIP1L1-PDGFR $\alpha$*  fusion gene and revised the manuscript. T.F. provided the Sanger sequencing image and revised the manuscript. All the authors have accepted the manuscript in its final form.

**Funding:** No specific funding was received from any funding bodies in the public, commercial or not-for-profit sectors to carry out the work described in this manuscript.

**Disclosure statement:** The authors have declared no conflicts of interest.

**Giacomo Emmi<sup>1</sup>, Elena Silvestri<sup>1</sup>, Roberto Marconi<sup>2</sup>, Valentina Carrai<sup>3</sup>, Tiziana Fanelli<sup>1</sup>, Patrizia Zucchini<sup>4</sup>, Roberto Marasca<sup>4</sup>, Alessandro Maria Vannucchi<sup>1,3</sup>, Lorenzo Emmi<sup>5</sup>, Domenico Prisco<sup>1,5</sup> and Augusto Vaglio<sup>6</sup>**

<sup>1</sup>Department of Experimental and Clinical Medicine, University of Florence, Florence, <sup>2</sup>Neurology Unit, Grosseto Hospital, Grosseto, <sup>3</sup>SOD Haematology, AOU Careggi, Florence, <sup>4</sup>Hematology Unit, Department of Medical and Surgical Sciences, University of Modena and Reggio Emilia, Modena, <sup>5</sup>SOD Interdisciplinary Internal Medicine, Center for Autoimmune Systemic Diseases, Behçet Center and Lupus Clinic, AOU Careggi, Florence and <sup>6</sup>Nephrology Unit, University Hospital of Parma, Parma, Italy  
Revised version accepted 27 May 2015

Correspondence to: Giacomo Emmi, Dipartimento di Medicina Sperimentale e Clinica, Università di Firenze – L.go G. Brambilla 3, 50134 Firenze, Italia.  
E-mail: giacomaci@yahoo.it

## Supplementary data

Supplementary data are available at *Rheumatology* Online.

## References

- 1 Jennette JC, Falk RJ, Bacon PA *et al.* 2012 revised International Chapel Hill Consensus Conference Nomenclature of Vasculitides. *Arthritis Rheum* 2013;65:1–11.

- 2 Vaglio A, Buzio C, Zwerina J. Eosinophilic granulomatosis with polyangiitis (Churg–Strauss): state of the art. *Allergy* 2013;68:261–73.
- 3 Josselin-Mahr L, Werbrouck-Chiroux A, Garderet L, Cabane J. Efficacy of imatinib mesylate in a case of Churg–Strauss syndrome: evidence for the pathogenic role of a tyrosine kinase? *Rheumatology* 2014;53:378–9
- 4 Erre GL, Pardini S, Cuccuru L, Taras L, Passiu G. Is there a role for imatinib mesylate in the treatment of eosinophilic granulomatosis with polyangiitis? *Joint Bone Spine* 2015;82:72–3
- 5 Mouthon L, Dunogue B, Guillevin L. Diagnosis and classification of eosinophilic granulomatosis with polyangiitis (formerly named Churg–Strauss syndrome). *J Autoimmun* 2014;48–49:99–103.
- 6 Li B, Zhang G, Li C *et al.* Identification of JAK2 as a mediator of FIP1L1-PDGFR $\alpha$ -induced eosinophil growth and function in CEL. *PLoS One* 2012;7:e34912.
- 7 Thiel J, Hässler F, Salzer U, Voll RE, Venhoff N. Rituximab in the treatment of refractory or relapsing eosinophilic granulomatosis with polyangiitis (Churg–Strauss syndrome). *Arthritis Res Ther* 2013;15:R133.
- 8 Pepper RJ, Fabre MA, Pavesio C *et al.* Rituximab is effective in the treatment of refractory Churg–Strauss syndrome and is associated with diminished T-cell interleukin-5 production. *Rheumatology* 2008;47:1104–5.

*Rheumatology* 2015;54:1753–1754

doi:10.1093/rheumatology/kev098

Advance Access publication 3 May 2015

### Comment on: Benefits and risks of low-dose glucocorticoid treatment in the patient with rheumatoid arthritis

SIR, The recently reported review [1] in this journal, though interesting, does not appear to do full justice to the title on the cover ‘New approaches to glucocorticoid treatment for rheumatoid arthritis’ and in fact fails to add substantially to what is already known on this subject. For example, the effect of glucocorticoids on radiological progression in RA has already been appraised [2], as have their clinical benefits and safety [3, 4]. Methodologically, the authors appear to have conducted a systematic review; however, their reporting is inadequate [5]. For example, the present review is marked by the absence of a flow diagram of studies, lack of sufficient information on the method of data collection, measures to ascertain the missing data in the studies and bias, the absence of quality assessment of the included studies, and a lack of discussion on the limitations at the study and outcome level. These and several other lacunae [5] prevent a reader from drawing any meaningful conclusions, and establish generalizability.

Deflazacort is the only glucocorticoid derivative that, despite its initial hype, is still widely used (though only in a few countries, including India, Spain and Mexico); it, therefore, deserves a fuller appraisal [6]. The popularly