

Complication of endoscopic tattooing: a case report of covered perforation

N. FALCO, T. FONTANA, R. TUTINO, L. LICARI, C. RASPANTI, A. MASCOLINO, I. MELFA, G. SCERRINO, G. SALAMONE, G. GULOTTA

SUMMARY: Complication of endoscopic tattooing: a case report of covered perforation.

N. FALCO, T. FONTANA, R. TUTINO, L. LICARI, C. RASPANTI, A. MASCOLINO, I. MELFA, G. SCERRINO, G. SALAMONE, G. GULOTTA

Aim. Laparoscopy is considered a good approach in treatment of colorectal neoplastic diseases; the endoscopic tattooing is then recommended (Evidence Level III and grade of recommendation A) to mark a lesion or a polypectomy site for intraoperative identification. We describe the case of perforation after tattooing treated conservatively.

Case report. 63 years old woman, underwent colonoscopy for lipoma tattooing with India ink SPOT® solution kit and saline test. Immediately after the procedure the patient has been referred the appearance of colic epi-mesogastric pain and fever; Computed Tomography

(CT) without MDC identified an irregular thickening of transverse colon with some microbubbles compatible with focal peritonitis. Initial paralytic ileus was present too. The blood count and metabolic panel examinations reveal a neutrophil leucocytosis (WBC: 11.000/mm³, 80% neutrophils).

Results. On the base of WSES sepsis severity score and recent literature patient was treated conservatively with total parenteral nutrition, and intravenous antibiotic therapy. After the resolution of fever and reactivation of peristalsis. The discharge occurred after six days with no early complications.

Conclusion. India ink tattooing with SPOT® solution kit and saline test represent the first choice. It is a feasible technique although perforation is a possible complication. It may need an immediately surgical operation but in most cases a conservative management is a good and safe tool even if surgery may be attempted too.

KEY WORDS: Endoscopy - Tattooing - Perforation - Surgery.

Introduction

In the last decade laparoscopy acquired more and more indications for many malignant and non malignant abdominal diseases although the procedure doesn't ever consent a good recognition of lesions in patients with small ones. Then tattooing is recommended (Evidence Level III and grade of recommendation A) to mark a lesion or a polypectomy site for future surgical identification (1). This procedure, that is quite cheap, should become a routine procedure in addition to routine colonoscopy although it isn't free from risks and complications (1). The most common technique is the India

ink tattooing with saline test. This technique, according to the literature, involves the injecting 1 ml of saline solution into the submucosal layer to form a proper submucosal elevation followed by the injection of 1 to 1.5 ml of India ink (2).

Patients and methods

RD, female, 63 years old. She underwent colonoscopy for diarrhoea with diagnosis of 3,5 cm polyp covered by intact mucosa, classified as lipoma of the middle tract of transverse colon. This medical case had been deeply examined with the use of Computed Tomography (CT) with ev infusion of iodate contrast medium. This examination confirmed the diagnosis of lipoma of middle transverse colon, and identified the presence of S7 hepatic angioma and inguinal lymphadenopathy (dt max 1.3 cm). Patient went in another hospital requiring a surgical approach. So the operation was planned and the

Department of Surgical, Oncological and Oral Sciences, University of Palermo, General Surgery and Emergency Operative Unit, Policlinico Universitario "P. Giaccone", Palermo, Italy

Corresponding author: Nicolò Falco, nicola.falco87@libero.it

© Copyright 2016, CIC Edizioni Internazionali, Roma

lesion has been tattooed two days before the planned resection with India ink SPOT[®] solution kit and saline test. Immediately after the colonoscopy and the tattooing procedure, the patient referred colic epi-mesogastric pain and fever (38.5° C) with paralytic ileus. After specialist consulting the patient started oral antibiotics but in spite of this therapy she kept on having the same symptoms. Then she came to emergency area of University Hospital of Palermo "P. Giaccone" where a CT without MDC identified in the middle part of transverse colon an irregular thickening of bowel wall with some microbubbles referring to focal peritonitis induced by covered perforation in the presumable region of the tattoo (Figure 1). The blood count and metabolic panel examinations reveal a neutrophil leucocytosis (WBC: 11.000/mm³, 80% neutrophils). Oral intake was stopped; total parenteral nutrition (TPN) and antibiotic therapy with Metronidazole 500 mg three times/die and Cefazolin 1 g two times a day were started. WSES sepsis severity score (WISS: Appendix) that had proven very useful for the stratification of the septic risk was used at the admission time and a score of 4 was calculated clinical findings and laboratory tests was controlled daily to monitoring sepsis evolution.

Results

After 4 days of therapy we noticed the missing of fever and the WBC decreasing. After 5 days, a new CT revealed that colon thickening reduced, and that the air microbubbles disappeared (Figure 2). Because of the per-

sistence of paralytic ileus and according to our experience in the treatment of post-operative ileus, the patients started the hiring of 10 cc of water two a days (3). 24 hours later we observed the reactivation of peristalsis. So a soft oral diet was started. The day after the patient was discharged with the indication to repeat the colonoscopy in a month. During follow-up, the patient didn't report onset of symptoms worthy of note.

Discussion

In 1975 Ponsky and King were first Authors to talk about the endoscopic tattooing of the colon with India ink (4). The tattooing technique has been experienced for the first time in 1989 on dogs; India ink, Methylene blue, and Indocyanine green and other eight agents were compared. This study showed that methylene blue had an excellent staining, but at the same time it was not long-lasting (about 24 hours). Instead the Indocyanine green and the India ink remained visible on the serosal surface over 48 hours, but the second one can cause a significant inflammatory infiltrate with micro-haemorrhage and thrombosis (5). Anyway Nizam et al. in a review of 447 cases (1996) of colonic tattooing with India ink confirmed that this inflammatory reaction is responsible of only 0,22% of post tattooing complications, moreover other different retrospective studies demonstrated the safety and the efficacy of this long-lasting India ink tattooing (6-8). In order to reduce the risk of complication, some different colonoscopic tattooing technique have been proposed. The first one is the saline

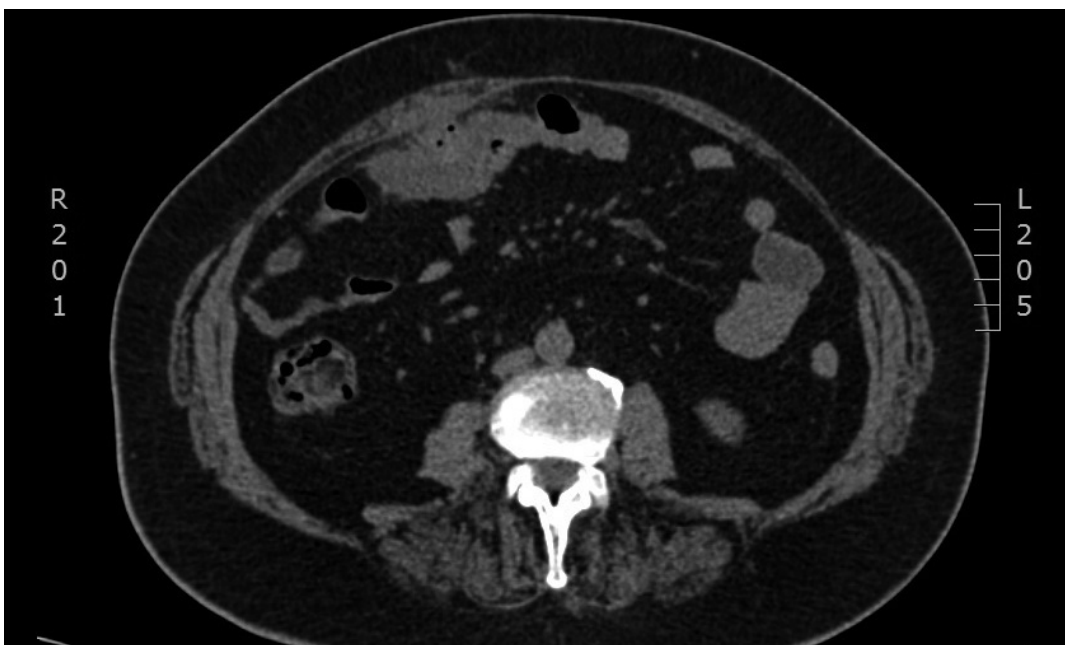

Fig. 1 - CT image of perforation.

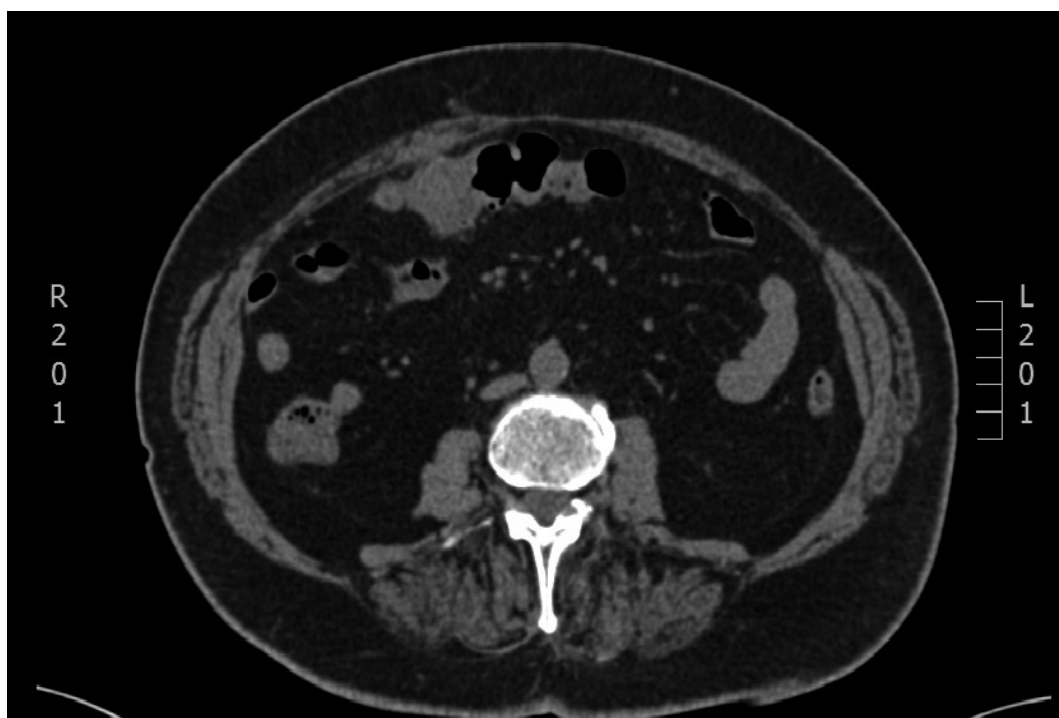


Fig. 2 - CT image of remission.

test injection method with use of SPOT® solution. This technique improve the security of India ink colouration, and become the choice for tattooing due to its simplicity, as well as for its security and its being a long-lasting stain (2). Recently, two other techniques were proposed: the first one was the application of a new Indocyanine green that could permit with a particular device to observe with more precision where the injection takes place, and also the lymphonodal drainage (9); the second consists instead in applying fluorescent clips, but it still has the problem of removal for traction, caused by the transit of stool (10).

In our case we observe a covered microperforation with probable peritoneal bacterial transposition. This clinical condition was diagnosed 24h after the iatrogenic perforation and with CT (11). The management of perforation after colonoscopy perforation isn't univocal because the choice of the most correct treatment depends from the cause of perforation (mechanical traction, diastatic wreckage, polypectomy, tattooing), comorbidities, bowel preparation, dimensions of the wreckage (12-14).

Cappello et al. describe a case occurring to 80 years old man with ulcerative colitis (RCU), hospitalized for diarrhoea (six motions/day) with mucus and, occasionally, blood. After bowel preparation he underwent diagnostic colonoscopy complicated 1 h after with an extensive subcutaneous emphysema. First they try to treat the patient conservatively with antibiotic therapy and TPN, but the septic parameters had been worsening and

it needed an exploratory laparotomy and subsequent right emicolectomy (12).

Castellvi et al. published a retrospective multicentric study of patients diagnosed of colonoscopic perforation. 54 patients were enrolled (34 were diagnostic colonoscopy and 20 therapeutic ones).

In conclusion Castellvi et al. recommend when possible a non operative management and when necessary an early surgical operation. Furthermore a good bowel preparation it's necessary to prevent an high septic status (13). Other example was described by Akgul et al. They decided to treat conservatively a post-colonoscopy 5 cm perforation of the posterior wall of the recto-sigmoid junction with subsequent retroperitoneal emphysema, stopping oral intake and with the infusion of intravenous antibiotics. The patient was discharged ten days later without any complications during one month follow-up (14). Endoscopic VAC therapy was approved for treatment of bowel leakage and useful also for the treatment of bowel perforation (15). Nevertheless in literature we can found just few cases of complications due to India ink tattooing. Coman et al. described a case of fat necrosis with a consequential inflammatory pseudotumor due to endoscopic tattooing of the colon with India ink (16). Gianom et al. described a similar case of localized necrosis and retroperitoneal perforation due to endoscopic tattooing formed as a consequence of a local inflammatory pseudotumor (17). Laura M. Alba et al. described another suggestive example of a patient who

developed a rectus muscle abscess 10 days after the injection of India ink adjacent to a large and sessile colonic polyp (4). Although it does not happen that often, there is still the possibility of inducing an inflammatory reaction, as well as to introduce enteric bacteria into the peritoneal cavity or into the adjacent structures; this possibility should be taken into account when is attempted an endoscopic colonic tattooing with India ink.

According to these literature data we decided to adopt a conservative strategy. In fact the post-colonoscopy diagnosis of the perforation, the lower bacterial burden given by the bowel preparation, justified a conservative therapeutic approach. Anyway the therapeutic choice depends on sepsis and its evolution but its evaluation is very difficult because of unpredictability of the SIRS (Systemic Inflammatory Response Syndrome). In this way we decided to use the WSES sepsis severity score (WISS: Appendix) that had proven very useful for the stratification of the septic risk (18). In fact at the admission time the score was 4 and after stopping oral intake, starting TPN and intravenous antibiotic therapy, we controlled daily the clinical findings and laboratory tests to monitoring sepsis evolution. The option of endoscopic vacuum therapy was starting evaluated but because of the rapid remission of opening clinical square it was not necessary (15).

Conclusion

According to Società Italiana di Chirurgia Colo-Rettale (SICCR) guidelines the endoscopic management of early forms of colon cancer consider with high grade of recommendation the tattooing of early lesion with long lasting colouration. India ink tattooing with SPOT kit and saline test represent the first choice in long term follow-up. India ink compared to other colouration is cause of chronic inflammation in 0,22% of case. The inflammatory infiltrate could be the cause of micro haemorrhage and thrombosis, fat necrosis with a consequential inflammatory pseudotumor, retroperitoneal perforation, rectus muscle abscess, introduction of en-

teric bacteria into the peritoneal cavity. It needs to consider all the complications of colonoscopy as perforation and stercoraceous peritonitis, stripping of mesocolon and subsequent emoperitoneum, subcutaneous emphysema, pneumoperitoneum, pneumomediastinum. These complications are more frequent and fearsome in patients with severe inflammation of colon in elderly people were comorbidity as cardiac failure, atheromasia of abdominal vessels could cause bowel ischemia or ipoperfusion with high postoperative risks. These complications may need a immediately surgical operation but as in our case a conservative approach with parenteral nutrition and antibiotic therapy with a large spectre of action and a TC follow-up could represent a feasible medical strategy. Endoscopic vacuum therapy and sealant are possible alternatives in case of covered perforations.

Appendix

Clinical condition at the admission	
• Severe sepsis (acute organ dysfunction) at the admission	3 score
• Septic shock (acute circulatory failure characterized by persistent arterial hypotension. It always requires vasopressor agents) at the admission	5 score
Setting of acquisition	
• Healthcare associated infection	2 score
Origin of the IAIs	
• Colonic non-diverticular perforation peritonitis	2 score
• Small bowel perforation peritonitis	3 score
• Diverticular diffuse peritonitis	2 score
• Post-operative diffuse peritonitis	2 score
Delay in source control	
• Delayed initial intervention (Preoperative duration of peritonitis (localized or diffuse) > 24 h)	3 score
Risk factors	
• Age > 70	2 score
• Immunosuppression (chronic glucocorticoids, immunosuppressant agents, chemotherapy, lymphatic diseases, virus)	3 score

References

1. Bianco F, Arezzo A, Agresta F, Coco C, Faletti R, Krivocapic Z, Rotondano G, Santoro GA, Vettoreto N, De Franciscis S, Belli A, Romano GM. Practice parameters for early colon cancer management: Italian Society of Colorectal Surgery (Società Italiana di Chirurgia Colo-Rettale; SICCR) Guidelines. *Tech Coloproctol*. 2015;19:577-585.
2. Park JW, Sohn DK, Hong CW, Han KS, Choi DH, Chang HJ, Lim S-B, Choi HS, Jeong S-Y. The usefulness of preoperative colonoscopic tattooing using a saline test injection method with pre-packaged sterile India ink for localization in laparoscopic colorectal surgery. *Surg Endosc*. 2008;22:501-505.
3. Bonventre S, Inviati A, Di Paola V, Morreale P, Di Giovanni S, Di Carlo P, Schifano D, Frazzetta G, Gulotta G, Scerrino G. Evaluating the efficacy of current treatments for reducing postoperative ileus: a randomized clinical trial in a single center. *Minerva Chir*. 2014 Feb;69(1):47-55.
4. Alba LM, Pandya PK, Clarkston WK. Rectus muscle abscess as-

- sociated with endoscopic tattooing of the colon with India ink. *Gastrointest Endosc.* 2000 Oct;52(4):557-8.
5. Hammond DC, Lane FR, Welk RA, Madura MJ, Borreson DK, Passinault WJ. Endoscopic tattooing of the colon. An experimental study. *Am Surg.* 1989 Jul;55(7):457-61.
 6. Nizam R, Siddiqi N, Landas SK, Kaplan DS, Holtzaple PG. Colonic tattooing with India ink: benefits, risks and alternatives *Am J Gastroenterol.* 1996.
 7. Shatz BA, Weinstock LB, Swanson PE, Thyssen EP. Long-term safety of India ink tattoos in the colon. *Gastrointest Endosc.* 1997 Feb;45(2):153-6.
 8. McArthur CS, Roayaie S, Wayne JD. Safety of preoperation endoscopic tattoo with india ink for identification of colonic lesions. *Surg Endosc.* 1999 Apr;13(4):397-400.
 9. Makoto Watanabe, Akira Tsunoda, Kazuhiro Narita, Mitsuo Kusano, Mitsuharu Miwa. Colonic Tattooing Using Fluorescence Imaging with Light-Emitting Diode-Activated Indocyanine Green: A Feasibility Study. *Surg Today.* 2009;39:214-218.
 10. Hiroshi Takeyama, Taishi Hata, Junichi Nishimura, Ryoji Nonaka, Mamoru Uemura, Naotsugu Haraguchi, Ichiro Takemasa, Tsunekazu Mizushima, Hirofumi Yamamoto, Yuichiro Doki, Masaki Mori. A novel endoscopic fluorescent clip visible with near-infrared imaging during laparoscopic surgery in a porcine model. *Surg Endosc.* 2014;28:1984-1990.
 11. Seishima R, Okabayashi K, Hasegawa H, Tsuruta M, Hoshino H, Yamada T, Kitagawa Y. Computed tomography attenuation values of ascites are helpful to predict perforation site. *World J Gastroenterol.* 2015 Feb 7;21(5):1573-9.
 12. Cappello M, Randazzo C, Peralta S, Cocorullo G. Subcutaneous emphysema, pneumomediastinum and pneumoperitoneum after diagnostic colonoscopy for ulcerative colitis: a rare but possible complication in patients with multiple risk factors. *Int J Colorectal Dis.* 2011 Mar;26(3):393-4.
 13. Castellví J, Pi F, Sueiras A, Vallet J, Bollo J, Tomas A, Verge J, Caballero F, Iglesias C, De Castro J. Colonoscopic perforation: useful parameters for early diagnosis and conservative treatment. *Int J Colorectal Dis.* 2011 Sep;26(9):1183-90.
 14. Akgul GG, Yenidogan E, Ozsoy Z, Okan I, Kayaoglu HA, Tali S, Sahin M. Conservative Management of Large Rectosigmoid Perforation under Peritoneal Reflection: Case Report and Review of the Literature. *Case Rep Surg.* 2015;2015:364576.
 15. Kuehn F, Janisch F, Schwandner F, Alsfasser G, Schiffmann L, Gock M, Klar E. Endoscopic Vacuum Therapy in Colorectal Surgery. *J Gastrointest Surg.* 2016 Feb;20(2):328-34.
 16. Coman E, Brandt LJ, Brenner S, Frank M, Sablay B, Bennett B. Fat necrosis and inflammatory pseudotumor due to endoscopic tattooing of the colon with india ink. *Gastrointest Endosc.* 1991 Jan-Feb;37(1):65-8.
 17. Gianom D, Hollinger A, Wirth HP. Intestinal perforation after preoperative colonic tattooing with India ink. *Swiss Surg.* 2003;9(6):307-10.
 18. Sartelli M, et al. Global validation of the WSES Sepsis Severity Score for patients with complicated intra-abdominal infections: a prospective multicentre study (WISS Study). *World J Emerg-Surg.* 2015 Dec 16;10:61.
-