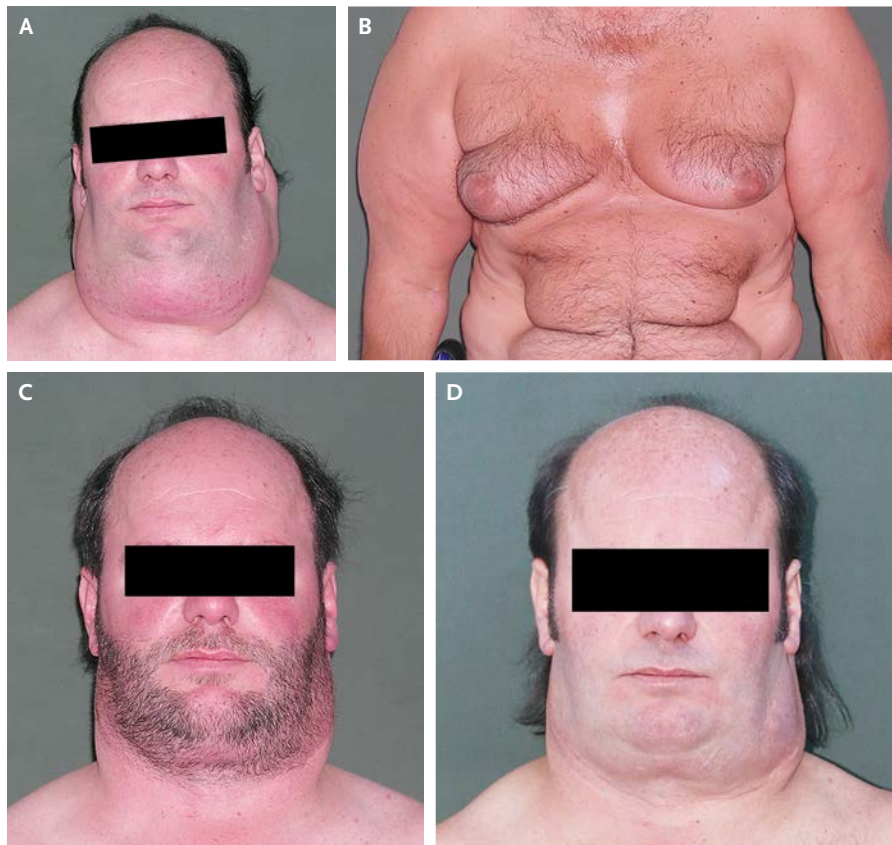


## IMAGES IN CLINICAL MEDICINE

Lindsey R. Baden, M.D., *Editor*

## Madelung's Disease



Giuseppe Nisi, M.D.  
Andrea Sisti, M.D.

University of Siena  
Siena, Italy  
[asisti6@gmail.com](mailto:asisti6@gmail.com)

**A** 48-YEAR-OLD MAN PRESENTED TO THE CLINIC FOR EVALUATION OF DYSPHAGIA and limited neck movements (flexion and rotation of the head). The patient was found to have Madelung's disease, also known as benign symmetric lipomatosis or the Launois–Bensaude syndrome. Madelung's disease is a rare condition that is characterized by the presence of multiple symmetric and disfiguring abnormal fat depositions in the head, neck, trunk, and nerve roots of the upper and lower limbs (Panels A and B). Patients often have coexisting illnesses, such as hepatic-function abnormalities, polyneuropathy, diabetes, gynecomastia, hyperuricemia, and dyslipidemia. Madelung's disease is often associated with alcohol abuse, but there is a familial form linked to matrilineal inheritance. The frequent finding of radial red fibers in the muscles of patients with Madelung's disease suggests mitochondrial dysfunction with reduced activity of the enzyme cytochrome *c* oxidase. Treatment is palliative and consists mainly of removal of fatty tissue by surgical resection or liposuction and by injection lipolysis. The patient was treated surgically and had a good functional and aesthetic result at 1 year after surgery (Panel C). Partial recurrence after treatment is common, as occurred in this patient 3 years after surgery (Panel D).

DOI: [10.1056/NEJMicm1503861](https://doi.org/10.1056/NEJMicm1503861)

Copyright © 2016 Massachusetts Medical Society.