

**Ministry of Health of the Republic of Belarus  
Educational establishment «Vitebsk state order  
of peoples' Friendship medical university.»**

***A.K. Usovich, W.A Tesfaye***

**Preparation materials for final  
examination on human anatomy  
speciality 1 79 01 01 (General medicine)**

Recommended by educational and methodical Association on medical education  
of the Republic of Belarus as a manual for students of institutions  
of higher education in the speciality 1-790101 "general medicine"



**Vitebsk – 2015**

12K 611(075.8) = 111

89 ~~УДК 611~~  
ББК 28.860я73  
У-76

Reviewed by

**E.C. Okolokulak** MD, PhD, DSc., Professor of the Department of Normal Anatomy Educational establishment "Grodno State Medical University"

Department of Human Anatomy with the course of Operative Surgery and Topographic anatomy, Educational establishment "Gomel State Medical University". Head of the Department, docent, PhD **V.N. Zdanovich**

**Usovich A.K.**

У 76 Preparation materials for final examination on human anatomy speciality 1 79 01 01 (General medicine)/ A.K. Usovich, W.A Tesfaye.-Vitebsk: VSMU, 2015.-120p.

ISBN 978-985-966-768-3

The manual «Preparation materials for final examination on human anatomy speciality 1 79 01 01 (General medicine)» includes criteria of knowledge evaluation at examination and competency of students on the subject "human anatomy, the order of passing an examination, multiple choice questions for carrying out of the first stage of examination, situational problems and answers, interpretation of roentgenograms, the list of basic and additional literature. The manual is prepared in accordance with the program on human anatomy for the students of medical faculties of higher medical educational institutions specialty 1 79 01 01 (General medicine) (Minsk, 2014).

The manual is intended for students of medical higher educational institutions.

ISBN 978-985-966-768-3

УДК 611  
ББК 28.860я73

© Usovich A.K., Tesfaye W.A., 2015  
© EE "Vitebsk state medical University, 2015

311492

Библиотека  
Учреждение образования  
"Витебский государственный  
ордена Дружбы народов  
медицинский университет"

## Contents

Preface	4
I. The order of passing an examination	5
II. Criteria of knowledge evaluation at examination and competency of students on the subject "human anatomy" (the five-point scale is specified in brackets)	6
III. The statute of the rating system	11
IV. Multiple choice questions for carrying out of the first stage of examination	15
V. List of the questions, which have been included in the examination cards for carrying out of the examination on human anatomy	97
VI. Sample of examination card	108
VII. Situational tasks for exam ...	108
VIII. Answers to situational tasks	112
IX. Algorithm of the photographs Interpretation	117
X. Literature ...	118

## PREFACE

In the training of doctors of any specialty, Human anatomy is the first science that opens the curtain to the future of professional activities, laying the foundations of special knowledge. Department of human anatomy (“anatomica”) is the first step on the road to the medicine. 2-year students, for whom, which is intended this manual, already understand how high this step is. If the 1-year students will see this manual, they may be in doubt that they will cover everything on human anatomy in 3 semesters, and show their knowledge and skills in exam.

This manual is recommended for students and includes all materials, (anatomical preparations, textbooks and atlases) which will support students to prepare for the exam.

For all students who started to work on this system from beginning (1 semester), criteria of assessment for all types of studying activities and the statute of the rating system which was approved by the rector of VSMU is necessary.

For current laboratory lesson and examination tests, we used illustration from textbook of students which is recommended. So in this manual illustrations from textbooks and atlases is not used for teaching students but to control and analyze knowledge of students during the training. Thus we do not infringe the right of authors illustrations, but we advertised these publications as educational literature. Hope that this publication will be useful for students to prepare in examination of human anatomy. The author will be grateful for helpful comments from teachers and students aimed at improving this work.

## I. Order of passing an examination

Examination of human anatomy on speciality 17 90101 (general medicine) is conducted in accordance with curriculum in winter exam after finishing 3 semesters. Final mark will be allotted in examination sheet and record-book of the student after discussion of state examination board.

Examination includes 3 stages.

1 stage - computer multiple-choice testing is held on termination of semester. Each student has to answer 100 questions out of 500 during 1 hour (the questions) stated below. Each multiple-choice question (test) has 5 variants of answers; correct answer may be from 1 up to 5 options. To answer the multiple-choice questions, the students are to have their record-books. The minimal pass mark for the multiple-choice questions is 70%. Below 69% is an outright fail and the examination must be repeated with the nearest opportunity.

If a student answers more than 70 % of questions correctly, he (she) will be transferred from the first stage and goes on to the subsequent stages if he (she) has passed 1, 2 and 3 semester anatomy course).

2<sup>nd</sup> stage - practical skills.

3<sup>rd</sup> stage – theoretical interview, which will be conducted on the day of examination in accordance with the schedule of dean's office. Questions on practical skills and theoretical interview are combined in these stages.

Distribution of tickets of examination for students starts at 8:00. When choosing the ticket student must show: her (his) record-book with stamps, diary of practical skills which informs that he (she) is admitted to the examination session. During examination students are recommended to wear a gown and a medical cap. While working with anatomical preparations, students may use medical gloves.

The order of taking an examination, all anatomical preparations, X-ray photographs (tomogram) will be explained to all students during a consultation, one day before the examination at 15:00. The timetable of consultations, examination program, questions for examination, and clinical problem solving for state examination are represented on the information stand of department.


Each student receives examination card, clinical problem solving for state examination and X-ray photograph or tomogram. According to questions of card and clinical problem solving, student selects anatomical preparations, on which he (she) will be able to show all structures.

On results of the answer a student gets 2 marks for each answer: first mark (theoretical) - result of the content of interview, second mark (practical) -result of demonstration on anatomical preparation or the X-ray photograph. Theoretical mark and practical mark are summarized on each part of question individually and then calculated separately (practical and theoretical parts).

The average result of the theoretical and practical stages of examination will be written in the general exam paper and in the record-book. The results of examination are announced for students at the end of state examination commission session.

Student may take his/her record-book after returning the textbooks of human anatomy in to the library of university.

Certify  
Rector of VSMU  
professor



V.P. Deikalo  
" 1 " September 2014

## **II. Criteria of knowledge evaluation and competence of students. Educational discipline "human anatomy" (five-point marking scale is indicated in brackets)**

### **10 points - (5+):**

- systematized, deep and full knowledge of all divisions of the educational program and basic questions which are outside the scope of the program; demonstration of organs and structures which have been previously studied in the frames of theme, details of their structure on preparations, plaster casts, roentgenograms, tomograms;

- correct usage of scientific Latin and English (Russian) terminology, stylistically competent and logically correct representation of the answer;

- irrefragable skill of the dissection technique and work with anatomical instruments (tweezers, scalpel); ability to work with negatoscope and to read the roentgenograms, tomograms according to algorithm;

- represented ability to handle with complex problems and non-standard situations independently and constructively;

- full and deep mastering of basic and additional literature recommended by the educational program of the discipline;

- skill to orientate oneself in theories, conceptions and directions of the studied discipline and to give a critical valuation, to use scientific achievements of other disciplines;

- ability to represent graphically (sketchily) basic stages of development of organs and systems of organism, formation of anomalies and deformities; to know basic causes their occurrence;

- creative independent work at laboratory classes, electives and during self-preparation to classes, participation in SRWS (Scientific Research Work of Students) and ARWS (Academic Research Work of Students) on problems of anatomy, active participation in group discussions, absence of violations of deontological and sanitary-hygienic rules of work with anatomical preparations, high level of culture of task execution.

### **9 points - (5):**

-systematized, deep and full knowledge of all divisions of the educational program; demonstration of organs and structures which have been previously

studied in the frames of the theme, details of their structure on preparations, plaster casts, roentgenograms, tomograms;

- correct usage of scientific Latin and English (Russian) terminology, stylistically competent and logically correct representation of the answer;

- skill of the dissection technique and work with anatomical instruments (tweezers, scalpel); ability to work with negatoscope and to read the roentgenograms, tomograms according to algorithm;

- ability to handle with complex problems and non-standard situations independently and constructively;

- full and deep mastering of basic and additional literature recommended by educational program on the discipline;

- skill to orientate oneself in theories, conceptions and directions of the studied discipline and to give a critical valuation;

- ability to represent graphically (sketchily) basic stages of development of organs and systems of organism, formation of anomalies and deformities; to know basic causes their occurrence;

- independent work at laboratory classes and during self-preparation to classes, active participation in group discussions, absence of violations of deontological and sanitary-hygienic rules of work with anatomical preparations, high level of culture of task execution.

8 points - (4+):

- systematized, deep and full knowledge of all divisions of the educational program; demonstration of organs and structures which have been previously studied in the frames of the theme, details of their structure on preparations, plaster casts, roentgenograms, tomograms;

- usage of scientific Latin and English (Russian) terminology, stylistically competent and logically correct representation of the answer, ability to make one's own conclusions;

- skill of the dissection technique and work with anatomical instruments (tweezers, scalpel); ability to work with negatoscope and to read the roentgenograms, tomograms according to algorithm;

- ability to handle with complex problems in the frames of educational program independently;

- mastering of basic and additional literature recommended by the educational program of the discipline;

- ability to represent graphically (sketchily) basic stages of development of organs and systems of organism, formation of anomalies and deformities; to know basic causes their occurrence;

- independent work at laboratory classes and during self-preparation to classes, active participation in group discussions, absence of violations of deontological and sanitary-hygienic rules of work with anatomical preparations, high level of culture of task execution.

7 points - (4):

- systematized, deep and full knowledge of all divisions of the educational program; demonstration of organs and structures which have been previously studied in the frames of the theme, details of their structure on preparations, plaster casts, roentgenograms, tomograms;

- usage of scientific Latin and English (Russian) terminology, stylistically competent and logically correct representation of the answer, ability to make one's own conclusions;

- skill of the dissection technique and work with anatomical instruments (tweezers, scalpel); ability to work with negatoscope and to read the roentgenograms, tomograms according to algorithm;

- ability to use typical solutions in the frames of educational program independently;

- mastering of basic and additional literature recommended by the educational program on the discipline;

- ability to represent graphically (sketchily) basic stages of development of organs and systems of organism, formation of anomalies and deformities;

- independent work at laboratory classes and during self-preparation to classes, periodic participation in group discussions, absence of violations of deontological and sanitary-hygienic rules of work with anatomical preparations, high level of culture of task execution.

6 points-(4 -):

- sufficient systematized and full knowledge of the educational program; demonstration of organs and structures which have been previously studied in the frames of the theme, details of their structure on preparations, plaster casts, roentgenograms, tomograms;

- knowledge of description of structure of an organ (part of a body) in correspondence with program of text-books, course of lectures;

- usage of scientific Latin and English (Russian) terminology, stylistically competent and logically correct representation of the answer, ability to make one's own conclusions;

- skill of the dissection technique and work with anatomical instruments (tweezers, scalpel); ability to work with negatoscope and to read the roentgenograms, tomograms according to algorithm;

- ability to use typical solutions in the frames of educational program independently;

- mastering of basic literature recommended by the educational program of the discipline;

- ability to represent graphically (sketchily) basic stages of development of organs and systems of organism, formation of anomalies and deformities;

- independent work at laboratory classes and during self-preparation to classes, periodic participation in group discussions, absence of violations of de-



ontological and sanitary-hygienic rules of work with anatomical preparations, high level of culture of task execution.

**5 points - (3+):**

- sufficient knowledge of the educational program;
- knowledge of description of structure of an organ, topography of an organ (part of a body) in correspondence with program of text-books, course of lectures, ability to remember small details of structure by means of directing questions of a teacher;
- usage of scientific Latin and English (Russian) terminology, stylistically competent and logically correct representation of the answer, ability to make one's own generalizations and conclusions by means of directing questions;
- skill of the dissection technique and work with anatomical instruments (tweezers, scalpel); ability to work with negatoscope and to read the roentgenograms, tomograms according to algorithm;
- ability to resolve standard (typical) tasks under the guidance of a teacher;
- ability to use typical solutions if the frames of educational program independently;
- mastering of basic literature recommended by the educational program of the discipline;
- ability to represent graphically (sketchily) basic stages of development of organs and systems of organism, formation of anomalies and deformities;
- independent work at laboratory classes and during self-preparation to classes, rare participation in group discussions, absence of violations of deontological and sanitary-hygienic rules of work with anatomical preparations.

**4 points - (3):**

- sufficient knowledge in correspondence with educational standard;
- knowledge of description of basic details of the structure and topography of an organ (part of a body) in correspondence with program of a text-book;
- usage of scientific Latin and English (Russian) terminology, stylistically competent and logically correct representation of the answer by means of directing questions, failure to make one's own generalizations and conclusions;
- demonstration of organs and structures in the frames of educational program, basic details of their structure on preparations, plaster casts, tables;
- skill of work with anatomical instruments (tweezers, scalpel); ability to work with negatoscope and to recognize the roentgenograms, tomograms according to algorithm with correction of a teacher;
- failure to use standard (typical) solutions in educational tasks by means of directing questions of a teacher ;
- ability to represent graphically (sketchily) basic stages of development of organs and systems of organism, formation of anomalies and deformities with single corrections of a teacher;

- work at laboratory classes under the guidance of a teacher, rare participation in group discussions, permissible level of violations of deontological and sanitary-hygienic rules of work with anatomical preparations.

**3 points- (2):**

- insufficient knowledge of organs in correspondence with educational standard;

-knowledge of description of the structure of an organ (part of a body) in correspondence with program of a text-book;

-failure to represent graphically (sketchily) basic stages of development of organs and systems of organism, formation of anomalies and deformities;

- usage of scientific Latin and English (Russian) terminology with significant linguistic and logical mistakes;

-enumeration of organs in the frames of educational program, recognition on preparations, plaster casts, tablets, failure to place them in correct way, failure to demonstrate knowledge of anatomy on natural preparations and moulages;

-incorrect usage of anatomical instruments (tweezers, scalpel), incompetence in deciding standard ( typical) situational tasks;

-inactivity at laboratory classes;

-inadequate, squeamish attitude to natural anatomical preparations, violation of deontological and sanitary-hygienic rules of the work with anatomical preparations.

**2 points- (2):**

- fragmentary knowledge in correspondence with educational standard, knowledge with low level of understanding;

- enumeration of organs in the frames of educational theme, without recognition on tables, moulages, preparations;

- incorrect usage of anatomical instruments (tweezers, scalpel); failure to decide standard (typical) situational tasks;

- incorrect usage of Latin and English (Russian) terms;

- inactivity at laboratory classes;

- inadequate, squeamish attitude to natural anatomical preparations, violation of deontological and sanitary-hygienic rules of the work with anatomical preparations.

**1 point - (2):**

- absence of knowledge and competence in correspondence with educational standard, distortion of sense of accounting question, failure to decide standard (typical) situational tasks.


**0 points - (2):**

- refusal answer.

**Certify**

Rector of VSMU

professor



### **III. The statute of the rating system**

The statute of the rating system to estimate the knowledge of students (rating-plan) on the department of human anatomy at studying the discipline "Human Anatomy" for specialty 1-79 0101 – General Medicine (Medical Faculty and Faculty of Overseas Students Training)

Rating system of the department is the system of integral estimation of all types of studying activities on academic discipline for students of Medical Faculty and Faculty of Overseas Students Training.

The purpose of student's successes estimation rating system is complex estimating of a student's work quality in the discipline and educational program mastering. Estimation of academic work quality is expressed as a percentage of the maximum possible value of attendance and achievement of a student.

The following types of educational activity are estimated

- **lectures;**
- **laboratory studies;**
- **independent work** (classroom and extra curricular).

Educational process at the Department of Human Anatomy is organized in a modular fashion. The whole educational material is divided into the following structural logic modules (blocks, sections):

I semester

- Anatomy of bones (skeletal system);
- Anatomy of joints (articular system);
- Anatomy of muscles (skeletal muscle system);

Semester credit

II Semester

- Anatomy of internal organs;
- Anatomy of cardiovascular system;
- Anatomy of endocrine glands;
- Introduction to anatomy of central nervous system;

Semester credit

III Semester

- Anatomy of central nervous system;
- Anatomy of peripheral nervous system;
- Anatomy of sense organs and human integument;

Exam

The main forms of control:

- written incoming test control consisting of 5 questions on every laboratory work;
- oral recitation on anatomical specimens during laboratory studies;
- anatomical specimens knowledge control during 8 final classes (colloquiums) on every of 8 modules (3 – in the first semester, 2- in the second semester, 3- in the third semester);
- computer test control before the exam;
- oral examination control of practical skills;
- oral control of knowledge on the exam.

Attendance of lectures and laboratory classes, as well as evaluation of current and final control is recorded in lecture and academic journals.

The assessment of all types of activity is conducted basing on the 10-mark scale according to the approved regulation.

Calculation to estimate the ranking mark of test (in a laboratory class and pre-examination) is cleared basing on a scale approved by the Vice-rector of educational work and international affairs. At the same time positive result is above 70% of correct answers on all types of test controls. The scale of marks for the test controls answers is the following:

- no correct answers - 0,
- less than 20 correct answers - 1,
- 40 and less correct answers - 2,
- 41-69 correct answers - 3,
- 70-74 correct answers - 4,
- 75-79 correct answers - 5,
- 80-84 correct answers - 6,
- 85-89 correct answers - 7,
- 90-94 correct answers - 8,
- 95-99 correct answers - 9,
- 100correct answers - 10.

Under the curriculum during 3 semesters 19 lectures and 73 laboratory classes are provided. According to the plan nine controls are carried out. Calculation of rating is done by multiplying each lecture (lesson) attendance and a class work mark for appropriate coefficient.

The discipline rating consists of 9 components each of which has its own "weight" when calculating.

- I. Current rating
  1. Lectures attendance;
  2. Laboratory class attendance
  3. The total mark for laboratory studies preparation (test control);
  4. The total mark for activity on laboratory class (current marks).
- II. Frontier rating
  1. The total mark for the final classes on all modules;
- III. Final rating
  1. Mark for exam testing;

2. Mark for practical skills in finding anatomical structures on specimen in the examination;

3. Assessment of oral interview in the exam.

#### IV. Creativity rating (T).

The table of work executed coefficients in studying the subject "Human Anatomy" for specialty 1- 79 01 01- General Medicine in Medical Faculty and the Faculty of Overseas Students Training.

Table

№	Types of work	Coefficient	Maximum score for the whole course (3 semester)
1	Lecture attendance	0,06	<b>1,14</b> (19x0,06)
2	Laboratory class attendance	0,06	<b>4,38</b> (73x0,06)
3	Test control (multiplication of a mark with coefficient (MxCQ))	0,01	<b>7,3</b> (73x10x0,01)
4	Final mark for practical skills control (MxCQ)	0,08	<b>25,6</b> (32x10x0,08)
5	Estimations of anatomy preparations knowledge on the final class (colloquium) (MxCQ)	0,4	<b>36,0</b> (9x10x0,4)
<b>Total - 74,42</b>			
(Maximal mark based on the current and intermediate control)			
6	Examination testing (MxCQ)	0,2	2
<b>Total «ideal student» - Total - 76,42</b>			
(Maximal sum of marks based on the current, intermediate and final control)			

A student won't get 0,06 points for the missing class. For disciplinary influence the 1st -2nd courses students who are late for laboratory class or (lecture) will lose some points. In this case the coefficient for attendance will be 0,03 (instead of 0,06).

At working out the missing lectures and laboratory classes a student gets an assessment, which is put onto the appropriate check box of the academic journal and taken into account in rating.

Unsatisfactory marks on modular frontier final classes can be corrected until getting a positive mark. As a student's willing it is possible to correct (by working out) current unsatisfactory (0-3) mark for laboratory class. A mark for test control on laboratory class can't be worked out or corrected.

The creative rating of a student can include the following kinds of activity:

- regularity of independent out-of-class work may give the student up to 1 point (if every week preparation for the specimens) (T1);
- preparation of abstract concerning development and abnormality of body and organs systems, and reading it on the group lesson - 0,5 point (T2);
- making of educational anatomical specimens - 3 points (T3);
- making of a chart A1 - 0,5 points (T4);
- making of a museums anatomical specimens - 10 points ((T5);

- making of a multimedia presentation in PowerPoint which includes not less than 50 slides, 30 images and 5 pages of text basing on a lecture -2 points for each presentation (T6);

- participation in a Students Scientific Society meetings - 0,5 points for each meeting (T7);

- speaking at a Students Scientific Society meetings – 0.5 points per report (T8)

- reporting at the Scientific Society meetings his researching -2 points for each report (T9);

- reporting at the conference with the following publication in the form of abstracts or articles in the collection - 4points for one report or article); (T10);

- participation in the Republican show-contest of students' research papers - 10 points for a paper (T11).

Creativity rating is not compulsory for a student. Its result is added to the rating assessment after the answers in the exam, only if there are no academic frontier and final (examination) control debts.

The discipline rating (P) is calculated as the sum of components taking into account their "weight":  $P = Ax0,06 + (Bx 0,06 - Cx0,03) + Dx0,01 + Ex0,05 + Fx0,3 + Gx0,2 + Hx2,0 + I2,0 + T (T1 + T2 + T3 + T4 + T5 + T6 + T7 + T8 + T9 + T10 + T11)$ .

A - number of attended lectures;

B - number of attended laboratory classes;

C - number of coming late for laboratory classes;

D - sum of marks for laboratory tests;

E - sum of current marks for work on laboratory classes;

F - sum of marks for the final classes (colloquiums on modules);

G - a mark for the exam test;

H - a mark for practical skills in the exam;

I - a mark for oral interview in the exam;

T - rating of creativity.

As a result of the curriculum completing a student can get collect:

I semester -  $P_{max} = 21,9$ points,  $P_{min} = 9,5$  points (there are no missing classes and unsatisfactory marks). If a student has a positive mark (4 and above) in all 3 final control classes and the total rating is  $P \geq 9,5$  he will get credit.

II semester -  $P_{max} = 31$  points,  $P_{min} = 13,6$  points (there are no missing classes and unsatisfactory marks). If a student has a positive mark (4 and above) in all 2 final control classes and the total rating is  $P \geq 13,6$  he will get credit.

III semester -  $P_{max} = 21,5$  points,  $P_{min} = 9,2$  points (there are no missing classes and unsatisfactory marks). If a student has a positive mark (4 and above) in all 3 final control classes and the total rating is  $P \geq 9,2$  he will get credit.

A student can be allowed for the exam if he attended all laboratory classes and lectures and has positive marks (4 and above) in all 8 final control classes, credits in 3 semesters and the total rating of  $P \geq 33$ .

After passing the exam a student gets mark on 10-point system into his credit book depending on the rating in accordance with the following scale:

Rating score	Mark on the 10-point system
75 and above	10
68-74	9
61-67	8
53-60	7
47-52	6
41-46	5
35-40	4

**Total rating** - is the average result of the sum of rating score and marks which a student received at examination for oral interview and practical skills. This mark is set down into the credit book.

$R_{total} = (R_{cre} + P + O) : 3$ .

R to= total rating

R cre= rating score

P sk= practical skills

O is= oral interview

**Exempt from the exam if desired:**

The students who have rating score of 68 points and above. All final classes are delivered on time, the final estimates for all total not less than 7. If the total rating is equal to rating score a student will be given the same mark into the credit book.

#### IV. Multiple-choice questions to pass the first stage of examination

1. The most medial part of the Palatine bone is called:

-Horizontal plate

+ Nasal crest

- Sphenoid bone

- Pyramidal process

-Perpendicular plate

2. In the posterior cranial fossa the following sulcus are distinguished:

- carotid groove

+ groove of inferior petrous sinus

+ groove of transverse sinus

+ groove of sigmoid sinus

- groove of superior sagittal sinus

3. The medial wall of pterygopalatine fossa (*fossa pterygopalatina*) is formed by:

-Pterygoid processes of sphenoid bone

-Tuber of maxilla

-Body of sphenoid bone

-Vertical plate of the palatine bone

+The sphenoidal process of palatine bone

4. What anatomical formation is not the main element of the joints?

- Articular surface

+ Articulate cartilage

- Articular cavity

- Articular capsule

- Articular lip

5. Which anatomical formation is the feature of complex joint?

- Synovial folds
- Articular cartilage
- + Articular disc
- Intra-articular ligament
- Synovial bursae

6. In which of the following areas does cerebrospinal fluid circulate?

- Below the pia
- + Subarachnoid space
- Subdural space
- Epidural space
- Naso lacrimal canal

7. The occipital venous sinus is situated in the basis of the:

- + Falx cerebelli
- Falx cerebri
- Tentorium cerebelli
- Cavernous sinus
- Diaphragma sellae

8. Which of these nerves innervates the deltoid muscle and provides sensory input from the shoulder?

- + axillary nerve
- Ulnar nerve
- Median nerve
- Radial nerve
- musculocutaneous nerve

9. Sensory innervation of the dura mater encephali is provided by:

- Cervical sympathetic trunk
- Cervical plexus
- + Trigeminal nerve
- Glossopharyngeal nerve
- + 10 th cranial nerve

10. At which part of the vertebral column forms kyphosis?

- Cervical
- Lumbar
- +Thoracic
- Coccygeal
- +Sacral

11. Which part of the vertebral column usually forms scoliosis?

- Cervical
- Lumbar
- +Thoracic
- Coccygeal
- Sacral



12. The pyramids are located in the:

- Pons
- + Medulla
- Midbrain
- Thalamus
- Cerebral peduncles

13. Which anatomical formation are (is) related to elbow joint (art. cubiti)?

- + Radial Collateral Ligament
- An articulate lip
- + Quadrate ligament
- + Oblique cord
- + Anular ligament

14. According to the articular surfaces shape, the humeroulnar joint (art. humeroulnaris) is:

- Spherical
- ellipsoid
- plane
- + Hinge
- Saddle

15. Proximal and distal radioulnar Joint joints are:

- Hinge
- Spherical
- + Combined
- + cylindrical
- Complex

16. According to the number of articular surfaces, carpometacarpal joint of the thumb is:

- Spherical
- Ellipsoid
- + Saddle
- Condylloid
- Trochoid

17. According to the shape of their articular surfaces, metacarpophalangeal joints of hand are:

- Spherical joint
- + Ellipsoid joint
- saddle joint
- Condylloid joint
- Trochoid joint

18. According to the shape of their articular surfaces, interphalangeal joints of hand are:

- Spherical joint
- Ellipsoid joint
- saddle joint
- Condylloid joint
- + Hinge joint

19. Which of the following anatomical formation are the boundary line between the greater and the lesser pelvis:

- + Promontorium
- + Arcuate line
- Inferior gluteal line
- Obturator groove
- + Pubic crest

20. The interosseous sacro-iliac ligaments attach to the:

- Iliac crest
- Iliac fossa
- +Iliac tuberosity
- Ischial tuberosity
- anterior gluteal lines

21. Which anatomical formation was generated at the result of fit of vessels and nerve?

- Iliac fossa
- +obturator groove
- Terminal line
- Pubic crest
- Lunat surface

22. The inferior aperture of the pelvis is bounded by:

- + Lig. sacrotuberale
- Lig. sacrospinale
- Discus interpubicus
- + Ramus ossis ischii
- +Lig. arcuatum pubis

23. Which of the following characteristics belong to the ankle joint?

- + It is a synovial joint
- + It is a hinge joint
- + In plantar flexion , additional movements are possible
- consists of three bones: the tibia, the fibula, and the calcaneus
- +Its main ligament are located medially and laterally

24. Which ligament strengthen the longitudinal arch of the foot ?

- Lig. bifurcatum
- + Lig. plantare longum
- Ligg. tarsometatarsea dorsalia
- + Ligg. tarsometatarsea plantaria
- Ligg. collateralia

25. Which definitions is the most correct about the subject of human anatomy?

- It is a science about structure of body
- It is a science about development of human body
- It is a science about the form, structure of an origin and development of human body
- It is a science about the structure and functions of human body
- + It is a science about an origin, macro and a microscopic structure, age, features and functions of human body

26. Which principles of studying of human body are used in modern anatomy?

- Principle of unity of theory and practice
- + Principle of integrity of an organism
- + Principle of conformity of structure and function
- + Principle of unity of an organism and environment
- principle of conformity of structure and an arrangement

27. Which parasympathetic ganglia are situated near the III branches of trigeminal nerve?

- Ciliary
- Pterygopalatine
- Lacrimal
- +Otic
- +Submandibular

28. What type of joint affords triaxial movement?

- Hinge
- + Ball and socket
- Saddle
- Condylloid
- Pivot

29. Which of the following functions are the functions of bones of the skeleton?

- + Supporting
- + Movement
- + Protection
- + Exchange of mineral substances
- + Blood formation

30. Which of these statements concerning the bone development is correct?

- Intramembranous ossification - always long bones
- + Intramembranous ossification -always flat bones
- +Ossification is the term for the formation of bone
- + The development of bones also called osteogenesis
- + The direct conversion of mesenchymal tissue into bone is called intramembranous ossification.

31. Middle meningeal artery is transmitted through:

- Foramen rotundum
- Foramen ovale
- + Foramen spinosum
- Foramen lacerum
- Foramen magnum:

32. The aortic opening (aortic hiatus) in the human diaphragm transmits:

- + aorta
- + thoracic duct
- vagus nerves
- + azygos vein
- vena cava inferior

33. Which of these statements concerning the great cerebral vein is correct:
- + is one of the large blood vessels in the skull draining the cerebrum (brain).
  - also called jugular vein
  - is one of the large blood vessels draining the leg
  - + It is also known as the "vein of Galen"
  - + formed by the two internal cerebral veins and continuing into the sinus rectus
34. Left testicular vein drain into:
- Inferior mesenteric vein
  - Inferior vena cava
  - right renal vein
  - Common iliac vein
  - + Left renal vein
35. The sternal angle is found at:
- Jugular notch
  - Xiphoid process
  - Level with the 4th costal cartilage
  - Level with the lower border of the 6th thoracic vertebra
  - + Manubriosternal joint
36. Which of the following defines true rib?
- + Upper 7 pairs
  - All 12 pairs
  - Lower 5 pairs
  - 10th and 11th pairs
  - 12th pair
37. Which of the following is synovial joint?
- Symphysis
  - + Pivot
  - + Gliding
  - + Ball and socket
  - + Condylloid
38. Superior petrosal sinus
- Receives blood from the middle superficial cerebral vein;
  - Lies in the attached border of the cerebellar falx;
  - + Drains into the transverse sinus;
  - Runs in the free edge of the cerebral falx;
  - Drains into the internal jugular vein;
39. The mediastinum contains all the following structures:
- + Heart
  - Lungs
  - + Pulmonary arteries
  - + Trachea
  - + Esophagus
40. Nerve fiber of ganglion ciliare innervate the following structures.
- + Musculus ciliaris.
  - Musculus dilatator pupillae
  - Glandula lacrimalis
  - + Musculus sphincter pupillae.
  - Musculus latissimus dorsi

41. Anterior cruciate ligament prevents:

- Post. dislocation of femur
- Post. dislocation of patella
- + Ant. dislocation of tibia
- Ant. dislocation of femur
- Post dislocation of tibia

42. Ossification of the parts of the body of the sternum usually is complete in the age:

- 1
- 3
- 6
- 15
- + 21

43. The superficial external pudendal artery is a branch of

- Testicular artery
- + Femoral artery
- External iliac artery
- Internal iliac artery
- Aorta

44. Which of these statements correctly describe intercostal muscles?

- External intercostals begin anteriorly
- External intercostal membrane is posterior
- Fibers of external intercostals slant upward and backward
- Fibers of internal intercostals run upward and forward
- + Innermost intercostals are the best developed of the intercostals

45. Which of these is an angular movement?

- + Flexion
- + Abduction
- Rotation
- + Hyperextension
- + Extension

46. Which of the following statements is correct regarding the blood vessels of the thoracic wall?

- In the intercostal space, the vessels run just below the respective intercostal nerve
- Branches of the vessels vary widely from those of the intercostal nerves
- + Superficial structures of the thorax are served by intercostal vessels
- Posterior intercostal arteries are branches of the internal thoracic artery
- Branches of the descending thoracic aorta become anterior intercostal arteries

47. All the following statements concerning the internal thoracic artery are correct, EXCEPT:

- + It is a branch of the arch of the aorta
- It descends behind the subclavian vein
- It divides into two terminal branches
- It gives branches to the mediastinum
- The musculophrenic artery is one of its terminal branches

48. Produce the fluid that keeps most joints moist

- Bursae
- Articular discs
- Articular cartilages
- + Synovial membrane
- Bone

49. Which of the following is an example of a hinge joint?

- + Elbow
- + Knee
- + Interphalangeal
- + Tibia/talus
- Shoulder

50. Which formation are located internally to the capsula of the knee joint (cavity art. Genus)?

- + Lig. Trasversum genus
- + Meniscus medialis
- + Plicae alares
- + Lig. Cruciatum anterius
- + Lig. Cruciatum posterius

51. The following muscles have no attachment to scapula:

- + Pectoralis major
- + Brahialis
- Biceps brachii
- Triceps
- + Temporalis

52. The opening of inferior vena cava in the diaphragm is at the level of:

- T6
- + T8
- T10
- T12
- L5

53. The opening in the diaphragm is(are) :

- + Aortic
- + Vena caval
- + Oesophageal
- Trahial
- Ingunal

54. Radial bursa encloses the tendon of:

- + Flexor pollicis longus
- Flexor carpi radilais
- Flexor tendons of medial 4 digits
- Flexor carpi ulnaris
- Flexor carpi ulnaris and Flexor carpi radilais

55. The triceps brachii muscle:

- Flexes the arm
- + Extends the arm
- Abducts the arm
- Rotates the wrist
- Flexes the forearm

56. Lateral boundary of cubital fossa is formed by:

- + Brachioradialis
- Pronator teres
- Brachialis
- Biceps
- Coracobrachialis

57. The following structures are attached to the greater tubercle of humerus:

- + Supraspinatus
- + Infraspinatus
- Subscapularis
- + Teres minor
- Pronator teres

58. The femoral ring is bound by the following structures:

- + Femoral vein
- + Lacunar ligament
- + Superior ramus of pubis
- Femoral artery
- + Inguinal ligament

59. Sartorius muscle originates from:

- Pectinate line
- + Anterior superior iliac spine
- Ischial tuberosity
- Pubis symphysis
- 1-5 costal ribs

60. In lower quarter of abdominal wall, aponeurosis of the internal oblique muscle does not split, and all three aponeurotic layers pass anterior to the rectus abdominis.

This area is called:

- Falx inguinalis
- + Arcuate line
- Linea semilunaris
- Linea alba
- Linea trochanterica

61. The ligamentum arteriosum is located between the:

- + Left pulmonary artery and the aortic arch
- Pulmonary trunk and the right pulmonary artery
- Left pulmonary vein and the aorta
- Right pulmonary vein and the pulmonary trunk
- Left bronchial artery and the aortic arch

62. All the following statements concerning pulmonary veins are correct, EXCEPT:

- Two veins pass from the hilum of each lung
- + Usually they enter the right atrium of the heart
- They show more variation than do the pulmonary arteries
- They are formed by confluence of capillaries in the lung
- Their primary tributaries are related to particular bronchopulmonary segments

63. The following statements characterize the structure of the scapula:

- A thickened medial border adjacent to the coracoid
- + A subscapular fossa on its costal surface
- + A spine continuing into the acromion
- + Three angles and three borders
- + The glenoid cavity at its lateral angle

64. Which of these statements concerning the pericardial sac are correct?

- + Has two layers, a serous layer and a fibrous layer.
- + Is a double-walled sac containing the heart and the roots of the great vessels.
- + The pericardial sac and its content comprise the middle mediastinum
- Is a double-walled sac containing the lung
- + The pericardial sac is fused to the central tendon of the diaphragm

65. Which of these statements correctly describes the heart?

- All the great veins enter its apex
- + Its base is made largely of the left atrium and a portion of the right atrium
- The apex points forward and toward the right
- The diaphragmatic surface is formed largely by the right ventricle and atrium
- The coronary sinus occupies the posterior interventricular sulcus

66. The right atrium includes all these structures, EXCEPT:

- Tricuspid valve
- Crista terminalis
- Musculi pectinati
- Fossa ovalis
- + Trabeculae carneae

67. Which of these statements correctly describes the azygos venous system?

- + Primarily, it drains blood from the body wall
- Normally, it drains into the inferior vena cava
- + It is located entirely on the right side of the vertebral column
- Normally, there are two in number
- + It is formed by the union of the ascending lumbar veins with the right subcostal veins .

68. Which of these statements correctly describes the thoracic duct?

- + It returns lymph from the greater part of the body to the venous system
- + The vessel usually starts from the level of the second lumbar vertebra
- It ends at the confluence of the right subclavian and brachiocephalic veins
- In adults, the thoracic duct is typically 10-15cm
- + It is also known as the left lymphatic duct



69. Characteristics of thoracic vertebrae include all the following, EXCEPT:

- Long vertical spinous processes of T5, T6, T7
- + A transverse foramen in each vertebra
- A small circular vertebral foramen
- Progressively shorter transverse processes from T10- T12
- Thoracic articular processes set on an arc to permit rotation

70. Ribs may be described correctly by all the following, EXCEPT:

- Every rib articulates with the vertebral column
- The upper 7 pairs of ribs are called vertebrostermal
- Ribs 8, 9, and 10 are called vertebrochondral ribs
- Floating ribs are the last 2 pairs
- + Ribs 1 through 12 are called true ribs
- + Ribs 1 through 12 are called true ribs

71. Which of these statements concerning ribs are correct?

Attach in the posterior to a thoracic vertebra.

The first 7 pairs are also called true ribs.

Ribs and cartilages increase in length progressively from 1st to 7th rib  
the last two (eleventh and twelfth ribs) are termed floating ribs

The costal groove runs along the outer surface of the body

72. Which of these statements concerning intercostal arteries are correct,

There are eleven posterior intercostal arteries on each side.

- +The lower 9 posterior intercostal arteries arise from the aorta
- +The anterior intercostal branches from internal thoracic artery
- + Intercostal arteries run under the shelter of a costal groove
- +Intercostal arteries may accompany each intercostal nerve

73. Which of the following structures is NOT located in the mediastinum?

- Heart and pericardium
- Trachea
- Vessels proceeding to and from the heart
- + Lungs
- Vagus nerves

74. All the following are parts of the parietal pleura, EXCEPT:

- Costal
- Mediastinal
- Diaphragmatic
- + Pulmonary
- Cervical

75. Which of the following bone participate to form the radiocarpal joint?

- + The radius
- + Os scaphoideum
- + Lunatum
- + Triquetrum
- Ulnar

76. Each segmental bronchus together with the portion of lung it supplies is called:

- Primary segment
- + Bronchopulmonary segment
- Lobar segment
- Epiarterial segment
- Alveolar segment

77. The pulsation of this artery can be palpated in front of the tragus:

- Occipital
- Posterior auricular
- Facial
- Lingual artery
- + Superficial temporal.

78. The tracheal bifurcation can be seen at the level:

- + T4-T5 in the supine living subject
- T8 in the erect subject
- T6 during inspiration
- T12 during expiration
- T2-T3 in the supine cadaver

79. The following structures enter into the right atrium of the heart :

- + Coronary sinus
- + Inferior vena cava
- + Superior vena cava
- + Anterior cardiac veins
- Pulmonary veins

80. Which of these statements concerning the articulations of the ribs with the vertebral column are correct?

- + Costovertebral articulations consist of synovial joints
- + The head of the rib articulates with vertebral body
- + An articular capsule surrounds the joint
- + The tubercle of a rib articulates with the tip of a transverse process
- The costovertebral joints are the articulations that connect the heads of the ribs with the bodies of the cervical vertebrae

81. Which of the following nucleus are cranial parts of parasympathetic nervous system:

- Intermediolateralis
- Nucleus pontinus.
- + Nucleus accessorius
- + Nucleus dorsalis nervi vagi
- Nucleus ambiguus

82. What nerve is mixed branch of cervical plexus?

- + Phrenic nerve
- Lesser occipital nerve
- Great auricular nerve
- Supraclavicular nerves
- vagus nerves

83. Which of the following statements is true of the trachea?

- It descends behind the esophagus
- Its posterior surface is convex
- + It ends at the level of the sternal angle
- During inspiration, its bifurcation ascends
- It contains O-shaped bars of cartilage

84. The superior vena cava returns blood from these structures:

- + Head
- + Neck
- + Upper limb
- Lungs
- Lower limb

85. All the following statements correctly describe the brachiocephalic veins, EXCEPT:

- Each is formed by the union of the internal jugular and the subclavian veins
- + They contain valves to prevent backflow of blood
- They unite to form the superior vena cava
- Each vein receives the internal thoracic vein
- They arise posterior to the medial ends of the clavicle

86. All these structures occupy the superior mediastinum:

- Heart and pericardium
- + Aortic arch
- + Trachea
- + Esophagus
- + Brachiocephalic ven

87. Which of the following statements regarding the coronary arteries is correct?

- Sharp lines of demarcation exist between their distribution to right and left ventricles
- Most of the blood in these arteries returns to the left atrium
- + They arise from the right and left aortic sinuses
- Variations of these arteries are uncommon
- They are infrequent sites of arteriosclerosis

88 Which of these statements concerning Sinoatrial node are correct,

- Its tissue located in the left atrium of the heart
- Its tissue located in the left ventricle of the heart
- +Innervated by vagus nerve
- +Also called the impulse-generating (pacemaker)
- +Also called the sinus node

89. All the following statements concerning the left ventricle are correct, EXCEPT:

- Its wall is much thicker than that of the right ventricle
- Its interior is covered by trabeculae carneae
- The chordae tendineae of papillary muscles are distributed to cusps of the atrioventricular valve
- + It forms the base of the heart
- The aorta arises from its anterior uppermost part

90. Characteristics of the left atrium consist of all the following ,EXCEPT:

- It forms most of the base of the heart
- It contains a few muscoli pectinati
- + It receives the pulmonary arteries
- Much of this atrium lies posterior to the right atrium
- The auricle overlaps the root of the pulmonary trunk

91. What is characteristic of the right ventricle?

- + It gives origin to the pulmonary trunk
- Usually it has only two papillary muscles
- It receives blood through the mitral valve
- It has internal muscular ridges, the *musculi pectinati*
- It contains the fossa ovalis

92. Which of the following statements correctly describes chambers of the heart?

- The coronary sulcus separates the two ventricles
- The right ventricle forms the right border of the heart
- The valve of the superior vena cava directs blood downward

+ The superior vena cava opens into the right atrium

- The interventricular septum contains the fossa ovalis

93. The heart may correctly be described by all the following, EXCEPT

- An apex formed by the tip of the left ventricle
- A diaphragmatic surface formed by both ventricles
- A base formed by the atria
- A location in the middle mediastinum

+ An anterior surface formed mainly by the left atrium

94. The epicardium receives its arterial blood supply from the following arteries:

- Pericardiophrenic
- + Coronary arteries
- Musculophrenic
- Superior phrenic
- Bronchial

95. Which of these statements concerning the fibrous pericardium is true?

- It has no close relationship with the central tendon of the diaphragm
- + It extends upward to the level of the sternal angle
- It moves freely within the thoracic cavity
- Its base is pierced by the aorta
- It has no attachment to the sternum

96. Which of these statements correctly describe lymphatic drainage of the lungs?

- Usually both bronchomediastinal lymph trunks terminate in the thoracic duct
- Only one lymphatic plexus is involved in this drainage
- Little transfer of lymph drainage from side to side occurs
- + No lymph vessels are located in the walls of the pulmonary alveoli
- Rarely is this lymph drainage responsible for transfer of cancer cells to other organs

97. Which artery is the first branch of the celiac trunk:

- + Gastroduodenal
- Left gastroepiploic
- Right gastric
- Inferior pancreaticoduodenal
- Superior pancreaticoduodenal

98. Characteristics of the left lung include:

- It is heavier than the right lung
- It is composed of three lobes
- The azygos vein arches over its root
- It has a horizontal fissure
- + The cardiac notch is found

99. The central part of the parietal diaphragmatic pleura is supplied by nerves:

- Intercostals
- Vagus
- + Phrenic
- Sympathetics
- Parasympathetics

100. The maculae can be found in the

- Cochlear duct
- + saccule
- semicircular canals
- semicircular ducts
- + Utricle

101. Calyx majori is present in?

- Pancreas
- + Kidney
- Salivary gland
- Intestine
- pleura

102. Indicate biliary ducts, forming common bile duct.

- + Cystic duct;
- Right hepatic duct;
- Left hepatic duct;
- + Common hepatic duct.
- Ductus pancreaticus

103. Point out part of duodenum, where pancreatic duct opens.

- Superior part;
- + Descending part;
- Ascending part;
- Horizontal part.
- Bulbus duodeni

104. Which paranasal sinuses communicate with the middle nasal meatus?

- + Frontal sinus;
- + Maxillary sinus;
- Sphenoidal sinus;
- + Middle cellulae of ethmoid bone.
- Posterior cellulae of ethmoid bone.

105. Denote anatomical formations, residing behind the trachea.

- + Esophagus;
- + Vagus nerve;
- Aortic arch;
- Thymus.
- + Truncus sympaticus

106. What is true about the parotid duct:

- Joins the submandibular duct
- + Opens at the level of the upper second molar tooth
- + (it pierces the buccinators muscle and passes on the surface of masseter)
- + Is lined by tall columnar epithelium
- + Opens at vestibulum cavitas oris.

107. What structure regulates the amount of light passing to the visual receptors of the eye?
- cornea
  - pupil
  - + iris.
  - ciliary body
  - lens
108. Portocaval anastomosis is seen between:
- + In the rectum-superior rectal vein and inferior rectal vein
  - At the umbilicus-portal vein and accessory hemiazygos vein
  - At the oesophagus-left gastric vein and paraumbilical vein
  - At the liver-portal vein and renal azygos vein
  - + At the umbilicus-paraumbilical vein and inferior epigastric vein
109. The right gastroepiploic artery is a branch of the:
- Left gastric
  - Splenic
  - Celiac trunk
  - + Gastroduodenal
  - Superior mesenteric
110. Denote anatomical formations, composing the renal crus.
- Renal pelvis;
  - + Renal vein;
  - + Lymphatic vessels;
  - Capsule of kidney.
  - + Ureter
111. The Adam's apple is a common term for the
- Pharynx
  - Epiglottis
  - Cricoid cartilage
  - + Thyroid cartilage
  - No answer
112. Which of the below structures are the smallest in diameter ?
- 1. Left primary bronchus
  - 2. Bronchioles
  - 3. Secondary bronchi
  - +4. Alveolar ducts
  - 5. Trachea
113. The parasympathetic ganglia of the head are (is)
- + Pterygopalatinum.
  - + Oticum.
  - + Ciliare
  - geniculatum
  - Gaseri
114. What substances ensure elasticity of bones?
- Salts of phosphorous;
  - Salts of magnesium;
  - + Ossein;
  - Salts of calcium;
  - Salts of calium;

115. Point out anatomical formations, characteristic for cervical vertebrae.
- + Foramen in transverse process;
  - + Bifurcated spinous process;
  - + Anterior and posterior tubercles on transverse processes;
  - Mastoid process;
  - Mammillary process;
116. Choose the nerve that carries sensory impulses.
- Oculomotor
  - + Trigemina
  - + Facial
  - + Vagus
  - Abducens
117. What thoracic vertebrae have complete costal facets on their bodies?
- + 1st;
  - 2nd;
  - 10th;
  - + 11th
  - + 12th;
118. Destruction of which cranial nerve would result in the inability to smile?
- X.
  - V
  - + VII
  - VI;
  - IX
119. Where a sulcus of subclavian artery is located on the first rib?
- + Behind tubercle of anterior scalene muscle;
  - In front of tubercle of anterior scalene muscle;
  - On tubercle of anterior scalene muscle;
  - In front of tubercle of rib.
  - On the lower border
120. Where the sulcus of rib is located?
- On internal surface;
  - Along superior margin;
  - On external surface;
  - Along inferior margin;
  - + Along inferior margin of internal surface;
121. Where glenoid cavity of scapula is located?
- On acromion;
  - On superior angle of scapula;
  - On coracoid process;
  - + On lateral angle of scapula;
  - On inferior angle of scapula;
122. What bones form the girdle of the upper limb (shoulder girdle)?
- Sternum;
  - + Clavicle;
  - + Scapula;
  - first rib;
  - Humerus;

123. The light reflex center is located in the

- Medulla
- Pons
- Mamillary region
- + Pretectal region
- Diencephalon

124. What protuberances are distinguished on the surfaces of clavicle?

- Lesser tubercle;
- + Trapezoid line;
- + Conoid tubercle;
- Coronoid tubercle;
- Occipital protuberance;

125. What anatomical formations are located on the proximal end of humerus?

- +1. Anatomical neck;
- 1. Sulcus of ulnar nerve;
- +1. Head;
- 1. Lateral epicondyle;
- 1. Sulcus of radial nerve;

126. What anatomical formations are located on the distal end of humerus?

- + Coronoid fossa;
- Lesser tubercle;
- + Capitulum;
- Intertubercular sulcus;
- Deltoid tuberosity;

127. Sulcus of radial nerve on the humerus is located:

- Near tuberculum minus;
- Near tuberculum majus;
- Above deltoid tuberosity;
- + On posterior surface;
- On medial surface;

128. Near which epicondyle of humerus sulcus of ulnar nerve is located?

- In front of medial epicondyle;
- In front of lateral epicondyle;
- + Behind medial epicondyle;
- Behind lateral epicondyle;
- Above lateral epicondyle;

129. What anatomical formations are located on the proximal end of ulna?

- Head;
- + Olecranon;
- + Trochlear notch;
- + Coronoid process;
- Neck;

130. What anatomical formations are located on the distal end of radius?

- + Ulnar notch;
- Head;
- Neck;
- + Styloid process;
- Trochlea;



131. What bones reside in a proximal row of the wrist?

- Capitate;
- + Scaphoid;
- + Lunate;
- + Triquetrum;
- ‡ Pisiform;

132. The following structures pass through the greater sciatic foramen except?

- The superior gluteal artery;
- The sciatic nerve ;
- + The obturator internus tendon;
- The pudendal nerve;
- The inferior gluteal vein ;

133. Point out the smallest dimensions of a female pelvis:

- Oblique diameter;
- Transverse diameter;
- + Direct measure of outlet of small pelvis;
- Transverse measure of outlet of small pelvis;
- Interspinous measure;

134. Point out anatomical specificities of a female pelvis:

- Superior pelvis plane forms with horizontal plane an angle of 50-55 degree;
- Pronounced promontory;
- Intertubercular angle is 70-75 degree;
- + Intertubercular angle is more than 90 degree;
- + Superior pelvis plane forms with horizontal plane an angle of 55-60 degree;

135. What dimension of small pelvis is called true or gynecological conjugate?

- + Distance between promontory and the most prominent point of symphysis;
- Distance between promontory and the inferior margin of symphysis;
- Distance between promontory and the superior margin of symphysis;
- Distance between apex of sacrum and the inferior margin of symphysis.
- Distance between anterior superior iliac spines;

136. What anatomical formations are located on the proximal end of femur?

- Lateral epicondyle;
- + Head;
- Medial epicondyle;
- Intercondylar fossa;
- + Greater trochanter;

137. What anatomical formations are located on the distal end of femur?

- Intertrochanteric crest;
- + Medial epicondyle;
- Head;
- + Popliteal surface;
- + Intercondylar fossa;

138. What anatomical formations are located on the proximal end of tibia?

- + Medial condyle;
- + Lateral condyle;
- + Intercondylar area;
- + Intercondylar eminence;
- Head;

139. What anatomical formations are located on the distal end of tibia?

- Tuberosity of tibia;
- + Medial malleolus;
- Lateral malleolus;
- + Fibular notch;
- Head;

140. What bones of tarsus form its distal row?

- + Medial cuneiform bone;
- + Navicular bone;
- + Lateral cuneiform bone;
- + Cuboid bone;
- Talus;

141. Axon of nucleus salivatorius superior innervates.

- + Glandula lacrimalis.
- Glandula parotis
- + Glandula submandibularis.
- Adrenal gland
- + Sublingualis

142. Name parts of calcaneus.

- Head;
- Medial malleolar surface;
- + Cuboid articular surface;
- + Sulcus of tendon of long peroneal (fibular) muscle;
- + Sustentaculum of talus;

143. Specify the anatomical structures, which belong to the central part of the vegetative nervous system

- + Columna intermediolaterali;
- + Nucleus accessories of III cranial nerve
- + Nuclei parasymphatici sacrales
- + Nucleus salivatorius superior;
- Trigeminal gangli;

144. Name bones of cranium, having a pneumatic cavity.

- + Sphenoid bone;
- Occipital bone;
- + Ethmoid bone;
- Palatine bone;
- + Temporal bone;

145. Name parts of frontal bone.

- + Squama;
- Body;
- + Orbital part;
- + Ethmoid notch;
- + Nasal part;

146. Name parts of occipital bone.

- + Basilar part;
- Body;
- + Hypoglossal canal;
- + Sulcus of transverse sinus;
- + Squama;

147. What anatomical formations are located on the posterior surface of the pyramid of temporal bone?

- + Subarcuate fossa;
- Foramen of tympanic canaliculus;
- External carotid foramen;
- Foramen of musculotubal canal;
- Trigeminal impression;

148. What canals pass through the pyramid of temporal bone?

- Optic canal;
- + Facial canal;
- Condylar canal;
- + Mastoid canaliculus;
- + Carotid canal;

149. Point out inlet and outlet openings of tympanic canaliculus.

- + Hiatus of canal of lesser petrosal nerve;
- Tympanomastoid fissure;
- Petrotympanic fissure;
- + Bottom of fossula petrosa;
- Tip of pyramid of temporal bone;

150. The stapes sends its vibrations to the:

- incus;
- tympanic membrane;
- + oval window;
- round window;
- Tympanomastoid fissure;

151. What fontanel of cranium closes on the second year of life?

- Posterior (occipital) fontanel;
- Sphenoid fontanel;
- + Anterior (frontal) fontanel;
- Mastoid fontanel;
- Occipital fontanel;

152. Name parts of ethmoid bone.

- + Perpendicular lamina;
- Horizontal lamina;
- + Ethmoid labyrinthus;
- + Cribriform lamina;
- + Orbital lamina;

153. Name conchae, being processes of ethmoid bone.

- + Supreme concha;
- + Superior concha;
- + Medial concha;
- Inferior concha;
- Posterior concha;

154. Name processes of maxilla.

- + Palatine process;
- + Zygomatic process;
- Temporal process;
- + Frontal process;
- + Alveolar process;

155. What anatomical formations are located on a nasal surface of maxilla?

- + Conchal crest;
- Canine fossa;
- + Lacrimal sulcus;
- + Maxillary hiatus;
- Palatine grooves;

156. Name processes of palatine bone.

- Palatine process;
- + Orbital process;
- + Sphenoid process;
- Maxillar process;
- + Pyramidal process;

157. What anatomical formations are located on ramus of mandible?

- Articular tubercle;
- + Coronoid process;
- + Condylar process;
- Articular fossa;
- + Mylohyoid line;

158. Name anatomical formations of anterior cranial fossa.

- + Cribriform lamina;
- + Foramen cecum;
- Laceral foramen;
- Fossa of lacrimal sac;
- Optic canal;

159. Denote openings in medial cranial fossa.

- + Spinous foramen;
- + Superior orbital fissure;
- Internal acoustic meatus;
- + Oval foramen;
- Inferior orbital fissure;

160. Name openings in posterior cranial fossa.

- Spinos foramen;
- + Jugular foramen;
- Optic canal;
- + Hypoglossal canal;
- + Foramen magnum

161. Which bones form pterygopalatine fossa?

- + Palatine bone;
- + Sphenoid bone;
- Zygomatic bone;
- + Maxilla;
- Temporal bone;

162. Foramen rotundum opens to:

- Nasal cavity;
- + Medial cranial fossa;
- + Pterygopalatine fossa;
- Orbit;
- Posterior cranial fossa;

163. In what cavity of cranium does pterygoid canal open?

- Infratemporal fossa;
- Medial cranial fossa;
- Oral cavity;
- + Pterygopalatine fossa.
- Orbit;

164. Which opening connects pterygopalatine fossa with orbit?

- + Inferior orbital fissure;
- Superior orbital fissure;
- Pterygomaxillary fissure;
- Sphenopalatine foramen;
- Pterygoid canal;

165. Which opening connects pterygopalatine fossa with nasal cavity?

- Oval foramen;
- + Sphenopalatine foramen;
- Pterygoid canal;
- Pterygomaxillary fissure;
- Inferior orbital fissure;

166. What bones form the inferior wall of the orbit?

- + Maxilla;
- Sphenoidal bone;
- + Palatine bone;
- + Zygomatic bone;
- Lacrimal bone;

167. Which bones form the medial wall of the orbit?

- + Sphenoid bone;
- + Ethmoid bone;
- + Lacrimal bone;
- + Maxilla;
- + Frontal bone;

168. Name openings in walls of the orbit.

- + Posterior ethmoidal foramen;
- + Optic canal;
- + Nasolacrimal canal;
- Pterygoid canal;
- + Anterior ethmoidal foramen;

169. What bones form the osseal (bony) nasal septum?

- Nasal bone;
- + Vomer;
- Lacrimal bone;
- + Ethmoid bone;
- Maxilla;

170. Which of the following cranial nerves innervate the Stapedius muscle?

- Trigeminal nerve (V)
- + Facial nerve (VII)
- Vagus nerve (X)
- Vestibulocochlear nerve (VIII)
- Glossopharyngeal nerve (IX)

171. Which of the following structure open into the medial nasal meatus?

- + Semilunar hiatus;
- + Anterior cells of ethmoid bone;
- Nasolacrimal canal;
- Sphenoidal sinus;
- + Middle cells of ethmoid bone;

172. What bones form the hard (osseal) palate?

- + Palatine bone;
- Ethmoid bone;
- + Maxilla;
- Sphenoid bone;
- Lacrimal bone;

173. What bones form the lateral wall of nasal cavity?

- + Lacrimal bone;
- + Ethmoid bone;
- + Sphenoidal bone;
- + Maxilla;
- Frontal bone

174. A patient who have difficulty in speaking, swallowing, and protruding the tongue have a lesion of

- Accessory nerve
- Glossopharyngeal nerve
- Facial nerve
- Vagus
- + Hypoglossal nerve

175. The following belongs to synarthros joint:

- + Sutures;
- + Gmphosis;
- Symphyses;
- shoulder joint
- Synovial

176. Denote fibrous junctions.

- + Sutures;
- + Gomphosis;
- Symphyses;
- + Membranes;
- + Fontanelles;

177. Denote cartilaginous junctions.

- Junction of pelvic bone with sacrum;
- Junction of spine with skull;
- + Junction of two lower true ribs with sternum;
- + Junction of bodies of vertebrae;
- + Junction of two lower ribs with spine;

178. What anatomical structures synovial joint has?

- + Joint cavity;
- + Articular lip;
- + Articular cartilage;
- + Synovial fluid;
- Sesamoid bones

179. What joints (in shape) relate to 1-axial?

- Sellar joint;
- + Pivot joint;
- Ellipsoid joint;
- + Hinge joint;
- Condyloid joint;

180. What joints (in shape) relate to 2-axial?

- + Condylar joint;
- Plane joint;
- Spherical joint;
- Trochoginglymus;
- + Sellar joint;

181. What is the shape of temporomandibular joint?

- Hinge;
- Spherical;
- + Ellipsoid;
- Plane;
- Sellar joint;

182. What ligaments join the arches of vertebrae?

- + Ligamenta flava;
- Tectorial membrane;
- Posterior longitudinal ligament;
- Nuchal ligament;
- Anterior longitudinal ligament;

183. What is the shape of median atlanto-axial joint?

- Hinge;
- + Pivot;
- Spherical;
- Plane;
- Saddle joint;

184. The following bones are connected through membranes, between

- + Tibia and fibula
- Tarsus and metatarsus
- + Ulnar and radial
- + Iliac and pubic
- + Occipital and atlant

185. What movements are possible in median atlanto-axial joint?

- Flexion and extension;
- Abduction of head;
- Adduction of head;
- + Rotation;
- Circumduction;

186. What type of junctions articulations of 2-7 ribs with sternum belongs to?

- Fibrous;
- Hemiarthroses;
- + Discontinuous;
- Cartilaginous;
- Synostoses

187. Knee joint belongs to

- + Compound joints;
- Combined joints;
- Simple joints;
- + Complex joints;
- There is no this type of joint

188. What joints of upper limb are 1-axial?

- Shoulder joint;
- + Proximal radio-ulnar joint;
- Humero-ulnar joint;
- + Interphalangeal joints of hand;
- + Distal radio-ulnar joint;

189. Which of the following ligaments attach to the anterior wall of the vertebral canal?

- ligamentum flavum;
- ligamentum nuchae;
- anterior longitudinal ligament.
- cruciate ligaments.
- + posterior longitudinal ligament.;

190. Denote joints, having intra-articular disk.

- + Sternoclavicular joint;
- Sacroiliac joint;
- + Radiocarpal joint;
- Talocalcaneal joint;
- + Intervertebral joints;

191. Denote anatomical formations, restricting abduction of upper limb in shoulder joint.

- Deltoid muscle;
- Subscapular muscle;
- Coraco-humeral ligament;
- + Coraco-acromial ligament;
- Tendon of long head of biceps brachii;

192. Denote muscles antagonists of the orbicularis oris.

- Procerus;
- + Depressor anguli oris;
- + Greater zygomaticus;
- + Risorius;
- + Levator labii superioris



193. Denote muscules, forming transverse folds on the forehead (the expression of surprise).

- Procerus;
- Orbicularis oculi;
- Corrugator supercilii;
- + Occipitofrontalis;

- Risorius

194. Name muscles simultaneously moving the angle of the mouth outwards and upwards.

- Levator labii superioris;

+ Greater zygomaticuc;

+ Levator anguli oris;

- Rizorius;

- Buccinator

195. Denote muscles, protracting mandible.

- Masseter;

- Temporalis;

+ Medial pterygoid;

+ Lateral pterygoid;

- Risorius

196. On what bones the masseter originates?

- Pterygoid process;

+ Zygomatic process of maxilla;

+ Zygomatic arch;

- Alveolar arch of maxilla;

- Corpus of sphenoid bone

197. Denote muscles, abducting the upper extremity above horizontal plane.

- Teres major;

+ Serratus anterior;

- Subscapularis;

- Trapexius;

- Deltoid

198. Denote anatomical formations sites for attachment of the lateral pterygoid muscle.

- Inner surface of angle of mandible;

+ Articular disk of temporomandibular joint;

- Lingula of mandible;

+ Neck of mandible;

- Branch of mandible

199. Denote muscles, contiguonis with deltoid.

- Subscapularis;

+ Supraspinatus;

+ Pectoralis major;

- Sternocleidomastoid;

+ Brahialis

200. What is the function of the supraspinatus?

- + Abducts arm;
- Rotates arm outwards;
- Adducts arm;
- + Pulls the capsule of shoulder joint.
- Rotates arm inwards

201. These muscles are attached to the medial two thirds of the clavicle:

- + Sternomastoid.;
- Deltoid;
- + Pectoralis major;
- + Subclavius.
- + Sternohyoid

202. On what bones the biceps brachii originates?

- Acromion;
- +Supraglenoid tubercle of scapula;
- + Coracoid process of scapula;
- Infraglenoid tubercle of scapula;
- Body of humerus

203. Which one of the following structures allows CSF to pass from the subarachnoid space to the dural sinus?

- inter-vertebral foramina
- choroid plexuses;
- corpus callosum
- + arachnoid villi
- spinal central canal

204. The following muscle attaches to the medial border of the scapula:

- + Levator scapulae.;
- Teres minor;
- + Serratus anterior.
- + Rhombideus minor.
- + Rhomboideus major.

205. Which of the following structures help to define the pelvic brim?

- the pubic symphysis;
- + the arcuate line;
- the acetabulum;
- the greater sciatic notch;
- the lesser sciatic notch

206. Denote anatomical structures, passing through the adductor canal.

- + Femoral artery;
- Obturator nerve:
- Radial nerve
- Ulnar nerve
- + Subcutaneous nerve

207. Denote canals inferior (below) the inguinal ligament.

- + Femoral canal;
- + Adductor canal;
- + Cruropopliteal canal;
- + Superior musculooperoneal canal.
- + Obturatorial canal

208. The back of the medial epicondyle is related to the:

- Radial nerve.
- Axillary nerve;
- + Ulnar nerve;
- Median nerve..
- femoral nerve

209. The following muscles flex the leg

- + gracilis
- + Semitendinosus;
- adductor magnus (hamstring part)
- + Semimembranosus;
- + biceps femoris;

210. Denote muscles of the anterior group of the leg.

- + Tibialis anterior;
- + Extensor digitorum longus;
- Flexor digitorum longus;
- + Peroneus tertius;
- Semitendinosus;

211. Denote muscles, forming the deep layer of the posterior group of the leg.

- + Popliteus;
- + Flexor digitorum longus;
- Plantaris;
- + Tibialis posterior.
- Tibialis anterior

212. Denote muscles, pronating the foot.

- Tibialis anterior;
- Tibialis posterior;
- + Peroneus longus;
- + Peroneus brevis;
- Plantaris

213. Denote muscles, extending the foot in the talocrural joint.

- + Extensor digitorum longus;
- + Extensor hallucis longus;
- Peroneus longus;
- + Tibialis anterior.
- Plantaris

214. Denote muscles, participating in the flexion (plantar flexion) of the foot.

- + Flexor digitorum longus;
- + Flexor hallucis longus;
- + Tibialis posterior;
- Priformis ;
- Triceps surae

215. Indicate layers of an eyeball.

- Mucous layer
- + Fibrous layer
- + Retina
- Serous layer
- + Vascular layer

216. Name parts of an analyzer?

- + Peripheral part
- + Nervous centres in the brain cortex
- + Descending conducting tract
- + Ascending conducting tract
- Basal nucleus

217. Indicate anatomical structures of vascular layer of an eyeball.

- + Ciliary zonule
- Iridocorneal angle
- + Ciliary body
- + Pupil
- Corneal limb

218. Indicate the site of localization of the ciliary zonule.

- Between ciliary body and sclera
- + Attached to ciliary body
- Attached to iris
- + Between lens and ciliary body
- Between lens and iris

219. What anatomical structures pass through the common tendinous ring in the orbit?

- Ophthalmic nerve
- + Ophthalmic artery
- + Optic nerve
- Inferior orbital vein
- Lacrimal artery

220. Which tunic of an artery is most responsible for maintaining blood pressure and continuous blood circulation?

- Tunica interna (intima)
- + Tunica media
- Tunica externa
- Tunica adventitia
- Tunica muscularis

221. What structure produces aqueous humor filling anterior and posterior chambers of an eyeball?

- Epithelium of cornea
- Epithelium of iris
- Pigmented layer of retina
- + Epithelium, covering ciliary body and its processes
- Vitreal corpus

222. Where the aqueous humor flows from the anterior chamber of an eyeball?

- + In scleral venous sinus
- In veins of iris
- In episcleral space
- In lacrimal sac
- In the posterior chamber

223. Indicate parts of the brain the conducting tract of the visual analyzer is passing through.

- + Lateral geniculate body
- Medial geniculate body
- + Occipital lobe of brain
- + Internal capsule
- Medial geniculate body

224. Indicate lateral and posterior walls of tympanic cavity.

- + Mastoid wall
- Labyrinthine wall
- + Membranous wall
- Carotid wall
- Tegmental wall

225. Indicate anatomical formations on the labyrinthine wall of tympanic cavity.

- + Promontory
- + Prominence of facial canal
- Pyramidal eminence
- Prominence of lateral semicircular canal
- Tympanic membrane

226. What anatomical structures are related to the transmitting system of the organ of hearing?

- + Auditory ossicles
- + Tympanic membrane
- + Membrane of oval window
- + Perilymph in scala vestibule
- Semicircular ducts

227. What orifices open into utricle?

- Ductus reuniens
- + Anterior semicircular duct
- + Posterior semicircular duct
- + Lateral semicircular duct
- Cochlear duct

228. Indicate orientation of the anterior semicircular duct.

- Parallel to superior surface of pyramid
- Parallel to posterior surface of pyramid
- + Perpendicular to longitudinal axis of pyramid
- Perpendicular to transverse axis of pyramid
- Parallel to longitudinal axis of pyramid

229. Indicate possible paths of outflow of perilymph from perilymphatic space of labyrinth.

- Into endolymphatic sac
- + Into subarachnoid space on inferior surface of pyramid of temporal bone
- Into membranous labyrinth
- Into utricular recess
- Into cochlear duct

230. Indicate structures of the central part of rhinencephalon.

- Subcallosal area
- Diagonal band
- + Parahippocampal gyrus
- + Uncus
- Hippocamp

231. Indicate nerves carrying taste innervation from the tongue.

- Greater petrosal nerve
- + Chorda tympani
- Branches of glossopharyngeal nerve
- Branches of vagus nerve
- + Facial nerve

232. Indicate papillae of tongue, having no taste buds.

- Foliate
- Valate
- + Filiform
- Fungiform
- + Conice

233. Indicate vessels and nerves of the organ of vision.

- + Central artery of retina
- Maxillary artery
- + Lymphatic vessels terminating in submandibular nodes
- + Branches of ophthalmic nerve
- + Oculomotor nerve

234. Indicate vessels of vestibulocochlear organ.

- + Branch of internal carotid artery
- + Branch of external carotid artery
- + Veins, running into external jugular vein
- + Veins, running into retromandibular vein
- + Branch of maxillary artery

235. Indicate vessels and nerves of external and middle ear.

- Branch of superior thyroid artery
- + Veins, running into external jugular vein
- + Veins, running into retromandibular vein
- + Branch of vagus nerve
- + Tympanic nerve

236. Indicate vessels and nerves of an auditory tube.

- + Anterior tympanic artery
- + Branch of ascending pharyngeal artery
- + Veins, running into pharyngeal venous plexus
- + Branch of glossopharyngeal nerve
- Veins, running into retromandibular vein

237. Indicate sites of passage of the oculomotor nerve.

- + Lateral wall of cavernous sinus
- Optic canal
- + Superior orbital fissure
- Inferior orbital fissure
- Round foramen

238. Indicate muscles, innervated by the inferior branch of oculomotor nerve.

- Levator palpebrae superioris

+ Inferior rectus

+ Medial rectus

- Superior rectus

+ Inferior oblique

239. Indicate muscles, innervated by trochlear nerve.

+ Superior oblique

- Inferior oblique

- Medial rectus

- Lateral rectus

- Superior rectus

240. Indicate muscles, innervated by abducent nerve.

- Medial rectus

- Inferior oblique

+ Lateral rectus

- Superior oblique

- Superior rectus

241. Indicate branches of trigeminal nerve, innervating the mucous membrane of nasal cavity.

+ Infraorbital nerve

+ Nasociliary nerve

- Zygomaticofacial branch of zygomatic nerve

- Zygomaticotemporal branch of zygomatic nerve

- Mandibular nerve

242. Indicate a nerve, its sensory fibres directed to ciliary ganglion.

+ Nasociliary nerve

- Frontal nerve

- Lacrimal nerve

- Oculomotor nerve

- Zygomatic nerve

243. Indicate branches of ophthalmic nerve.

+ Lacrimal nerve

- Infraorbital nerve

+ Frontal nerve

+ Nasociliary nerve

- Superior alveolar nerve

244. Indicate branches of mandibular nerve.

+ Buccal nerve

+ Auriculotemporal nerve

+ Lingual nerve

+ Inferior alveolar nerve

- Superior alveolar nerve

245. The greater petrosal nerve leaves the facial canal through:

- Hiatus of canal of lesser petrosal nerve

- Stylomastoid foramen

- Internal opening of carotid canal

+ Hiatus of canal of greater petrosal nerve

- Round foramen

246. Indicate nerves forming the nerve of pterygoid canal.

- Lesser petrosal nerve
- Tympanic chord
- + Greater petrosal nerve
- + Deep petrosal nerve
- Internal carotic nerve

247. Indicate nerves, branching from pterygopalatine ganglion.

- + Greater and lesser palatine nerves
- Posterior inferior nasal branches
- Short ciliary nerves
- + Posterior superior lateral and medial nasal branches
- + Pharyngeal branches

248. Indicate branches of facial nerve in facial canal.

- Somatic branches
- + Greater petrosal nerve
- + Tympanic chord
- + Nerve to stapedius
- Posterior auricular nerve

249. Indicate branches of glossopharyngeal nerve.

- + Pharyngeal branches
- + Tonsillar branches
- + Tympanic nerve
- Temporal branches
- Zygomatic nerve

250. Indicate nerves, forming pharyngeal plexus.

- + Vagus nerve
- + Glossopharyngeal nerve
- Trigeminal nerve
- + Sympathetic trunk
- Facial nerve

251. Indicate organs, innervated by the posterior trunk of vagus nerve.

- Rectum
- + Liver
- + Small intestine
- + Stomach
- + Pancreas

252. Indicate organs, innervated by the anterior trunk of vagus nerve.

- Kidney
- Vermiform appendix
- + Liver
- + Stomach
- Pancreas

253. Indicate sites of passage of the vagus nerve.

- + Posterolateral sulcus of myelencephalon
- + Posterior to root of lung
- On pretracheal sheet of cervical fascia
- + On prevertebral sheet of cervical fascia
- Anterior root of lung



254. Indicate anatomical structures, innervated by auricular branch of vagus nerve.

- Posterior auricular muscle
- + Skin of external surface of auricle
- + Skin of posterior wall of external acoustic meatus
- Superior auricular muscle
- Walls of occipital sinus

255. Indicate branches of accessory nerve.

- Anterior branch
  - + External branch
  - + Internal branch
  - Posterior branch
  - Lateral branch
256. Indicate muscles, innervated by accessory nerve.

- Rhomboid muscle
- + Sternocleidomastoid
- Digastric
- + Trapezius
- Genioglossal muscle

257. Indicate the level of projection of the upper border of the spinal cord.

- Upper margin of 1st cervical vertebra
- + Lower margin of foramen magnum
- Lower margin of 1st cervical vertebra
- Site of outlet of roots of 1st pair of spinal nerves
- Upper margin of foramen magnum

258. The following blood vessels empty into the right atrium:

- + Inferior vena cava
- + Superior vena cava
- + Coronary sinus
- Pulmonary veins
- Pulmonary artery

259. What anatomical structures form a spinal nerve?

- Posterior funiculus of spinal cord
- Lateral funiculus of spinal cord
- + Anterior root of spinal cord
- + Posterior root of spinal cord
- Anterior funiculus of spinal cord

260. What anatomical structures form the elementary reflex arch?

- + Afferent neuron
- + Intermediate neuron
- Conductor neuron
- + Efferent neuron
- Central nucleus

261. Indicate nuclei of the posterior horn of the spinal cord.

- + Thoracic nucleus
- Central nucleus
- Posterolateral nucleus
- + Nucleus proprius
- Anterolateral nucleus

262. Following are the pairs describing skull foramina and the nerves related. Choose the correct pair

- Foramen rotundum: Mandibular nerve
- Foramen ovale: Maxillary nerve
- Foramen spinosum: ophthalmic nerve
- + Internal acoustic meatus: Nerves intermedius
- + Foramen jugulare: cranial nerve IX.X.XI

263. Denote the nerves which innervate the triceps brachii :

- Long thoracic
- Lower subscapular
- Axillary
- Musculocutaneous
- + Radial

264. Indicate part of the brain the cerebral peduncles that belongs to

- + Midbrain
- Diencephalon
- Telencephalon
- Metencephalon
- Cerebellum

265. What parts of the brain are related to cerebrum?

- + Insula
- + Corpus callosum
- + Rhinencephalon
- + Basal nuclei
- Cerebellum

266. What anatomical structures belong to telencephalon?

- Black substance
- + Basal nuclei
- + Internal capsule
- + Fornix
- Thalamuses

267 Denote the statements which correctly describe the axillary artery:

- It originates from the arch of the aorta
- + It gives origin to the thoracoacromion artery
- + It has the lateral thoracic artery as its first branch
- It divides into radial and ulnar arteries
- + It provides blood supply to the humerus

268. Between what gyri of the brain the sulcus of corpus callosum is located?

- Lingual gyrus
- + Cingulate gyrus
- Superior frontal gyrus
- + Corpus callosum
- Insula

269. Indicate gyri on the inferior surface of cerebral hemispheres.

- Precuneus
- + Straight gyrus
- + Orbital gyrus
- Angular gyrus
- Cingulate gyrus

270. Near what sulcus the supramarginal gyrus is located?

- Superior temporal sulcus
- + Lateral sulcus
- Central sulcus
- Calcarine sulcus
- Rhinal sulcus

271. Indicate gyri of the frontal lobe of the cerebral hemisphere.

- + Opercular part
- + Triangular part
- Supramarginal gyrus
- + Precentral gyrus
- + Orbital part

273. In which gyrus a cortical motor center is located?

- Superior frontal gyrus
- Postcentral gyrus
- Middle temporal gyrus
- + Precentral gyrus
- + Paracentral part

274. Indicate the site of localization of cortical centre of general sensitivity.

- Middle frontal gyrus
- Occipital lobe
- + Postcentral gyrus
- Opercular part
- + Superior parietal lobul

275. Between what sulci the precuneus is located?

- + Parieto-occipital sulcus
- + Cingulate sulcus
- Sulcus of corpus callosum
- Occipito-temporal sulcus
- Postcentral gyrus

276. Great cardiac vein lies in

- + Anterior interventricular groove
- Posterior interventricular groove
- Anterior atrio-ventricular groove
- Posterior atrio-ventricular groove
- + Coronary groove

277. What gyri are located in the temporal lobe of the cerebral hemisphere?

- Supramarginal gyrus
- + Transverse temporal gyrus
- Angular gyrus
- Precentral sulcus
- Triangular gyrus

278. The following events occur at the sternal angle of Louis:

- + Trachea bifurcates into main bronchi
- + Azygous vein enters superior vena cava
- Coronary arteries originate from the aorta
- + Superior border of fibrous pericardium
- + Border between superior and inferior mediastina

279. What anatomical structures border the internal capsule?

- + Head of caudate nucleus
- + Thalamus
- + Lentiform nucleus
- Claustrum
- Red nucleus

280. Indicate basal nuclei of the brain.

- Red nucleus
- + Corpus striatum
- + Amygdaloid body
- + Claustrum
- Hippocampus

281. Indicate the site of localization of the amygdaloid body.

- Insula
- Occipital lobe
- + Temporal lobe
- Parietal lobe
- Hippocampus

282. The descending thoracic aorta

- Has 11 pairs of posterior intercostal arteries.
- Has three bronchial arteries to the right lung.
- Is located lateral (left) to vertebra T12.
- + Is located posterior to the esophagus at the level of the esophageal hiatus of the diaphragm.
- Has 2 subcostal branches to the superior surface of the diaphragm

283. What walls of the anterior horn of lateral ventricle are formed by corpus callosum?

- + Superior wall
- + Inferior wall
- Lateral wall
- + Anterior wall
- Medial wall

284. The right vagus nerve

- + Lies at the lateral (right) border of the trachea in the superior mediastinum.
- Descends posterior to the right subclavian artery to enter the superior mediastinum.
- Passes anterior to the root of the right lung to which it supplies pulmonary parasympathetic fibers.
- + Has a recurrent laryngeal branch, which passes posterior to the derivative of the embryonic right 6th aortic arch.
- + Innervate stomach

285. What anatomical structures form walls of the inferior horn of lateral ventricle?
- + Fimbria of hippocampus
  - Corpus callosum
  - Thalamus
  - + Hippocampus
  - Olfactory bulb
286. What anatomical structures belong to diencephalon?
- Inferior olive
  - Septum pellucidum
  - + Mamillary body
  - + Optic chiasm
  - + Lamina terminalis
287. What anatomical structures belong to hypothalamus?
- + Tuber cinereum
  - + Supraoptic nucleus
  - + Lamina terminalis
  - Posterior commissure
  - Corpus callosum
288. What anatomical structures belong to metathalamus?
- Hypophysis
  - Pineal body
  - + Medial geniculate body
  - + Lateral geniculate body
  - Caudate nucleus
289. What structures form walls of the 3rd ventricle?
- + Hypothalamus
  - + Column of fornix
  - + Thalamus
  - Corpus callosum
  - Anterior perforated substance
290. Indicate hypothalamic nuclei.
- Caudate nucleus
  - + Paraventricular nucleus
  - Suprachiasmatic nucleus
  - Red nucleus
  - + Supraoptic nucleus
291. Indicate limbic structures.
- Dentate gyrus
  - + Anterior perforated substance
  - + Hippocampus
  - + Olfactory bulb
  - + Olfactory tract
292. What anatomical structures belong to medial lemniscus
- + internal arcuate fibers
  - Inferior colliculi of midbrain
  - + Medial geniculate body
  - + axons of nucleus gracilis
  - + axons of nucleus cuneatus.

294. Indicate subcortical acoustic centers.

- Lateral geniculate body
- Pulvinar
- + Medial geniculate body
- + Inferior colliculi of midbrain
- Black substance

295. Indicate anatomical structures, relating to isthmus of rhombencephalon.

- + Superior medullary velum
- + Trigone of lemniscus
- + Superior cerebellar peduncles
- Brachii of inferior colliculi
- Inferior cerebellar peduncles

296. What structures divide pons into tegmentum and basis?

- Medial lemniscus
- + Trapezoid body
- Spinal lemniscus
- Transverse pontine fibres
- Basilar sulcus

297. Indicate the site of localization of the lateral lemniscus.

- Superior cerebellar peduncles
- Superior medullary velum
- Inferior cerebellar peduncles
- + Trigone of lemniscus
- Trapezoid body

298. Indicate cranial nerves, having nuclei in pons.

- + 7th pair
- 9th pair
- + 6th pair
- 10th pair
- + 5th pair

299. What parts of the brain are connected by middle cerebellar peduncles?

- Midbrain
- Myelencephalon
- + Cerebellum
- + Pons
- Cerebrum

300. Which of the following statements on the intercostal neurovascular bundle in the right 5th intercostal space is CORRECT?

- The intercostal nerve, which innervates the intercostal muscles in the space, is a posterior ramus (or primary division) of a thoracic spinal nerve.
- The venous drainage of the space is anteriorly to the internal thoracic veins and posteriorly to the hemiazygous vein.
- The two anterior intercostal arteries that supply the space are branches of the musculophrenic artery.
- The space is supplied by two posterior intercostal arteries, which are branches of the aorta.
- + At a level just anterior to the angle of the ribs, the neurovascular bundle is located between the innermost and internal intercostal muscles

301. What parts of the brain are connected by inferior cerebellar peduncles.
- Pons
  - + Myelencephalon
  - + Cerebellum
  - Superior segments of spinal cord.
  - Midbrain
302. Indicate the site of localization of nucleus of accessory nerve.
- Midbrain
  - + Myelencephalon
  - Pons
  - + Superior segments of spinal cord
  - Cerebellum
303. Indicate the site of localization of motor nucleus of trigeminal nerve.
- + Pons
  - Midbrain
  - Myelencephalon
  - Isthmus of rhombencephalon
  - Cerebellum
304. Indicate cranial nerves, for which the nucleus of solitary tract is a common one.
- 12th nerve
  - + 9th nerve
  - 11th nerve
  - + 10th nerve
  - + 7th nerve
305. Choose the statements which describe the lateral cord of the brachial plexus correctly:
- It represents lateral divisions of the plexus
  - Typically it has five branches
  - + It contains nerve fibers from C8 and T5
  - It gives rise to the ulnar nerve
  - + It gives rise to the musculocutaneous nerve
306. Indicate cranial nerves, for which the nucleus ambiguus is a common one.
- 7th nerve
  - + 10th nerve
  - + 9th nerve
  - 12th nerve
  - 6th nerve
307. The following statements concerning chorda tympani nerve are true
- + Joins lingual nerve in infratemporal fossa
  - + Is a branch of facial nerve
  - + Contains preganglionic parasympathetic fibers
  - Innervate tympanic membrane
  - Carries secretomotor fibers to the parotid gland

308. The posterior cord of the brachial plexus is described correctly by all the following statements, EXCEPT

- It is formed by union of all the posterior divisions of the plexus
- It gives off the upper subscapular nerve
- + It gives off the median nerve
- It gives off the axillary nerve
- It has the radial nerve as a terminal branch

309. Fibres of what conducting tract form the dorsal decussation of the midbrain tegmentum.

- Rubrospinal
- + Tegmentospinal
- Pyramidal
- Tract of pain and temperature sensitivity
- Vestibulospinal tract

310. Fibres of what conducting tract form the ventral decussation of the midbrain tegmentum.

- Posterior longitudinal fascicle
- Corticospinal tract
- + Rubrospinal tract
- Medial lemniscus
- Corticothalamic

311. What conducting tracts pass through the genu of internal capsule.

- Anterior spinothalamic
- Corticothalamic
- Frontopontine
- + Corticonuclear
- Rubrospinal

312. Indicate conducting tracts in the posterior funiculi of the spinal cord.

- Posterior longitudinal fascicle
- Anterior spinocerebellar tract
- Posterior spinocerebellar tract
- + Cuneate fasciculus
- Rubrospinal tract

313. Indicate conducting tracts in the lateral funiculi of the spinal cord.

- Lateral proper fasciculus
- Lateral lemniscus
- Vestibulospinal tract
- + Rubrospinal tract
- Corticonuclear

314. Denote the borders of spatium antescalenum:

- Pleura
- + Sternothyroideus muscles
- + Sternohyoideus muscle
- Medial scalenus muscle
- + Anterior scalenus muscle



315. Indicate conducting tracts in the internal capsule.

- Long associative fibres
- Commissural fibres
- + Projectional fibres
- Short associative fibres
- Lateral lemniscus

316. Contraction of the tensor tympani and the stapedius prevents damage to the eardrum and inner ear. These muscles are controlled by the following nerves:

- Tympanic and chorda tympani nerve
- + Trigeminal and facial nerves
- Facial and auditory nerves
- Trigeminal and accessory nerves
- Facial and vagus

317. What parts of the brain and spinal cord the posterior spinocerebellar tract passes through?

- + Lateral funiculus of spinal cord
- + Inferior cerebellar peduncle
- Superior cerebellar peduncle
- Posterior funiculus of spinal cord
- Anterior funiculus of spinal cord

318. Indicate nuclei of the brain, processes of which form the medial lemniscus.

- Proper nucleus of posterior horn of spinal cord
- + Cuneate nucleus
- + Gracile nucleus
- Motor nucleus of trigeminal nerve
- Solitar nucleus

319. What parts of the brain the corticonuclear tract passes through?

- Posterior limb of internal capsule
- + Genu of internal capsule
- Tegmentum of midbrain
- Base of pons
- + Precentral gyrus

320. Indicate anatomical structures, residing in epidural space of the vertebral canal.

- Liquor
- + Fatty tissue
- + Venous plexus
- Spinal nerves
- Spinal cord

321. Indicate structures of brain, secreting liquor.

- Arachnoid mater
- + Choroid plexus of lateral ventricles
- + Choroid plexus of 3rd ventricle
- + Choroid tela of 4th ventricle
- Dura mater

322. Indicate openings, connecting a cavity of 4th ventricle with subarachnoid space.

- Opening of cerebral aqueduct

+ Lateral apertures

+ Median aperture

- Interventricular foramina

- Foramen caecum

323. From what cavity of the brain liquor flows into subarachnoid space.

+ From 4th ventricle

- From 3rd ventricle

- From lateral ventricles

- From aqueduct of midbrain

- From 5th ventricle

324. Popliteal pulse is not felt clearly because

- It is not over prominent bone

- Pulse is weak

+ It is deep seated

- It is branch of iliac artery

- It is both deep seated and not over prominent bone

325. Indicate features of the dura mater of the brain.

+ Fused with bones of skull in some places

+ Presence of venous sinuses

+ Presence of processes

- Presence of denticulate ligaments

+ Presence of cerebral falx

326. What sinus the inferior sagittal sinus flows into?

- Superior sagittal sinus

- Sigmoid sinus

+ Straight sinus

- Transverse sinus

- Occipital sinus

327. What sinuses and veins flow into the straight sinus?

+ Superior sagittal sinus

+ Inferior sagittal sinus

- Small cerebral vein

+ Great cerebral vein

- Transverse sinus

328. Indicate sinuses merging in the region of internal occipital eminence and forming confluence of sinuses.

+ Transverse sinus

- Sigmoid sinus

+ Superior sagittal sinus

+ Straight sinus

+ Occipital sinus

329. Which cranial nerves exit brain on the medial surface of peduncle of the brain?

- 6th pair of nerves

- 4th pair of nerves

- 5th pair of nerves

+ 3rd pair of nerves

- 7th pair of nerves

330. What cranial nerves exit brain on the dorsal surface of the brainstem.

- 3rd pair of nerves
- + 4th pair of nerves
- 5th pair of nerves
- 6th pair of nerves
- 7th pair of nerves

331. What cranial nerves exit brainstem between pons and myelencephalon?

- 4th pair of nerves
- 3rd pair of nerves
- + 6th pair of nerves
- 5th pair of nerves
- 10th pair of nerves

332. What cranial nerves exit brainstem between pyramid and olive?

- 9th pair of nerves
- 11. th pair of nerves
- + 12th pair of nerves
- 10th pair of nerves
- 7th pair of nerves

333. What cranial nerves exit brainstem behind an olive?

- + 9th pair of nerves
- + 10th pair of nerves
- 12th pair of nerves
- + 11. th pair of nerves
- 7th pair of nerves

334. Indicate anatomical structures relating to peripheral nervous system

- + Cranial nerves
- + Spinal nerves
- + Splanchnic nerves
- + Sensory ganglia of spinal nerves
- Spinal cord

335. Indicate nervous fibres in spinal nerves.

- Postganglionic parasympathetic
- + Sensory
- Preganglionic sympathetic
- + Motor

+ Postganglionic sympathetic

336. Which vessel does not originate from the arch of the aorta?

- Brachiocephalic artery
- Left subclavian artery
- + Right subclavian artery
- Left common carotid artery
- + Right common carotid artery

335. Indicate anatomical structures, supplied by posterior branches of spinal nerves.

- + Deep muscles of back
- + Skin of dorsal surface of trunk
- Superficial muscles of neck
- + Suboccipital muscles
- Scalene muscles

336. Indicate spinal nerves, having white communicating branches.

- + Thoracic nerves
- Cervical nerves
- + 1st and 2nd lumbar nerves
- Sacral nerves
- Lumbar nerves

337. Indicate cutaneous branches of cervical plexus.

- + Great auricular nerve
- + Transverse cervical nerve
- + Lesser occipital nerve
- + Supraclavicular nerve
- Cervical ansa

338. Indicate muscles, innervated by cervical plexus.

- + Scalene muscles
- + Longus colli and capitis
- + Rectus capitis anterior
- + Levator scapulae
- + Trapezius

339. Indicate sites of passage of greater occipital nerve?

- Foramen magnum
- Between occipital bone and atlas
- + Between atlas and axis
- + Through trapezius
- Interscalenal space

340. Indicate anatomical structures, innervated by transverse cervical nerve.

- Trapezius
- Sternocleidomastoid
- + Skin of anterior cervical region
- + Skin of lateral cervical region
- Deltoid

341. Indicate anatomical structures, innervated by supraclavicular nerves.

- Skin on deltoid muscle
- + Skin on greater pectoral muscle
- Skin of lateral cervical region
- Skin of anterior cervical region
- Skin on trapezius muscle

342. Indicate anatomical structures, innervated by phrenic nerve.

- + Liver
- + Pericardium
- + Pleura
- + Peritoneum
- Pancreas

343. Indicate sources of supply of trapezius and sternocleidomastoid muscles.

- + Accessory nerve
- Glossopharyngeal nerve
- + Branches of cervical plexus
- Branches of brachial plexus
- Hypoglossal nerve

344. Indicate a source of supply of the skin of anterior and lateral cervical regions.
- Accessory nerve
  - Hypoglossal nerve
  - Facial nerve
  - + Transverse cervical nerve
  - Glossopharyngeal nerve
345. Indicate sites of passage of phrenic nerve
- + In superior mediastinum
  - + On front surface of anterior scalene muscle
  - + Between subclavian artery and vein
  - + Anterior to root of lung
  - In posterior mediastinum
346. Indicate nerves, being the short branches of brachial plexus.
- + Long thoracic nerve
  - + Axillary nerve
  - + Lateral and medial pectoral nerves
  - Medial cutaneous nerve of arm
  - + Subscapular nerve
347. Indicate muscles, innervated by the axillary nerve.
- Anterior scalene muscle
  - + Deltoid muscle
  - Lesser pectoral muscle
  - Greater pectoral muscle
  - Posterior scalene muscle
348. Indicate muscles, innervated by the long thoracic nerve.
- Subscapularis
  - + Anterior serratus
  - Latissimus dorsi
  - Intercostal muscles
  - Deltoid
349. What nerves provide sensory supply in elbow joint?
- + Ulnar nerve
  - + Radial nerve
  - + Median nerve
  - Axillary nerve
  - Medial pectoral nerve
350. Indicate nerves, originating from the medial fascicle of the brachial plexus.
- + Ulnar nerve
  - Radial nerve
  - + Medial pectoral nerve
  - + Medial cutaneous nerve of arm
  - Axillary nerve
351. Indicate muscles, innervated by musculocutaneous nerve.
- + Coracobrachialis
  - + Biceps brachii
  - Triceps brachii
  - Teres pronator
  - Subscapularis

352. Indicate anatomical structures, innervated by the ulnar nerve.

- Flexor carpi radialis
- + Flexor carpi ulnaris
- + Medial part of flexor digitorum profundus
- + Elbow joint

- Triceps brachii

353. The spinal cord is suspended in the dura mater by the

- Filum terminale
- Cauda equina
- Conus medullaris
- + Denticulate ligament
- Alar ligament

354. The principal site of absorption of cerebrospinal fluid into the venous system is through the

- Diploic veins
- + Arachnoid villa
- Pterygoid plexus
- Vertebral venous plexus
- Cavernous sinus

355. The dorsal root ganglia are located in the

- Vertebral furrow
- Coccyx
- + Intervertebral foramina
- Intervertebral disks
- Sympathetic chain

356. The bundle of nerve rootlets in the subarachnoid space caudal to the termination of the spinal cord is known as the

- Lumbosacral plexus
- Femoral nerve
- Pelvic splanchnic nerve
- Sciatic nerve
- + Cauda equina

357. Which of these statements concerning the filum terminale of spinal cord are correct ?

- + It is a fibrous strand extending from the inferior end of the conus medullaris
- It ascends among the nerve rootlets comprising the cranial nerve
- + It consists of two parts, an upper and a lower.
- It inserts into the lower jaw
- + It is one of the modifications of pia mater

358. All the following statements concerning the anterior spinal artery are correct,

EXCEPT

- It arises from branches of the vertebral arteries
- It is located in the anterior median fissure
- It runs the length of the spinal cord
- It supplies the anterior two-thirds of the spinal cord
- + It arises from branches of the internal carotid

359. Which of the following structures are located in the epidural space
- +Spinal nerve roots
  - muscular tissue
  - +loose connective tissue
  - +the anterior vertebral venous plexus
  - +the posterior vertebral venous plexus
360. Which of these statements concerning the posterior cruciate ligament are correct?
- It connects the posterior intercondylar area of the tibia to the lateral condyle of the femur
  - It is composed of dura mater
  - It connects the posterior intercondylar area of the tibia to the patella
  - + It connects the posterior intercondylar area of the tibia to the medial condyle of the femur
  - + is an intracapsular ligament
361. Which of the following statements concerning the pia mater is correct?
- It is the intermediate covering membrane of the spinal cord
  - It is composed of white fibrous and elastic tissue
  - It is composed of two layers of dense connective tissue
  - It is deep to the anterior spinal artery
  - + It continues inferior to the conus medullaris as the filum terminale
362. The lumbar cistern contains the
- Posterior internal venous plexus
  - Posterior spinal arteries
  - Anterior external venous plexus
  - + Cauda equina
  - Denticulate ligaments
363. The supraclavicular nerves supply:
- +Skin above the pectoral major muscles
  - Skin of the region of trapezoid muscle
  - Skin of the region of sternocleidomastoid muscle
  - Deltoideus and pectoralis minor muscles
  - Deltoideus muscles
364. If an incision had to be made in the small intestine to remove an obstruction, which layer of tissue would be cut first?
- Muscularis
  - Mucosa
  - + Serosa
  - Submucosa
  - Submucosa and stomach
365. To free the small intestine from the posterior abdominal wall, which of the following would have to be cut?
- Round ligament
  - + Mesentery
  - Lesser omentum
  - Falciform ligament
  - Aorta

366. Which of the following are part of cystic duct?

- + Neck
- + Fundus
- + Body
- Fornix
- Duct

367. Urine that leaves the distal convoluted tubule passes through the following structures. In which sequence?

- Collecting duct, hilus, calyces, ureter
- + Collecting duct, calyces, pelvis, ureter
- Calyces, collecting duct, pelvis, ureter
- Calyces, hilus, pelvis, ureter
- Prostate

368. Blood is drained directly from the kidneys by the:

- Renal arteries
- Inferior vena cava
- Efferent arterioles
- + Renal veins
- Aorta

369. Which organ has segmental structure?

- + Kidney
- Urinary bladder
- + Lung
- + Liver
- Bile duct

370. The male urethra is encircled by which structure?

- Epididymis
- Scrotum
- + Prostate gland
- Seminal vesicle
- Urinary bladder

371. Fertilization normally occurs in the:

- + Uterine tubes
- Vagina
- Uterus
- Ovaries
- Prostate gland

372. A pair of slender tubes from each ovary to the side of the fundus of the uterus, through which the ova pass called

- +Salpinx
- +Fallopian tube
- Vagina
- +Oviduct
- +Uterine tubes



373. Which sequence better represents the course taken by sperm from the site of origin to the exterior?

+ Seminiferous tubules, efferent ductules, duct of epididymis, ductus deferens, ejaculatory duct, urethra

- Seminiferous tubules, efferent ductules, duct of epididymis, ductus deferens, urethra, ejaculatory duct

- Seminiferous tubules, efferent ductules, ductus deferens, duct of epididymis, ejaculatory duct, urethra

- Seminiferous tubules, duct of epididymis, efferent ductules, ductus deferens, ejaculatory duct, urethra

- Seminiferous tubules, efferent ductules, duct of epididymis, ductus deferens, excretory duct, urethra

374. The right colic flexure occurs between the:

- Transverse and descending colon

- Cecum and ascending colon

+ Ascending colon and transverse colon

- Descending colon and rectum

- Ascending colon and descending colon

375. Which of the following is not considered part of the digestive system?

- Pancreas

+ Spleen

- Tongue

- Cecum

- Stomach

376. Which of the following is not a spermatic duct?

- Epididymis

+ Spermatic cord

- Ejaculatory duct

- Ductus deferens

+ Bile duct

377. Which are the parts of the uterus?

+ Fundus

+ Cervix

- Fornix

+ Body

- Ampulla

378. Which statement about the small intestine is false?

- Terminates at the ileocecal junction

- Is mostly intraperitoneal

- Begins at the pylorus

+ Includes the jejunum, which receives the common bile duct

- Contains Haustra

379. Which is not true of the colon?

- Right flexure below the liver

+ Taeniae coli contain circular muscle fibers

- Haustra are saclike outpocketings of the colon wall

- Sigmoid colon lies on the left side of the body

- Haustra is located in small intestine

380. Which of the following statements concerning the inferior thoracic aperture are correct?

- + It is closed by the diaphragm
- + Structures passing through the inferior thoracic aperture between the thorax and abdomen include the inferior vena cava and esophagus.
- The superior thoracic aperture is much larger than the inferior thoracic aperture
- + It is bounded by 12th thoracic vertebra posteriorly
- + It is bounded by costal cartilages of ribs 7 through 10 anteriorly,
- + It is bounded by the xiphosternal junction anteriorly,

381. All the following statements concerning the xiphosternal junction are correct, EXCEPT:

- It is a landmark in the median line for the upper surface of the liver
- It is a landmark for the diaphragm
- It is a landmark for the lower border of the heart
- It is located at the vertebral level of T9
- + It is located at the level of the cartilage of the 11th rib

382. The sternal angle is found at which of these locations?

- Jugular notch
- Xiphoid process
- Level with the 1st costal cartilage
- Level with the lower border of the 1st thoracic vertebra
- + Manubriosternal joint

383. Which of these items is true regarding external anatomy of the lung?

- The upper tapered end of the lung is its base
- The root of the lung is located at its base
- + Visceral pleura covers all lung surfaces
- There is no visceral pleura
- Each lung has three lobes

384. The "Eustachian" tubes:

- Are attached to the uterus
- Connect the internal ear with the nasopharynx
- + Connect the middle ear with the nasopharynx
- Connect the inner ear to the nasal cavity
- Connect the middle ear with external ear

385. Which of the following statements is true about the trachea?

- It is the passage of food
- It is the upper part the esophagus
- It is 52 cm long
- It is the lower part the esophagus
- + It contains cartilage

386. Which statement is not true regarding the ductus deferens?

- Part of it is located within the spermatic cord
- + It loops over the ureter before entering the ureter
- It joins the duct of the seminal vesicle to form the ejaculatory duct
- The first part of the tube is located within the scrotum
- Part of it is located within Prostate gland

387. Which organ has a hilum?

- + Lung
- Pancreas
- + Kidney
- Bile duct
- Stomach

388. Which are located with the kidney?

- + Pyramid
- + Collecting tubule
- + Minor calyx
- Fundus
- Neck

389. Which would not contribute to the components of the semen?

- + Corpus spongiosum
- Prostate gland
- Testis
- Bulbourethral gland
- Urinary bladder

390. Which statement concerning the pleura is CORRECT:

- The mediastinal pleura receives sensory fibers from intercostal nerves.
- The visceral pleura is innervated by intercostal nerves and is very sensitive to pain.
- At the midaxillary line, the parietal pleura is located at the level of the 8th rib.
- + Posteriorly, the parietal pleura extends from the level of the spine of vertebra C7 to vertebra T12.
- The parietal pleura innervated by hypoglossal nerve.

391. Which statement about the small intestine is false:

- Terminates at the ileocecal junction
- Is mostly intraperitoneal
- Begins at the pylorus
- + Includes the jejunum, which receives the common bile duct
- + Includes the ileum

392. Which of the following are unpaired cartilages

- Arytenoid cartilage
- + Epiglottis
- + Cricoid cartilage
- + Thyroid cartilage
- Triticeal cartilage

393. Which structure is part of the inner ear?

- + Semicircular canal
- Auditory or Eustachian tube
- + Cochlea
- + Vestibule
- + Organ of Corti

394. Which of the following is specifically associated with the cochlea?

- Sacculle
- Crista ampularis
- + Organ of Corti
- Stapes
- Tympanic membrane

395. Which of the following structures are located in the fibrous tunic of the eye?

- Iris and choroid
- Retina and choroid
- + Sclera and cornea
- Retina and cornea
- Lens and cornea

396. The dilation and constriction of smooth muscle in this structure regulates the amount of light entering the eye:

- Pupil
- + Iris
- Lens
- Sclera
- Suspensory ligament

397. In which lobe of the cerebrum vision is detected?

- Temporal
- + Occipital
- Frontal
- Insula
- Parietal

398. The auditory ossicle nearest the tympanic membrane

- Stapes
- + Malleus
- Cochlea
- Incus
- Vestibule

399. The rubrospinal tract originates in the

- + Red nucleus
- Sclera
- Cerebral cortex.
- + Midbrain
- Cornea

400. The photoreceptors concentrated in the fovea centralis:

- Rods
- + Cones
- Both rods and cones
- Neither rods nor cones
- Optic canal

401. Focusing on near objects is the function of the

- Retina
- Cornea
- Pupil
- + Lens
- Iris

402. The cochlear duct contains

- Perilymph
- Bony labyrinth
- Vestibular fluid
- + Endolymph
- Venous blood

403. The blind spot is also the

- Macula lutea
- Fovea centralis
- + Optic disc
- Retina
- Location of mostly rods

404. Through which surfaces light rays pass?

- + Cornea
- + Lens
- + Vitreous body
- + Aqueous humor
- Choroid

405. In the auditory pathway the nervous impulse ends in the

- Occipital lobe
- + Temporal lobe
- Parietal lobe
- Frontal lobe
- Insula

406. The middle or vascular tunic of the eyeball includes the

- + Choroid
- Retina
- Cornea
- Conjunctiva
- Sclera

407. Fluid which cleans and lubricates the eyeball is produced by the

- Canal of Schlemm
- Sclera
- + Lacrimal gland
- Conjunctiva
- Choroidea

408. Which artery is (are) main divisions of the celiac trunk?

- Occipital artery
- + Common hepatic artery
- Right gastric artery
- Inferior pancreaticoduodenal artery
- + left gastric artery

409. All the following are branches of the external carotid artery, EXCEPT:

- Ascending pharyngeal A.
- Superior thyroid A.
- Occipital A.
- + Vertebral A.
- lingual A.

410. Which of the following is not part of the alimentary canal?

- Pharynx
- Stomach
- + Liver
- Large intestine
- + Spleen

411. Which of the following arteries is not a branch of the axillary artery:
- Thoracoacromial
  - + Profunda brachii
  - Lateral thoracic
  - Anterior humeral circumflex
  - Subscapularis
412. The parasympathetic nervous system has origin in the following cranial nerves
- + Oculomotor
  - + Facial
  - + Glossopharyngeal
  - + Vagus
  - Trigeminal
413. Structures contained within the submandibular triangle include:
- + Lingual N
  - Common carotid A
  - + Facial A
  - + Submandibular gland
  - + Hypoglossal N
414. The motor division of the trigeminal nerve leaves the skull through:
- Foramen rotundum
  - + Foramen ovale
  - Superior orbital fissure
  - Inferior orbital fissure
  - Foramen spinosum
415. Branches of the trigeminal nerve include all of the following, EXCEPT:
- + Lesser petrosal
  - Zygomatic
  - Frontal
  - Ethmoidal
  - Lacrimal
416. The portal vein:
- Located on the left side of the lung
  - + Mostly it is formed by the splenic and superior mesenteric veins
  - Lies in front of the neck of the pancreas
  - Lies behind the inferior vena cava
  - Drains all the gastrointestinal tract and its paired glands
417. The cystic duct joins which of the following duct to form the common bile duct?
- Pancreatic
  - + Hepatic
  - Wharton's
  - Stenson's
  - Accessory pancreatic

418. Vascularity to the lesser curvature of the stomach is provided by all of the following, EXCEPT:

- + Gastroduodenal A
- Left gastric A
- Common hepatic A
- Right gastric A
- Celiac A

419. Which artery is (are) derived from the arteries of the celiac trunk?

- + Gastroduodenal
- + Left gastroepiploic
- + Right gastric
- Inferior pancreaticoduodenal
- + Superior pancreaticoduodenal

420. Which of the following statements is correct concerning the first part of the duodenum?

- + It is surrounded by the hepatoduodenal ligament
- It is related to the caudate lobe of the liver
- The common bile duct passes ventrally
- It is located at the level of the third lumbar vertebra
- It has circular folds in its interior

421. By which structures the second portion of the duodenum is crossed?

- Right renal artery
- + Transverse colon
- Right ureter
- Portal vein
- Superior mesenteric vein

422. Which of the following arteries crosses the anterior aspect of the third part of the duodenum?

- Proper hepatic
- Left colic
- + Superior mesenteric
- Inferior mesenteric
- Splenic

423. Which of the following statements is correct about the greater duodenal papilla?

- It is the location for the terminal opening of the accessory pancreatic duct
- It is located in the interior of the third part of the duodenum
- + It is continued below by the longitudinal fold of the duodenum
- It is superior to the lesser duodenal papilla
- It opens into the duodenojejunal flexure

424. Behind which of the following arteries the lower left portion of the head of the pancreas is inserted?

- Left gastroepiploic
- Common hepatic
- Left colic
- Inferior mesenteric
- + Superior mesenteric

425. The superior mesenteric and splenic veins unite to form the portal vein behind
- First part of the duodenum
  - Transverse colon
  - Spleen
  - + Neck of the pancreas
  - Duodenojejunal junction
426. The tail of the pancreas enters
- Epiploic foramen
  - + Iliorenal ligament
  - Suspensory ligament of the duodenum
  - Paracolic fossa
  - Left coronary ligament
427. Which of the following structures represents the obliterated remains of the umbilical vein?
- + Ligamentum teres hepatis
  - Ligamentum venosum
  - Ductus arteriosus
  - Falciform ligament
  - Porta hepatis
428. The hepatoduodenal ligament transmits
- Hepatic vein
  - Main pancreatic duct
  - + Portal vein
  - Ligamentum venosum
  - Superior mesenteric vein
429. The cystic artery usually arises from the following arteries?
- Splenic
  - Gastroduodenal
  - Right gastroepiploic
  - + Right hepatic
  - Celiac trunk
430. The hepatic veins drains into which of the following veins?
- Portal
  - Coronary
  - + Inferior vena cava
  - Superior mesenteric
  - Splenic
431. The portal vein ascends to the liver in the free margin of the
- Mesocolon
  - Greater omentum
  - Mesentery
  - + Lesser omentum
  - Falciform ligament



432. Which of the following are supplied by branches of the superior mesenteric artery

- + Ascending colon
- + Duodenojejunal junction
- + Jejunioileal junction
- Rectum
- Descending colon

433. Which of the following statements is correct about middle colic artery?

- It takes origin from the celiac trunk
- It supplies the cecum
- It anastomoses with the inferior pancreatico-duodenal artery
- + It is a branch of the superior mesenteric artery
- It primarily supplies the left colic flexure

434. Epiploic appendages are located on the

- Duodenum
- Stomach
- Ileum
- Jejunum
- + Sigmoid

435. Which of the following statements is correct about the vermiform appendix?

- It is usually retroperitoneal
- + It has a small mesentery
- It receives its blood supply from the inferior mesenteric artery
- It is usually located in a subhepatic position
- It receives its innervation from the pelvic splanchnic

436. The transverse mesocolon is attached posteriorly to the

- Hepatoduodenal ligament
- Spleen
- + Second portion of the duodenum
- Lesser omentum
- Gastrocolic ligament

437. The psoas major muscle inserts onto the

- Greater trochanter
- Anterior superior iliac spine
- Crest of the ilium
- + Lesser trochanter
- Ischial spine

438. The right suprarenal vein drains into which of the following veins?

- Right renal
- Inferior mesenteric
- Superior mesenteric
- Portal
- + Inferior vena cava

439. Which of the following structures is located in the renal column?

- Interlobular arteries
- Collecting tubule
- Arcuate arteries
- + Interlobar arteries
- Minor calyx vein

440. Which of the following structures is important in the selective reabsorption of water and the return of dissolved materials back into the circulation?

- Glomerular capsule
- Renal papilla
- + Straight and convoluted tubules
- Glomerulus
- Major calyx

441. Which of the following statements is correct about the pelvic splanchnic nerves?

- + Provide parasympathetic fibers to the bladder
- Provide parasympathetic fibers to the right colic flexure
- + Arise from the anterior rami of the sacral spinal nerves S2-S4
- + provide parasympathetic innervation to the hindgut.
- provide sympathetic fibers to the heart

442. Which of the following statements is correct about the gallbladder?

- The submucosal layer is well developed
- The mucous membrane is thrown into circular folds
- + Its epithelium concentrates the contents of the gallbladder
- It produces bile
- It lies to the left of the falciform ligament

443. Which of the following statements is correct about the falciform ligament?

- It represents the inferior limit of the common mesentery
- It encloses the ligamentum teres of the liver
- + It extends from the umbilicus to the liver
- It contains the common bile duct
- It does not extend over the diaphragmatic surface of the liver

444. The anterior surface of the liver lies against all the following structures, EXCEPT

- Diaphragm
- Costal margin
- Xiphoid process
- Abdominal wall
- + Spleen.

445. Which of the following structures are situated between the celiac trunk and the superior mesenteric artery?

- + Duodenum and pancreas
- Spleen and stomach
- Transverse colon and ileum
- Stomach and cecum
- Pancreas and jejunum

446. Blood is drained directly from the kidneys by the:

- Renal arteries
- Inferior vena cava
- Efferent arterioles
- + Renal veins
- Aorta

447. Which organ has segmental structure?

- + Kidney
- Urinary bladder
- + Lung
- + Liver
- Bile duct

448. By which structure the male urethra is encircled?

- Epididymis
- Scrotum
- + Prostate gland
- Seminal vesicle
- Urinary bladder

449. The rounded portion of the uterine body superior to the attachment of the uterine tubes is called:

- Infundibulum
- Cervix
- Fornix
- + Fundus
- Ovarian hilum

450. Which of the following is not part of the alimentary canal?

- Pharynx
- Stomach
- + Liver
- Large intestine
- + Spleen

451. Through which surfaces light rays pass?

- + Cornea
- + Lens
- + Vitreous body
- + Aqueous humor
- Choroid

452. In the auditory pathway the nervous impulse ends in the

- Occipital lobe
- + Temporal lobe
- Parietal lobe
- Frontal lobe
- Insula

453. The middle or vascular tunic of the eyeball includes

- + Choroid
- Retina
- Cornea
- Conjunctiva
- Sclera

454. Motor innervation of the latissimus dorsi muscle is provided by :

- Accessory nerve
- Dorsal scapular nerve.
- + Thoracodorsal nerve
- Transverse cervical nerve
- Axillary nerve

455. Regarding the clavicle, all are correct, EXCEPT:

- + It is an example of the short bones.
- It is the first bone to ossify in the fetal life.
- It ossifies in membrane.
- It is the commonly fractured bone.
- It has no medullary cavity

456. The intersection of the coronal and sagittal suture is called:

- + bregma.
- lambda.
- inion.
- pterion.
- nasion.

457. The surgical neck of the humerus is related to:

- Radial nerve.
- + Axillary nerve.
- Ulnar nerve.
- Median nerve.
- Common interosseus nerve

458. Erb's point is:

- C4, C5
- + C5, C6
- C6, C7
- C7, C8, T1
- C1, C4

459. In Erb's paralysis, the deformity is called:

- Winging of the scapula.
- Claw hand.
- Ape hand.
- Wrist drop.
- + Policeman's tip position

460. The pancreatic magna artery is a branch of which of the following arteries?

- common hepatic
- inferior mesenteric
- superior mesenteric
- left gastroepiploic
- + splenic

461. Paralysis of the serratus anterior muscle causes:

- + Winging of the scapula.
- Claw hand.
- Ape hand.
- Wrist drop.
- Policeman's tip p

462. The following muscles are grouped together as "muscles of mastication":

- Buccinator
- + Masseter
- + Temporalis
- + Lateral Pterygoids
- + Medial Pterygoids

463. Lesion of the axillary nerve causes:

- Winging of the scapula.
- + Flat shoulder.
- Claw hand.
- Ape hand.
- Wrist drop.

464. The superior vena cava returns blood from all of these structures, EXCEPT:

- Head
- Neck
- Upper limb
- + Lungs
- Thoracic wall

465. All the following statements correctly describe the brachiocephalic veins, EXCEPT:

- Each is formed by the union of the internal jugular and the subclavian veins
- + They contain valves to prevent backflow of blood
- They unite to form the superior vena cava
- Each vein receives the internal thoracic vein
- They arise posterior to the medial ends of the clavicle

466. One of the following is the "Key" for articulation of the tarsus transversa ( Chopart joint ) is:

- Ligamentum plantare longum
- Ligamentum talonaviculare
- + Ligamentum bifurcatum
- Ligamentum cuneonaviculare
- Lig collaterale tibia

467. The sympathetic trunk:

- Has a constant, fixed number of ganglia
- Lies anterior to the vertebrae in the thorax
- + Extends from the base of the skull to the coccyx
- Receives white rami throughout its extent
- Supplies postganglionic processes to thoracic and lumbar spinal nerves only

468. Which of the following nerves sends branches to the muscles of the arm?

- Median
- Ulnar
- Dorsal scapular
- + Musculocutaneous
- Long thoracic

469. Which of the following nerves arise from the posterior cord of the brachial plexus,

- Ulnar
- Musculocutaneous
- Long thoracic
- + Axillary
- + Radial

470. The parasympathetic nervous system has origin in all the following cranial nerves, EXCEPT:

- Oculomotor
- Facial
- Glossopharyngeal
- Vagus
- + Trigeminal

471. The following statements concerning the facial nerve or its named branches are true, EXCEPT:

- Ganglion of the facial nerve is the geniculate ganglion.
- The buccinator muscle is innervated by a branch of the facial nerve.
- The greater petrosal N. is joined by a postganglionic sympathetic nerve.
- Salivary glands are innervated by parasympathetic fibers of the facial nerve.
- + Innervate muscle of the tongue

472. Denote the branch of subclavian artery:

- Facial
- + Transversa artery of a neck
- + Vertebral
- + Internal thoracic
- + Thyro-cervical trunk

473. Greater splanchnic nerve usually synapses in the:

- Anterior mesenteric ganglion
- + Celiac ganglion
- Reticular ganglion
- Inferior mesenteric ganglion
- Ganglia of the lower thoracic sympathetic trunk

474. Which of the following nerves arise from medial cords of the brachial plexus?

- Dorsal scapular
- radial
- axillary
- + Ulnar
- long thoracic

475. All of the following are branches of the pudendal nerve, EXCEPT:

- + Inferior gluteal N
- Perineal N.
- Inferior rectal N.
- Dorsal nerve of the penis
- Dorsal nerve of the clitoris

476. The nerve supply to the extensor digitorum brevis is the:

- + Deep peroneal N.
- Superficial peroneal N
- Sural N
- Tibial N
- Saphenous N

477. Which of the following innervates the tensor fascia lata muscle?

- + Superior gluteal N.
- Inferior gluteal N
- Femoral N.
- Obturator N
- Ilio-inguinal N

478. Herniation of the intervertebral disc between the fifth and sixth cervical vertebrae will compress the:

- Fourth cervical nerve root
- Fifth cervical nerve root
- + Sixth cervical nerve root
- Seventh and eighth cervical nerve roots
- Seventh cervical nerve root

479. Which of these is (are) a component of the cardiac conduction system?

- + Atrioventricular node
- + Sinoatrial node
- + Conduction myofibers
- Aortic semilunar valve.
- + Atrioventricular bundle

480. The following cranial nerves send gustatory input to the brainstem

- V, VII, IX, X
- + VII,
- V, VII, IX, X, XII
- VII, IX, X, XII
- VII, IX, X, XI, XII

481. Which of the following tracts has strong facilitatory effects on motoneurons innervating antigravity muscles

- + Medial vestibulospinal
- Ventral corticospinal
- Rubrospinal
- Tectospinal
- Gracile

482. Its fibers form the afferent limb of the corneal reflex

- + Ophthalmic nerve
- Facial nerve
- Maxillary nerve
- Mandibular nerve
- Glossopharyngeal nerve

483. Which of the following ganglia gives rise to the carotid plexus

- + Superior cervical
- Middle cervical
- Stellate
- Inferior cervical
- Geniculate

484. Sensory nerve fibers carrying sensation from all the teeth enter the CNS at the

- Spinal cord
- Medulla
- + Pons
- Midbrain
- Cerebellum

485. This nerve has fibers that extend into three different cranial nerve nuclei in the pons

- Trigeminal
- Abducens
- + Facial
- Vestibulocochlear
- Glossopharyngeal

486. Which of these cranial nerves DOES NOT provide any sensory or motor innervation to the tongue

- VII
- + VIII
- IX
- X
- XII

487. The following is the site of emergence of the IX cranial nerve

- Pontomedullary sulcus
- Cerebellopontine angle
- Floor of the IV ventricle
- Preolivary sulcus
- + Postolivary sulcus

488. The cells in the inferior salivatory nucleus send their axons via

- Intermediate nerve
- Vagus nerve
- + Glossopharyngeal nerve
- Pterygopalatine ganglion
- Spinal nerve

489. A protrusion of a viscus or bowel medial to the inferior epigastric artery is seen in:

- indirect inguinal hernia
- femoral hernia
- hiatus hernia
- + direct inguinal hernia
- Umbilical hernia

490. Which of the following muscles is (are) innervated by the Facial nerve?

- + Zygomaticus major
- + Buccinator
- + Platysma
- + Orbicularis oculi
- Masseter

491. All of the following correct?

- + The spleen lies in the upper left abdominal cavity
- + The spleen is the body's largest lymphoid organ
- + The spleen resembles a large lymph node except that it contains blood instead of lymph
- + The spleen filters the blood
- + The spleen removes damaged blood cells and bacteria



492. All of the following principle correct?

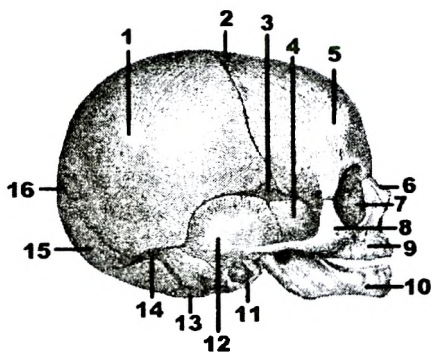
- The arteries are situated on the extensor surfaces of the body
- + The arteries are arranged in accordance with the skeleton, which supplies the framework of the organism .
- + The arteries are arranged in accordance with the skeleton, which supplies the framework of the organism .
- + Arteries follow the shortest distance ;
- + The arteries are situated on the flexor surfaces of the body

493. The posterior belly of the digastric muscle is innervated by a branch of this cranial nerve:

- V
- + VII
- IX
- X
- XI

496. Find the correct number from the picture which indicate « Fonticulus anterior:

Answer: 2.

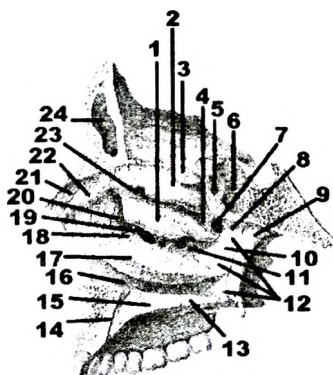


497. Find the correct number from the picture which indicate « Sinus frontalis:

Answer: 24.

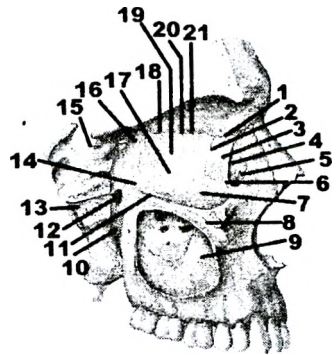
498. Which anatomical formation is indicated by №7?

- Canalis pterygoideus
- Hiatus semilunaris
- Apertura sinus sphenoidalis
- + Foramen sphenopalatinum
- Infundibulum ethmoidale



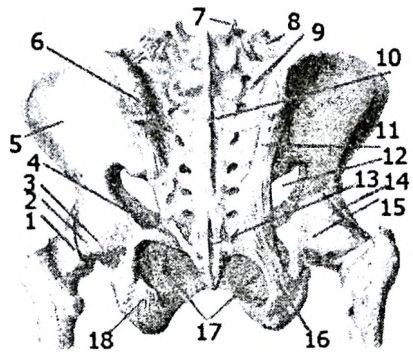
499. Find the correct number from the picture which indicate « Canalis pterygoideus:

Answer: 13.



500. Which anatomical formation is indicated by № 4?

- Membrana obturatoria
- Lig. sacroiliacum posterius
- + Lig. sacrospinale
- Zona orbicularis
- Lig. iliofemorale
- Lig. pubofemorale
- Lig. transversum acetabuli
- Lig. capitis femoris
- Labrum acetabuli
- Lig. sacrotuberale



501. Find the correct number from the picture which indicate « Lig. sacroiliacum posterius»

Answer: 11.

502. Find the correct number from the picture which indicate « Lig. iliofemorale»:

Answer: 14.

503. Find the correct number from the picture, which indicate « Lig. sacrotuberale»:

Answer: 16.

504. Find the correct number from the picture which indicate «Membrana obturatoria» :

Answer: 17.

505. Find the correct number from the picture which indicate « Meniscus lateralis»:

Answer: 5.

506. Find the correct number from the picture which indicate « Lig. collaterale fibulare»:

Answer: 6.

507. Find the correct number from the picture which indicate « Lig. cruciatum posterius»:

Answer: 9.

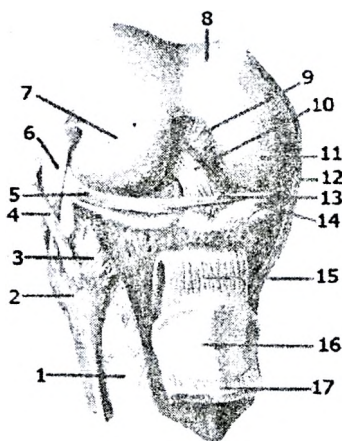
508. Find the correct number from the picture which indicate « Lig. craciatum anteriorus»:

Answer: 10.

509. Find the correct number from the picture which indicate « Lig. transversum genus»:

Answer: 13.

510. Find the correct number from the picture which indicates « Lig. patellae»:  
Answer: 15.

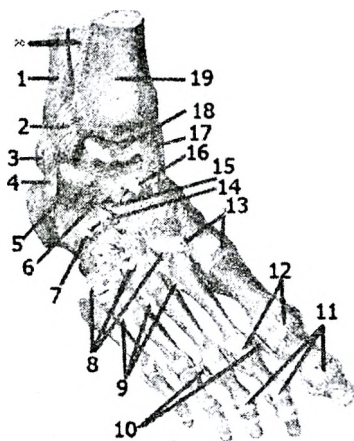


511. Find the correct number from the picture which indicates « Lig. bifurcatum»:

- 4,5
- 10,12
- 8,13
- + 14,15
- 16, 17

512. Which joint is indicated by №18?

- + Articulatio talocruralis
- Articulatio subtalaris
- Articulatio tarsi transversa
- Articulatio talocalcaneonavicularis
- Articulatio calcaneocuboidea
- Articulatio cuneonavicularis
- Articulationes intercuneiformes
- Articulationes tarsometatarsales
- Articulationes metatarsophalangeae
- Articulationes interphalangeae pedis



513. Find the correct number from the picture which indicates « Lig. capitis fibulae anterior»

Answer: 3.

514. Find the correct number from the picture which indicates « Lig. collaterale fibulare»

Answer: 4.

515. Find the correct number from the picture which indicates « Retinaculum patellae laterale»

Answer: 5.

516. Find the correct number from the picture which indicates « Retinaculum patellae mediale»

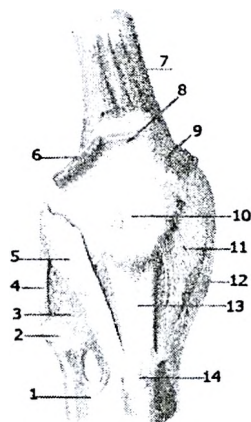
Answer: 11.

517. Find the correct number from the picture which indicates « Lig. collaterale tibiale»

Answer: 12.

518. Find the correct number from the picture which indicates « Lig. patellae»

Answer: 13.



519. Which anatomical formation is indicated by №1?

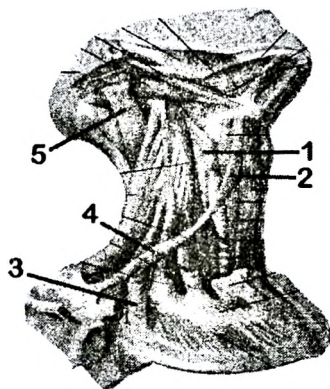
- M. constrictor pharyngis superior
- M. constrictor pharyngis medius
- + M. constrictor pharyngis inferior
- M. longus capitis
- M. longus colli

520. Which anatomical formation is indicated by №2?

- M. thyrohyoideus
- M. sternothyoideus
- M. omohyoideus venter inferior
- + M. omohyoideus venter superior
- M. sternohyoideus

521. Which anatomical formation is indicated by №3?

- M. scalenus anterior
- M. scalenus medius
- + M. scalenus posterior
- M. longus colli
- M. longus capitis



524. Which anatomical formation is indicated by №4?

- + M. scalenus anterior
- M. scalenus medius
- M. scalenus posterior
- M. longus colli
- M. longus capitis

525. Which anatomical formation is indicated by №5?

- M. longissimus cervicis
- + M. longissimus capitis
- M. spinalis cervicis
- M. splenius capitis
- M. longus capitis

---

526. Which anatomical formation is indicated by №1?

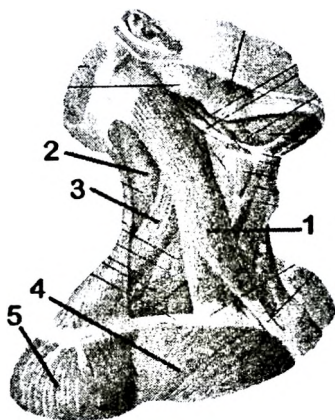
- M. longissimus cervicis
- M. longissimus capitis
- M. spinalis cervicis
- M. splenius capitis
- + M. sternocleidomastoideus

527. Which anatomical formation is indicated by №2?

- M. longissimus cervicis
- M. longissimus capitis
- M. spinalis cervicis
- + M. splenius capitis
- M. sternocleidomastoideus

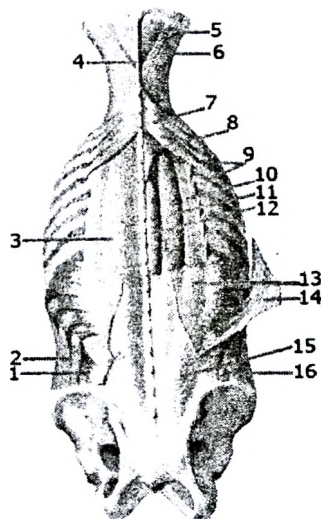
528. Which anatomical formation is indicated by №3?

- M. longissimus cervicis
- M. longissimus capitis
- M. spinalis cervicis
- + M. levator scapulae
- M. sternocleidomastoideus



529. Which anatomical formation is indicated by №8?

- M. serratus posterior inferior
- M. serratus posterior superior
- M. iliocostalis
- M. erector spinae
- M. longissimus capitis
- + M. splenius cervicis

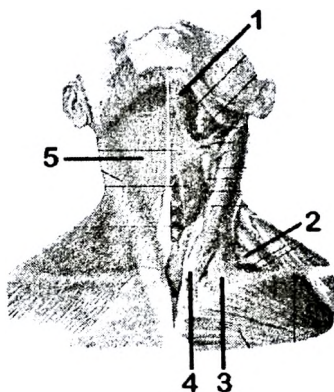


530. Which anatomical formation is indicated by №1?

- + M. digastricus venter anterior
- M. digastricus venter posterior
- Platysma
- M. levator scapulae
- M. sternocleidomastoideus

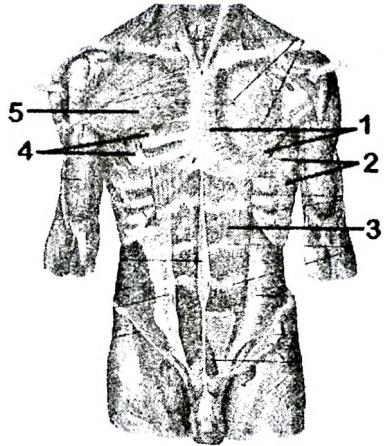
531. Which anatomical formation is indicated by №5?

- M. digastricus venter anterior
- M. digastricus venter posterior
- + Platysma
- M. levator scapulae
- M. sternocleidomastoideus



532. Which anatomical formation is indicated by №1?

- M. pectoralis minor
- + M. pectoralis major
- M. serratus anterior
- M. rectus abdominis
- M. serratus posterior superior



533. Which anatomical formation is indicated by №2?

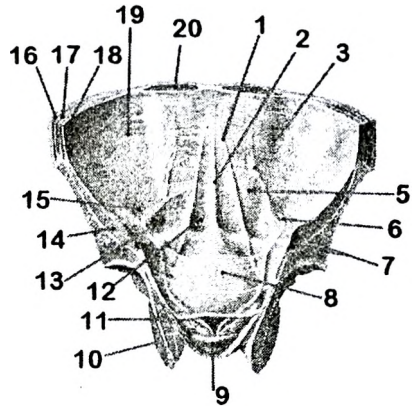
- M. pectoralis minor
- M. pectoralis major
- + M. serratus anterior
- M. rectus abdominis
- M. serratus posterior superior

534. Which anatomical formation is indicated by №3?

- M. pectoralis minor
- M. pectoralis major
- M. serratus anterior
- + M. rectus abdominis
- M. serratus posterior superior

535. Which anatomical formation is indicated by №1?

- Fossa inguinalis medialis
- + Plica umbilicalis medialis
- Plica umbilicalis lateralis
- Fossa inguinalis lateralis
- Plica umbilicalis mediana

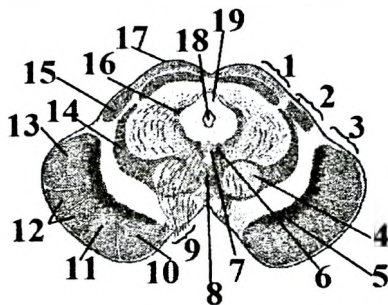


536. Which anatomical formation is indicated by №13?

- + Fossa inguinalis medialis
- Plica umbilicalis medialis
- Plica umbilicalis lateralis
- Fossa inguinalis lateralis
- Plica umbilicalis mediana

537. Which anatomical formation is indicated by №12?

- + Fibrae corticospinales
- Fibrae corticonucleares
- Fibrae corticopontinae
- Fibrae pontis transversae
- Fibrae pontis longitudinales



538. Which anatomical formation is indicated by №10?

- Fibrae corticospinales
- Fibrae corticonucleares
- + Fibrae corticopontinae
- Fibrae pontis transversae
- Fibrae pontis longitudinales

539. Which anatomical formation is indicated by №1?

- M. abductor digiti minimi
- M. flexor digiti minimi brevis
- + M. opponens digiti minimi
- Mm. interossei palmares
- Mm. lumbricales

540. Which anatomical formation is indicated by №2?

- M. opponens pollicis
- M. adductor pollicis caput obliquum
- M. flexor pollicis brevis caput superficiale
- M. flexor pollicis brevis caput profundum
- + M. adductor pollicis caput transversum

541. Which anatomical formation is indicated by №3?

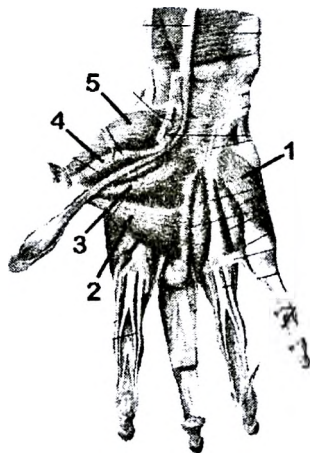
- M. opponens pollicis
- + M. adductor pollicis caput obliquum
- M. flexor pollicis brevis caput superficiale
- M. flexor pollicis brevis caput profundum
- M. adductor pollicis caput transversum

542. Which anatomical formation is indicated by №4?

- M. opponens pollicis
- M. adductor pollicis caput obliquum
- + M. flexor pollicis brevis caput superficiale
- M. flexor pollicis brevis caput profundum
- M. adductor pollicis caput transversum

543. Which anatomical formation is indicated by №5?

- + M. opponens pollicis
- M. adductor pollicis caput obliquum
- M. flexor pollicis brevis caput superficiale
- M. flexor pollicis brevis caput profundum
- M. adductor pollicis caput transversum





544. Which anatomical formation is indicated by №1?

- M. psoas major
- M. iliopsoas
- M. piriformis
- + M. pectineus
- M. adductor longus

545. Which anatomical formation is indicated by №2?

- M. psoas major
- M. iliopsoas
- M. piriformis
- M. pectineus
- + M. adductor longus

546. Which anatomical formation is indicated by №3?

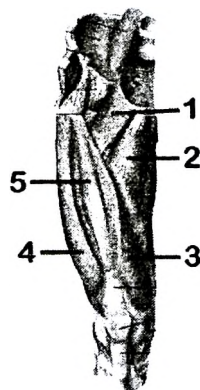
- M. rectus femoris
- M. vastus lateralis
- M. vastus intermedius
- + M. vastus medialis
- M. tensor fasciae latae

547. Which anatomical formation is indicated by №4?

- M. rectus femoris
- + M. vastus lateralis
- M. vastus intermedius
- M. vastus medialis
- M. tensor fasciae latae

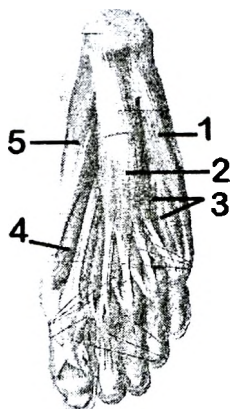
548. Which anatomical formation is indicated by №5?

- M. rectus femoris
- M. vastus lateralis
- + M. vastus intermedius
- M. vastus medialis
- M. tensor fasciae latae



549. Which anatomical formation is indicated by №1?

- + M. abductor digiti minimi
- M. flexor digitorum brevis
- M. quadratus plantae
- M. flexor hallucis brevis
- M. abductor hallucis



550. Which anatomical formation is indicated by №2?

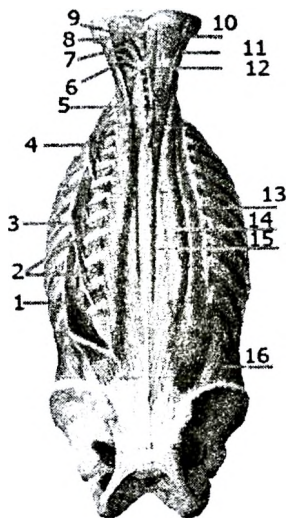
- M. abductor digiti minimi
- + M. flexor digitorum brevis
- M. quadratus plantae
- M. flexor hallucis brevis
- M. abductor hallucis

551. Which anatomical formation is indicated by №5?

- M. abductor digiti minimi
- M. flexor digitorum brevis
- M. quadratus plantae
- M. flexor hallucis brevis
- + M. abductor hallucis

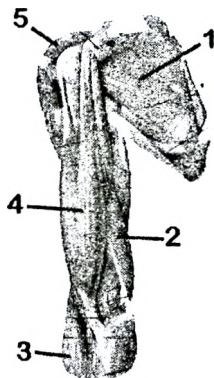
552. Find the correct number from the picture which indicate « M. semispinalis capitis:

Answer: 10.



553. Which anatomical formation is indicated by №1?

- + M. subscapularis
- M. brachialis
- M. coracobrachialis
- M. brachioradialis
- M. biceps brachii



554. Which anatomical formation is indicated by №2?

- M. subscapularis
- + M. triceps brachii
- M. coracobrachialis
- M. brachioradialis
- M. biceps brachii

555. Which anatomical formation is indicated by №3?

- M. subscapularis
- M. triceps brachii
- M. coracobrachialis
- + M. brachioradialis
- M. biceps brachii

556. Which anatomical formation is indicated by №4?

- M. subscapularis
- M. triceps brachii
- M. coracobrachialis
- M. brachioradialis
- + M. biceps brachii

557. Find the correct number from the picture which indicate « sinus venosus sclera (schlemm's canal):

Answer - 2

558. Find the correct number from the picture which indicate « fovea centralis»:

Answer - 3

559. Find the correct number from the picture which indicate « vagina bulbi (tenon's capsule)»:

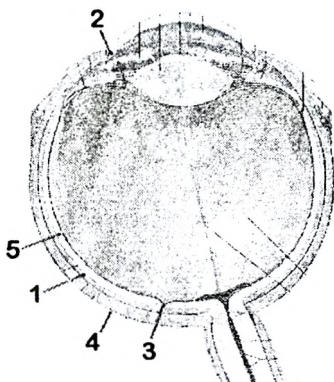
Answer - 4

560. Find the correct number from the picture which indicate « pars optica retinae»:

Answer - 5

561. Find the correct number from the picture which indicate « choroidea»:

Answer - 1



562. Find the correct number from the picture which indicate « a. ciliaris posterior longa»:

Answer – 2

563. Find the correct number from the picture which indicate « a centralis retinae»:

Answer – 3

564. Find the correct number from the picture which indicate « angulus iridocornealis»:

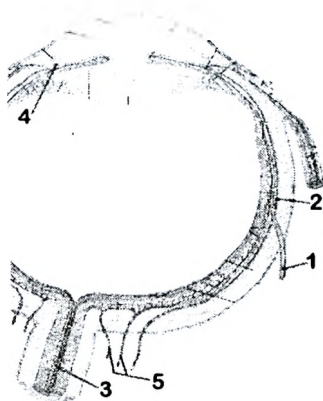
Answer – 4

565. Find the correct number from the picture which indicate « a. ciliaris posterior breves»:

Answer – 5

566. Find the correct number from the picture which indicates « v. vorticosa»:

Answer – 1



567. Find the correct number from the picture which indicates « glandula lacrimalis»:

Answer – 5

568. Find the correct number from the picture which indicates « ductuli excretorii glandulae lacrimalis»:

Answer – 4

569. Find the correct number from the picture which indicates « canaliculi lacrimales»:

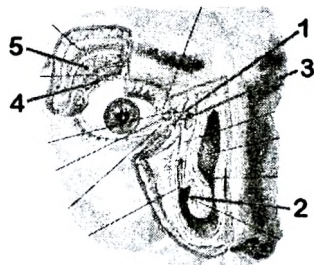
Answer – 1

570. Find the correct number from the picture which indicates « saccus lacrimalis»:

Answer – 3

571. Find the correct number from the picture which indicates « meatus nasi inferior»:

Answer – 2



572. Find the correct number from the picture which indicate « spatia anguli iridis»

Answer – 5

573. Find the correct number from the picture which indicates « capsula lentis»:

Answer – 1

573. Find the correct number from the picture which indicates« m. ciliaris»:

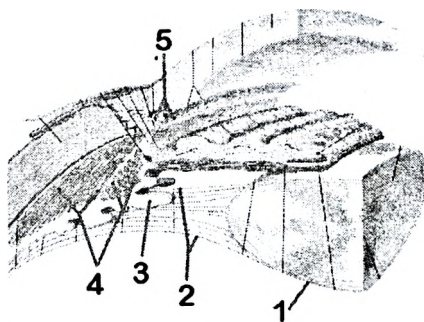
Answer – 4

574. Find the correct number from the picture which indicates « fibrae zonulares»:

Answer – 2

575. Find the correct number from the picture which indicates « processus ciliaris»:

Answer – 3



576. Find the correct number from the picture which indicates « fossa triangularis»:

Answer – 5

577. Find the correct number from the picture which indicate « helix»:

Answer – 2

578. Find the correct number from the picture which indicates « antitragus»:

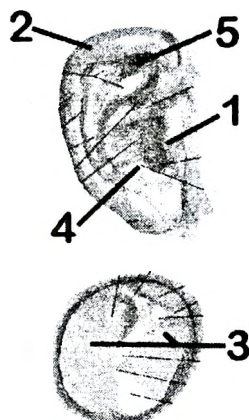
Answer – 4

579. Find the correct number from the picture which indicates « tragus»:

Answer – 1

580. Find the correct number from the picture which indicatess« pars tensa»:

Answer – 3



581. Find the correct number from the picture which indicates « canalis semicircularis anterior»:

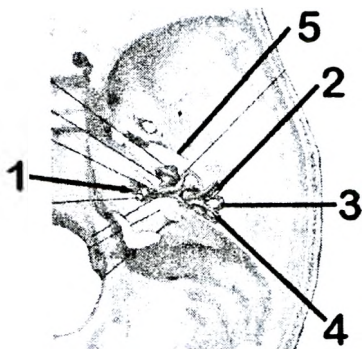
Answer – 2

582. Find the correct number from the picture which indicates « canalis semicircularis posterior» №:

Answer – 4

583. Find the correct number from the picture which indicates « canalis semicircularis lateralis»:

Answer – 3



584. Find the correct number from the picture which indicates « sulcus nervi petrosi majoris»:

Answer – 5

585. Find the correct number from the picture which indicates « porus acusticus internus»:

Answer – 1

586. Find the correct number from the picture which indicates « cupula cochleae»:

Answer – 2

587. Find the correct number from the picture which indicate « vestibulum»:

Answer – 4

588. Find the correct number from the picture which indicates « cochleae»:

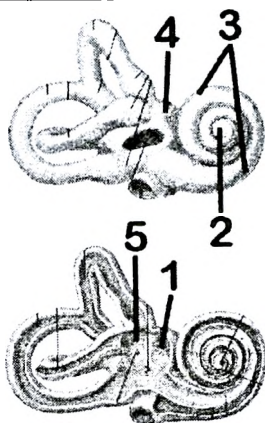
Answer – 3

589. Find the correct number from the picture which indicates « recessus ellipticus»:

Answer – 5

590. Find the correct number from the picture which indicates « recessus sphericus»:

Answer – 1



591. Find the correct number from the picture which indicates « a. carotis intern»:

Answer – 2

592. Find the correct number from the picture which indicate « m. tensoris tympani»:

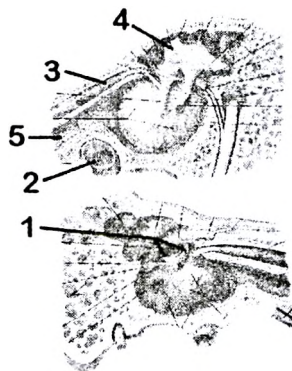
Answer – 3

593. Find the correct number from the picture which indicate « tuba auditiva»:

Answer – 5

594. Find the correct number from the picture which indicate « caput mallei»:

Answer – 4



---

595. Find the correct number from the picture which indicate « scala vestibule»:

Answer – 3

596. Find the correct number from the picture which indicate « scala tympani»:

Answer – 5

597. Find the correct number from the picture which indicate « ductus cochlearis»:

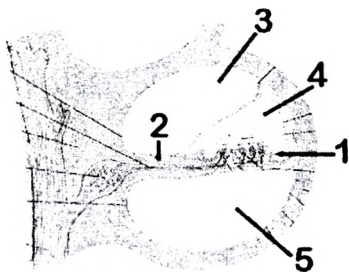
Answer – 4

598. Find the correct number from the picture which indicate « organum spirale (corti)»:

Answer – 1

599. Find the correct number from the picture which indicate « lamina spiralis ossea»:

Answer – 2



600. Find the correct number from the picture which indicate « n. auriculotemporalis» (5th cranial nerve):

Answer – 2

601. Find the correct number from the picture which indicates « n. auricularis magnus»:

Answer – 1

602. Find the correct number from the picture which indicate « n. mentalis (5th cranial nerve)»:

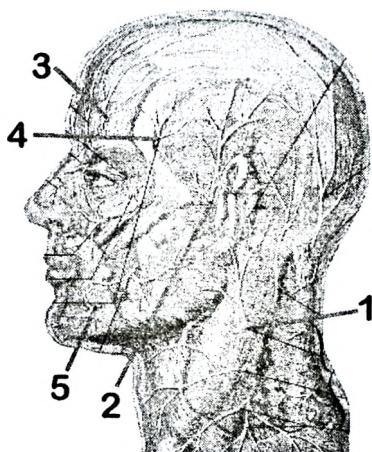
Answer – 5

603. Find the correct number from the picture which indicate « n. supraorbitalis (5th cranial nerve)»:

Answer – 3

604. Find the correct number from the picture which indicate « n. zygomaticotemporalis (5th cranial nerve)»:

Answer – 4



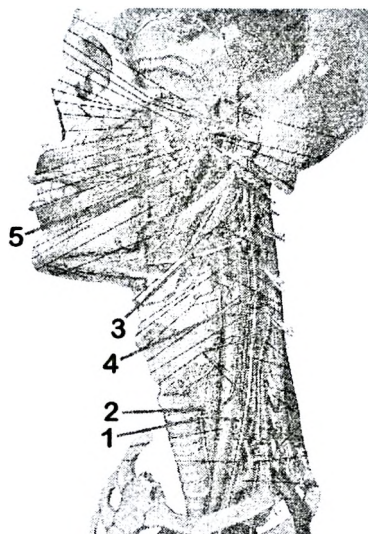
---

605. Find the correct number from the picture which indicate « n. hypoglossus (XII th cranial nerve)»:

Answer – 3

606. Find the correct number from the picture which indicate « n. alveolaris inferior (V th cranial nerve)»:

Answer – 5





## **V. List of the questions, which have been included in the examination cards for carrying out of the state examination on human anatomy for a speciality 1790101 (general medicine)**

### **Section I. General theoretical questions**

1. Subject and contents of anatomy. Place of anatomy in a number of biological disciplines. Modern methods and principles of anatomical research (investigations).
2. Anatomy and clinic. Significance of anatomical knowledge for the comprehension of mechanisms of development of diseases, their diagnostics, treatment and prevention.
3. Personal variability of organs. Variants of the norm and abnormalities of the structure of organs and organism as a whole. Types of body Constitution.
4. Early stages of the human embryonic development. Germinal layers and their derivatives.
5. Anatomy in Belarus. Golub and his school. Scientific course of investigations for Belorussian anatomists.

### **Section II. Anatomy of locomotor apparatus**

1. Bone as an organ: development, structure, and growth. Classification of bones. Types of ossification.
2. Chemical composition and physical properties of bone.
3. Development of the axial skeleton during ontogenesis. Vertebral column as a whole. Variants of structure and abnormalities.
4. Development of the upper limb during ontogenesis. Variants of structure and abnormalities of development.  
Upper limb as an organ of labour.
5. Development of the lower limb during ontogenesis. Variants of structure and developmental anomalies of lower limb as an organ of locomotor system.
6. Development of the skull during ontogenesis. Visceral arches and their derivatives. Age, sex and personal features of the skull.
7. Anatomical and biomechanical classification of the junctions between bones.
8. Structure of the joint, its main and accessory elements. Classification of joints according to their structure, shape of articulating surfaces and function (action).
9. Skeletal muscle as an organ. Development, classification, functions of skeletal muscles. The accessory apparatus of muscles.
10. Action of muscles. An osteo-muscular system as a system of levers of the I<sup>st</sup> and II<sup>nd</sup> types.
11. The vertebrae: structure of different parts of vertebrae in the vertebral column. Joints between vertebrae, blood supply and nerve supply.
12. Vertebral column as a whole: parts, structure, spinal curvatures, and movement. Muscles, which make movement of the vertebral column, its blood supply and innervation.
13. Anatomy of the breast bone (sternum) and ribs. Articulations between the ribs and the breast bone, costovertebral joints. Muscles, which make movement of the ribs, its blood and nerve supply.
14. Thoracic cage as a whole: structure, its individual and typological features, functions.
15. Joints between the vertebral column and the skull. Muscles that make movement of

the head, its blood supply and innervations.

16. The structure of bones of neurocranium: (occipital, frontal, parietal and ethmoid bone, blood supply and nerve supply.

17. Cranial suturae.

18. The sphenoid bone: structure, foramina (openings) and its contents.

19. The temporal bone: structure, canals and its contents. Blood supply and nerve supply of temporal bone.

20. The anatomy bones of the visceral cranium: development, structure, blood supply and innervation

21. The external surface of the base of the skull (basis cranii externa): structure, opening and their contents. Temporal and infratemporal fossa, and its contents.

22. The internal surface of the base of the skull (basis cranii interna): structure, foramina and its contents.

23. Anatomy of the nose and paranasal sinuses: structure, functions, blood supply and nerve supply.

24. The orbits: structure, openings and its contents.

25. The pterygopalatine fossa: structure, openings and contents.

26. Joints between the bones of skull. The temporomandibular joint: structure, shape and movement. Anatomy.

27. Anatomy of bones of the shoulder girdle, joints, blood supply and innervations. Peculiarities structure of bones the shoulder girdle.

28. Anatomy of the shoulder and forearm bones, its blood supply and nerve supply.

29. Anatomy of bones of the hand, its blood supply and nerve supply.

30. The shoulder joint: structure, shape and movement. Anatomy of muscles, which make movement of the shoulder joint, blood supply and nerve supply.

31. Elbow joint: structure, shape, and movement. Anatomy of muscles, which make movement of the elbow joint, blood and nerve supply.

32. Articulations of bones of forearm: structure, shape and movement. Muscles which make movement in this joint, blood supply and innervations.

33. Radiocarpal joint: structure, shape, and movement. Muscles, which make movement in this joint, blood supply and nerve supply.

34. Joints of the hand bones: structure, shape, and movement. Muscles, which make movement in this joint, its blood supply and nerve supply.

35. The hand as a whole: structure, parts and hard foundation of the hand, joints of the hand. Particular features of the hand, as an organ of labour.

36. Anatomy of the topographical structures of the pelvis, their contents.

37. Anatomy of bones of the femur and leg, its blood supply and nerve supply.

38. Anatomy of bones of the foot. Blood supply and nerve supply.

39. Anatomy of the hip bones. Pelvis as a whole. Features of the female pelvis and its measurements.

40. Hip joint: structure, shape, movement. Anatomy of muscles, which make motion in hip joint, their blood supply and innervation.

41. The knee joint: structure, shape and movement. Muscles, which produce movement in this joint, its blood supply and nerve supply.

42. The ankle joint: structure, shape, and movement. Muscles, which produce movement in this joint, blood supply and nerve supply.

43. Joints of foot: structure, shape and movement. Muscles which produce movement in the joint of foot, blood supply and nerve supply.
44. Foot as a whole: parts, bony structure of the foot. Arches of the foot and mechanisms of their strengthening. Surgical articulations of the foot.
45. The comparative characteristic of the skeleton, joints and muscles of the upper and lower limbs.
46. Muscles of facial expression: structure, functions, blood supply and nerve supply.
47. Muscles of mastication: structure, function, fascias, blood supply and nerve supply.
48. Muscles of the neck: group and individual characteristic, functions, blood supply, innervation
49. Topography and fascias of the neck. The interfascial spaces of the neck, their clinical value
50. Muscles and fascias of the chest: topography, structure, functions, blood supply and innervation.
51. Diaphragm as an organ: structure, parts, functions, foramens and its contents. Blood supply, innervation of the diaphragm.
52. Muscles of the abdomen: classification, structure, functions, blood supply and innervation.
53. Abdominal prelum: anatomy and functions. White line of the abdomen. The sheath of the rectus abdominis muscle.
54. The inguinal canal: topography, walls, foramens and its contents. Weak places of the abdominal wall.
55. Muscles and fascias of the shoulder girdle: structure, functions, blood supply, innervation.
56. Muscles and fascias of the shoulder: structure, functions, blood supply, innervation. Grooves of the shoulder and its contents.
57. Muscles and fascias of the forearm: structure, functions, blood supply and innervation. Grooves of the forearm and its contents.
58. Muscles of the manus: classification, functions, blood supply, innervation.
59. Anatomy of the axillary region: fossa, cavity, foramens and triangles. The humero-muscular canal and its contents.
60. Osteo-fibrous canals and sinovial vaginae (tendon sheaths) of the foot, their contents.
61. Muscles and fascias of the shoulder girdle: structure, functions, blood supply, innervations.
62. Muscles of the femur: classification, structure, functions, blood supply, innervation.
63. Muscles of the leg: classification, structure, functions, blood supply, innervation.
64. Muscles of foot: classification, structure, functions, blood supply, innervation.
65. Anatomy of the pelvis' topographic formations, their contents.
66. Femoral canal: topography, walls, foramens and clinical value. Anatomy of the subcutaneous fissure, its clinical value
67. Anatomy of the topographical structures of the femur: lacunas, grooves (sulci), femoro-popliteus canal, their contents.
68. Anatomy and contents of the popliteal fossa. Topographical structures of the leg

and their contents.

69. Osteo-fibrous canals and synovial vaginae (tendon sheaths) of the hand and its contents.

70. The pelvic diaphragm: structure, functions, blood supply, innervation. An ischio-rectal fossa and its contents.

71. Pelvic diaphragm: structure, functions, blood supply, innervation.

### **Section III. Anatomy of internal organ**

#### ***1. Digestive system***

1. General anatomical and functional characteristic of alimentary system

2. Development of the oral cavity and its derivatives in the ontogenesis, anomalies.

3. Derivatives of the primitive alimentary canal in the ontogenesis, anomalies.

4. Transformation of ventral and dorsal mesenteries of the embryo in the ontogenesis, anatomy its derivatives.

5. Structures of the wall of hollow organs. Functional anatomy of its layer

6. Serous cavities (general characteristic). Relation of serous membranes to organs.

7. The oral cavity: parts, wall. Anomalies of lips and gums: structure, blood supply and nerve supply

8. The palate: development, parts, structure, functions, blood supply, innervation.

9. The tongue: structure, functions, blood supply, nerve supply, and regional lymph nodes.

10. Teeth (deciduous and permanent): structure, dentition and its formula, blood supply and nerve supply of the teeth.

11. The parotid gland: topography, structure, blood supply, nerve supply, and regional lymph nodes.

12. Submandibular and sublingual salivary glands: topography, structure, blood supply, nerve supply, and regional lymph nodes.

13. The pharynx: topography, structure, functions, blood supply, nerve supply, and regional lymph nodes.

14. The oesophagus: topography, structure, blood supply, and nerve supply and lymph drainage.

15. The stomach: development, structure, topography, functions, blood supply, nerve supply, its regional lymph nodes and radioanatomy.

16. The duodenum: structure, topography, functions, blood supply, nerve supply, regional lymph nodes, radioanatomy.

17. The jejunum and ileum: topography, structure, functions, blood supply, nerve supply, and regional lymph nodes.

18. General anatomical and functional characteristic of the intestine. Different between small and large intestine.

19. General anatomical and functional characteristic of large intestine: parts, their holotomy, and relation to peritoneum, blood supply, nerve supply, and regional lymph nodes.

20. The caecum and appendix: topography, structure, functions, blood supply, nerve supply, and lymph nodes.

21. The rectum: development, topography, structure, functions, blood supply, nerve supply, lymph nodes.

22. The colon: topography, structure, blood supply, innervations, regional lymph nodes.

23. The liver: structure, topography, functions, blood supply, innervations and lymph nodes.
24. The gall bladder: topography, structure, functions, blood supply, innervations and regional lymph nodes.
25. The pancreas: structure, topography, functions, blood supply, innervation and lymph nodes.
26. Topography of the peritoneum of the upper storey (level) of the peritoneal cavity. Lesser omentum and its contents.
27. Topography of the peritoneum of the lower storey (level) of the peritoneal cavity. Greater omentum.
28. Anatomy of the peritoneum in the cavity of small pelvis. Relation of organs of lesser pelvis to peritoneum.
29. Anatomy of the derivatives of the peritoneum: omentum, mesentery, ligaments, and folds of the peritoneum, retroperitoneal recesses.

### **2. Respiratory system**

30. General anatomical and functional characteristic of the respiratory system.
31. Development of organs of the respiratory system in the ontogenesis. Structural variants and anomalies.
32. Nasal cavity: development, structure, connections, functions, blood supply, innervation.
33. Larynx: topography, anatomy of cartilages and joints of the larynx. Blood supply, innervation, regional lymph nodes of the cavity of the larynx.
34. Muscles of the larynx: structure, functions, blood supply, innervation, regional lymph nodes.
35. The trachea: development, topography, structure, blood supply, innervation, regional lymph nodes.
36. The bronchial tree (bronchial arbor): structure, functions, blood supply, innervation, radioanatomy.
37. Lungs: structure, topography, blood supply, innervations, regional lymph nodes. Segments of the lungs.
38. The bronchial tree (bronchial arbor): structure, functions, blood supply, innervation, radioanatomy.
39. The pleura: departments, borders(limit), cavity and recesses of a pleura. A blood supply and innervation of the pleura.
40. Mediastinum: parts, organs of the mediastinum.

### **3. Urinary organs**

41. General anatomical and functional characteristic of the urinary system.
42. Development of urinary organs in the ontogenesis. Structural variants and anomalies.
43. Kidneys: development, topography, structure, coverings, fixing apparatus of the kidney. Abnormalities of structure and topography of kidneys.
44. Features of blood circulation in the kidney. Segments of the kidney. The structure and functions of the nephron.
45. The urinary tract: development, structure, blood supply, innervation, regional lymph nodes. Abnormalities of development and variants of normal development.

46. The urinary bladder: development, topography, structure, functions, blood supply, innervation, lymph nodes. Congenital anomalies.
47. The urethra: development, topography and structure, functions, blood supply, innervation. Abnormalities of development.
48. The ureter: development, topography, structure, blood supply, innervation, regional lymph nodes. Abnormalities of development
49. The female urethra: development, topography, opening, structure, blood supply, nerve supply.

#### ***4. Male Genital Organs***

50. General anatomical and functional characteristic of the male genital organs.
51. The development of male genital organs in the ontogenesis. Structural variants and anomalies.
52. Testis: development, topography, structure, functions, blood supply, innervation, regional lymph nodes. Abnormalities of development
53. The epididymis: development, topography, structure, functions, blood supply, innervation, regional lymph nodes.
54. Ductus deferens: development, structure, parts, functions, blood supply, innervation.
55. Anatomy and functions of the ejaculatory duct. Its development and abnormalities
56. Prostate: topography, structure, functions, blood supply, innervation, regional lymph nodes
57. Coverings of the testis, their origin. Anatomy of the scrotum, formation of its coverings
58. External male genital organs: development, structure, functions, blood supply, innervation, regional lymph nodes.
59. Seminal vesicles and bulbourethral glands: topography, structure, functions, blood supply, innervation, and regional lymph nodes.

#### ***5. Female Genital Organs***

60. General anatomical and functional characteristic of the female genital organs.
61. The development of the female genital organs in the ontogenesis. Structural variants and anomalies.
62. Ovary: development, topography, structure, ligaments, functions, blood supply, innervation and regional lymph nodes.
63. Uterus: development, structure, functions, blood supply, innervation and regional lymph nodes. Abnormalities of development.
64. Topography and ligaments of the uterus.
65. Uterine tube: development, parts, structure, functions, blood supply, innervation and regional lymph nodes. Abnormalities of development.
66. Vagina: development, structure, topography, blood supply, innervation, regional lymph nodes. Abnormalities of development.
67. Female external genital organs: development, structure, functions, blood supply, innervation and regional lymph nodes.

#### ***6. Endocrine Glands***

68. Classification of endocrine glands. Particular features, morphology and functions of

endocrine glands

69. Thyroid gland: development, topography, structure, functions, blood supply, innervation regional lymph nodes

70. Parathyroid glands: development, topography, structure, functions, blood supply, nerve supply, and lymph nodes.

71. Hypophysis cerebri: development, topography, structure, function, peculiarities feature of blood supply, innervation

72. Suprarenal glands: development, topography, structure, functions, blood supply, nerve supply, lymph nodes

73. Adrenal group of glands: medulla of the suprarenal glands, accessory supra renal gland. Their development, structure, topography

#### **Section IV. The Cardiovascular System**

1. General anatomic-functional characteristic of the cardiovascular system. Circles of blood circulation. Parts of the microcirculatory bed and their functions.

2. Blood vessels. Rules of distribution and branching of arteries and veins. Collateral blood circulation.

3. Foetus blood circulation and its changes after birth.

4. Development of the heart during ontogenesis. Congenital defects of the heart.

5. Development of arteries during ontogenesis. Variants of structure and abnormalities of development.

6. Development of veins during ontogenesis. Variants of structure and abnormalities of development

7. General anatomic-functional characteristic of lymphatic drainage

8. Lymph nodes: classification, structure, functions. Concept of a regional lymph outflow.

9. General anatomic-functional characteristic of lymphoid tissue

10. The heart: structure, topography.

11. Structure of walls of the heart. Pericardial sac. Blood supply, innervation of the pericardium

12. Arteries of the heart, areas of their blood supply. Veins of the heart, lymphatic vessels and regional lymph nodes.

13. Valves of the heart: structure, function. Places of projection and auscultation of the valves

14. Innervation of the heart. Conductive system of the heart and its functional value.

15. Anatomy of lesser circulation, vessels and its functional value.

16. Aorta: parts, topography.

17. Branches of the arch of the aorta and thoracic part of the aorta descendens.

18. Common carotid artery, region of blood supply. Structure and topography of the neurovascular fascicle of the neck.

19. Anatomy and areas of blood supply of (anterior, posterior and middle) branches of the external carotid artery.

20. Terminal branches of the external carotid artery: topography, their branches and areas of blood supply.

21. Internal carotid artery: topography, parts, branches and areas of blood supply.

22. Subclavian artery: topography, parts, their branches and areas of blood supply.

23. Vertebral artery. Anatomy of the arterial circle of the brain. Blood supply of the brain and spinal cord.
  24. Ophthalmic artery: topography, branches, areas of blood supply. Anastomoses between branches of the external and internal carotid arteries
  25. Anatomies of vessels, which blood supply the walls of the thoracic cavity.
  26. Axillary artery: topography, branches, and area of blood supply. Arteries, which take part in anastomosis around the shoulder joint.
  27. Brachial artery: topography, branches, and area of blood supply.
  28. Ulnar artery: topography, branches, areas of blood supply. Anatomy of the arterial network of the elbow joint
  29. Radial artery: topography, branches, areas of a blood supply
  30. Arches and arterios of the hand: formation, branches, areas of a blood supply.
  31. Arteries of the dorsal surface of hand. Blood supply of the radiocarpal joint and joints between carpal bones
  32. Abdominal aorta: topography, general anatomy of its branches. Anastomosis between the proper branches of abdominal aorta.
  33. Parietal branches of abdominal aorta. Blood supply of the walls of abdominal cavity
  34. Paired visceral branches of the abdominal aorta and areas of their blood supply.
  35. Celiac artery: topography, branches, and areas of a blood supply, anastomosis.
  36. Mesenteric arteries: topography, branches, areas of blood supply, anastomosis.
  37. Common and external iliac arteries. Anatomy of anatomises between branches of thoracic and abdominal aorta.
  38. Internal iliac artery: topography, branches, area of blood supply.
  39. Femoral and the popliteal arteries: topography, branches, area of blood supply.
- Vascular network of the knee joint.
40. Posterior tibial artery: topography, branches, and area of blood supply
  41. Anterior tibial artery: topography, branches, and area of blood supply.
  42. Dorsalis pedis artery: topography, branches, and areas of blood supply. Blood supply of talocrural joint.
  43. Plantar arteries, branches and area of blood supply.
  44. Superior vena cava: topography, inflows. Vena azygos and vena hemiazygos, its anatomises with vena cava inferior and portal veins
  45. Internal jugular vein: topography, inflows. Blood outflow from the brain, the meninges of the brain, skull bones, organs of vision, auditory and equilibrium.
  46. Veins of the upper extremity: groups, topography, areas of blood outflow.
  47. Inferior vena cava: topography, inflows.
  48. Venous plexuses and veins of the pelvis: topography, areas of blood outflow, anastomoses with the inflows of the portal vein.
  49. Subcutaneous veins of the lower extremity: topography, inflows, variant of localization.
  50. Deep veins of the lower extremity: topography, and areas of blood draining.
  51. Portal vein: formation, topography, features of the structure, areas of blood outflow.
  52. Porto-caval and cava-caval anastomoses: topography, formation, functional role.
  53. Porto-cava-caval anastomoses: topography, formation and functional value.
  54. Lymphatic ducts: formation, topography, and area of lymph drainage.



55. Structural and functional features of lymph capillaries and lymphatic vessels. Classification of lymphatic vessels.
56. Lymphatic vessels, trunks and lymph nodes of head and neck.
57. Lymphatic vessels, trunks and lymph nodes of thoracic cavity
58. Lymphatic vessels, trunks and lymph nodes of Upper extremity. .
59. Lymph vessels and regional lymph nodes of abdominal cavity
60. Lymphatic vessels and regional lymph nodes of the pelvis
61. Lymphatic vessels, trunks and regional lymph nodes of the lower extremity.
62. Lymph and blood outflow from the mammary gland, its regional lymph nodes
63. Lymph and blood outflow from the stomach, its regional lymph nodes.
64. Blood and lymph outflow from the parts of intestine, its regional lymph nodes
65. Blood and lymph outflow from the lungs, their regional lymph nodes.
66. Tonsils of the pharynx: topography, structure, blood supply, innervation..
67. Thymus: topography, structure, functions, blood supply, innervation.
68. Secondary organs of peripheral lymphoid system: topography, general features of structure, functions.
68. Spleen: topography, structure, functions, blood supply, nerve supply.

### **Section V. The nervous system and the sensory organs**

1. Nervous system and its value in the organism. Classification of nervous system and relation of its parts.
2. Early stages of development of the nervous system. Development of the brain and spinal cord in ontogenesis.
3. Reflex. Somatic and vegetative reflex arcs: the structure, functions, features. The characteristic of receptors.
4. Total characteristic of analyzers. I. P. Pavlov's doctrine about functions of dynamic localization in the cortex of the cerebrum.
5. Functional anatomy of central part of segmental department of vegetative nervous system.
6. Morphology and function of peripheral part of vegetative nervous system.
7. Morphological and functional differences between vegetative and somatic nervous system, parasympathetic and sympathetic
8. General characteristic of vegetative plexuses. Classification of vegetative plexuses
9. General anatomical and functional characteristic of peripheral part of the somatic nervous system.
10. General anatomical and functional characteristic of the cranial nerves.
11. General anatomical and functional characteristic of the visual analyzer.
12. General anatomical and functional characteristic of the auditory analyzer.
13. General anatomical and functional characteristic of the vestibular analyzer.
14. General characteristic of conductive pathway of spinal cord and brain: the embryogenesis, functions, classification.
15. Anatomy and functions of ventricular system, cerebrospinal fluid, development.

#### ***1. Central nervous system***

16. Spinal cord: development, topography, and external structure. Spinal nerves: formation, ganglia, roots, branches.

17. Spinal nerve formation: root, ganglion, branches.
18. Topography of the gray matter of the spinal cord. Meninges and intermeningeal spaces of the spinal cord
19. Localization of conductive pathway in white mater of spinal cord, its formation and functional value.
20. Segmental apparatus of the spinal cord and its functions.
21. External structure of the brain. Topography of its parts
22. Medulla oblongata: external and internal structure
23. Pons: an external and internal structure.
24. Cerebellum: external and internal structure.
25. Cerebellar peduncles, structure, fibres, functional value of fascicles.
26. Projection the nuclei of cranial nerves on the dorsal surface of the brainstem, places of their exit from the brain and skull
27. Fourth ventricle and its communications.
28. Mesencephalon: parts, external and internal structure. Aqueductus mesencephali
29. Thalamic area of the diencephalon: compartments, external and internal structure, functions
30. Hypothalamus: structure, functions, feature of neurones. The third ventricle
31. Lemniscus medialis: formation, topography and functions Basal nuclei of the brain. Striopallidal system.
32. Basal nuclei of prosencephalon. striopallidal system
33. White matter of prosencephalon: the internal capsule, fornix and corpus callosum
34. Lateral ventricles. Formation and circulation of the cerebrospinal fluid.
35. Rhinencephalon. I pair of cranial nerves. The olfactory analyzer. Limbical system.
36. Sulcuses and gyruses of the supralateral surface of hemispheres and localization of functions in the cortex.
37. Sulcus and gyrus of medial and lower surfaces of hemispheres, localization of functions in the cortex
38. Membranes of the brain. The subdural and subarachnoidal spaces, contents.
39. Reticular formation: features of neurones, nuclei, conductive pathway and functions.
40. Distribution of functions in the cerebral cortex.
41. Associative, commisural and projective fibers of the telencefalon
42. Topography of the pain sense and therrprature conductive tract in the brain and spinal cord preparation, its functional value.
43. Topography of the touch and pressure conductive tract in the brain and spinal cord preparation, its functional value.
44. Topography of conductive pathway of proprioceptive sensibility of cortical direction in the brain and spinal cord preparation, its functional value.
45. Topography of conductive pathway of proprioceptive sensibility of the cerebellar direction on the cross sections of the brain and spinal cord, their functions
46. Topography of pyramidal pathway on the cross sections of the brain and spinal cord, their functions
47. Extrapyramidal system: structure, conductive pathways, functions.

## ***2. Peripheral nervous system***

48. III, IV, VI cranial nerves: nuclei, places of an exit, areas of innervation.
49. Trigeminal nerve: nuclei, branches, places of exit, areas of innervation
50. The facial nerve: nuclei, place of exit, areas of innervations. A conductive pathway of a gustatory analyser
51. Glossopharyngeal nerve: nuclei, place of exit and areas of innervations
52. Vagus nerve: nuclei, places of exit and areas of innervation.
53. XI, XII cranial nerves: nuclei, places of exit and areas of innervation.
54. Cervical plexus: formation, topography, branches, areas of innervation
55. Brachial plexus: formation, topography, parts, short branches and areas of innervations..
56. Brachial plexus: formation, topography, parts, long branches and areas of innervations.
57. Innervation of the skin, muscles and joints of the lower extremity.
58. Intercostals nerves: topography, branches, areas of innervation. Posterior branches of the spinal nerves.
59. Lumbar plexus: formation, topography, branches, and areas of innervation.
60. Sacral plexus: formation, topography, short branches, areas of innervation.
61. Long branches of the sacral plexus: topography, area of innervations
62. Innervation of the skin, muscles and joints of the lower extremity.

## ***3. Vegetative nervous system***

63. Cervical part of the sympathetic trunk: ganglions, branches, areas of innervation
64. Thoracic part of the sympathetic trunk: topography, ganglions, branches and area of innervation.
65. Lumbar plexus: formation, topography, branches, areas of innervation
66. Plexus of abdominal aorta: division, sources of formation, ganglions, parts, area of innervation.
67. The pelvic plexus: topography, formation, parts, areas of innervation.
68. Intraorganic and extraorganic cardiac plexuses: parts, formation, function.

## ***4. Sensory Organs***

69. Fibrous and vascular coat of the eyeball. The accommodation apparatus: structure, functions, and reflex arc.
70. Retina of the eyeball. The conductive pathway of visual analyzer
71. Refractive substances of the eyeball. Aqueous humor of the eyeball: formation, contents, outflow, and functions.
72. Accessory structures of the eyeball: muscles, lacrimal apparatus, eyelids, conjunctiva, blood vessels and nerves.
73. External and middle ear: the structure, functions, blood and nerve supply.
74. Structure of the auditory part of the internal ear. Auditory pathways.
75. Vestibular apparatus. VIII pairs of cranial nerve. Vestibular pathway.
76. Anatomy of the skin and its derivatives, principles of innervation. Mammary gland, topography, structure, functions, blood and nerve supply.

## VI. Sample of examination card

### Examination card №

1. Development of skull in ontogenesis. Visceral arches and their derivative. Age, sex and individual features of the skull.
2. Muscles and fascia of forearm: structure, functions, blood supply, innervation. groove of forearm and their contents.
3. Kidney: development, topography, structure, fixing apparatus. anomalia structure and topography of the kidneys.
4. Hypothalamus: structure, function, characteristics of neurons. The third ventricle.
5. Interpretation of radiographs.
6. Solving of situational tasks.

## VII. Situational tasks for exam

1. During bleeding in the head and neck regions in an extreme situation the bleeding was temporary decreased by pressing the carotid artery to the carotid tubercle. *Where exactly is this tubercle localized?*
2. While X-ray examination the accessory ribs on both sides joined to the 1st lumbar vertebra were found. *What do we call the accessory ribs? Is it possible to have accessory ribs in other parts of the body? If yes, point out their localization. What are these ribs called?*
3. A patient complains on chronic nose-bleeds. To control the severity of these nosebleeds, his physician decides to ligate the sphenopalatine artery. *From which arteries does the sphenopalatine artery arise?*
4. A patient arrives in the emergency room after having suffered severe head trauma in a motorcycle accident. Radiographic studies of the head reveal a basilar skull fracture in the region of the foramen ovalc. *Which nerve may be damaged? Which functional losses would be related to this injury?*
5. A 52-year-old woman was admitted to the hospital with a diagnosis of right-sided pleurisy with pneumonia. It was decided to remove a sample of pleural fluid from her pleural cavity. *Where the should be inserted, close to the which border of the rib and in which line?*
6. A 25-year-old woman pregnant with her first child had been in the second stage of labor (pushing) for several hours. The crown of the child's head was just visible through the vaginal orifice, but the obstetrician was concerned that the woman was exhausted and was no longer able to push effectively. She decided to perform an episiotomy. *What is an episiotomy and when is it performed?*
7. After observing the procedure many times and numerous attempts on cadavers, you are called on to perform a subclavian catheterization on a critically ill adult patient. An infraclavicular approach on the right side is chosen. *Where is the subclavian vein located?*

8. A 31-year-old man was involved in a motorcycle accident, resulting in destruction of the groove in the lower surface of the cuboid bone. *Which muscle tendons were most likely damaged?*
9. A 32-year-old woman slipped and fell and now complains of being unable to extend her leg at the knee joint. *Which muscles were paralyzed as a result of this accident?*
10. Rupture of the ligamentum teres capitis femoris may lead to damage to a branch of which arteries?
11. Obturator nerve and sciatic (tibial portion) nerve of a 15-year-old boy are transected as a result of a motorcycle accident. *This injury would result in complete paralysis of which muscles?*
12. A patient is unable to prevent anterior displacement of the femur on the tibia when the knee is flexed. *Which ligaments are most likely damaged?*
13. A 17-year-old female has painful pimple just below the lower lip. *The pain is due to irritation of which nerve?*
14. A 46 year old male presented with wristdrop. *This is due to pathology of which nerve?*
15. Fracture of the medial epicondyle results to injury of what nerve?
16. A major vessel that can be compressed against the first rib by applying direct pressure on the supraclavicular triangle.
17. Injury to the right facial nerve just after it comes out of the stylomastoid foramen would lead to?
18. Loss of sensation in the lower lip results from lesion in?
19. A 45 year old man was diagnosed to have Bell's palsy. The patient complained of dribbling of saliva and food out of his mouth. *This finding is due to?*
20. A 45-year-old man presented with periorbital edema, headache and fever. With a history of squeezing an infected pustule on the nose a diagnosis of cavernous sinus thrombosis was made. *Infection from this area was carried by the facial vein to the cavernous sinus through which vein?*
21. After extensive surgical dissection in the posterior cervical triangle, drooping of the skin in the neck was noted postoperatively. *This is due to injury of which nerve?*
22. A 5 y/o boy with abscess of the scalp developed seizures. He was diagnosed to have meningitis. *What bridge or vein crossed by bacteria from the loose connective tissue of the scalp to the meninges?*
23. A 5 y/o girl has otitis media following infection of the nasal cavity. *This was so because of communication of the middle ear cavity and nasopharynx via which anatomical structure:*
24. A 45 year old man suffered from a gunshot wound. The bullet entered anteriorly at the angle of Louis. *If the bullet went straight backward, which vertebrae would most likely be hit?*
25. A 6 month-old boy was brought to clinic for well-baby check-up. *You would expect which cranial fontanelle to still be open?*

26. A 45-year-old patient has been given a course of antibiotics by gluteal intramuscular injections after a major abdominal surgery. *To avoid damaging the sciatic nerve during an injection, the needle should be inserted into which gluteal areas?*
27. A patient presents with sensory loss on adjacent sides of the great and second toes and impaired dorsiflexion of the foot. *These signs probably indicate damage of which nerves?*
28. A neurologic exam of a 34 year old man reveals a direct and consensual light reflex in his left eye; but neither a direct nor consensual reflex in his right eye. *What nerve is involved?*
29. 43 year old woman undergoes a radical mastectomy. "Winging" of the scapula is observed after she recovers from surgery. *Damage to which nerves is suggested by this finding?*
30. Which muscles of the hand will be paralyzed if there is a lesion of the ulnar nerve?
31. A patient suffers a fracture of the medial malleolus. A consequence of such injury is scarring & entrapment of the nerve in this area. *Which nerve is damaged?*
32. How many constrictions does ureter have?
33. A man of about 40 years comes to hospital with inability to close his left eye, tears overflowing on the left cheek and saliva dribbling from his left angle of mouth. *What nerve is damaged?*
34. A patient is undergoing abdominal surgery. Anesthetist is sitting at the head end of the table and monitoring patients pulse by palpating arteries in the head and the neck region. *What artery is the anaesthetist palpating? Name the other palpable arteries in the body?*
35. A patient of carcinoma the anterior two-thirds of tongue complains of pain in his lower teeth, temporal region and temporomandibular joint. *Why is pain of the tongue refer to lower teeth?*
36. A young man complained of fever and sore throat, noted a swelling and felt pain on both sides of his face in front of the ear. Within a few days, he noted swellings below his jaw and below his chin. *The pain increased while chewing. Physician noted enlargement of all three salivary glands? Where do the ducts of salivary gland open? Why did the pain increase while chewing?*
37. A 70-year-old man complained on vision problems and bumping into things. Examination showed loss of vision in both right visual fields. *Where could a lesion be located to cause this loss of vision?*
38. A 5-year-old child is admitted to the emergency department with severe headache, high fever, malaise and confusion. The patient suffers from meningitis. A lumbar puncture is ordered. *Which vertebral level is the most appropriate location for the lumbar puncture?*
39. A 40-year-old man suffers with severe neck pain after a whiplash injury, sustained when his car was struck from behind. Radiographic studies reveal

trauma to the ligament lying on the anterior surface of the cervical vertebral bodies. *Which ligament is this?*

40. A 47-year-old woman states that she experienced moderate pain for 2 years over her left lower back, pain that radiates to her left lower limb. Radiographic examination revealed disk herniation between vertebral levels L4 and L5. *Which nerves were most likely affected by the disk herniation?*

41. A 35-year-old male race car driver is admitted to the emergency department after a severe car crash. Radiographic studies reveal damage to the tip of the transverse process of the third cervical vertebra, with pulsating hematoma. *What artery was the most likely damage?*

42. A 32-year-old male soccer player is forced to leave the game following a head-to-head collision with another player. He is admitted to the hospital, and radiographic examination reveals slight dislocation of the atlantoaxial joint. As a result, he experiences decreased range of motion at that joint. *What movement of the head would most likely be severely affected?*

42. A 35-year-old male pedestrian is crossing a busy intersection and was hit by a truck. He is admitted to the emergency department, and a CT scan reveals a dislocation of the fourth thoracic vertebra. *Which of the following costal structures is most likely also involved in the injury?*

43. A 19-year-old patient was admitted to the emergency department with high fever, severe headache, nausea and stiff neck for 3 days. The attending physician suspects meningitis and obtains a sample of CSF using a lumbar puncture. *From which of the following spaces was the CSF collected?*

44. During surgical operation for the oblique inguinal hernia in a female, the surgeon injured the ligament located within the inguinal canal. *a) What is the name of the ligament mentioned above? b) What other ligaments of the uterus do you know?*

45. During the examination of 45 year old woman there was found gastroptosis (downward displacement of the stomach). The weakness of the ligament apparatus fixing this organ was considered to be one of the causes of gastroptosis. *Name the ligaments of the stomach.*

46. During the rectoscopy the proctologist has to remember two flexures of the rectum in the saggital plane. What do we call the flexures of the rectum? *Where are they localized?*

47. During an operation in the hepatic bursa, it is necessary to examine its walls. *What are the boundaries of the hepatic bursa?*

48. According to clinical experience foreign bodies can be found usually in the right principal bronchus than in the left one. *What is the anatomical case of this fact?*

49. What is *Waldeyer's tonsillar ring*?

50. A patient with hereditary blood clotting problems is admitted with pain in the back of her knee. An arteriogram reveals a blood clot in the popliteal artery at its proximal end. *Which arteries will allow blood to reach the foot?*

## VIII. Answers of situational tasks

1. Tuberculum caroticum is the anterior tubercle of the transverse process of the sixth cervical vertebra, against which the carotid artery may be compressed by the finger
2. Of most practical importance among variations of costal development are accessory ribs (seventh cervical and first lumbar rib); the twelfth pair of ribs as a rudimentary structure is marked by wider variability than the other ribs. Two forms of the twelfth rib are distinguished: sabre-like, with a long rib sloping downward, and stiletto-like, with a small, short rib stretching horizontally.
3. From maxillary artery
4. Mandibular nerve, Paralysis of muscles of mastication
5. Needles in the region of the thorax should be inserted near the upper border of a rib in order to avoid damage to the neurovascular bundles found below the ribs. The needle needs to be inserted below the level of the lungs, in the costodiaphragmatic recess, which would be the eighth or lower interspace. Recall that at the midclavicular line, the recess is between rib spaces 6 and 8, at the midaxillary line between 8 and 10 and at the paravertebral line between 10 and 12.
6. An episiotomy is an incision made in the perineum to enlarge the distal end of the birth canal. Episiotomies are performed in order to ease delivery, especially in difficult cases like breech and forceps deliveries.
7. The subclavian vein is found in the lower part of the omoclavicular triangle. It is the continuation of the axillary vein, beginning at the lower border of the first rib. It crosses the clavicle just medial to the midclavicular point and proceeds superiorly and arches over the first rib anterior to the anterior scalene muscle before turning posteriorly again and descending into the thorax.
8. The groove in the lower surface of the cuboid bone is occupied by the tendon of the peroneus longus muscle. The flexor hallucis longus tendon occupies a groove on the posterior surface of the body of the talus and a groove on the inferior surface of the calcaneus during its course. The tibialis posterior muscle tendon occupies the medial malleolar groove of the tibia. Other muscle tendons are not in the groove of the tarsal bones
9. The quadriceps femoris muscle includes the rectus femoris muscle and the vastus medialis, intermedialis, and lateralis muscles. They extend the leg at the knee joint. The semitendinosus, semimembranosus, and biceps femoris muscles (the hamstrings) extend the thigh and flex the leg. The sartorius and gracilis muscles can flex the thigh and the leg.
10. The obturator artery gives rise to an acetabular branch that runs in the round ligament of the head of the femur
11. The adductor magnus is innervated by both the obturator and sciatic (tibial portion) nerves. Hence, a lesion here could cause paralysis. The rectus femoris and sartorius are innervated by the femoral nerve. The biceps femoris long head



is innervated by the tibial portion of the sciatic nerve, whereas the short head is innervated by the common peroneal portion of the sciatic nerve. The pectineus is innervated by both the femoral and obturator nerves

12. The posterior cruciate ligament is important because it prevents forward displacement of the femur on the tibia when the knee is flexed. The anterior cruciate ligament prevents backward displacement of the femur on the tibia.

13. Mandibular nerve

14. Radial nerve

15. Ulnar nerve

16. Subclavian artery

17. Paralysis of the muscles of facial expression on the affected side

18. CN V3 (Mandibular nerve)

19. Inflammation of the facial nerve

20. Superior ophthalmic vein

21. Facial nerve

22. Emissary

23. Eustachian tube

24. T4 – T5 vertebrae

25. Anterior fontanelle

26. To avoid damaging the sciatic nerve during an intramuscular injection, the clinician should insert the needle in the upper lateral quadrant of the gluteal region. The inserted needle in the lower medial quadrant may damage the pudendal and sciatic nerves. The inserted needle midway between the ischial tuberosity and the lesser trochanter may damage the sciatic and posterior femoral cutaneous nerves on the quadratus femoris. The inserted needle over the sacrospinous ligament may damage the pudendal nerve and vessels.

27. The deep peroneal nerve supplies the anterior muscles of the leg, including the tibialis anterior, extensor hallucis longus, extensor digitorum longus, and peroneus tertius muscles, which dorsiflex the foot. The medial branch of the deep peroneal nerve supplies the skin of adjacent sides of the great and second toes, whereas the lateral branch supplies the extensor digitorum brevis and extensor hallucis brevis. The superficial peroneal nerve innervates the peroneus longus and brevis, which plantar flexes the foot, and supplies the skin on the side of the lower leg and the dorsum of the ankle and foot. The tibial nerve innervates the muscles of the posterior compartment that plantar flexes and supplies the skin on the heel and plantar aspect of the foot. The lateral plantar nerve innervates muscles and skin of the lateral plantar aspect of the foot. The sural nerve supplies the skin on the posterolateral aspect of the leg and the lateral aspect of the foot and the little toe.

28. Right oculomotor nerve- The pupillary light reflex is assessed by shining a light in one eye and observing pupillary constriction in the same (direct) and the other eye (consensual). The afferent limb of the reflex is the optic nerve and the efferent limb is the oculomotor nerve. Clearly the left optic and oculomotor

nerves are working because a direct response is seen in the left eye. Also, the right optic nerve is working to produce a consensual reflex in the left eye.

29. The serratus anterior muscle which holds down its attachment to the scapula is supplied by the long thoracic nerve and may be injured in breast surgery because of its location. The long thoracic nerve arises from the roots of the brachial plexus, C<sub>5</sub>, C<sub>6</sub>, and C<sub>7</sub>.

30. The intrinsic muscles of the hand are innervated by the ulnar nerve except 5 muscles (3 thenar muscles and the first 2 lumbricals) which are innervated by the median n. palmar interossei and adductor pollicis are supplied by the ulnar nerve.

31. The nerve involved here is the tibial nerve as it passes behind the medial malleolus to divide into medial and lateral plantar nerves that supply the intrinsic muscles of the foot and the skin of the sole of the foot.

32. The ureter has three constrictions. The ureteropelvic junction, where it crosses the pelvic brim because it is kinked, and at the ureterovesical junction.

33. The reason for the patients in this condition is paralysis of his left facial nerve. It is called Bell's palsy.

34. The anaesthetist has been monitoring the pulse by palpating the common carotid artery at the anterior border of sternocleidomastoid muscle. He need not get up to feel the radial pulse repeatedly. Other palpable arteries in the head and the neck are superficial temporal and facial. In upper limb palpable arteries are third part of axillary artery, brachial artery and radial pulse. In the abdomen one can feel abdominal aorta pulsation when one lies supine. Palpable arteries in the lower limb are femoral, popliteal, dorsalis pedis and posterior tibial.

35. Sensations from anterior two-thirds of the tongue are carried by lingual branches of mandibular nerves. Since there are two many pain in pulses due to diseases, these impulses course through other branches of the nerve, where it is get referred. So pain is felt to lower teeth, from where sensations are carried by inferior alveolar nerve. The mandibular nerve also carries sensations from temporal mandibular joint and temporal region so the pain also gets referred to these regions

36. The duct of the parotid gland opens in the vestibule of mouth opposite the second upper molar tooth. The duct of submandibular gland opens at the papilla on the sublingual folds. The sublingual glands opens by 10- 12 ducts on the sublingual fold. The investing layer of cervical fascia encloses both the parotid and submandibular glands and is attached to the lower border of mandible. As mandible moves during chewing, the fascia gets stretched which result in the pain. The fascia and the skin are supplied by the greater auricular nerves.

37. Loss of vision in both right visual fields, called right homonymous hemianopsia, is caused by a lesion in the left visual pathways caudal to the optic chiasm. The lesion could be in the left optic tract, left lateral geniculate nucleus, optic radiations in the left parietal lobe, or visual cortex in the left occipital lobe. Other neurological exam findings may help to localize the lesion; e.g. an addi-

tional finding of loss of sensation (all modalities) on the right side would help localize the lesion to the left parietal lobe. If there are no motor or sensory deficits, i.e. the patient's only deficit is right homonymous hemianopsia, and if there is macular sparing, then the most likely location of the lesion is the left occipital lobe.

38. Lumbar puncture is performed by taking a sample of CSF from the lumbar cistern (the subarachnoid space below the spinal cord) between vertebrae L4 and L5 or sometimes between L3 and L4. It is done in this region because the spinal cord ends at the level of L1 to L2 and the dural sac ends at the level of S2. Therefore it is the safest place to do the procedure because it lies between these areas and the risk of injuring the spinal cord is avoided.

39. The anterior longitudinal ligament lies anterior to the vertebral bodies along the vertebral column. The ligamentum flavum connects the lamina of two adjacent vertebrae. The nuchal ligament is a continuation of the supraspinous ligament above C7, which connects spinous processes. The posterior longitudinal ligament lies on the posterior edge of the vertebral bodies. The transverse cervical (cardinal) ligament is associated with the pelvic region of the body and not the spinal column.

40. Disk herniation in the lumbar region between L4 and L5 affects the L5 spinal nerve roots. Even though the L4 spinal nerve root lies directly between the L4 and L5 vertebrae, it exits from the spinal canal superior to the intervertebral disk, whereas the L5 spinal nerve root lies directly posterior to the disk.

41. The anterior spinal artery is located anteriorly along the spinal cord and is not directly associated with the vertebrae. The vertebral arteries run through the transverse foramina of cervical vertebrae C6 through C1 and are therefore most closely associated with injury to the transverse processes. The ascending cervical artery is a very small branch from the thyrocervical trunk of the subclavian artery, running on the anterior aspect of the vertebrae. The deep cervical artery arises from the costocervical trunk is also a very small artery and courses along the posterior aspect of the cervical vertebrae. The posterior spinal arteries are adherent to the posterior aspect of the spinal cord.

42. The T4 thoracic vertebra articulates with the head of the fifth rib. The head of the rib has two facets. The rib articulates with the superior facet on the body of its own vertebra (fourth rib articulates with the superior facet T4 vertebra) and with the inferior facet on the body of the vertebra above (fourth rib articulates with the inferior facet of T3 vertebra). Taking the T4 vertebra into consideration, the superior facet of this vertebra articulates with the head of the fourth rib and the inferior facet articulates with the head of the fifth rib. The head of the fourth rib has two points of articulation (a joint with the vertebral body and costovertebral joint) on T4, so when it is injured it moves as a unit, whereas the fifth rib has only one articulation with T4.

43. The subarachnoid space, containing the CSF, is located between the pia and the arachnoid mater. Neither the epidural space, the subdural space, nor the pre-

tracheal space contains CSF. Although the central canal, contained within the substance of the spinal cord, does contain CSF, extraction of CSF from this region would result in spinal cord injury. CSF circulates in the area of the subarachnoid space and can be aspirated only from that location. The subdural space is only a potential space between the dura and arachnoid mater. The epidural space contains the epidural fat and Batson's venous plexus and is the preferred site for aspirating CSF for diagnostic purposes (and epidural anesthesia). CSF is not located in the pretracheal space.

44.a) round ligament b). Broad Ligaments. From each side of the uterus, the pelvic peritoneum extends laterally, downward, and backward. A double fold of pelvic peritoneum forms the layers of the broad ligament, enclosing the uterus. These layers separate to cover the floor and sides of the pelvis. The uterine tube is situated within the free upper border of broad ligament. The part of the broad ligament lying immediately below the uterine tube is termed the mesosalpinx. The ovary lies behind the broad ligament. Transverse Cervical Ligaments. These cardinal ligaments are composed of connective tissue masses with smooth muscle fibers that are strong support for the uterus in the pelvis. Uterosacral Ligaments. These are a posterior continuation of the peritoneal tissue, which forms the cardinal ligaments. The ligaments pass posteriorly to the sacrum on either side of the rectum.

45. 1. Lig. gastrojejunalis; 2. Lig. hepatogastricum; 3. Lig. gastrocolicum; 4. Lig. gastrosplenic; etc

46. The rectum begins at the level of the promontory and descends into the true pelvis in front of the sacrum to form two anteroposterior flexures: an upper *sacral flexure (flexura sacralis)* convex to the back in conformity with the sacral concavity and a lower *perineal flexure (flexura perinealis)* convex to the front in the region of the coccyx. As a result the rectum is S-shaped, wide in the middle and narrow at the ends.

47. The boundaries of the omental bursa will now be evident. It is bounded in front, from above downward, by the caudate lobe of the liver, the lesser omentum, the stomach, and the anterior two layers of the greater omentum. Behind, it is limited, from below upward, by the two posterior layers of the greater omentum, the transverse colon, and the ascending layer of the transverse mesocolon, the upper surface of the pancreas, the left suprarenal gland, and the upper end of the left kidney. To the right of the esophageal opening of the stomach it is formed by that part of the diaphragm which supports the caudate lobe of the liver. Laterally, the bursa extends from the epiploic foramen to the spleen, where it is limited by the phrenocolic and gastrosplenic ligaments.

48. Foreign bodies in airway are usually located in the right main bronchus, because of its more vertical orientation, and require a high index of suspicion. In many cases the moment of the aspiration is not remembered. foreign bodies in

airway can produce complications like infections (pneumonia and abscess), chronic coughing, bronchial stenosis and atelectasis.

49. Waldeyer's tonsillar ring is an anatomical term describing the lymphoid tissue ring located in the pharynx. The ring consists of (from superior to inferior): Adenoids (also termed pharyngeal tonsils) Tubal tonsils

Palatine tonsils (more commonly termed "the tonsils", less commonly termed "faucial tonsils") Lingual tonsils.

50. IF the proximal end of the popliteal artery is blocked, blood may reach the foot by way of the descending branch of the lateral circumflex femoral artery, which participates in the anastomosis around the knee joint. Other blood vessels are direct or indirect branches of the popliteal artery.

## **IX. Algorithm of the X-ray photographs interpretation**

1. Determination of anatomical area and projection, which is represented in the X-ray photograph.

2. Examining of the surrounding soft tissues. Turn attention on the outline shadow of skin, group of muscles, cavities of body.

3. Turn attention to: size and shape of bones, final stage of the process of development and formation of bone (physiological curve anatomical projection, cavity, epiphyseal cartilages, growth zone, and nucleus of ossification e.t.c).

4. Estimation, the intensity of shadow of a bone (in comparison with soft tissues, depending on the conditions of projection and on the summation of shadows).

5. Examining contour of bones – find: well defined outline of shadow, smooth, continuous (with exception of unevenness in the region of anatomical protrusions and roughnesses). Discontinuity of outline with incomplete process of synostosis.

6. Identify and interpret picture of the internal shadow of bone tissue (osteal trabecule of the spongy substance of epiphyses and the metaphysic, the line of synostosis, the intensity shadow of compact substance, change of its thickness in different parts of the bones, the medullary canal).

7. During investigation of joints turn attention to the form of the articular surfaces of the bones, relations of the joint, height and the extent of X-ray articulate shadow (on examining the back bone - find the distance between intervertebral disks).

8. During interpretation of radiographic images of internal organs, identify: skeletotomy of organs and their parts, sizes and the shape of organ, type of outlines (smooth, well defined outline of shadow, continuous), the relief of mucous membranes.

9. During interpretation of angiograms, identify: main vessel, its first branches and in subsequent orders (those, which are visible in the X-ray photograph), if it is possible the skeletotomy of division of the vessels and departure levels of the vessels.).

## X. Literature

### Basic literature:

1. M. R. Sapin, L. L. Kolesnikov, D. B. Nikitjuk. / Textbook of human anatomy for medical students. M., 2005. –V. 1.–P.416 (or other editions)
2. M. R. Sapin, L. L. Kolesnikov, D. B. Nikitjuk. / Textbook of human anatomy for medical students M., 2005. –V. 2.–P.480(or other editions)
3. . Prives M., Lysenkov N., Bushkovich V. HUMAN ANATOMY. Vol. I.- 9 Edition. – Moscow: MIR, 1985. -596 P. (or other editions)
4. Prives M., Lysenkov N., Bushkovich V. HUMAN ANATOMY. Vol. 2.- 9 Edition. – Moscow: MIR, 1985. - 440 P. (or other editions)
5. Sinelnikov R. D. Atlas of Human Anatomy : in 3 vol. : translated from the Russian. Vol. 1 : : The science of bones, joints, ligaments and muscles / R. D. Sinelnikov. - Moskow : M. P, 1988. - 464 p. (or other editions)
6. Usovich A. K. Human Anatomy : textbook for 1-year medical students. Part 1 : introduction anatomy and skeletal system; / A. K. Usovich, T A. Ostrovskaya; - Vitebsk :, 2006.
7. Usovich A. K. Human Anatomy : textbook for 1-year medical students. Part 2 : : Joints; Articular system / A. K. Usovich, W. A. Tesfaye ; - Vitebsk : 2012.
8. Okolokulak E.S. Anatomy of the nervous system. Sense organs./ E.S. Okolokulak, D.A. Volchkevich, F.G. Gadzieva.– Гродно: ГрГМУ, 2014.– 196 p. 9.
9. Chaurasia B. D. Human anatomy : regional and applied. Vol. 1 : : Upper Limb & Thorax / B. D. Chaurasia. - 3-rd ed. - New Delhi :, 1995. - 252 p. (or other editions)
10. Chaurasia B. D. Human anatomy : regional and applied. Vol. 2 : : Lower Limb & Abdomen / B. D. Chaurasia. - 3-rd ed., - New Delhi :, 2002. - 374 p. (or other editions)
11. Chaurasia B. D. Human anatomy : regional and applied. Vol. 3 : : Head, Neck & Brain / B. D. Chaurasia. - 2-nd ed., - New Delhi :, 1993. - 332 p.
12. Singh I. A Textbook of Human Neuroanatomy / I. Singh. - 2-nd ed. - New Delhi :, 1983. - 293 p.
13. Singh I. Essentials of anatomy : textbook / I. Singh. - New Delhi : Jaypee Brothers, 2003. - 536 p.
14. GRAY'S ANATOMY. – 38 Edition. - Churchill Livingstone, Edinburg, London, New-York, Philadelphia, Sidney, Toronto, 1995. – 2092 P. (or other editions)
15. Richard Drake & A. Wayne Vogl & Adam Mitchell & Richard Tibbitts & Paul Richardson / Gray's Atlas of Anatomy –2008.–558p(or other editions)
16. Netter F. Atlas of human anatomy. 3 ed.– 2003.–627 p. (or other editions)
17. Anne M.R. Agur & Ming J. Lee Grant's Atlas of anatomy/ –2009. –864p

18. Moore Keith L., Daily Arthur F. CLINICALLY ORIENTED ANATOMY. – 4 Edition. - Lippincott Williams & Wilkins, Canada, - 1999. – 1168 P. (or other edition)
19. Kent M. VanDeGraaff & Stuart Ira Fox Synopsis of human anatomy and physiology / –1997.– 675p

**Additional literature:**

1. Abrahams P. H. McMinn's Color Atlas of Human Anatomy / P. H. Abrahams, Marks Jr S. C., R. T. Hutchings. - 5-th ed. - Edinburgh : Mosby, 2003. - 378 p
2. Romanes G. J. CUNNINGHAM'S MANUAL of PRACTICAL ANATOMY. 3 volumes. – V edition. - Oxford, New York, Tokyo: Oxford University press, 1999.
4. Rohen W., Johannes Chihiro Yokochi, Eike Lutjen-Drecoll. COLOUR ATLAS OF ANATOMY (A PHOTOGRAPHIC STUDY OF THE HUMAN BODY WITH 1111 FIGURES, 947 IN COLOUR). IV Edition. – Germany: Williams & Wilkins, 1999. – 486 P.
5. Richard S. Snell, Clinical Anatomy for Medical Students/ Richard S. Snell//– 2000. – 912 p

311492

Библиотека  
Учреждение образования  
"Витебский государственный  
ордена Дружбы народов  
медицинский университет"

Библиотека ВГМУ



Educational publication (Учебное издание)

**Usovich Alexander K. (Усович Александр Константинович)**  
**Tesfaye Wolde A. (Тесфайе Волде Асфай)**

**Preparation materials for final examination on human anatomy  
speciality 1 79 01 01 (General medicine)**

manual (пособие)

Редактор: Усович А.К., Тесфайе В.А.  
Технический редактор: Борисов И.А.

Компьютерный набор, верстка и иллюстрации Тесфайе В.А., Усович А.К.

Подписано в печать 9 01 2015 Формат 60x84 1/16.  
Бумага типографская №2. Гарнитура Таймс. Усл. печ. листов 6,98.  
Уч.-изд. л 1,5 Тираж 230 экз. Заказ № 1  
Издатель и полиграфическое исполнение  
УО «Витебский государственный медицинский университет»  
ЛП № 02330/453 от 30.12.2013 г.

пр. Фрунзе, 27. 210023, г. Витебск