

# Neutron Therapy for Salivary and Thyroid Gland Cancer

O. V. Gribova<sup>1,2,a)</sup>, L. I. Musabaeva<sup>1,b)</sup>, E. L. Choyazonov<sup>1,2,c)</sup>,  
V. A. Lisin<sup>1,d)</sup>, and V. A. Novikov<sup>1,e)</sup>

<sup>1</sup> Tomsk Cancer Research Institute, Kooperativny Street 5, Tomsk, 634050 Russia

<sup>2</sup> National Research Tomsk Polytechnic University, Lenina Avenue 30, Tomsk, 634050 Russia

<sup>a)</sup> Corresponding author: [gribova79@mail.ru](mailto:gribova79@mail.ru)

<sup>b)</sup> [musabaevaLI@oncology.tomsk.ru](mailto:musabaevaLI@oncology.tomsk.ru)

<sup>c)</sup> [nii@oncology.tomsk.ru](mailto:nii@oncology.tomsk.ru)

<sup>d)</sup> [Lisin@oncology.tomsk.ru](mailto:Lisin@oncology.tomsk.ru)

<sup>e)</sup> [dr.vanovikov@gmail.com](mailto:dr.vanovikov@gmail.com)

**Abstract.** The purpose of this study was to analyze the results of the combined modality treatment and radiation therapy using 6.3 MeV fast neutrons for salivary gland cancer and prognostically unfavorable thyroid gland cancer. The study group comprised 127 patients with salivary gland cancer and 46 patients with thyroid gland cancer, who received neutron therapy alone and in combination with surgery. The results obtained demonstrated that the combined modality treatment including fast neutron therapy led to encouraging local control in patients with salivary and thyroid gland cancers.

## INTRODUCTION

Salivary gland cancer accounts for 3–4% of all head and neck cancers [1]. Due to the resistance of salivary gland tumors to photon therapy, local recurrence rate reaches 50%. Kokemuller et al. [2, 3] reported that postoperative radiotherapy with high-energy photon beams does not improve local and regional controls and survival of patients with adenocystic cancer of the salivary glands. Thus, the development of new methods for the treatment of malignant tumors of the salivary glands is of great importance.

Thyroid cancer (TC) is the most common tumor of the endocrine system and accounts for 1.5–2.2 % of all malignancies registered in Russia [4].

A. Antonacci et al. [5] identified the factors under which the prognosis of the TC disease gets worse: anaplastic, squamous cell, medullary TC, insular forms of TC, spread of tumor beyond the capsule, invasion into adjacent tissues, and the presence of residual tumor after surgery. Anaplastic TC accounts for not more than 4–6% of all thyroid cancers, and along with squamous cell thyroid cancer it is considered as one of the most aggressive human cancers [4, 6]. One of the ways to improve the effectiveness of radiation therapy is the use of high linear energy transfer radiation, in particular fast neutrons [7–9]. Neutron therapy delivered to the “bed” of the removed tumor is not widely used, because there is a perception of increased rates of post-radiation changes in normal tissues and adjacent critical organs. In addition, single and total doses of fast neutrons for the above cancers are not identified. Therefore, the use of fast neutrons in the postoperative period requires further detailed research.

Since 1984, more than 800 patients with head and neck cancer (salivary and thyroid glands, nasal cavity and paranasal sinuses, larynx, oropharynx and oral mucosa and metastases in lymph nodes of neck) have been treated with 6.3 MeV fast neutrons at the Cancer Research Institute in Tomsk [10–15].

## MATERIALS AND METHODS

### Salivary Gland Cancer

All patients received neutron therapy using U-120 cyclotron with the average energy of 6.3 MeV. The study included 83 patients with cancer of the parotid, minor salivary and submandibular glands who underwent surgery

followed by neutron therapy or neutron-photon therapy. Neutron-photon therapy alone was administered to 44 patients. The average age of the patients was 54 years. Adenocarcinomas (38%), mucoepidermoid carcinoma (22%) and adenoid cystic carcinoma (19%) were the most common histological types.

The control group included 40 patients with cancer of the parotid, minor salivary and submandibular glands, who received conventional external beam radiotherapy given alone ( $n = 13$ ) or in combination with surgery ( $n = 27$ ).

### Thyroid Cancer

The study included 46 patients with thyroid cancer who received either combined modality treatment including surgery and postoperative neutron therapy/neutron-photon therapy ( $n = 24$ ), or neutron-photon therapy alone ( $n = 22$ ). The median age of the patients was 55 (range: 15 to 75). The male to female ratio was 1 : 1. Anaplastic carcinoma was the most common histological type (33%) followed by medullary carcinoma (22%), squamous cell carcinoma (9%) and poorly differentiated papillary and follicular carcinoma (36%).

All patients underwent surgery in the first treatment phase of the combined modality treatment. The patients with unresectable primary tumors or recurrent tumors received neutron or neutron-photon therapy alone.

### Technique of Neutron Therapy

Therapeutic neutron beams produced by U-120 cyclotron were used. The average energy of fast neutrons was 6.3 MeV. Source to skin surface distance was 110 cm [16–18].

Radiation therapy was performed twice a week. A computer program for neutron therapy planning was developed to calculate the absorbed dose of fast neutrons in the tumor and critical organs [19].

Two schedules of neutron dose fractionation were used. The first schedule of fractionation was: 1.2–1.4 Gy single dose, 3.1–3.0 RBE for skin, 3.7–4.2 Gy photon-equivalent dose, 8–12 Gy total dose of fast neutrons (40–50 Gy isoeffect dose). The second regimen was: 3–5 fractions of fast neutrons given twice a week, 1.8–2.4 Gy single dose, 2.8–2.7 RBE, 5.0–6.5 Gy photon-equivalent dose, 5.4 to 7.2 Gy total dose (equal to 35–40 Gy of photon irradiation).

Rokus-M and Teratron gamma-therapeutic apparatus were used for photon radiotherapy and PMB-7 MeV for electron beam radiotherapy. The follow-up ranged from 6 months to 20 years.

Statistical analysis was performed using Statistica 6.0 software.

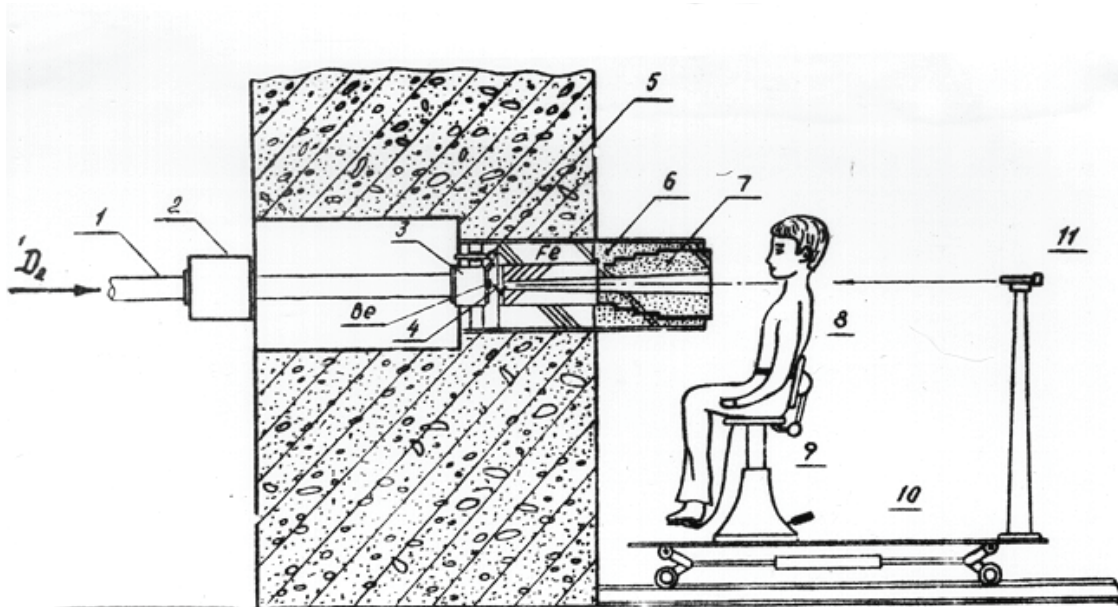
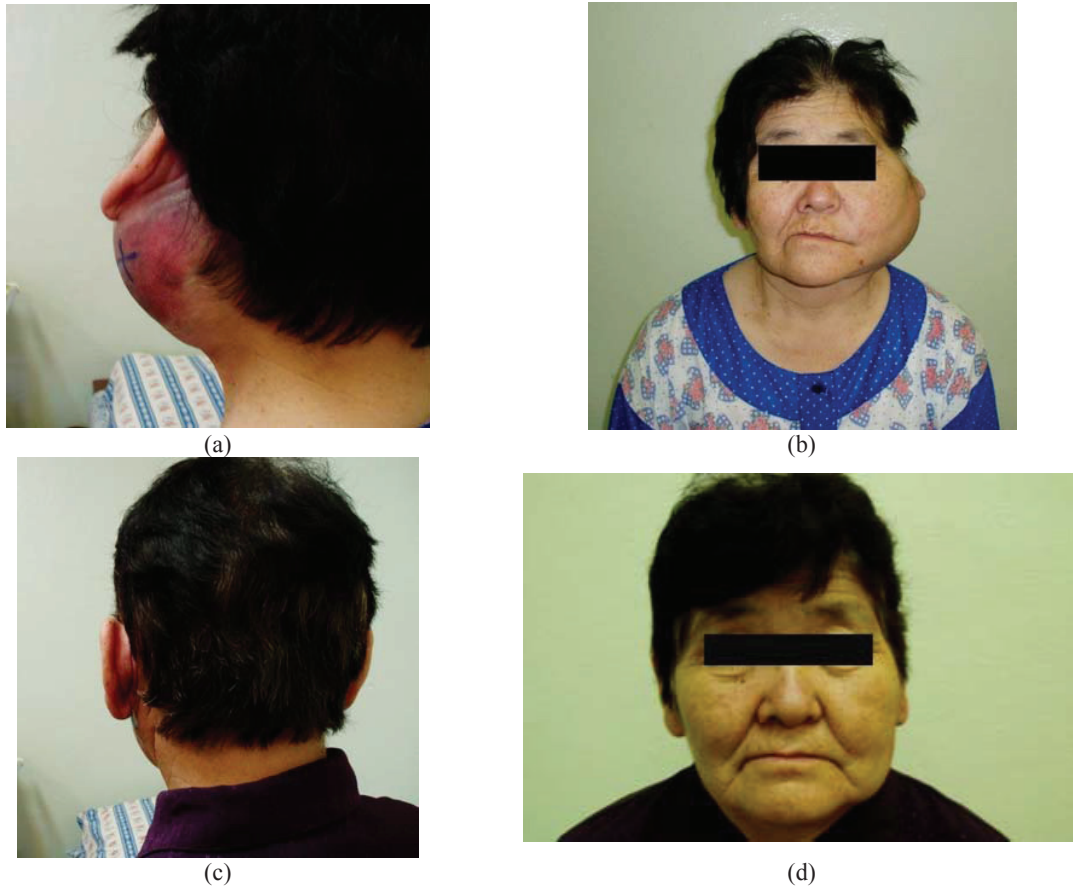

FIGURE 1. Therapeutic neutron beam scheme and the position of the patient during irradiation session



**FIGURE 2.** The patient with inoperable salivary gland cancer before (a, b) and after (c, d) neutron-photon therapy

## RESULTS AND DISCUSSION

The patients with salivary gland cancer received both modes of fractionation of fast neutrons in almost equal proportions. The average single dose of fast neutrons was 1.4 Gy for patients treated with surgery + neutron/photon therapy and 1.65 Gy for patients treated with radiotherapy alone. The contribution of fast neutrons to the total dose of neutron-photon therapy was 46-48%. The average total dose of postoperative radiotherapy was 40 Gy. For patients treated with radiotherapy alone, the average total dose was 60 Gy.

The control group patients with salivary gland cancer received a standard photon therapy.

Both schedules of neutron fractionation were used in the treatment of thyroid cancer, but the first schedule was used more often (in 73% of cases). Single dose of fast neutrons was 1.4 Gy for the patients treated with surgery + radiotherapy and 1.47 Gy for patients treated with radiotherapy alone. The contribution of fast neutrons to the total dose of neutron-photon therapy was 46-48%. The average total dose was 52.5 Gy in combination treatment and 61.0 Gy in radiotherapy alone.

In the patients with salivary gland cancer, who received combination treatment with postoperative neutron therapy, the 3-, 5- and 7-year survival rates were  $83.2 \pm 6.3\%$ ,  $65.8 \pm 10.4\%$  and  $52.6 \pm 14.4\%$ , respectively. In the control group patients, the 3-year overall survival rate was  $53 \pm 9.2\%$  and the 5-year survival rate was  $31.8 \pm 10.3\%$ .

The 3- and 5-year overall survival rates in patients with inoperable salivary gland cancer, who received fast neutron therapy alone, were  $60.6 \pm 13.6\%$  and  $48.5 \pm 15.3\%$ , respectively. In the control group, the corresponding values were  $30 \pm 16.9\%$  and 0%, respectively.

The 3- and 5-year recurrence-free survival rates were respectively  $70.3 \pm 8.1\%$  and  $49.3 \pm 11.8\%$  for salivary gland cancer patients treated with surgery and postoperative neutron therapy. In the control group, the 3- and 5-year recurrence-free survival rates were  $46 \pm 13.9\%$  and  $18.5 \pm 11.5\%$ , respectively.

Immediate response rate of inoperable salivary gland cancer was higher to fast neutrons than to conventional photon therapy. In neutron therapy group, complete tumor regression was observed in 26 cases (59%), partial regression in 15 cases (34%). No response to therapy with evidence of disease progression was noted in three cases (7%). In the control group, partial tumor regression was observed in 5 cases (62.5%). No response to radiotherapy was recorded in 2 cases (25%), complete regression occurred in one case (12.5%).

### **Clinical Trial of 6.3 MeV Fast Neutron Therapy for Patients with Thyroid Cancer**

In patients with thyroid cancer, who received combination treatment with postoperative neutron therapy, the 5-year overall survival rate was  $70.2 \pm 8.9\%$ . The 5-year recurrence-free survival rate was  $52 \pm 10.6\%$ .

The 5-year overall survival rate in patients with inoperable thyroid cancer, who received fast neutron therapy alone, was  $46.9 \pm 9.7\%$ .

The analysis of long-term treatment outcomes of the patients with thyroid cancer showed the overall five-year survival rate of  $32.8 \pm 15.1\%$  in the patients with anaplastic thyroid carcinoma and  $63.4 \pm 7.8\%$  in the patients with medullary carcinoma. All patients with squamous cell carcinoma of the thyroid gland died of distant metastases without evidence of local recurrence within 1-year follow-up.

### **Local Radiation-Induced Reactions in Patients with Salivary and Thyroid Cancers**

Radiation-induced skin damages (mainly grade I erythema according to RTOG scale) were observed in 81% of patients with salivary gland cancer who received combination treatment including surgery and postoperative neutron or neutron-photon therapy. In patients with salivary gland cancer, who received neutron or neutron-photon therapy alone, radiation-induced skin damages were noted in 96% of cases.

In the patients with thyroid cancer, who were treated with fast neutrons in the postoperative period, radiation-induced skin reactions were observed in 73% of cases and were mainly represented by erythema (52%). In the patients with thyroid cancer, who received neutron-photon therapy alone, dry and moist desquamation was observed in 81% of cases.

## **CONCLUSION**

The analysis of treatment outcomes in the patients with salivary gland cancer demonstrated the superiority of combination treatment including surgery and postoperative neutron or neutron-photon therapy over the standard photon therapy in terms of the 3- 5- and 10-year survival rates and radiation-induced skin reactions.

Clinical trials of neutron-photon therapy used alone and in combination with surgery showed reduction in the incidence of local recurrence for patients with aggressive forms of thyroid cancer. In addition, well tolerance and the absence of severe complications dictate the necessity of prospective studies to improve treatment outcomes.

## **ACKNOWLEDGMENTS**

The study reported in this article was conducted according to accepted ethical guidelines involving research in humans and/or animals and was approved by an Ethical Committee of Tomsk Cancer Research Institute.

The study is compliant with the ethical standards as currently outlined in the Declaration of Helsinki.

All individual participants discussed in this study, or for whom any identifying information or image has been presented, have freely given their informed written consent for such information and/or image to be included in the published article.

The study was financially supported by the Fundamental Research Program of the Russian Academy of Sciences, project No. 093.

## REFERENCES

1. P. M. Speight, A. W. Barrett, Salivary gland tumours, *Oral Dis.* **8**(5), 229–240 (2002).
2. H. Kokemuller, N. Bruggemann, P. Brachvogel, and A. Eckardt, Malignant epithelial salivary gland tumors. Clinical review of 2 decades, *Mund. Kiefer. Gesichtschir.* **8**(3), 191–201 (2004).
3. R. K. Sur, B. Donde, and V. Levin, Adenoid cystic carcinoma of the salivary glands: a review of 10 years, *Laryngoscope* **107**(9), 1276–1280 (1997).
4. A. I. Paches and R. M. Propp, *Thyroid Cancer* (Medicine, Moscow, 1995).
5. A. Antonacci, G. Brili, G. Bakki, et al., *Thyroid Cancer. Prognostic Factors in Oncology*, edited by V. E. Kratenok (Byelorussian Centre of Scientific Medical Information, Minsk, 1999).
6. J. Misonou, Pure squamous cell carcinoma of the thyroid gland—report of an autopsy case and review of the literature, *Jap. J. Surgery* **18**(4), 459–474 (1988).
7. I. A. Gulidov, Ju. S. Mardynskij, A. F. Cyb, and A. S. Sysoev, Neutrons of nuclear reactors in the treatment of malignant neoplasms, in *Digest of Conference Materials* (Obninsk, 2001).
8. O. V. Gribova, L. I. Musabaeva, E. L. Choinzonov, V. A. Novikov, and V. A. Lisin, The use of fast neutrons in treatment of malignant tumors of the head and neck, *Voprosy Onkologii* **1**, 149–153 (2015).
9. S. A. Vasilyev, A. I. Velichevskaya, T. V. Vishnevskaya, A. A. Belenko, O. V. Gribova, M. B. Plaksin, Zh. A. Startseva, and I. N. Lebedev, Background level of  $\gamma$ H2AX foci in human cells as a factor of individual radiosensitivity, *Radiatsion. Biolog. Radioecolog.* **55**(4), 402 (2015).
10. V. V. Velikaya, O. V. Gribova, L. I. Musabaeva, Zh. A. Startseva, K. A. Simonov, A. N. Aleinik, and V. A. Lisin, Ozone therapy for radiation reactions and skin lesions after neutron therapy in patients with malignant tumors, *Voprosy Onkologii* **61**(4), 571–574 (2015).
11. O. V. Gribova, L. I. Musabaeva, E. L. Choinzonov, and M. R. Mukhamedov, The clinical course of thyroid cancer following its combined treatment with the use of fast-neutron therapy in the patients at the high risk of relapses, **5**, 91–92 (2012).
12. A. A. Melnikov, S. A. Vasilyev, L. I. Musabaeva, V. V. Velikaya, O. V. Gribova, Zh. A. Startseva, L. N. Urazova, I. N. Lebedev, and E. L. Choinzonov, Cytogenetic effects of neutron therapy in patients with parotid gland tumors and relapse of breast cancer, **34**(4), 354–357 (2012).
13. S. G. Stuchebrov, A. V. Batranin, and I. A. Miloichikova, Modernization of the X-ray tomographic scanner based on gas-discharge linear detector, *J. Phys. Conf. Ser.* **671**, 012004-1–012004-6 (2016).
14. S. G. Stuchebrov, I. A. Miloichikova, and I. B. Danilova, Measurement technique of dose rate distribution of ionization sources with unstable in time beam parameters, *J. Phys. Conf. Ser.* **671**, 012057-1–012057-5 (2016).
15. S. G. Stuchebrov, I. A. Miloichikova, and I. B. Danilova, The X-ray beam passage through the collimator made of different materials: numerical simulation, *J. Phys. Conf. Ser.* **671**, 012012-1–012012-5 (2016).
16. S. G. Stuchebrov, I. A. Miloichikova, A. L. Melnikov, and M. A. Pereverzeva, Numerical simulation of the microtron electron beam absorption by the modified ABS-plastic, *J. Phys. Conf. Ser.* **671**, 012036-1–012036-5 (2016).
17. S. G. Stuchebrov, I. A. Miloichikova, and K. O. Shilova, The dosimetric parameters investigation of the pulsed X-ray and gamma radiation sources, *J. Phys. Conf. Ser.* **671**, 012051-1–012051-6 (2016).
18. I. A. Miloichikova, S. G. Stuchebrov, G. K. Zhakysbaeva, and A. R. Vagner, Application of traditional and nanostructure materials for medical electron beams collimation: numerical simulation, *IOP Conf. Ser. Mater. Sci. Eng.* **98**, 012011-1–012011-6 (2015).
19. V. A. Lisin, Dosimetry planning of gamma-neutron therapy of malignant tumors using cyclotrone U-120, *Med. Radiology Radiation Safety* **5**, 53–57 (1994).