

The first experience of using of $^{99m}\text{Tc-Al}_2\text{O}_3$ for detection of sentinel lymph nodes in breast cancer

A Doroshenko¹, V Chernov^{1,2}, A Medvedeva^{1,2}, R Zeltchan^{1,2}, E Slonimskaya¹, N Varlamova², V Skuridin², A Dergilev³, I Sinilkin^{1,2}

1 Tomsk Cancer Research Institute, Kooperativny Street 5, Tomsk, Russia

2 Tomsk Polytechnic University, Lenin Avenue 30, Tomsk, Russia

3 Novosibirsk State Medical University, Krasny Prospect 52, Novosibirsk, Russia

sinilkinig@oncology.tomsk.ru

Abstract. Purpose: to study the feasibility of using the new radiopharmaceutical based on the technetium-99m-labeled gamma-alumina for identification of sentinel lymph nodes (SLNs) in breast cancer patients. Materials and methods. The study included two groups of breast cancer patients who underwent single photon emission computed tomography (SPECT) and intraoperative gamma probe identification of sentinel lymph nodes (SLNs). To identify SLNs, the day before surgery Group I patients (n=34) were injected with radioactive $^{99m}\text{Tc-Al}_2\text{O}_3$, and Group II patients (n=30) received ^{99m}Tc -labeled phytate colloid. Results. A total of 37 SLNs were detected in Group I patients. The number of identified SLNs per patient ranged from 1 to 2 (the average number of identified SLNs was 1.08). Axillary lymph nodes were the most common site of SLN localization. At 18 hours after $^{99m}\text{Tc-Al}_2\text{O}_3$ injection, the percentage of its accumulation in the SLN was 7-11% (of the counts in the injection site) by SPECT and 17-31% by gamma probe detection. In Group II patients, SLNs were detected in 27 patients. At 18 hours after injection of the phytate colloid, the percentage of its accumulation in the SLN was 1.5-2% out of the counts in the injection site by SPECT and 4-7% by gamma probe. Conclusion. The new radiopharmaceutical based on the $^{99m}\text{Tc} - \text{Al}_2\text{O}_3$ demonstrates high accumulation in SLNs without redistribution through the entire lymphatic basin. Sensitivity and specificity of $^{99m}\text{Tc} - \text{Al}_2\text{O}_3$ were 100% for both SPECT and intraoperative gamma probe identification.

1. Introduction

Development of the sentinel node concept started at the beginning of the 1990s with evaluation and comparison of the procedures that could be used to detect the sentinel node(s).

If the SLN is free of metastatic disease, all other lymph nodes will also be free of disease [[1],[2]]. The use of colloid radiopharmaceuticals labeled with technetium-99m has appeared to be effective and safe for scintigraphic and/or intraoperative gamma probe identification of SLN [[2]]. Sentinel node biopsy may be a reasonable alternative to avoid extensive axillary lymph node dissection in breast cancer patients with negative SLNs, thereby improving the quality of life of approximately 100,000 patients undergoing lymphodissection for treating breast cancer [[1],[3],[4],[5]]. The two most widely



accepted clinical scenarios for SLN biopsy are melanoma and breast cancer. Most modern medical centers worldwide now offer SLN biopsy for these malignancies, yet debate continues regarding whether SLN biopsy should be routinely used in clinical practice [[1],[2],[4],[6],[9]].

The size of radioactive particles is the most important factor in determining the choice of radiopharmaceuticals. Schauer AJ et al. [[5]] reported that a colloid with the particle size of less than 50 nm can be accumulated not only in the SLN but also in the non-SLNs. Particles of greater than 100 nm slowly migrate from the injection site. A colloid with the particle size of the order of 50-80 nm may be preferable for the SLN detection. Nanocolloids made to date are based on the compounds that form stable hydrosols, and organic substances of different structures are often chosen as starting materials for their production. Another part of such pharmaceuticals represents inorganic complexes with ^{99m}Tc-rhenium sulfide and antimony, the application of which are limited by their complex manufacturing process and high cost. Our studies have shown that stable colloidal compounds can be obtained in a simpler way - by means of adsorption on the reduced ^{99m}Tc alumina gamma [[7],[8]]. The original premise for the use of alumina as a "carrier" of ^{99m}Tc- label is its relatively low toxicity, combined with good adsorption properties, availability and low cost.

A specific feature of this compound is an organic coating of nanoparticles. During passage through the lymphatic system, nanoparticles lose their organic coating and accumulate in SLN without redistribution in the body.

Breast cancer is the most common cancer in women worldwide. Approximately 30,000 new early stages breast cancer cases are diagnosed each year in Russia [[10]]. However, in patients with early stages of breast cancer, regional lymph node metastases are found in only 10-30% of cases. Extended lymph node dissection may increase the risk of postoperative complications [[10]].

The purpose of our study was to evaluate the feasibility of using the new radiopharmaceutical, based on technetium-^{99m}-labeled gamma-alumina for the detection of sentinel lymph nodes in breast cancer patients.

2. Materials and methods

The study included 64 patients with histologically verified breast cancer (T1-2N0-1M0). For SLN visualization, all patients were divided into two groups. Group I consisted of 34 women, who received 4 peritumoral injections of radioactive ^{99m}Tc-Al₂O₃ at a total dose of 80 MBq (20 MBq per quadrant), the day before surgery. Group II comprised 30 women, who were injected with phytate colloid at a total dose of 80 MBq (4 peritumoral injections, 20 MBq per injection), the day before surgery.

All patients underwent single photon emission computed tomography (SPECT) using the dual-head gamma camera (E.CAM 180, Siemens, energy 140 keV, window 15%) in 18 hours after the radiotracer injection. A total of 16 projections were acquired (30 seconds per projection, matrix size 64x64). The scan images were analyzed using the ESoft software (Siemens, Germany). Three-dimensional images of the sagittal, transverse and coronal sections were obtained. To obtain quantitative values, the axial sections were used. The radiotracer accumulation in the SLN with respect to the injection site was evaluated using a quantitative criterion.

For intraoperative detection of sentinel lymph nodes, the hand-held collimated Gamma Finder II® probe was used, which allowed the surgeon to precisely locate gamma radiation source and obtain accurate information about the distribution of the radionuclide in tissues and organs of the patient. The registered gamma radiation level was displayed in numerical values. The lymph node with radioactivity of at least three times more than the background counts was defined as a sentinel lymph node.

The sentinel lymph node was marked and separately sent for express cytological examination. The lymph node was sectioned transversely into 2 mm slices. Depending on the size of the node, 6–10 imprints were made from each slice by gently touching the cut surface of the node to a glass slide.

Cytological specimens were stained for 15 seconds using the kit for rapid staining of blood smears (Leucodiff 200) and examined with a Zeiss Axio Scope (Germany).

Each group of the patients was subdivided into the groups with 12 patients who underwent extended lymphodissection despite the results of histological examination. After lymphodissection, the removed lymph nodes were re-examined with gamma probe to detect SLNs missed during intraoperative examination.

3. Results and discussion

A total of 37 SLNs were identified in Group I patients. The number of identified SLNs per patient ranged from 1 to 2 (the mean number of identified SLNs was 1.08). The most frequent SLN location was the axillary region (97.2%) (Figure 1). Metastases in the excised SLNs were detected in 9 patients (26.6%), who subsequently underwent the conventional axillary lymph node dissection. Four patients (11.4%) had metastases not only in the SLN but also in lymph nodes of the level II. The presence of SLN metastasis indicates lymphatic dissemination of tumor cells and the formation of clinically undetectable regional lymph node metastases. Sentinel lymph node was free from metastasis in 25 patients (73.5%). We did not observe the phenomenon of so called “jumping” metastases in these patients.

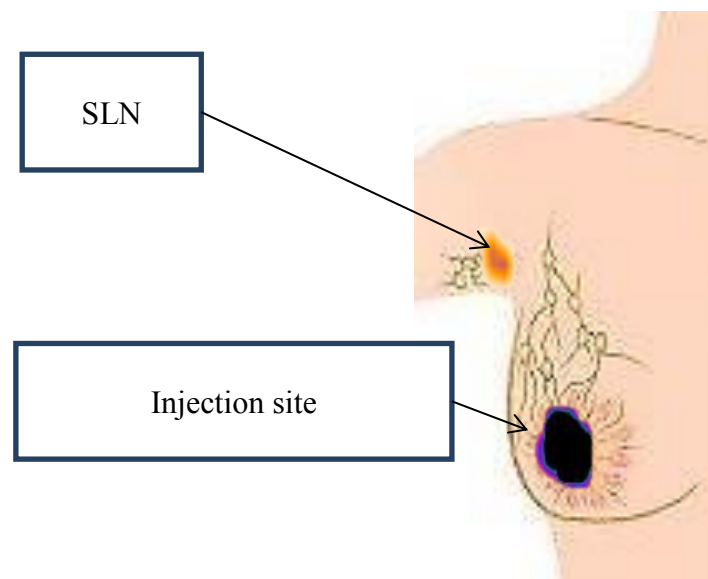


Figure 1. SPECT SLN detection in breast cancer patients.

The $^{99m}\text{Tc-AI203}$ uptake in the SLN in 18 hours after injection was 7-11% (of the radioactivity in the injection site) by SPECT and 17-31% by intraoperative gamma probe detection.

Thus, the sensitivity and specificity of $^{99m}\text{Tc-AI203}$ for detecting SLNs in breast cancer patients were 100%.

The intraoperative SLN detection was performed through a small skin incision. Sparing surgical procedures can significantly reduce overall surgery trauma and recovery time (Figure 2).

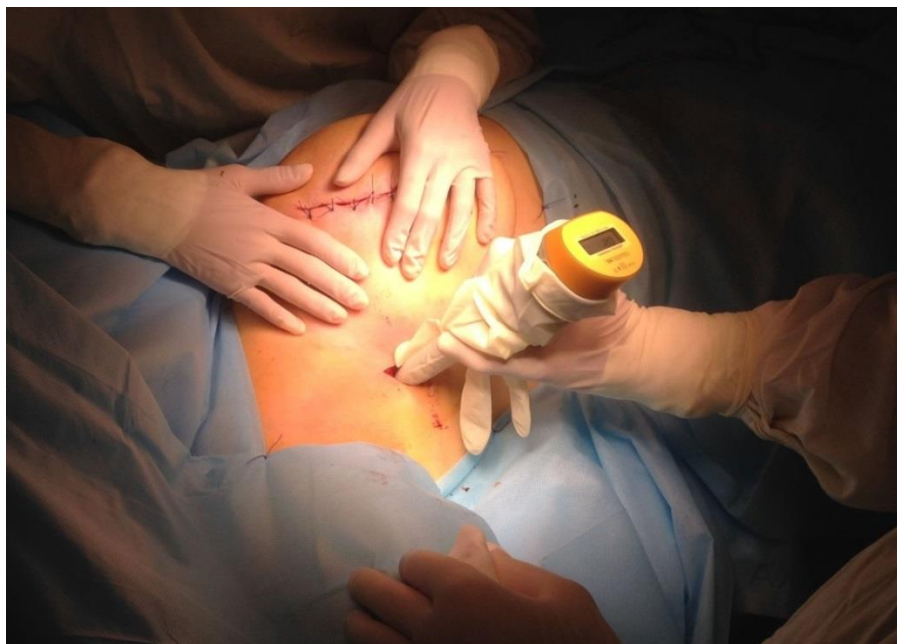


Figure 2. Intraoperative radio guided SLN detection with the use of the hand-held collimated gamma Finder II® in breast cancer patients.

In Group II, 28 SLNs were identified in 27 patients. The number of SLNs detected per patient ranged from 1 to 2 (the mean number of detected SLNs was 1.04). All detected SLNs were located in the axillary region.

Metastases in the excised SLNs were detected in 8 patients (29.6%), who subsequently underwent the conventional axillary lymph node dissection. In 6 patients (22.2%), the removed SLN and lymph nodes of the level II had a positive histology. In 21 patients (77.7%), the SLN was negative, with no clinical evidence of lymph node metastasis during the follow-up. In this group of patients, there was also no phenomenon of so called “jumping” metastases.

The percentage of phytate colloid accumulation in the SLN in 18 hours after injection was 1.5-2% by SPECT and 4-7% by intraoperative gamma probe detection.

Thus, the use of phytate colloid for detecting SLNs in breast cancer patients demonstrated 90% sensitivity.

Various techniques of SLN identification are widely discussed in the published literature. Currently, most investigators propose that the blue dye and isotope complement each other, and the detection of SLN is more successful using combined dye- isotope technique, with sensitivity and specificity approaching 100% [[10],[12]]. In our study, the use of $^{99m}\text{Tc}-\text{Al}_2\text{O}_3$, a novel molecular imaging agent has shown promising results in detecting SLNs with high sensitivity and specificity.

For histological examination of the identified sentinel lymph nodes, we used the light optical microscopy with hematoxylin-eosin. A number of authors have published immunohistochemistry and flow cytometry for the detection of micrometastases in lymph nodes, allowing a three-fold increase in the detection rate to be achieved [13]. The wide use of the modern methods of histological express analysis will significantly improve the clinical significance of detecting the sentinel lymph nodes in breast cancer patients.

Thus, the use of the new radiopharmaceutical allows the precise detection of SLNs to be achieved, thereby personalizing the extent of surgery in patients with primary operable breast and cervical cancers.

4. Conclusion

The novel radiopharmaceutical based on $^{99m}\text{Tc}-\text{Al}_2\text{O}_3$ has high accumulation in sentinel lymph nodes, with no evidence of further redistribution along the lymphatic collector, thus significantly facilitating scintigraphic and intraoperative SLN identification.

The sensitivity and specificity of using $^{99m}\text{Tc}-\text{Al}_2\text{O}_3$ were 100% for both SPECT and intraoperative identification of sentinel lymph nodes.

References

- [1] Chernov VI, Sinilkin IG, Shiryaev SV. 2010 *National leadership on nuclear medicine* Ed. Lishmanov YB, Chernov VI Tomsk STT B **2** 336
- [2] Paredes P, Vidal-Sicart S, Zanón G et al. 2005 *E.J.Nucl. Med.* **32** 1283
- [3] Channel SV, Novikov SN, Zhukov LA, Zotov OV, Semiglazov VF, Krivorotko PV 2011 *Questions of Oncology* **57** 616
- [4] Chernov VI, Sinilkin IG, Choynzonov EC, Chijevskaya SY, Titskaya AA, Zelchan RV, Bragina OD, Lyapunov AY, Skuridin VS 2015 *Eur J Nucl Med Mol Imaging* **42** (Suppl 1) 704
- [5] Maza S 2003 *QJNuclMed* **30** 651
- [6] Afanasyev SG, Avgustinovich AV, Chernov VI, Sinilkin IG 2009 *Siberian Journal of Oncology* **34** 27.
- [7] Skuridin VS, Stasiuk ES, Varlamova VN, Rogov AS, Sadkin VL, Nesterov EA 2013 *Proceedings of TPU. Chemistry* **323** 33
- [8] Skuridin VS, Stasiuk ES, Varlamova NV, Postnikov PS, Nesterov EA, Sadkin VL 2011 *The universities, Physics* **54** 332
- [9] Sinilkin I, Chernov V, Zelchan R, Titskaya A, Skuridin V 2014 *Eur J Nucl Med Mol Imaging* **41** (Suppl 2) 518
- [10] Malignant neoplasms in Russia in 2014 (morbidity and mortality), edited by Caprin AD, Starinskaya VV, Petrova GV Moscow 2016
- [11] Kim MC, Kim HH, Jung GJ, Lee JH, Choi SR, Kang DY, Roh MS, Jeong JS 2004 *Ann Surg* **239** 383
- [12] Kara PP, Ayhan A, Caner B 2008 *Ann Nucl Med* **22**(6) 487
- [13] Arigami T, Natsugoe S, Uenosono Y, et al. 2006 *Ann Surg* **243** 341