



VCU

Virginia Commonwealth University
VCU Scholars Compass

Theses and Dissertations

Graduate School

2016

THE INCIDENCE OF ROOT DENTINAL MICRO-CRACKS CAUSED BY RECIPROCATING AND CONTINUOUS ROTARY INSTRUMENTATION

Stephen N. Schroeder
Virginia Commonwealth University

Follow this and additional works at: <https://scholarscompass.vcu.edu/etd>



Part of the [Endodontology Commons](#)

© Stephen N. Schroeder

Downloaded from

<https://scholarscompass.vcu.edu/etd/4587>

This Thesis is brought to you for free and open access by the Graduate School at VCU Scholars Compass. It has been accepted for inclusion in Theses and Dissertations by an authorized administrator of VCU Scholars Compass. For more information, please contact libcompass@vcu.edu.

The incidence of root dentinal micro-cracks caused by reciprocating and
continuous rotary instrumentation.

A thesis submitted in partial fulfillment of the requirements for the degree of Master of Science
in Dentistry at Virginia Commonwealth University

by

Stephen Nicholas Schroeder,
BS, James Madison University, 2007
DDS, Virginia Commonwealth University School of Dentistry, 2012

Director: Garry L. Myers, DDS
Director, Advanced Education Program in Endodontics, Department of Endodontics,
Virginia Commonwealth University School of Dentistry

Virginia Commonwealth University
Richmond, Virginia
November, 2016

Acknowledgment

The author wishes to thank several people without whose support I could not have completed this thesis. I would like to thank my wife, Erica, for her love, patience, and support during my time as a resident. I would like to thank Dr. Myers for his help and direction with this project, as well as Dr. Best for all of his expertise with the statistical aspects of this thesis.

Table of Contents

List of Tables.....	iv
List of Figures.....	v
Abstract.....	vi
Introduction.....	7
Methods.....	11
Results.....	17
Reliability.....	19
Analysis of cracks by instrumentation type.....	23
Discussion.....	25
References.....	30
Appendices.....	32
Appendix 1: Images in order of presentation.....	32
Appendix 2: REDCap surveys (in three batches).....	36
Vita.....	197

Tables

Table 1. Cracks due to instrumentation by rater.....	18
Table 2. Agreement between each of the four raters.....	20-21
Table 3. Summary of agreement percentages.....	22
Table 4. Cracks by instrument type.....	23
Table 5. Results of comparing cracks by instrumentation.....	24

Figures

Figure 1. Example Rater Responses.....	13
Figure 2. Flow of Ratings – Red signifies instrumentation that leads to crack and green signifies instrumentation that does not lead to cracks (n=576 ratings).....	15
Figure 3. Cracks by Instrumentation (from Table 5).....	24

Abstract

THE INCIDENCE OF ROOT DENTINAL MICRO-CRACKS CAUSED BY RECIPROCATING AND CONTINUOUS ROTARY INSTRUMENTATION.

By Stephen Nicholas Schroeder

A thesis submitted in partial fulfillment of the requirements for the degree of Master of Science in Dentistry at Virginia Commonwealth University.

Virginia Commonwealth University, 2016

Director: Garry L. Myers, DDS
Program Director, Advanced Education Program in Endodontics

The aim of this study was to compare the incidence of root canal dentinal micro-cracks after canal instrumentation using reciprocating files (WaveOne Gold® and Twisted Adaptive®) and continuous rotation files (Edge Evolve® and EndoSequence®) in an ex-vivo benchtop study. This project used a novel methodology of finding dentinal defects using the “K-cube”, which allows evaluators to visualize sectioned root surfaces before instrumentation and after instrumentation. Mesial roots from 40 human mandibular first molars were divided into 4 groups of 10 for each file type. Root section pictures were taken with a Zeiss Discovery V20 stereomicroscope before and after canal instrumentation. Each of the pre-instrumentation and post-instrumentation images were evaluated for dentinal defects by four calibrated endodontists utilizing REDCap survey. Using a chi-square analysis, there was no statistically significant difference between dentinal defects created by continuous and reciprocating rotation ($p=0.1924$) and no difference between the four file types ($p=0.2317$).

Introduction

The removal of inflammatory or infected pulp tissue from the root canal systems of teeth has long been recognized as an essential part of root canal therapy (1). Endodontic rotary instruments are used to navigate and shape the canal system allowing disinfecting irrigants, such as sodium hypochlorite, access throughout the entire canal system reducing the number of microorganisms (2, 3). Forces generated from these rotary instruments will transfer to the dentinal walls of the root, and if excessive, can induce dentinal micro-cracks. In time, these dentinal defects may lead to vertical root fractures (VRF) which are often associated with tooth loss (4, 5).

VRF's are more commonly found in teeth with improper post placement, excessive lateral condensation forces, and excessive removal of radicular dentin (4-7). The intracanal medicament calcium hydroxide, placed for over 180 days, has also been implicated in leading to dentinal micro-cracks (8, 9). However, less is known about the causes of dentinal defects and the long-term effect on teeth and VRF's. It has been postulated that the specific type of rotation of rotary instruments may be a contributing factor in the formation of dentinal defects (10). The most commonly fractured endodontically treated teeth are maxillary second premolars and mesial roots of the mandibular molars (5).

There are many choices of endodontic instruments available to shape root canal systems in teeth. These range from hand files such as K-files and Hedstroms to engine powered rotary instrumentation with rotary files. The primary purpose of rotary instrumentation is to give a

uniform shape of the canal making it large enough for disinfecting chemicals to reach the most apical portion of the canal. The amount of dentin removed from the canal depends on the shape and size of the rotary instrument being used. Rotary instruments are made of different body tapers, tip sizes, blade configurations, and materials giving each rotary instrument a unique design leading to different degrees of dentin removal. However, it is not known what influence these different designs can confer on the remaining root dentin walls.

There are two types of rotation used in today's instrumentation techniques: continuous rotation and a reciprocating motion. Rotary Nickel Titanium (NiTi) file systems that use continuous motion rotate in complete 360-degree cycles. The continuous rotation can cause torsional and cyclic stresses. Torsional fatigue on the file occurs when the file tip binds in the canal but the shaft continues rotating. Cyclic flexion fatigue is placed on the file due to repeated tension-compression cycles created when the file bends with the canal curvature (11, 12). Both of these stresses increase the risk of instrument fracture. Rotary instruments have undergone design changes over time to minimize stresses on the instruments to prevent fracture (13).

It is claimed that the reciprocating file systems lessen the amount of stress placed on files, thus, reducing subsequent fracture of instruments (11). There are multiple types of reciprocation systems in the market, some of the most popular being WaveOne® (Dentsply Maillefer, Ballaigues, Switzerland) and Twisted Adaptive® (SybronKerr). These systems engage and disengage dentin in a counter clockwise (CCW), clockwise (CW) movement or a CW, CCW movement respectively. Each reciprocating file system has its own proprietary degree and direction of motion, giving each file system a unique reciprocating motion. Supposedly, this reciprocation movement of files decreases binding by the alternating movement and reduces flexion stress by having fewer cycles of rotation.

Dentinal defects will occur when the tensile strength of the root canal wall exceeds the tensile strength of the dentin (14). Dentinal defects can occur with any instrumentation technique using rotary NiTi files (15), and have been shown to be common with rotary techniques that have a reciprocating motion rather than the continuous motion rotation (10). There is also conflicting evidence that shows that continuous rotation rotaries may cause more dentinal micro-cracks (16). The taper of files may also increase stress on the dentinal walls, leading to increased micro-cracks (17). Reciprocation files have a larger taper associated with the files, which one can infer could lead to further increases in dentinal defects. However, according to Lam et al., the greater the apical enlargement or the greater the increase in taper did not increase fracture susceptibility of teeth (18).

Previous methods of dentinal defect detection have looked for defects after root canal instrumentation and sectioning of the teeth. The sectioning process can induce stress fractures in the dentin creating defects that may be interpreted as being formed from the rotary instrumentation process. Drying of the specimens also can lead to fractures. According to Shemesh, the natural drying process of teeth during instrumentation and cutting procedures potentially could lead to spontaneous dentinal defects and fractures of the teeth (19).

A recent investigation performed by De-Deus et al., found that use of micro computed tomographic analysis (micro CT) eliminated the need for using saws (20). The application of micro CT allowed the investigator to instrument the tooth and then examine it without the destructive effects of a Isomet saw. They found that all micro-cracks after instrumentation were present before instrumentation.

The periodontal ligament may also contribute to an anti-crack effect. According to Rose and Svec, the PDL may have a protective effect when instrumenting teeth with rotary

instrumentation. Rose and Svec instrumented teeth in sectioned pig jaws still containing PDL. The results showed no cracks induced by instrumentation (21). Many of the more recent investigations created a simulated PDL by using polyvinylsiloxane, however, it is not known if this is an appropriate simulation of the PDL and if it has any influence on the results.

The aim of this investigation was to compare the incidence of root canal micro-crack formation after preparation with reciprocating files (WaveOne Gold® and Twisted Adaptive®) and continuous rotation files (Edge Evolve® and EndoSequence®). This project also used a novel methodology of evaluating dentinal defects. The methodology used was a device known as the K-cube which allows the investigator to visualize the root dentin before instrumentation and after instrumentation, giving a more accurate representation of the effects of instrumentation on root dentin (22).

Methods

Mesial roots with closed apices and visible canals with less than 10 degrees of curvature from 40 human mandibular first molars were selected for this study. Teeth were visualized with a stereomicroscope (Zeiss Discovery V20 Stereo zoom microscope with transmitted, reflection and fluorescence illumination) to exclude any roots with visible external cracks. Each of the mandibular molars had approximately 16 mm of the mesial root sectioned from the crown using an Isomet low-speed saw with a 0.50 mm thick diamond blade while irrigating with water. Lengths of the mesial canals were determined using size 15 K-files. The file was inserted into the canal until it was visualized at the apical foramen. One mm was then subtracted from the length of the file at the apical foramen to determine the final working length. Acrylic resin was placed in the K-cube and the mesial root placed in the resin. The K-cube secured the tooth in the acrylic. Once the acrylic had cured, the acrylic block with the tooth was removed from the K-cube.

The acrylic block containing the root was then sectioned every 4 mm with the Isomet low-speed saw while irrigating with water. The sectioning resulted in three sections of the mesial root in acrylic. The pre-rotary instrumentation images of the coronal sectioned root were then photographed using the Zeiss Discovery stereomicroscope and subsequently assessed for any cracks inherent in the sample or caused by sectioning. Each pre-instrumentation image for the root was to be used as the control prior to canal instrumentation.

The three acrylic root sections were reassembled and secured in the K-cube prior to instrumentation. Each root was randomly assigned to one of four groups and instrumented

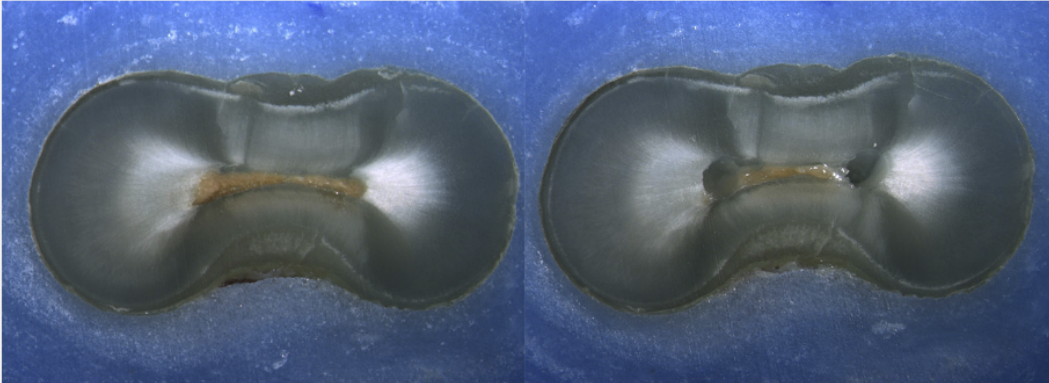
according to the group they were assigned. Each group consisted of 10 roots. Group 1 was instrumented with Edge Evolve® files using a continuous rotation “crown down” technique to an apical size 35/0.04 (23, 24). Group 2 was instrumented with EndoSequence® files using a continuous rotation “crown down” technique to a size 35/0.04. Group 3 was instrumented according to the manufacturer’s instructions with WaveOne Gold® Primary files using a reciprocating motion to a size 25/0.08 (variable taper). The WaveOne® reciprocating motion was driven by a dedicated motor configured for these files (Dentsply® motor). Group 4 was instrumented with Twisted Adaptive® files using a reciprocating motion to a size ML2 35/0.04 (variable taper). Twisted Adaptive® instruments were driven by a dedicated motor (Elements Adaptive motor, SybronEndo) that automatically adapted the motion to a continuous rotary or reciprocating movement depending on the stress induced over the instrument during instrumentation. After instrumentation was completed for each root the sections were disassembled and post-instrumentation images of the coronal sectioned root surfaces were photographed using the Zeiss Discovery stereomicroscope

Each root section’s pre-instrumentation and post-instrumentation images were then compared side-by-side and evaluated for the presence of dentinal defects by four endodontists. Each evaluator completed their evaluations independently. The evaluators were calibrated ahead of time by viewing a series of slides illustrating no defects, incomplete cracks, and complete cracks. No dentinal defect consisted of no craze lines, micro-cracks, or fractures. Incomplete micro-cracks extended from the canal towards the external surface of the root, or extended from the external surface of the root towards the canal. Complete micro-cracks extended from the canal wall to the external surface of the root.

The evaluators were asked a series of questions regarding the samples they investigated and entered their findings into a REDCap database. The questions were designed to be displayed sequentially so that the answer to an earlier question would determine the subsequent questions to be answered. For example, see Figure 1.

Figure 1. Example Rater Responses

Image: i133.jpg
Pre-Op on the left and Post-Op on the right



Is there any evidence of a dentinal crack prior to rotary instrumentation (Pre-Op)?
* must provide value

Yes
 No

Does the crack in the Pre-Op image increase in size when viewed in the Post-Op image?
 Yes
 No

Is the crack that increased in the Pre-Op image now:
* must provide value

an Incomplete Crack from the canal towards the root surface
 an Incomplete Crack from the root surface towards the canal
 A complete crack

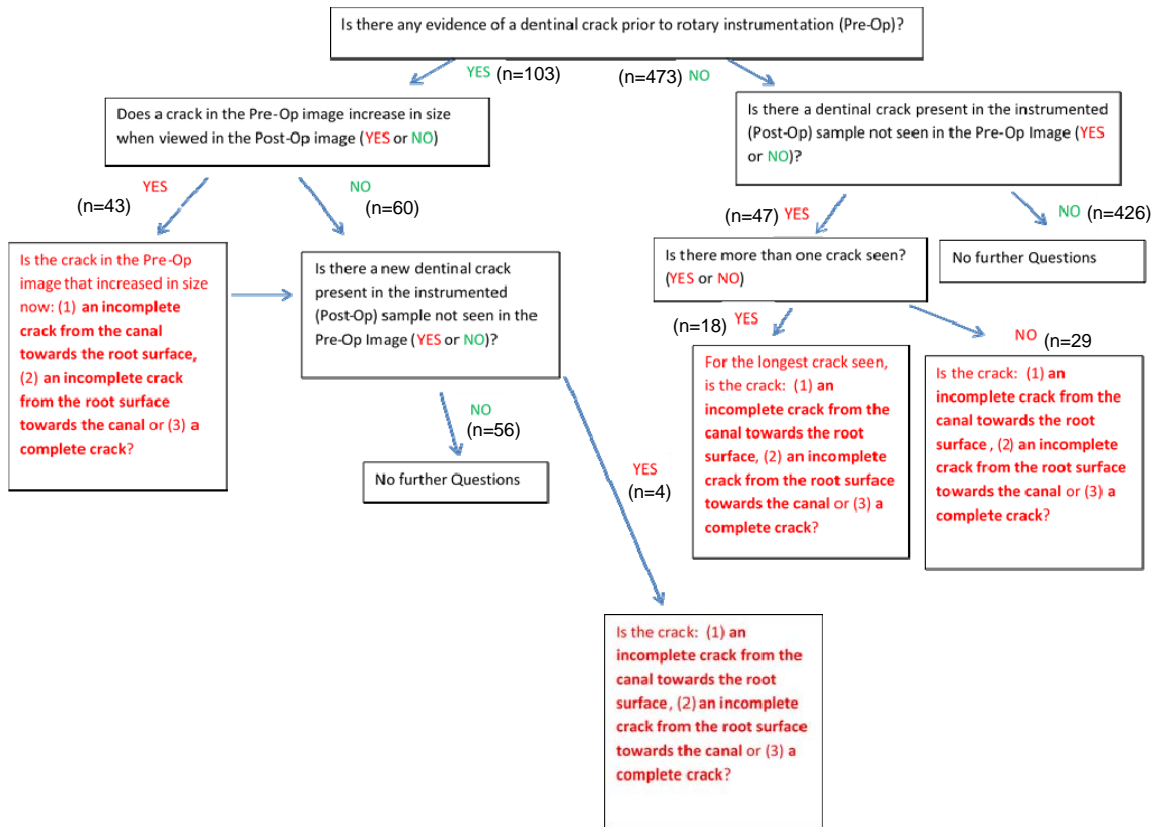
Is there a new dentinal crack present in the instrumented (Post-Op) sample not seen in the Pre-Op image?
 Yes
 No

Done. Go to next page

Initially, all that is displayed is the caption “Pre-Op on the left and Post-Op on the right” above the sectioned root image and the first question: “Is there any evidence of a dentinal crack prior to rotary instrumentation (Pre-Op)?” If the rater replies “Yes” then questions regarding the Pre-Op crack appear. If the rater replies “No” then no Pre-Op questions appear and instead a series of Post-Op questions appears. Figure 1 illustrates the “Yes” response indicated and so the second

question appeared: “Does the crack in the Pre-Op image increase in size when viewed in the Post-Op image?” If the rater had replied “No” a different set of questions would have been displayed (not shown). However, in Figure 1 the reply was “Yes”, so a third question appeared: “Is the crack that increased in the Pre-Op image now:” with three available answer options. A response of “an Incomplete Crack from the root surface towards the canal” was indicated. This represented a type of a micro-crack “caused by instrumentation”. When this response was indicated, the fourth question displayed was, “Is there a new dentinal crack present in the instrumented (Post-Op) sample not seen in the Pre-Op image?” If the answer had been “Yes” then questions about that crack would have appeared, but in Figure 1 the answer was “No” and so all the questions relevant to this image set were complete and the rater moved on to the next set of images. The questions and their conditional flow are shown in Figure 2. The same questions were available for all images.

Figure 2. Flow of Ratings – Red signifies instrumentation that leads to crack and green signifies instrumentation that does not lead to cracks (n = 576 ratings)



There were nine questions possible but, due to the conditional flow, as few as 2 or as many as 5 were necessary for a single image. The responses to the questions were summarized to determine the primary outcome for each image, that is, whether instrumentation seemed to have resulted in dentinal micro-crack formation. Specifically, there were two paths through the questions where Cracks Due to Instrumentation=No was indicated. The first path was “Is there any evidence of a dentinal crack prior to rotary instrumentation (Pre-Op)?”=No followed by “Is there a dentinal crack present in the instrumented (Post-Op) sample not seen in the Pre-Op image?”=No. The second path was “Is there any evidence of a dentinal crack prior to rotary instrumentation (Pre-Op)?”=Yes, followed by “Does the crack in the Pre-Op image increase in

size when viewed in the Post-Op image?”=No and then “Is there a new dentinal crack present in the instrumented (Post-Op) sample not seen in the Pre-Op image?”=No. All other paths through the question series resulted in Cracks Due to Instrumentation=Yes.

The evaluators responses were compared using a repeated-measures logistic regression analysis that takes into account the correlation of ratings within a rater and the difference in ratings potentially due to: Instrumentation (4 groups), Rater (four raters), and tooth section (3 sections). The SAS Genmod procedure used an unstructured covariance to account for the repeated assessments made by the four raters across the 120 images. All analyses were performed using SAS software (SAS version 9.4, JMP version 11.2, SAS Institute Inc., Cary NC, USA). Statistical significance was declared at $\alpha = 0.05$.

Results

Four Endodontists each rated 144 “Pre-op” and “Post-op” images for signs of micro-cracks. Figure 2 shows the flow of ratings. All ratings in red signify micro-cracks that were due to instrumentation, while all green ratings signify instrumentation that did not cause micro-cracks. In the first question, if the answer was yes and there was evidence of a micro-crack present prior to rotary instrumentation that micro-crack would be compared to the post-op image to see if the micro-crack had increased in size. If the crack did not increase in size this meant instrumentation did not affect the crack inherent in the sample and the post op image would then be looked at to see if new dentinal micro-cracks developed. If no new micro-cracks were seen no further questions were asked and the reviewer would go to the next sample. If the pre-op crack did increase in size in the post op image this implied that instrumentation had caused the micro-crack to become larger, thus, analysis of the crack was performed describing it as being an incomplete micro-crack (from the canal towards the root surface or the root surface towards the canal) or a complete micro-crack. The post-op image was analyzed to see if any new micro-cracks developed and if there were new cracks the crack would be analyzed. If no new micro-cracks were seen then the reviewer would proceed on to the next sample. If the reviewer found that there was no evidence of a micro-crack before instrumentation they would look at the post-op sample to see if any new micro-cracks developed. If more than one crack was found they would analyze the longest crack as being an incomplete micro-crack (from the canal towards the root surface or the root surface towards the canal) or a complete micro-crack. If only one micro-crack was found they would analyze the crack as described previously.

In the resulting 576 ratings, 94 images were identified as having micro-cracks present due to instrumentation (16.3%). The predominant rating was that there was neither a crack in the pre-op nor the post-op image (73%, 426/576) followed by a rating that there was a micro-crack present in the pre-op image but it remained unchanged in the post-op image (9.7%, 56/576). Of the micro-cracks identified as being due to instrumentation, 5.2% were identified as being present in the pre-op image and then increasing in length in the post-op image, with no new micro-cracks evident in the post-op image (30/576). An additional 5% were single cracks only visible on the post-op image (29/576) and 3.1% were multiple cracks only visible on the post-op image (18/576). There were 2.2% that were both enlarged after appearing on the pre-op image and also additional cracks appearing on the post-op image (13/576). And four images (0.7%) displayed an enlarged pre-op crack and a new crack appearing on the post-op image.

The four raters had significantly different prevalence of micro-cracks (Table 1, chi-square = 32.9, df=3, P < .0001). One rater reported as few as 5 cracks (3.5%) and another reported as high as 53 cracks (36.8%).

Table 1. Cracks due to instrumentation by rater

Rater	Cracks due to instrumentation		Total
	No	Yes	
Rater A	131	13	144
	91.0%	9.0%	
Rater B	121	23	144
	84.0%	16.0%	
Rater C	91	53	144
	63.2%	36.8%	
Rater D	139	5	144
	96.5%	3.5%	
Total	482	94	576
	83.7%	16.3%	

Significantly different (chi-square = 32.9, df=3, P < .0001).

Reliability

There are two aspects of reliability reported here: agreement and reproducibility.

Agreement between the four raters will be discussed first. With four raters, there were six paired comparisons and each are shown in Table 2. In the top panel, we see that A and B agreed in 118 (NO's) +10 (YES's) of the 144 cases for an exact agreement of 89%. The Kappa coefficient is a chance-corrected index of agreement. Its value was a more modest 50%. Agreement was made the more difficult as A reported micro-cracks due to instrumentation in 9.0% of the cases and B's prevalence was 16.0%; and this was significantly different ($P = 0.0124$). In the next pair we see that C had higher prevalence of 36.8% than A which had a 9.0% prevalence ($P = <0.0001$). Pair C and A agreed in 65.3% of the cases with its Kappa coefficient value being a slight agreement of 11.4%. In the next pair we see that rater D reported the fewest cracks due to instrumentation at 3.5% and rater A reported 9.0% prevalence of cracks ($P=0.0209$). Pair D and A agreed in 91.7% of the cases with its Kappa coefficient indicated fair agreement at 29.8%. In the next pair rater C had the highest prevalence of cracks with 36.8% and rater B prevalence of cracks was 16.0% ($P=<0.0001$). Pair C and B agreed in 66.7% of cases with its Kappa coefficient value being at slight agreement at 18.7%. The next pair rater D had a prevalence of cracks at 3.5% and rater B had a prevalence of 16.0% ($P=0.0001$). Pair D and B agreed in 84.7% of cases with its Kappa coefficient value being at slight agreement with 16.7%. The last pair rater D had a prevalence of micro-cracks of 3.5% and rater C prevalence of micro-cracks at 36.8% ($P=<0.0001$). Pair D and C agreed in 66.7% of cases with its Kappa coefficient value being at slight agreement with 11.6%.

Table 2. Agreement between each of the four raters

Rater_A	Rater_B		Total
	No	Yes	
No	118 81.9%	13 9.0%	131 91.0%
Yes	3 2.1%	10 6.9%	13 9.0%
Total	121 84.0%	23 16.0%	144 100.0%

Test: Prevalence difference (P = 0.0124)

Agreement: Exact = 88.9%, Kappa = 49.8

Rater_A	Rater_C		Total
	No	Yes	
No	86 59.7%	45 31.3%	131 91.0%
Yes	5 3.5%	8 5.6%	13 9.0%
Total	91 63.2%	53 36.8%	144 100.0%

Test: Prevalence difference (P = <.0001)

Agreement: Exact = 65.3%, Kappa = 11.4

Rater_A	Rater_D		Total
	Yes	Total	
No	129 89.6%	2 1.4%	131 91.0%
Yes	10 6.9%	3 2.1%	13 9.0%
Total	139 96.5%	5 3.5%	144 100.0%

Test: Prevalence difference (P = 0.0209)

Agreement: Exact = 91.7%, Kappa = 29.8

Rater_B	Rater_C		Total
	No	Yes	
No	82	39	121
	56.9%	27.1%	84.0%
Yes	9	14	23
	6.3%	9.7%	16.0%
Total	91	53	144
	63.2%	36.8%	100.0%

Test: Prevalence difference (P = <.0001)
 Agreement: Exact = 66.7%, Kappa = 18.7

Rater_B	Rater_D		Total
	No	Yes	
No	119	2	121
	82.6%	1.4%	84.0%
Yes	20	3	23
	13.9%	2.1%	16.0%
Total	139	5	144
	96.5%	3.5%	100.0%

Test: Prevalence difference (P = 0.0001)
 Agreement: Exact = 84.7%, Kappa = 16.7

Rater_C	Rater_D		Total
	No	Yes	
No	91	0	91
	63.2%	0.0%	63.2%
Yes	48	5	53
	33.3%	3.5%	36.8%
Total	139	5	144
	96.5%	3.5%	100.0%

Test: Prevalence difference (P = <.0001)
 Agreement: Exact = 66.7%, Kappa = 11.6

The agreement between the four raters is summarized in Table 3. There was modest agreement between the first two raters A and B. There was less agreement in prevalence of micro-cracks amongst the other raters.

Table 3. Summary of agreement percentages

	Prevalence	Exact Agreement (Kappa)		
		Rater B	Rater C	Rater D
Rater A	9.0	88.9 (49.8)	65.3 (11.4)	91.7 (29.8)
Rater B	16.0		66.7 (18.7)	84.7 (16.7)
Rater C	36.8			66.7 (11.6)
Rater D	3.5			

Reproducibility was assessed by observing how often each of the raters gave identical assessments to identical duplicate images. This was performed to identify how often the rater agreed with themselves. Again, this assessment was limited due to the apparently low prevalence of micro-cracks. Across the 96 ratings of duplicate images there were no cracks reported in 75 of the pairs (78.1%). Were a crack to actually be evident, there is the possibility that there would be 8 ratings of Crack=Yes. This did occur once, in the case of the example illustrated in Figure 1 (Sample 4 Section 3 TW.jpg). There was one (of 24) image where five (of 8) of the ratings indicated Crack=Yes (Sample 31 Section 3 Edge.jpg). Across the 96 duplicated images, both images were rated as Crack=No in 75 instances (78%), and both images were rated as Crack=Yes in 10 instances (10%). In 11 images (11%) there was disagreement, one rating was Crack=Yes and the other was Crack=No. For each rater, the results of rating duplicate images were as follows. Rater A indicated “No” for 22 images on both occasions, “Yes” for 1 image on both occasions, and gave different ratings on one occasion. Rater B indicated “No” for both images in 18 cases, “Yes” for both images in 3 cases and gave different ratings on the remaining 3 cases. Rater C indicated “No” for both images in 14 cases, “Yes” for both images in 5 cases

and gave different ratings on the remaining 5 cases. Rater D indicated “No” for both images in 21 cases, “Yes” for both in one case, and indicated different ratings in two cases.

Analysis of cracks by instrumentation type

The purpose of this study was to compare the percentage of micro-cracks created by the four instrumentation types, and in particular, a comparison between the continuous and reciprocating types. Table 4 shows the raw counts and percentages for the four instrument groups.

Table 4. Cracks by instrument type

Instrument	Crack due to instrumentation		Total
	No	Yes	
ES	120 85.7%	20 14.3%	140
Edge	125 80.1%	31 19.9%	156
TW	119 80.4%	29 19.6%	148
WO	118 89.4%	14 10.6%	132
Total	482 83.7%	94 16.3%	576

Abbreviations: ES=EndoSequence®, Edge=Edge Evolve®, TW=Twisted Adaptive®, WO=WaveOne Gold®

Nominally, WO had the lowest percentage of cracks (10.6%) and Edge had the highest (19.9%) but these raw results should not be taken as definitive. As we have seen, there are differences due to raters and the ratings within a rater are correlated. So, a repeated-measures logistic regression model was used to take the following factors into account: Potential differences due to Instrument, Rater, or Section. As observed in the raw data in Table 1, the logistic regression results confirmed that there was a rater difference (chi-square = 27.9, df=3, P < 0.0001). There was no statistically significant difference between the three sections (chi-square = 0.3, df=2, P =

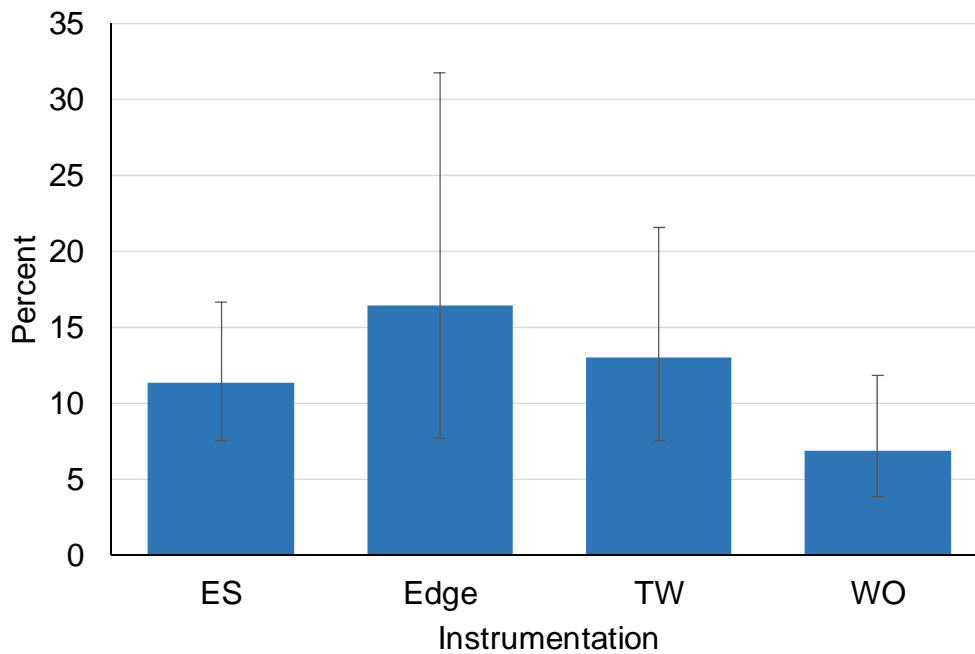
0.8597). After adjusting for these differences, there was no significant difference between the four instrumentation types (chi-square = 4.29, df=3, P = 0.2317), or between the two groups of instrumentation techniques (chi-square = 1.70, df=1, P = 0.1924). The percentages in Table 5 are interpreted as the percentages of micro-cracks for the average rater at the average section. For example of the data from Table 5 in a bar graph, see Figure 3.

Table 5. Results of comparing cracks by instrumentation

Instrumentation	Percent	95% CI	
ES	11.31	7.54	16.61
Edge	16.41	7.66	31.72
TW	12.96	7.48	21.52
WO	6.83	3.86	11.80

Repeated-measures logistic regression results: no significant difference between the four instrumentation types (chi-square = 4.29, df=3, P = 0.2317), or between the two groups (ES+Edge vs TW+WO) of instrumentation types (chi-square = 1.70, df=1, P = 0.1924).

Figure 3. Cracks by Instrumentation (from Table 5)



Discussion

Research devoted to investigating the creation of micro-cracks due to rotary instrumentation has fundamental flaws in the design. The most common method of researching micro-cracks is by sectioning instrumented roots using an isomet saw and comparing them to a set of control teeth that were sectioned without any prior instrumentation. This method of control is weak, as it is not known if inherent defects in the teeth were present before the sectioning process. These pre-existing natural defects could be misidentified as micro-cracks. The sectioning process can be destructive on root dentin creating defects in the sample that were not present before the sectioning process biasing the instrumented samples.

Newer technologies have improved the study design of micro-crack experiments. Technology such as Micro-CT is one such improvement. Micro-CT is highly accurate, non-destructive, and the tooth serves as its own control. However, this technology is expensive and the technical procedure is complex and time-consuming.

The design of this research study utilized a new methodology of evaluating micro-cracks using the K-cube. The K-cube, created by Steven Klyn and Timothy Kirkpatrick, allows a tooth to be sectioned, reassembled, instrumented, and then disassembled to evaluate the presence of micro-cracks before and after instrumentation (22). This provided the opportunity to investigate micro-cracks after the destructive sectioning process by having a picture of the root section before instrumentation. This study design is the first in micro-crack studies to allow the tooth to be its own control when sectioned.

There was concern that the K-cube may not realign the sectioned roots accurately, effectively blocking the canals during instrumentation. However, pilot studies revealed that this was not an issue. Before instrumentation, a small 10 or 15 K-file could navigate the reassembled sectioned teeth with ease. This method gave an effective glide path of the canal to introduce the rotary files in the canal system without ledging or forcing the files between sections.

One limitation of this study design was the lack of a simulated PDL. Clinically, the PDL and bone may act as a cushion to the tooth during instrumentation, allowing forces from instrumentation to be distributed in a passive manner. Other micro-crack studies have simulated a PDL by using polyvinylsiloxane. This was not able to be done with the K-cube as the sectioning process combined with a thin polyvinylsiloxane cushion led to the root sections not being retained in the acrylic block. However, it is not known if a simulated PDL adds any benefit to dentinal micro-crack studies as the benefit of a simulated PDL has not been adequately researched. Thus, it was decided that a simulated PDL would not be used in this study.

It has also been reported that the biomechanical response of root dentin is influenced by the hydration of root dentin. Lim et al used a customized high-sensitivity digital moiré interferometry to qualitatively evaluate dentinal microstrain during instrumentation. Dentin that was hydrated had only minor changes in post instrumentation microstrain, however, non-hydrated dentin showed localized microstrain after instrumentation. This increased microstrain when instrumenting in a dry tooth may lead to the creation of more micro-cracks. Because of this information, teeth were constantly bathed in saline while being instrumented in this study (25). However, the minor gaps from the sectioning process caused the saline to leak out of the samples into the K-cube during instrumentation. This may have caused the samples to become dry leading to a higher incidence of micro-cracks.

In this study, 16.3% of observed micro-cracks were due to rotary instrumentation. This finding is consistent with other studies. Bier et al. found an average incidence of 7% of micro-cracks due to rotary instrumentation (sample size of 200). Ustun et al found an average incidence of 9.6% of micro-cracks due to rotary instrumentation (sample size of 80), and Burklein et al. found an average incidence of 25.4% of micro-cracks due to rotary instrumentation (sample size of 80). The average incidence of micro-cracks in this study falls into the range of these other studies, despite the smaller sample size. An interesting finding that other study designs have not been able to demonstrate is the effect instrumentation has on pre-existing micro-cracks. In this study, 5.2% of the pre-existing micro- increased in size after canal instrumentation. This illustrates that pre-existing micro-cracks may increase in size due to the stress of the file on the tooth.

Current studies on reciprocating systems causing micro-cracks are limited and conflicting. This study found that there was no significant difference between reciprocating or continuous rotary instrumentation creating micro-cracks. There was also no significant difference between the four instrument types used - EndoSequence®, Edge Evolve®, Twisted Adaptive®, and WaveOne Gold®. WaveOne Gold® had the fewest observed new micro-cracks. This may be because WaveOne® files are a single file system. The less instrumentation performed in the canal would reduce the amount of time the rotary instrument is in contact with dentin and in theory, reduce the incidence of micro-crack formation. While instrumenting the samples in this study, WaveOne Gold® did reach length the fastest, while Edge Evolve® took the longest time to instrument the samples, and coincidentally had the most micro-cracks identified. The amount of time instrumenting the canal system may be a factor that leads to more micro-cracks being created during instrumentation.

As a side note, no instrument separated during instrumentation, however, every Twisted Adaptive® file did unwind after instrumentation. It is not known if this common occurrence was a result of being used on a tooth confined in an acrylic block.

The results suggest that dentinal micro-cracks, while infrequent can be created by either of the two rotary instrumentation motions used in this study. However, it is not known if micro-cracks are a clinically significant problem. No study has shown that micro-cracks will become root fractures, thereby necessitating extraction of the tooth. Micro-cracks may be normal defects that occur during instrumentation which are benign and do not affect the prognosis of the tooth. More research in this area is needed.

Among the four evaluators there was modest agreement among raters A and B and slight agreement amongst the rest. This discrepancy may be due to the nature of visualizing micro-cracks. It can be difficult to distinguish what is a natural dentinal defect versus a micro-crack due to instrumentation. The lighting from the stereomicroscope before and after instrumentation was constant; however, the removal of dentin and potential drying of the teeth may have led to different reflections from the surface. This could lead to micro-cracks being misidentified, or the lighting could even obscure the view of micro-cracks. Consideration was given to using transillumination to visualize micro-cracks. Coelho et al. looked at using a light emitting diode instead of stereomicroscopy lighting, however, they found that there was no difference in the visualization of the defects (26). Being able to identify and visualize cracks consistently with lighting is an area that needs to be investigated further.

Another potential reason for the discrepancy amongst the raters is that the calibration session given may not have been adequate in explaining what to look for in micro-cracks. While all raters were given the same calibration session, it was given at different times for each rater. It

is possible raters misunderstood what to look for or it was poorly explained during their calibration session.

The study design also duplicated images to see how the raters would respond to the same picture at different times. This would provide an assessment of how the raters agreed with themselves. The results of this showed that raters were very consistent in agreement with themselves.

In conclusion, the K-cube proved to be a novel method of investigating micro-cracks and has potential to be further explored in micro-crack research. Reciprocating and continuous rotary instrumentation and instrument type showed no significant difference in prevalence of micro-crack formation. Additional studies need to be performed in how micro-cracks affect the prognosis of teeth.

References

1. Kakehasi S, Stanley HR, Fitzgerald RJ. The effects of surgical exposures of dental pulps in germ-free and conventional laboratory rats. *Oral Surg Oral Med Oral Pathol.* 1965;20:340-9.
2. Hand RE, Smith ML, Harrison JW. Analysis of the effect of dilution on the necrotic tissue dissolution property of sodium hypochlorite. *J Endod.* 1978;4:60-4.
3. Brunson M, Heilborn C, Johnson DJ, Cohenca N. Effect of apical preparation size and preparation taper on irrigant volume delivered by using negative pressure irrigation system. *J Endod.* 2010;36:721-4.
4. Barreto MS, Moraes RdA, Rosa RAd, Moreira CHC, Só MVR, Bier CAS. Vertical root fractures and dentin defects: Effects of root canal preparation, filling, and mechanical cycling. *J Endod.* 2012;38:1135-9.
5. Tamse A, Fuss Z, Lustig J, Kaplavi J. An evaluation of endodontically treated vertically fractured teeth. *J Endod.* 1999;25:506-8.
6. Wilcox LR, Roskelley C, Sutton T. The relationship of root canal enlargement to finger-spreader induced vertical root fracture. *J Endod.* 1997;23:533-4.
7. Fuss Z, Lustig J, Katz A, Tamse A. An evaluation of endodontically treated vertical root fractured teeth: Impact of operative procedures. *J Endod.* 2001;27:46-8.
8. Doyon GE, Dumsha T, von Fraunhofer JA. Fracture resistance of human root dentin exposed to intracanal calcium hydroxide. *J Endod.* 2005;31:895-7.
9. Zarei M, Afkhami F, Malek Poor Z. Fracture resistance of human root dentin exposed to calcium hydroxide intervisit medication at various time periods: An in vitro study. *Dental traumatology.* 2013;29:156-60.
10. Bürklein S, Tsotsis P, Schäfer E. Incidence of dentinal defects after root canal preparation: Reciprocating versus rotary instrumentation. *J Endod.* 2013;39:501-4.
11. Varela-Patiño P, Ibañez-Párraga A, Rivas-Mundiña B, Cantatore G, Otero XL, Martín-Biedma B. Alternating versus continuous rotation: A comparative study of the effect on instrument life. *J Endod.* 2010;36:157-9.
12. Sattapan B, Palamara JE, Messer HH. Torque during canal instrumentation using rotary nickel-titanium files. *J Endod.* 2000;26:156-60.

13. Gambarini G, Grande NM, Plotino G, Somma F, Garala M, De Luca M, et al. Fatigue resistance of engine-driven rotary nickel-titanium instruments produced by new manufacturing methods. *J Endod.* 2008;34:1003-5.
14. Hülsmann M. Effects of mechanical instrumentation and chemical irrigation on the root canal dentin and surrounding tissues. *Endodontic Topics.* 2013;29:55-86.
15. Bier CAS, Shemesh H, Tanomaru-Filho M, Wesselink PR, Wu M. The ability of different nickel-titanium rotary instruments to induce dentinal damage during canal preparation. *J Endod.* 2009;35:236-8.
16. Ashwinkumar V, Krithikadatta J, Surendran S, Velmurugan N. Effect of reciprocating file motion on microcrack formation in root canals: An SEM study. *Int Endod J.* 2014;47:622-7.
17. Kansal R, Rajput A, Talwar S, Roongta R, Verma M. Assessment of dentinal damage during canal preparation using reciprocating and rotary files. *J Endod.* 2014;40:1443-6.
18. Lam PPS, Palamara JEA, Messer HH. Fracture strength of tooth roots following canal preparation by hand and rotary instrumentation. *J Endod.* 2005;31:529-32.
19. Shemesh H. Endodontic instrumentation and root filling procedures: Effect on mechanical integrity of dentin. *Endodontic Topics.* 2015;33:43-9.
20. De-Deus G, Belladonna FG, Souza EM, Silva EJNL, Neves AdA, Alves H, et al. Micro-computed tomographic assessment on the effect of ProTaper next and twisted file adaptive systems on dentinal cracks. *J Endod.* 2015;41:1116-9.
21. Rose E, Svec T. An evaluation of apical cracks in teeth undergoing orthograde root canal instrumentation. *J Endod.* 2015;41:2021-4.
22. Klyn SL, Kirkpatrick TC, Rutledge RE. In vitro comparisons of debris removal of the EndoActivator system, the F file, ultrasonic irrigation, and NaOCl irrigation alone after hand-rotary instrumentation in human mandibular molars. *J Endod.* 2010;36:1367-71.
23. Morgan LF, Montgomery S. An evaluation of the crown-down pressureless technique. *J Endod.* 1984;10:491-8.
24. Salzgeber RM, Brilliant JD. An in vivo evaluation of the penetration of an irrigating solution in root canals. *J Endod.* 1977;3:394-8.
25. Lim H, Li F, Friedman S, Kishen A. Residual microstrain in root dentin after canal instrumentation measured with digital moiré interferometry. *J Endod.* 2016;42:1397-402.
26. Coelho MS, Card SJ, Tawil PZ. Light-emitting diode assessment of dentinal defects after root canal preparation with profile, TRUShape, and WaveOne gold systems. *J Endod.* 2016;42:1393-6.

Appendices

Appendix 1: Images in order of presentation

File	Image #	Sample	Section	Instrumentation
	Batch 1			
Sample 14 Section 3 ES.jpg	1	14	3	ES
Sample 3 Section 1 WO.jpg	2	3	1	WO
Sample 19 Section 1 ES.jpg	3	19	1	ES
Sample 18 Section 3 TW.jpg	4	18	3	TW
Sample 38 Section 1 Edge.jpg	5	38	1	Edge
Sample 37 Section 3 WO.jpg	6	37	3	WO
Sample 8 Section 3 WO.jpg	7	8	3	WO
Sample 5 Section 2 TW.jpg	8	5	2	TW
Sample 37 Section 2 WO.jpg	9	37	2	WO
Sample 21 Section 3 Edge.jpg	10	21	3	Edge
Sample 37 Section 3 WO.jpg	11	37	3	WO
Sample 10 Section 3 Edge.jpg	12	10	3	Edge
Sample 5 Section 2 TW.jpg	13	5	2	TW
Sample 8 Section 3 WO.jpg	14	8	3	WO
Sample 9 Section 2 Edge.jpg	15	9	2	Edge
Sample 20 Section 2 Edge.jpg	16	20	2	Edge
Sample 26 Section 2 TW.jpg	17	26	2	TW
Sample 32 Section 2 TW.jpg	18	32	2	TW
Sample 37 Section 1 WO.jpg	19	37	1	WO
Sample 10 Section 2 Edge.jpg	20	10	2	Edge
Sample 29 Section 3 ES.jpg	21	29	3	ES
Sample 19 Section 1 ES.jpg	22	19	1	ES
Sample 11 Section 2 WO.jpg	23	11	2	WO
Sample 21 Section 2 Edge.jpg	24	21	2	Edge
Sample 6 Section 2 Edge.jpg	25	6	2	Edge
Sample 12 Section 2 ES.jpg	26	12	2	ES
Sample 20 Section 1 Edge.jpg	27	20	1	Edge
Sample 3 Section 2 WO.jpg	28	3	2	WO
Sample 1 Section 2 Edge.jpg	29	1	2	Edge
Sample 32 Section 3 TW.jpg	30	32	3	TW
Sample 34 Section 1 WO.jpg	31	34	1	WO

File	Image #	Sample	Section	Instrumentation
Sample 28 Section 1 WO.jpg	32	28	1	WO
Sample 8 Section 2 WO.jpg	33	8	2	WO
Sample 31 Section 1 Edge.jpg	34	31	1	Edge
Sample 33 Section 1 ES.jpg	35	33	1	ES
Sample 17 Section 3 WO.jpg	36	17	3	WO
Sample 21 Section 1 Edge.jpg	37	21	1	Edge
Sample 39 Section 2 ES.jpg	38	39	2	ES
Sample 35 Section 1 ES.jpg	39	35	1	ES
Sample 21 Section 3 Edge.jpg	40	21	3	Edge
Sample 6 Section 3 Edge.jpg	41	6	3	Edge
Sample 27 Section 3 TW.jpg	42	27	3	TW
Sample 1 Section 3 Edge.jpg	43	1	3	Edge
Sample 13 Section 1 TW.jpg	44	13	1	TW
Sample 12 Section 2 ES.jpg	45	12	2	ES
Sample 14 Section 3 ES.jpg	46	14	3	ES
Sample 21 Section 2 Edge.jpg	47	21	2	Edge
Sample 28 Section 3 WO.jpg	48	28	3	WO
Batch 2				
Sample 35 Section 2 ES.jpg	49	35	2	ES
Sample 18 Section 2 TW.jpg	50	18	2	TW
Sample 38 Section 3 Edge.jpg	51	38	3	Edge
Sample 31 Section 3 Edge.jpg	52	31	3	Edge
Sample 16 Section 2 TW.jpg	53	16	2	TW
Sample 2 Section 2 TW.jpg	54	2	2	TW
Sample 15 Section 2 ES.jpg	55	15	2	ES
Sample 26 Section 3 TW.jpg	56	26	3	TW
Sample 4 Section 2 TW.jpg	57	4	2	TW
Sample 39 Section 3 ES.jpg	58	39	3	ES
Sample 16 Section 1 TW.jpg	59	16	1	TW
Sample 13 Section 3 TW.jpg	60	13	3	TW
Sample 2 Section 3 TW.jpg	61	2	3	TW
Sample 38 Section 3 Edge.jpg	62	38	3	Edge
Sample 5 Section 1 TW.jpg	63	5	1	TW
Sample 2 Section 2 TW.jpg	64	2	2	TW
Sample 28 Section 2 WO.jpg	65	28	2	WO
Sample 23 Section 3 WO.jpg	66	23	3	WO
Sample 40 Section 2 Edge.jpg	67	40	2	Edge
Sample 16 Section 1 TW.jpg	68	16	1	TW
Sample 12 Section 1 ES.jpg	69	12	1	ES
Sample 4 Section 1 TW.jpg	70	4	1	TW

File	Image #	Sample	Section	Instrumentation
Sample 11 Section 3 WO.jpg	71	11	3	WO
Sample 1 Section 1 Edge.jpg	72	1	1	Edge
Sample 7 Section 2 ES.jpg	73	7	2	ES
Sample 24 Section 3 Edge.jpg	74	24	3	Edge
Sample 19 Section 3 ES.jpg	75	19	3	ES
Sample 20 Section 3 Edge.jpg	76	20	3	Edge
Sample 3 Section 3 WO.jpg	77	3	3	WO
Sample 22 Section 1 TW.jpg	78	22	1	TW
Sample 31 Section 3 Edge.jpg	79	31	3	Edge
Sample 30 Section 3 ES.jpg	80	30	3	ES
Sample 4 Section 2 TW.jpg	81	4	2	TW
Sample 20 Section 3 Edge.jpg	82	20	3	Edge
Sample 15 Section 1 ES.jpg	83	15	1	ES
Sample 24 Section 2 Edge.jpg	84	24	2	Edge
Sample 9 Section 1 Edge.jpg	85	9	1	Edge
Sample 4 Section 1 TW.jpg	86	4	1	TW
Sample 25 Section 1 WO.jpg	87	25	1	WO
Sample 30 Section 1 ES.jpg	88	30	1	ES
Sample 35 Section 3 ES.jpg	89	35	3	ES
Sample 11 Section 1 WO.jpg	90	11	1	WO
Sample 19 Section 2 ES.jpg	91	19	2	ES
Sample 39 Section 3 ES.jpg	92	39	3	ES
Sample 31 Section 2 Edge.jpg	93	31	2	Edge
Sample 30 Section 2 ES.jpg	94	30	2	ES
Sample 36 Section 1 WO.jpg	95	36	1	WO
Sample 9 Section 3 Edge.jpg	96	9	3	Edge
Batch 3				
Sample 6 Section 1 Edge.jpg	97	6	1	Edge
Sample 39 Section 1 ES.jpg	98	39	1	ES
Sample 23 Section 1 WO.jpg	99	23	1	WO
Sample 8 Section 1 WO.jpg	100	8	1	WO
Sample 36 Section 2 WO.jpg	101	36	2	WO
Sample 22 Section 2 TW.jpg	102	22	2	TW
Sample 29 Section 1 ES.jpg	103	29	1	ES
Sample 17 Section 1 WO.jpg	104	17	1	WO
Sample 24 Section 1 Edge.jpg	105	24	1	Edge
Sample 40 Section 1 Edge.jpg	106	40	1	Edge
Sample 16 Section 3 TW.jpg	107	16	3	TW
Sample 25 Section 2 WO.jpg	108	25	2	WO
Sample 7 Section 1 ES.jpg	109	7	1	ES

File	Image #	Sample	Section	Instrumentation
Sample 40 Section 3 Edge.jpg	110	40	3	Edge
Sample 5 Section 3 TW.jpg	111	5	3	TW
Sample 17 Section 2 WO.jpg	112	17	2	WO
Sample 2 Section 1 TW.jpg	113	2	1	TW
Sample 13 Section 2 TW.jpg	114	13	2	TW
Sample 22 Section 3 TW.jpg	115	22	3	TW
Sample 26 Section 1 TW.jpg	116	26	1	TW
Sample 32 Section 1 TW.jpg	117	32	1	TW
Sample 27 Section 1 TW.jpg	118	27	1	TW
Sample 15 Section 3 ES.jpg	119	15	3	ES
Sample 17 Section 1 WO.jpg	120	17	1	WO
Sample 27 Section 2 TW.jpg	121	27	2	TW
Sample 7 Section 3 ES.jpg	122	7	3	ES
Sample 40 Section 1 Edge.jpg	123	40	1	Edge
Sample 24 Section 1 Edge.jpg	124	24	1	Edge
Sample 6 Section 1 Edge.jpg	125	6	1	Edge
Sample 29 Section 2 ES.jpg	126	29	2	ES
Sample 34 Section 3 WO.jpg	127	34	3	WO
Sample 23 Section 2 WO.jpg	128	23	2	WO
Sample 39 Section 1 ES.jpg	129	39	1	ES
Sample 38 Section 2 Edge.jpg	130	38	2	Edge
Sample 18 Section 1 TW.jpg	131	18	1	TW
Sample 40 Section 3 Edge.jpg	132	40	3	Edge
Sample 4 Section 3 TW.jpg	133	4	3	TW
Sample 12 Section 3 ES.jpg	134	12	3	ES
Sample 14 Section 1 ES.jpg	135	14	1	ES
Sample 14 Section 2 ES.jpg	136	14	2	ES
Sample 33 Section 3 ES.jpg	137	33	3	ES
Sample 27 Section 2 TW.jpg	138	27	2	TW
Sample 34 Section 2 WO.jpg	139	34	2	WO
Sample 36 Section 3 WO.jpg	140	36	3	WO
Sample 33 Section 2 ES.jpg	141	33	2	ES
Sample 25 Section 3 WO.jpg	142	25	3	WO
Sample 4 Section 3 TW.jpg	143	4	3	TW
Sample 10 Section 1 Edge.jpg	144	10	1	Edge

Appendix 2: REDCap surveys

Cracks in Pre-Op vs Post-Op images

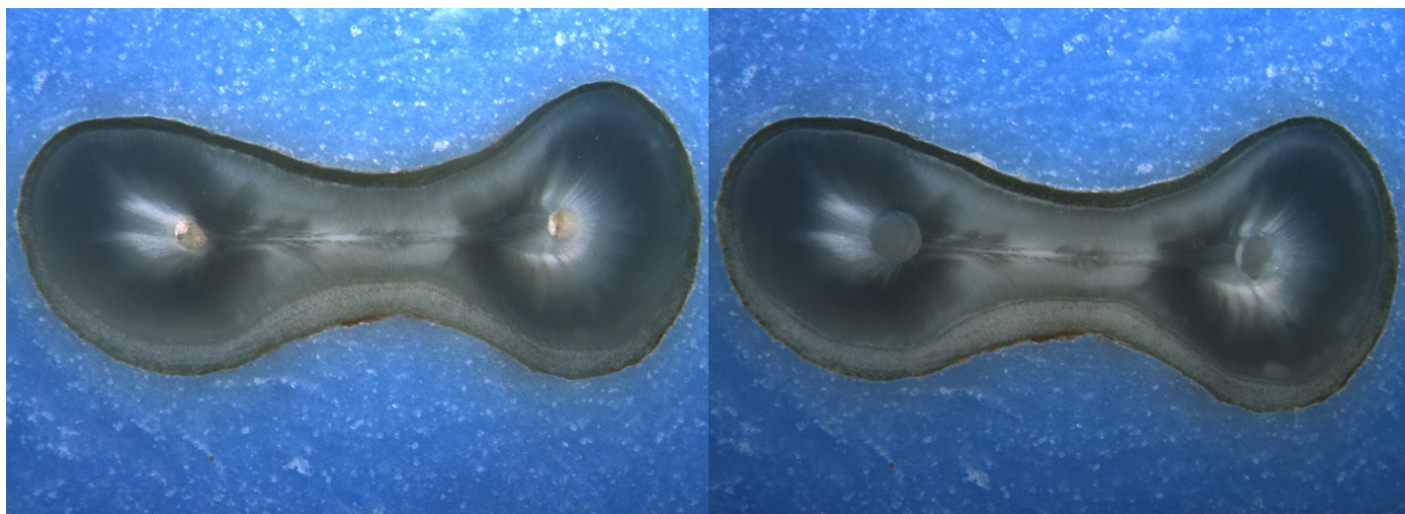
Please complete the survey below.

Thank you!

Rater's last name

Image: i001.jpg

Pre-Op on the left and Post-Op on the right



Is there any evidence of a dentinal crack prior to rotary instrumentation (Pre-Op)?

- Yes
 No

Does the crack in the Pre-Op image increase in size when viewed in the Post-Op image?

- Yes
 No

Is the crack that increased in the Pre-Op image now:

- an Incomplete Crack from the canal towards the root surface
 an Incomplete Crack from the root surface towards the canal
 A complete crack

Is there a new dentinal crack present in the instrumented (Post-Op) sample not seen in the Pre-Op image?

- Yes
 No

Is the new crack in the Post-Op image:

- an Incomplete Crack from the canal towards the root surface
 an Incomplete Crack from the root surface towards the canal
 A complete crack

Is there a dentinal crack present in the instrumented (Post-Op) sample not seen in the Pre-Op image?

- Yes
 No

Is there more than one crack seen in the Post-Op image?

- Yes
 No

For the longest crack seen in the Post-Op image, is the crack:

- an Incomplete Crack from the canal towards the root surface
 an Incomplete Crack from the root surface towards the canal
 A complete crack

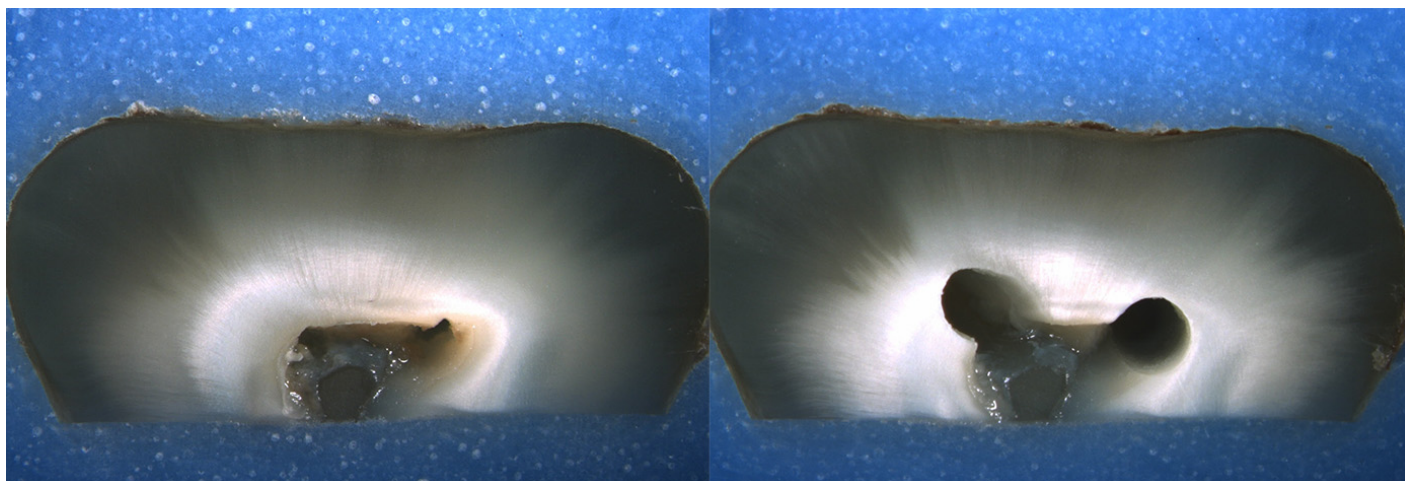
Is the crack seen in the Post-Op image:

- an Incomplete Crack from the canal towards the root surface
 an Incomplete Crack from the root surface towards the canal
 A complete crack

Done. Go to next page

Image: i002.jpg

Pre-Op on the left and Post-Op on the right



Is there any evidence of a dentinal crack prior to rotary instrumentation (Pre-Op)?

- Yes
 No

Does the crack in the Pre-Op image increase in size when viewed in the Post-Op image?

- Yes
 No

Is the crack that increased in the Pre-Op image now:

- an Incomplete Crack from the canal towards the root surface
 an Incomplete Crack from the root surface towards the canal
 A complete crack

Is there a new dentinal crack present in the instrumented (Post-Op) sample not seen in the Pre-Op image?

- Yes
 No

Is the new crack in the Post-Op image:

- an Incomplete Crack from the canal towards the root surface
 an Incomplete Crack from the root surface towards the canal
 A complete crack

Is there a dentinal crack present in the instrumented (Post-Op) sample not seen in the Pre-Op image?

- Yes
 No

Is there more than one crack seen in the Post-Op image?

- Yes
 No

For the longest crack seen in the Post-Op image, is the crack:

- an Incomplete Crack from the canal towards the root surface
 an Incomplete Crack from the root surface towards the canal
 A complete crack

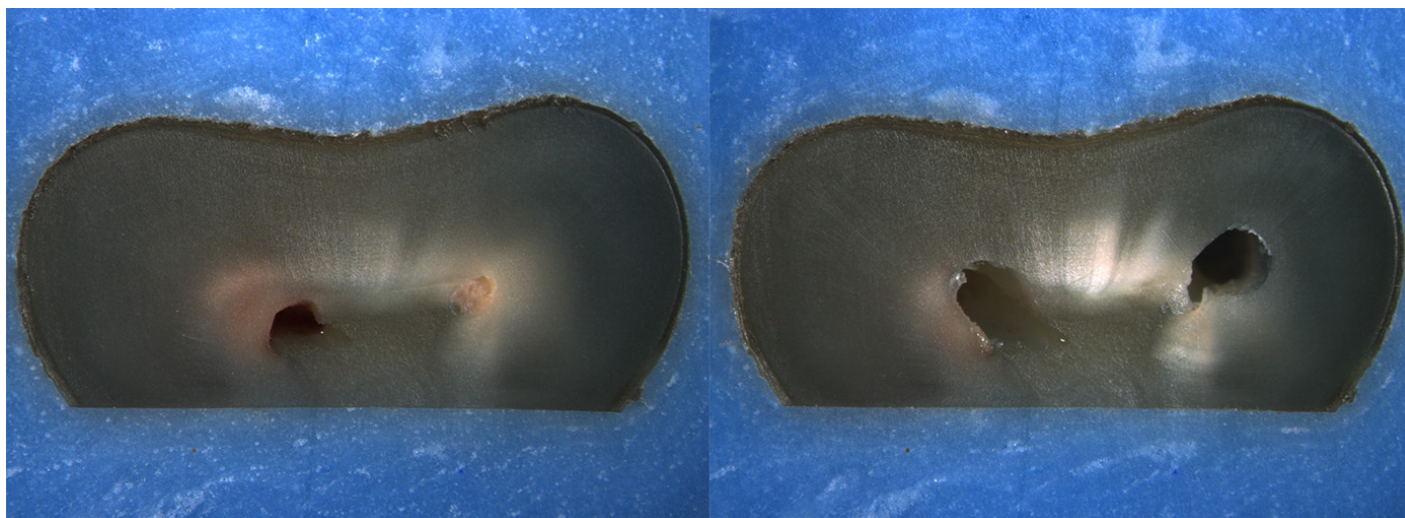
Is the crack seen in the Post-Op image:

- an Incomplete Crack from the canal towards the root surface
 an Incomplete Crack from the root surface towards the canal
 A complete crack

Done. Go to next page

Image: i003.jpg

Pre-Op on the left and Post-Op on the right



Is there any evidence of a dentinal crack prior to rotary instrumentation (Pre-Op)?

- Yes
 No

Does the crack in the Pre-Op image increase in size when viewed in the Post-Op image?

- Yes
 No

Is the crack that increased in the Pre-Op image now:

- an Incomplete Crack from the canal towards the root surface
 an Incomplete Crack from the root surface towards the canal
 A complete crack

Is there a new dentinal crack present in the instrumented (Post-Op) sample not seen in the Pre-Op image?

- Yes
 No

Is the new crack in the Post-Op image:

- an Incomplete Crack from the canal towards the root surface
 an Incomplete Crack from the root surface towards the canal
 A complete crack

Is there a dentinal crack present in the instrumented (Post-Op) sample not seen in the Pre-Op image?

- Yes
 No

Is there more than one crack seen in the Post-Op image?

- Yes
 No

For the longest crack seen in the Post-Op image, is the crack:

- an Incomplete Crack from the canal towards the root surface
 an Incomplete Crack from the root surface towards the canal
 A complete crack


Is the crack seen in the Post-Op image:

- an Incomplete Crack from the canal towards the root surface
 an Incomplete Crack from the root surface towards the canal
 A complete crack

Done. Go to next page

Image: i004.jpg

Pre-Op on the left and Post-Op on the right



Is there any evidence of a dentinal crack prior to rotary instrumentation (Pre-Op)?

- Yes
 No

Does the crack in the Pre-Op image increase in size when viewed in the Post-Op image?

- Yes
 No

Is the crack that increased in the Pre-Op image now:

- an Incomplete Crack from the canal towards the root surface
 an Incomplete Crack from the root surface towards the canal
 A complete crack

Is there a new dentinal crack present in the instrumented (Post-Op) sample not seen in the Pre-Op image?

- Yes
 No

Is the new crack in the Post-Op image:

- an Incomplete Crack from the canal towards the root surface
 an Incomplete Crack from the root surface towards the canal
 A complete crack

Is there a dentinal crack present in the instrumented (Post-Op) sample not seen in the Pre-Op image?

- Yes
 No

Is there more than one crack seen in the Post-Op image?

- Yes
 No

For the longest crack seen in the Post-Op image, is the crack:

- an Incomplete Crack from the canal towards the root surface
 an Incomplete Crack from the root surface towards the canal
 A complete crack


Is the crack seen in the Post-Op image:

- an Incomplete Crack from the canal towards the root surface
 an Incomplete Crack from the root surface towards the canal
 A complete crack

Done. Go to next page

Image: i005.jpg

Pre-Op on the left and Post-Op on the right



Is there any evidence of a dentinal crack prior to rotary instrumentation (Pre-Op)?

- Yes
 No

Does the crack in the Pre-Op image increase in size when viewed in the Post-Op image?

- Yes
 No

Is the crack that increased in the Pre-Op image now:

- an Incomplete Crack from the canal towards the root surface
 an Incomplete Crack from the root surface towards the canal
 A complete crack

Is there a new dentinal crack present in the instrumented (Post-Op) sample not seen in the Pre-Op image?

- Yes
 No

Is the new crack in the Post-Op image:

- an Incomplete Crack from the canal towards the root surface
 an Incomplete Crack from the root surface towards the canal
 A complete crack

Is there a dentinal crack present in the instrumented (Post-Op) sample not seen in the Pre-Op image?

- Yes
 No

Is there more than one crack seen in the Post-Op image?

- Yes
 No

For the longest crack seen in the Post-Op image, is the crack:

- an Incomplete Crack from the canal towards the root surface
 an Incomplete Crack from the root surface towards the canal
 A complete crack

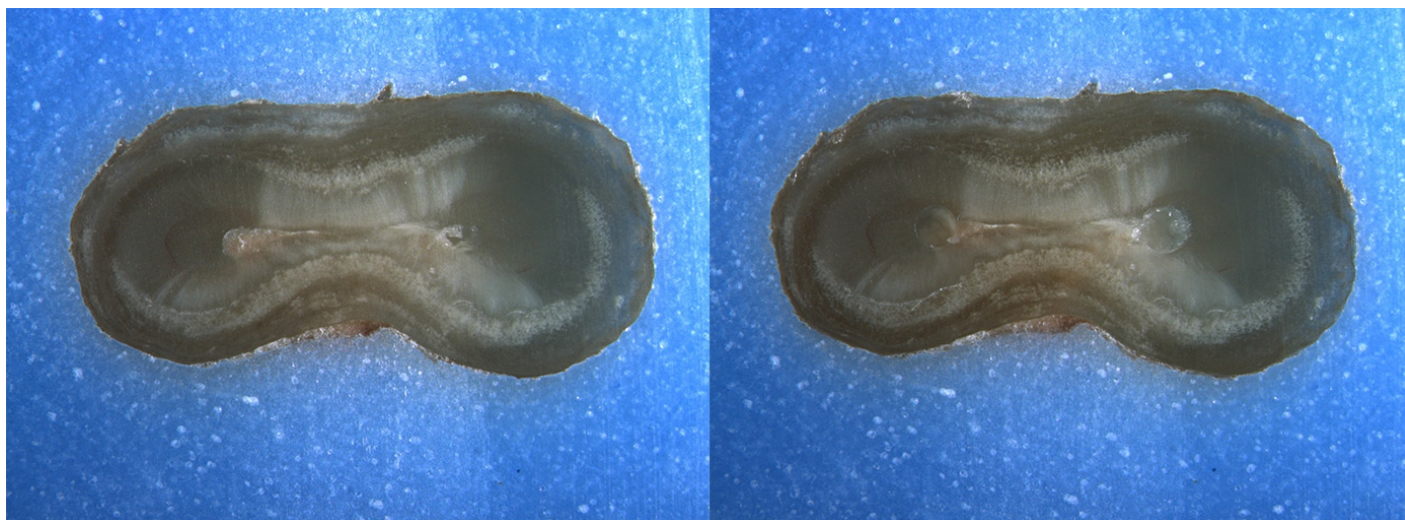
Is the crack seen in the Post-Op image:

- an Incomplete Crack from the canal towards the root surface
 an Incomplete Crack from the root surface towards the canal
 A complete crack

Done. Go to next page

Image: i006.jpg

Pre-Op on the left and Post-Op on the right



Is there any evidence of a dentinal crack prior to rotary instrumentation (Pre-Op)?

- Yes
 No

Does the crack in the Pre-Op image increase in size when viewed in the Post-Op image?

- Yes
 No

Is the crack that increased in the Pre-Op image now:

- an Incomplete Crack from the canal towards the root surface
 an Incomplete Crack from the root surface towards the canal
 A complete crack

Is there a new dentinal crack present in the instrumented (Post-Op) sample not seen in the Pre-Op image?

- Yes
 No

Is the new crack in the Post-Op image:

- an Incomplete Crack from the canal towards the root surface
 an Incomplete Crack from the root surface towards the canal
 A complete crack

Is there a dentinal crack present in the instrumented (Post-Op) sample not seen in the Pre-Op image?

- Yes
 No

Is there more than one crack seen in the Post-Op image?

- Yes
 No

For the longest crack seen in the Post-Op image, is the crack:

- an Incomplete Crack from the canal towards the root surface
 an Incomplete Crack from the root surface towards the canal
 A complete crack

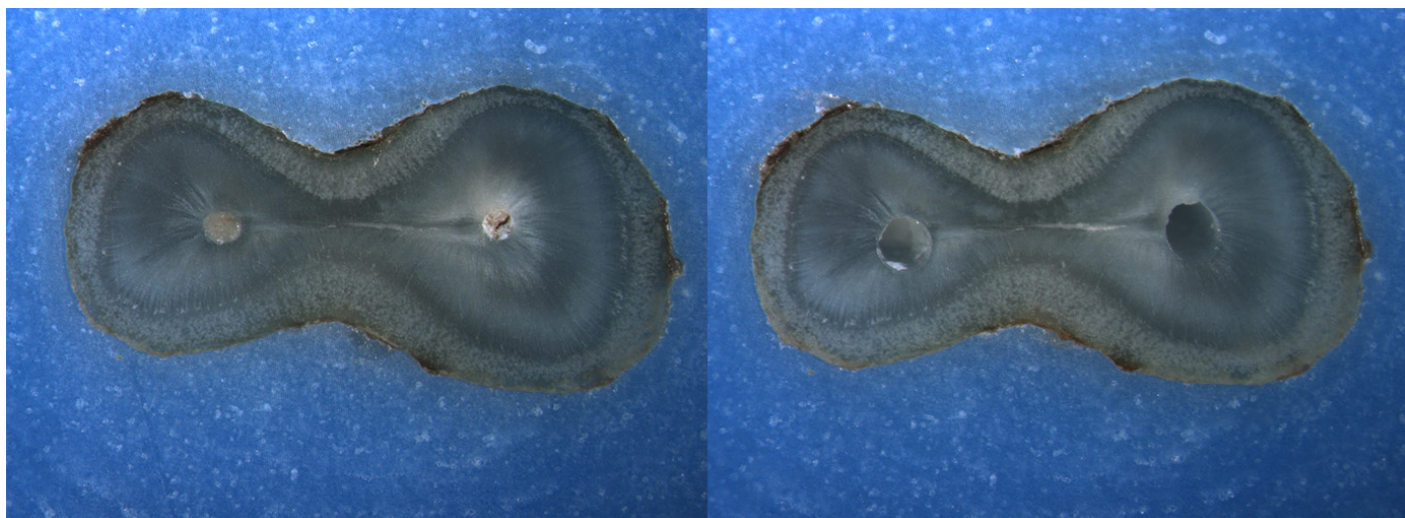
Is the crack seen in the Post-Op image:

- an Incomplete Crack from the canal towards the root surface
 an Incomplete Crack from the root surface towards the canal
 A complete crack

Done. Go to next page

Image: i007.jpg

Pre-Op on the left and Post-Op on the right



Is there any evidence of a dentinal crack prior to rotary instrumentation (Pre-Op)?

- Yes
 No

Does the crack in the Pre-Op image increase in size when viewed in the Post-Op image?

- Yes
 No

Is the crack that increased in the Pre-Op image now:

- an Incomplete Crack from the canal towards the root surface
 an Incomplete Crack from the root surface towards the canal
 A complete crack

Is there a new dentinal crack present in the instrumented (Post-Op) sample not seen in the Pre-Op image?

- Yes
 No

Is the new crack in the Post-Op image:

- an Incomplete Crack from the canal towards the root surface
 an Incomplete Crack from the root surface towards the canal
 A complete crack

Is there a dentinal crack present in the instrumented (Post-Op) sample not seen in the Pre-Op image?

- Yes
 No

Is there more than one crack seen in the Post-Op image?

- Yes
 No

For the longest crack seen in the Post-Op image, is the crack:

- an Incomplete Crack from the canal towards the root surface
 an Incomplete Crack from the root surface towards the canal
 A complete crack

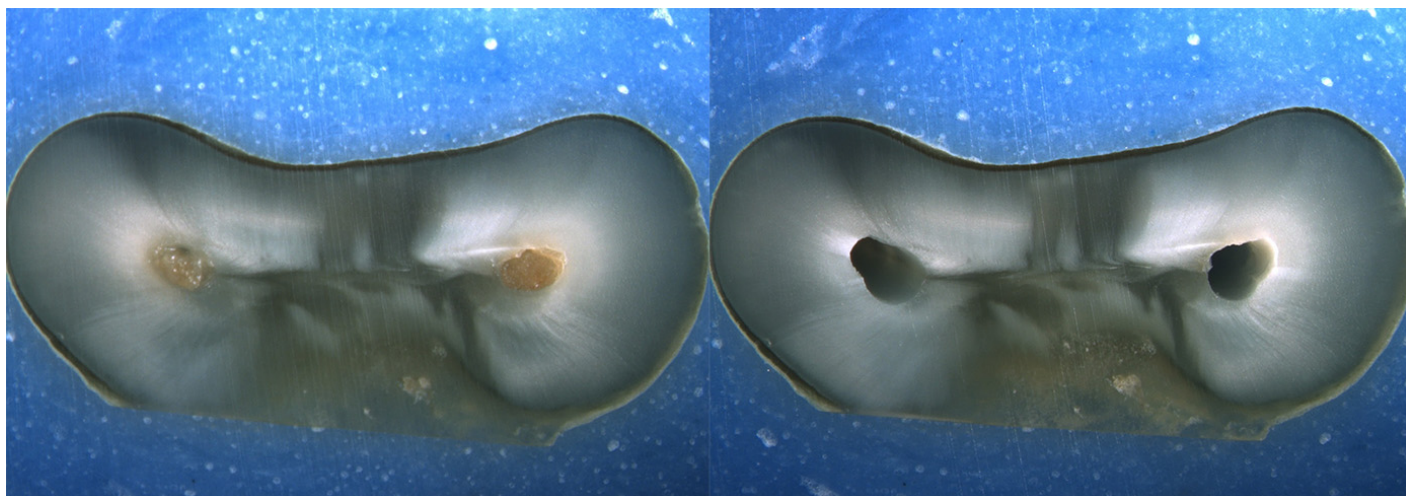
Is the crack seen in the Post-Op image:

- an Incomplete Crack from the canal towards the root surface
 an Incomplete Crack from the root surface towards the canal
 A complete crack

Done. Go to next page

Image: i008.jpg

Pre-Op on the left and Post-Op on the right



Is there any evidence of a dentinal crack prior to rotary instrumentation (Pre-Op)?

- Yes
 No

Does the crack in the Pre-Op image increase in size when viewed in the Post-Op image?

- Yes
 No

Is the crack that increased in the Pre-Op image now:

- an Incomplete Crack from the canal towards the root surface
 an Incomplete Crack from the root surface towards the canal
 A complete crack

Is there a new dentinal crack present in the instrumented (Post-Op) sample not seen in the Pre-Op image?

- Yes
 No

Is the new crack in the Post-Op image:

- an Incomplete Crack from the canal towards the root surface
 an Incomplete Crack from the root surface towards the canal
 A complete crack

Is there a dentinal crack present in the instrumented (Post-Op) sample not seen in the Pre-Op image?

- Yes
 No

Is there more than one crack seen in the Post-Op image?

- Yes
 No

For the longest crack seen in the Post-Op image, is the crack:

- an Incomplete Crack from the canal towards the root surface
 an Incomplete Crack from the root surface towards the canal
 A complete crack

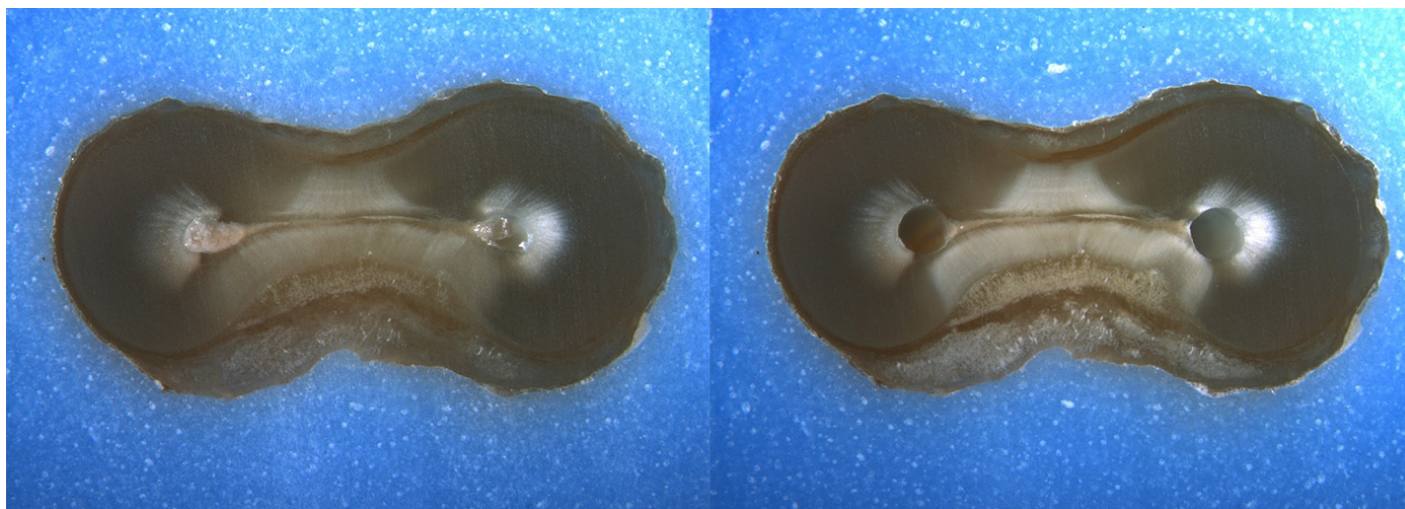
Is the crack seen in the Post-Op image:

- an Incomplete Crack from the canal towards the root surface
 an Incomplete Crack from the root surface towards the canal
 A complete crack

Done. Go to next page

Image: i009.jpg

Pre-Op on the left and Post-Op on the right



Is there any evidence of a dentinal crack prior to rotary instrumentation (Pre-Op)?

- Yes
 No

Does the crack in the Pre-Op image increase in size when viewed in the Post-Op image?

- Yes
 No

Is the crack that increased in the Pre-Op image now:

- an Incomplete Crack from the canal towards the root surface
 an Incomplete Crack from the root surface towards the canal
 A complete crack

Is there a new dentinal crack present in the instrumented (Post-Op) sample not seen in the Pre-Op image?

- Yes
 No

Is the new crack in the Post-Op image:

- an Incomplete Crack from the canal towards the root surface
 an Incomplete Crack from the root surface towards the canal
 A complete crack

Is there a dentinal crack present in the instrumented (Post-Op) sample not seen in the Pre-Op image?

- Yes
 No

Is there more than one crack seen in the Post-Op image?

- Yes
 No

For the longest crack seen in the Post-Op image, is the crack:

- an Incomplete Crack from the canal towards the root surface
 an Incomplete Crack from the root surface towards the canal
 A complete crack

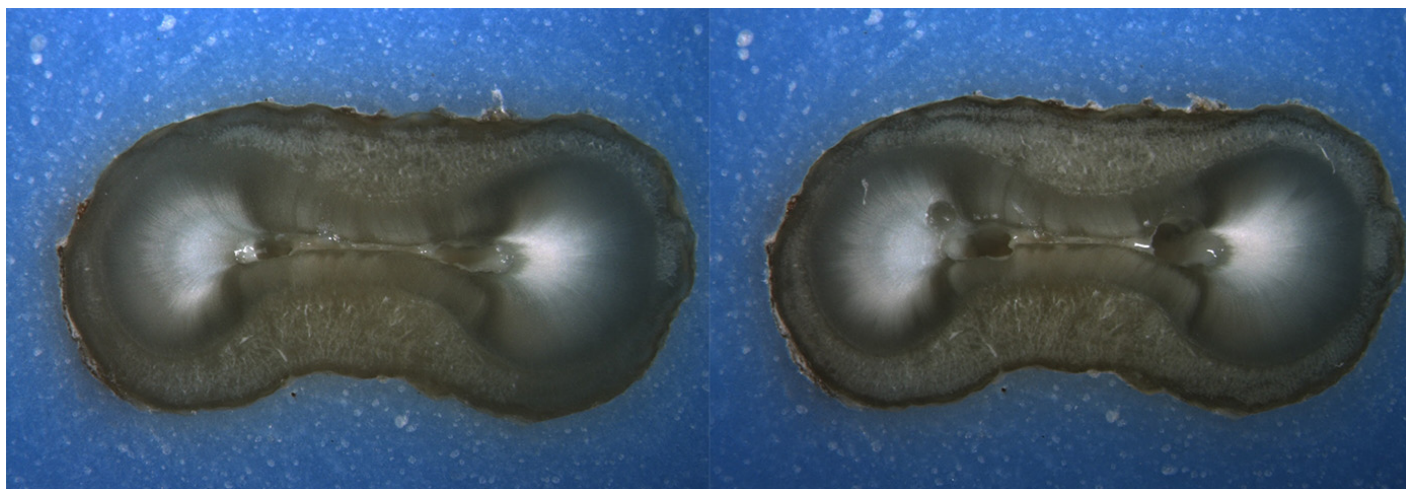
Is the crack seen in the Post-Op image:

- an Incomplete Crack from the canal towards the root surface
 an Incomplete Crack from the root surface towards the canal
 A complete crack

Done. Go to next page

Image: i010.jpg

Pre-Op on the left and Post-Op on the right



Is there any evidence of a dentinal crack prior to rotary instrumentation (Pre-Op)?

- Yes
 No

Does the crack in the Pre-Op image increase in size when viewed in the Post-Op image?

- Yes
 No

Is the crack that increased in the Pre-Op image now:

- an Incomplete Crack from the canal towards the root surface
 an Incomplete Crack from the root surface towards the canal
 A complete crack

Is there a new dentinal crack present in the instrumented (Post-Op) sample not seen in the Pre-Op image?

- Yes
 No

Is the new crack in the Post-Op image:

- an Incomplete Crack from the canal towards the root surface
 an Incomplete Crack from the root surface towards the canal
 A complete crack

Is there a dentinal crack present in the instrumented (Post-Op) sample not seen in the Pre-Op image?

- Yes
 No

Is there more than one crack seen in the Post-Op image?

- Yes
 No

For the longest crack seen in the Post-Op image, is the crack:

- an Incomplete Crack from the canal towards the root surface
 an Incomplete Crack from the root surface towards the canal
 A complete crack

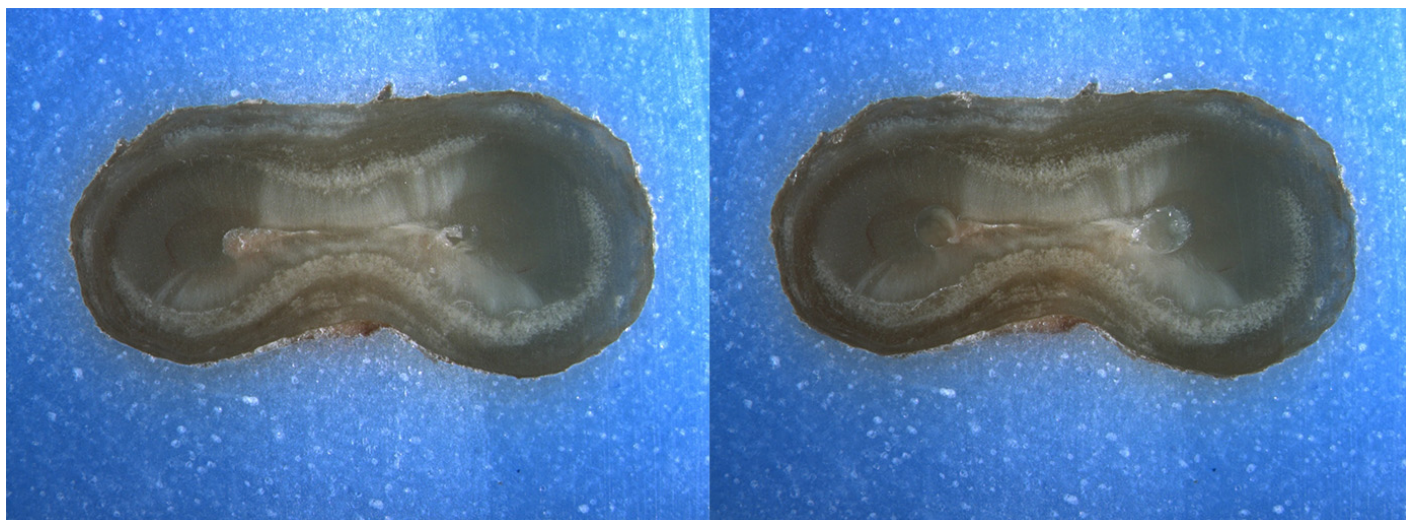
Is the crack seen in the Post-Op image:

- an Incomplete Crack from the canal towards the root surface
 an Incomplete Crack from the root surface towards the canal
 A complete crack

Done. Go to next page

Image: i011.jpg

Pre-Op on the left and Post-Op on the right



Is there any evidence of a dentinal crack prior to rotary instrumentation (Pre-Op)?

- Yes
 No

Does the crack in the Pre-Op image increase in size when viewed in the Post-Op image?

- Yes
 No

Is the crack that increased in the Pre-Op image now:

- an Incomplete Crack from the canal towards the root surface
 an Incomplete Crack from the root surface towards the canal
 A complete crack

Is there a new dentinal crack present in the instrumented (Post-Op) sample not seen in the Pre-Op image?

- Yes
 No

Is the new crack in the Post-Op image:

- an Incomplete Crack from the canal towards the root surface
 an Incomplete Crack from the root surface towards the canal
 A complete crack

Is there a dentinal crack present in the instrumented (Post-Op) sample not seen in the Pre-Op image?

- Yes
 No

Is there more than one crack seen in the Post-Op image?

- Yes
 No

For the longest crack seen in the Post-Op image, is the crack:

- an Incomplete Crack from the canal towards the root surface
 an Incomplete Crack from the root surface towards the canal
 A complete crack

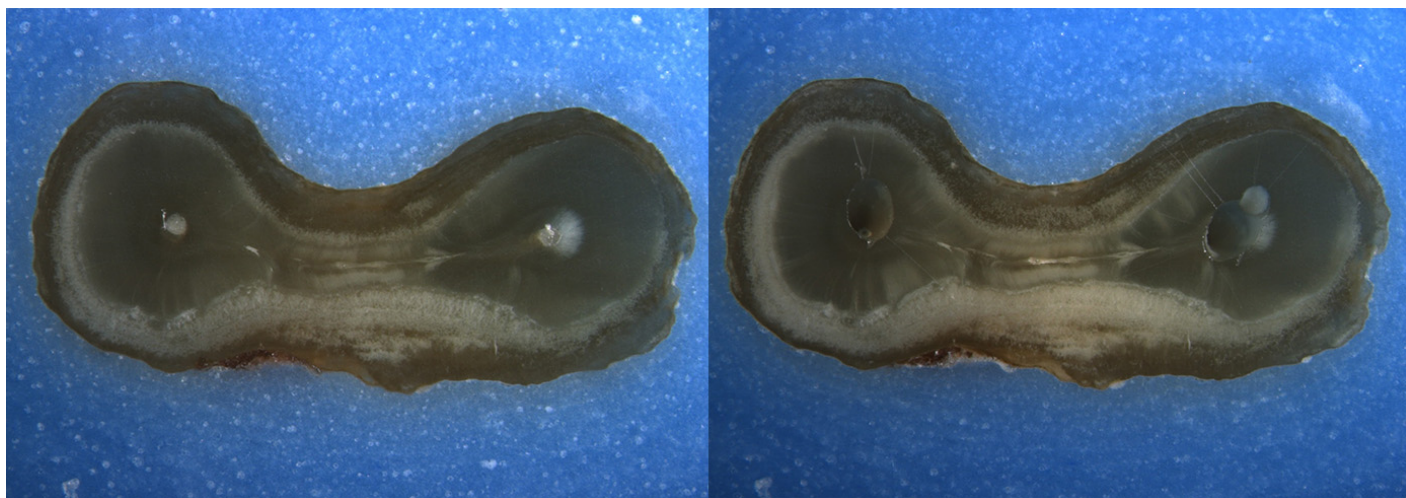
Is the crack seen in the Post-Op image:

- an Incomplete Crack from the canal towards the root surface
 an Incomplete Crack from the root surface towards the canal
 A complete crack

Done. Go to next page

Image: i012.jpg

Pre-Op on the left and Post-Op on the right



Is there any evidence of a dentinal crack prior to rotary instrumentation (Pre-Op)?

- Yes
 No

Does the crack in the Pre-Op image increase in size when viewed in the Post-Op image?

- Yes
 No

Is the crack that increased in the Pre-Op image now:

- an Incomplete Crack from the canal towards the root surface
 an Incomplete Crack from the root surface towards the canal
 A complete crack

Is there a new dentinal crack present in the instrumented (Post-Op) sample not seen in the Pre-Op image?

- Yes
 No

Is the new crack in the Post-Op image:

- an Incomplete Crack from the canal towards the root surface
 an Incomplete Crack from the root surface towards the canal
 A complete crack

Is there a dentinal crack present in the instrumented (Post-Op) sample not seen in the Pre-Op image?

- Yes
 No

Is there more than one crack seen in the Post-Op image?

- Yes
 No

For the longest crack seen in the Post-Op image, is the crack:

- an Incomplete Crack from the canal towards the root surface
 an Incomplete Crack from the root surface towards the canal
 A complete crack

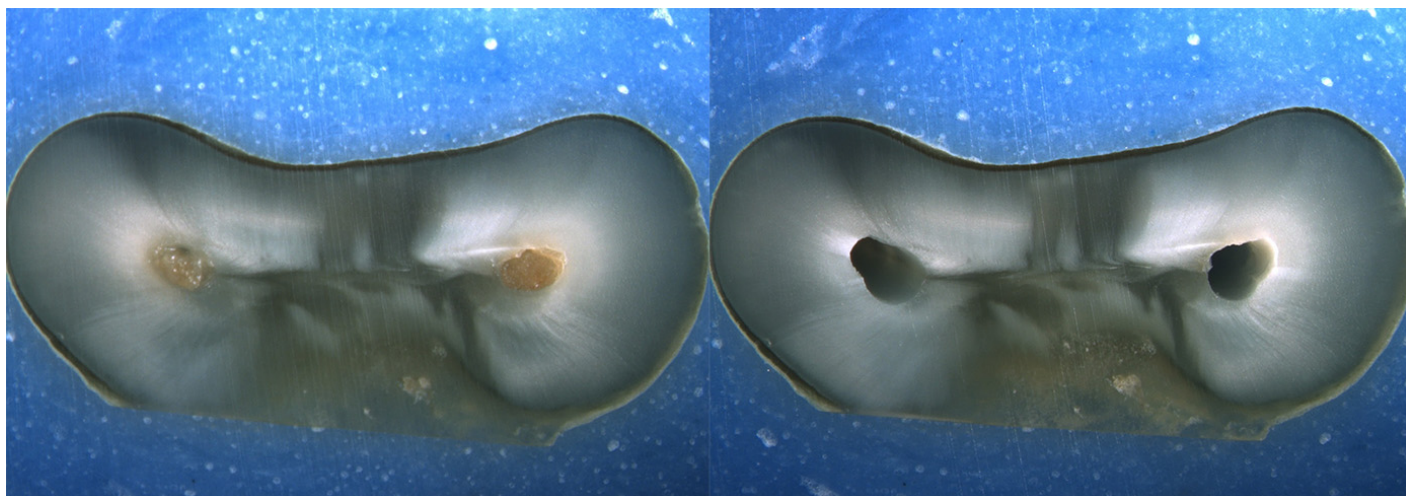
Is the crack seen in the Post-Op image:

- an Incomplete Crack from the canal towards the root surface
 an Incomplete Crack from the root surface towards the canal
 A complete crack

Done. Go to next page

Image: i013.jpg

Pre-Op on the left and Post-Op on the right



Is there any evidence of a dentinal crack prior to rotary instrumentation (Pre-Op)?

- Yes
 No

Does the crack in the Pre-Op image increase in size when viewed in the Post-Op image?

- Yes
 No

Is the crack that increased in the Pre-Op image now:

- an Incomplete Crack from the canal towards the root surface
 an Incomplete Crack from the root surface towards the canal
 A complete crack

Is there a new dentinal crack present in the instrumented (Post-Op) sample not seen in the Pre-Op image?

- Yes
 No

Is the new crack in the Post-Op image:

- an Incomplete Crack from the canal towards the root surface
 an Incomplete Crack from the root surface towards the canal
 A complete crack

Is there a dentinal crack present in the instrumented (Post-Op) sample not seen in the Pre-Op image?

- Yes
 No

Is there more than one crack seen in the Post-Op image?

- Yes
 No

For the longest crack seen in the Post-Op image, is the crack:

- an Incomplete Crack from the canal towards the root surface
 an Incomplete Crack from the root surface towards the canal
 A complete crack

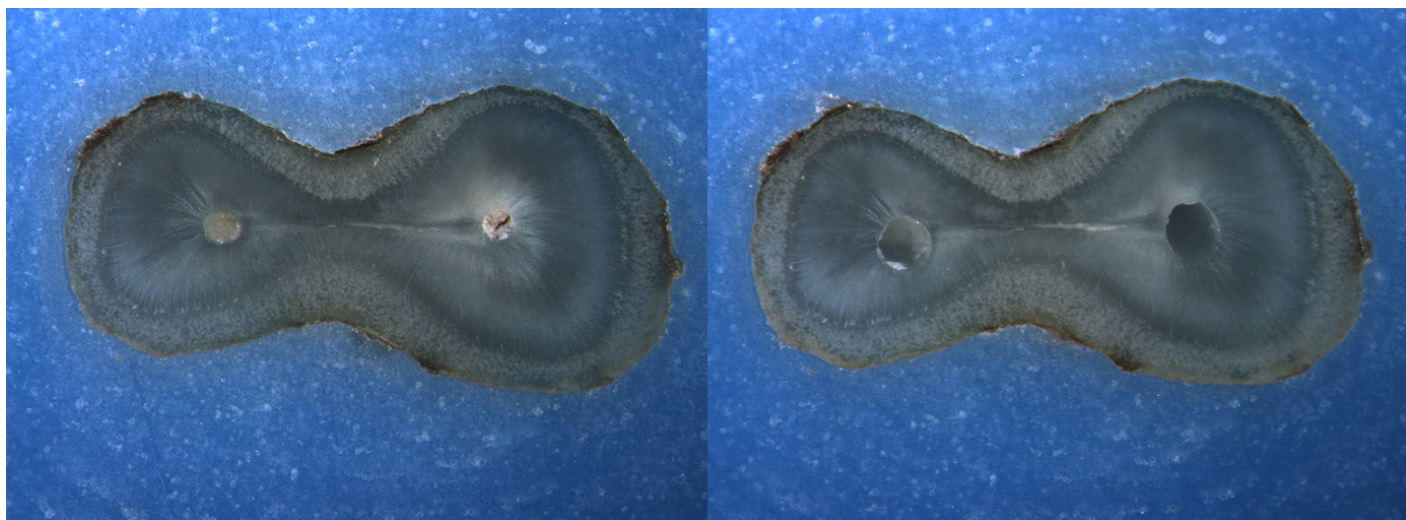
Is the crack seen in the Post-Op image:

- an Incomplete Crack from the canal towards the root surface
 an Incomplete Crack from the root surface towards the canal
 A complete crack

Done. Go to next page

Image: i014.jpg

Pre-Op on the left and Post-Op on the right



Is there any evidence of a dentinal crack prior to rotary instrumentation (Pre-Op)?

- Yes
 No

Does the crack in the Pre-Op image increase in size when viewed in the Post-Op image?

- Yes
 No

Is the crack that increased in the Pre-Op image now:

- an Incomplete Crack from the canal towards the root surface
 an Incomplete Crack from the root surface towards the canal
 A complete crack

Is there a new dentinal crack present in the instrumented (Post-Op) sample not seen in the Pre-Op image?

- Yes
 No

Is the new crack in the Post-Op image:

- an Incomplete Crack from the canal towards the root surface
 an Incomplete Crack from the root surface towards the canal
 A complete crack

Is there a dentinal crack present in the instrumented (Post-Op) sample not seen in the Pre-Op image?

- Yes
 No

Is there more than one crack seen in the Post-Op image?

- Yes
 No

For the longest crack seen in the Post-Op image, is the crack:

- an Incomplete Crack from the canal towards the root surface
 an Incomplete Crack from the root surface towards the canal
 A complete crack

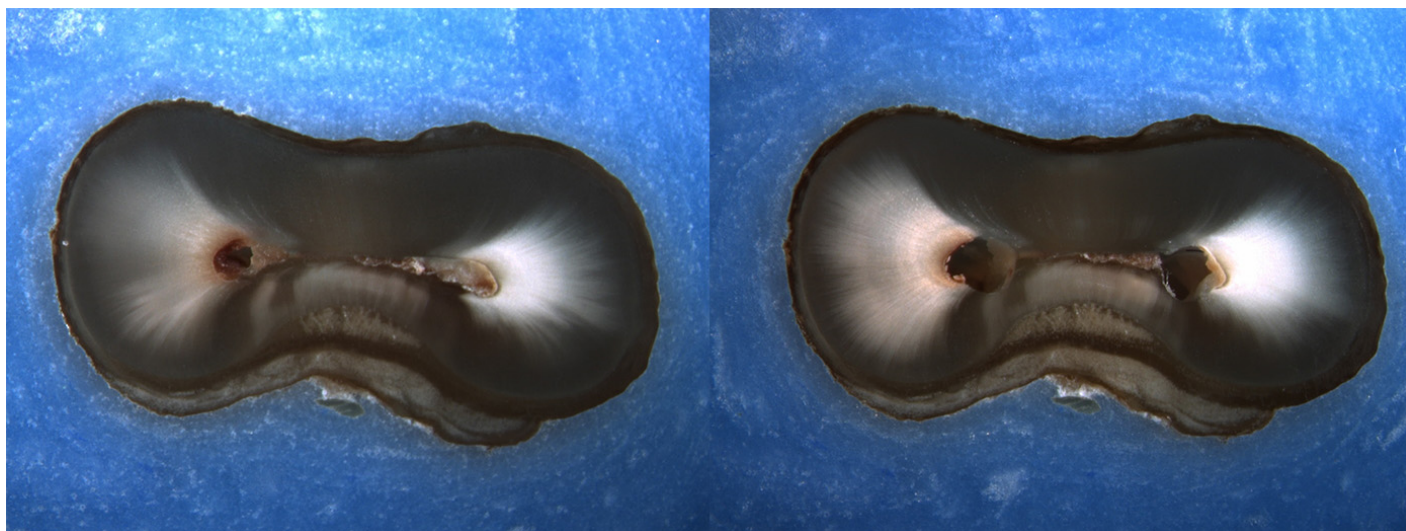
Is the crack seen in the Post-Op image:

- an Incomplete Crack from the canal towards the root surface
 an Incomplete Crack from the root surface towards the canal
 A complete crack

Done. Go to next page

Image: i015.jpg

Pre-Op on the left and Post-Op on the right



Is there any evidence of a dentinal crack prior to rotary instrumentation (Pre-Op)?

- Yes
 No

Does the crack in the Pre-Op image increase in size when viewed in the Post-Op image?

- Yes
 No

Is the crack that increased in the Pre-Op image now:

- an Incomplete Crack from the canal towards the root surface
 an Incomplete Crack from the root surface towards the canal
 A complete crack

Is there a new dentinal crack present in the instrumented (Post-Op) sample not seen in the Pre-Op image?

- Yes
 No

Is the new crack in the Post-Op image:

- an Incomplete Crack from the canal towards the root surface
 an Incomplete Crack from the root surface towards the canal
 A complete crack

Is there a dentinal crack present in the instrumented (Post-Op) sample not seen in the Pre-Op image?

- Yes
 No

Is there more than one crack seen in the Post-Op image?

- Yes
 No

For the longest crack seen in the Post-Op image, is the crack:

- an Incomplete Crack from the canal towards the root surface
 an Incomplete Crack from the root surface towards the canal
 A complete crack


Is the crack seen in the Post-Op image:

- an Incomplete Crack from the canal towards the root surface
 an Incomplete Crack from the root surface towards the canal
 A complete crack

Done. Go to next page

Image: i016.jpg

Pre-Op on the left and Post-Op on the right



Is there any evidence of a dentinal crack prior to rotary instrumentation (Pre-Op)?

- Yes
 No

Does the crack in the Pre-Op image increase in size when viewed in the Post-Op image?

- Yes
 No

Is the crack that increased in the Pre-Op image now:

- an Incomplete Crack from the canal towards the root surface
 an Incomplete Crack from the root surface towards the canal
 A complete crack

Is there a new dentinal crack present in the instrumented (Post-Op) sample not seen in the Pre-Op image?

- Yes
 No

Is the new crack in the Post-Op image:

- an Incomplete Crack from the canal towards the root surface
 an Incomplete Crack from the root surface towards the canal
 A complete crack

Is there a dentinal crack present in the instrumented (Post-Op) sample not seen in the Pre-Op image?

- Yes
 No

Is there more than one crack seen in the Post-Op image?

- Yes
 No

For the longest crack seen in the Post-Op image, is the crack:

- an Incomplete Crack from the canal towards the root surface
 an Incomplete Crack from the root surface towards the canal
 A complete crack


Is the crack seen in the Post-Op image:

- an Incomplete Crack from the canal towards the root surface
 an Incomplete Crack from the root surface towards the canal
 A complete crack

Done. Go to next page

Image: i017.jpg

Pre-Op on the left and Post-Op on the right



Is there any evidence of a dentinal crack prior to rotary instrumentation (Pre-Op)?

- Yes
 No

Does the crack in the Pre-Op image increase in size when viewed in the Post-Op image?

- Yes
 No

Is the crack that increased in the Pre-Op image now:

- an Incomplete Crack from the canal towards the root surface
 an Incomplete Crack from the root surface towards the canal
 A complete crack

Is there a new dentinal crack present in the instrumented (Post-Op) sample not seen in the Pre-Op image?

- Yes
 No

Is the new crack in the Post-Op image:

- an Incomplete Crack from the canal towards the root surface
 an Incomplete Crack from the root surface towards the canal
 A complete crack

Is there a dentinal crack present in the instrumented (Post-Op) sample not seen in the Pre-Op image?

- Yes
 No

Is there more than one crack seen in the Post-Op image?

- Yes
 No

For the longest crack seen in the Post-Op image, is the crack:

- an Incomplete Crack from the canal towards the root surface
 an Incomplete Crack from the root surface towards the canal
 A complete crack

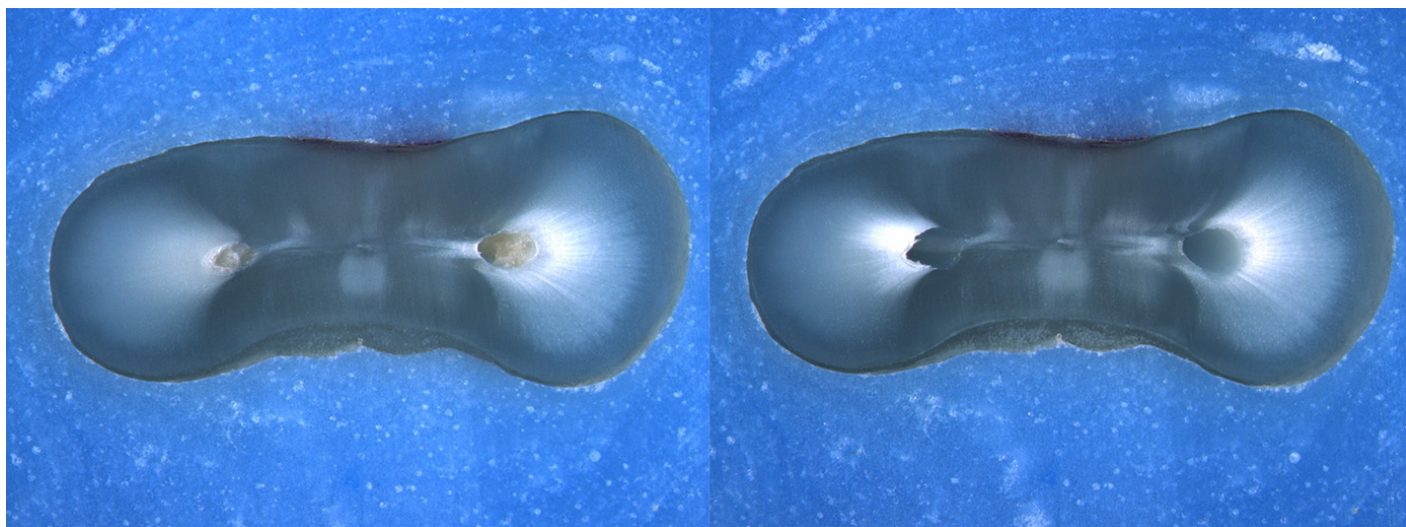
Is the crack seen in the Post-Op image:

- an Incomplete Crack from the canal towards the root surface
 an Incomplete Crack from the root surface towards the canal
 A complete crack

Done. Go to next page

Image: i018.jpg

Pre-Op on the left and Post-Op on the right



Is there any evidence of a dentinal crack prior to rotary instrumentation (Pre-Op)?

- Yes
 No

Does the crack in the Pre-Op image increase in size when viewed in the Post-Op image?

- Yes
 No

Is the crack that increased in the Pre-Op image now:

- an Incomplete Crack from the canal towards the root surface
 an Incomplete Crack from the root surface towards the canal
 A complete crack

Is there a new dentinal crack present in the instrumented (Post-Op) sample not seen in the Pre-Op image?

- Yes
 No

Is the new crack in the Post-Op image:

- an Incomplete Crack from the canal towards the root surface
 an Incomplete Crack from the root surface towards the canal
 A complete crack

Is there a dentinal crack present in the instrumented (Post-Op) sample not seen in the Pre-Op image?

- Yes
 No

Is there more than one crack seen in the Post-Op image?

- Yes
 No

For the longest crack seen in the Post-Op image, is the crack:

- an Incomplete Crack from the canal towards the root surface
 an Incomplete Crack from the root surface towards the canal
 A complete crack

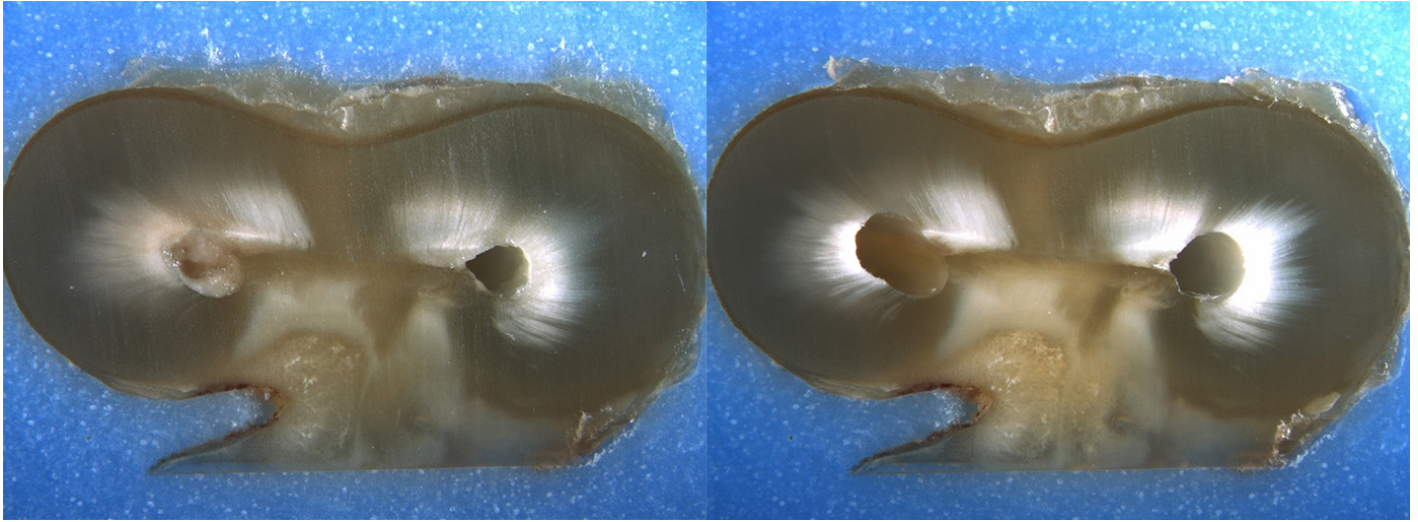
Is the crack seen in the Post-Op image:

- an Incomplete Crack from the canal towards the root surface
 an Incomplete Crack from the root surface towards the canal
 A complete crack

Done. Go to next page

Image: i019.jpg

Pre-Op on the left and Post-Op on the right



Is there any evidence of a dentinal crack prior to rotary instrumentation (Pre-Op)?

- Yes
 No

Does the crack in the Pre-Op image increase in size when viewed in the Post-Op image?

- Yes
 No

Is the crack that increased in the Pre-Op image now:

- an Incomplete Crack from the canal towards the root surface
 an Incomplete Crack from the root surface towards the canal
 A complete crack

Is there a new dentinal crack present in the instrumented (Post-Op) sample not seen in the Pre-Op image?

- Yes
 No

Is the new crack in the Post-Op image:

- an Incomplete Crack from the canal towards the root surface
 an Incomplete Crack from the root surface towards the canal
 A complete crack

Is there a dentinal crack present in the instrumented (Post-Op) sample not seen in the Pre-Op image?

- Yes
 No

Is there more than one crack seen in the Post-Op image?

- Yes
 No

For the longest crack seen in the Post-Op image, is the crack:

- an Incomplete Crack from the canal towards the root surface
 an Incomplete Crack from the root surface towards the canal
 A complete crack

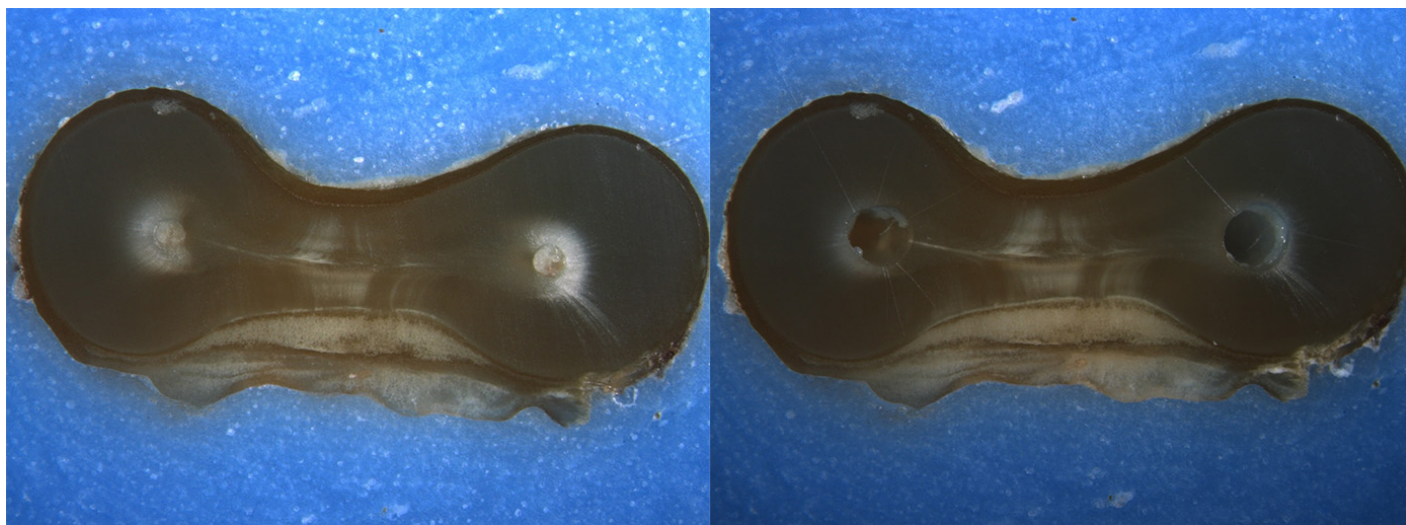
Is the crack seen in the Post-Op image:

- an Incomplete Crack from the canal towards the root surface
 an Incomplete Crack from the root surface towards the canal
 A complete crack

Done. Go to next page

Image: i020.jpg

Pre-Op on the left and Post-Op on the right



Is there any evidence of a dentinal crack prior to rotary instrumentation (Pre-Op)?

- Yes
 No

Does the crack in the Pre-Op image increase in size when viewed in the Post-Op image?

- Yes
 No

Is the crack that increased in the Pre-Op image now:

- an Incomplete Crack from the canal towards the root surface
 an Incomplete Crack from the root surface towards the canal
 A complete crack

Is there a new dentinal crack present in the instrumented (Post-Op) sample not seen in the Pre-Op image?

- Yes
 No

Is the new crack in the Post-Op image:

- an Incomplete Crack from the canal towards the root surface
 an Incomplete Crack from the root surface towards the canal
 A complete crack

Is there a dentinal crack present in the instrumented (Post-Op) sample not seen in the Pre-Op image?

- Yes
 No

Is there more than one crack seen in the Post-Op image?

- Yes
 No

For the longest crack seen in the Post-Op image, is the crack:

- an Incomplete Crack from the canal towards the root surface
 an Incomplete Crack from the root surface towards the canal
 A complete crack

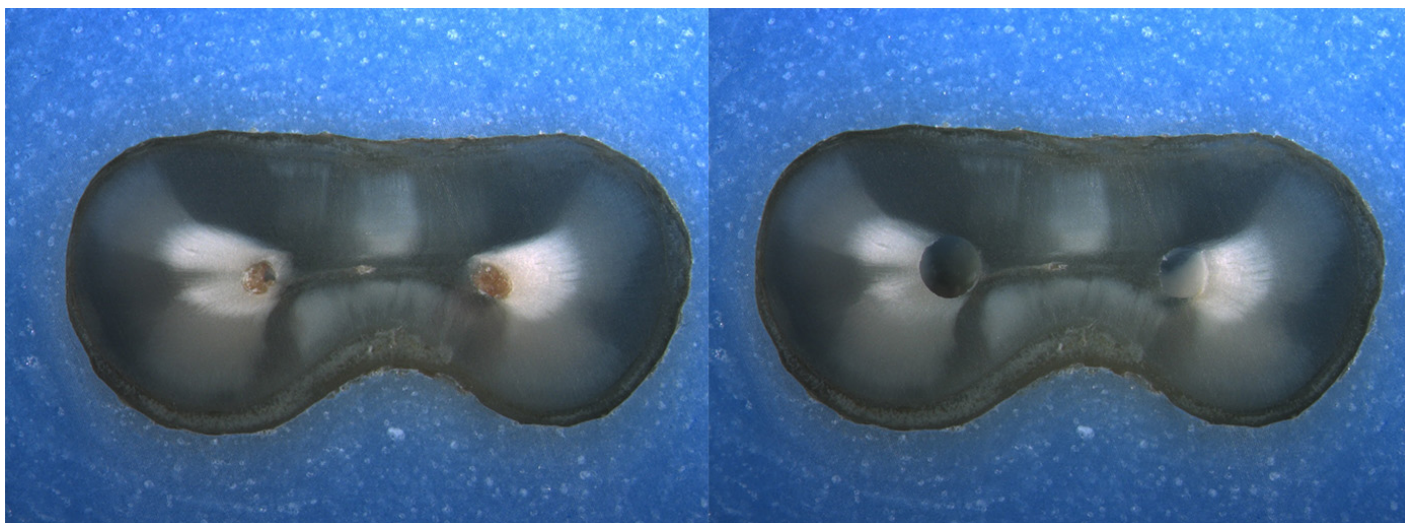
Is the crack seen in the Post-Op image:

- an Incomplete Crack from the canal towards the root surface
 an Incomplete Crack from the root surface towards the canal
 A complete crack

Done. Go to next page

Image: i021.jpg

Pre-Op on the left and Post-Op on the right



Is there any evidence of a dentinal crack prior to rotary instrumentation (Pre-Op)?

- Yes
 No

Does the crack in the Pre-Op image increase in size when viewed in the Post-Op image?

- Yes
 No

Is the crack that increased in the Pre-Op image now:

- an Incomplete Crack from the canal towards the root surface
 an Incomplete Crack from the root surface towards the canal
 A complete crack

Is there a new dentinal crack present in the instrumented (Post-Op) sample not seen in the Pre-Op image?

- Yes
 No

Is the new crack in the Post-Op image:

- an Incomplete Crack from the canal towards the root surface
 an Incomplete Crack from the root surface towards the canal
 A complete crack

Is there a dentinal crack present in the instrumented (Post-Op) sample not seen in the Pre-Op image?

- Yes
 No

Is there more than one crack seen in the Post-Op image?

- Yes
 No

For the longest crack seen in the Post-Op image, is the crack:

- an Incomplete Crack from the canal towards the root surface
 an Incomplete Crack from the root surface towards the canal
 A complete crack

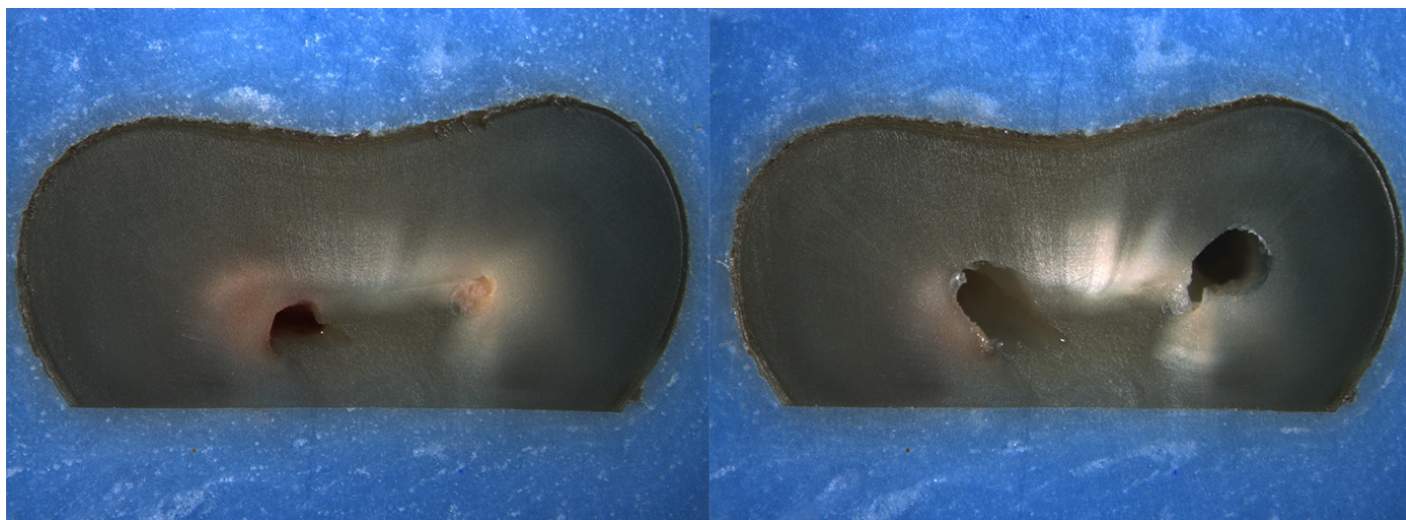
Is the crack seen in the Post-Op image:

- an Incomplete Crack from the canal towards the root surface
 an Incomplete Crack from the root surface towards the canal
 A complete crack

Done. Go to next page

Image: i022.jpg

Pre-Op on the left and Post-Op on the right



Is there any evidence of a dentinal crack prior to rotary instrumentation (Pre-Op)?

- Yes
 No

Does the crack in the Pre-Op image increase in size when viewed in the Post-Op image?

- Yes
 No

Is the crack that increased in the Pre-Op image now:

- an Incomplete Crack from the canal towards the root surface
 an Incomplete Crack from the root surface towards the canal
 A complete crack

Is there a new dentinal crack present in the instrumented (Post-Op) sample not seen in the Pre-Op image?

- Yes
 No

Is the new crack in the Post-Op image:

- an Incomplete Crack from the canal towards the root surface
 an Incomplete Crack from the root surface towards the canal
 A complete crack

Is there a dentinal crack present in the instrumented (Post-Op) sample not seen in the Pre-Op image?

- Yes
 No

Is there more than one crack seen in the Post-Op image?

- Yes
 No

For the longest crack seen in the Post-Op image, is the crack:

- an Incomplete Crack from the canal towards the root surface
 an Incomplete Crack from the root surface towards the canal
 A complete crack

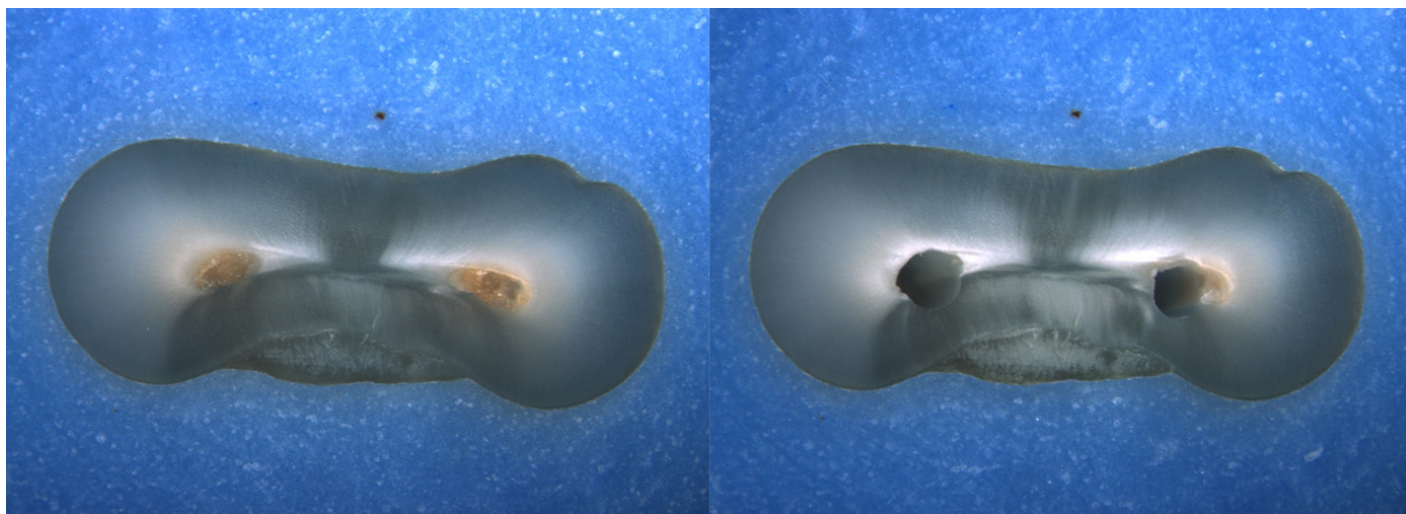
Is the crack seen in the Post-Op image:

- an Incomplete Crack from the canal towards the root surface
 an Incomplete Crack from the root surface towards the canal
 A complete crack

Done. Go to next page

Image: i023.jpg

Pre-Op on the left and Post-Op on the right



Is there any evidence of a dentinal crack prior to rotary instrumentation (Pre-Op)?

- Yes
 No

Does the crack in the Pre-Op image increase in size when viewed in the Post-Op image?

- Yes
 No

Is the crack that increased in the Pre-Op image now:

- an Incomplete Crack from the canal towards the root surface
 an Incomplete Crack from the root surface towards the canal
 A complete crack

Is there a new dentinal crack present in the instrumented (Post-Op) sample not seen in the Pre-Op image?

- Yes
 No

Is the new crack in the Post-Op image:

- an Incomplete Crack from the canal towards the root surface
 an Incomplete Crack from the root surface towards the canal
 A complete crack

Is there a dentinal crack present in the instrumented (Post-Op) sample not seen in the Pre-Op image?

- Yes
 No

Is there more than one crack seen in the Post-Op image?

- Yes
 No

For the longest crack seen in the Post-Op image, is the crack:

- an Incomplete Crack from the canal towards the root surface
 an Incomplete Crack from the root surface towards the canal
 A complete crack

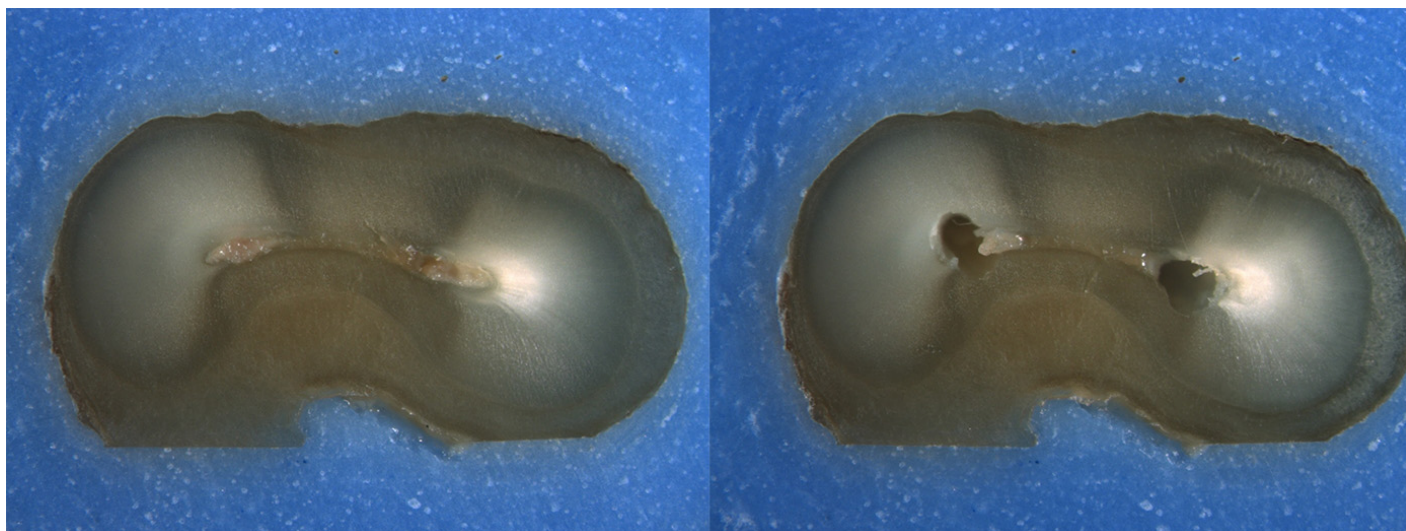
Is the crack seen in the Post-Op image:

- an Incomplete Crack from the canal towards the root surface
 an Incomplete Crack from the root surface towards the canal
 A complete crack

Done. Go to next page

Image: i024.jpg

Pre-Op on the left and Post-Op on the right



Is there any evidence of a dentinal crack prior to rotary instrumentation (Pre-Op)?

- Yes
 No

Does the crack in the Pre-Op image increase in size when viewed in the Post-Op image?

- Yes
 No

Is the crack that increased in the Pre-Op image now:

- an Incomplete Crack from the canal towards the root surface
 an Incomplete Crack from the root surface towards the canal
 A complete crack

Is there a new dentinal crack present in the instrumented (Post-Op) sample not seen in the Pre-Op image?

- Yes
 No

Is the new crack in the Post-Op image:

- an Incomplete Crack from the canal towards the root surface
 an Incomplete Crack from the root surface towards the canal
 A complete crack

Is there a dentinal crack present in the instrumented (Post-Op) sample not seen in the Pre-Op image?

- Yes
 No

Is there more than one crack seen in the Post-Op image?

- Yes
 No

For the longest crack seen in the Post-Op image, is the crack:

- an Incomplete Crack from the canal towards the root surface
 an Incomplete Crack from the root surface towards the canal
 A complete crack

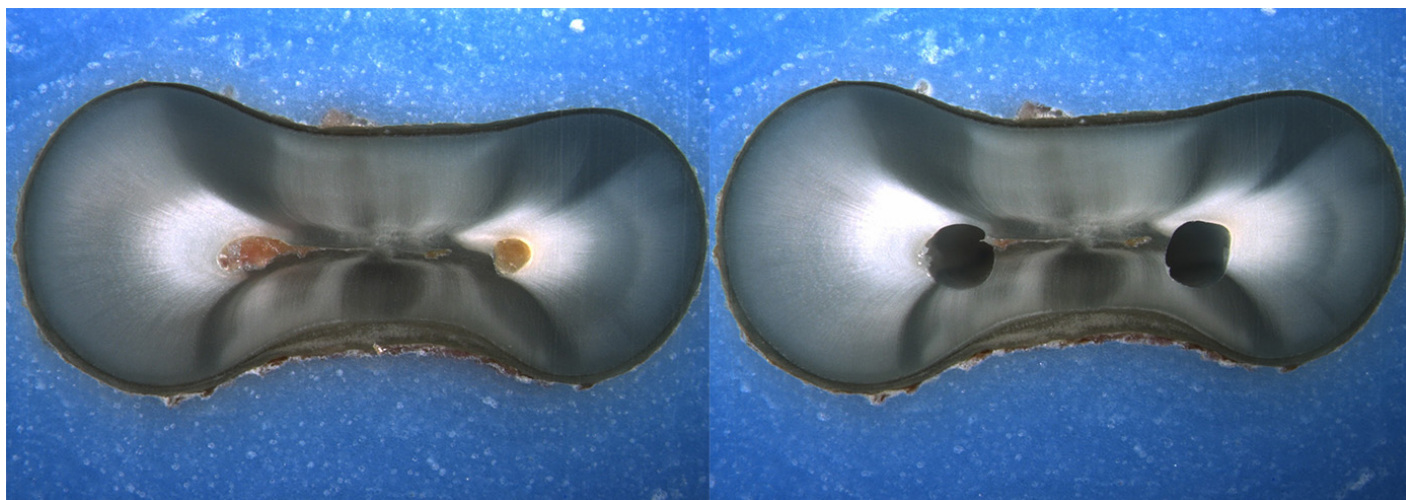
Is the crack seen in the Post-Op image:

- an Incomplete Crack from the canal towards the root surface
 an Incomplete Crack from the root surface towards the canal
 A complete crack

Done. Go to next page

Image: i025.jpg

Pre-Op on the left and Post-Op on the right



Is there any evidence of a dentinal crack prior to rotary instrumentation (Pre-Op)?

- Yes
 No

Does the crack in the Pre-Op image increase in size when viewed in the Post-Op image?

- Yes
 No

Is the crack that increased in the Pre-Op image now:

- an Incomplete Crack from the canal towards the root surface
 an Incomplete Crack from the root surface towards the canal
 A complete crack

Is there a new dentinal crack present in the instrumented (Post-Op) sample not seen in the Pre-Op image?

- Yes
 No

Is the new crack in the Post-Op image:

- an Incomplete Crack from the canal towards the root surface
 an Incomplete Crack from the root surface towards the canal
 A complete crack

Is there a dentinal crack present in the instrumented (Post-Op) sample not seen in the Pre-Op image?

- Yes
 No

Is there more than one crack seen in the Post-Op image?

- Yes
 No

For the longest crack seen in the Post-Op image, is the crack:

- an Incomplete Crack from the canal towards the root surface
 an Incomplete Crack from the root surface towards the canal
 A complete crack

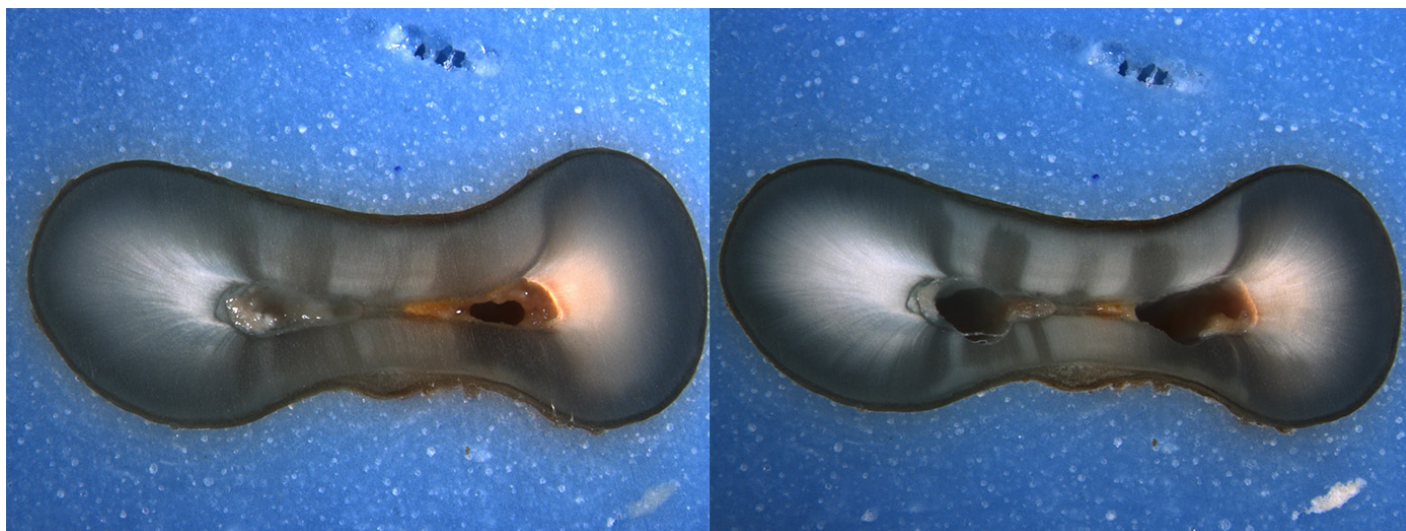
Is the crack seen in the Post-Op image:

- an Incomplete Crack from the canal towards the root surface
 an Incomplete Crack from the root surface towards the canal
 A complete crack

Done. Go to next page

Image: i026.jpg

Pre-Op on the left and Post-Op on the right



Is there any evidence of a dentinal crack prior to rotary instrumentation (Pre-Op)?

- Yes
 No

Does the crack in the Pre-Op image increase in size when viewed in the Post-Op image?

- Yes
 No

Is the crack that increased in the Pre-Op image now:

- an Incomplete Crack from the canal towards the root surface
 an Incomplete Crack from the root surface towards the canal
 A complete crack

Is there a new dentinal crack present in the instrumented (Post-Op) sample not seen in the Pre-Op image?

- Yes
 No

Is the new crack in the Post-Op image:

- an Incomplete Crack from the canal towards the root surface
 an Incomplete Crack from the root surface towards the canal
 A complete crack

Is there a dentinal crack present in the instrumented (Post-Op) sample not seen in the Pre-Op image?

- Yes
 No

Is there more than one crack seen in the Post-Op image?

- Yes
 No

For the longest crack seen in the Post-Op image, is the crack:

- an Incomplete Crack from the canal towards the root surface
 an Incomplete Crack from the root surface towards the canal
 A complete crack

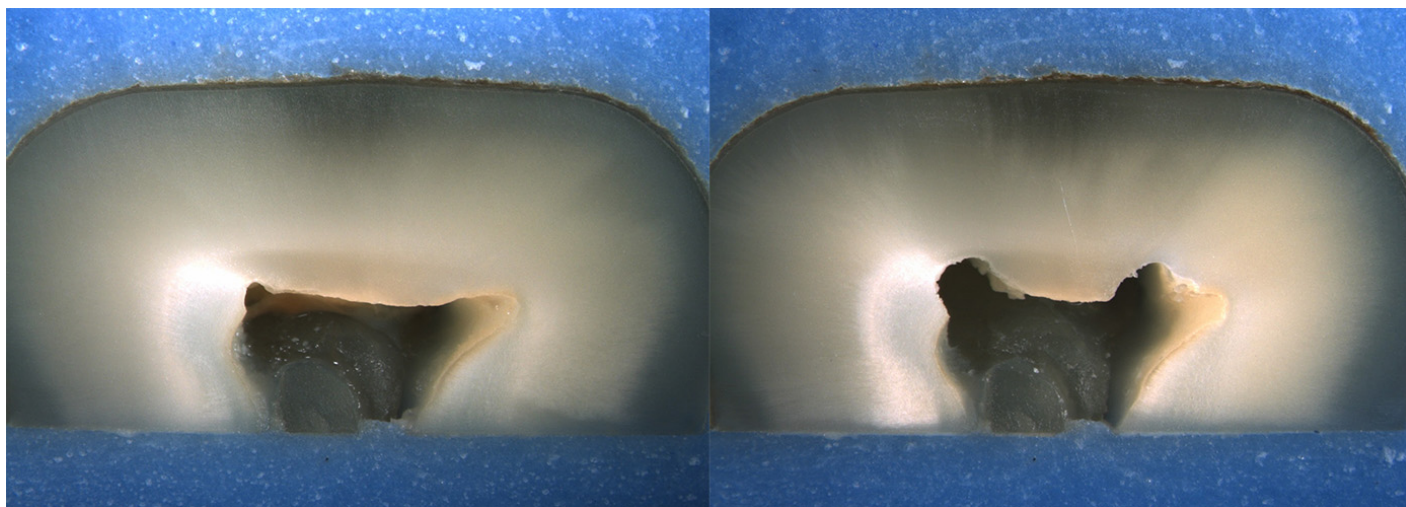
Is the crack seen in the Post-Op image:

- an Incomplete Crack from the canal towards the root surface
 an Incomplete Crack from the root surface towards the canal
 A complete crack

Done. Go to next page

Image: i027.jpg

Pre-Op on the left and Post-Op on the right



Is there any evidence of a dentinal crack prior to rotary instrumentation (Pre-Op)?

- Yes
 No

Does the crack in the Pre-Op image increase in size when viewed in the Post-Op image?

- Yes
 No

Is the crack that increased in the Pre-Op image now:

- an Incomplete Crack from the canal towards the root surface
 an Incomplete Crack from the root surface towards the canal
 A complete crack

Is there a new dentinal crack present in the instrumented (Post-Op) sample not seen in the Pre-Op image?

- Yes
 No

Is the new crack in the Post-Op image:

- an Incomplete Crack from the canal towards the root surface
 an Incomplete Crack from the root surface towards the canal
 A complete crack

Is there a dentinal crack present in the instrumented (Post-Op) sample not seen in the Pre-Op image?

- Yes
 No

Is there more than one crack seen in the Post-Op image?

- Yes
 No

For the longest crack seen in the Post-Op image, is the crack:

- an Incomplete Crack from the canal towards the root surface
 an Incomplete Crack from the root surface towards the canal
 A complete crack

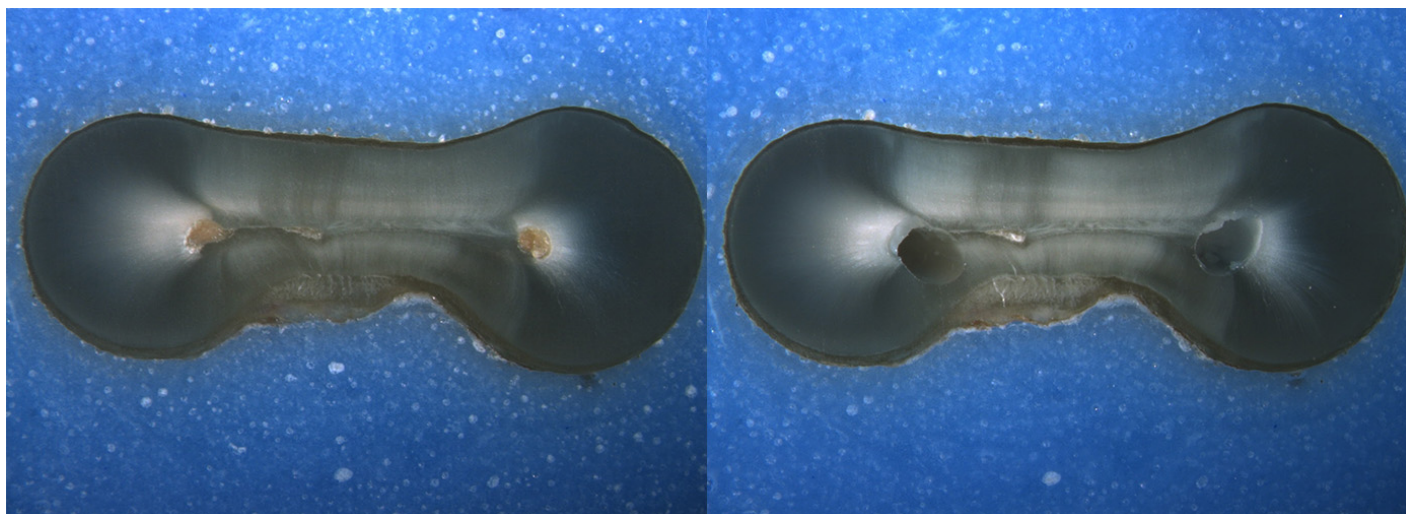
Is the crack seen in the Post-Op image:

- an Incomplete Crack from the canal towards the root surface
 an Incomplete Crack from the root surface towards the canal
 A complete crack

Done. Go to next page

Image: i028.jpg

Pre-Op on the left and Post-Op on the right



Is there any evidence of a dentinal crack prior to rotary instrumentation (Pre-Op)?

- Yes
 No

Does the crack in the Pre-Op image increase in size when viewed in the Post-Op image?

- Yes
 No

Is the crack that increased in the Pre-Op image now:

- an Incomplete Crack from the canal towards the root surface
 an Incomplete Crack from the root surface towards the canal
 A complete crack

Is there a new dentinal crack present in the instrumented (Post-Op) sample not seen in the Pre-Op image?

- Yes
 No

Is the new crack in the Post-Op image:

- an Incomplete Crack from the canal towards the root surface
 an Incomplete Crack from the root surface towards the canal
 A complete crack

Is there a dentinal crack present in the instrumented (Post-Op) sample not seen in the Pre-Op image?

- Yes
 No

Is there more than one crack seen in the Post-Op image?

- Yes
 No

For the longest crack seen in the Post-Op image, is the crack:

- an Incomplete Crack from the canal towards the root surface
 an Incomplete Crack from the root surface towards the canal
 A complete crack

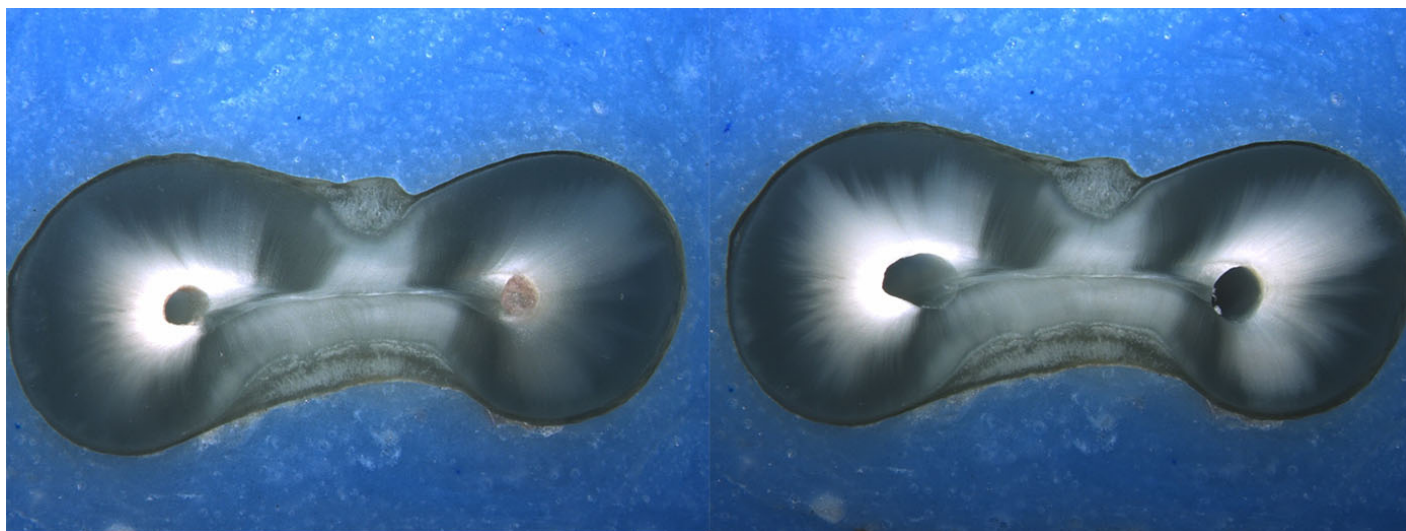
Is the crack seen in the Post-Op image:

- an Incomplete Crack from the canal towards the root surface
 an Incomplete Crack from the root surface towards the canal
 A complete crack

Done. Go to next page

Image: i029.jpg

Pre-Op on the left and Post-Op on the right



Is there any evidence of a dentinal crack prior to rotary instrumentation (Pre-Op)?

- Yes
 No

Does the crack in the Pre-Op image increase in size when viewed in the Post-Op image?

- Yes
 No

Is the crack that increased in the Pre-Op image now:

- an Incomplete Crack from the canal towards the root surface
 an Incomplete Crack from the root surface towards the canal
 A complete crack

Is there a new dentinal crack present in the instrumented (Post-Op) sample not seen in the Pre-Op image?

- Yes
 No

Is the new crack in the Post-Op image:

- an Incomplete Crack from the canal towards the root surface
 an Incomplete Crack from the root surface towards the canal
 A complete crack

Is there a dentinal crack present in the instrumented (Post-Op) sample not seen in the Pre-Op image?

- Yes
 No

Is there more than one crack seen in the Post-Op image?

- Yes
 No

For the longest crack seen in the Post-Op image, is the crack:

- an Incomplete Crack from the canal towards the root surface
 an Incomplete Crack from the root surface towards the canal
 A complete crack


Is the crack seen in the Post-Op image:

- an Incomplete Crack from the canal towards the root surface
 an Incomplete Crack from the root surface towards the canal
 A complete crack

Done. Go to next page

Image: i030.jpg

Pre-Op on the left and Post-Op on the right



Is there any evidence of a dentinal crack prior to rotary instrumentation (Pre-Op)?

- Yes
 No

Does the crack in the Pre-Op image increase in size when viewed in the Post-Op image?

- Yes
 No

Is the crack that increased in the Pre-Op image now:

- an Incomplete Crack from the canal towards the root surface
 an Incomplete Crack from the root surface towards the canal
 A complete crack

Is there a new dentinal crack present in the instrumented (Post-Op) sample not seen in the Pre-Op image?

- Yes
 No

Is the new crack in the Post-Op image:

- an Incomplete Crack from the canal towards the root surface
 an Incomplete Crack from the root surface towards the canal
 A complete crack

Is there a dentinal crack present in the instrumented (Post-Op) sample not seen in the Pre-Op image?

- Yes
 No

Is there more than one crack seen in the Post-Op image?

- Yes
 No

For the longest crack seen in the Post-Op image, is the crack:

- an Incomplete Crack from the canal towards the root surface
 an Incomplete Crack from the root surface towards the canal
 A complete crack

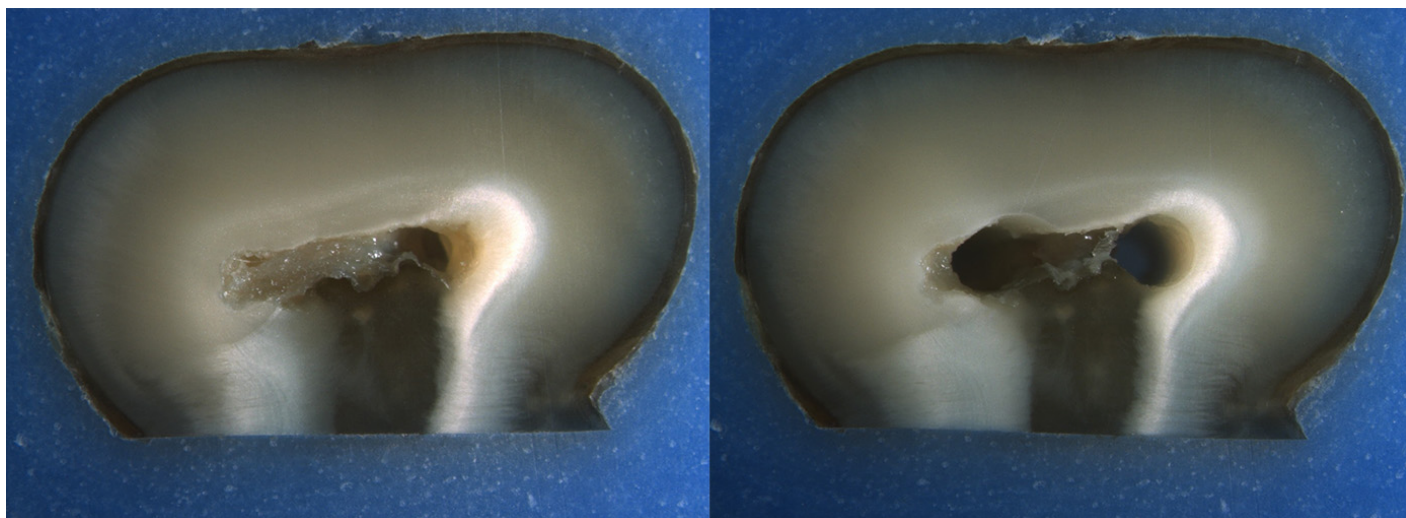
Is the crack seen in the Post-Op image:

- an Incomplete Crack from the canal towards the root surface
 an Incomplete Crack from the root surface towards the canal
 A complete crack

Done. Go to next page

Image: i031.jpg

Pre-Op on the left and Post-Op on the right



Is there any evidence of a dentinal crack prior to rotary instrumentation (Pre-Op)?

- Yes
 No

Does the crack in the Pre-Op image increase in size when viewed in the Post-Op image?

- Yes
 No

Is the crack that increased in the Pre-Op image now:

- an Incomplete Crack from the canal towards the root surface
 an Incomplete Crack from the root surface towards the canal
 A complete crack

Is there a new dentinal crack present in the instrumented (Post-Op) sample not seen in the Pre-Op image?

- Yes
 No

Is the new crack in the Post-Op image:

- an Incomplete Crack from the canal towards the root surface
 an Incomplete Crack from the root surface towards the canal
 A complete crack

Is there a dentinal crack present in the instrumented (Post-Op) sample not seen in the Pre-Op image?

- Yes
 No

Is there more than one crack seen in the Post-Op image?

- Yes
 No

For the longest crack seen in the Post-Op image, is the crack:

- an Incomplete Crack from the canal towards the root surface
 an Incomplete Crack from the root surface towards the canal
 A complete crack

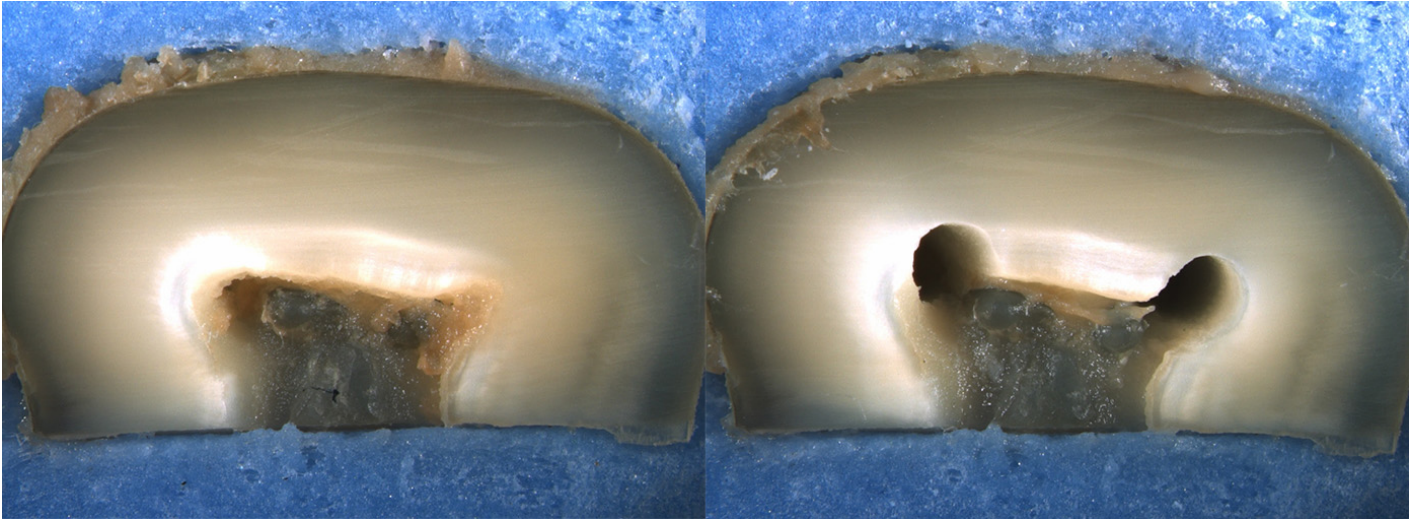
Is the crack seen in the Post-Op image:

- an Incomplete Crack from the canal towards the root surface
 an Incomplete Crack from the root surface towards the canal
 A complete crack

Done. Go to next page

Image: i032.jpg

Pre-Op on the left and Post-Op on the right



Is there any evidence of a dentinal crack prior to rotary instrumentation (Pre-Op)?

- Yes
 No

Does the crack in the Pre-Op image increase in size when viewed in the Post-Op image?

- Yes
 No

Is the crack that increased in the Pre-Op image now:

- an Incomplete Crack from the canal towards the root surface
 an Incomplete Crack from the root surface towards the canal
 A complete crack

Is there a new dentinal crack present in the instrumented (Post-Op) sample not seen in the Pre-Op image?

- Yes
 No

Is the new crack in the Post-Op image:

- an Incomplete Crack from the canal towards the root surface
 an Incomplete Crack from the root surface towards the canal
 A complete crack

Is there a dentinal crack present in the instrumented (Post-Op) sample not seen in the Pre-Op image?

- Yes
 No

Is there more than one crack seen in the Post-Op image?

- Yes
 No

For the longest crack seen in the Post-Op image, is the crack:

- an Incomplete Crack from the canal towards the root surface
 an Incomplete Crack from the root surface towards the canal
 A complete crack

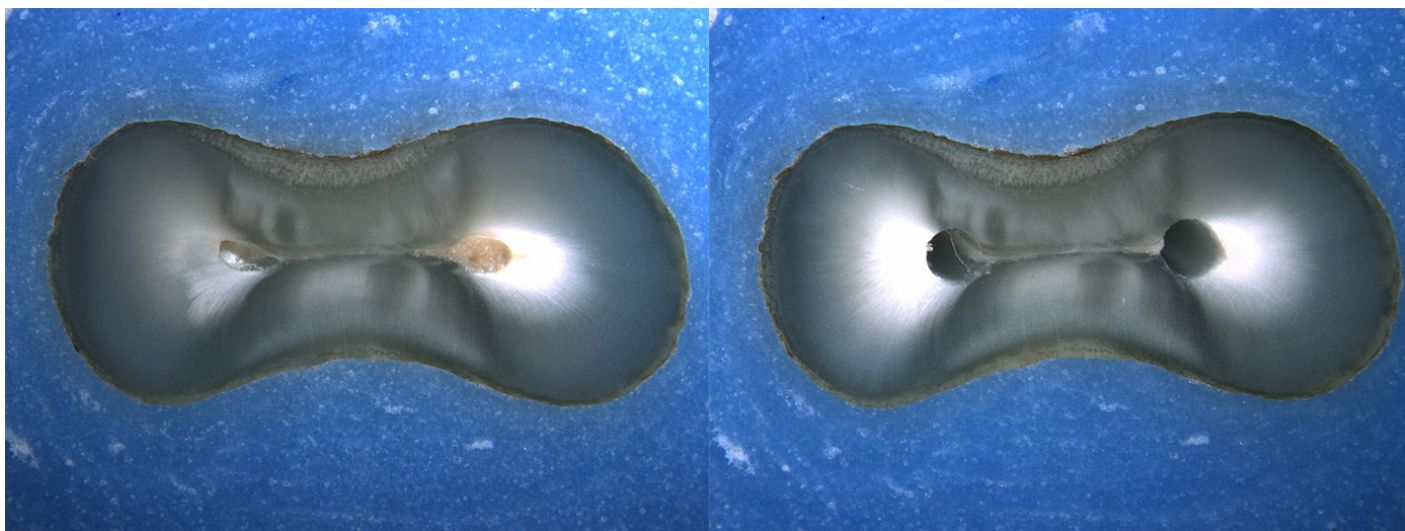
Is the crack seen in the Post-Op image:

- an Incomplete Crack from the canal towards the root surface
 an Incomplete Crack from the root surface towards the canal
 A complete crack

Done. Go to next page

Image: i033.jpg

Pre-Op on the left and Post-Op on the right



Is there any evidence of a dentinal crack prior to rotary instrumentation (Pre-Op)?

- Yes
 No

Does the crack in the Pre-Op image increase in size when viewed in the Post-Op image?

- Yes
 No

Is the crack that increased in the Pre-Op image now:

- an Incomplete Crack from the canal towards the root surface
 an Incomplete Crack from the root surface towards the canal
 A complete crack

Is there a new dentinal crack present in the instrumented (Post-Op) sample not seen in the Pre-Op image?

- Yes
 No

Is the new crack in the Post-Op image:

- an Incomplete Crack from the canal towards the root surface
 an Incomplete Crack from the root surface towards the canal
 A complete crack

Is there a dentinal crack present in the instrumented (Post-Op) sample not seen in the Pre-Op image?

- Yes
 No

Is there more than one crack seen in the Post-Op image?

- Yes
 No

For the longest crack seen in the Post-Op image, is the crack:

- an Incomplete Crack from the canal towards the root surface
 an Incomplete Crack from the root surface towards the canal
 A complete crack


Is the crack seen in the Post-Op image:

- an Incomplete Crack from the canal towards the root surface
 an Incomplete Crack from the root surface towards the canal
 A complete crack

Done. Go to next page

Image: i034.jpg

Pre-Op on the left and Post-Op on the right



Is there any evidence of a dentinal crack prior to rotary instrumentation (Pre-Op)?

- Yes
 No

Does the crack in the Pre-Op image increase in size when viewed in the Post-Op image?

- Yes
 No

Is the crack that increased in the Pre-Op image now:

- an Incomplete Crack from the canal towards the root surface
 an Incomplete Crack from the root surface towards the canal
 A complete crack

Is there a new dentinal crack present in the instrumented (Post-Op) sample not seen in the Pre-Op image?

- Yes
 No

Is the new crack in the Post-Op image:

- an Incomplete Crack from the canal towards the root surface
 an Incomplete Crack from the root surface towards the canal
 A complete crack

Is there a dentinal crack present in the instrumented (Post-Op) sample not seen in the Pre-Op image?

- Yes
 No

Is there more than one crack seen in the Post-Op image?

- Yes
 No

For the longest crack seen in the Post-Op image, is the crack:

- an Incomplete Crack from the canal towards the root surface
 an Incomplete Crack from the root surface towards the canal
 A complete crack

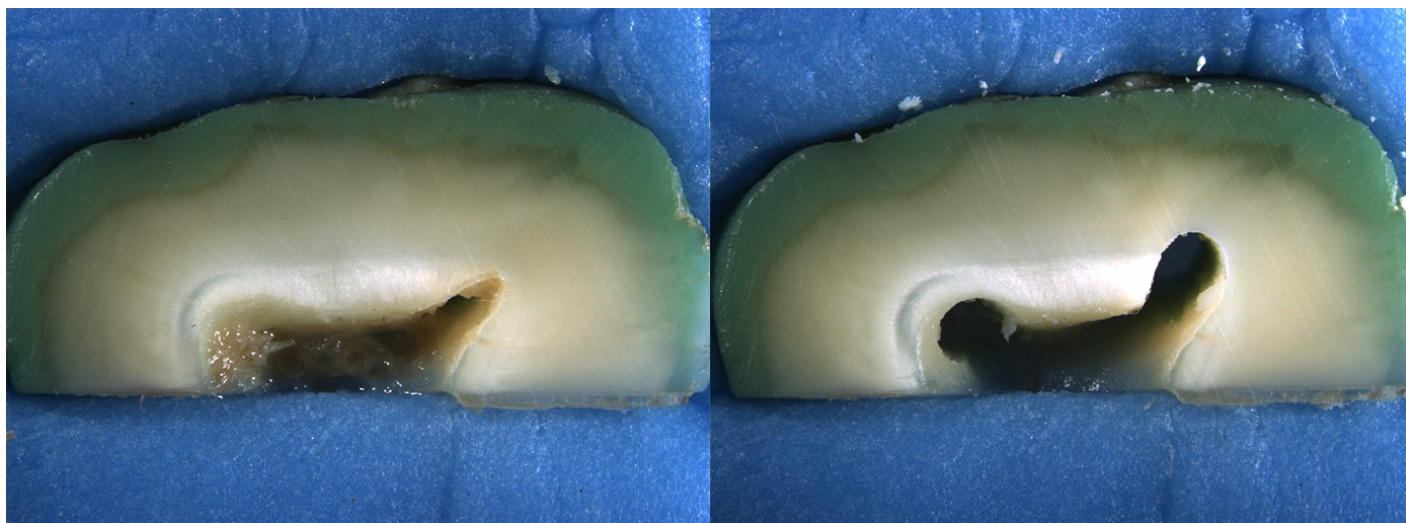
Is the crack seen in the Post-Op image:

- an Incomplete Crack from the canal towards the root surface
 an Incomplete Crack from the root surface towards the canal
 A complete crack

Done. Go to next page

Image: i035.jpg

Pre-Op on the left and Post-Op on the right



Is there any evidence of a dentinal crack prior to rotary instrumentation (Pre-Op)?

- Yes
 No

Does the crack in the Pre-Op image increase in size when viewed in the Post-Op image?

- Yes
 No

Is the crack that increased in the Pre-Op image now:

- an Incomplete Crack from the canal towards the root surface
 an Incomplete Crack from the root surface towards the canal
 A complete crack

Is there a new dentinal crack present in the instrumented (Post-Op) sample not seen in the Pre-Op image?

- Yes
 No

Is the new crack in the Post-Op image:

- an Incomplete Crack from the canal towards the root surface
 an Incomplete Crack from the root surface towards the canal
 A complete crack

Is there a dentinal crack present in the instrumented (Post-Op) sample not seen in the Pre-Op image?

- Yes
 No

Is there more than one crack seen in the Post-Op image?

- Yes
 No

For the longest crack seen in the Post-Op image, is the crack:

- an Incomplete Crack from the canal towards the root surface
 an Incomplete Crack from the root surface towards the canal
 A complete crack


Is the crack seen in the Post-Op image:

- an Incomplete Crack from the canal towards the root surface
 an Incomplete Crack from the root surface towards the canal
 A complete crack

Done. Go to next page

Image: i036.jpg

Pre-Op on the left and Post-Op on the right



Is there any evidence of a dentinal crack prior to rotary instrumentation (Pre-Op)?

- Yes
 No

Does the crack in the Pre-Op image increase in size when viewed in the Post-Op image?

- Yes
 No

Is the crack that increased in the Pre-Op image now:

- an Incomplete Crack from the canal towards the root surface
 an Incomplete Crack from the root surface towards the canal
 A complete crack

Is there a new dentinal crack present in the instrumented (Post-Op) sample not seen in the Pre-Op image?

- Yes
 No

Is the new crack in the Post-Op image:

- an Incomplete Crack from the canal towards the root surface
 an Incomplete Crack from the root surface towards the canal
 A complete crack

Is there a dentinal crack present in the instrumented (Post-Op) sample not seen in the Pre-Op image?

- Yes
 No

Is there more than one crack seen in the Post-Op image?

- Yes
 No

For the longest crack seen in the Post-Op image, is the crack:

- an Incomplete Crack from the canal towards the root surface
 an Incomplete Crack from the root surface towards the canal
 A complete crack


Is the crack seen in the Post-Op image:

- an Incomplete Crack from the canal towards the root surface
 an Incomplete Crack from the root surface towards the canal
 A complete crack

Done. Go to next page

Image: i037.jpg

Pre-Op on the left and Post-Op on the right



Is there any evidence of a dentinal crack prior to rotary instrumentation (Pre-Op)?

- Yes
 No

Does the crack in the Pre-Op image increase in size when viewed in the Post-Op image?

- Yes
 No

Is the crack that increased in the Pre-Op image now:

- an Incomplete Crack from the canal towards the root surface
 an Incomplete Crack from the root surface towards the canal
 A complete crack

Is there a new dentinal crack present in the instrumented (Post-Op) sample not seen in the Pre-Op image?

- Yes
 No

Is the new crack in the Post-Op image:

- an Incomplete Crack from the canal towards the root surface
 an Incomplete Crack from the root surface towards the canal
 A complete crack

Is there a dentinal crack present in the instrumented (Post-Op) sample not seen in the Pre-Op image?

- Yes
 No

Is there more than one crack seen in the Post-Op image?

- Yes
 No

For the longest crack seen in the Post-Op image, is the crack:

- an Incomplete Crack from the canal towards the root surface
 an Incomplete Crack from the root surface towards the canal
 A complete crack

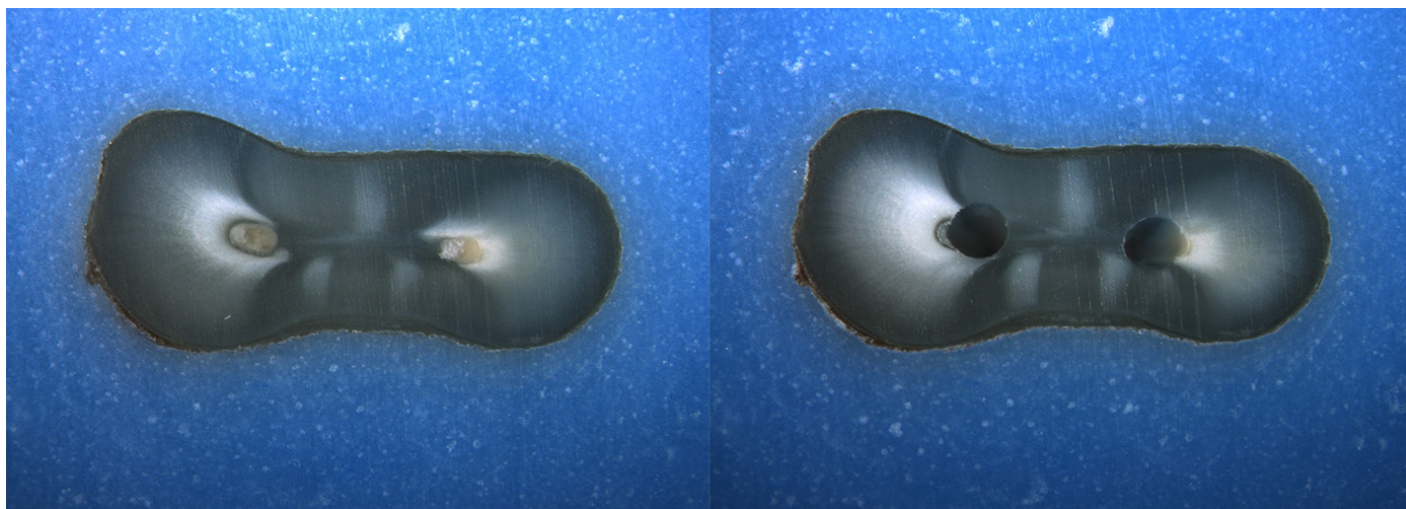
Is the crack seen in the Post-Op image:

- an Incomplete Crack from the canal towards the root surface
 an Incomplete Crack from the root surface towards the canal
 A complete crack

Done. Go to next page

Image: i038.jpg

Pre-Op on the left and Post-Op on the right



Is there any evidence of a dentinal crack prior to rotary instrumentation (Pre-Op)?

- Yes
 No

Does the crack in the Pre-Op image increase in size when viewed in the Post-Op image?

- Yes
 No

Is the crack that increased in the Pre-Op image now:

- an Incomplete Crack from the canal towards the root surface
 an Incomplete Crack from the root surface towards the canal
 A complete crack

Is there a new dentinal crack present in the instrumented (Post-Op) sample not seen in the Pre-Op image?

- Yes
 No

Is the new crack in the Post-Op image:

- an Incomplete Crack from the canal towards the root surface
 an Incomplete Crack from the root surface towards the canal
 A complete crack

Is there a dentinal crack present in the instrumented (Post-Op) sample not seen in the Pre-Op image?

- Yes
 No

Is there more than one crack seen in the Post-Op image?

- Yes
 No

For the longest crack seen in the Post-Op image, is the crack:

- an Incomplete Crack from the canal towards the root surface
 an Incomplete Crack from the root surface towards the canal
 A complete crack


Is the crack seen in the Post-Op image:

- an Incomplete Crack from the canal towards the root surface
 an Incomplete Crack from the root surface towards the canal
 A complete crack

Done. Go to next page

Image: i039.jpg

Pre-Op on the left and Post-Op on the right



Is there any evidence of a dentinal crack prior to rotary instrumentation (Pre-Op)?

- Yes
 No

Does the crack in the Pre-Op image increase in size when viewed in the Post-Op image?

- Yes
 No

Is the crack that increased in the Pre-Op image now:

- an Incomplete Crack from the canal towards the root surface
 an Incomplete Crack from the root surface towards the canal
 A complete crack

Is there a new dentinal crack present in the instrumented (Post-Op) sample not seen in the Pre-Op image?

- Yes
 No

Is the new crack in the Post-Op image:

- an Incomplete Crack from the canal towards the root surface
 an Incomplete Crack from the root surface towards the canal
 A complete crack

Is there a dentinal crack present in the instrumented (Post-Op) sample not seen in the Pre-Op image?

- Yes
 No

Is there more than one crack seen in the Post-Op image?

- Yes
 No

For the longest crack seen in the Post-Op image, is the crack:

- an Incomplete Crack from the canal towards the root surface
 an Incomplete Crack from the root surface towards the canal
 A complete crack

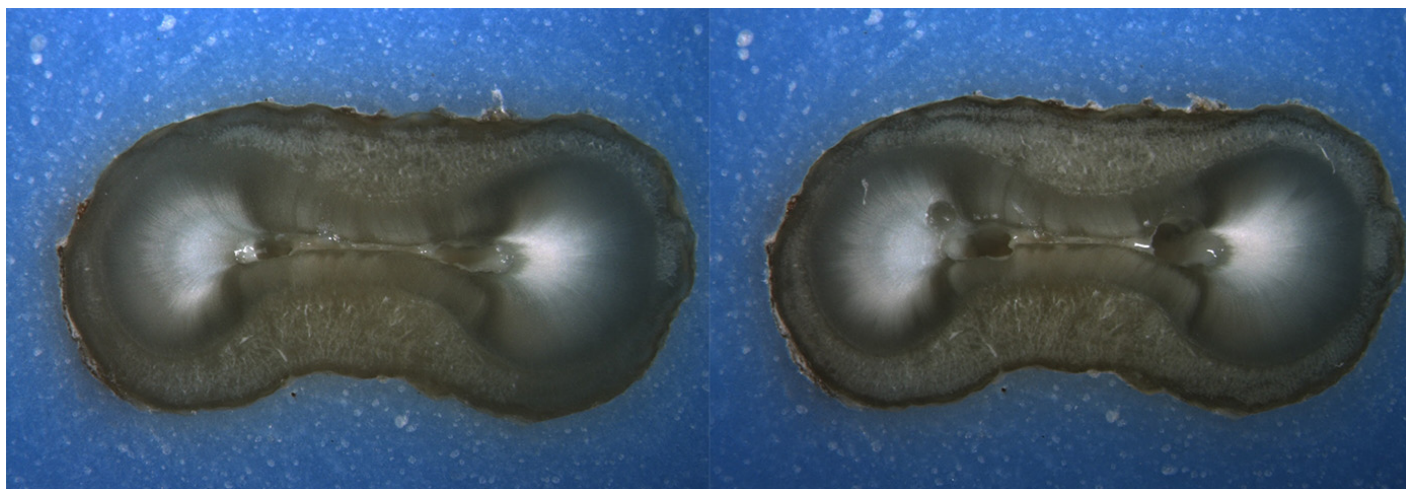
Is the crack seen in the Post-Op image:

- an Incomplete Crack from the canal towards the root surface
 an Incomplete Crack from the root surface towards the canal
 A complete crack

Done. Go to next page

Image: i040.jpg

Pre-Op on the left and Post-Op on the right



Is there any evidence of a dentinal crack prior to rotary instrumentation (Pre-Op)?

- Yes
 No

Does the crack in the Pre-Op image increase in size when viewed in the Post-Op image?

- Yes
 No

Is the crack that increased in the Pre-Op image now:

- an Incomplete Crack from the canal towards the root surface
 an Incomplete Crack from the root surface towards the canal
 A complete crack

Is there a new dentinal crack present in the instrumented (Post-Op) sample not seen in the Pre-Op image?

- Yes
 No

Is the new crack in the Post-Op image:

- an Incomplete Crack from the canal towards the root surface
 an Incomplete Crack from the root surface towards the canal
 A complete crack

Is there a dentinal crack present in the instrumented (Post-Op) sample not seen in the Pre-Op image?

- Yes
 No

Is there more than one crack seen in the Post-Op image?

- Yes
 No

For the longest crack seen in the Post-Op image, is the crack:

- an Incomplete Crack from the canal towards the root surface
 an Incomplete Crack from the root surface towards the canal
 A complete crack

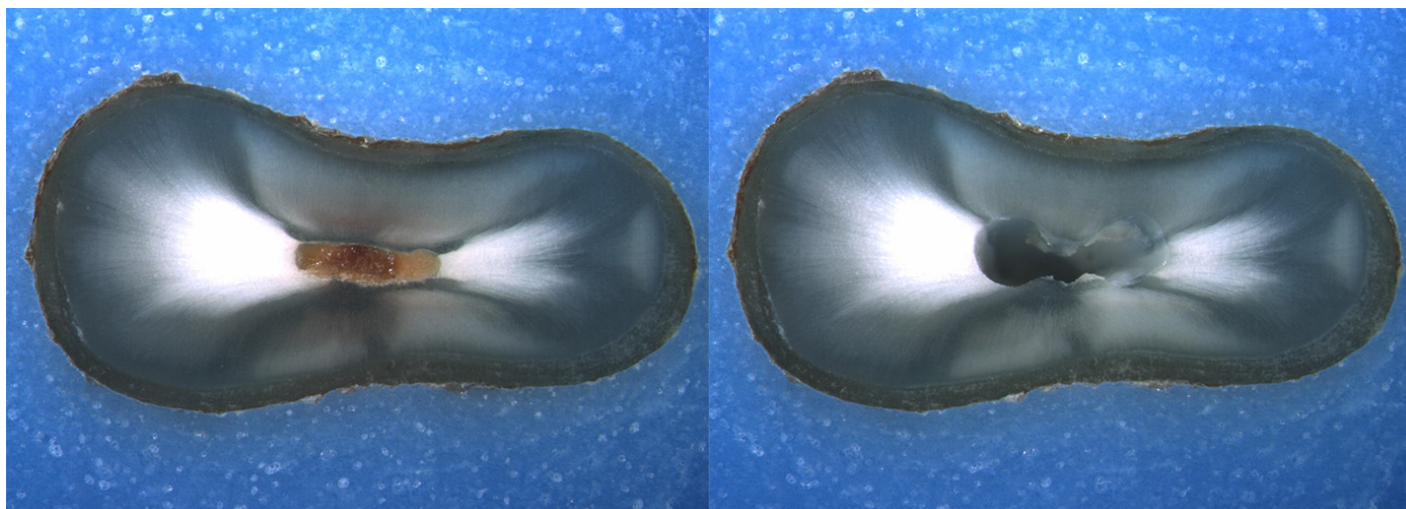
Is the crack seen in the Post-Op image:

- an Incomplete Crack from the canal towards the root surface
 an Incomplete Crack from the root surface towards the canal
 A complete crack

Done. Go to next page

Image: i041.jpg

Pre-Op on the left and Post-Op on the right



Is there any evidence of a dentinal crack prior to rotary instrumentation (Pre-Op)?

- Yes
 No

Does the crack in the Pre-Op image increase in size when viewed in the Post-Op image?

- Yes
 No

Is the crack that increased in the Pre-Op image now:

- an Incomplete Crack from the canal towards the root surface
 an Incomplete Crack from the root surface towards the canal
 A complete crack

Is there a new dentinal crack present in the instrumented (Post-Op) sample not seen in the Pre-Op image?

- Yes
 No

Is the new crack in the Post-Op image:

- an Incomplete Crack from the canal towards the root surface
 an Incomplete Crack from the root surface towards the canal
 A complete crack

Is there a dentinal crack present in the instrumented (Post-Op) sample not seen in the Pre-Op image?

- Yes
 No

Is there more than one crack seen in the Post-Op image?

- Yes
 No

For the longest crack seen in the Post-Op image, is the crack:

- an Incomplete Crack from the canal towards the root surface
 an Incomplete Crack from the root surface towards the canal
 A complete crack

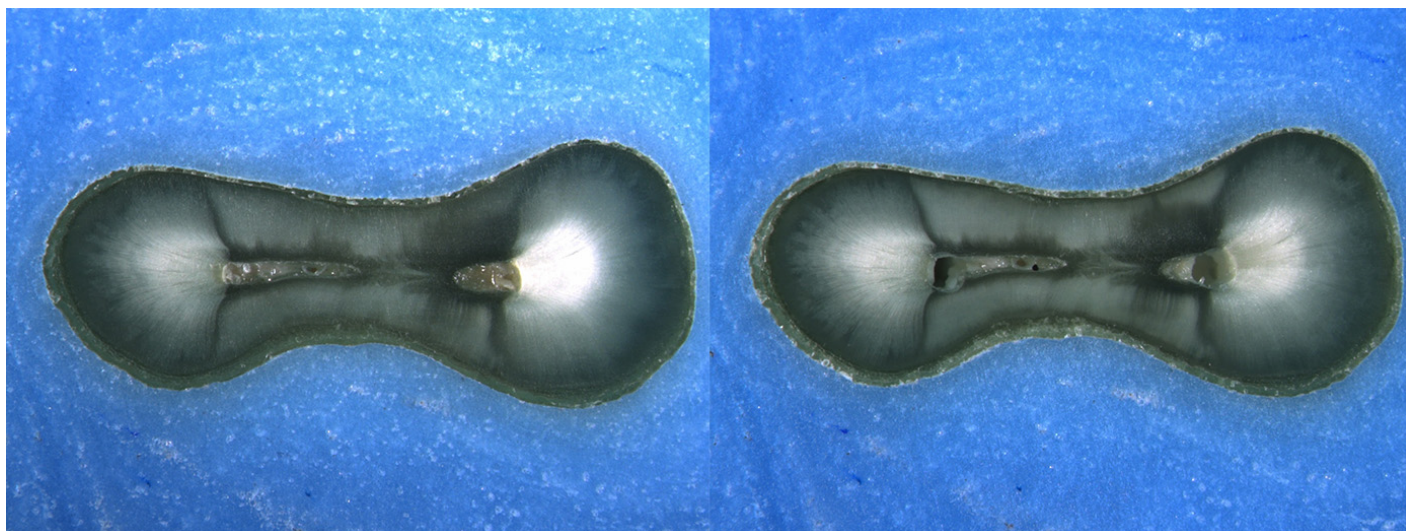
Is the crack seen in the Post-Op image:

- an Incomplete Crack from the canal towards the root surface
 an Incomplete Crack from the root surface towards the canal
 A complete crack

Done. Go to next page

Image: i042.jpg

Pre-Op on the left and Post-Op on the right



Is there any evidence of a dentinal crack prior to rotary instrumentation (Pre-Op)?

- Yes
 No

Does the crack in the Pre-Op image increase in size when viewed in the Post-Op image?

- Yes
 No

Is the crack that increased in the Pre-Op image now:

- an Incomplete Crack from the canal towards the root surface
 an Incomplete Crack from the root surface towards the canal
 A complete crack

Is there a new dentinal crack present in the instrumented (Post-Op) sample not seen in the Pre-Op image?

- Yes
 No

Is the new crack in the Post-Op image:

- an Incomplete Crack from the canal towards the root surface
 an Incomplete Crack from the root surface towards the canal
 A complete crack

Is there a dentinal crack present in the instrumented (Post-Op) sample not seen in the Pre-Op image?

- Yes
 No

Is there more than one crack seen in the Post-Op image?

- Yes
 No

For the longest crack seen in the Post-Op image, is the crack:

- an Incomplete Crack from the canal towards the root surface
 an Incomplete Crack from the root surface towards the canal
 A complete crack


Is the crack seen in the Post-Op image:

- an Incomplete Crack from the canal towards the root surface
 an Incomplete Crack from the root surface towards the canal
 A complete crack

Done. Go to next page

Image: i043.jpg

Pre-Op on the left and Post-Op on the right



Is there any evidence of a dentinal crack prior to rotary instrumentation (Pre-Op)?

- Yes
 No

Does the crack in the Pre-Op image increase in size when viewed in the Post-Op image?

- Yes
 No

Is the crack that increased in the Pre-Op image now:

- an Incomplete Crack from the canal towards the root surface
 an Incomplete Crack from the root surface towards the canal
 A complete crack

Is there a new dentinal crack present in the instrumented (Post-Op) sample not seen in the Pre-Op image?

- Yes
 No

Is the new crack in the Post-Op image:

- an Incomplete Crack from the canal towards the root surface
 an Incomplete Crack from the root surface towards the canal
 A complete crack

Is there a dentinal crack present in the instrumented (Post-Op) sample not seen in the Pre-Op image?

- Yes
 No

Is there more than one crack seen in the Post-Op image?

- Yes
 No

For the longest crack seen in the Post-Op image, is the crack:

- an Incomplete Crack from the canal towards the root surface
 an Incomplete Crack from the root surface towards the canal
 A complete crack

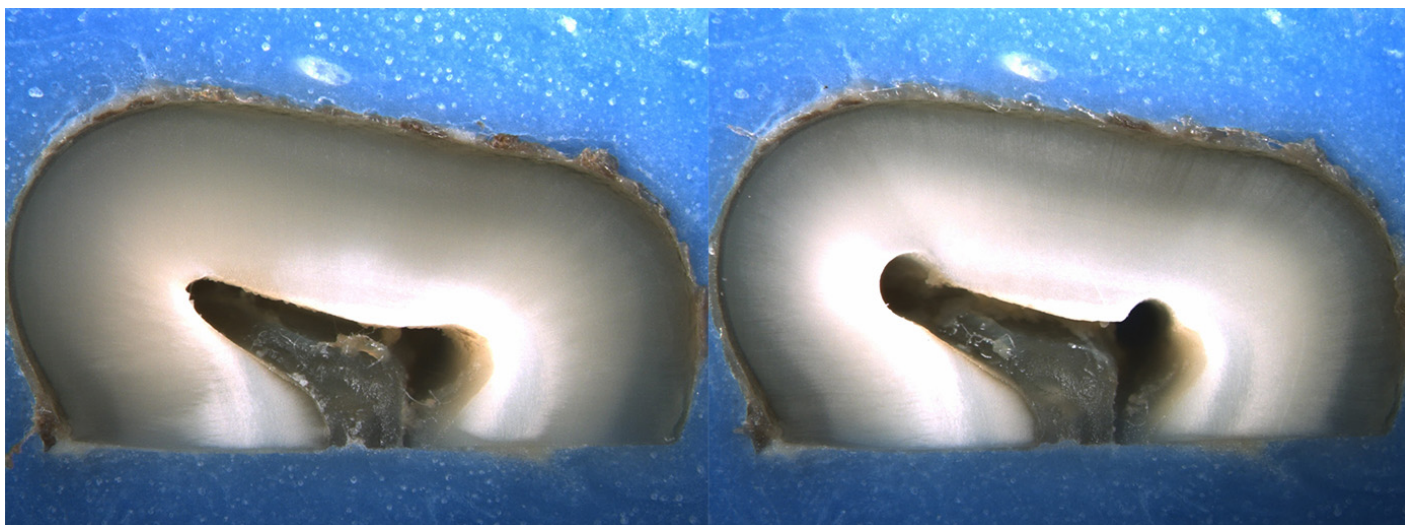
Is the crack seen in the Post-Op image:

- an Incomplete Crack from the canal towards the root surface
 an Incomplete Crack from the root surface towards the canal
 A complete crack

Done. Go to next page

Image: i044.jpg

Pre-Op on the left and Post-Op on the right



Is there any evidence of a dentinal crack prior to rotary instrumentation (Pre-Op)?

- Yes
 No

Does the crack in the Pre-Op image increase in size when viewed in the Post-Op image?

- Yes
 No

Is the crack that increased in the Pre-Op image now:

- an Incomplete Crack from the canal towards the root surface
 an Incomplete Crack from the root surface towards the canal
 A complete crack

Is there a new dentinal crack present in the instrumented (Post-Op) sample not seen in the Pre-Op image?

- Yes
 No

Is the new crack in the Post-Op image:

- an Incomplete Crack from the canal towards the root surface
 an Incomplete Crack from the root surface towards the canal
 A complete crack

Is there a dentinal crack present in the instrumented (Post-Op) sample not seen in the Pre-Op image?

- Yes
 No

Is there more than one crack seen in the Post-Op image?

- Yes
 No

For the longest crack seen in the Post-Op image, is the crack:

- an Incomplete Crack from the canal towards the root surface
 an Incomplete Crack from the root surface towards the canal
 A complete crack

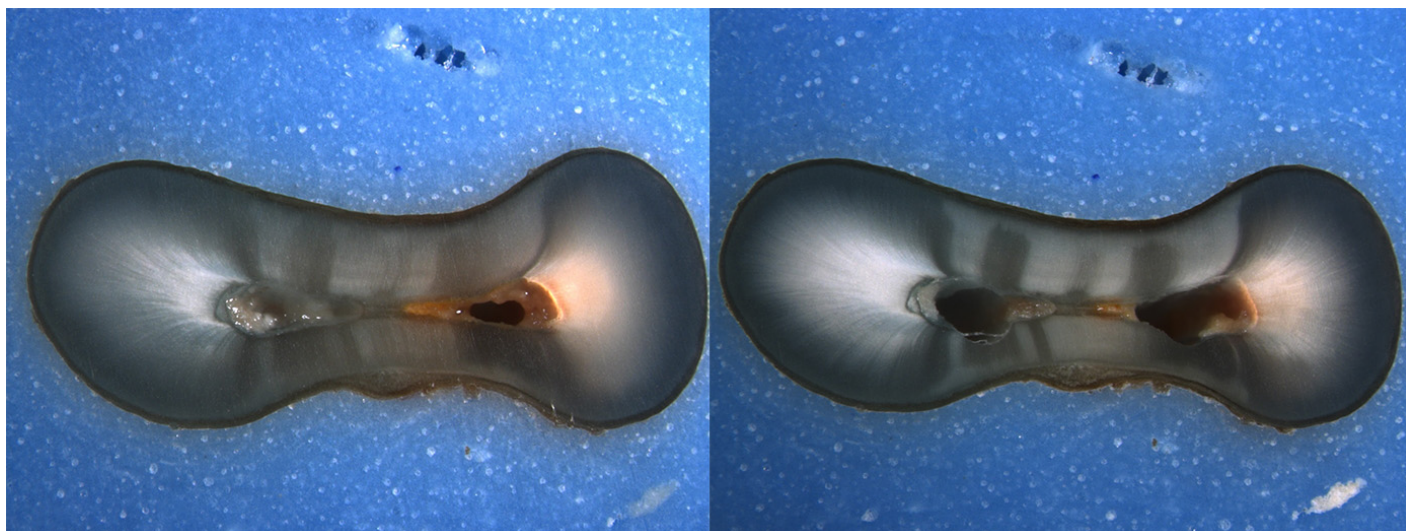
Is the crack seen in the Post-Op image:

- an Incomplete Crack from the canal towards the root surface
 an Incomplete Crack from the root surface towards the canal
 A complete crack

Done. Go to next page

Image: i045.jpg

Pre-Op on the left and Post-Op on the right



Is there any evidence of a dentinal crack prior to rotary instrumentation (Pre-Op)?

- Yes
 No

Does the crack in the Pre-Op image increase in size when viewed in the Post-Op image?

- Yes
 No

Is the crack that increased in the Pre-Op image now:

- an Incomplete Crack from the canal towards the root surface
 an Incomplete Crack from the root surface towards the canal
 A complete crack

Is there a new dentinal crack present in the instrumented (Post-Op) sample not seen in the Pre-Op image?

- Yes
 No

Is the new crack in the Post-Op image:

- an Incomplete Crack from the canal towards the root surface
 an Incomplete Crack from the root surface towards the canal
 A complete crack

Is there a dentinal crack present in the instrumented (Post-Op) sample not seen in the Pre-Op image?

- Yes
 No

Is there more than one crack seen in the Post-Op image?

- Yes
 No

For the longest crack seen in the Post-Op image, is the crack:

- an Incomplete Crack from the canal towards the root surface
 an Incomplete Crack from the root surface towards the canal
 A complete crack

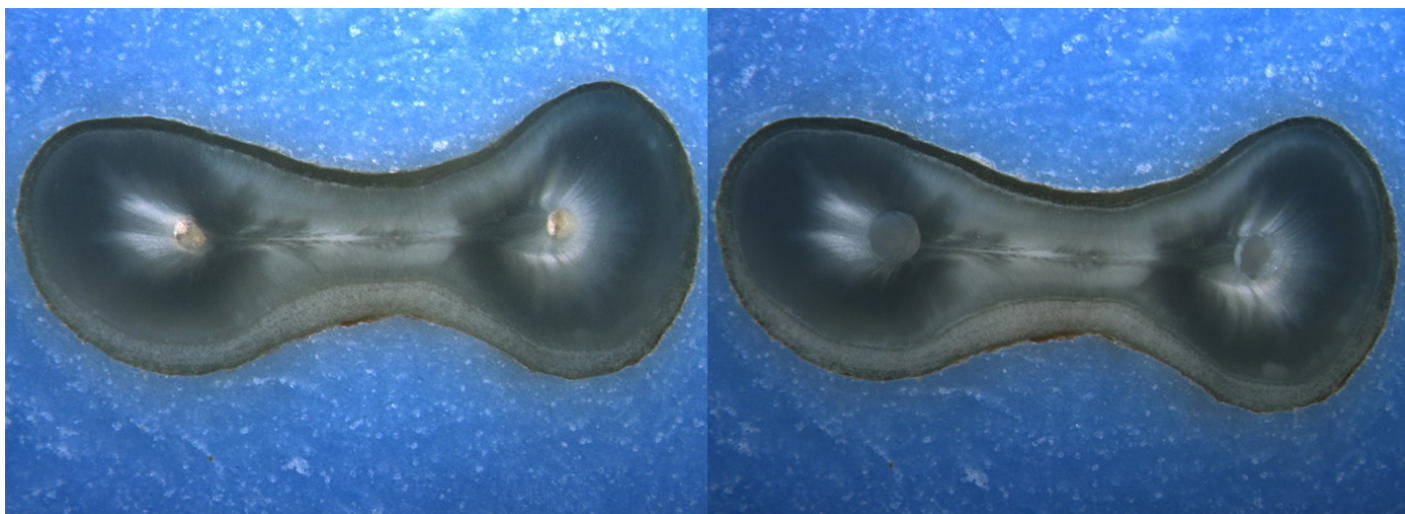
Is the crack seen in the Post-Op image:

- an Incomplete Crack from the canal towards the root surface
 an Incomplete Crack from the root surface towards the canal
 A complete crack

Done. Go to next page

Image: i046.jpg

Pre-Op on the left and Post-Op on the right



Is there any evidence of a dentinal crack prior to rotary instrumentation (Pre-Op)?

- Yes
 No

Does the crack in the Pre-Op image increase in size when viewed in the Post-Op image?

- Yes
 No

Is the crack that increased in the Pre-Op image now:

- an Incomplete Crack from the canal towards the root surface
 an Incomplete Crack from the root surface towards the canal
 A complete crack

Is there a new dentinal crack present in the instrumented (Post-Op) sample not seen in the Pre-Op image?

- Yes
 No

Is the new crack in the Post-Op image:

- an Incomplete Crack from the canal towards the root surface
 an Incomplete Crack from the root surface towards the canal
 A complete crack

Is there a dentinal crack present in the instrumented (Post-Op) sample not seen in the Pre-Op image?

- Yes
 No

Is there more than one crack seen in the Post-Op image?

- Yes
 No

For the longest crack seen in the Post-Op image, is the crack:

- an Incomplete Crack from the canal towards the root surface
 an Incomplete Crack from the root surface towards the canal
 A complete crack

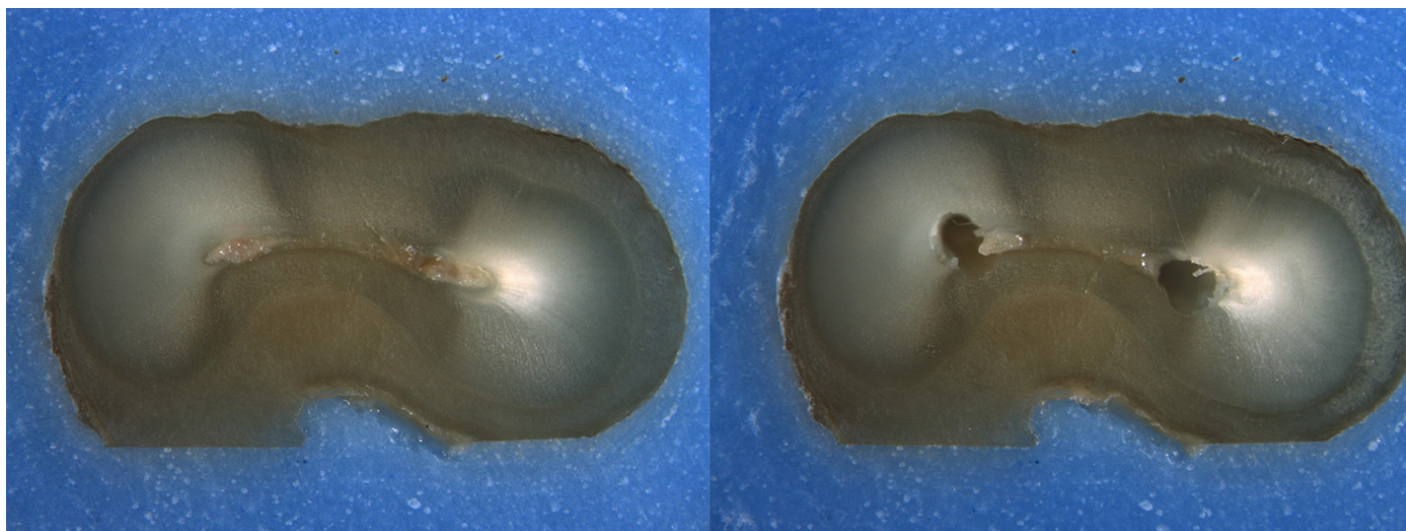
Is the crack seen in the Post-Op image:

- an Incomplete Crack from the canal towards the root surface
 an Incomplete Crack from the root surface towards the canal
 A complete crack

Done. Go to next page

Image: i047.jpg

Pre-Op on the left and Post-Op on the right



Is there any evidence of a dentinal crack prior to rotary instrumentation (Pre-Op)?

- Yes
 No

Does the crack in the Pre-Op image increase in size when viewed in the Post-Op image?

- Yes
 No

Is the crack that increased in the Pre-Op image now:

- an Incomplete Crack from the canal towards the root surface
 an Incomplete Crack from the root surface towards the canal
 A complete crack

Is there a new dentinal crack present in the instrumented (Post-Op) sample not seen in the Pre-Op image?

- Yes
 No

Is the new crack in the Post-Op image:

- an Incomplete Crack from the canal towards the root surface
 an Incomplete Crack from the root surface towards the canal
 A complete crack

Is there a dentinal crack present in the instrumented (Post-Op) sample not seen in the Pre-Op image?

- Yes
 No

Is there more than one crack seen in the Post-Op image?

- Yes
 No

For the longest crack seen in the Post-Op image, is the crack:

- an Incomplete Crack from the canal towards the root surface
 an Incomplete Crack from the root surface towards the canal
 A complete crack

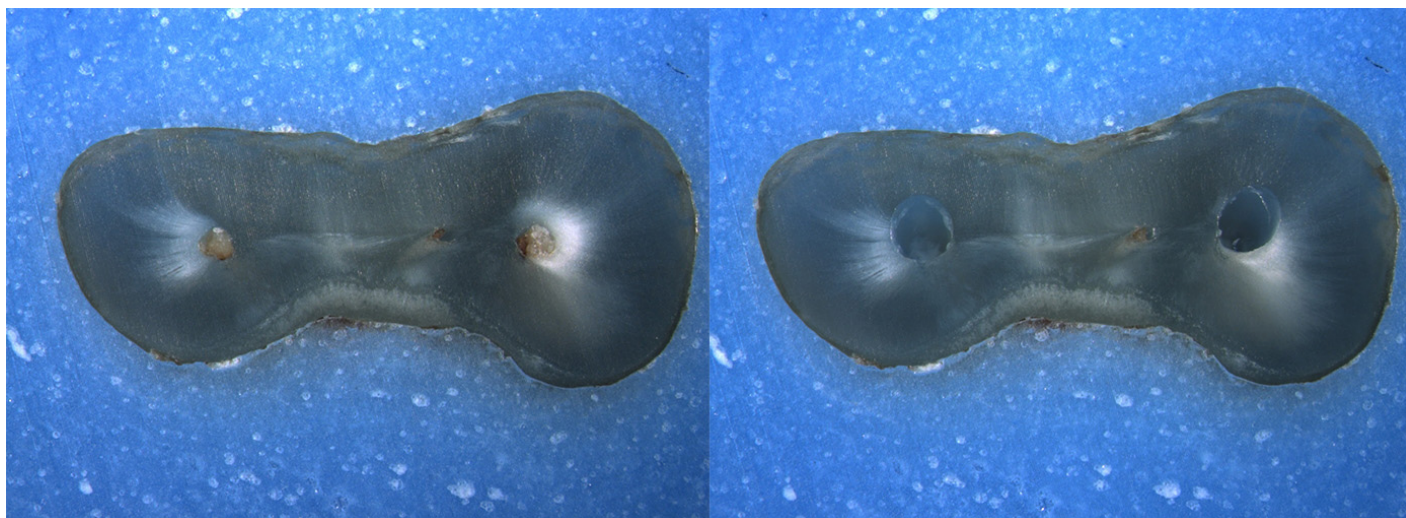
Is the crack seen in the Post-Op image:

- an Incomplete Crack from the canal towards the root surface
 an Incomplete Crack from the root surface towards the canal
 A complete crack

Done. Go to next page

Image: i048.jpg

Pre-Op on the left and Post-Op on the right



Is there any evidence of a dentinal crack prior to rotary instrumentation (Pre-Op)?

- Yes
 No

Does the crack in the Pre-Op image increase in size when viewed in the Post-Op image?

- Yes
 No

Is the crack that increased in the Pre-Op image now:

- an Incomplete Crack from the canal towards the root surface
 an Incomplete Crack from the root surface towards the canal
 A complete crack

Is there a new dentinal crack present in the instrumented (Post-Op) sample not seen in the Pre-Op image?

- Yes
 No

Is the new crack in the Post-Op image:

- an Incomplete Crack from the canal towards the root surface
 an Incomplete Crack from the root surface towards the canal
 A complete crack

Is there a dentinal crack present in the instrumented (Post-Op) sample not seen in the Pre-Op image?

- Yes
 No

Is there more than one crack seen in the Post-Op image?

- Yes
 No

For the longest crack seen in the Post-Op image, is the crack:

- an Incomplete Crack from the canal towards the root surface
 an Incomplete Crack from the root surface towards the canal
 A complete crack

Is the crack seen in the Post-Op image:

- an Incomplete Crack from the canal towards the root surface
 an Incomplete Crack from the root surface towards the canal
 A complete crack

Done with this batch. Yay!

Cracks in Pre-Op vs Post-Op images

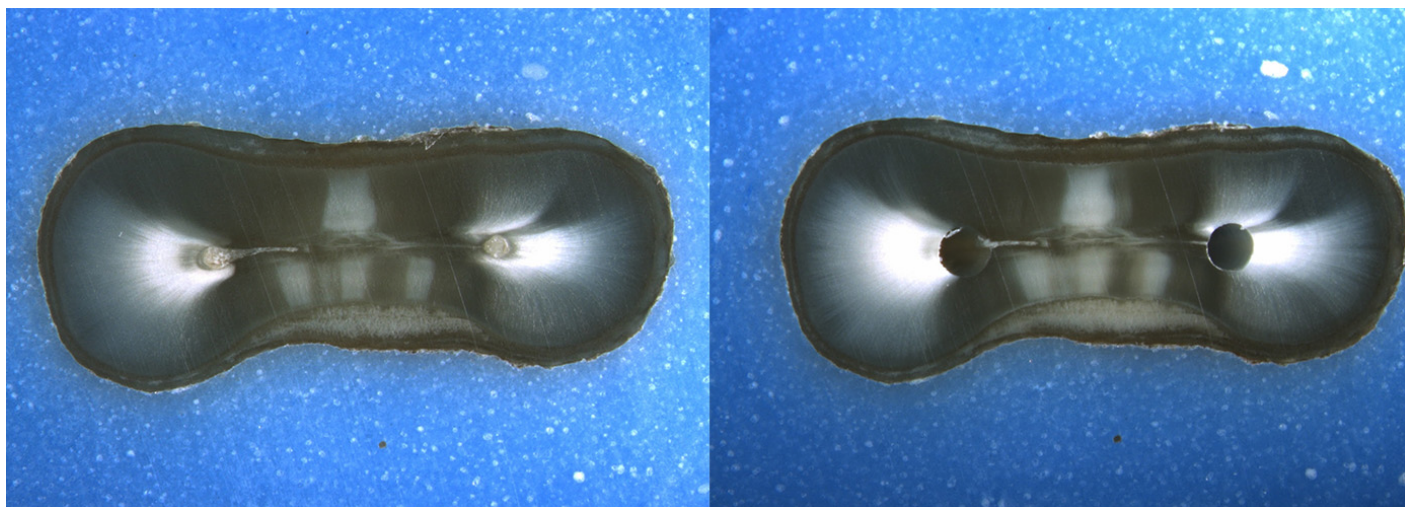
Please complete the survey below.

Thank you!

Rater's last name

Image: i049.jpg

Pre-Op on the left and Post-Op on the right



Is there any evidence of a dentinal crack prior to rotary instrumentation (Pre-Op)?

- Yes
 No

Does the crack in the Pre-Op image increase in size when viewed in the Post-Op image?

- Yes
 No

Is the crack that increased in the Pre-Op image now:

- an Incomplete Crack from the canal towards the root surface
 an Incomplete Crack from the root surface towards the canal
 A complete crack

Is there a new dentinal crack present in the instrumented (Post-Op) sample not seen in the Pre-Op image?

- Yes
 No

Is the new crack in the Post-Op image:

- an Incomplete Crack from the canal towards the root surface
 an Incomplete Crack from the root surface towards the canal
 A complete crack

Is there a dentinal crack present in the instrumented (Post-Op) sample not seen in the Pre-Op image?

- Yes
 No

Is there more than one crack seen in the Post-Op image?

- Yes
 No

For the longest crack seen in the Post-Op image, is the crack:

- an Incomplete Crack from the canal towards the root surface
 an Incomplete Crack from the root surface towards the canal
 A complete crack

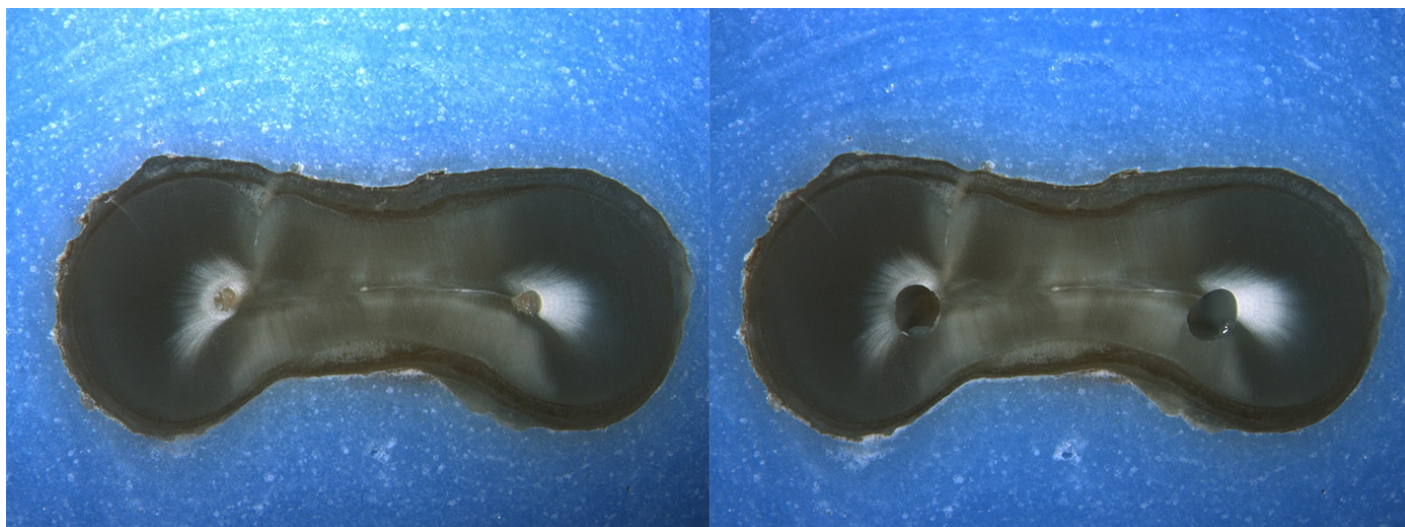
Is the crack seen in the Post-Op image:

- an Incomplete Crack from the canal towards the root surface
 an Incomplete Crack from the root surface towards the canal
 A complete crack

Done. Go to next page

Image: i050.jpg

Pre-Op on the left and Post-Op on the right



Is there any evidence of a dentinal crack prior to rotary instrumentation (Pre-Op)?

- Yes
 No

Does the crack in the Pre-Op image increase in size when viewed in the Post-Op image?

- Yes
 No

Is the crack that increased in the Pre-Op image now:

- an Incomplete Crack from the canal towards the root surface
 an Incomplete Crack from the root surface towards the canal
 A complete crack

Is there a new dentinal crack present in the instrumented (Post-Op) sample not seen in the Pre-Op image?

- Yes
 No

Is the new crack in the Post-Op image:

- an Incomplete Crack from the canal towards the root surface
 an Incomplete Crack from the root surface towards the canal
 A complete crack

Is there a dentinal crack present in the instrumented (Post-Op) sample not seen in the Pre-Op image?

- Yes
 No

Is there more than one crack seen in the Post-Op image?

- Yes
 No

For the longest crack seen in the Post-Op image, is the crack:

- an Incomplete Crack from the canal towards the root surface
 an Incomplete Crack from the root surface towards the canal
 A complete crack

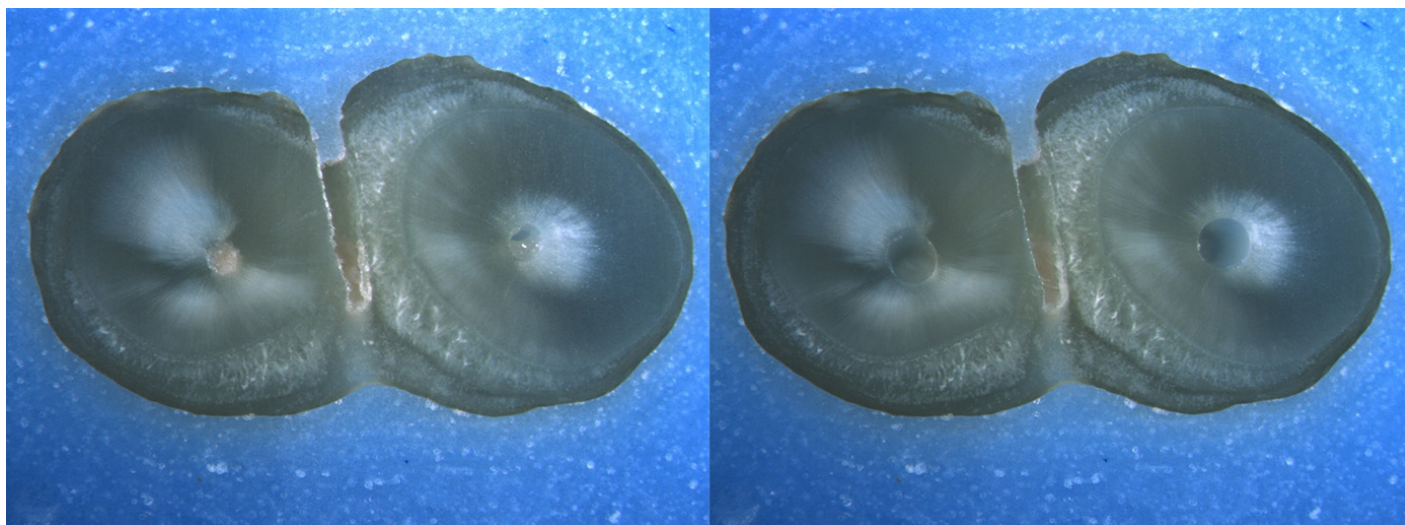
Is the crack seen in the Post-Op image:

- an Incomplete Crack from the canal towards the root surface
 an Incomplete Crack from the root surface towards the canal
 A complete crack

Done. Go to next page

Image: i051.jpg

Pre-Op on the left and Post-Op on the right



Is there any evidence of a dentinal crack prior to rotary instrumentation (Pre-Op)?

- Yes
 No

Does the crack in the Pre-Op image increase in size when viewed in the Post-Op image?

- Yes
 No

Is the crack that increased in the Pre-Op image now:

- an Incomplete Crack from the canal towards the root surface
 an Incomplete Crack from the root surface towards the canal
 A complete crack

Is there a new dentinal crack present in the instrumented (Post-Op) sample not seen in the Pre-Op image?

- Yes
 No

Is the new crack in the Post-Op image:

- an Incomplete Crack from the canal towards the root surface
 an Incomplete Crack from the root surface towards the canal
 A complete crack

Is there a dentinal crack present in the instrumented (Post-Op) sample not seen in the Pre-Op image?

- Yes
 No

Is there more than one crack seen in the Post-Op image?

- Yes
 No

For the longest crack seen in the Post-Op image, is the crack:

- an Incomplete Crack from the canal towards the root surface
 an Incomplete Crack from the root surface towards the canal
 A complete crack


Is the crack seen in the Post-Op image:

- an Incomplete Crack from the canal towards the root surface
 an Incomplete Crack from the root surface towards the canal
 A complete crack

Done. Go to next page

Image: i052.jpg

Pre-Op on the left and Post-Op on the right



Is there any evidence of a dentinal crack prior to rotary instrumentation (Pre-Op)?

- Yes
 No

Does the crack in the Pre-Op image increase in size when viewed in the Post-Op image?

- Yes
 No

Is the crack that increased in the Pre-Op image now:

- an Incomplete Crack from the canal towards the root surface
 an Incomplete Crack from the root surface towards the canal
 A complete crack

Is there a new dentinal crack present in the instrumented (Post-Op) sample not seen in the Pre-Op image?

- Yes
 No

Is the new crack in the Post-Op image:

- an Incomplete Crack from the canal towards the root surface
 an Incomplete Crack from the root surface towards the canal
 A complete crack

Is there a dentinal crack present in the instrumented (Post-Op) sample not seen in the Pre-Op image?

- Yes
 No

Is there more than one crack seen in the Post-Op image?

- Yes
 No

For the longest crack seen in the Post-Op image, is the crack:

- an Incomplete Crack from the canal towards the root surface
 an Incomplete Crack from the root surface towards the canal
 A complete crack

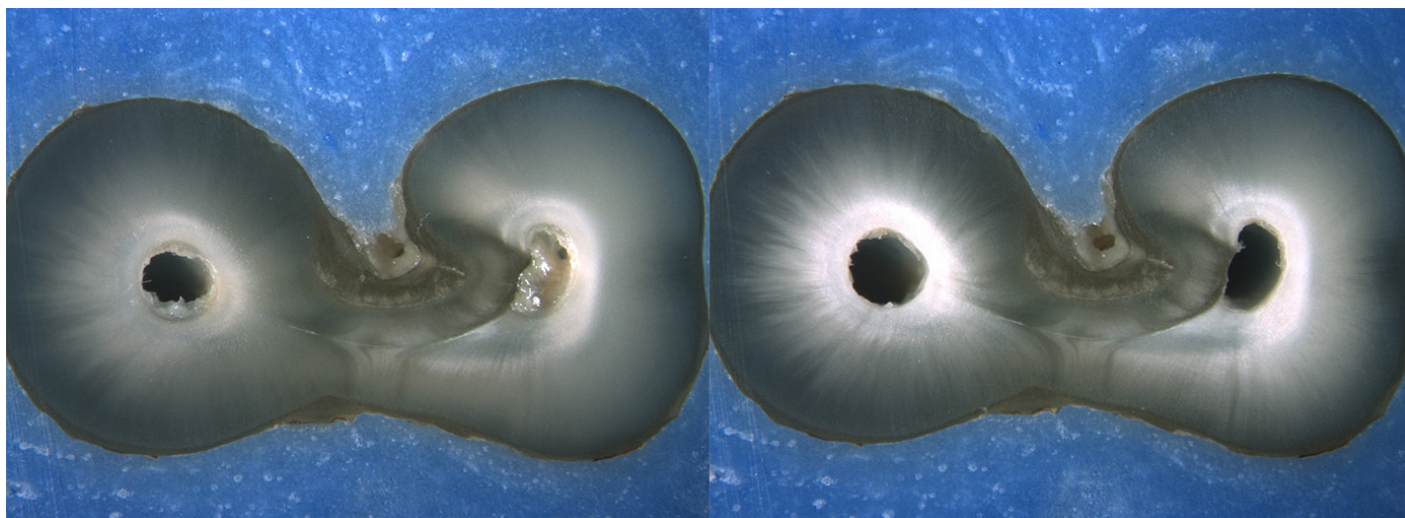
Is the crack seen in the Post-Op image:

- an Incomplete Crack from the canal towards the root surface
 an Incomplete Crack from the root surface towards the canal
 A complete crack

Done. Go to next page

Image: i053.jpg

Pre-Op on the left and Post-Op on the right



Is there any evidence of a dentinal crack prior to rotary instrumentation (Pre-Op)?

- Yes
 No

Does the crack in the Pre-Op image increase in size when viewed in the Post-Op image?

- Yes
 No

Is the crack that increased in the Pre-Op image now:

- an Incomplete Crack from the canal towards the root surface
 an Incomplete Crack from the root surface towards the canal
 A complete crack

Is there a new dentinal crack present in the instrumented (Post-Op) sample not seen in the Pre-Op image?

- Yes
 No

Is the new crack in the Post-Op image:

- an Incomplete Crack from the canal towards the root surface
 an Incomplete Crack from the root surface towards the canal
 A complete crack

Is there a dentinal crack present in the instrumented (Post-Op) sample not seen in the Pre-Op image?

- Yes
 No

Is there more than one crack seen in the Post-Op image?

- Yes
 No

For the longest crack seen in the Post-Op image, is the crack:

- an Incomplete Crack from the canal towards the root surface
 an Incomplete Crack from the root surface towards the canal
 A complete crack

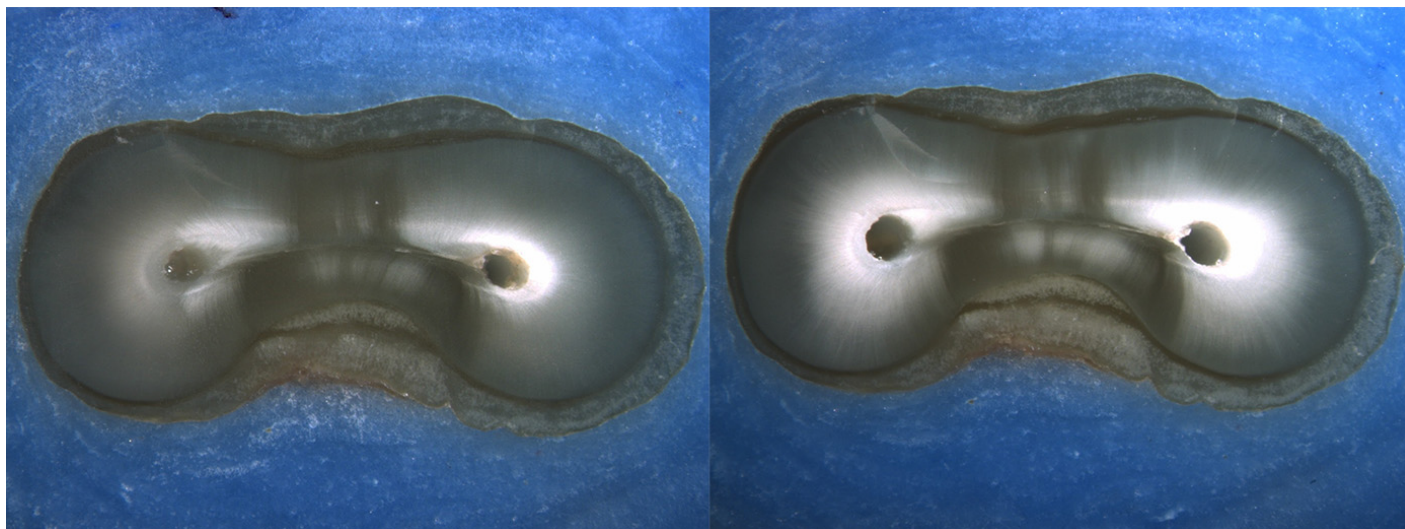
Is the crack seen in the Post-Op image:

- an Incomplete Crack from the canal towards the root surface
 an Incomplete Crack from the root surface towards the canal
 A complete crack

Done. Go to next page

Image: i054.jpg

Pre-Op on the left and Post-Op on the right



Is there any evidence of a dentinal crack prior to rotary instrumentation (Pre-Op)?

- Yes
 No

Does the crack in the Pre-Op image increase in size when viewed in the Post-Op image?

- Yes
 No

Is the crack that increased in the Pre-Op image now:

- an Incomplete Crack from the canal towards the root surface
 an Incomplete Crack from the root surface towards the canal
 A complete crack

Is there a new dentinal crack present in the instrumented (Post-Op) sample not seen in the Pre-Op image?

- Yes
 No

Is the new crack in the Post-Op image:

- an Incomplete Crack from the canal towards the root surface
 an Incomplete Crack from the root surface towards the canal
 A complete crack

Is there a dentinal crack present in the instrumented (Post-Op) sample not seen in the Pre-Op image?

- Yes
 No

Is there more than one crack seen in the Post-Op image?

- Yes
 No

For the longest crack seen in the Post-Op image, is the crack:

- an Incomplete Crack from the canal towards the root surface
 an Incomplete Crack from the root surface towards the canal
 A complete crack


Is the crack seen in the Post-Op image:

- an Incomplete Crack from the canal towards the root surface
 an Incomplete Crack from the root surface towards the canal
 A complete crack

Done. Go to next page

Image: i055.jpg

Pre-Op on the left and Post-Op on the right



Is there any evidence of a dentinal crack prior to rotary instrumentation (Pre-Op)?

- Yes
 No

Does the crack in the Pre-Op image increase in size when viewed in the Post-Op image?

- Yes
 No

Is the crack that increased in the Pre-Op image now:

- an Incomplete Crack from the canal towards the root surface
 an Incomplete Crack from the root surface towards the canal
 A complete crack

Is there a new dentinal crack present in the instrumented (Post-Op) sample not seen in the Pre-Op image?

- Yes
 No

Is the new crack in the Post-Op image:

- an Incomplete Crack from the canal towards the root surface
 an Incomplete Crack from the root surface towards the canal
 A complete crack

Is there a dentinal crack present in the instrumented (Post-Op) sample not seen in the Pre-Op image?

- Yes
 No

Is there more than one crack seen in the Post-Op image?

- Yes
 No

For the longest crack seen in the Post-Op image, is the crack:

- an Incomplete Crack from the canal towards the root surface
 an Incomplete Crack from the root surface towards the canal
 A complete crack

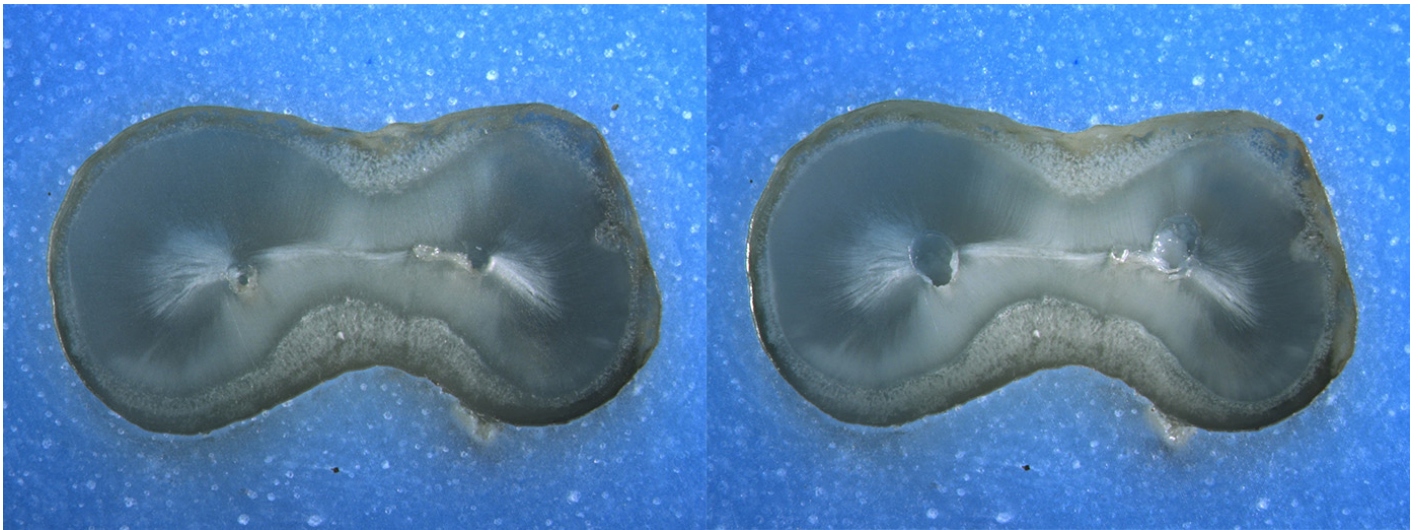
Is the crack seen in the Post-Op image:

- an Incomplete Crack from the canal towards the root surface
 an Incomplete Crack from the root surface towards the canal
 A complete crack

Done. Go to next page

Image: i056.jpg

Pre-Op on the left and Post-Op on the right



Is there any evidence of a dentinal crack prior to rotary instrumentation (Pre-Op)?

- Yes
 No

Does the crack in the Pre-Op image increase in size when viewed in the Post-Op image?

- Yes
 No

Is the crack that increased in the Pre-Op image now:

- an Incomplete Crack from the canal towards the root surface
 an Incomplete Crack from the root surface towards the canal
 A complete crack

Is there a new dentinal crack present in the instrumented (Post-Op) sample not seen in the Pre-Op image?

- Yes
 No

Is the new crack in the Post-Op image:

- an Incomplete Crack from the canal towards the root surface
 an Incomplete Crack from the root surface towards the canal
 A complete crack

Is there a dentinal crack present in the instrumented (Post-Op) sample not seen in the Pre-Op image?

- Yes
 No

Is there more than one crack seen in the Post-Op image?

- Yes
 No

For the longest crack seen in the Post-Op image, is the crack:

- an Incomplete Crack from the canal towards the root surface
 an Incomplete Crack from the root surface towards the canal
 A complete crack

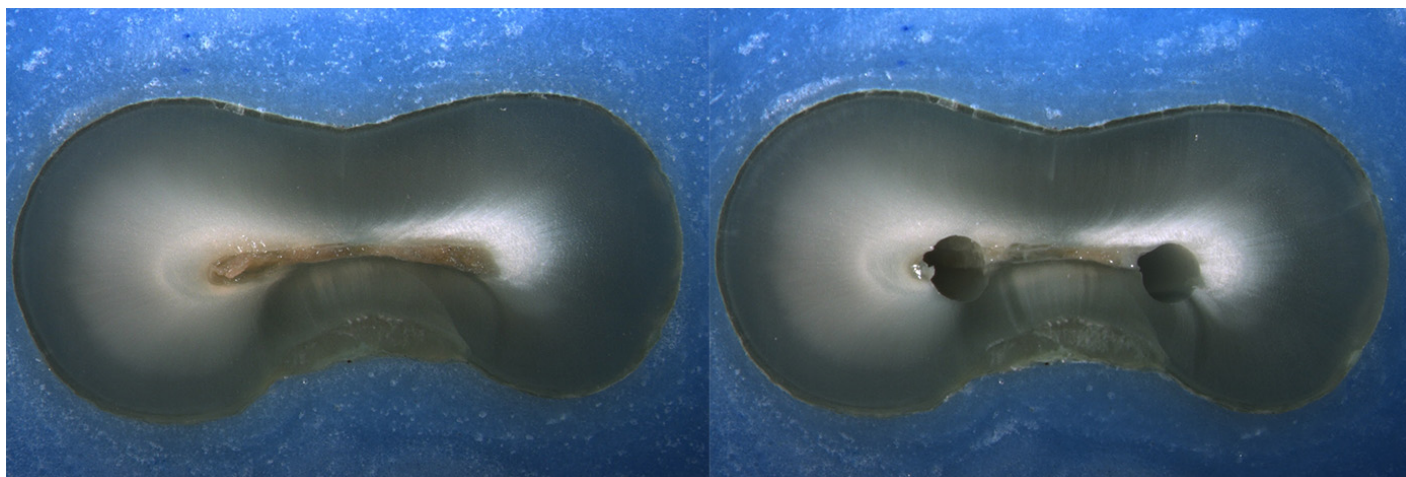
Is the crack seen in the Post-Op image:

- an Incomplete Crack from the canal towards the root surface
 an Incomplete Crack from the root surface towards the canal
 A complete crack

Done. Go to next page

Image: i057.jpg

Pre-Op on the left and Post-Op on the right



Is there any evidence of a dentinal crack prior to rotary instrumentation (Pre-Op)?

- Yes
 No

Does the crack in the Pre-Op image increase in size when viewed in the Post-Op image?

- Yes
 No

Is the crack that increased in the Pre-Op image now:

- an Incomplete Crack from the canal towards the root surface
 an Incomplete Crack from the root surface towards the canal
 A complete crack

Is there a new dentinal crack present in the instrumented (Post-Op) sample not seen in the Pre-Op image?

- Yes
 No

Is the new crack in the Post-Op image:

- an Incomplete Crack from the canal towards the root surface
 an Incomplete Crack from the root surface towards the canal
 A complete crack

Is there a dentinal crack present in the instrumented (Post-Op) sample not seen in the Pre-Op image?

- Yes
 No

Is there more than one crack seen in the Post-Op image?

- Yes
 No

For the longest crack seen in the Post-Op image, is the crack:

- an Incomplete Crack from the canal towards the root surface
 an Incomplete Crack from the root surface towards the canal
 A complete crack

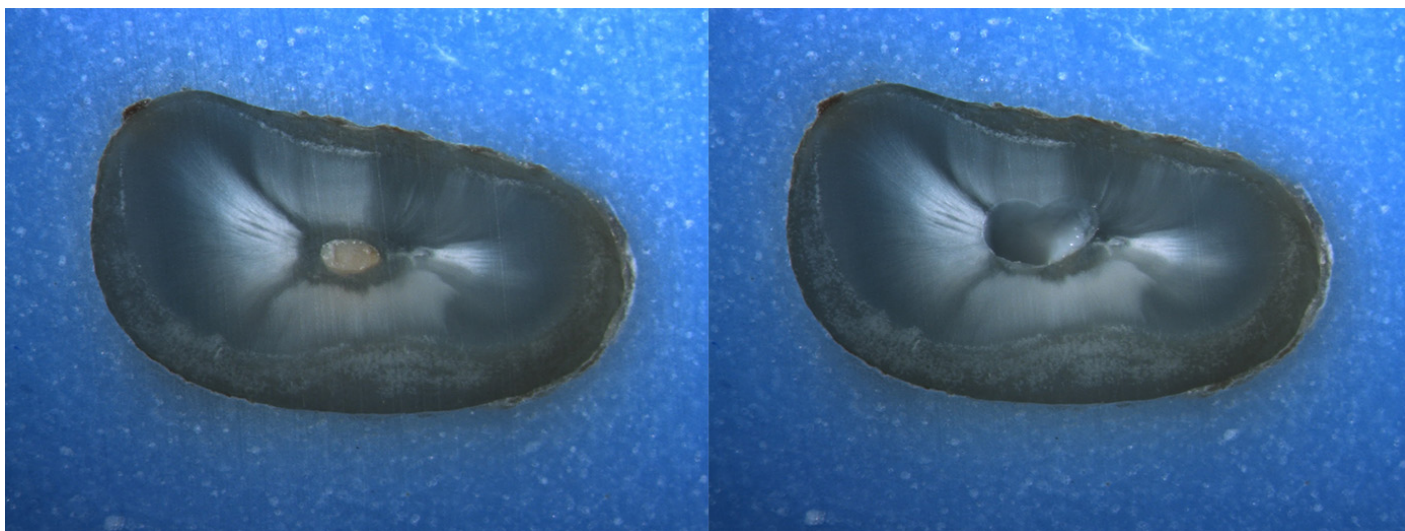
Is the crack seen in the Post-Op image:

- an Incomplete Crack from the canal towards the root surface
 an Incomplete Crack from the root surface towards the canal
 A complete crack

Done. Go to next page

Image: i058.jpg

Pre-Op on the left and Post-Op on the right



Is there any evidence of a dentinal crack prior to rotary instrumentation (Pre-Op)?

- Yes
 No

Does the crack in the Pre-Op image increase in size when viewed in the Post-Op image?

- Yes
 No

Is the crack that increased in the Pre-Op image now:

- an Incomplete Crack from the canal towards the root surface
 an Incomplete Crack from the root surface towards the canal
 A complete crack

Is there a new dentinal crack present in the instrumented (Post-Op) sample not seen in the Pre-Op image?

- Yes
 No

Is the new crack in the Post-Op image:

- an Incomplete Crack from the canal towards the root surface
 an Incomplete Crack from the root surface towards the canal
 A complete crack

Is there a dentinal crack present in the instrumented (Post-Op) sample not seen in the Pre-Op image?

- Yes
 No

Is there more than one crack seen in the Post-Op image?

- Yes
 No

For the longest crack seen in the Post-Op image, is the crack:

- an Incomplete Crack from the canal towards the root surface
 an Incomplete Crack from the root surface towards the canal
 A complete crack

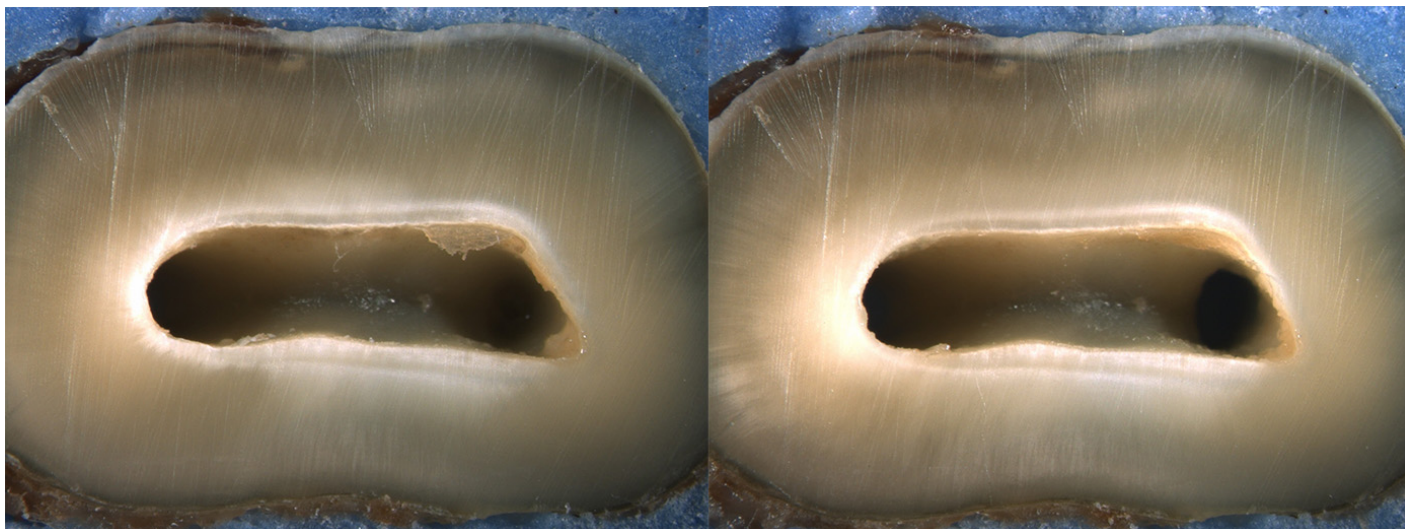
Is the crack seen in the Post-Op image:

- an Incomplete Crack from the canal towards the root surface
 an Incomplete Crack from the root surface towards the canal
 A complete crack

Done. Go to next page

Image: i059.jpg

Pre-Op on the left and Post-Op on the right



Is there any evidence of a dentinal crack prior to rotary instrumentation (Pre-Op)?

- Yes
 No

Does the crack in the Pre-Op image increase in size when viewed in the Post-Op image?

- Yes
 No

Is the crack that increased in the Pre-Op image now:

- an Incomplete Crack from the canal towards the root surface
 an Incomplete Crack from the root surface towards the canal
 A complete crack

Is there a new dentinal crack present in the instrumented (Post-Op) sample not seen in the Pre-Op image?

- Yes
 No

Is the new crack in the Post-Op image:

- an Incomplete Crack from the canal towards the root surface
 an Incomplete Crack from the root surface towards the canal
 A complete crack

Is there a dentinal crack present in the instrumented (Post-Op) sample not seen in the Pre-Op image?

- Yes
 No

Is there more than one crack seen in the Post-Op image?

- Yes
 No

For the longest crack seen in the Post-Op image, is the crack:

- an Incomplete Crack from the canal towards the root surface
 an Incomplete Crack from the root surface towards the canal
 A complete crack

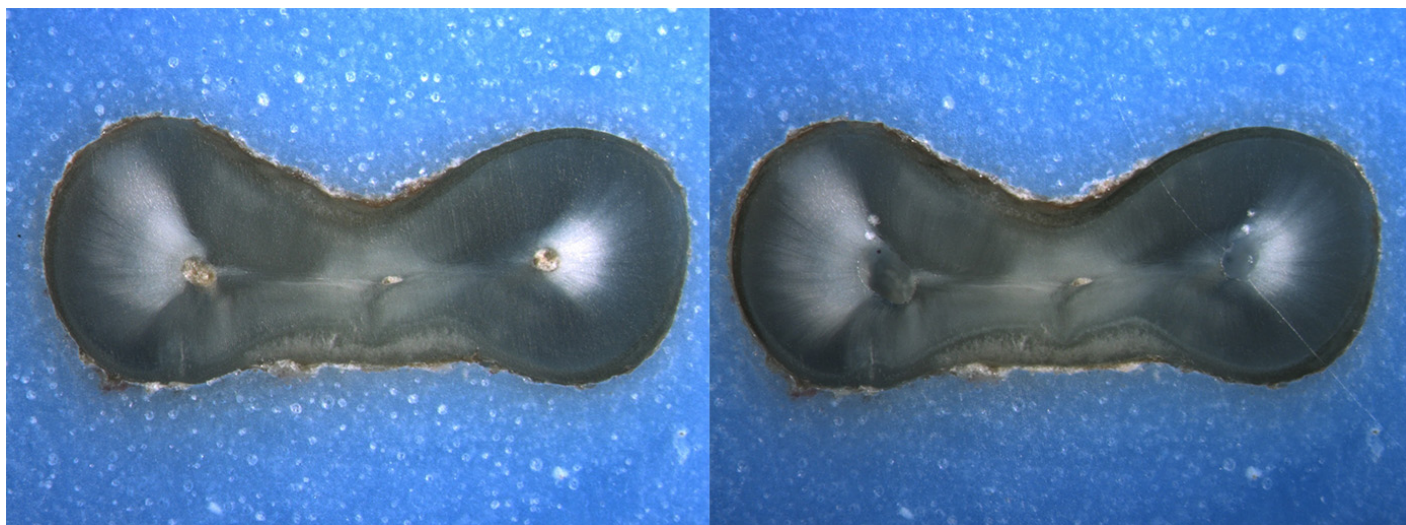
Is the crack seen in the Post-Op image:

- an Incomplete Crack from the canal towards the root surface
 an Incomplete Crack from the root surface towards the canal
 A complete crack

Done. Go to next page

Image: i060.jpg

Pre-Op on the left and Post-Op on the right



Is there any evidence of a dentinal crack prior to rotary instrumentation (Pre-Op)?

- Yes
 No

Does the crack in the Pre-Op image increase in size when viewed in the Post-Op image?

- Yes
 No

Is the crack that increased in the Pre-Op image now:

- an Incomplete Crack from the canal towards the root surface
 an Incomplete Crack from the root surface towards the canal
 A complete crack

Is there a new dentinal crack present in the instrumented (Post-Op) sample not seen in the Pre-Op image?

- Yes
 No

Is the new crack in the Post-Op image:

- an Incomplete Crack from the canal towards the root surface
 an Incomplete Crack from the root surface towards the canal
 A complete crack

Is there a dentinal crack present in the instrumented (Post-Op) sample not seen in the Pre-Op image?

- Yes
 No

Is there more than one crack seen in the Post-Op image?

- Yes
 No

For the longest crack seen in the Post-Op image, is the crack:

- an Incomplete Crack from the canal towards the root surface
 an Incomplete Crack from the root surface towards the canal
 A complete crack

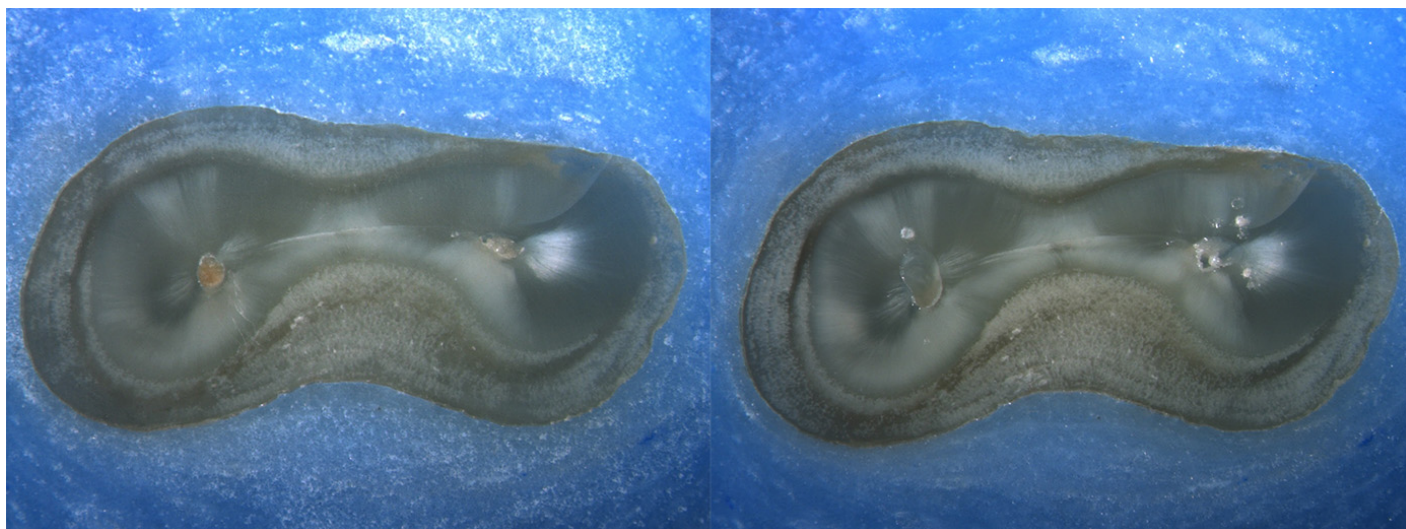
Is the crack seen in the Post-Op image:

- an Incomplete Crack from the canal towards the root surface
 an Incomplete Crack from the root surface towards the canal
 A complete crack

Done. Go to next page

Image: i061.jpg

Pre-Op on the left and Post-Op on the right



Is there any evidence of a dentinal crack prior to rotary instrumentation (Pre-Op)?

- Yes
 No

Does the crack in the Pre-Op image increase in size when viewed in the Post-Op image?

- Yes
 No

Is the crack that increased in the Pre-Op image now:

- an Incomplete Crack from the canal towards the root surface
 an Incomplete Crack from the root surface towards the canal
 A complete crack

Is there a new dentinal crack present in the instrumented (Post-Op) sample not seen in the Pre-Op image?

- Yes
 No

Is the new crack in the Post-Op image:

- an Incomplete Crack from the canal towards the root surface
 an Incomplete Crack from the root surface towards the canal
 A complete crack

Is there a dentinal crack present in the instrumented (Post-Op) sample not seen in the Pre-Op image?

- Yes
 No

Is there more than one crack seen in the Post-Op image?

- Yes
 No

For the longest crack seen in the Post-Op image, is the crack:

- an Incomplete Crack from the canal towards the root surface
 an Incomplete Crack from the root surface towards the canal
 A complete crack

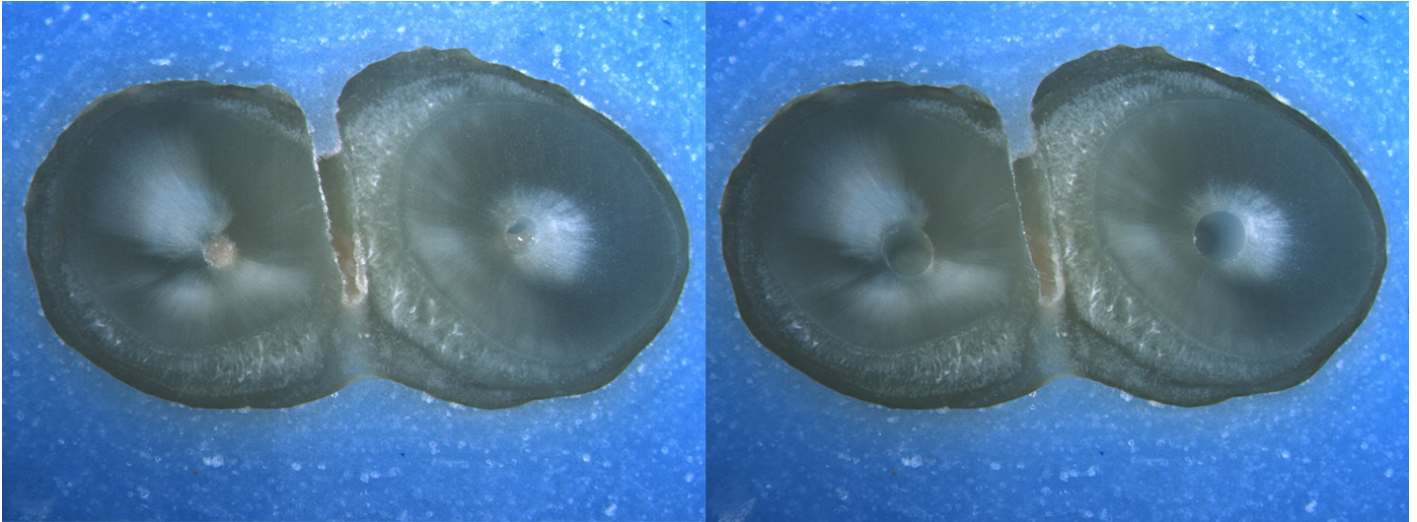
Is the crack seen in the Post-Op image:

- an Incomplete Crack from the canal towards the root surface
 an Incomplete Crack from the root surface towards the canal
 A complete crack

Done. Go to next page

Image: i062.jpg

Pre-Op on the left and Post-Op on the right



Is there any evidence of a dentinal crack prior to rotary instrumentation (Pre-Op)?

- Yes
 No

Does the crack in the Pre-Op image increase in size when viewed in the Post-Op image?

- Yes
 No

Is the crack that increased in the Pre-Op image now:

- an Incomplete Crack from the canal towards the root surface
 an Incomplete Crack from the root surface towards the canal
 A complete crack

Is there a new dentinal crack present in the instrumented (Post-Op) sample not seen in the Pre-Op image?

- Yes
 No

Is the new crack in the Post-Op image:

- an Incomplete Crack from the canal towards the root surface
 an Incomplete Crack from the root surface towards the canal
 A complete crack

Is there a dentinal crack present in the instrumented (Post-Op) sample not seen in the Pre-Op image?

- Yes
 No

Is there more than one crack seen in the Post-Op image?

- Yes
 No

For the longest crack seen in the Post-Op image, is the crack:

- an Incomplete Crack from the canal towards the root surface
 an Incomplete Crack from the root surface towards the canal
 A complete crack


Is the crack seen in the Post-Op image:

- an Incomplete Crack from the canal towards the root surface
 an Incomplete Crack from the root surface towards the canal
 A complete crack

Done. Go to next page

Image: i063.jpg

Pre-Op on the left and Post-Op on the right



Is there any evidence of a dentinal crack prior to rotary instrumentation (Pre-Op)?

- Yes
 No

Does the crack in the Pre-Op image increase in size when viewed in the Post-Op image?

- Yes
 No

Is the crack that increased in the Pre-Op image now:

- an Incomplete Crack from the canal towards the root surface
 an Incomplete Crack from the root surface towards the canal
 A complete crack

Is there a new dentinal crack present in the instrumented (Post-Op) sample not seen in the Pre-Op image?

- Yes
 No

Is the new crack in the Post-Op image:

- an Incomplete Crack from the canal towards the root surface
 an Incomplete Crack from the root surface towards the canal
 A complete crack

Is there a dentinal crack present in the instrumented (Post-Op) sample not seen in the Pre-Op image?

- Yes
 No

Is there more than one crack seen in the Post-Op image?

- Yes
 No

For the longest crack seen in the Post-Op image, is the crack:

- an Incomplete Crack from the canal towards the root surface
 an Incomplete Crack from the root surface towards the canal
 A complete crack

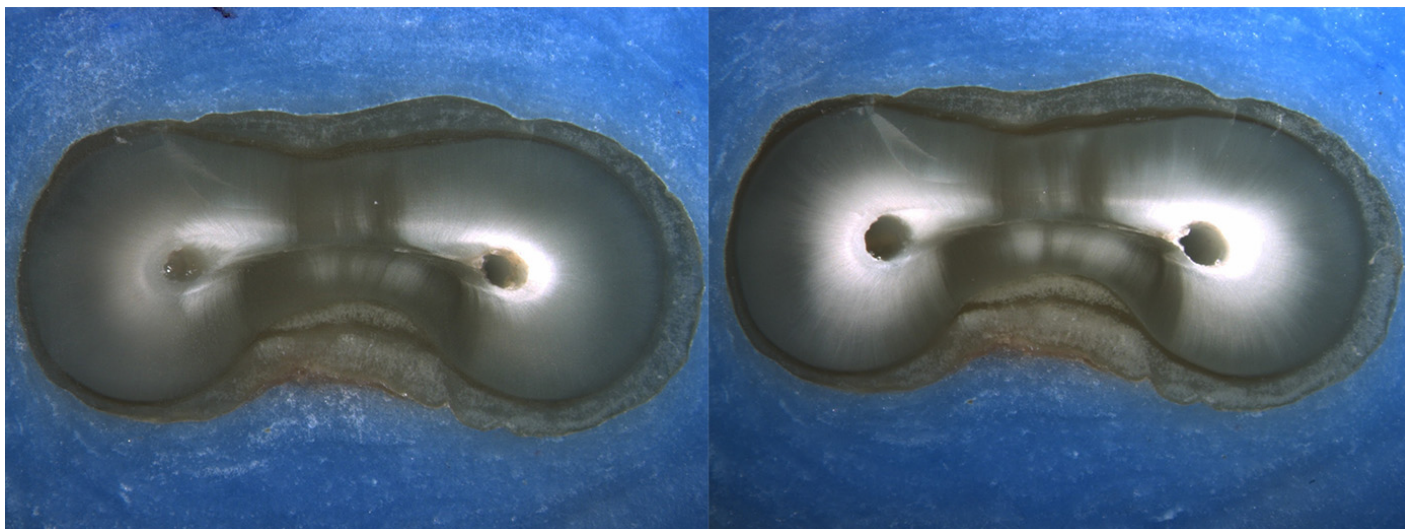
Is the crack seen in the Post-Op image:

- an Incomplete Crack from the canal towards the root surface
 an Incomplete Crack from the root surface towards the canal
 A complete crack

Done. Go to next page

Image: i064.jpg

Pre-Op on the left and Post-Op on the right



Is there any evidence of a dentinal crack prior to rotary instrumentation (Pre-Op)?

- Yes
 No

Does the crack in the Pre-Op image increase in size when viewed in the Post-Op image?

- Yes
 No

Is the crack that increased in the Pre-Op image now:

- an Incomplete Crack from the canal towards the root surface
 an Incomplete Crack from the root surface towards the canal
 A complete crack

Is there a new dentinal crack present in the instrumented (Post-Op) sample not seen in the Pre-Op image?

- Yes
 No

Is the new crack in the Post-Op image:

- an Incomplete Crack from the canal towards the root surface
 an Incomplete Crack from the root surface towards the canal
 A complete crack

Is there a dentinal crack present in the instrumented (Post-Op) sample not seen in the Pre-Op image?

- Yes
 No

Is there more than one crack seen in the Post-Op image?

- Yes
 No

For the longest crack seen in the Post-Op image, is the crack:

- an Incomplete Crack from the canal towards the root surface
 an Incomplete Crack from the root surface towards the canal
 A complete crack

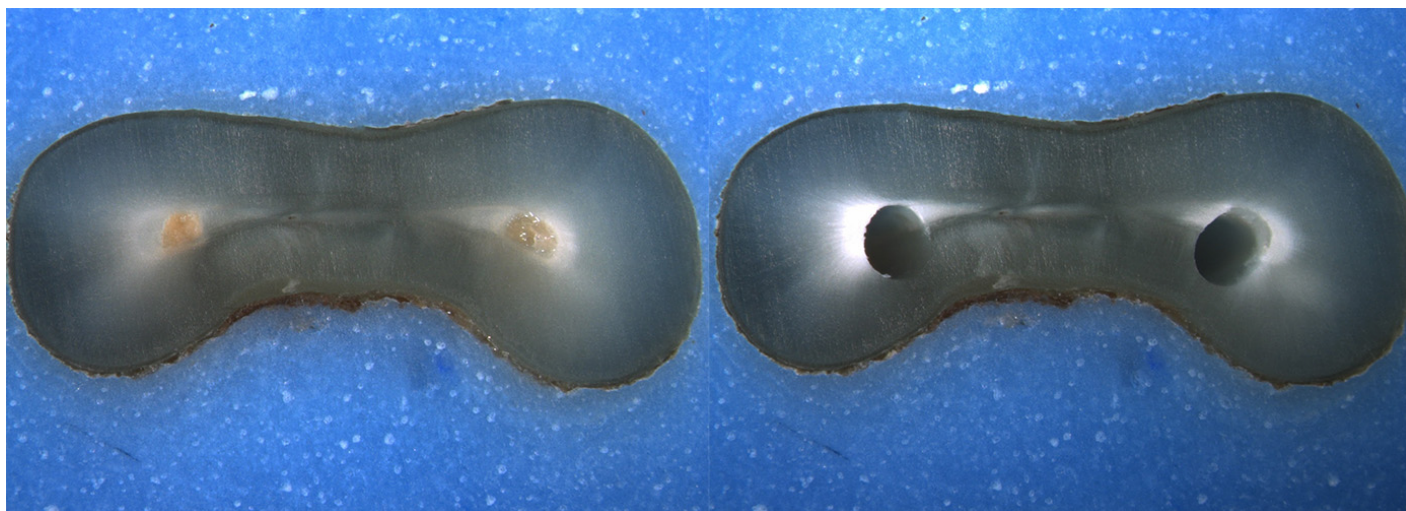
Is the crack seen in the Post-Op image:

- an Incomplete Crack from the canal towards the root surface
 an Incomplete Crack from the root surface towards the canal
 A complete crack

Done. Go to next page

Image: i065.jpg

Pre-Op on the left and Post-Op on the right



Is there any evidence of a dentinal crack prior to rotary instrumentation (Pre-Op)?

- Yes
 No

Does the crack in the Pre-Op image increase in size when viewed in the Post-Op image?

- Yes
 No

Is the crack that increased in the Pre-Op image now:

- an Incomplete Crack from the canal towards the root surface
 an Incomplete Crack from the root surface towards the canal
 A complete crack

Is there a new dentinal crack present in the instrumented (Post-Op) sample not seen in the Pre-Op image?

- Yes
 No

Is the new crack in the Post-Op image:

- an Incomplete Crack from the canal towards the root surface
 an Incomplete Crack from the root surface towards the canal
 A complete crack

Is there a dentinal crack present in the instrumented (Post-Op) sample not seen in the Pre-Op image?

- Yes
 No

Is there more than one crack seen in the Post-Op image?

- Yes
 No

For the longest crack seen in the Post-Op image, is the crack:

- an Incomplete Crack from the canal towards the root surface
 an Incomplete Crack from the root surface towards the canal
 A complete crack


Is the crack seen in the Post-Op image:

- an Incomplete Crack from the canal towards the root surface
 an Incomplete Crack from the root surface towards the canal
 A complete crack

Done. Go to next page

Image: i066.jpg

Pre-Op on the left and Post-Op on the right



Is there any evidence of a dentinal crack prior to rotary instrumentation (Pre-Op)?

- Yes
 No

Does the crack in the Pre-Op image increase in size when viewed in the Post-Op image?

- Yes
 No

Is the crack that increased in the Pre-Op image now:

- an Incomplete Crack from the canal towards the root surface
 an Incomplete Crack from the root surface towards the canal
 A complete crack

Is there a new dentinal crack present in the instrumented (Post-Op) sample not seen in the Pre-Op image?

- Yes
 No

Is the new crack in the Post-Op image:

- an Incomplete Crack from the canal towards the root surface
 an Incomplete Crack from the root surface towards the canal
 A complete crack

Is there a dentinal crack present in the instrumented (Post-Op) sample not seen in the Pre-Op image?

- Yes
 No

Is there more than one crack seen in the Post-Op image?

- Yes
 No

For the longest crack seen in the Post-Op image, is the crack:

- an Incomplete Crack from the canal towards the root surface
 an Incomplete Crack from the root surface towards the canal
 A complete crack

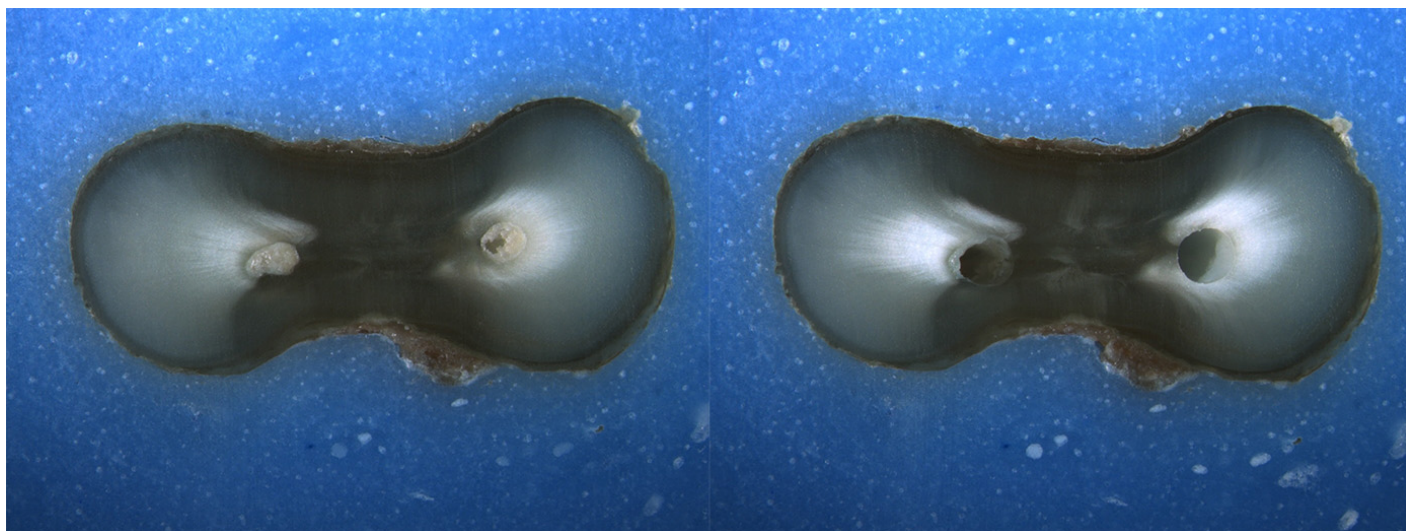
Is the crack seen in the Post-Op image:

- an Incomplete Crack from the canal towards the root surface
 an Incomplete Crack from the root surface towards the canal
 A complete crack

Done. Go to next page

Image: i067.jpg

Pre-Op on the left and Post-Op on the right



Is there any evidence of a dentinal crack prior to rotary instrumentation (Pre-Op)?

- Yes
 No

Does the crack in the Pre-Op image increase in size when viewed in the Post-Op image?

- Yes
 No

Is the crack that increased in the Pre-Op image now:

- an Incomplete Crack from the canal towards the root surface
 an Incomplete Crack from the root surface towards the canal
 A complete crack

Is there a new dentinal crack present in the instrumented (Post-Op) sample not seen in the Pre-Op image?

- Yes
 No

Is the new crack in the Post-Op image:

- an Incomplete Crack from the canal towards the root surface
 an Incomplete Crack from the root surface towards the canal
 A complete crack

Is there a dentinal crack present in the instrumented (Post-Op) sample not seen in the Pre-Op image?

- Yes
 No

Is there more than one crack seen in the Post-Op image?

- Yes
 No

For the longest crack seen in the Post-Op image, is the crack:

- an Incomplete Crack from the canal towards the root surface
 an Incomplete Crack from the root surface towards the canal
 A complete crack

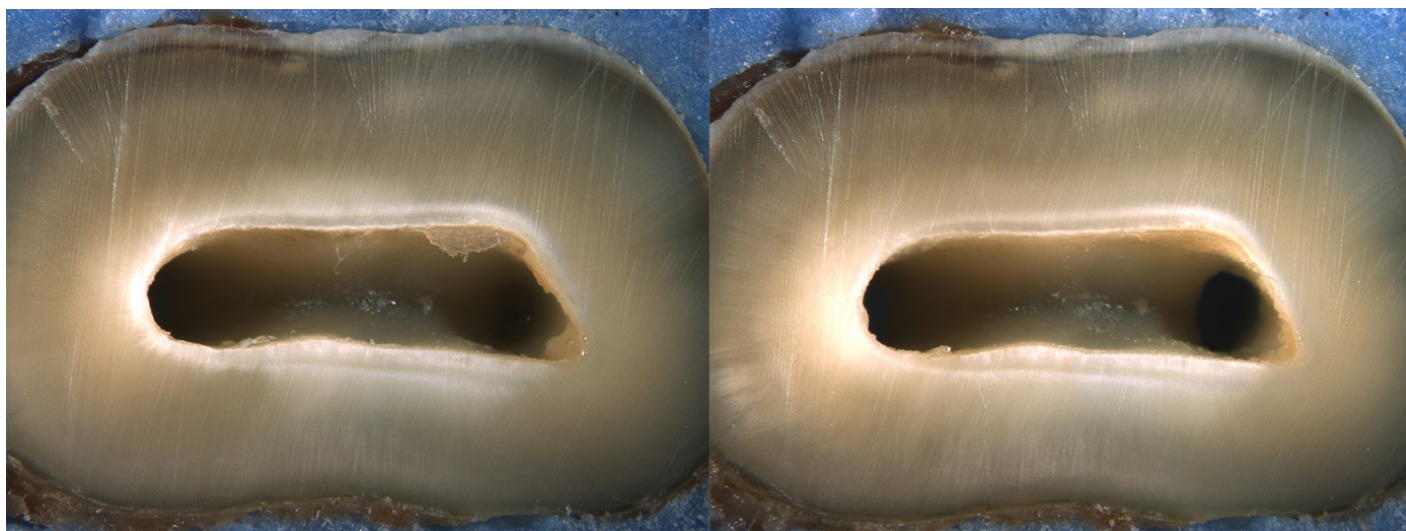
Is the crack seen in the Post-Op image:

- an Incomplete Crack from the canal towards the root surface
 an Incomplete Crack from the root surface towards the canal
 A complete crack

Done. Go to next page

Image: i068.jpg

Pre-Op on the left and Post-Op on the right



Is there any evidence of a dentinal crack prior to rotary instrumentation (Pre-Op)?

- Yes
 No

Does the crack in the Pre-Op image increase in size when viewed in the Post-Op image?

- Yes
 No

Is the crack that increased in the Pre-Op image now:

- an Incomplete Crack from the canal towards the root surface
 an Incomplete Crack from the root surface towards the canal
 A complete crack

Is there a new dentinal crack present in the instrumented (Post-Op) sample not seen in the Pre-Op image?

- Yes
 No

Is the new crack in the Post-Op image:

- an Incomplete Crack from the canal towards the root surface
 an Incomplete Crack from the root surface towards the canal
 A complete crack

Is there a dentinal crack present in the instrumented (Post-Op) sample not seen in the Pre-Op image?

- Yes
 No

Is there more than one crack seen in the Post-Op image?

- Yes
 No

For the longest crack seen in the Post-Op image, is the crack:

- an Incomplete Crack from the canal towards the root surface
 an Incomplete Crack from the root surface towards the canal
 A complete crack

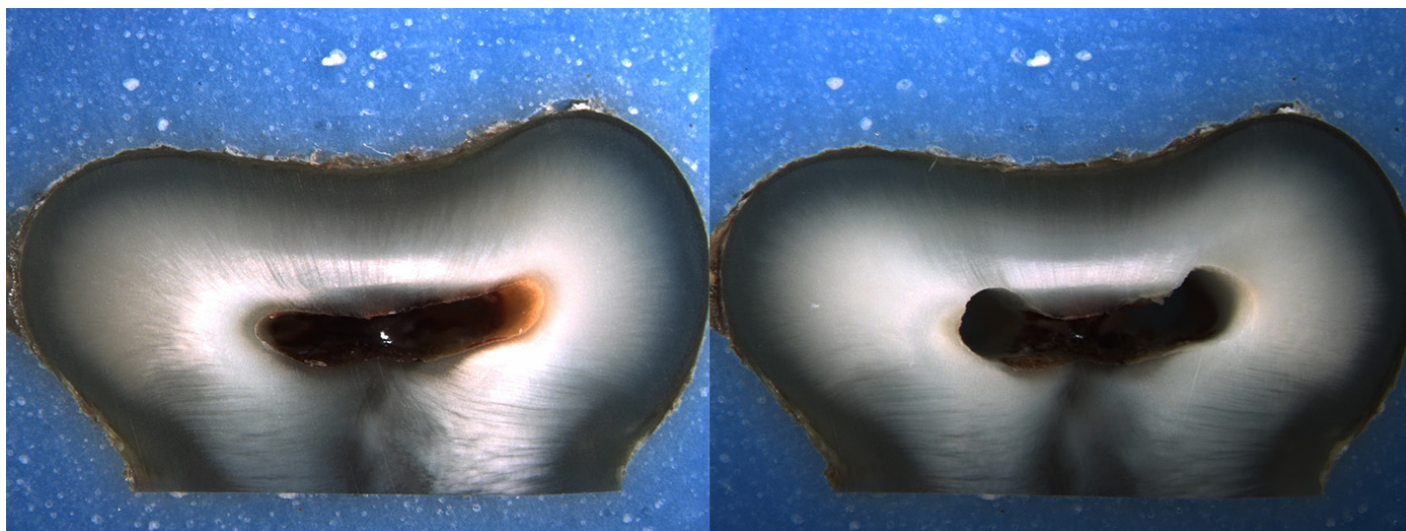
Is the crack seen in the Post-Op image:

- an Incomplete Crack from the canal towards the root surface
 an Incomplete Crack from the root surface towards the canal
 A complete crack

Done. Go to next page

Image: i069.jpg

Pre-Op on the left and Post-Op on the right



Is there any evidence of a dentinal crack prior to rotary instrumentation (Pre-Op)?

- Yes
 No

Does the crack in the Pre-Op image increase in size when viewed in the Post-Op image?

- Yes
 No

Is the crack that increased in the Pre-Op image now:

- an Incomplete Crack from the canal towards the root surface
 an Incomplete Crack from the root surface towards the canal
 A complete crack

Is there a new dentinal crack present in the instrumented (Post-Op) sample not seen in the Pre-Op image?

- Yes
 No

Is the new crack in the Post-Op image:

- an Incomplete Crack from the canal towards the root surface
 an Incomplete Crack from the root surface towards the canal
 A complete crack

Is there a dentinal crack present in the instrumented (Post-Op) sample not seen in the Pre-Op image?

- Yes
 No

Is there more than one crack seen in the Post-Op image?

- Yes
 No

For the longest crack seen in the Post-Op image, is the crack:

- an Incomplete Crack from the canal towards the root surface
 an Incomplete Crack from the root surface towards the canal
 A complete crack

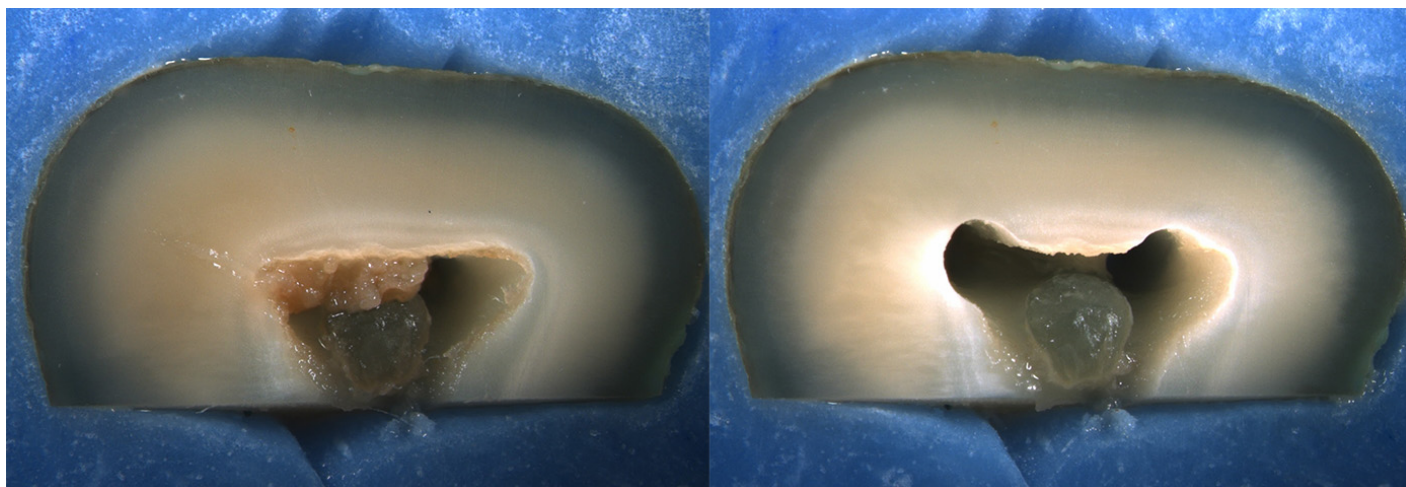
Is the crack seen in the Post-Op image:

- an Incomplete Crack from the canal towards the root surface
 an Incomplete Crack from the root surface towards the canal
 A complete crack

Done. Go to next page

Image: i070.jpg

Pre-Op on the left and Post-Op on the right



Is there any evidence of a dentinal crack prior to rotary instrumentation (Pre-Op)?

- Yes
 No

Does the crack in the Pre-Op image increase in size when viewed in the Post-Op image?

- Yes
 No

Is the crack that increased in the Pre-Op image now:

- an Incomplete Crack from the canal towards the root surface
 an Incomplete Crack from the root surface towards the canal
 A complete crack

Is there a new dentinal crack present in the instrumented (Post-Op) sample not seen in the Pre-Op image?

- Yes
 No

Is the new crack in the Post-Op image:

- an Incomplete Crack from the canal towards the root surface
 an Incomplete Crack from the root surface towards the canal
 A complete crack

Is there a dentinal crack present in the instrumented (Post-Op) sample not seen in the Pre-Op image?

- Yes
 No

Is there more than one crack seen in the Post-Op image?

- Yes
 No

For the longest crack seen in the Post-Op image, is the crack:

- an Incomplete Crack from the canal towards the root surface
 an Incomplete Crack from the root surface towards the canal
 A complete crack

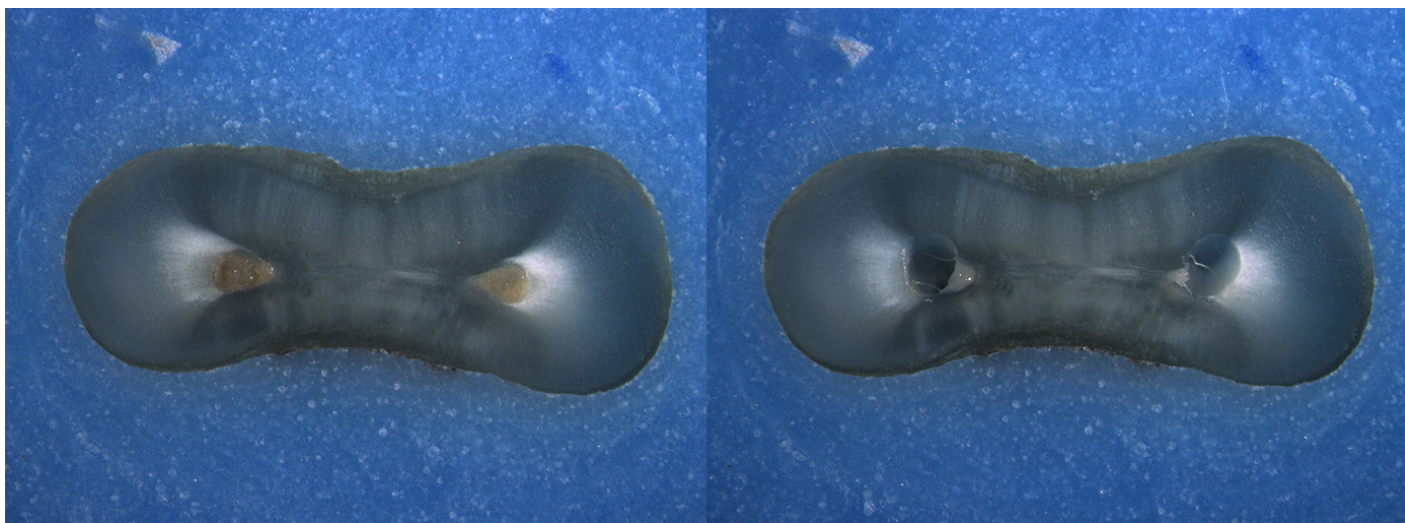
Is the crack seen in the Post-Op image:

- an Incomplete Crack from the canal towards the root surface
 an Incomplete Crack from the root surface towards the canal
 A complete crack

Done. Go to next page

Image: i071.jpg

Pre-Op on the left and Post-Op on the right



Is there any evidence of a dentinal crack prior to rotary instrumentation (Pre-Op)?

- Yes
 No

Does the crack in the Pre-Op image increase in size when viewed in the Post-Op image?

- Yes
 No

Is the crack that increased in the Pre-Op image now:

- an Incomplete Crack from the canal towards the root surface
 an Incomplete Crack from the root surface towards the canal
 A complete crack

Is there a new dentinal crack present in the instrumented (Post-Op) sample not seen in the Pre-Op image?

- Yes
 No

Is the new crack in the Post-Op image:

- an Incomplete Crack from the canal towards the root surface
 an Incomplete Crack from the root surface towards the canal
 A complete crack

Is there a dentinal crack present in the instrumented (Post-Op) sample not seen in the Pre-Op image?

- Yes
 No

Is there more than one crack seen in the Post-Op image?

- Yes
 No

For the longest crack seen in the Post-Op image, is the crack:

- an Incomplete Crack from the canal towards the root surface
 an Incomplete Crack from the root surface towards the canal
 A complete crack

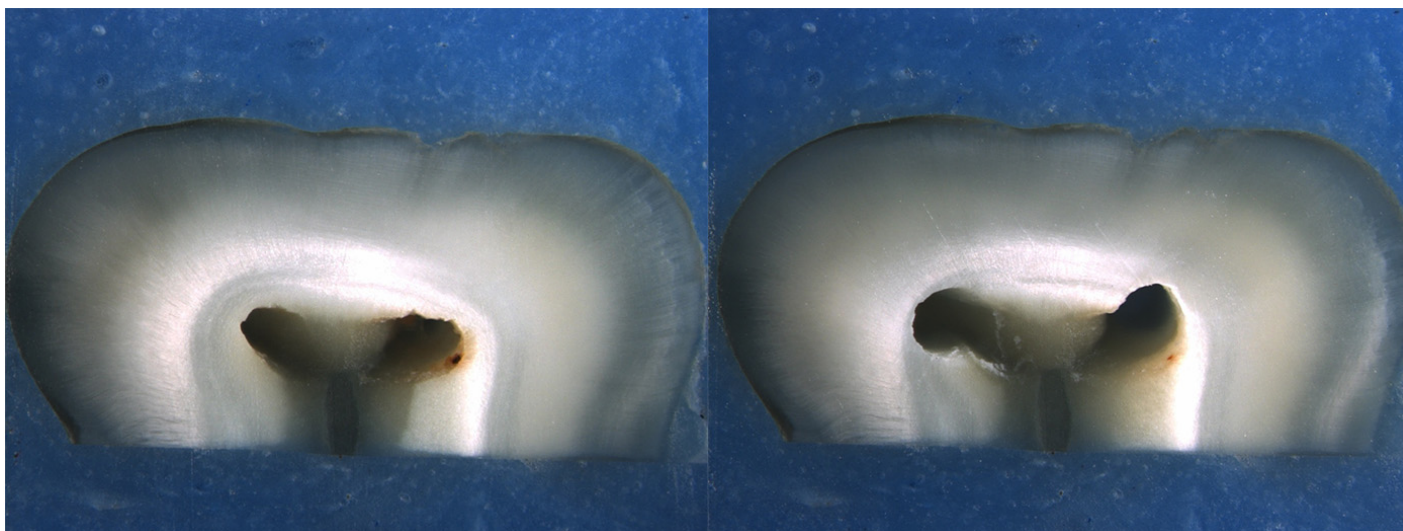
Is the crack seen in the Post-Op image:

- an Incomplete Crack from the canal towards the root surface
 an Incomplete Crack from the root surface towards the canal
 A complete crack

Done. Go to next page

Image: i072.jpg

Pre-Op on the left and Post-Op on the right



Is there any evidence of a dentinal crack prior to rotary instrumentation (Pre-Op)?

- Yes
 No

Does the crack in the Pre-Op image increase in size when viewed in the Post-Op image?

- Yes
 No

Is the crack that increased in the Pre-Op image now:

- an Incomplete Crack from the canal towards the root surface
 an Incomplete Crack from the root surface towards the canal
 A complete crack

Is there a new dentinal crack present in the instrumented (Post-Op) sample not seen in the Pre-Op image?

- Yes
 No

Is the new crack in the Post-Op image:

- an Incomplete Crack from the canal towards the root surface
 an Incomplete Crack from the root surface towards the canal
 A complete crack

Is there a dentinal crack present in the instrumented (Post-Op) sample not seen in the Pre-Op image?

- Yes
 No

Is there more than one crack seen in the Post-Op image?

- Yes
 No

For the longest crack seen in the Post-Op image, is the crack:

- an Incomplete Crack from the canal towards the root surface
 an Incomplete Crack from the root surface towards the canal
 A complete crack

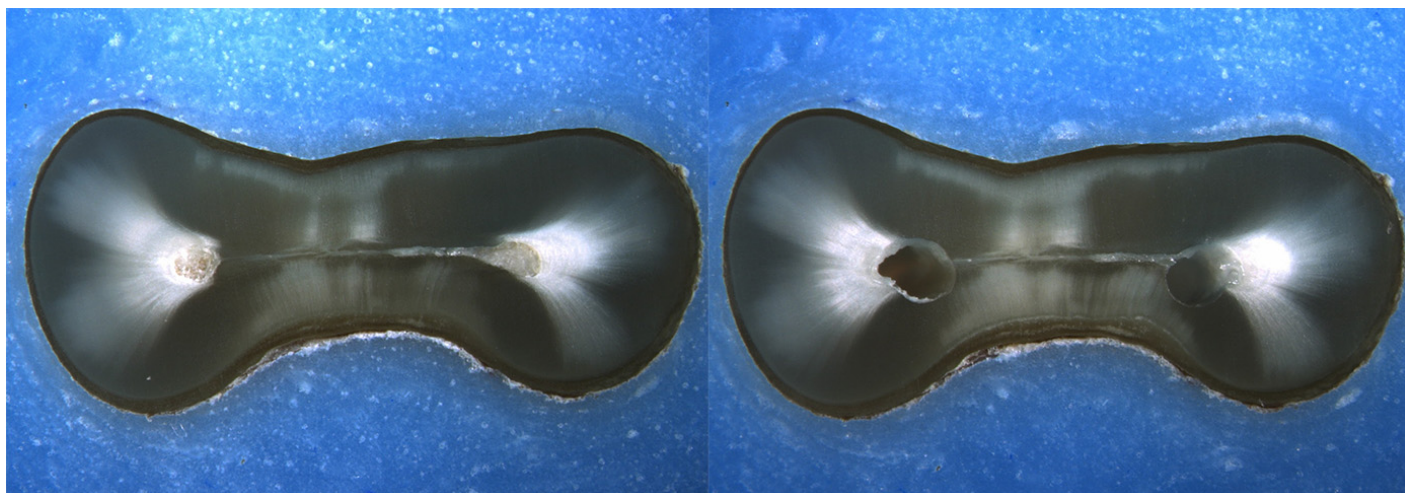
Is the crack seen in the Post-Op image:

- an Incomplete Crack from the canal towards the root surface
 an Incomplete Crack from the root surface towards the canal
 A complete crack

Done. Go to next page

Image: i073.jpg

Pre-Op on the left and Post-Op on the right



Is there any evidence of a dentinal crack prior to rotary instrumentation (Pre-Op)?

- Yes
 No

Does the crack in the Pre-Op image increase in size when viewed in the Post-Op image?

- Yes
 No

Is the crack that increased in the Pre-Op image now:

- an Incomplete Crack from the canal towards the root surface
 an Incomplete Crack from the root surface towards the canal
 A complete crack

Is there a new dentinal crack present in the instrumented (Post-Op) sample not seen in the Pre-Op image?

- Yes
 No

Is the new crack in the Post-Op image:

- an Incomplete Crack from the canal towards the root surface
 an Incomplete Crack from the root surface towards the canal
 A complete crack

Is there a dentinal crack present in the instrumented (Post-Op) sample not seen in the Pre-Op image?

- Yes
 No

Is there more than one crack seen in the Post-Op image?

- Yes
 No

For the longest crack seen in the Post-Op image, is the crack:

- an Incomplete Crack from the canal towards the root surface
 an Incomplete Crack from the root surface towards the canal
 A complete crack

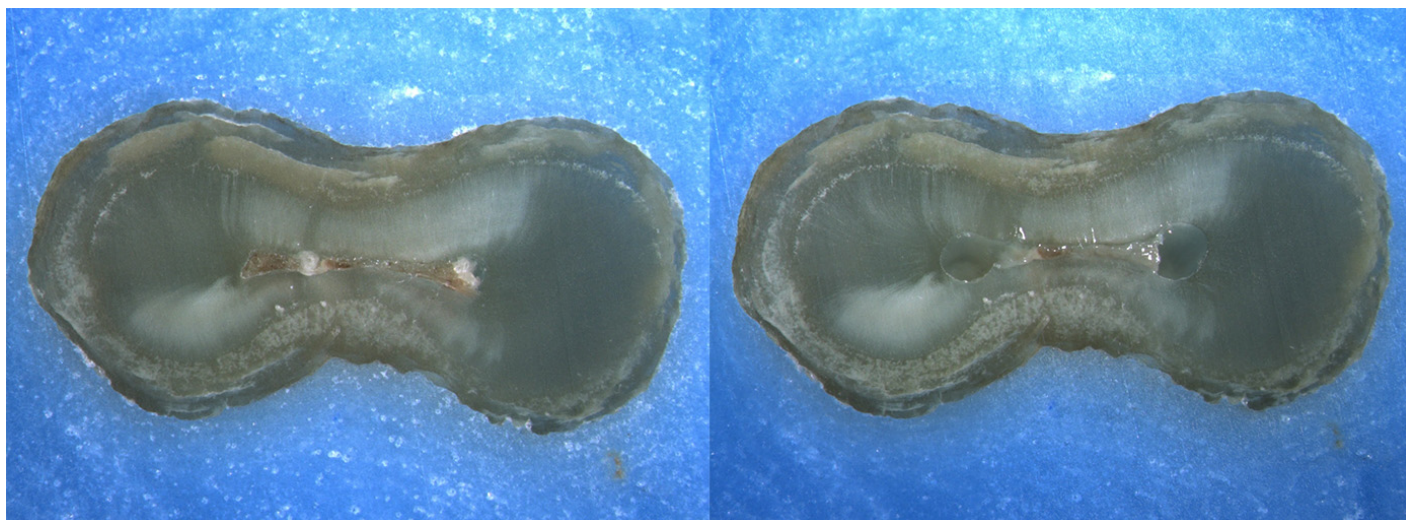
Is the crack seen in the Post-Op image:

- an Incomplete Crack from the canal towards the root surface
 an Incomplete Crack from the root surface towards the canal
 A complete crack

Done. Go to next page

Image: i074.jpg

Pre-Op on the left and Post-Op on the right



Is there any evidence of a dentinal crack prior to rotary instrumentation (Pre-Op)?

- Yes
 No

Does the crack in the Pre-Op image increase in size when viewed in the Post-Op image?

- Yes
 No

Is the crack that increased in the Pre-Op image now:

- an Incomplete Crack from the canal towards the root surface
 an Incomplete Crack from the root surface towards the canal
 A complete crack

Is there a new dentinal crack present in the instrumented (Post-Op) sample not seen in the Pre-Op image?

- Yes
 No

Is the new crack in the Post-Op image:

- an Incomplete Crack from the canal towards the root surface
 an Incomplete Crack from the root surface towards the canal
 A complete crack

Is there a dentinal crack present in the instrumented (Post-Op) sample not seen in the Pre-Op image?

- Yes
 No

Is there more than one crack seen in the Post-Op image?

- Yes
 No

For the longest crack seen in the Post-Op image, is the crack:

- an Incomplete Crack from the canal towards the root surface
 an Incomplete Crack from the root surface towards the canal
 A complete crack


Is the crack seen in the Post-Op image:

- an Incomplete Crack from the canal towards the root surface
 an Incomplete Crack from the root surface towards the canal
 A complete crack

Done. Go to next page

Image: i075.jpg

Pre-Op on the left and Post-Op on the right



Is there any evidence of a dentinal crack prior to rotary instrumentation (Pre-Op)?

- Yes
 No

Does the crack in the Pre-Op image increase in size when viewed in the Post-Op image?

- Yes
 No

Is the crack that increased in the Pre-Op image now:

- an Incomplete Crack from the canal towards the root surface
 an Incomplete Crack from the root surface towards the canal
 A complete crack

Is there a new dentinal crack present in the instrumented (Post-Op) sample not seen in the Pre-Op image?

- Yes
 No

Is the new crack in the Post-Op image:

- an Incomplete Crack from the canal towards the root surface
 an Incomplete Crack from the root surface towards the canal
 A complete crack

Is there a dentinal crack present in the instrumented (Post-Op) sample not seen in the Pre-Op image?

- Yes
 No

Is there more than one crack seen in the Post-Op image?

- Yes
 No

For the longest crack seen in the Post-Op image, is the crack:

- an Incomplete Crack from the canal towards the root surface
 an Incomplete Crack from the root surface towards the canal
 A complete crack

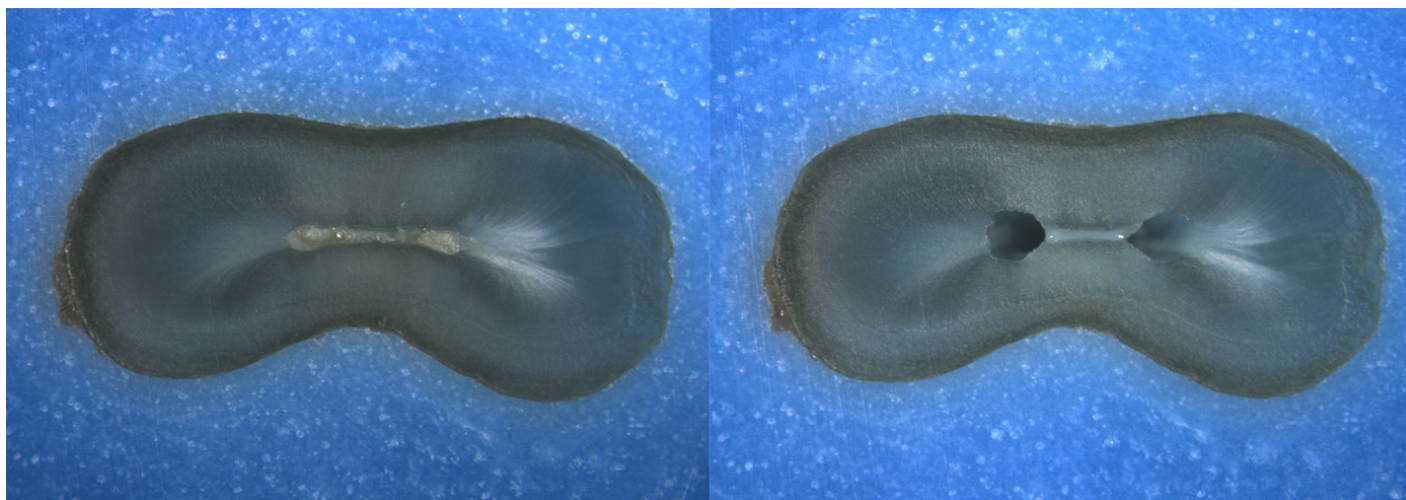
Is the crack seen in the Post-Op image:

- an Incomplete Crack from the canal towards the root surface
 an Incomplete Crack from the root surface towards the canal
 A complete crack

Done. Go to next page

Image: i076.jpg

Pre-Op on the left and Post-Op on the right



Is there any evidence of a dentinal crack prior to rotary instrumentation (Pre-Op)?

- Yes
 No

Does the crack in the Pre-Op image increase in size when viewed in the Post-Op image?

- Yes
 No

Is the crack that increased in the Pre-Op image now:

- an Incomplete Crack from the canal towards the root surface
 an Incomplete Crack from the root surface towards the canal
 A complete crack

Is there a new dentinal crack present in the instrumented (Post-Op) sample not seen in the Pre-Op image?

- Yes
 No

Is the new crack in the Post-Op image:

- an Incomplete Crack from the canal towards the root surface
 an Incomplete Crack from the root surface towards the canal
 A complete crack

Is there a dentinal crack present in the instrumented (Post-Op) sample not seen in the Pre-Op image?

- Yes
 No

Is there more than one crack seen in the Post-Op image?

- Yes
 No

For the longest crack seen in the Post-Op image, is the crack:

- an Incomplete Crack from the canal towards the root surface
 an Incomplete Crack from the root surface towards the canal
 A complete crack

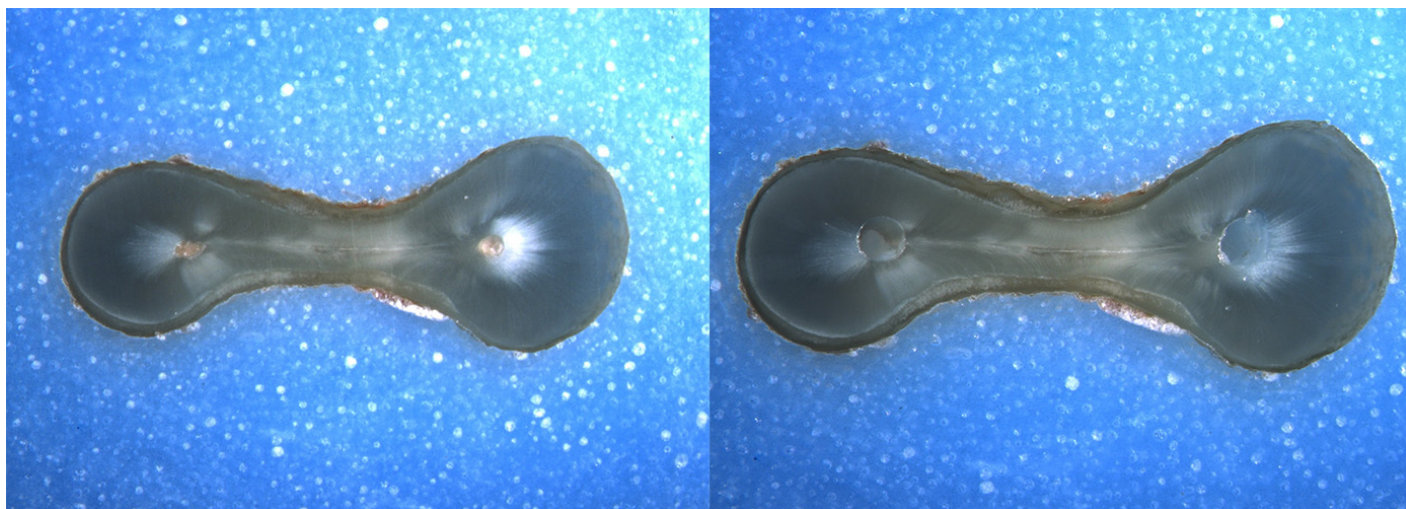
Is the crack seen in the Post-Op image:

- an Incomplete Crack from the canal towards the root surface
 an Incomplete Crack from the root surface towards the canal
 A complete crack

Done. Go to next page

Image: i077.jpg

Pre-Op on the left and Post-Op on the right



Is there any evidence of a dentinal crack prior to rotary instrumentation (Pre-Op)?

- Yes
 No

Does the crack in the Pre-Op image increase in size when viewed in the Post-Op image?

- Yes
 No

Is the crack that increased in the Pre-Op image now:

- an Incomplete Crack from the canal towards the root surface
 an Incomplete Crack from the root surface towards the canal
 A complete crack

Is there a new dentinal crack present in the instrumented (Post-Op) sample not seen in the Pre-Op image?

- Yes
 No

Is the new crack in the Post-Op image:

- an Incomplete Crack from the canal towards the root surface
 an Incomplete Crack from the root surface towards the canal
 A complete crack

Is there a dentinal crack present in the instrumented (Post-Op) sample not seen in the Pre-Op image?

- Yes
 No

Is there more than one crack seen in the Post-Op image?

- Yes
 No

For the longest crack seen in the Post-Op image, is the crack:

- an Incomplete Crack from the canal towards the root surface
 an Incomplete Crack from the root surface towards the canal
 A complete crack

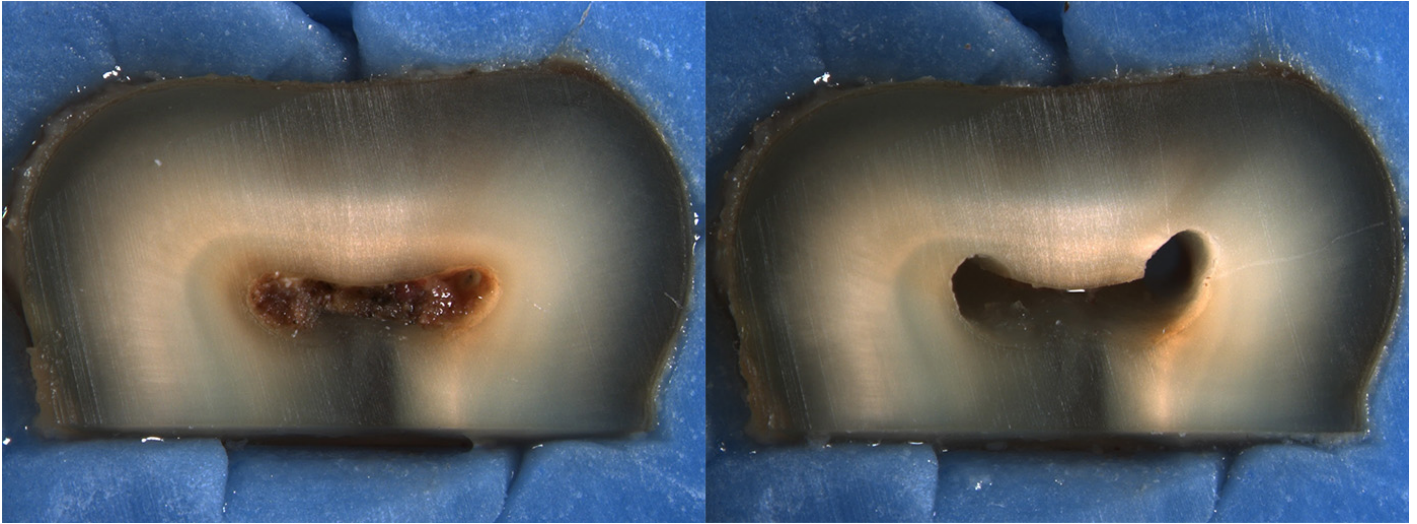
Is the crack seen in the Post-Op image:

- an Incomplete Crack from the canal towards the root surface
 an Incomplete Crack from the root surface towards the canal
 A complete crack

Done. Go to next page

Image: i078.jpg

Pre-Op on the left and Post-Op on the right



Is there any evidence of a dentinal crack prior to rotary instrumentation (Pre-Op)?

- Yes
 No

Does the crack in the Pre-Op image increase in size when viewed in the Post-Op image?

- Yes
 No

Is the crack that increased in the Pre-Op image now:

- an Incomplete Crack from the canal towards the root surface
 an Incomplete Crack from the root surface towards the canal
 A complete crack

Is there a new dentinal crack present in the instrumented (Post-Op) sample not seen in the Pre-Op image?

- Yes
 No

Is the new crack in the Post-Op image:

- an Incomplete Crack from the canal towards the root surface
 an Incomplete Crack from the root surface towards the canal
 A complete crack

Is there a dentinal crack present in the instrumented (Post-Op) sample not seen in the Pre-Op image?

- Yes
 No

Is there more than one crack seen in the Post-Op image?

- Yes
 No

For the longest crack seen in the Post-Op image, is the crack:

- an Incomplete Crack from the canal towards the root surface
 an Incomplete Crack from the root surface towards the canal
 A complete crack


Is the crack seen in the Post-Op image:

- an Incomplete Crack from the canal towards the root surface
 an Incomplete Crack from the root surface towards the canal
 A complete crack

Done. Go to next page

Image: i079.jpg

Pre-Op on the left and Post-Op on the right



Is there any evidence of a dentinal crack prior to rotary instrumentation (Pre-Op)?

- Yes
 No

Does the crack in the Pre-Op image increase in size when viewed in the Post-Op image?

- Yes
 No

Is the crack that increased in the Pre-Op image now:

- an Incomplete Crack from the canal towards the root surface
 an Incomplete Crack from the root surface towards the canal
 A complete crack

Is there a new dentinal crack present in the instrumented (Post-Op) sample not seen in the Pre-Op image?

- Yes
 No

Is the new crack in the Post-Op image:

- an Incomplete Crack from the canal towards the root surface
 an Incomplete Crack from the root surface towards the canal
 A complete crack

Is there a dentinal crack present in the instrumented (Post-Op) sample not seen in the Pre-Op image?

- Yes
 No

Is there more than one crack seen in the Post-Op image?

- Yes
 No

For the longest crack seen in the Post-Op image, is the crack:

- an Incomplete Crack from the canal towards the root surface
 an Incomplete Crack from the root surface towards the canal
 A complete crack

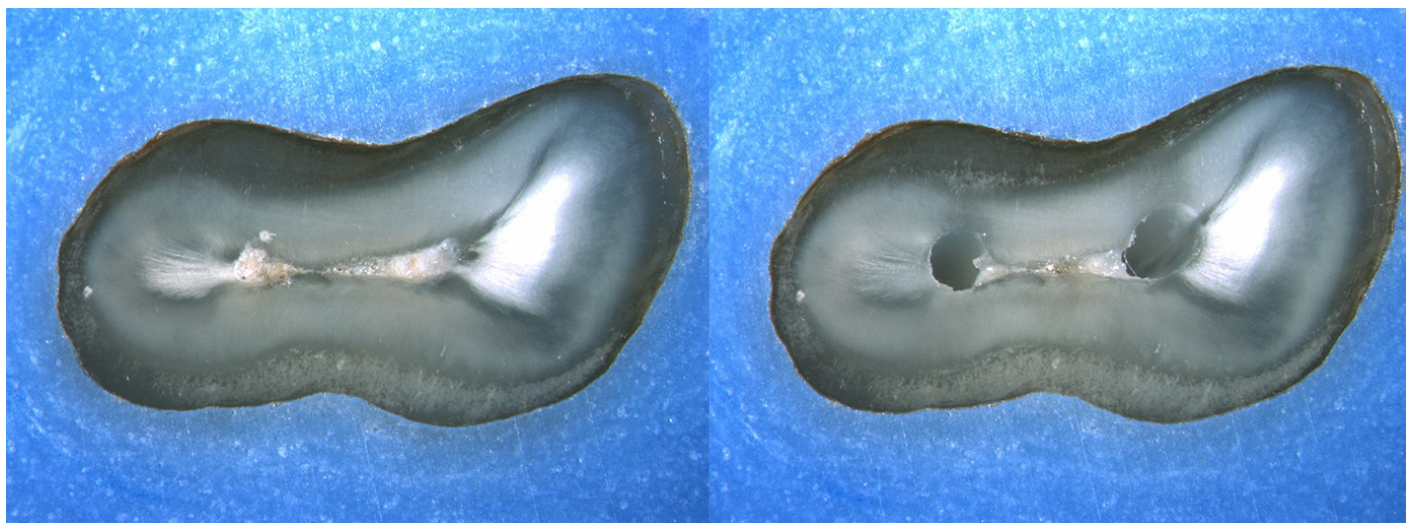
Is the crack seen in the Post-Op image:

- an Incomplete Crack from the canal towards the root surface
 an Incomplete Crack from the root surface towards the canal
 A complete crack

Done. Go to next page

Image: i080.jpg

Pre-Op on the left and Post-Op on the right



Is there any evidence of a dentinal crack prior to rotary instrumentation (Pre-Op)?

- Yes
 No

Does the crack in the Pre-Op image increase in size when viewed in the Post-Op image?

- Yes
 No

Is the crack that increased in the Pre-Op image now:

- an Incomplete Crack from the canal towards the root surface
 an Incomplete Crack from the root surface towards the canal
 A complete crack

Is there a new dentinal crack present in the instrumented (Post-Op) sample not seen in the Pre-Op image?

- Yes
 No

Is the new crack in the Post-Op image:

- an Incomplete Crack from the canal towards the root surface
 an Incomplete Crack from the root surface towards the canal
 A complete crack

Is there a dentinal crack present in the instrumented (Post-Op) sample not seen in the Pre-Op image?

- Yes
 No

Is there more than one crack seen in the Post-Op image?

- Yes
 No

For the longest crack seen in the Post-Op image, is the crack:

- an Incomplete Crack from the canal towards the root surface
 an Incomplete Crack from the root surface towards the canal
 A complete crack

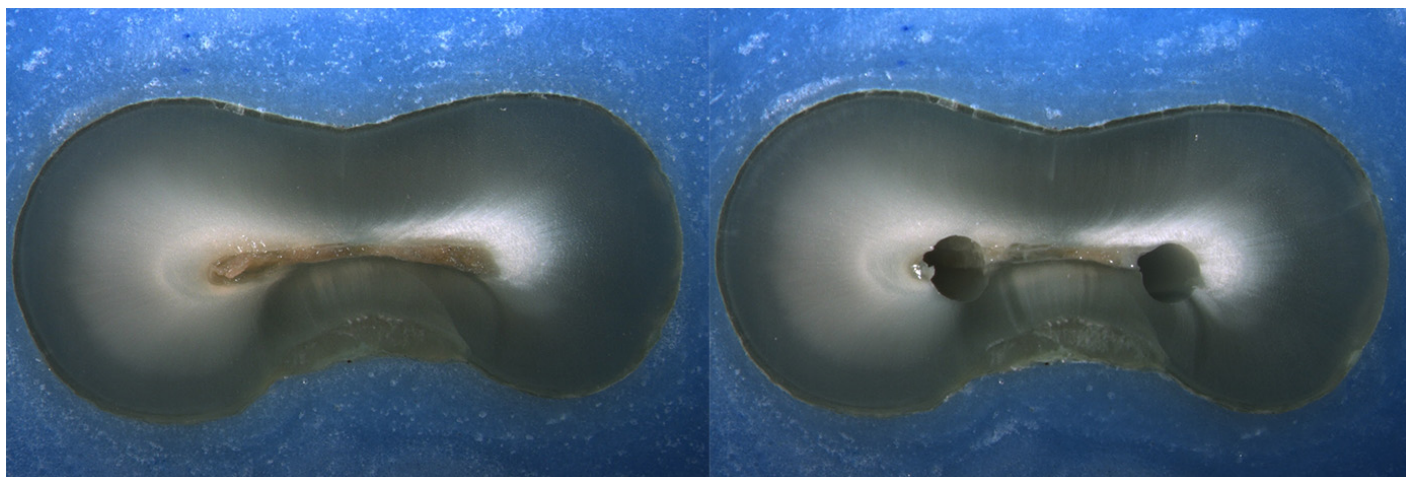
Is the crack seen in the Post-Op image:

- an Incomplete Crack from the canal towards the root surface
 an Incomplete Crack from the root surface towards the canal
 A complete crack

Done. Go to next page

Image: i081.jpg

Pre-Op on the left and Post-Op on the right



Is there any evidence of a dentinal crack prior to rotary instrumentation (Pre-Op)?

- Yes
 No

Does the crack in the Pre-Op image increase in size when viewed in the Post-Op image?

- Yes
 No

Is the crack that increased in the Pre-Op image now:

- an Incomplete Crack from the canal towards the root surface
 an Incomplete Crack from the root surface towards the canal
 A complete crack

Is there a new dentinal crack present in the instrumented (Post-Op) sample not seen in the Pre-Op image?

- Yes
 No

Is the new crack in the Post-Op image:

- an Incomplete Crack from the canal towards the root surface
 an Incomplete Crack from the root surface towards the canal
 A complete crack

Is there a dentinal crack present in the instrumented (Post-Op) sample not seen in the Pre-Op image?

- Yes
 No

Is there more than one crack seen in the Post-Op image?

- Yes
 No

For the longest crack seen in the Post-Op image, is the crack:

- an Incomplete Crack from the canal towards the root surface
 an Incomplete Crack from the root surface towards the canal
 A complete crack

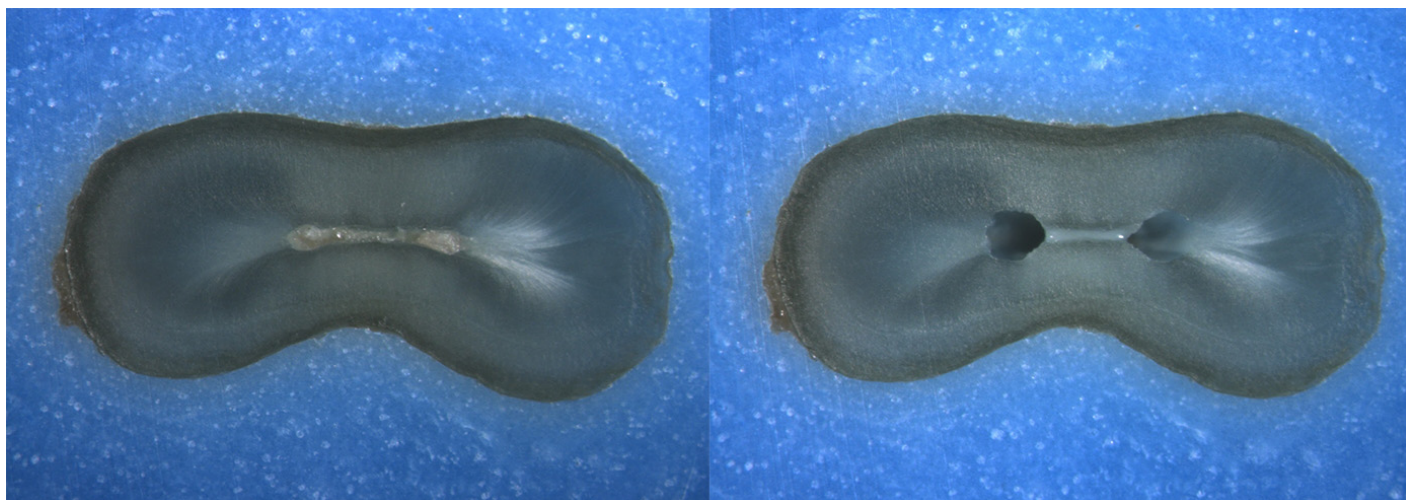
Is the crack seen in the Post-Op image:

- an Incomplete Crack from the canal towards the root surface
 an Incomplete Crack from the root surface towards the canal
 A complete crack

Done. Go to next page

Image: i082.jpg

Pre-Op on the left and Post-Op on the right



Is there any evidence of a dentinal crack prior to rotary instrumentation (Pre-Op)?

- Yes
 No

Does the crack in the Pre-Op image increase in size when viewed in the Post-Op image?

- Yes
 No

Is the crack that increased in the Pre-Op image now:

- an Incomplete Crack from the canal towards the root surface
 an Incomplete Crack from the root surface towards the canal
 A complete crack

Is there a new dentinal crack present in the instrumented (Post-Op) sample not seen in the Pre-Op image?

- Yes
 No

Is the new crack in the Post-Op image:

- an Incomplete Crack from the canal towards the root surface
 an Incomplete Crack from the root surface towards the canal
 A complete crack

Is there a dentinal crack present in the instrumented (Post-Op) sample not seen in the Pre-Op image?

- Yes
 No

Is there more than one crack seen in the Post-Op image?

- Yes
 No

For the longest crack seen in the Post-Op image, is the crack:

- an Incomplete Crack from the canal towards the root surface
 an Incomplete Crack from the root surface towards the canal
 A complete crack

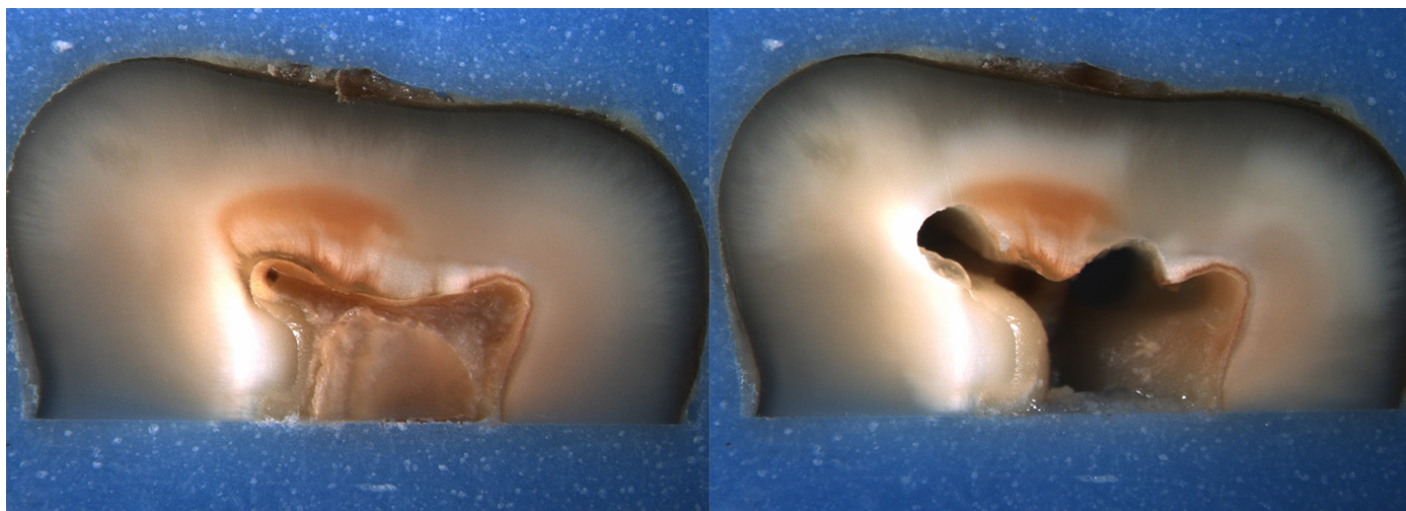
Is the crack seen in the Post-Op image:

- an Incomplete Crack from the canal towards the root surface
 an Incomplete Crack from the root surface towards the canal
 A complete crack

Done. Go to next page

Image: i083.jpg

Pre-Op on the left and Post-Op on the right



Is there any evidence of a dentinal crack prior to rotary instrumentation (Pre-Op)?

- Yes
 No

Does the crack in the Pre-Op image increase in size when viewed in the Post-Op image?

- Yes
 No

Is the crack that increased in the Pre-Op image now:

- an Incomplete Crack from the canal towards the root surface
 an Incomplete Crack from the root surface towards the canal
 A complete crack

Is there a new dentinal crack present in the instrumented (Post-Op) sample not seen in the Pre-Op image?

- Yes
 No

Is the new crack in the Post-Op image:

- an Incomplete Crack from the canal towards the root surface
 an Incomplete Crack from the root surface towards the canal
 A complete crack

Is there a dentinal crack present in the instrumented (Post-Op) sample not seen in the Pre-Op image?

- Yes
 No

Is there more than one crack seen in the Post-Op image?

- Yes
 No

For the longest crack seen in the Post-Op image, is the crack:

- an Incomplete Crack from the canal towards the root surface
 an Incomplete Crack from the root surface towards the canal
 A complete crack

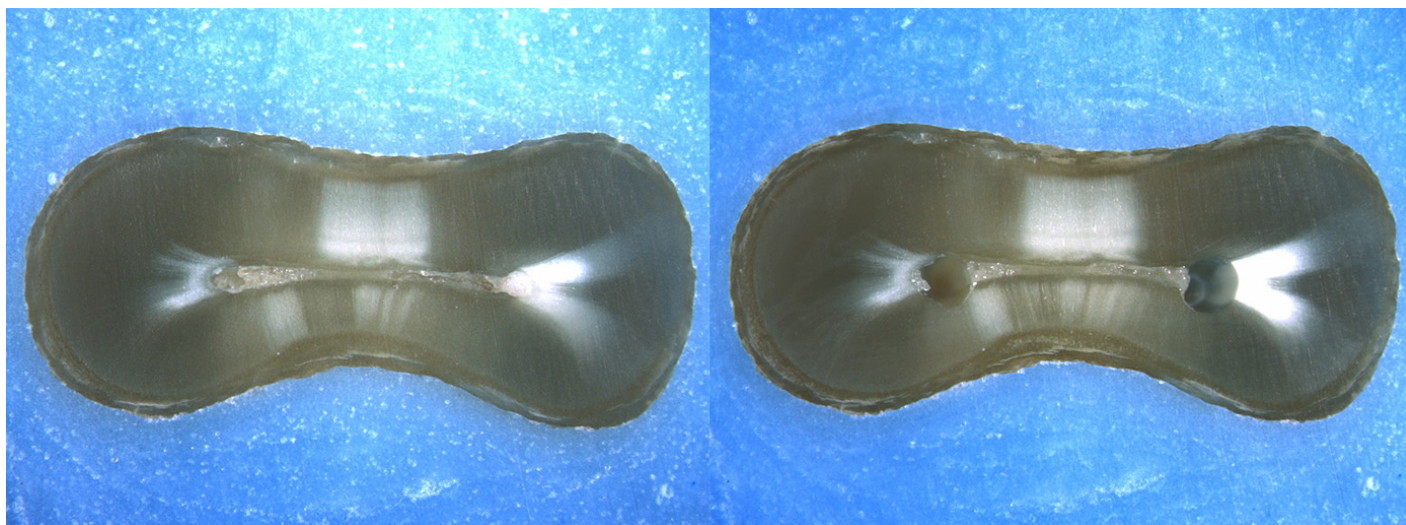
Is the crack seen in the Post-Op image:

- an Incomplete Crack from the canal towards the root surface
 an Incomplete Crack from the root surface towards the canal
 A complete crack

Done. Go to next page

Image: i084.jpg

Pre-Op on the left and Post-Op on the right



Is there any evidence of a dentinal crack prior to rotary instrumentation (Pre-Op)?

- Yes
 No

Does the crack in the Pre-Op image increase in size when viewed in the Post-Op image?

- Yes
 No

Is the crack that increased in the Pre-Op image now:

- an Incomplete Crack from the canal towards the root surface
 an Incomplete Crack from the root surface towards the canal
 A complete crack

Is there a new dentinal crack present in the instrumented (Post-Op) sample not seen in the Pre-Op image?

- Yes
 No

Is the new crack in the Post-Op image:

- an Incomplete Crack from the canal towards the root surface
 an Incomplete Crack from the root surface towards the canal
 A complete crack

Is there a dentinal crack present in the instrumented (Post-Op) sample not seen in the Pre-Op image?

- Yes
 No

Is there more than one crack seen in the Post-Op image?

- Yes
 No

For the longest crack seen in the Post-Op image, is the crack:

- an Incomplete Crack from the canal towards the root surface
 an Incomplete Crack from the root surface towards the canal
 A complete crack

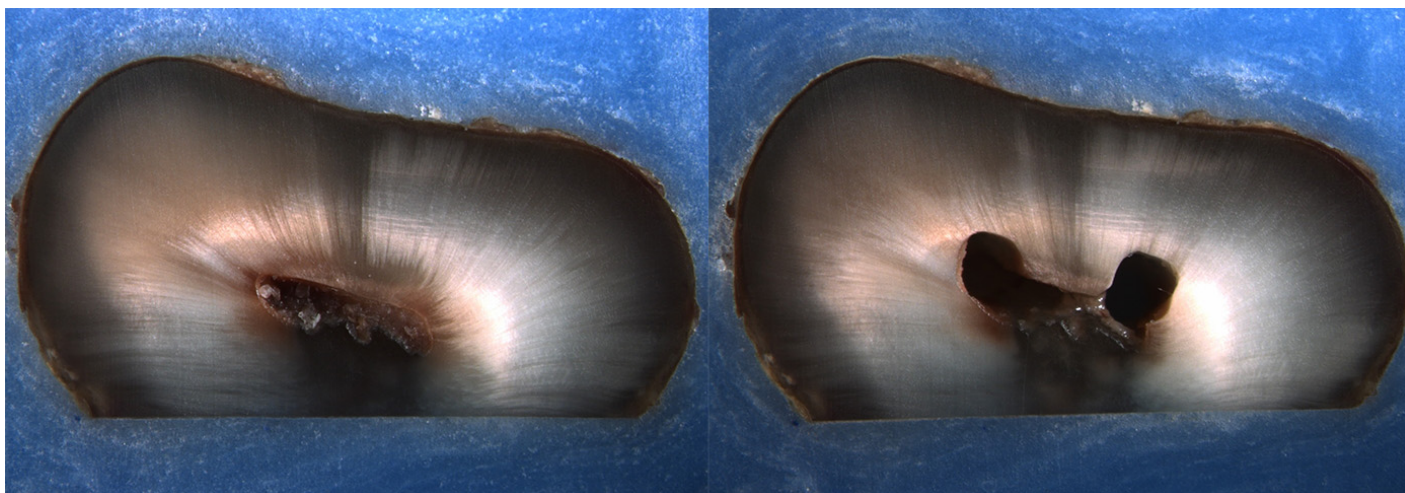
Is the crack seen in the Post-Op image:

- an Incomplete Crack from the canal towards the root surface
 an Incomplete Crack from the root surface towards the canal
 A complete crack

Done. Go to next page

Image: i085.jpg

Pre-Op on the left and Post-Op on the right



Is there any evidence of a dentinal crack prior to rotary instrumentation (Pre-Op)?

- Yes
 No

Does the crack in the Pre-Op image increase in size when viewed in the Post-Op image?

- Yes
 No

Is the crack that increased in the Pre-Op image now:

- an Incomplete Crack from the canal towards the root surface
 an Incomplete Crack from the root surface towards the canal
 A complete crack

Is there a new dentinal crack present in the instrumented (Post-Op) sample not seen in the Pre-Op image?

- Yes
 No

Is the new crack in the Post-Op image:

- an Incomplete Crack from the canal towards the root surface
 an Incomplete Crack from the root surface towards the canal
 A complete crack

Is there a dentinal crack present in the instrumented (Post-Op) sample not seen in the Pre-Op image?

- Yes
 No

Is there more than one crack seen in the Post-Op image?

- Yes
 No

For the longest crack seen in the Post-Op image, is the crack:

- an Incomplete Crack from the canal towards the root surface
 an Incomplete Crack from the root surface towards the canal
 A complete crack

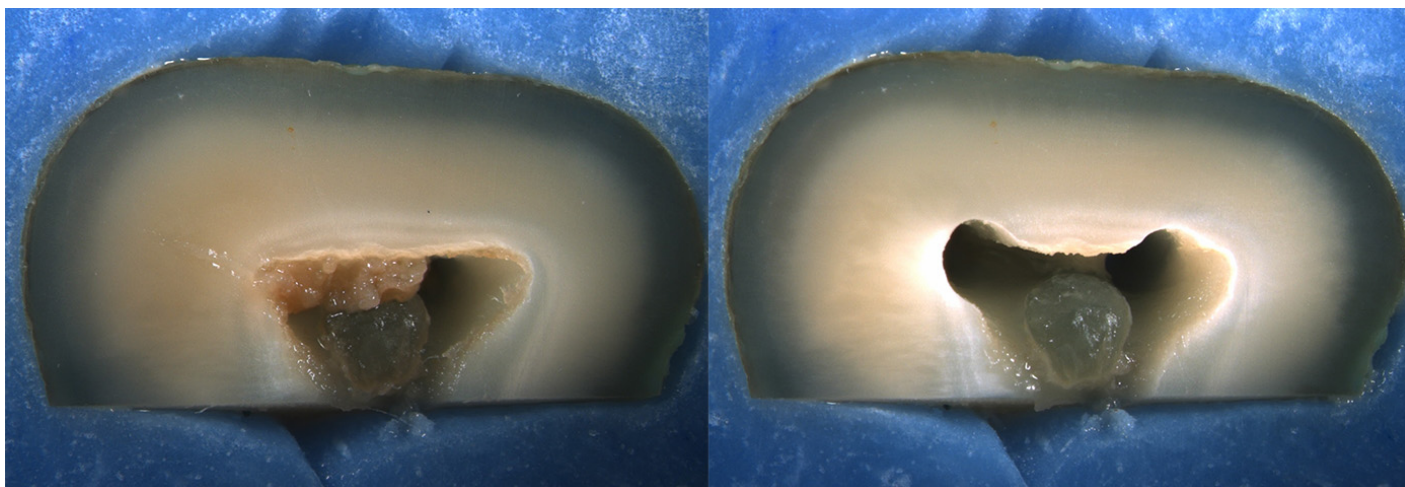
Is the crack seen in the Post-Op image:

- an Incomplete Crack from the canal towards the root surface
 an Incomplete Crack from the root surface towards the canal
 A complete crack

Done. Go to next page

Image: i086.jpg

Pre-Op on the left and Post-Op on the right



Is there any evidence of a dentinal crack prior to rotary instrumentation (Pre-Op)?

- Yes
 No

Does the crack in the Pre-Op image increase in size when viewed in the Post-Op image?

- Yes
 No

Is the crack that increased in the Pre-Op image now:

- an Incomplete Crack from the canal towards the root surface
 an Incomplete Crack from the root surface towards the canal
 A complete crack

Is there a new dentinal crack present in the instrumented (Post-Op) sample not seen in the Pre-Op image?

- Yes
 No

Is the new crack in the Post-Op image:

- an Incomplete Crack from the canal towards the root surface
 an Incomplete Crack from the root surface towards the canal
 A complete crack

Is there a dentinal crack present in the instrumented (Post-Op) sample not seen in the Pre-Op image?

- Yes
 No

Is there more than one crack seen in the Post-Op image?

- Yes
 No

For the longest crack seen in the Post-Op image, is the crack:

- an Incomplete Crack from the canal towards the root surface
 an Incomplete Crack from the root surface towards the canal
 A complete crack

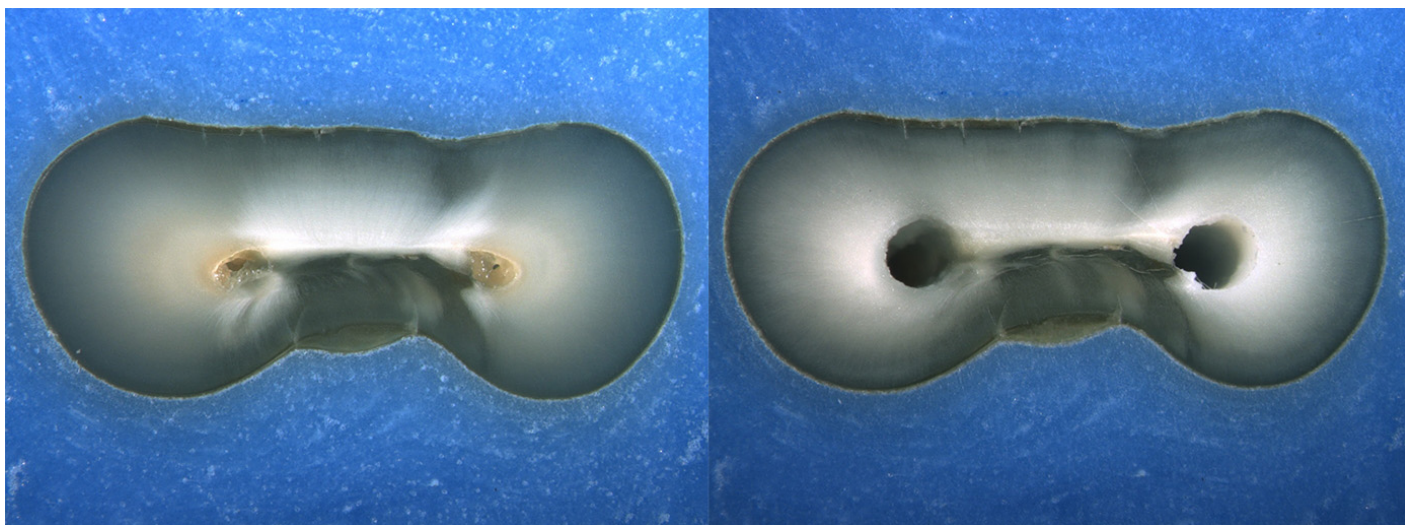
Is the crack seen in the Post-Op image:

- an Incomplete Crack from the canal towards the root surface
 an Incomplete Crack from the root surface towards the canal
 A complete crack

Done. Go to next page

Image: i087.jpg

Pre-Op on the left and Post-Op on the right



Is there any evidence of a dentinal crack prior to rotary instrumentation (Pre-Op)?

- Yes
 No

Does the crack in the Pre-Op image increase in size when viewed in the Post-Op image?

- Yes
 No

Is the crack that increased in the Pre-Op image now:

- an Incomplete Crack from the canal towards the root surface
 an Incomplete Crack from the root surface towards the canal
 A complete crack

Is there a new dentinal crack present in the instrumented (Post-Op) sample not seen in the Pre-Op image?

- Yes
 No

Is the new crack in the Post-Op image:

- an Incomplete Crack from the canal towards the root surface
 an Incomplete Crack from the root surface towards the canal
 A complete crack

Is there a dentinal crack present in the instrumented (Post-Op) sample not seen in the Pre-Op image?

- Yes
 No

Is there more than one crack seen in the Post-Op image?

- Yes
 No

For the longest crack seen in the Post-Op image, is the crack:

- an Incomplete Crack from the canal towards the root surface
 an Incomplete Crack from the root surface towards the canal
 A complete crack

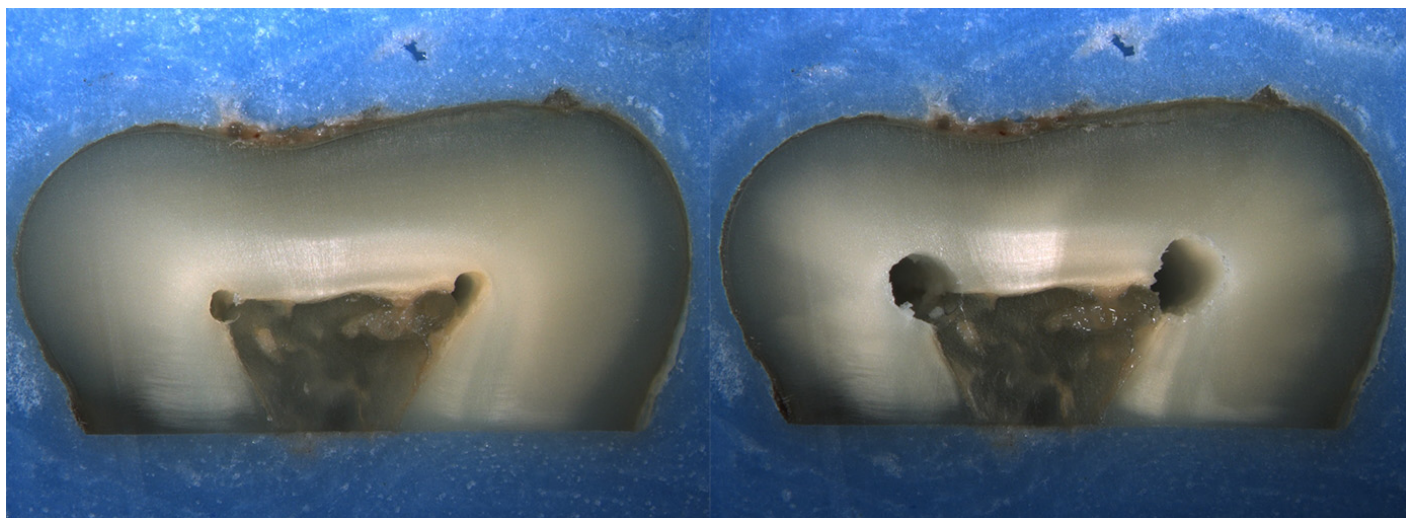
Is the crack seen in the Post-Op image:

- an Incomplete Crack from the canal towards the root surface
 an Incomplete Crack from the root surface towards the canal
 A complete crack

Done. Go to next page

Image: i088.jpg

Pre-Op on the left and Post-Op on the right



Is there any evidence of a dentinal crack prior to rotary instrumentation (Pre-Op)?

- Yes
 No

Does the crack in the Pre-Op image increase in size when viewed in the Post-Op image?

- Yes
 No

Is the crack that increased in the Pre-Op image now:

- an Incomplete Crack from the canal towards the root surface
 an Incomplete Crack from the root surface towards the canal
 A complete crack

Is there a new dentinal crack present in the instrumented (Post-Op) sample not seen in the Pre-Op image?

- Yes
 No

Is the new crack in the Post-Op image:

- an Incomplete Crack from the canal towards the root surface
 an Incomplete Crack from the root surface towards the canal
 A complete crack

Is there a dentinal crack present in the instrumented (Post-Op) sample not seen in the Pre-Op image?

- Yes
 No

Is there more than one crack seen in the Post-Op image?

- Yes
 No

For the longest crack seen in the Post-Op image, is the crack:

- an Incomplete Crack from the canal towards the root surface
 an Incomplete Crack from the root surface towards the canal
 A complete crack

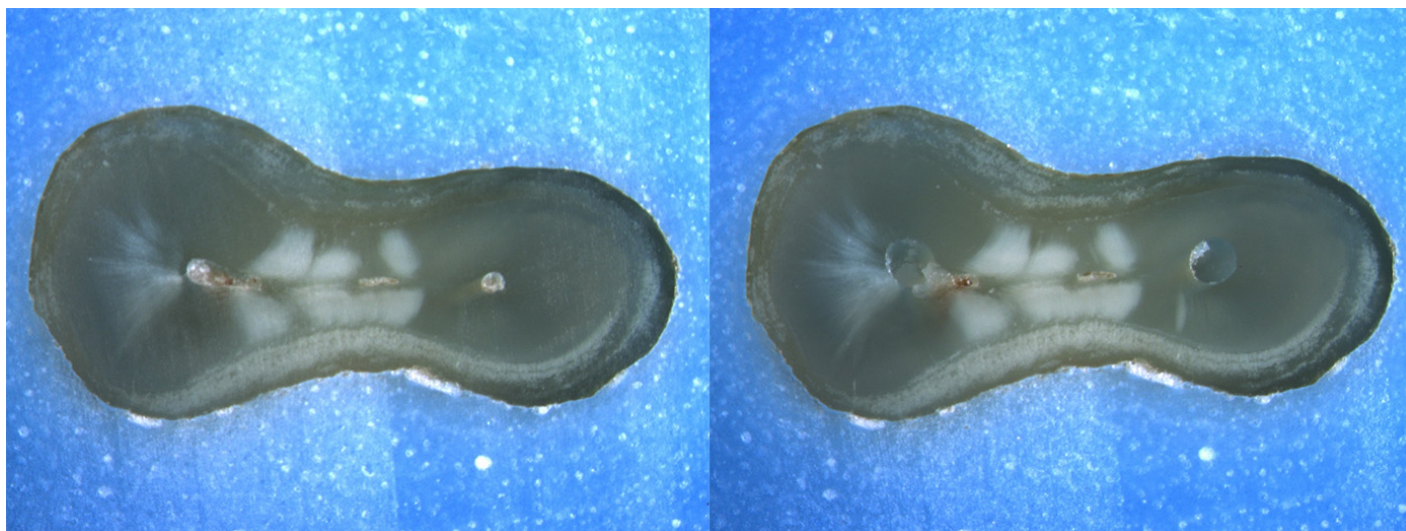
Is the crack seen in the Post-Op image:

- an Incomplete Crack from the canal towards the root surface
 an Incomplete Crack from the root surface towards the canal
 A complete crack

Done. Go to next page

Image: i089.jpg

Pre-Op on the left and Post-Op on the right



Is there any evidence of a dentinal crack prior to rotary instrumentation (Pre-Op)?

- Yes
 No

Does the crack in the Pre-Op image increase in size when viewed in the Post-Op image?

- Yes
 No

Is the crack that increased in the Pre-Op image now:

- an Incomplete Crack from the canal towards the root surface
 an Incomplete Crack from the root surface towards the canal
 A complete crack

Is there a new dentinal crack present in the instrumented (Post-Op) sample not seen in the Pre-Op image?

- Yes
 No

Is the new crack in the Post-Op image:

- an Incomplete Crack from the canal towards the root surface
 an Incomplete Crack from the root surface towards the canal
 A complete crack

Is there a dentinal crack present in the instrumented (Post-Op) sample not seen in the Pre-Op image?

- Yes
 No

Is there more than one crack seen in the Post-Op image?

- Yes
 No

For the longest crack seen in the Post-Op image, is the crack:

- an Incomplete Crack from the canal towards the root surface
 an Incomplete Crack from the root surface towards the canal
 A complete crack

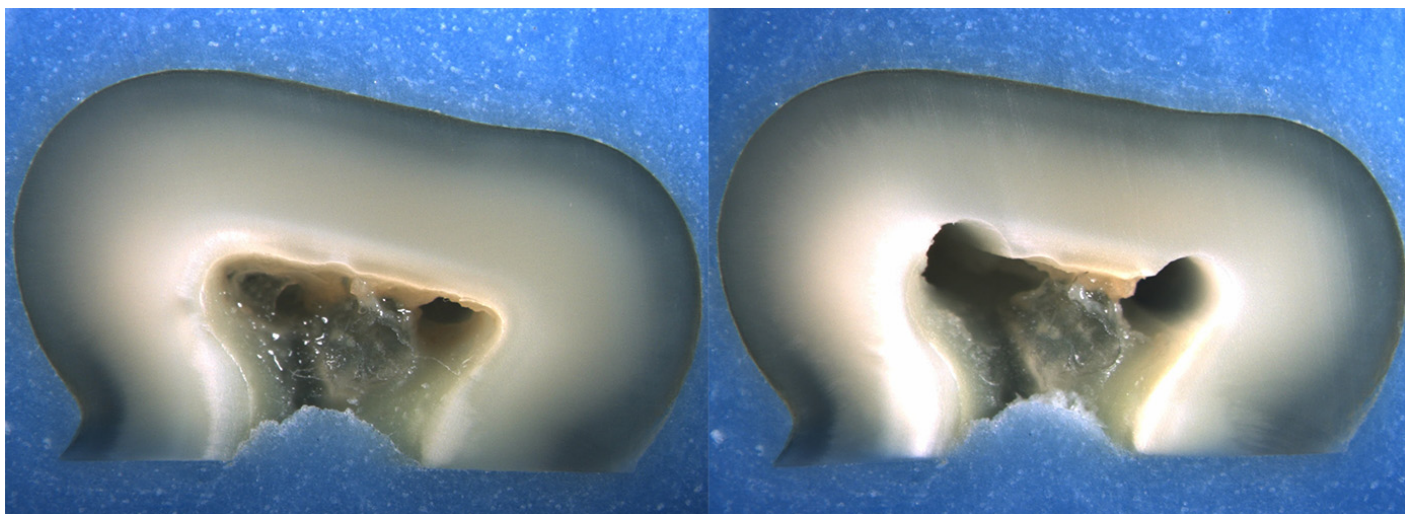
Is the crack seen in the Post-Op image:

- an Incomplete Crack from the canal towards the root surface
 an Incomplete Crack from the root surface towards the canal
 A complete crack

Done. Go to next page

Image: i090.jpg

Pre-Op on the left and Post-Op on the right



Is there any evidence of a dentinal crack prior to rotary instrumentation (Pre-Op)?

- Yes
 No

Does the crack in the Pre-Op image increase in size when viewed in the Post-Op image?

- Yes
 No

Is the crack that increased in the Pre-Op image now:

- an Incomplete Crack from the canal towards the root surface
 an Incomplete Crack from the root surface towards the canal
 A complete crack

Is there a new dentinal crack present in the instrumented (Post-Op) sample not seen in the Pre-Op image?

- Yes
 No

Is the new crack in the Post-Op image:

- an Incomplete Crack from the canal towards the root surface
 an Incomplete Crack from the root surface towards the canal
 A complete crack

Is there a dentinal crack present in the instrumented (Post-Op) sample not seen in the Pre-Op image?

- Yes
 No

Is there more than one crack seen in the Post-Op image?

- Yes
 No

For the longest crack seen in the Post-Op image, is the crack:

- an Incomplete Crack from the canal towards the root surface
 an Incomplete Crack from the root surface towards the canal
 A complete crack

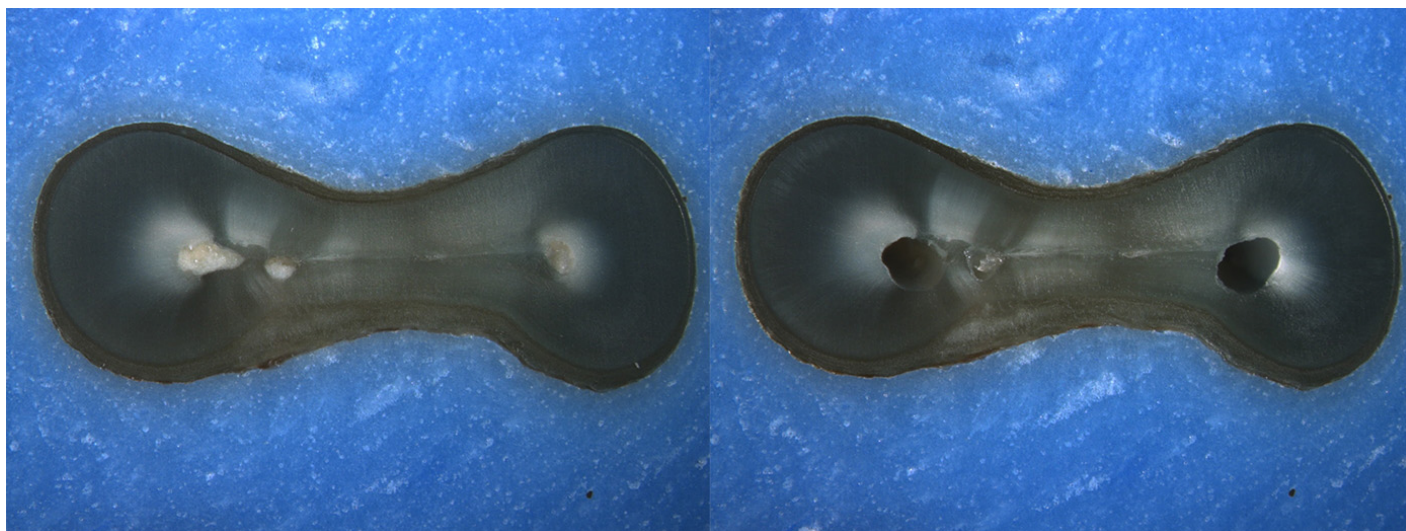
Is the crack seen in the Post-Op image:

- an Incomplete Crack from the canal towards the root surface
 an Incomplete Crack from the root surface towards the canal
 A complete crack

Done. Go to next page

Image: i091.jpg

Pre-Op on the left and Post-Op on the right



Is there any evidence of a dentinal crack prior to rotary instrumentation (Pre-Op)?

- Yes
 No

Does the crack in the Pre-Op image increase in size when viewed in the Post-Op image?

- Yes
 No

Is the crack that increased in the Pre-Op image now:

- an Incomplete Crack from the canal towards the root surface
 an Incomplete Crack from the root surface towards the canal
 A complete crack

Is there a new dentinal crack present in the instrumented (Post-Op) sample not seen in the Pre-Op image?

- Yes
 No

Is the new crack in the Post-Op image:

- an Incomplete Crack from the canal towards the root surface
 an Incomplete Crack from the root surface towards the canal
 A complete crack

Is there a dentinal crack present in the instrumented (Post-Op) sample not seen in the Pre-Op image?

- Yes
 No

Is there more than one crack seen in the Post-Op image?

- Yes
 No

For the longest crack seen in the Post-Op image, is the crack:

- an Incomplete Crack from the canal towards the root surface
 an Incomplete Crack from the root surface towards the canal
 A complete crack

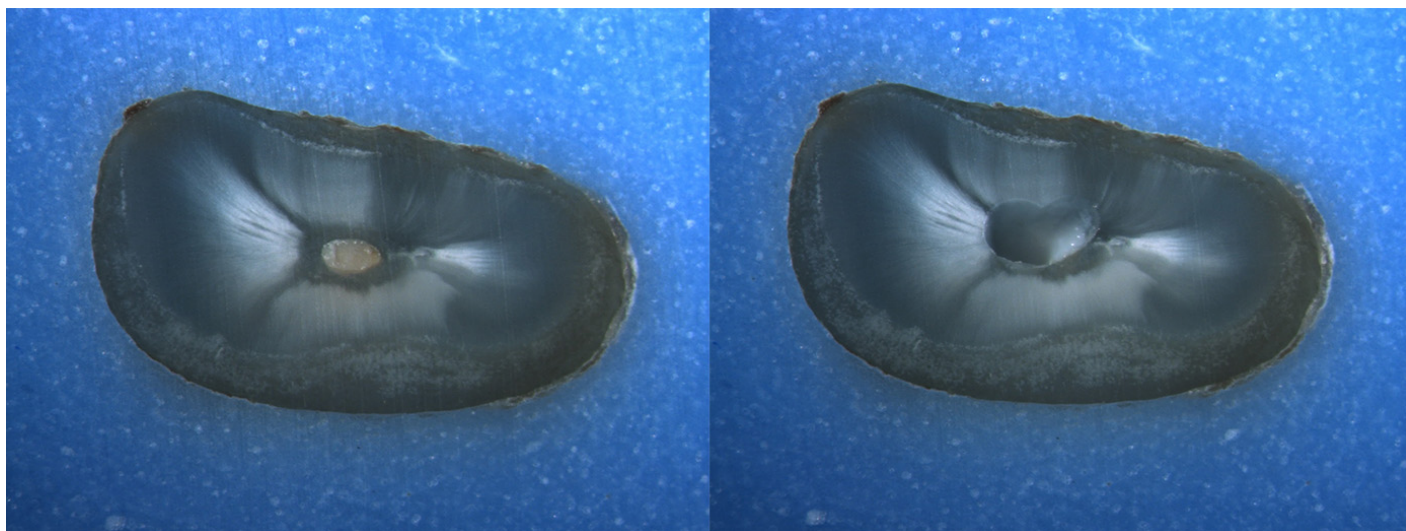
Is the crack seen in the Post-Op image:

- an Incomplete Crack from the canal towards the root surface
 an Incomplete Crack from the root surface towards the canal
 A complete crack

Done. Go to next page

Image: i092.jpg

Pre-Op on the left and Post-Op on the right



Is there any evidence of a dentinal crack prior to rotary instrumentation (Pre-Op)?

- Yes
 No

Does the crack in the Pre-Op image increase in size when viewed in the Post-Op image?

- Yes
 No

Is the crack that increased in the Pre-Op image now:

- an Incomplete Crack from the canal towards the root surface
 an Incomplete Crack from the root surface towards the canal
 A complete crack

Is there a new dentinal crack present in the instrumented (Post-Op) sample not seen in the Pre-Op image?

- Yes
 No

Is the new crack in the Post-Op image:

- an Incomplete Crack from the canal towards the root surface
 an Incomplete Crack from the root surface towards the canal
 A complete crack

Is there a dentinal crack present in the instrumented (Post-Op) sample not seen in the Pre-Op image?

- Yes
 No

Is there more than one crack seen in the Post-Op image?

- Yes
 No

For the longest crack seen in the Post-Op image, is the crack:

- an Incomplete Crack from the canal towards the root surface
 an Incomplete Crack from the root surface towards the canal
 A complete crack

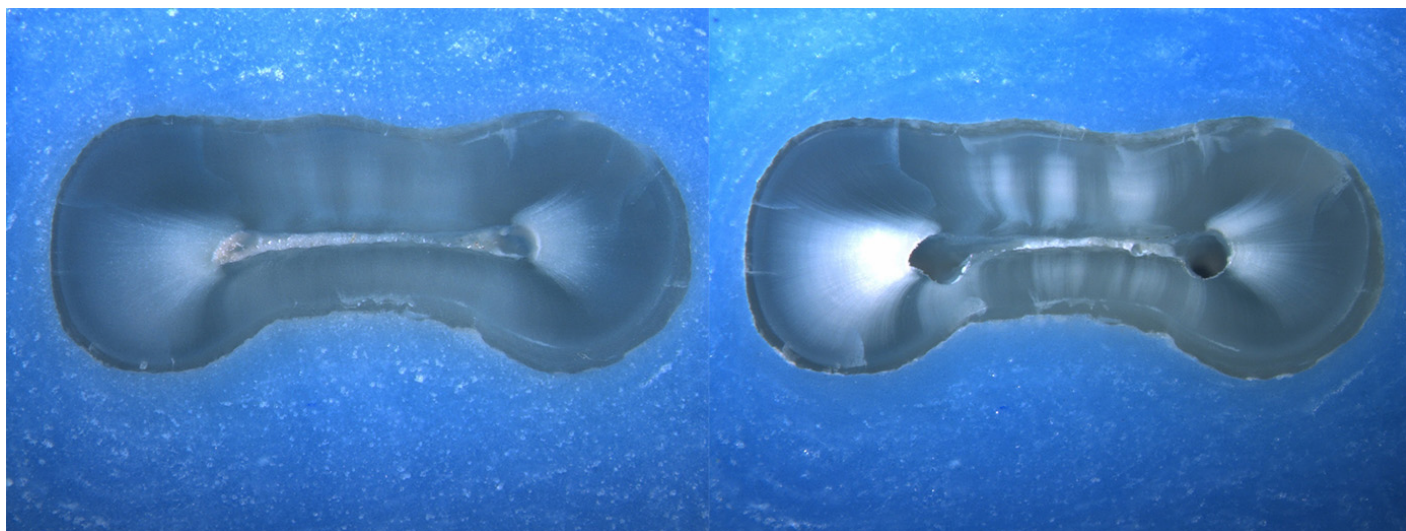
Is the crack seen in the Post-Op image:

- an Incomplete Crack from the canal towards the root surface
 an Incomplete Crack from the root surface towards the canal
 A complete crack

Done. Go to next page

Image: i093.jpg

Pre-Op on the left and Post-Op on the right



Is there any evidence of a dentinal crack prior to rotary instrumentation (Pre-Op)?

- Yes
 No

Does the crack in the Pre-Op image increase in size when viewed in the Post-Op image?

- Yes
 No

Is the crack that increased in the Pre-Op image now:

- an Incomplete Crack from the canal towards the root surface
 an Incomplete Crack from the root surface towards the canal
 A complete crack

Is there a new dentinal crack present in the instrumented (Post-Op) sample not seen in the Pre-Op image?

- Yes
 No

Is the new crack in the Post-Op image:

- an Incomplete Crack from the canal towards the root surface
 an Incomplete Crack from the root surface towards the canal
 A complete crack

Is there a dentinal crack present in the instrumented (Post-Op) sample not seen in the Pre-Op image?

- Yes
 No

Is there more than one crack seen in the Post-Op image?

- Yes
 No

For the longest crack seen in the Post-Op image, is the crack:

- an Incomplete Crack from the canal towards the root surface
 an Incomplete Crack from the root surface towards the canal
 A complete crack

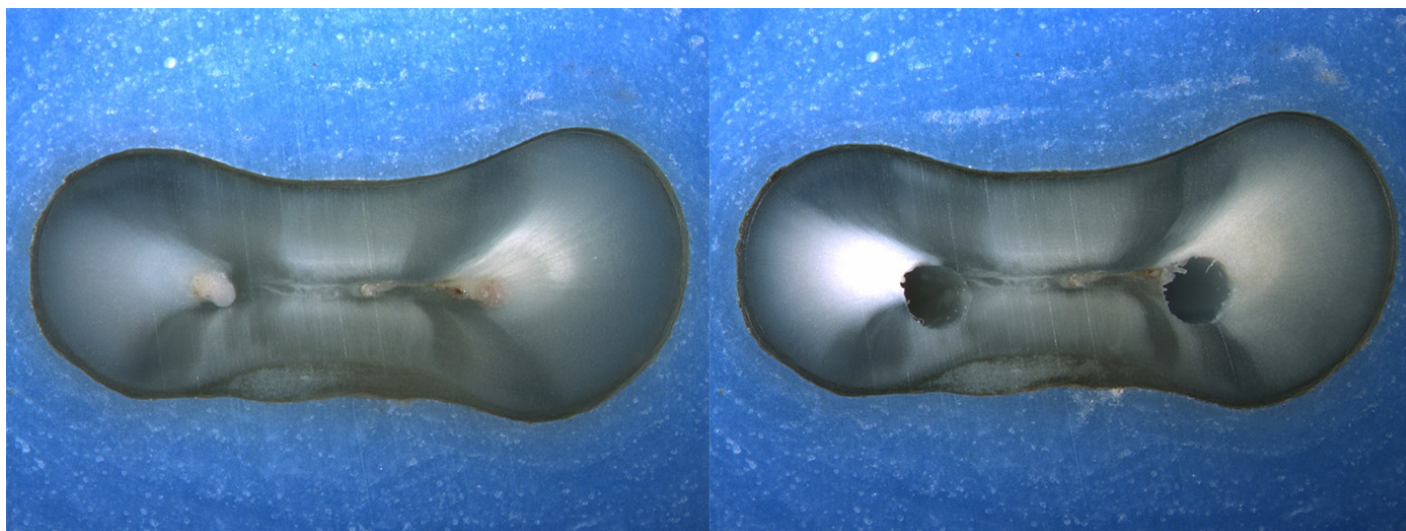
Is the crack seen in the Post-Op image:

- an Incomplete Crack from the canal towards the root surface
 an Incomplete Crack from the root surface towards the canal
 A complete crack

Done. Go to next page

Image: i094.jpg

Pre-Op on the left and Post-Op on the right



Is there any evidence of a dentinal crack prior to rotary instrumentation (Pre-Op)?

- Yes
 No

Does the crack in the Pre-Op image increase in size when viewed in the Post-Op image?

- Yes
 No

Is the crack that increased in the Pre-Op image now:

- an Incomplete Crack from the canal towards the root surface
 an Incomplete Crack from the root surface towards the canal
 A complete crack

Is there a new dentinal crack present in the instrumented (Post-Op) sample not seen in the Pre-Op image?

- Yes
 No

Is the new crack in the Post-Op image:

- an Incomplete Crack from the canal towards the root surface
 an Incomplete Crack from the root surface towards the canal
 A complete crack

Is there a dentinal crack present in the instrumented (Post-Op) sample not seen in the Pre-Op image?

- Yes
 No

Is there more than one crack seen in the Post-Op image?

- Yes
 No

For the longest crack seen in the Post-Op image, is the crack:

- an Incomplete Crack from the canal towards the root surface
 an Incomplete Crack from the root surface towards the canal
 A complete crack


Is the crack seen in the Post-Op image:

- an Incomplete Crack from the canal towards the root surface
 an Incomplete Crack from the root surface towards the canal
 A complete crack

Done. Go to next page

Image: i095.jpg

Pre-Op on the left and Post-Op on the right



Is there any evidence of a dentinal crack prior to rotary instrumentation (Pre-Op)?

- Yes
 No

Does the crack in the Pre-Op image increase in size when viewed in the Post-Op image?

- Yes
 No

Is the crack that increased in the Pre-Op image now:

- an Incomplete Crack from the canal towards the root surface
 an Incomplete Crack from the root surface towards the canal
 A complete crack

Is there a new dentinal crack present in the instrumented (Post-Op) sample not seen in the Pre-Op image?

- Yes
 No

Is the new crack in the Post-Op image:

- an Incomplete Crack from the canal towards the root surface
 an Incomplete Crack from the root surface towards the canal
 A complete crack

Is there a dentinal crack present in the instrumented (Post-Op) sample not seen in the Pre-Op image?

- Yes
 No

Is there more than one crack seen in the Post-Op image?

- Yes
 No

For the longest crack seen in the Post-Op image, is the crack:

- an Incomplete Crack from the canal towards the root surface
 an Incomplete Crack from the root surface towards the canal
 A complete crack

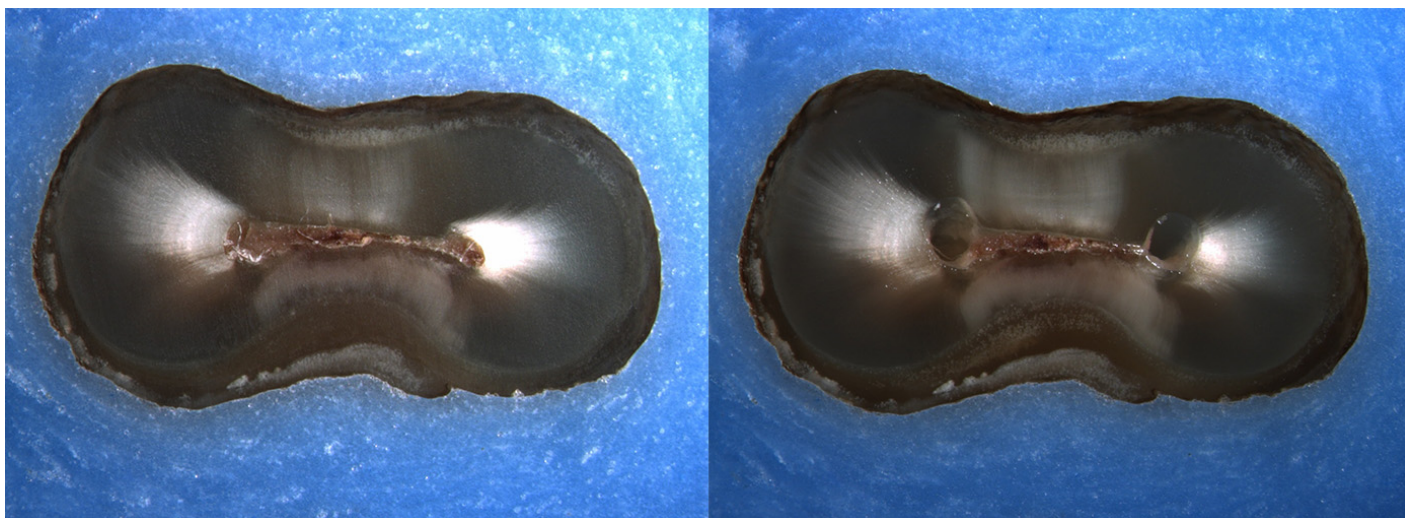
Is the crack seen in the Post-Op image:

- an Incomplete Crack from the canal towards the root surface
 an Incomplete Crack from the root surface towards the canal
 A complete crack

Done. Go to next page

Image: i096.jpg

Pre-Op on the left and Post-Op on the right



Is there any evidence of a dentinal crack prior to rotary instrumentation (Pre-Op)?

- Yes
 No

Does the crack in the Pre-Op image increase in size when viewed in the Post-Op image?

- Yes
 No

Is the crack that increased in the Pre-Op image now:

- an Incomplete Crack from the canal towards the root surface
 an Incomplete Crack from the root surface towards the canal
 A complete crack

Is there a new dentinal crack present in the instrumented (Post-Op) sample not seen in the Pre-Op image?

- Yes
 No

Is the new crack in the Post-Op image:

- an Incomplete Crack from the canal towards the root surface
 an Incomplete Crack from the root surface towards the canal
 A complete crack

Is there a dentinal crack present in the instrumented (Post-Op) sample not seen in the Pre-Op image?

- Yes
 No

Is there more than one crack seen in the Post-Op image?

- Yes
 No

For the longest crack seen in the Post-Op image, is the crack:

- an Incomplete Crack from the canal towards the root surface
 an Incomplete Crack from the root surface towards the canal
 A complete crack

Is the crack seen in the Post-Op image:

- an Incomplete Crack from the canal towards the root surface
 an Incomplete Crack from the root surface towards the canal
 A complete crack

Done with this batch. Yay!

Cracks in Pre-Op vs Post-Op images

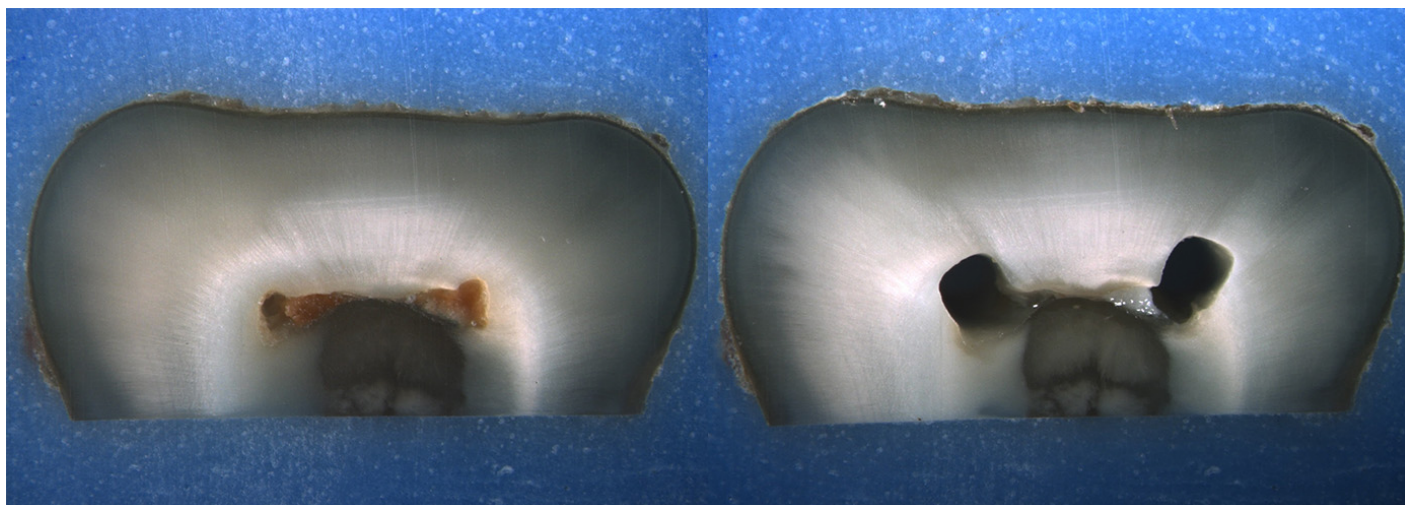
Please complete the survey below.

Thank you!

Rater's last name

Image: i097.jpg

Pre-Op on the left and Post-Op on the right



Is there any evidence of a dentinal crack prior to rotary instrumentation (Pre-Op)?

- Yes
 No

Does the crack in the Pre-Op image increase in size when viewed in the Post-Op image?

- Yes
 No

Is the crack that increased in the Pre-Op image now:

- an Incomplete Crack from the canal towards the root surface
 an Incomplete Crack from the root surface towards the canal
 A complete crack

Is there a new dentinal crack present in the instrumented (Post-Op) sample not seen in the Pre-Op image?

- Yes
 No

Is the new crack in the Post-Op image:

- an Incomplete Crack from the canal towards the root surface
 an Incomplete Crack from the root surface towards the canal
 A complete crack

Is there a dentinal crack present in the instrumented (Post-Op) sample not seen in the Pre-Op image?

- Yes
 No

Is there more than one crack seen in the Post-Op image?

- Yes
 No

For the longest crack seen in the Post-Op image, is the crack:

- an Incomplete Crack from the canal towards the root surface
 an Incomplete Crack from the root surface towards the canal
 A complete crack


Is the crack seen in the Post-Op image:

- an Incomplete Crack from the canal towards the root surface
 an Incomplete Crack from the root surface towards the canal
 A complete crack

Done. Go to next page

Image: i098.jpg

Pre-Op on the left and Post-Op on the right



Is there any evidence of a dentinal crack prior to rotary instrumentation (Pre-Op)?

- Yes
 No

Does the crack in the Pre-Op image increase in size when viewed in the Post-Op image?

- Yes
 No

Is the crack that increased in the Pre-Op image now:

- an Incomplete Crack from the canal towards the root surface
 an Incomplete Crack from the root surface towards the canal
 A complete crack

Is there a new dentinal crack present in the instrumented (Post-Op) sample not seen in the Pre-Op image?

- Yes
 No

Is the new crack in the Post-Op image:

- an Incomplete Crack from the canal towards the root surface
 an Incomplete Crack from the root surface towards the canal
 A complete crack

Is there a dentinal crack present in the instrumented (Post-Op) sample not seen in the Pre-Op image?

- Yes
 No

Is there more than one crack seen in the Post-Op image?

- Yes
 No

For the longest crack seen in the Post-Op image, is the crack:

- an Incomplete Crack from the canal towards the root surface
 an Incomplete Crack from the root surface towards the canal
 A complete crack

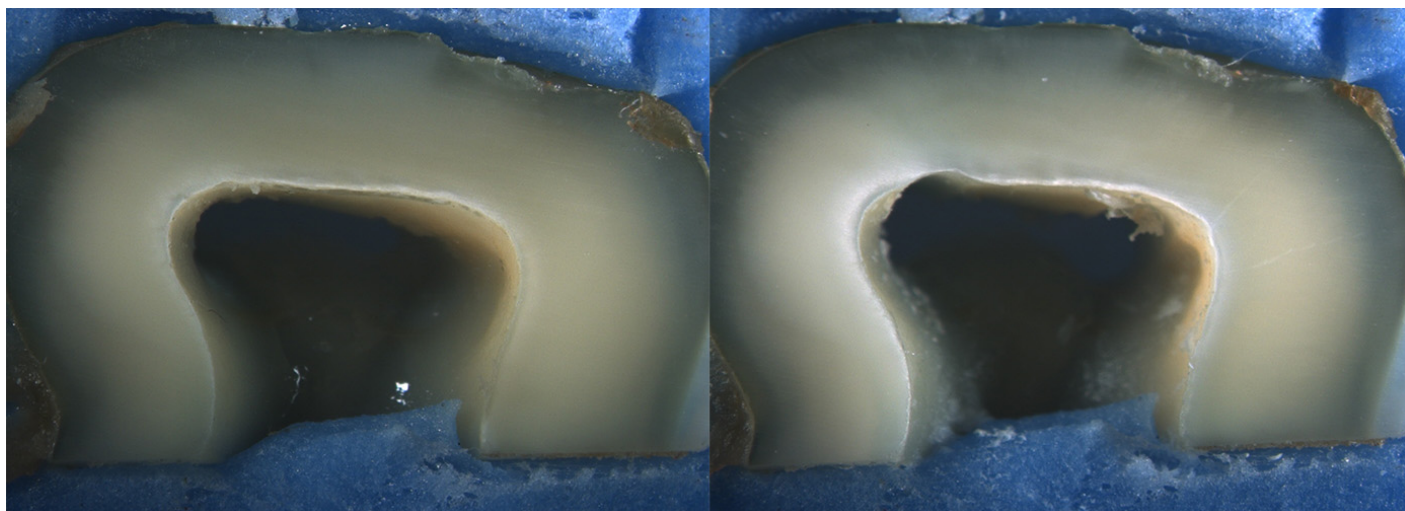
Is the crack seen in the Post-Op image:

- an Incomplete Crack from the canal towards the root surface
 an Incomplete Crack from the root surface towards the canal
 A complete crack

Done. Go to next page

Image: i099.jpg

Pre-Op on the left and Post-Op on the right



Is there any evidence of a dentinal crack prior to rotary instrumentation (Pre-Op)?

- Yes
 No

Does the crack in the Pre-Op image increase in size when viewed in the Post-Op image?

- Yes
 No

Is the crack that increased in the Pre-Op image now:

- an Incomplete Crack from the canal towards the root surface
 an Incomplete Crack from the root surface towards the canal
 A complete crack

Is there a new dentinal crack present in the instrumented (Post-Op) sample not seen in the Pre-Op image?

- Yes
 No

Is the new crack in the Post-Op image:

- an Incomplete Crack from the canal towards the root surface
 an Incomplete Crack from the root surface towards the canal
 A complete crack

Is there a dentinal crack present in the instrumented (Post-Op) sample not seen in the Pre-Op image?

- Yes
 No

Is there more than one crack seen in the Post-Op image?

- Yes
 No

For the longest crack seen in the Post-Op image, is the crack:

- an Incomplete Crack from the canal towards the root surface
 an Incomplete Crack from the root surface towards the canal
 A complete crack

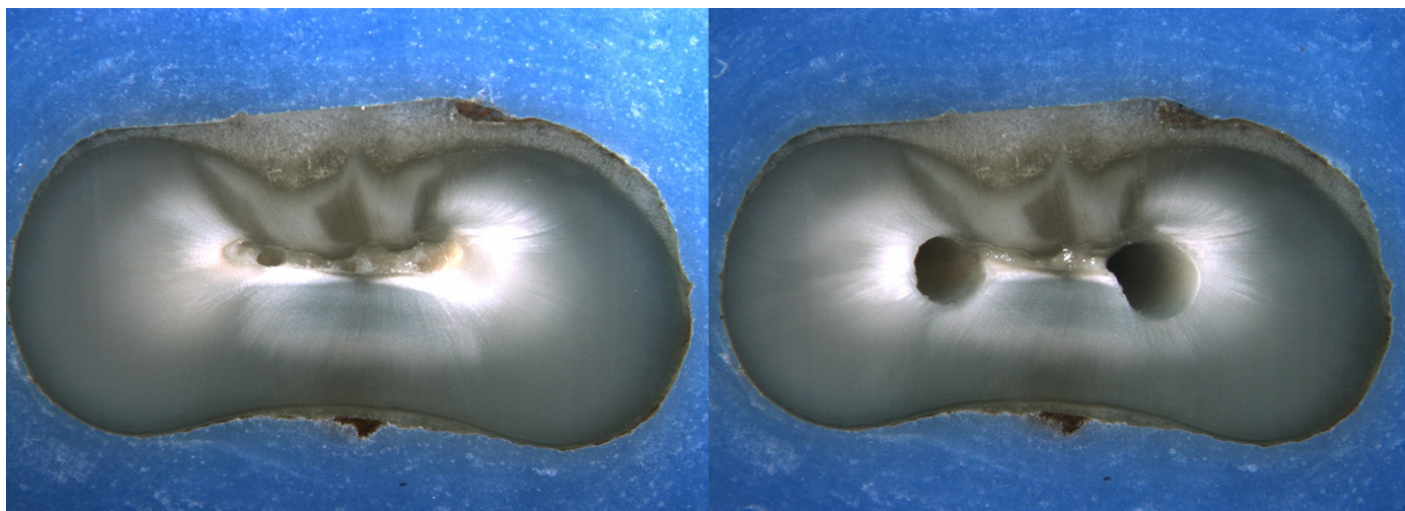
Is the crack seen in the Post-Op image:

- an Incomplete Crack from the canal towards the root surface
 an Incomplete Crack from the root surface towards the canal
 A complete crack

Done. Go to next page

Image: i100.jpg

Pre-Op on the left and Post-Op on the right



Is there any evidence of a dentinal crack prior to rotary instrumentation (Pre-Op)?

- Yes
 No

Does the crack in the Pre-Op image increase in size when viewed in the Post-Op image?

- Yes
 No

Is the crack that increased in the Pre-Op image now:

- an Incomplete Crack from the canal towards the root surface
 an Incomplete Crack from the root surface towards the canal
 A complete crack

Is there a new dentinal crack present in the instrumented (Post-Op) sample not seen in the Pre-Op image?

- Yes
 No

Is the new crack in the Post-Op image:

- an Incomplete Crack from the canal towards the root surface
 an Incomplete Crack from the root surface towards the canal
 A complete crack

Is there a dentinal crack present in the instrumented (Post-Op) sample not seen in the Pre-Op image?

- Yes
 No

Is there more than one crack seen in the Post-Op image?

- Yes
 No

For the longest crack seen in the Post-Op image, is the crack:

- an Incomplete Crack from the canal towards the root surface
 an Incomplete Crack from the root surface towards the canal
 A complete crack

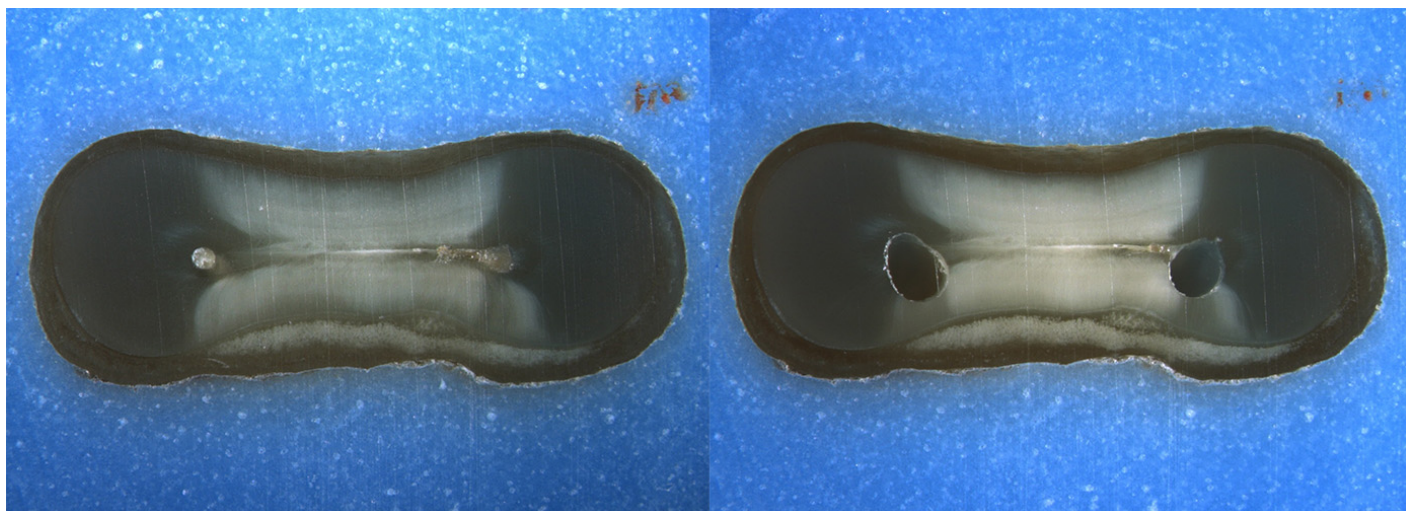
Is the crack seen in the Post-Op image:

- an Incomplete Crack from the canal towards the root surface
 an Incomplete Crack from the root surface towards the canal
 A complete crack

Done. Go to next page

Image: i101.jpg

Pre-Op on the left and Post-Op on the right



Is there any evidence of a dentinal crack prior to rotary instrumentation (Pre-Op)?

- Yes
 No

Does the crack in the Pre-Op image increase in size when viewed in the Post-Op image?

- Yes
 No

Is the crack that increased in the Pre-Op image now:

- an Incomplete Crack from the canal towards the root surface
 an Incomplete Crack from the root surface towards the canal
 A complete crack

Is there a new dentinal crack present in the instrumented (Post-Op) sample not seen in the Pre-Op image?

- Yes
 No

Is the new crack in the Post-Op image:

- an Incomplete Crack from the canal towards the root surface
 an Incomplete Crack from the root surface towards the canal
 A complete crack

Is there a dentinal crack present in the instrumented (Post-Op) sample not seen in the Pre-Op image?

- Yes
 No

Is there more than one crack seen in the Post-Op image?

- Yes
 No

For the longest crack seen in the Post-Op image, is the crack:

- an Incomplete Crack from the canal towards the root surface
 an Incomplete Crack from the root surface towards the canal
 A complete crack

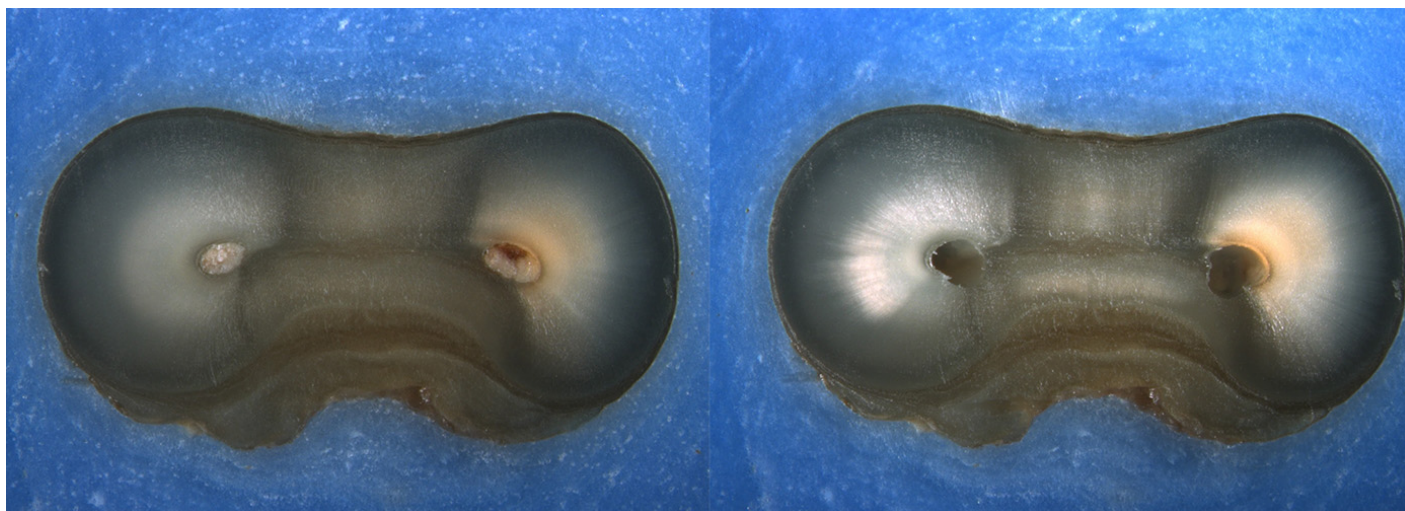
Is the crack seen in the Post-Op image:

- an Incomplete Crack from the canal towards the root surface
 an Incomplete Crack from the root surface towards the canal
 A complete crack

Done. Go to next page

Image: i102.jpg

Pre-Op on the left and Post-Op on the right



Is there any evidence of a dentinal crack prior to rotary instrumentation (Pre-Op)?

- Yes
 No

Does the crack in the Pre-Op image increase in size when viewed in the Post-Op image?

- Yes
 No

Is the crack that increased in the Pre-Op image now:

- an Incomplete Crack from the canal towards the root surface
 an Incomplete Crack from the root surface towards the canal
 A complete crack

Is there a new dentinal crack present in the instrumented (Post-Op) sample not seen in the Pre-Op image?

- Yes
 No

Is the new crack in the Post-Op image:

- an Incomplete Crack from the canal towards the root surface
 an Incomplete Crack from the root surface towards the canal
 A complete crack

Is there a dentinal crack present in the instrumented (Post-Op) sample not seen in the Pre-Op image?

- Yes
 No

Is there more than one crack seen in the Post-Op image?

- Yes
 No

For the longest crack seen in the Post-Op image, is the crack:

- an Incomplete Crack from the canal towards the root surface
 an Incomplete Crack from the root surface towards the canal
 A complete crack

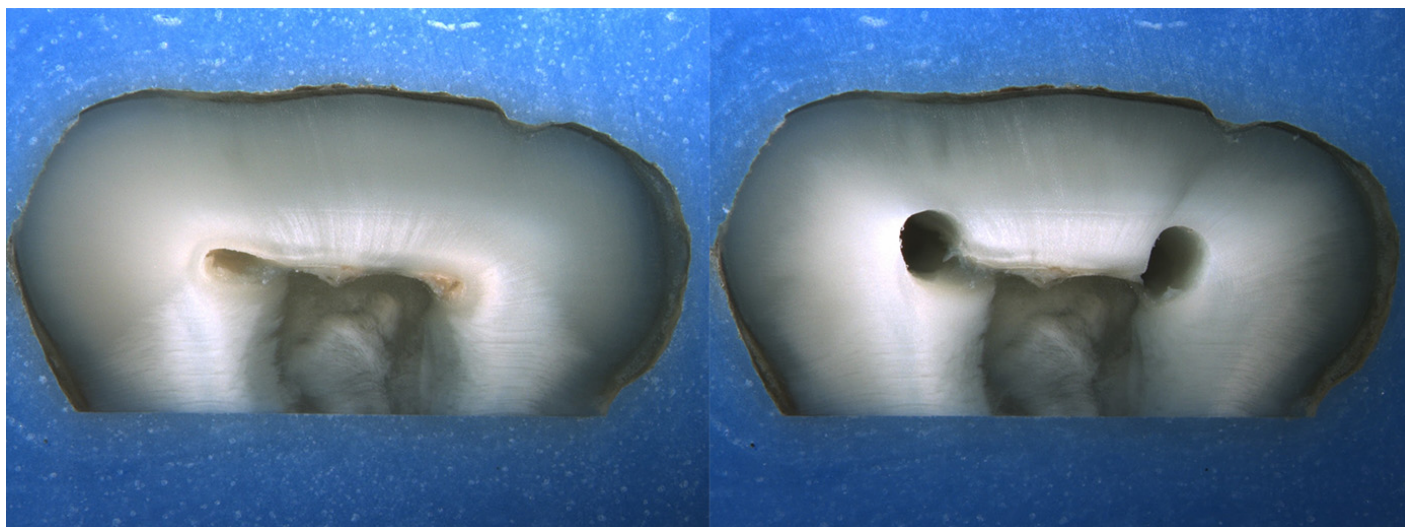
Is the crack seen in the Post-Op image:

- an Incomplete Crack from the canal towards the root surface
 an Incomplete Crack from the root surface towards the canal
 A complete crack

Done. Go to next page

Image: i103.jpg

Pre-Op on the left and Post-Op on the right



Is there any evidence of a dentinal crack prior to rotary instrumentation (Pre-Op)?

- Yes
 No

Does the crack in the Pre-Op image increase in size when viewed in the Post-Op image?

- Yes
 No

Is the crack that increased in the Pre-Op image now:

- an Incomplete Crack from the canal towards the root surface
 an Incomplete Crack from the root surface towards the canal
 A complete crack

Is there a new dentinal crack present in the instrumented (Post-Op) sample not seen in the Pre-Op image?

- Yes
 No

Is the new crack in the Post-Op image:

- an Incomplete Crack from the canal towards the root surface
 an Incomplete Crack from the root surface towards the canal
 A complete crack

Is there a dentinal crack present in the instrumented (Post-Op) sample not seen in the Pre-Op image?

- Yes
 No

Is there more than one crack seen in the Post-Op image?

- Yes
 No

For the longest crack seen in the Post-Op image, is the crack:

- an Incomplete Crack from the canal towards the root surface
 an Incomplete Crack from the root surface towards the canal
 A complete crack

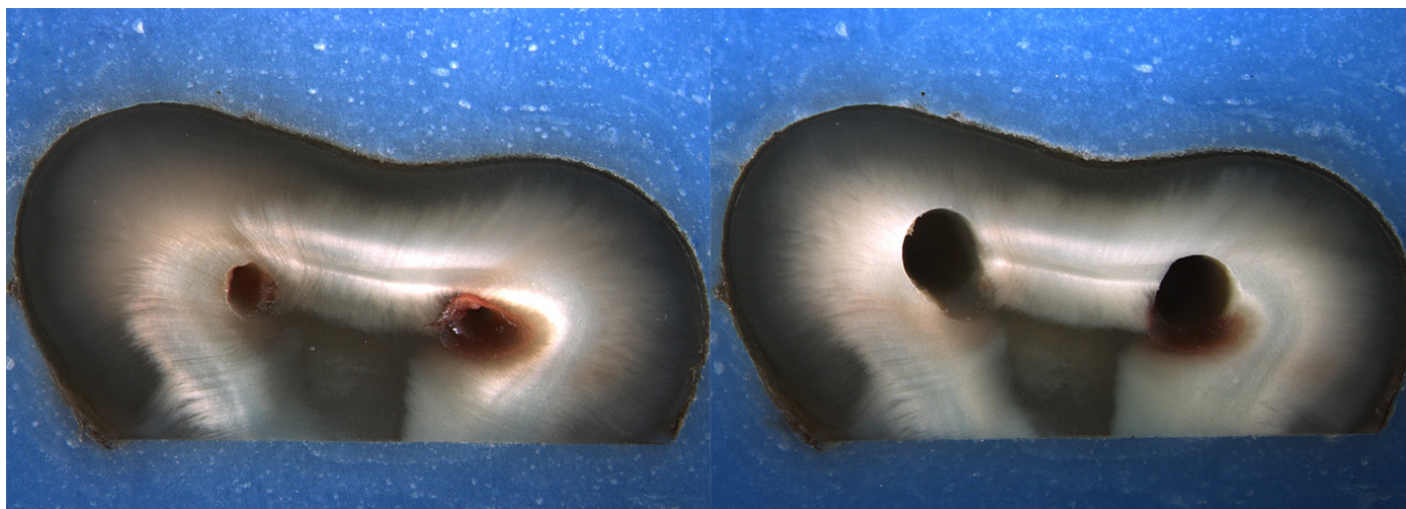
Is the crack seen in the Post-Op image:

- an Incomplete Crack from the canal towards the root surface
 an Incomplete Crack from the root surface towards the canal
 A complete crack

Done. Go to next page

Image: i104.jpg

Pre-Op on the left and Post-Op on the right



Is there any evidence of a dentinal crack prior to rotary instrumentation (Pre-Op)?

- Yes
 No

Does the crack in the Pre-Op image increase in size when viewed in the Post-Op image?

- Yes
 No

Is the crack that increased in the Pre-Op image now:

- an Incomplete Crack from the canal towards the root surface
 an Incomplete Crack from the root surface towards the canal
 A complete crack

Is there a new dentinal crack present in the instrumented (Post-Op) sample not seen in the Pre-Op image?

- Yes
 No

Is the new crack in the Post-Op image:

- an Incomplete Crack from the canal towards the root surface
 an Incomplete Crack from the root surface towards the canal
 A complete crack

Is there a dentinal crack present in the instrumented (Post-Op) sample not seen in the Pre-Op image?

- Yes
 No

Is there more than one crack seen in the Post-Op image?

- Yes
 No

For the longest crack seen in the Post-Op image, is the crack:

- an Incomplete Crack from the canal towards the root surface
 an Incomplete Crack from the root surface towards the canal
 A complete crack

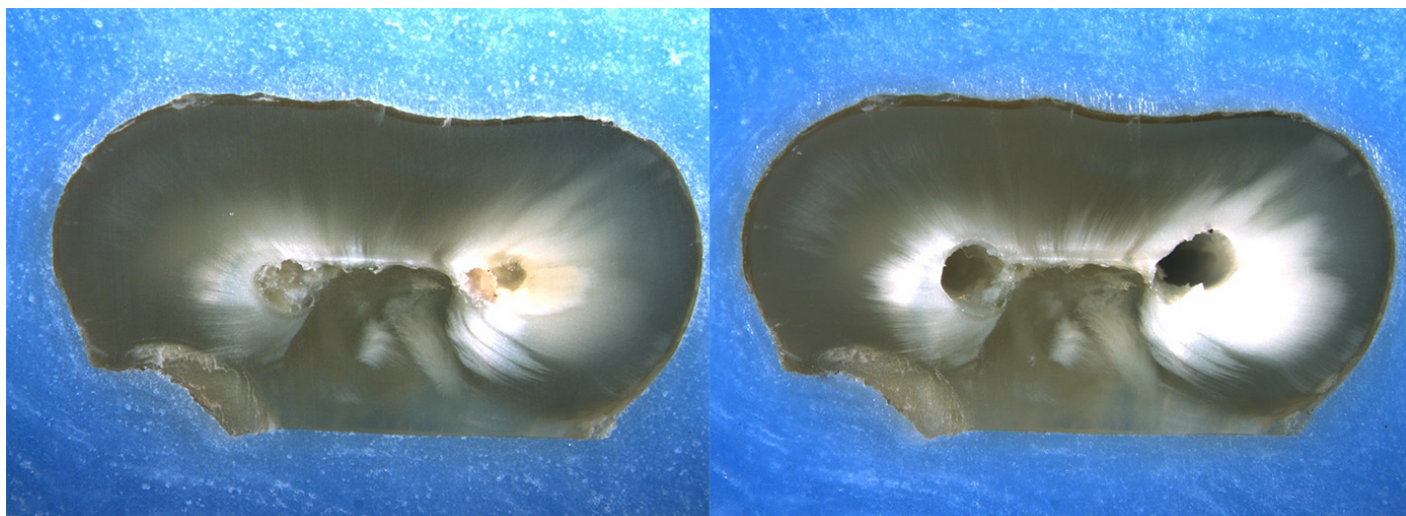
Is the crack seen in the Post-Op image:

- an Incomplete Crack from the canal towards the root surface
 an Incomplete Crack from the root surface towards the canal
 A complete crack

Done. Go to next page

Image: i105.jpg

Pre-Op on the left and Post-Op on the right



Is there any evidence of a dentinal crack prior to rotary instrumentation (Pre-Op)?

- Yes
 No

Does the crack in the Pre-Op image increase in size when viewed in the Post-Op image?

- Yes
 No

Is the crack that increased in the Pre-Op image now:

- an Incomplete Crack from the canal towards the root surface
 an Incomplete Crack from the root surface towards the canal
 A complete crack

Is there a new dentinal crack present in the instrumented (Post-Op) sample not seen in the Pre-Op image?

- Yes
 No

Is the new crack in the Post-Op image:

- an Incomplete Crack from the canal towards the root surface
 an Incomplete Crack from the root surface towards the canal
 A complete crack

Is there a dentinal crack present in the instrumented (Post-Op) sample not seen in the Pre-Op image?

- Yes
 No

Is there more than one crack seen in the Post-Op image?

- Yes
 No

For the longest crack seen in the Post-Op image, is the crack:

- an Incomplete Crack from the canal towards the root surface
 an Incomplete Crack from the root surface towards the canal
 A complete crack

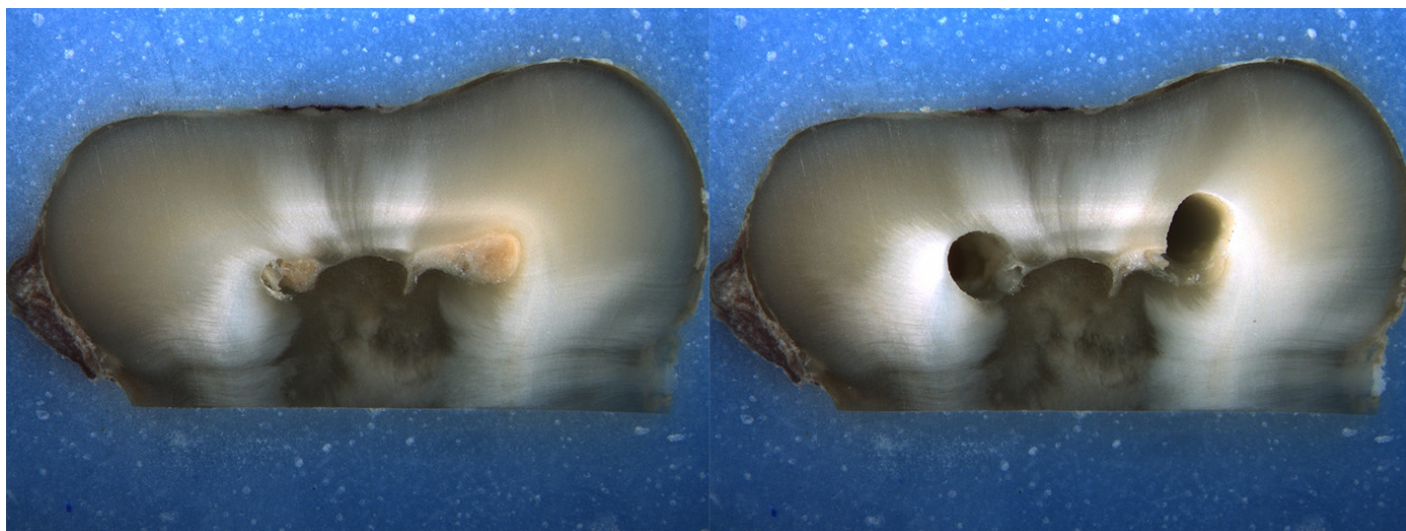
Is the crack seen in the Post-Op image:

- an Incomplete Crack from the canal towards the root surface
 an Incomplete Crack from the root surface towards the canal
 A complete crack

Done. Go to next page

Image: i106.jpg

Pre-Op on the left and Post-Op on the right



Is there any evidence of a dentinal crack prior to rotary instrumentation (Pre-Op)?

- Yes
 No

Does the crack in the Pre-Op image increase in size when viewed in the Post-Op image?

- Yes
 No

Is the crack that increased in the Pre-Op image now:

- an Incomplete Crack from the canal towards the root surface
 an Incomplete Crack from the root surface towards the canal
 A complete crack

Is there a new dentinal crack present in the instrumented (Post-Op) sample not seen in the Pre-Op image?

- Yes
 No

Is the new crack in the Post-Op image:

- an Incomplete Crack from the canal towards the root surface
 an Incomplete Crack from the root surface towards the canal
 A complete crack

Is there a dentinal crack present in the instrumented (Post-Op) sample not seen in the Pre-Op image?

- Yes
 No

Is there more than one crack seen in the Post-Op image?

- Yes
 No

For the longest crack seen in the Post-Op image, is the crack:

- an Incomplete Crack from the canal towards the root surface
 an Incomplete Crack from the root surface towards the canal
 A complete crack


Is the crack seen in the Post-Op image:

- an Incomplete Crack from the canal towards the root surface
 an Incomplete Crack from the root surface towards the canal
 A complete crack

Done. Go to next page

Image: i107.jpg

Pre-Op on the left and Post-Op on the right



Is there any evidence of a dentinal crack prior to rotary instrumentation (Pre-Op)?

- Yes
 No

Does the crack in the Pre-Op image increase in size when viewed in the Post-Op image?

- Yes
 No

Is the crack that increased in the Pre-Op image now:

- an Incomplete Crack from the canal towards the root surface
 an Incomplete Crack from the root surface towards the canal
 A complete crack

Is there a new dentinal crack present in the instrumented (Post-Op) sample not seen in the Pre-Op image?

- Yes
 No

Is the new crack in the Post-Op image:

- an Incomplete Crack from the canal towards the root surface
 an Incomplete Crack from the root surface towards the canal
 A complete crack

Is there a dentinal crack present in the instrumented (Post-Op) sample not seen in the Pre-Op image?

- Yes
 No

Is there more than one crack seen in the Post-Op image?

- Yes
 No

For the longest crack seen in the Post-Op image, is the crack:

- an Incomplete Crack from the canal towards the root surface
 an Incomplete Crack from the root surface towards the canal
 A complete crack

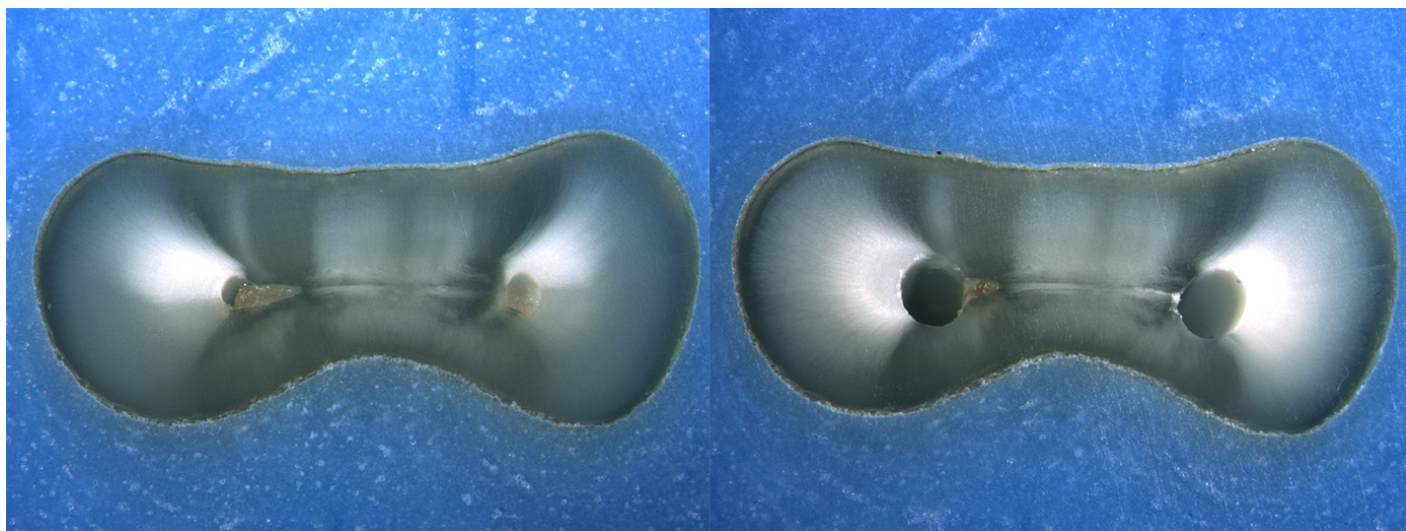
Is the crack seen in the Post-Op image:

- an Incomplete Crack from the canal towards the root surface
 an Incomplete Crack from the root surface towards the canal
 A complete crack

Done. Go to next page

Image: i108.jpg

Pre-Op on the left and Post-Op on the right



Is there any evidence of a dentinal crack prior to rotary instrumentation (Pre-Op)?

- Yes
 No

Does the crack in the Pre-Op image increase in size when viewed in the Post-Op image?

- Yes
 No

Is the crack that increased in the Pre-Op image now:

- an Incomplete Crack from the canal towards the root surface
 an Incomplete Crack from the root surface towards the canal
 A complete crack

Is there a new dentinal crack present in the instrumented (Post-Op) sample not seen in the Pre-Op image?

- Yes
 No

Is the new crack in the Post-Op image:

- an Incomplete Crack from the canal towards the root surface
 an Incomplete Crack from the root surface towards the canal
 A complete crack

Is there a dentinal crack present in the instrumented (Post-Op) sample not seen in the Pre-Op image?

- Yes
 No

Is there more than one crack seen in the Post-Op image?

- Yes
 No

For the longest crack seen in the Post-Op image, is the crack:

- an Incomplete Crack from the canal towards the root surface
 an Incomplete Crack from the root surface towards the canal
 A complete crack

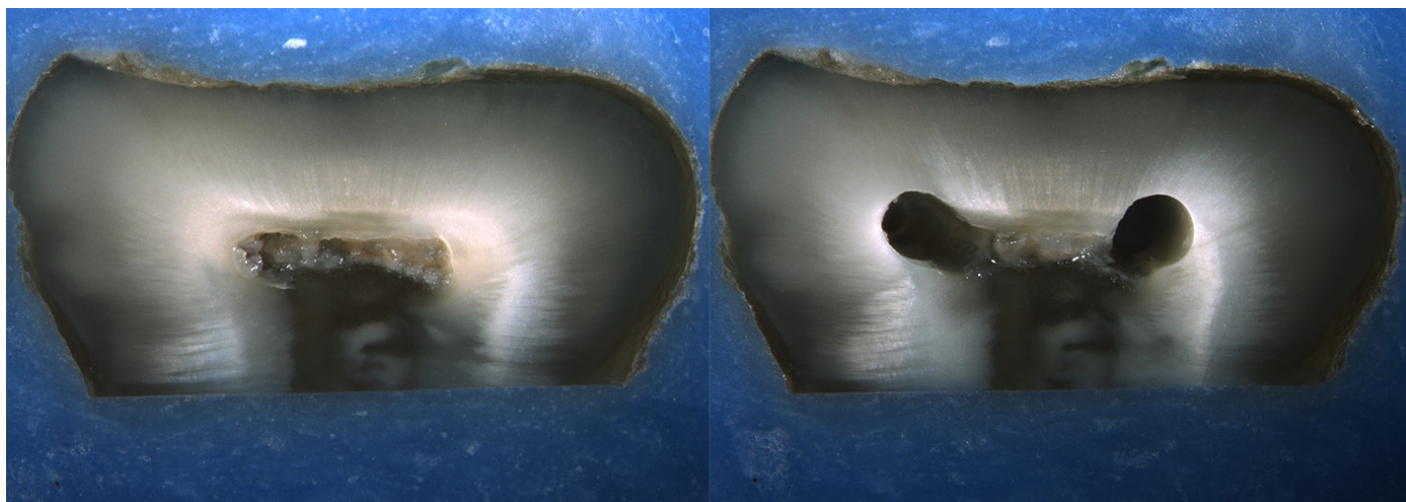
Is the crack seen in the Post-Op image:

- an Incomplete Crack from the canal towards the root surface
 an Incomplete Crack from the root surface towards the canal
 A complete crack

Done. Go to next page

Image: i109.jpg

Pre-Op on the left and Post-Op on the right



Is there any evidence of a dentinal crack prior to rotary instrumentation (Pre-Op)?

- Yes
 No

Does the crack in the Pre-Op image increase in size when viewed in the Post-Op image?

- Yes
 No

Is the crack that increased in the Pre-Op image now:

- an Incomplete Crack from the canal towards the root surface
 an Incomplete Crack from the root surface towards the canal
 A complete crack

Is there a new dentinal crack present in the instrumented (Post-Op) sample not seen in the Pre-Op image?

- Yes
 No

Is the new crack in the Post-Op image:

- an Incomplete Crack from the canal towards the root surface
 an Incomplete Crack from the root surface towards the canal
 A complete crack

Is there a dentinal crack present in the instrumented (Post-Op) sample not seen in the Pre-Op image?

- Yes
 No

Is there more than one crack seen in the Post-Op image?

- Yes
 No

For the longest crack seen in the Post-Op image, is the crack:

- an Incomplete Crack from the canal towards the root surface
 an Incomplete Crack from the root surface towards the canal
 A complete crack


Is the crack seen in the Post-Op image:

- an Incomplete Crack from the canal towards the root surface
 an Incomplete Crack from the root surface towards the canal
 A complete crack

Done. Go to next page

Image: i110.jpg

Pre-Op on the left and Post-Op on the right



Is there any evidence of a dentinal crack prior to rotary instrumentation (Pre-Op)?

- Yes
 No

Does the crack in the Pre-Op image increase in size when viewed in the Post-Op image?

- Yes
 No

Is the crack that increased in the Pre-Op image now:

- an Incomplete Crack from the canal towards the root surface
 an Incomplete Crack from the root surface towards the canal
 A complete crack

Is there a new dentinal crack present in the instrumented (Post-Op) sample not seen in the Pre-Op image?

- Yes
 No

Is the new crack in the Post-Op image:

- an Incomplete Crack from the canal towards the root surface
 an Incomplete Crack from the root surface towards the canal
 A complete crack

Is there a dentinal crack present in the instrumented (Post-Op) sample not seen in the Pre-Op image?

- Yes
 No

Is there more than one crack seen in the Post-Op image?

- Yes
 No

For the longest crack seen in the Post-Op image, is the crack:

- an Incomplete Crack from the canal towards the root surface
 an Incomplete Crack from the root surface towards the canal
 A complete crack

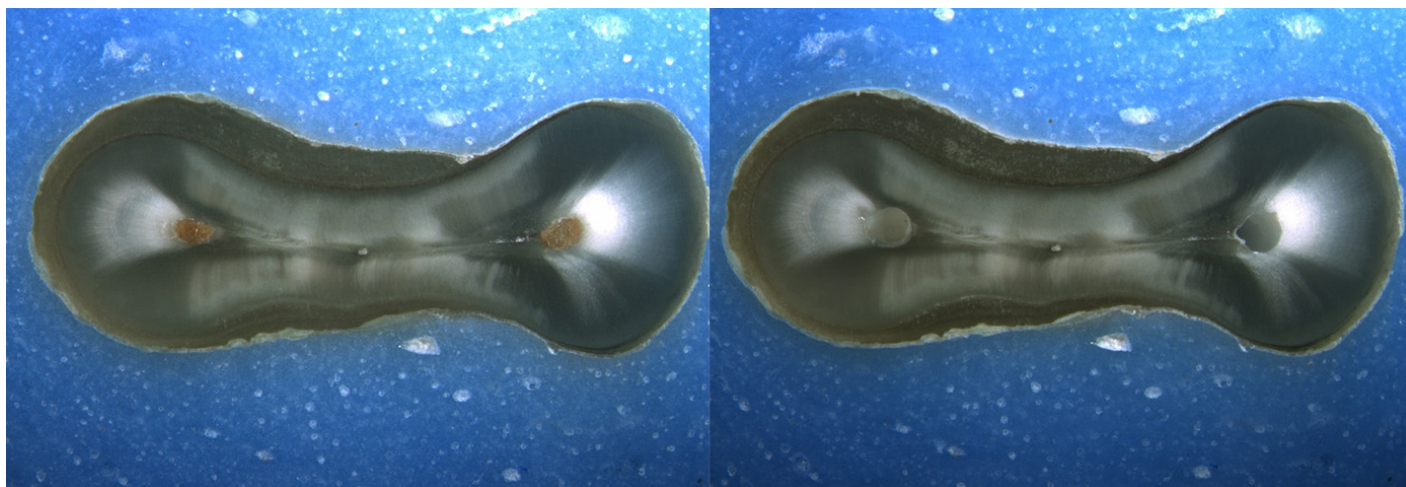
Is the crack seen in the Post-Op image:

- an Incomplete Crack from the canal towards the root surface
 an Incomplete Crack from the root surface towards the canal
 A complete crack

Done. Go to next page

Image: i111.jpg

Pre-Op on the left and Post-Op on the right



Is there any evidence of a dentinal crack prior to rotary instrumentation (Pre-Op)?

- Yes
 No

Does the crack in the Pre-Op image increase in size when viewed in the Post-Op image?

- Yes
 No

Is the crack that increased in the Pre-Op image now:

- an Incomplete Crack from the canal towards the root surface
 an Incomplete Crack from the root surface towards the canal
 A complete crack

Is there a new dentinal crack present in the instrumented (Post-Op) sample not seen in the Pre-Op image?

- Yes
 No

Is the new crack in the Post-Op image:

- an Incomplete Crack from the canal towards the root surface
 an Incomplete Crack from the root surface towards the canal
 A complete crack

Is there a dentinal crack present in the instrumented (Post-Op) sample not seen in the Pre-Op image?

- Yes
 No

Is there more than one crack seen in the Post-Op image?

- Yes
 No

For the longest crack seen in the Post-Op image, is the crack:

- an Incomplete Crack from the canal towards the root surface
 an Incomplete Crack from the root surface towards the canal
 A complete crack

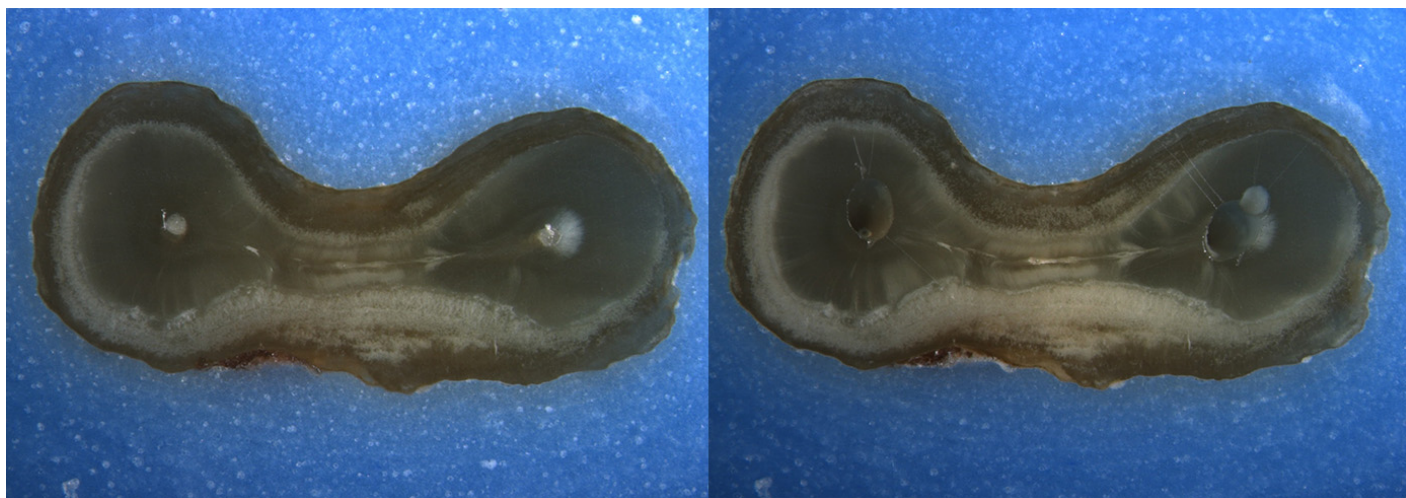
Is the crack seen in the Post-Op image:

- an Incomplete Crack from the canal towards the root surface
 an Incomplete Crack from the root surface towards the canal
 A complete crack

Done. Go to next page

Image: i112.jpg

Pre-Op on the left and Post-Op on the right



Is there any evidence of a dentinal crack prior to rotary instrumentation (Pre-Op)?

- Yes
 No

Does the crack in the Pre-Op image increase in size when viewed in the Post-Op image?

- Yes
 No

Is the crack that increased in the Pre-Op image now:

- an Incomplete Crack from the canal towards the root surface
 an Incomplete Crack from the root surface towards the canal
 A complete crack

Is there a new dentinal crack present in the instrumented (Post-Op) sample not seen in the Pre-Op image?

- Yes
 No

Is the new crack in the Post-Op image:

- an Incomplete Crack from the canal towards the root surface
 an Incomplete Crack from the root surface towards the canal
 A complete crack

Is there a dentinal crack present in the instrumented (Post-Op) sample not seen in the Pre-Op image?

- Yes
 No

Is there more than one crack seen in the Post-Op image?

- Yes
 No

For the longest crack seen in the Post-Op image, is the crack:

- an Incomplete Crack from the canal towards the root surface
 an Incomplete Crack from the root surface towards the canal
 A complete crack

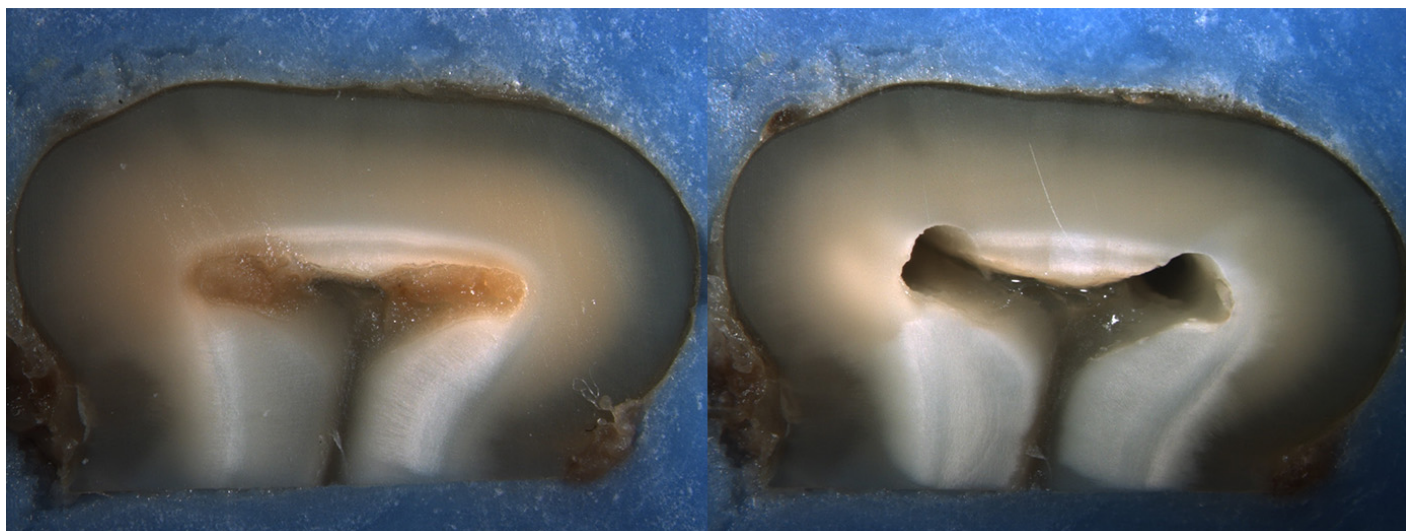
Is the crack seen in the Post-Op image:

- an Incomplete Crack from the canal towards the root surface
 an Incomplete Crack from the root surface towards the canal
 A complete crack

Done. Go to next page

Image: i113.jpg

Pre-Op on the left and Post-Op on the right



Is there any evidence of a dentinal crack prior to rotary instrumentation (Pre-Op)?

- Yes
 No

Does the crack in the Pre-Op image increase in size when viewed in the Post-Op image?

- Yes
 No

Is the crack that increased in the Pre-Op image now:

- an Incomplete Crack from the canal towards the root surface
 an Incomplete Crack from the root surface towards the canal
 A complete crack

Is there a new dentinal crack present in the instrumented (Post-Op) sample not seen in the Pre-Op image?

- Yes
 No

Is the new crack in the Post-Op image:

- an Incomplete Crack from the canal towards the root surface
 an Incomplete Crack from the root surface towards the canal
 A complete crack

Is there a dentinal crack present in the instrumented (Post-Op) sample not seen in the Pre-Op image?

- Yes
 No

Is there more than one crack seen in the Post-Op image?

- Yes
 No

For the longest crack seen in the Post-Op image, is the crack:

- an Incomplete Crack from the canal towards the root surface
 an Incomplete Crack from the root surface towards the canal
 A complete crack

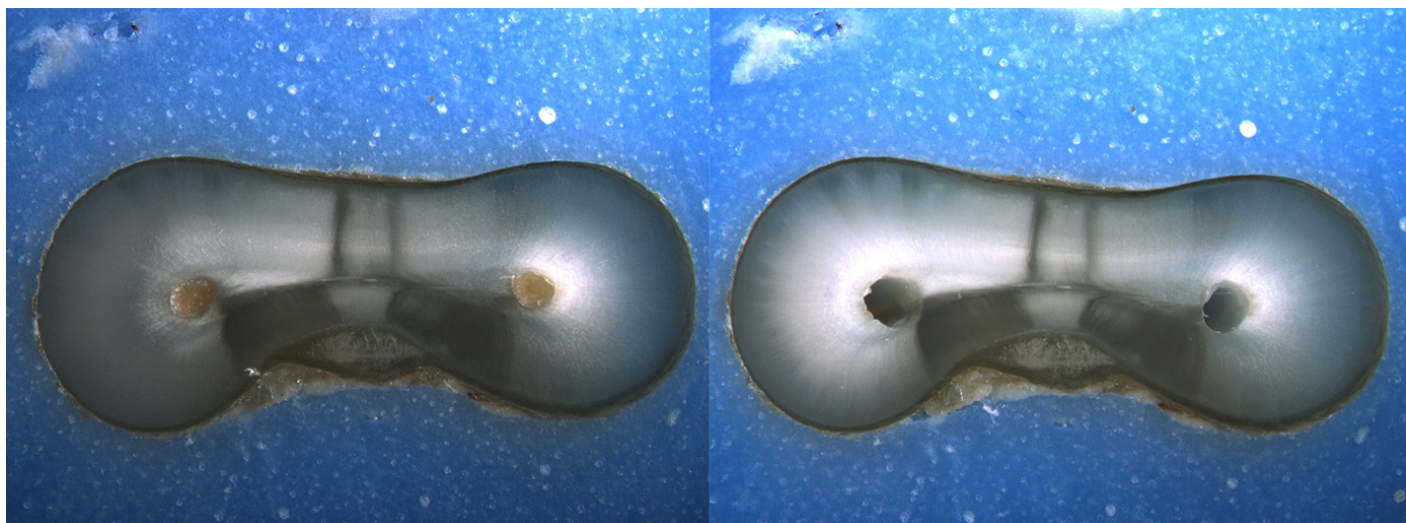
Is the crack seen in the Post-Op image:

- an Incomplete Crack from the canal towards the root surface
 an Incomplete Crack from the root surface towards the canal
 A complete crack

Done. Go to next page

Image: i114.jpg

Pre-Op on the left and Post-Op on the right



Is there any evidence of a dentinal crack prior to rotary instrumentation (Pre-Op)?

- Yes
 No

Does the crack in the Pre-Op image increase in size when viewed in the Post-Op image?

- Yes
 No

Is the crack that increased in the Pre-Op image now:

- an Incomplete Crack from the canal towards the root surface
 an Incomplete Crack from the root surface towards the canal
 A complete crack

Is there a new dentinal crack present in the instrumented (Post-Op) sample not seen in the Pre-Op image?

- Yes
 No

Is the new crack in the Post-Op image:

- an Incomplete Crack from the canal towards the root surface
 an Incomplete Crack from the root surface towards the canal
 A complete crack

Is there a dentinal crack present in the instrumented (Post-Op) sample not seen in the Pre-Op image?

- Yes
 No

Is there more than one crack seen in the Post-Op image?

- Yes
 No

For the longest crack seen in the Post-Op image, is the crack:

- an Incomplete Crack from the canal towards the root surface
 an Incomplete Crack from the root surface towards the canal
 A complete crack

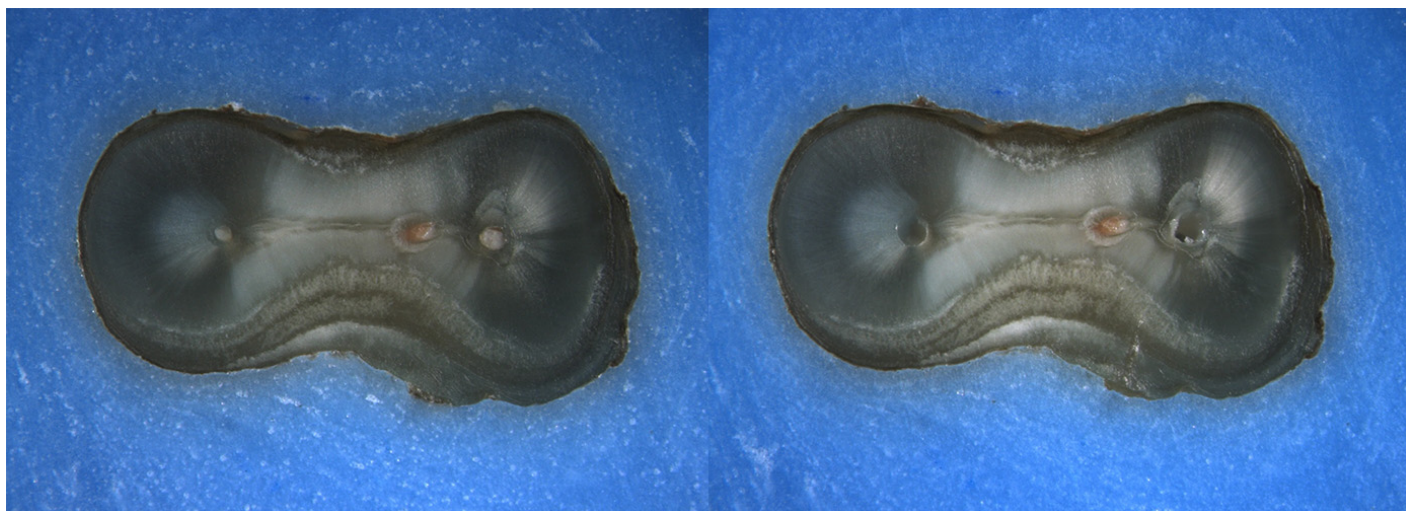
Is the crack seen in the Post-Op image:

- an Incomplete Crack from the canal towards the root surface
 an Incomplete Crack from the root surface towards the canal
 A complete crack

Done. Go to next page

Image: i115.jpg

Pre-Op on the left and Post-Op on the right



Is there any evidence of a dentinal crack prior to rotary instrumentation (Pre-Op)?

- Yes
 No

Does the crack in the Pre-Op image increase in size when viewed in the Post-Op image?

- Yes
 No

Is the crack that increased in the Pre-Op image now:

- an Incomplete Crack from the canal towards the root surface
 an Incomplete Crack from the root surface towards the canal
 A complete crack

Is there a new dentinal crack present in the instrumented (Post-Op) sample not seen in the Pre-Op image?

- Yes
 No

Is the new crack in the Post-Op image:

- an Incomplete Crack from the canal towards the root surface
 an Incomplete Crack from the root surface towards the canal
 A complete crack

Is there a dentinal crack present in the instrumented (Post-Op) sample not seen in the Pre-Op image?

- Yes
 No

Is there more than one crack seen in the Post-Op image?

- Yes
 No

For the longest crack seen in the Post-Op image, is the crack:

- an Incomplete Crack from the canal towards the root surface
 an Incomplete Crack from the root surface towards the canal
 A complete crack

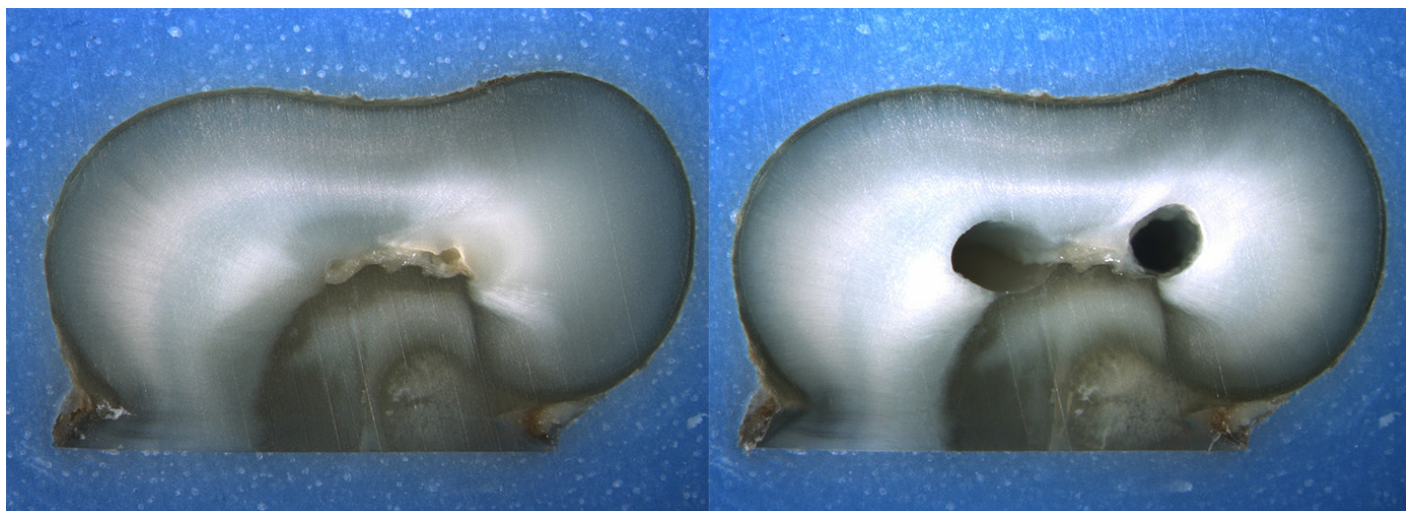
Is the crack seen in the Post-Op image:

- an Incomplete Crack from the canal towards the root surface
 an Incomplete Crack from the root surface towards the canal
 A complete crack

Done. Go to next page

Image: i116.jpg

Pre-Op on the left and Post-Op on the right



Is there any evidence of a dentinal crack prior to rotary instrumentation (Pre-Op)?

- Yes
 No

Does the crack in the Pre-Op image increase in size when viewed in the Post-Op image?

- Yes
 No

Is the crack that increased in the Pre-Op image now:

- an Incomplete Crack from the canal towards the root surface
 an Incomplete Crack from the root surface towards the canal
 A complete crack

Is there a new dentinal crack present in the instrumented (Post-Op) sample not seen in the Pre-Op image?

- Yes
 No

Is the new crack in the Post-Op image:

- an Incomplete Crack from the canal towards the root surface
 an Incomplete Crack from the root surface towards the canal
 A complete crack

Is there a dentinal crack present in the instrumented (Post-Op) sample not seen in the Pre-Op image?

- Yes
 No

Is there more than one crack seen in the Post-Op image?

- Yes
 No

For the longest crack seen in the Post-Op image, is the crack:

- an Incomplete Crack from the canal towards the root surface
 an Incomplete Crack from the root surface towards the canal
 A complete crack

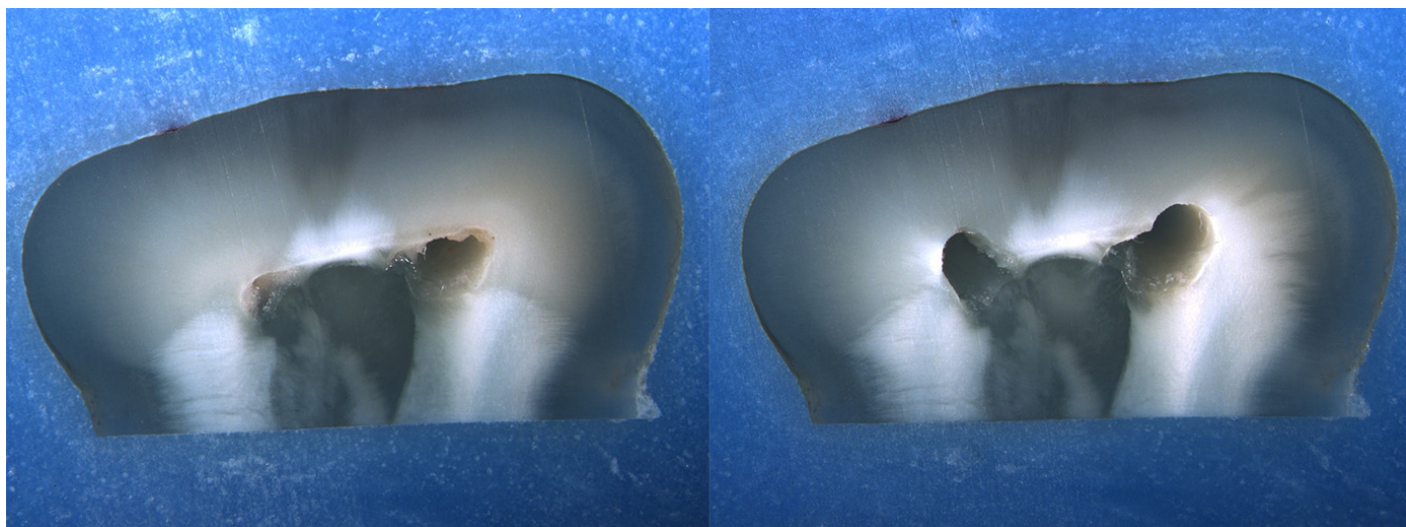
Is the crack seen in the Post-Op image:

- an Incomplete Crack from the canal towards the root surface
 an Incomplete Crack from the root surface towards the canal
 A complete crack

Done. Go to next page

Image: i117.jpg

Pre-Op on the left and Post-Op on the right



Is there any evidence of a dentinal crack prior to rotary instrumentation (Pre-Op)?

- Yes
 No

Does the crack in the Pre-Op image increase in size when viewed in the Post-Op image?

- Yes
 No

Is the crack that increased in the Pre-Op image now:

- an Incomplete Crack from the canal towards the root surface
 an Incomplete Crack from the root surface towards the canal
 A complete crack

Is there a new dentinal crack present in the instrumented (Post-Op) sample not seen in the Pre-Op image?

- Yes
 No

Is the new crack in the Post-Op image:

- an Incomplete Crack from the canal towards the root surface
 an Incomplete Crack from the root surface towards the canal
 A complete crack

Is there a dentinal crack present in the instrumented (Post-Op) sample not seen in the Pre-Op image?

- Yes
 No

Is there more than one crack seen in the Post-Op image?

- Yes
 No

For the longest crack seen in the Post-Op image, is the crack:

- an Incomplete Crack from the canal towards the root surface
 an Incomplete Crack from the root surface towards the canal
 A complete crack

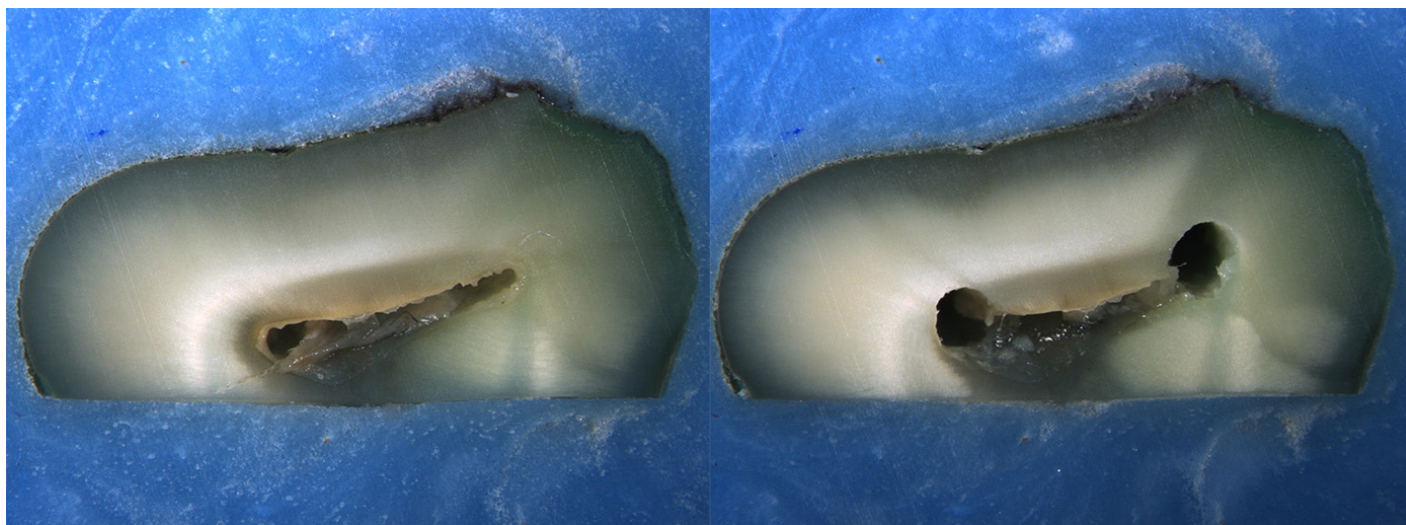
Is the crack seen in the Post-Op image:

- an Incomplete Crack from the canal towards the root surface
 an Incomplete Crack from the root surface towards the canal
 A complete crack

Done. Go to next page

Image: i118.jpg

Pre-Op on the left and Post-Op on the right



Is there any evidence of a dentinal crack prior to rotary instrumentation (Pre-Op)?

- Yes
 No

Does the crack in the Pre-Op image increase in size when viewed in the Post-Op image?

- Yes
 No

Is the crack that increased in the Pre-Op image now:

- an Incomplete Crack from the canal towards the root surface
 an Incomplete Crack from the root surface towards the canal
 A complete crack

Is there a new dentinal crack present in the instrumented (Post-Op) sample not seen in the Pre-Op image?

- Yes
 No

Is the new crack in the Post-Op image:

- an Incomplete Crack from the canal towards the root surface
 an Incomplete Crack from the root surface towards the canal
 A complete crack

Is there a dentinal crack present in the instrumented (Post-Op) sample not seen in the Pre-Op image?

- Yes
 No

Is there more than one crack seen in the Post-Op image?

- Yes
 No

For the longest crack seen in the Post-Op image, is the crack:

- an Incomplete Crack from the canal towards the root surface
 an Incomplete Crack from the root surface towards the canal
 A complete crack

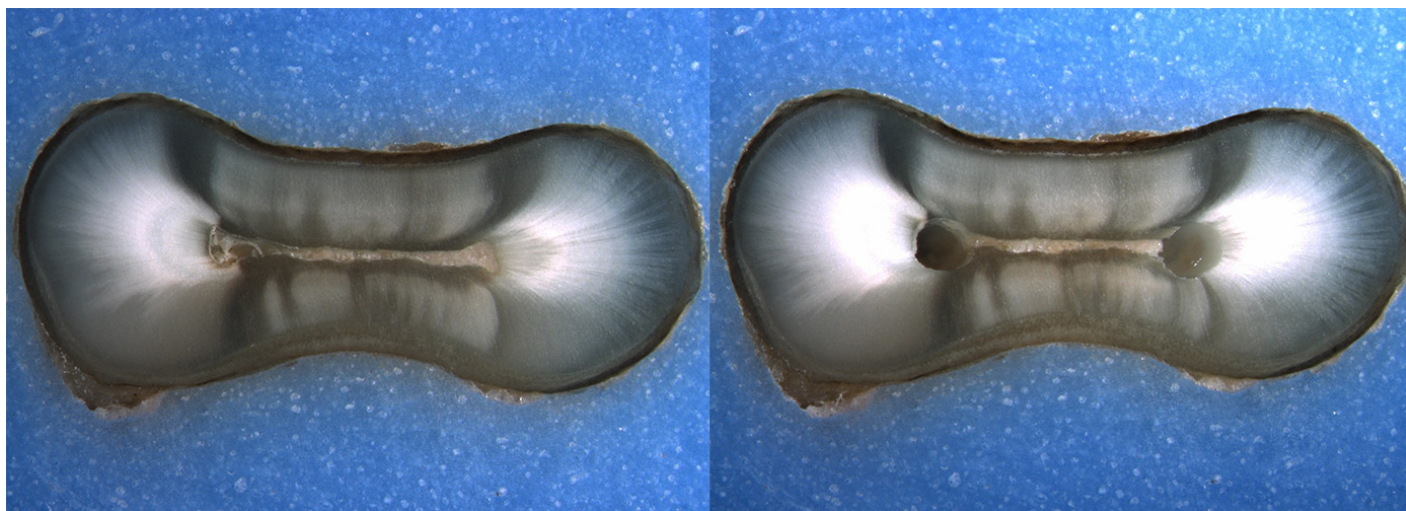
Is the crack seen in the Post-Op image:

- an Incomplete Crack from the canal towards the root surface
 an Incomplete Crack from the root surface towards the canal
 A complete crack

Done. Go to next page

Image: i119.jpg

Pre-Op on the left and Post-Op on the right



Is there any evidence of a dentinal crack prior to rotary instrumentation (Pre-Op)?

- Yes
 No

Does the crack in the Pre-Op image increase in size when viewed in the Post-Op image?

- Yes
 No

Is the crack that increased in the Pre-Op image now:

- an Incomplete Crack from the canal towards the root surface
 an Incomplete Crack from the root surface towards the canal
 A complete crack

Is there a new dentinal crack present in the instrumented (Post-Op) sample not seen in the Pre-Op image?

- Yes
 No

Is the new crack in the Post-Op image:

- an Incomplete Crack from the canal towards the root surface
 an Incomplete Crack from the root surface towards the canal
 A complete crack

Is there a dentinal crack present in the instrumented (Post-Op) sample not seen in the Pre-Op image?

- Yes
 No

Is there more than one crack seen in the Post-Op image?

- Yes
 No

For the longest crack seen in the Post-Op image, is the crack:

- an Incomplete Crack from the canal towards the root surface
 an Incomplete Crack from the root surface towards the canal
 A complete crack

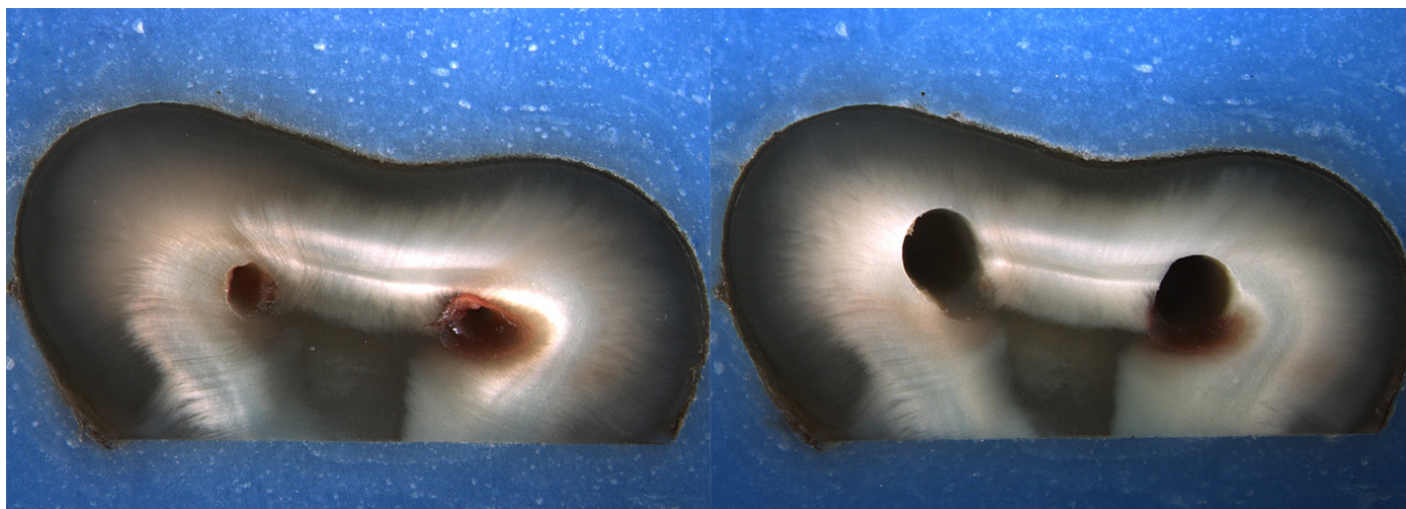
Is the crack seen in the Post-Op image:

- an Incomplete Crack from the canal towards the root surface
 an Incomplete Crack from the root surface towards the canal
 A complete crack

Done. Go to next page

Image: i120.jpg

Pre-Op on the left and Post-Op on the right



Is there any evidence of a dentinal crack prior to rotary instrumentation (Pre-Op)?

- Yes
 No

Does the crack in the Pre-Op image increase in size when viewed in the Post-Op image?

- Yes
 No

Is the crack that increased in the Pre-Op image now:

- an Incomplete Crack from the canal towards the root surface
 an Incomplete Crack from the root surface towards the canal
 A complete crack

Is there a new dentinal crack present in the instrumented (Post-Op) sample not seen in the Pre-Op image?

- Yes
 No

Is the new crack in the Post-Op image:

- an Incomplete Crack from the canal towards the root surface
 an Incomplete Crack from the root surface towards the canal
 A complete crack

Is there a dentinal crack present in the instrumented (Post-Op) sample not seen in the Pre-Op image?

- Yes
 No

Is there more than one crack seen in the Post-Op image?

- Yes
 No

For the longest crack seen in the Post-Op image, is the crack:

- an Incomplete Crack from the canal towards the root surface
 an Incomplete Crack from the root surface towards the canal
 A complete crack

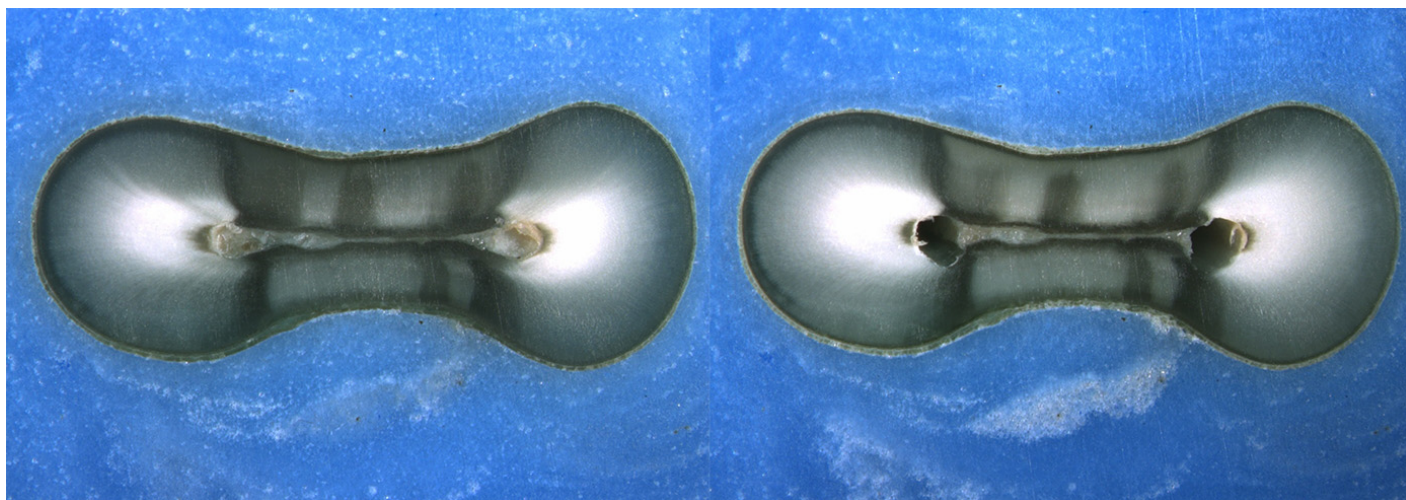
Is the crack seen in the Post-Op image:

- an Incomplete Crack from the canal towards the root surface
 an Incomplete Crack from the root surface towards the canal
 A complete crack

Done. Go to next page

Image: i121.jpg

Pre-Op on the left and Post-Op on the right



Is there any evidence of a dentinal crack prior to rotary instrumentation (Pre-Op)?

- Yes
 No

Does the crack in the Pre-Op image increase in size when viewed in the Post-Op image?

- Yes
 No

Is the crack that increased in the Pre-Op image now:

- an Incomplete Crack from the canal towards the root surface
 an Incomplete Crack from the root surface towards the canal
 A complete crack

Is there a new dentinal crack present in the instrumented (Post-Op) sample not seen in the Pre-Op image?

- Yes
 No

Is the new crack in the Post-Op image:

- an Incomplete Crack from the canal towards the root surface
 an Incomplete Crack from the root surface towards the canal
 A complete crack

Is there a dentinal crack present in the instrumented (Post-Op) sample not seen in the Pre-Op image?

- Yes
 No

Is there more than one crack seen in the Post-Op image?

- Yes
 No

For the longest crack seen in the Post-Op image, is the crack:

- an Incomplete Crack from the canal towards the root surface
 an Incomplete Crack from the root surface towards the canal
 A complete crack

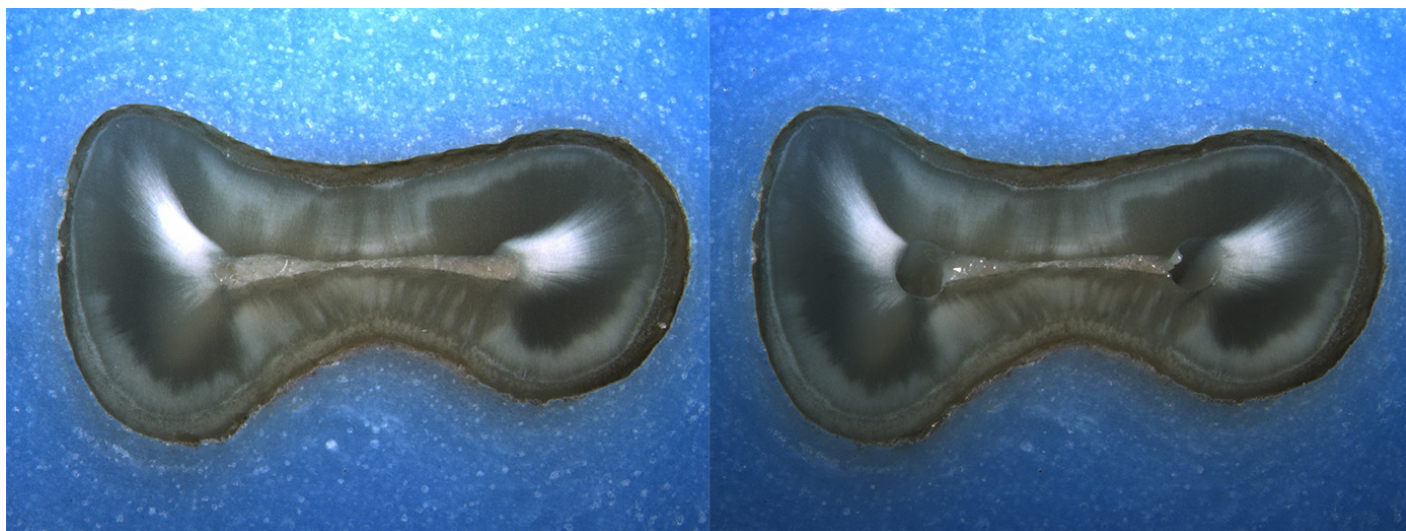
Is the crack seen in the Post-Op image:

- an Incomplete Crack from the canal towards the root surface
 an Incomplete Crack from the root surface towards the canal
 A complete crack

Done. Go to next page

Image: i122.jpg

Pre-Op on the left and Post-Op on the right



Is there any evidence of a dentinal crack prior to rotary instrumentation (Pre-Op)?

- Yes
 No

Does the crack in the Pre-Op image increase in size when viewed in the Post-Op image?

- Yes
 No

Is the crack that increased in the Pre-Op image now:

- an Incomplete Crack from the canal towards the root surface
 an Incomplete Crack from the root surface towards the canal
 A complete crack

Is there a new dentinal crack present in the instrumented (Post-Op) sample not seen in the Pre-Op image?

- Yes
 No

Is the new crack in the Post-Op image:

- an Incomplete Crack from the canal towards the root surface
 an Incomplete Crack from the root surface towards the canal
 A complete crack

Is there a dentinal crack present in the instrumented (Post-Op) sample not seen in the Pre-Op image?

- Yes
 No

Is there more than one crack seen in the Post-Op image?

- Yes
 No

For the longest crack seen in the Post-Op image, is the crack:

- an Incomplete Crack from the canal towards the root surface
 an Incomplete Crack from the root surface towards the canal
 A complete crack

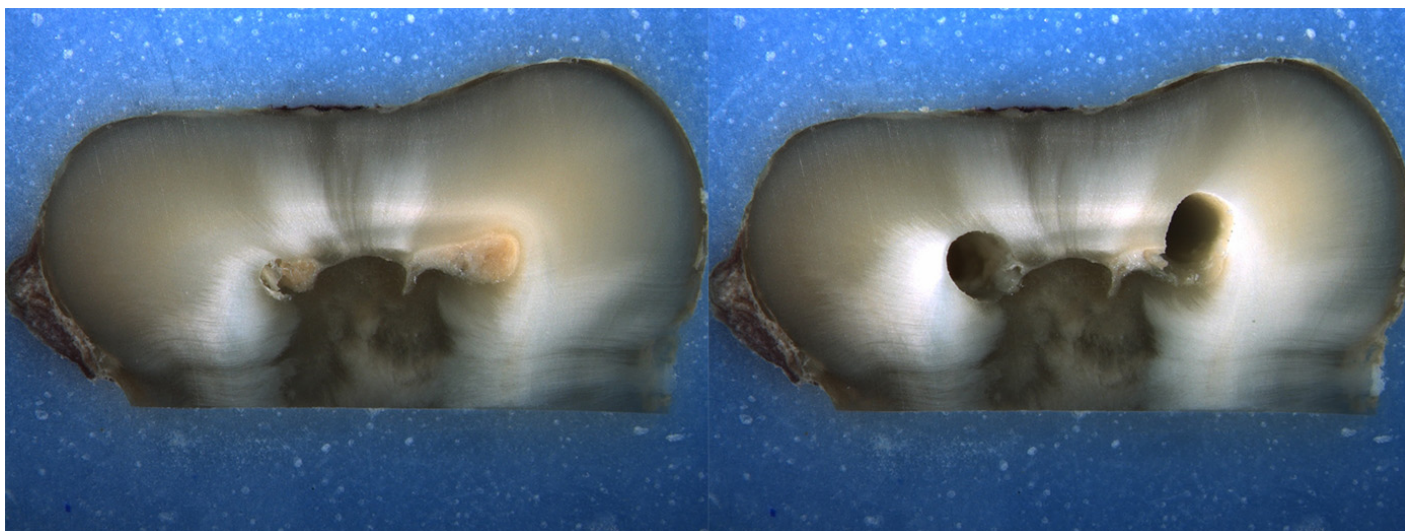
Is the crack seen in the Post-Op image:

- an Incomplete Crack from the canal towards the root surface
 an Incomplete Crack from the root surface towards the canal
 A complete crack

Done. Go to next page

Image: i123.jpg

Pre-Op on the left and Post-Op on the right



Is there any evidence of a dentinal crack prior to rotary instrumentation (Pre-Op)?

- Yes
 No

Does the crack in the Pre-Op image increase in size when viewed in the Post-Op image?

- Yes
 No

Is the crack that increased in the Pre-Op image now:

- an Incomplete Crack from the canal towards the root surface
 an Incomplete Crack from the root surface towards the canal
 A complete crack

Is there a new dentinal crack present in the instrumented (Post-Op) sample not seen in the Pre-Op image?

- Yes
 No

Is the new crack in the Post-Op image:

- an Incomplete Crack from the canal towards the root surface
 an Incomplete Crack from the root surface towards the canal
 A complete crack

Is there a dentinal crack present in the instrumented (Post-Op) sample not seen in the Pre-Op image?

- Yes
 No

Is there more than one crack seen in the Post-Op image?

- Yes
 No

For the longest crack seen in the Post-Op image, is the crack:

- an Incomplete Crack from the canal towards the root surface
 an Incomplete Crack from the root surface towards the canal
 A complete crack

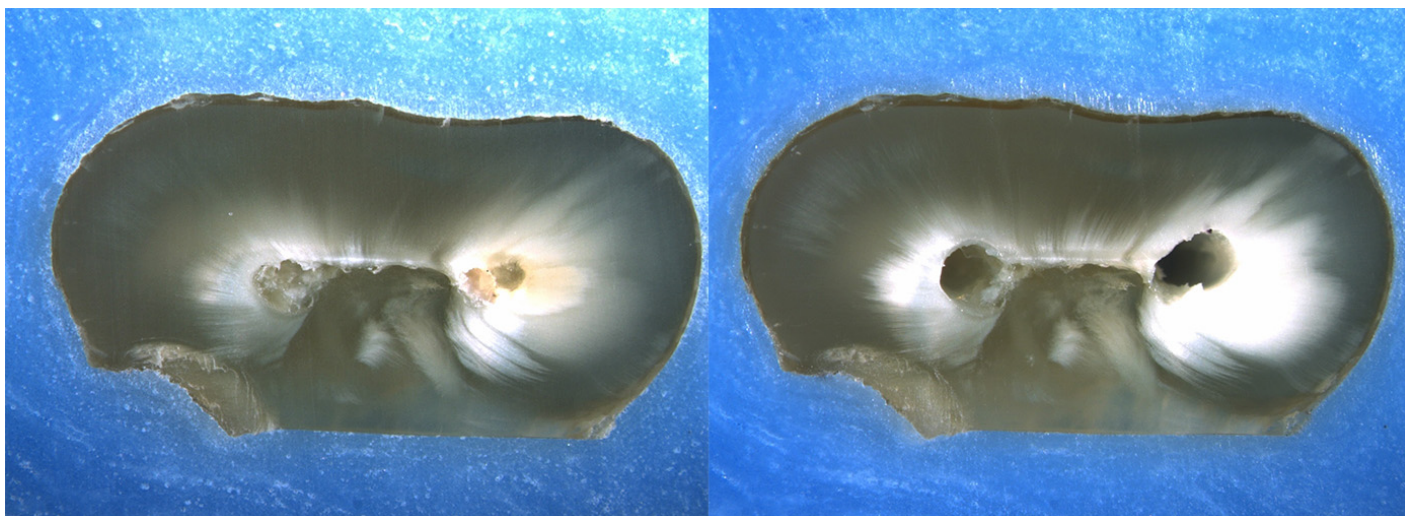
Is the crack seen in the Post-Op image:

- an Incomplete Crack from the canal towards the root surface
 an Incomplete Crack from the root surface towards the canal
 A complete crack

Done. Go to next page

Image: i124.jpg

Pre-Op on the left and Post-Op on the right



Is there any evidence of a dentinal crack prior to rotary instrumentation (Pre-Op)?

- Yes
 No

Does the crack in the Pre-Op image increase in size when viewed in the Post-Op image?

- Yes
 No

Is the crack that increased in the Pre-Op image now:

- an Incomplete Crack from the canal towards the root surface
 an Incomplete Crack from the root surface towards the canal
 A complete crack

Is there a new dentinal crack present in the instrumented (Post-Op) sample not seen in the Pre-Op image?

- Yes
 No

Is the new crack in the Post-Op image:

- an Incomplete Crack from the canal towards the root surface
 an Incomplete Crack from the root surface towards the canal
 A complete crack

Is there a dentinal crack present in the instrumented (Post-Op) sample not seen in the Pre-Op image?

- Yes
 No

Is there more than one crack seen in the Post-Op image?

- Yes
 No

For the longest crack seen in the Post-Op image, is the crack:

- an Incomplete Crack from the canal towards the root surface
 an Incomplete Crack from the root surface towards the canal
 A complete crack

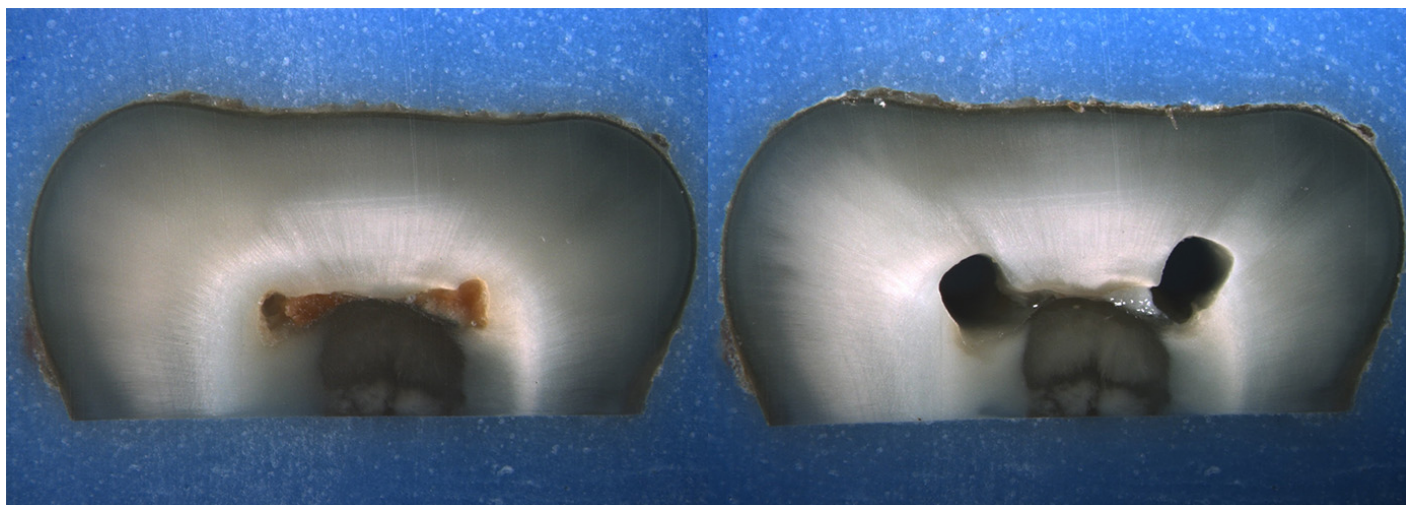
Is the crack seen in the Post-Op image:

- an Incomplete Crack from the canal towards the root surface
 an Incomplete Crack from the root surface towards the canal
 A complete crack

Done. Go to next page

Image: i125.jpg

Pre-Op on the left and Post-Op on the right



Is there any evidence of a dentinal crack prior to rotary instrumentation (Pre-Op)?

- Yes
 No

Does the crack in the Pre-Op image increase in size when viewed in the Post-Op image?

- Yes
 No

Is the crack that increased in the Pre-Op image now:

- an Incomplete Crack from the canal towards the root surface
 an Incomplete Crack from the root surface towards the canal
 A complete crack

Is there a new dentinal crack present in the instrumented (Post-Op) sample not seen in the Pre-Op image?

- Yes
 No

Is the new crack in the Post-Op image:

- an Incomplete Crack from the canal towards the root surface
 an Incomplete Crack from the root surface towards the canal
 A complete crack

Is there a dentinal crack present in the instrumented (Post-Op) sample not seen in the Pre-Op image?

- Yes
 No

Is there more than one crack seen in the Post-Op image?

- Yes
 No

For the longest crack seen in the Post-Op image, is the crack:

- an Incomplete Crack from the canal towards the root surface
 an Incomplete Crack from the root surface towards the canal
 A complete crack

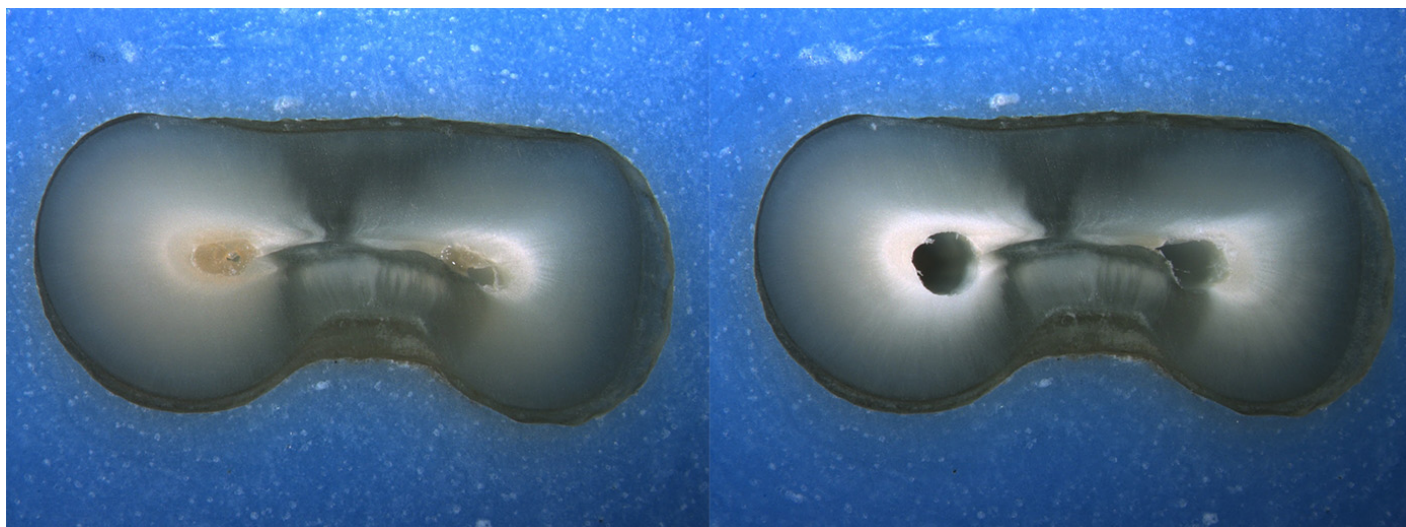
Is the crack seen in the Post-Op image:

- an Incomplete Crack from the canal towards the root surface
 an Incomplete Crack from the root surface towards the canal
 A complete crack

Done. Go to next page

Image: i126.jpg

Pre-Op on the left and Post-Op on the right



Is there any evidence of a dentinal crack prior to rotary instrumentation (Pre-Op)?

- Yes
 No

Does the crack in the Pre-Op image increase in size when viewed in the Post-Op image?

- Yes
 No

Is the crack that increased in the Pre-Op image now:

- an Incomplete Crack from the canal towards the root surface
 an Incomplete Crack from the root surface towards the canal
 A complete crack

Is there a new dentinal crack present in the instrumented (Post-Op) sample not seen in the Pre-Op image?

- Yes
 No

Is the new crack in the Post-Op image:

- an Incomplete Crack from the canal towards the root surface
 an Incomplete Crack from the root surface towards the canal
 A complete crack

Is there a dentinal crack present in the instrumented (Post-Op) sample not seen in the Pre-Op image?

- Yes
 No

Is there more than one crack seen in the Post-Op image?

- Yes
 No

For the longest crack seen in the Post-Op image, is the crack:

- an Incomplete Crack from the canal towards the root surface
 an Incomplete Crack from the root surface towards the canal
 A complete crack

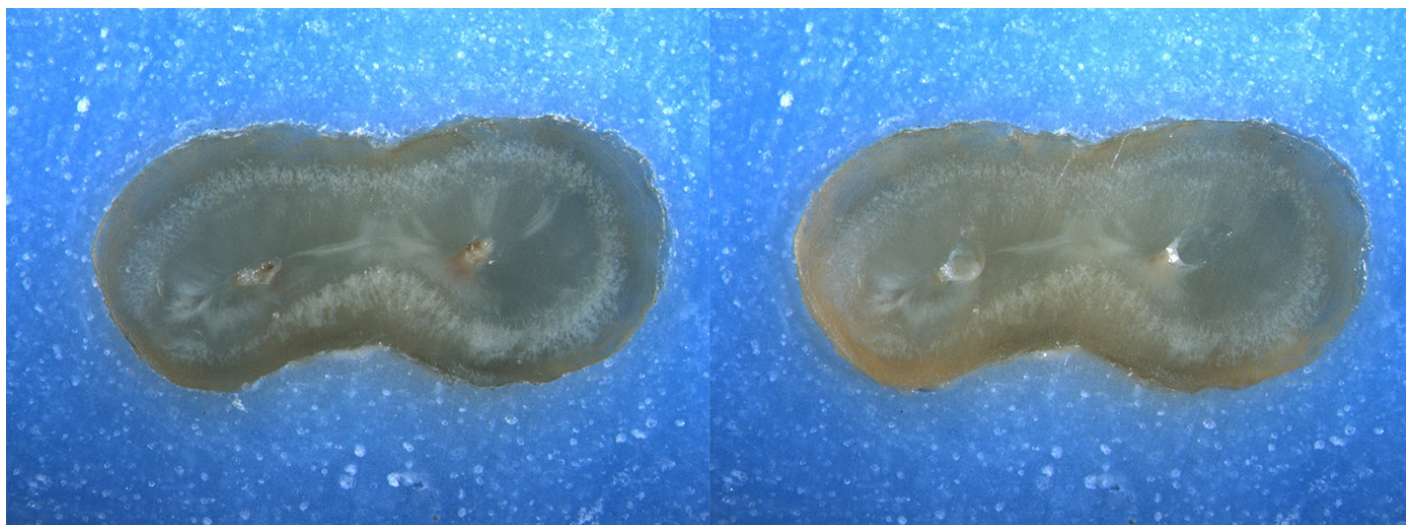
Is the crack seen in the Post-Op image:

- an Incomplete Crack from the canal towards the root surface
 an Incomplete Crack from the root surface towards the canal
 A complete crack

Done. Go to next page

Image: i127.jpg

Pre-Op on the left and Post-Op on the right



Is there any evidence of a dentinal crack prior to rotary instrumentation (Pre-Op)?

- Yes
 No

Does the crack in the Pre-Op image increase in size when viewed in the Post-Op image?

- Yes
 No

Is the crack that increased in the Pre-Op image now:

- an Incomplete Crack from the canal towards the root surface
 an Incomplete Crack from the root surface towards the canal
 A complete crack

Is there a new dentinal crack present in the instrumented (Post-Op) sample not seen in the Pre-Op image?

- Yes
 No

Is the new crack in the Post-Op image:

- an Incomplete Crack from the canal towards the root surface
 an Incomplete Crack from the root surface towards the canal
 A complete crack

Is there a dentinal crack present in the instrumented (Post-Op) sample not seen in the Pre-Op image?

- Yes
 No

Is there more than one crack seen in the Post-Op image?

- Yes
 No

For the longest crack seen in the Post-Op image, is the crack:

- an Incomplete Crack from the canal towards the root surface
 an Incomplete Crack from the root surface towards the canal
 A complete crack


Is the crack seen in the Post-Op image:

- an Incomplete Crack from the canal towards the root surface
 an Incomplete Crack from the root surface towards the canal
 A complete crack

Done. Go to next page

Image: i128.jpg

Pre-Op on the left and Post-Op on the right



Is there any evidence of a dentinal crack prior to rotary instrumentation (Pre-Op)?

- Yes
 No

Does the crack in the Pre-Op image increase in size when viewed in the Post-Op image?

- Yes
 No

Is the crack that increased in the Pre-Op image now:

- an Incomplete Crack from the canal towards the root surface
 an Incomplete Crack from the root surface towards the canal
 A complete crack

Is there a new dentinal crack present in the instrumented (Post-Op) sample not seen in the Pre-Op image?

- Yes
 No

Is the new crack in the Post-Op image:

- an Incomplete Crack from the canal towards the root surface
 an Incomplete Crack from the root surface towards the canal
 A complete crack

Is there a dentinal crack present in the instrumented (Post-Op) sample not seen in the Pre-Op image?

- Yes
 No

Is there more than one crack seen in the Post-Op image?

- Yes
 No

For the longest crack seen in the Post-Op image, is the crack:

- an Incomplete Crack from the canal towards the root surface
 an Incomplete Crack from the root surface towards the canal
 A complete crack


Is the crack seen in the Post-Op image:

- an Incomplete Crack from the canal towards the root surface
 an Incomplete Crack from the root surface towards the canal
 A complete crack

Done. Go to next page

Image: i129.jpg

Pre-Op on the left and Post-Op on the right



Is there any evidence of a dentinal crack prior to rotary instrumentation (Pre-Op)?

- Yes
 No

Does the crack in the Pre-Op image increase in size when viewed in the Post-Op image?

- Yes
 No

Is the crack that increased in the Pre-Op image now:

- an Incomplete Crack from the canal towards the root surface
 an Incomplete Crack from the root surface towards the canal
 A complete crack

Is there a new dentinal crack present in the instrumented (Post-Op) sample not seen in the Pre-Op image?

- Yes
 No

Is the new crack in the Post-Op image:

- an Incomplete Crack from the canal towards the root surface
 an Incomplete Crack from the root surface towards the canal
 A complete crack

Is there a dentinal crack present in the instrumented (Post-Op) sample not seen in the Pre-Op image?

- Yes
 No

Is there more than one crack seen in the Post-Op image?

- Yes
 No

For the longest crack seen in the Post-Op image, is the crack:

- an Incomplete Crack from the canal towards the root surface
 an Incomplete Crack from the root surface towards the canal
 A complete crack


Is the crack seen in the Post-Op image:

- an Incomplete Crack from the canal towards the root surface
 an Incomplete Crack from the root surface towards the canal
 A complete crack

Done. Go to next page

Image: i130.jpg

Pre-Op on the left and Post-Op on the right



Is there any evidence of a dentinal crack prior to rotary instrumentation (Pre-Op)?

- Yes
 No

Does the crack in the Pre-Op image increase in size when viewed in the Post-Op image?

- Yes
 No

Is the crack that increased in the Pre-Op image now:

- an Incomplete Crack from the canal towards the root surface
 an Incomplete Crack from the root surface towards the canal
 A complete crack

Is there a new dentinal crack present in the instrumented (Post-Op) sample not seen in the Pre-Op image?

- Yes
 No

Is the new crack in the Post-Op image:

- an Incomplete Crack from the canal towards the root surface
 an Incomplete Crack from the root surface towards the canal
 A complete crack

Is there a dentinal crack present in the instrumented (Post-Op) sample not seen in the Pre-Op image?

- Yes
 No

Is there more than one crack seen in the Post-Op image?

- Yes
 No

For the longest crack seen in the Post-Op image, is the crack:

- an Incomplete Crack from the canal towards the root surface
 an Incomplete Crack from the root surface towards the canal
 A complete crack


Is the crack seen in the Post-Op image:

- an Incomplete Crack from the canal towards the root surface
 an Incomplete Crack from the root surface towards the canal
 A complete crack

Done. Go to next page

Image: i131.jpg

Pre-Op on the left and Post-Op on the right



Is there any evidence of a dentinal crack prior to rotary instrumentation (Pre-Op)?

- Yes
 No

Does the crack in the Pre-Op image increase in size when viewed in the Post-Op image?

- Yes
 No

Is the crack that increased in the Pre-Op image now:

- an Incomplete Crack from the canal towards the root surface
 an Incomplete Crack from the root surface towards the canal
 A complete crack

Is there a new dentinal crack present in the instrumented (Post-Op) sample not seen in the Pre-Op image?

- Yes
 No

Is the new crack in the Post-Op image:

- an Incomplete Crack from the canal towards the root surface
 an Incomplete Crack from the root surface towards the canal
 A complete crack

Is there a dentinal crack present in the instrumented (Post-Op) sample not seen in the Pre-Op image?

- Yes
 No

Is there more than one crack seen in the Post-Op image?

- Yes
 No

For the longest crack seen in the Post-Op image, is the crack:

- an Incomplete Crack from the canal towards the root surface
 an Incomplete Crack from the root surface towards the canal
 A complete crack


Is the crack seen in the Post-Op image:

- an Incomplete Crack from the canal towards the root surface
 an Incomplete Crack from the root surface towards the canal
 A complete crack

Done. Go to next page

Image: i132.jpg

Pre-Op on the left and Post-Op on the right



Is there any evidence of a dentinal crack prior to rotary instrumentation (Pre-Op)?

- Yes
 No

Does the crack in the Pre-Op image increase in size when viewed in the Post-Op image?

- Yes
 No

Is the crack that increased in the Pre-Op image now:

- an Incomplete Crack from the canal towards the root surface
 an Incomplete Crack from the root surface towards the canal
 A complete crack

Is there a new dentinal crack present in the instrumented (Post-Op) sample not seen in the Pre-Op image?

- Yes
 No

Is the new crack in the Post-Op image:

- an Incomplete Crack from the canal towards the root surface
 an Incomplete Crack from the root surface towards the canal
 A complete crack

Is there a dentinal crack present in the instrumented (Post-Op) sample not seen in the Pre-Op image?

- Yes
 No

Is there more than one crack seen in the Post-Op image?

- Yes
 No

For the longest crack seen in the Post-Op image, is the crack:

- an Incomplete Crack from the canal towards the root surface
 an Incomplete Crack from the root surface towards the canal
 A complete crack

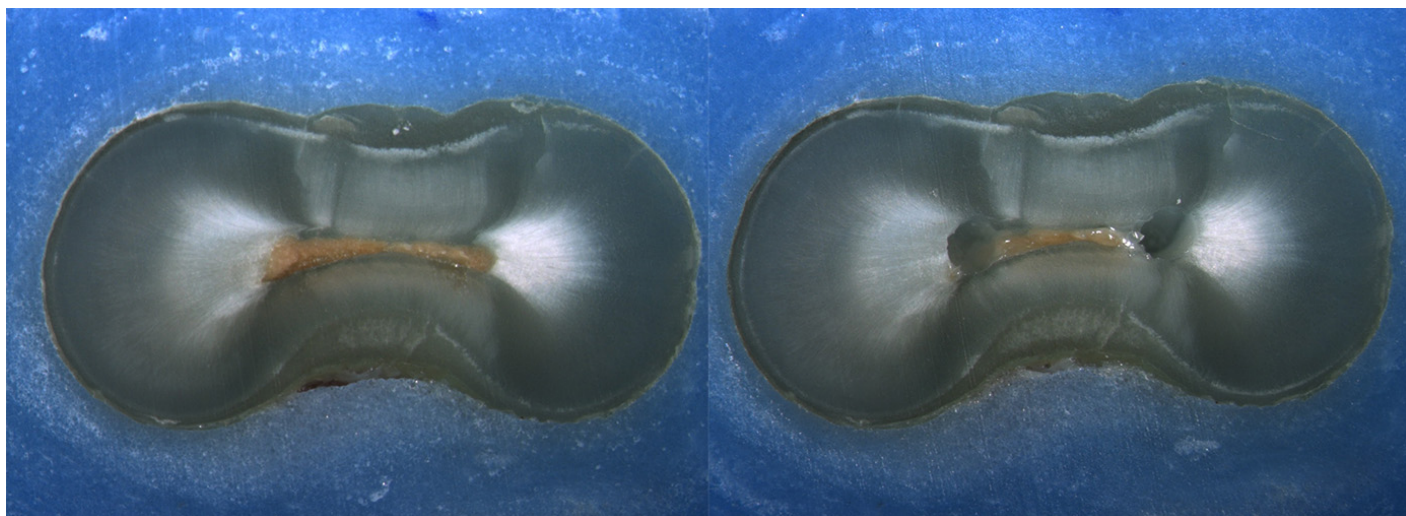
Is the crack seen in the Post-Op image:

- an Incomplete Crack from the canal towards the root surface
 an Incomplete Crack from the root surface towards the canal
 A complete crack

Done. Go to next page

Image: i133.jpg

Pre-Op on the left and Post-Op on the right



Is there any evidence of a dentinal crack prior to rotary instrumentation (Pre-Op)?

- Yes
 No

Does the crack in the Pre-Op image increase in size when viewed in the Post-Op image?

- Yes
 No

Is the crack that increased in the Pre-Op image now:

- an Incomplete Crack from the canal towards the root surface
 an Incomplete Crack from the root surface towards the canal
 A complete crack

Is there a new dentinal crack present in the instrumented (Post-Op) sample not seen in the Pre-Op image?

- Yes
 No

Is the new crack in the Post-Op image:

- an Incomplete Crack from the canal towards the root surface
 an Incomplete Crack from the root surface towards the canal
 A complete crack

Is there a dentinal crack present in the instrumented (Post-Op) sample not seen in the Pre-Op image?

- Yes
 No

Is there more than one crack seen in the Post-Op image?

- Yes
 No

For the longest crack seen in the Post-Op image, is the crack:

- an Incomplete Crack from the canal towards the root surface
 an Incomplete Crack from the root surface towards the canal
 A complete crack


Is the crack seen in the Post-Op image:

- an Incomplete Crack from the canal towards the root surface
 an Incomplete Crack from the root surface towards the canal
 A complete crack

Done. Go to next page

Image: i134.jpg

Pre-Op on the left and Post-Op on the right



Is there any evidence of a dentinal crack prior to rotary instrumentation (Pre-Op)?

- Yes
 No

Does the crack in the Pre-Op image increase in size when viewed in the Post-Op image?

- Yes
 No

Is the crack that increased in the Pre-Op image now:

- an Incomplete Crack from the canal towards the root surface
 an Incomplete Crack from the root surface towards the canal
 A complete crack

Is there a new dentinal crack present in the instrumented (Post-Op) sample not seen in the Pre-Op image?

- Yes
 No

Is the new crack in the Post-Op image:

- an Incomplete Crack from the canal towards the root surface
 an Incomplete Crack from the root surface towards the canal
 A complete crack

Is there a dentinal crack present in the instrumented (Post-Op) sample not seen in the Pre-Op image?

- Yes
 No

Is there more than one crack seen in the Post-Op image?

- Yes
 No

For the longest crack seen in the Post-Op image, is the crack:

- an Incomplete Crack from the canal towards the root surface
 an Incomplete Crack from the root surface towards the canal
 A complete crack

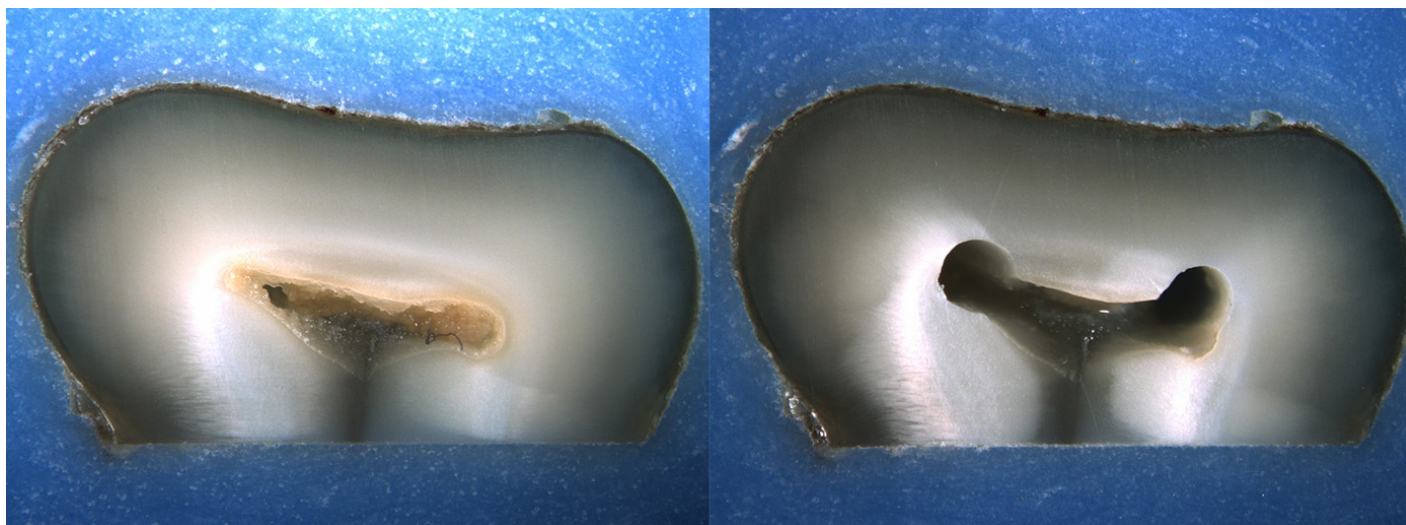
Is the crack seen in the Post-Op image:

- an Incomplete Crack from the canal towards the root surface
 an Incomplete Crack from the root surface towards the canal
 A complete crack

Done. Go to next page

Image: i135.jpg

Pre-Op on the left and Post-Op on the right



Is there any evidence of a dentinal crack prior to rotary instrumentation (Pre-Op)?

- Yes
 No

Does the crack in the Pre-Op image increase in size when viewed in the Post-Op image?

- Yes
 No

Is the crack that increased in the Pre-Op image now:

- an Incomplete Crack from the canal towards the root surface
 an Incomplete Crack from the root surface towards the canal
 A complete crack

Is there a new dentinal crack present in the instrumented (Post-Op) sample not seen in the Pre-Op image?

- Yes
 No

Is the new crack in the Post-Op image:

- an Incomplete Crack from the canal towards the root surface
 an Incomplete Crack from the root surface towards the canal
 A complete crack

Is there a dentinal crack present in the instrumented (Post-Op) sample not seen in the Pre-Op image?

- Yes
 No

Is there more than one crack seen in the Post-Op image?

- Yes
 No

For the longest crack seen in the Post-Op image, is the crack:

- an Incomplete Crack from the canal towards the root surface
 an Incomplete Crack from the root surface towards the canal
 A complete crack

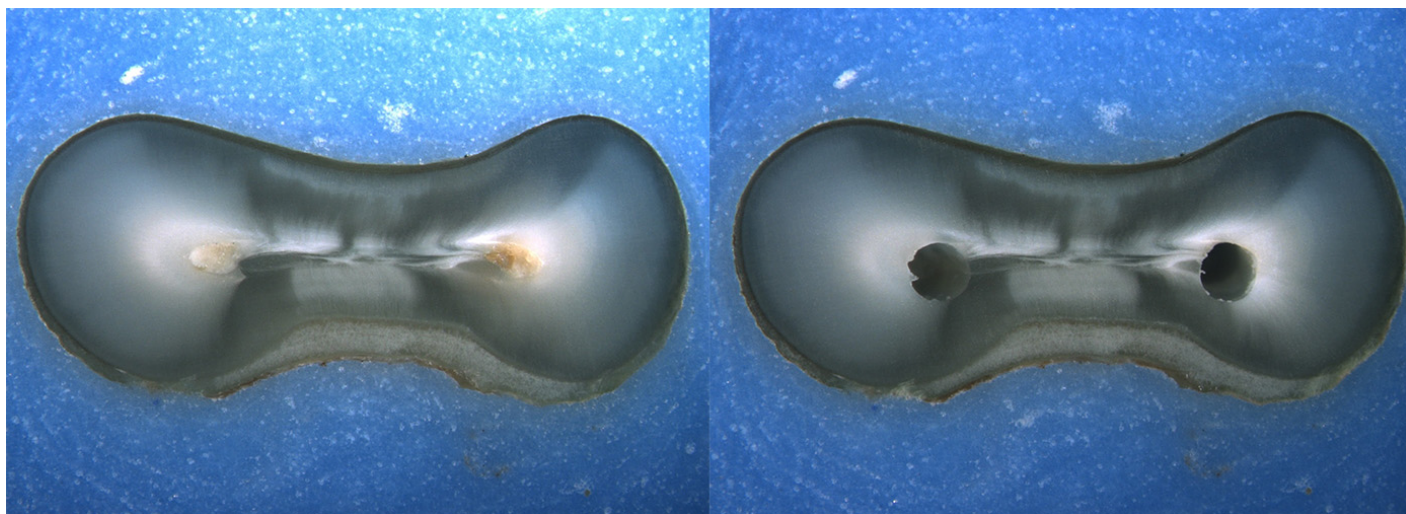
Is the crack seen in the Post-Op image:

- an Incomplete Crack from the canal towards the root surface
 an Incomplete Crack from the root surface towards the canal
 A complete crack

Done. Go to next page

Image: i136.jpg

Pre-Op on the left and Post-Op on the right



Is there any evidence of a dentinal crack prior to rotary instrumentation (Pre-Op)?

- Yes
 No

Does the crack in the Pre-Op image increase in size when viewed in the Post-Op image?

- Yes
 No

Is the crack that increased in the Pre-Op image now:

- an Incomplete Crack from the canal towards the root surface
 an Incomplete Crack from the root surface towards the canal
 A complete crack

Is there a new dentinal crack present in the instrumented (Post-Op) sample not seen in the Pre-Op image?

- Yes
 No

Is the new crack in the Post-Op image:

- an Incomplete Crack from the canal towards the root surface
 an Incomplete Crack from the root surface towards the canal
 A complete crack

Is there a dentinal crack present in the instrumented (Post-Op) sample not seen in the Pre-Op image?

- Yes
 No

Is there more than one crack seen in the Post-Op image?

- Yes
 No

For the longest crack seen in the Post-Op image, is the crack:

- an Incomplete Crack from the canal towards the root surface
 an Incomplete Crack from the root surface towards the canal
 A complete crack

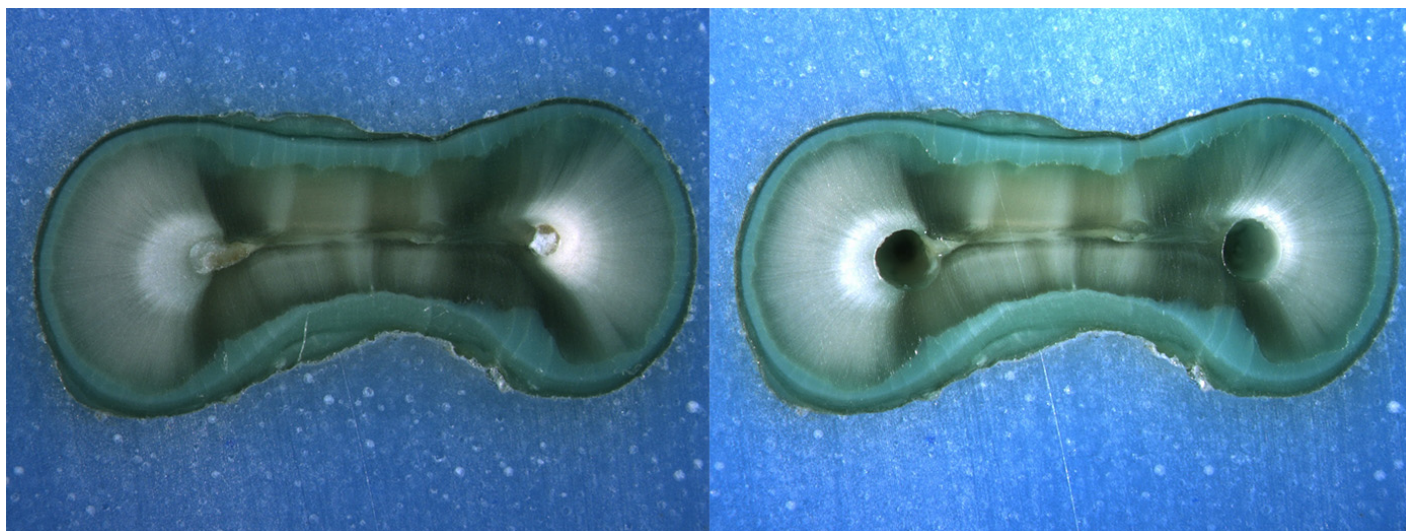
Is the crack seen in the Post-Op image:

- an Incomplete Crack from the canal towards the root surface
 an Incomplete Crack from the root surface towards the canal
 A complete crack

Done. Go to next page

Image: i137.jpg

Pre-Op on the left and Post-Op on the right



Is there any evidence of a dentinal crack prior to rotary instrumentation (Pre-Op)?

- Yes
 No

Does the crack in the Pre-Op image increase in size when viewed in the Post-Op image?

- Yes
 No

Is the crack that increased in the Pre-Op image now:

- an Incomplete Crack from the canal towards the root surface
 an Incomplete Crack from the root surface towards the canal
 A complete crack

Is there a new dentinal crack present in the instrumented (Post-Op) sample not seen in the Pre-Op image?

- Yes
 No

Is the new crack in the Post-Op image:

- an Incomplete Crack from the canal towards the root surface
 an Incomplete Crack from the root surface towards the canal
 A complete crack

Is there a dentinal crack present in the instrumented (Post-Op) sample not seen in the Pre-Op image?

- Yes
 No

Is there more than one crack seen in the Post-Op image?

- Yes
 No

For the longest crack seen in the Post-Op image, is the crack:

- an Incomplete Crack from the canal towards the root surface
 an Incomplete Crack from the root surface towards the canal
 A complete crack

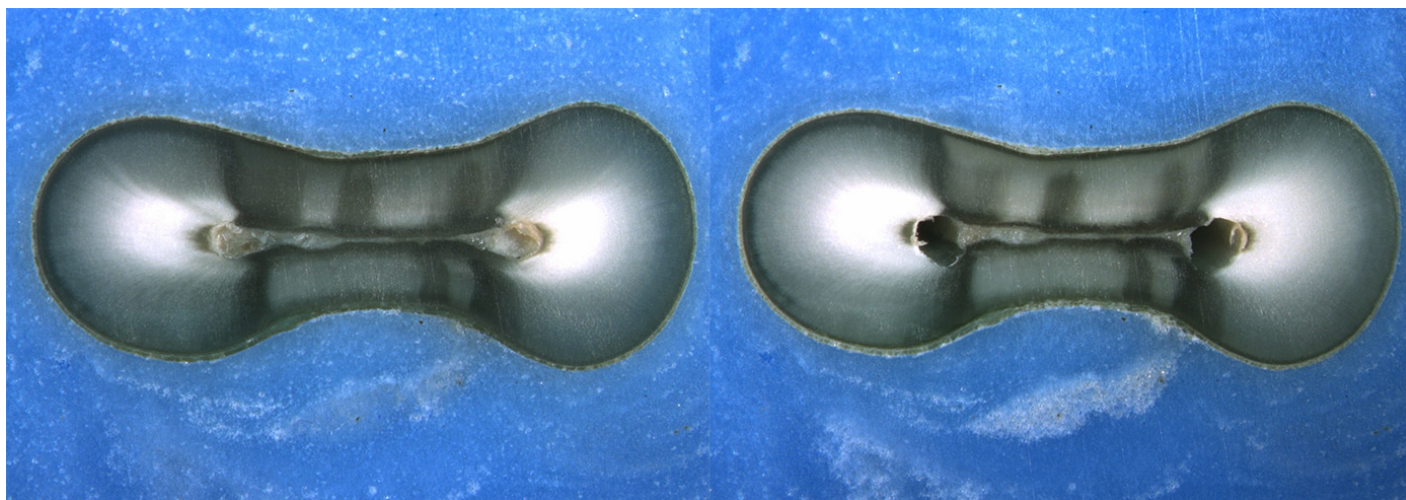
Is the crack seen in the Post-Op image:

- an Incomplete Crack from the canal towards the root surface
 an Incomplete Crack from the root surface towards the canal
 A complete crack

Done. Go to next page

Image: i138.jpg

Pre-Op on the left and Post-Op on the right



Is there any evidence of a dentinal crack prior to rotary instrumentation (Pre-Op)?

- Yes
 No

Does the crack in the Pre-Op image increase in size when viewed in the Post-Op image?

- Yes
 No

Is the crack that increased in the Pre-Op image now:

- an Incomplete Crack from the canal towards the root surface
 an Incomplete Crack from the root surface towards the canal
 A complete crack

Is there a new dentinal crack present in the instrumented (Post-Op) sample not seen in the Pre-Op image?

- Yes
 No

Is the new crack in the Post-Op image:

- an Incomplete Crack from the canal towards the root surface
 an Incomplete Crack from the root surface towards the canal
 A complete crack

Is there a dentinal crack present in the instrumented (Post-Op) sample not seen in the Pre-Op image?

- Yes
 No

Is there more than one crack seen in the Post-Op image?

- Yes
 No

For the longest crack seen in the Post-Op image, is the crack:

- an Incomplete Crack from the canal towards the root surface
 an Incomplete Crack from the root surface towards the canal
 A complete crack

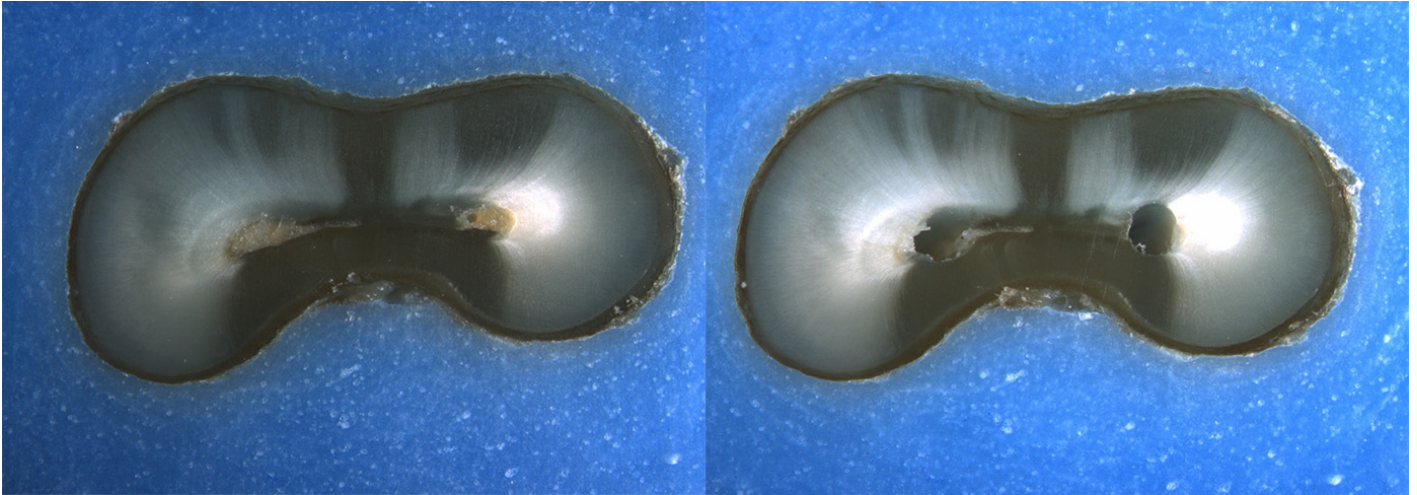
Is the crack seen in the Post-Op image:

- an Incomplete Crack from the canal towards the root surface
 an Incomplete Crack from the root surface towards the canal
 A complete crack

Done. Go to next page

Image: i139.jpg

Pre-Op on the left and Post-Op on the right



Is there any evidence of a dentinal crack prior to rotary instrumentation (Pre-Op)?

- Yes
 No

Does the crack in the Pre-Op image increase in size when viewed in the Post-Op image?

- Yes
 No

Is the crack that increased in the Pre-Op image now:

- an Incomplete Crack from the canal towards the root surface
 an Incomplete Crack from the root surface towards the canal
 A complete crack

Is there a new dentinal crack present in the instrumented (Post-Op) sample not seen in the Pre-Op image?

- Yes
 No

Is the new crack in the Post-Op image:

- an Incomplete Crack from the canal towards the root surface
 an Incomplete Crack from the root surface towards the canal
 A complete crack

Is there a dentinal crack present in the instrumented (Post-Op) sample not seen in the Pre-Op image?

- Yes
 No

Is there more than one crack seen in the Post-Op image?

- Yes
 No

For the longest crack seen in the Post-Op image, is the crack:

- an Incomplete Crack from the canal towards the root surface
 an Incomplete Crack from the root surface towards the canal
 A complete crack

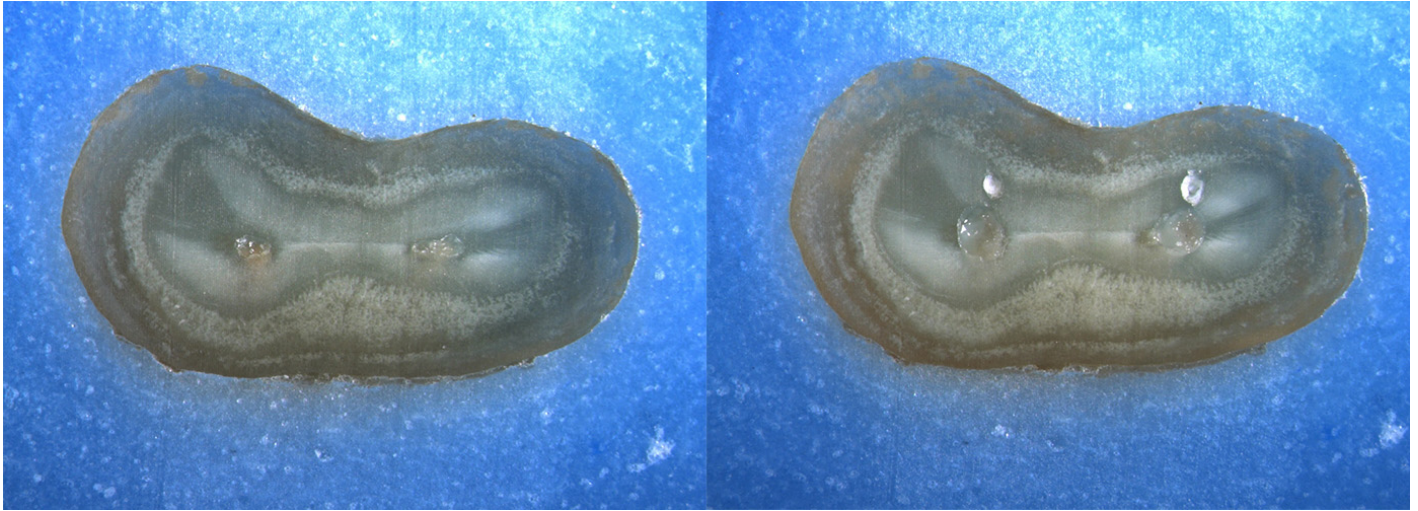
Is the crack seen in the Post-Op image:

- an Incomplete Crack from the canal towards the root surface
 an Incomplete Crack from the root surface towards the canal
 A complete crack

Done. Go to next page

Image: i140.jpg

Pre-Op on the left and Post-Op on the right



Is there any evidence of a dentinal crack prior to rotary instrumentation (Pre-Op)?

- Yes
 No

Does the crack in the Pre-Op image increase in size when viewed in the Post-Op image?

- Yes
 No

Is the crack that increased in the Pre-Op image now:

- an Incomplete Crack from the canal towards the root surface
 an Incomplete Crack from the root surface towards the canal
 A complete crack

Is there a new dentinal crack present in the instrumented (Post-Op) sample not seen in the Pre-Op image?

- Yes
 No

Is the new crack in the Post-Op image:

- an Incomplete Crack from the canal towards the root surface
 an Incomplete Crack from the root surface towards the canal
 A complete crack

Is there a dentinal crack present in the instrumented (Post-Op) sample not seen in the Pre-Op image?

- Yes
 No

Is there more than one crack seen in the Post-Op image?

- Yes
 No

For the longest crack seen in the Post-Op image, is the crack:

- an Incomplete Crack from the canal towards the root surface
 an Incomplete Crack from the root surface towards the canal
 A complete crack

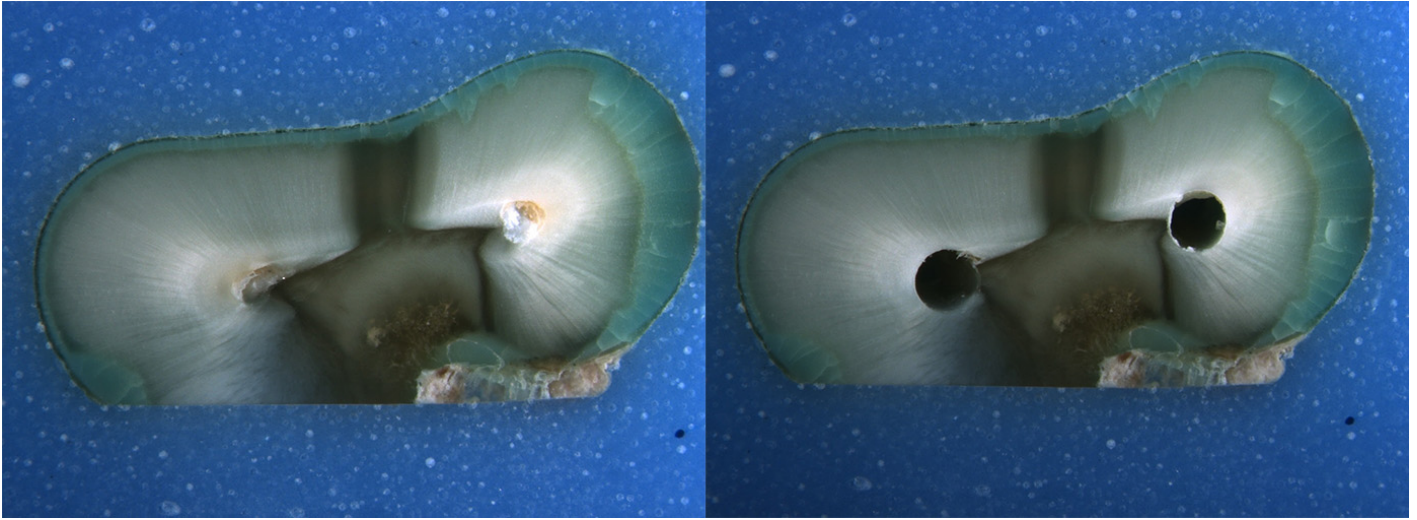
Is the crack seen in the Post-Op image:

- an Incomplete Crack from the canal towards the root surface
 an Incomplete Crack from the root surface towards the canal
 A complete crack

Done. Go to next page

Image: i141.jpg

Pre-Op on the left and Post-Op on the right



Is there any evidence of a dentinal crack prior to rotary instrumentation (Pre-Op)?

- Yes
 No

Does the crack in the Pre-Op image increase in size when viewed in the Post-Op image?

- Yes
 No

Is the crack that increased in the Pre-Op image now:

- an Incomplete Crack from the canal towards the root surface
 an Incomplete Crack from the root surface towards the canal
 A complete crack

Is there a new dentinal crack present in the instrumented (Post-Op) sample not seen in the Pre-Op image?

- Yes
 No

Is the new crack in the Post-Op image:

- an Incomplete Crack from the canal towards the root surface
 an Incomplete Crack from the root surface towards the canal
 A complete crack

Is there a dentinal crack present in the instrumented (Post-Op) sample not seen in the Pre-Op image?

- Yes
 No

Is there more than one crack seen in the Post-Op image?

- Yes
 No

For the longest crack seen in the Post-Op image, is the crack:

- an Incomplete Crack from the canal towards the root surface
 an Incomplete Crack from the root surface towards the canal
 A complete crack

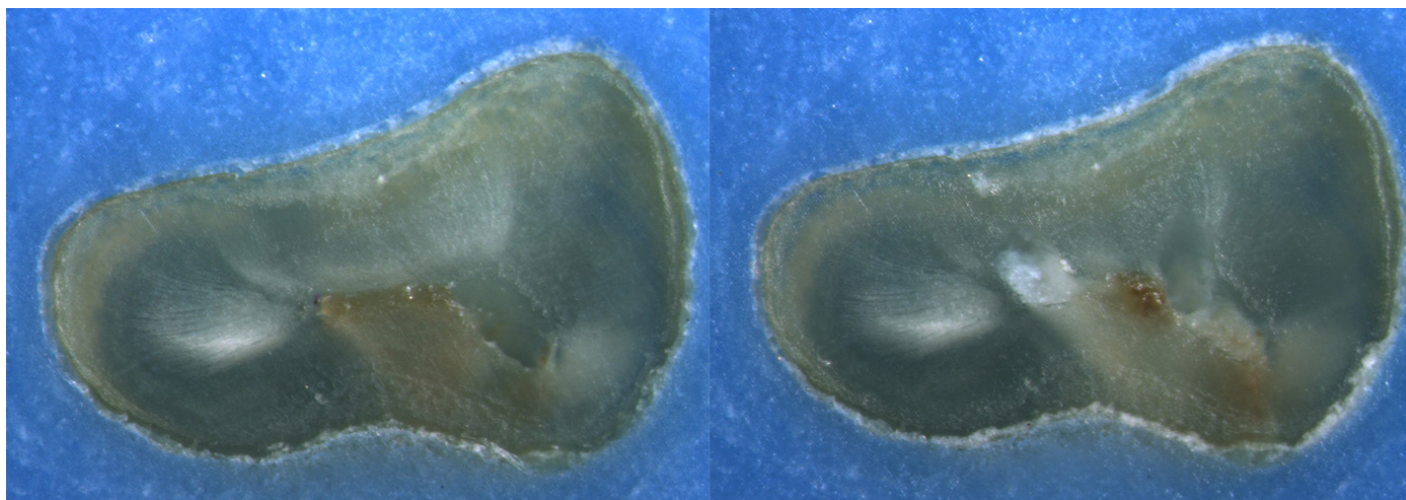
Is the crack seen in the Post-Op image:

- an Incomplete Crack from the canal towards the root surface
 an Incomplete Crack from the root surface towards the canal
 A complete crack

Done. Go to next page

Image: i142.jpg

Pre-Op on the left and Post-Op on the right



Is there any evidence of a dentinal crack prior to rotary instrumentation (Pre-Op)?

- Yes
 No

Does the crack in the Pre-Op image increase in size when viewed in the Post-Op image?

- Yes
 No

Is the crack that increased in the Pre-Op image now:

- an Incomplete Crack from the canal towards the root surface
 an Incomplete Crack from the root surface towards the canal
 A complete crack

Is there a new dentinal crack present in the instrumented (Post-Op) sample not seen in the Pre-Op image?

- Yes
 No

Is the new crack in the Post-Op image:

- an Incomplete Crack from the canal towards the root surface
 an Incomplete Crack from the root surface towards the canal
 A complete crack

Is there a dentinal crack present in the instrumented (Post-Op) sample not seen in the Pre-Op image?

- Yes
 No

Is there more than one crack seen in the Post-Op image?

- Yes
 No

For the longest crack seen in the Post-Op image, is the crack:

- an Incomplete Crack from the canal towards the root surface
 an Incomplete Crack from the root surface towards the canal
 A complete crack

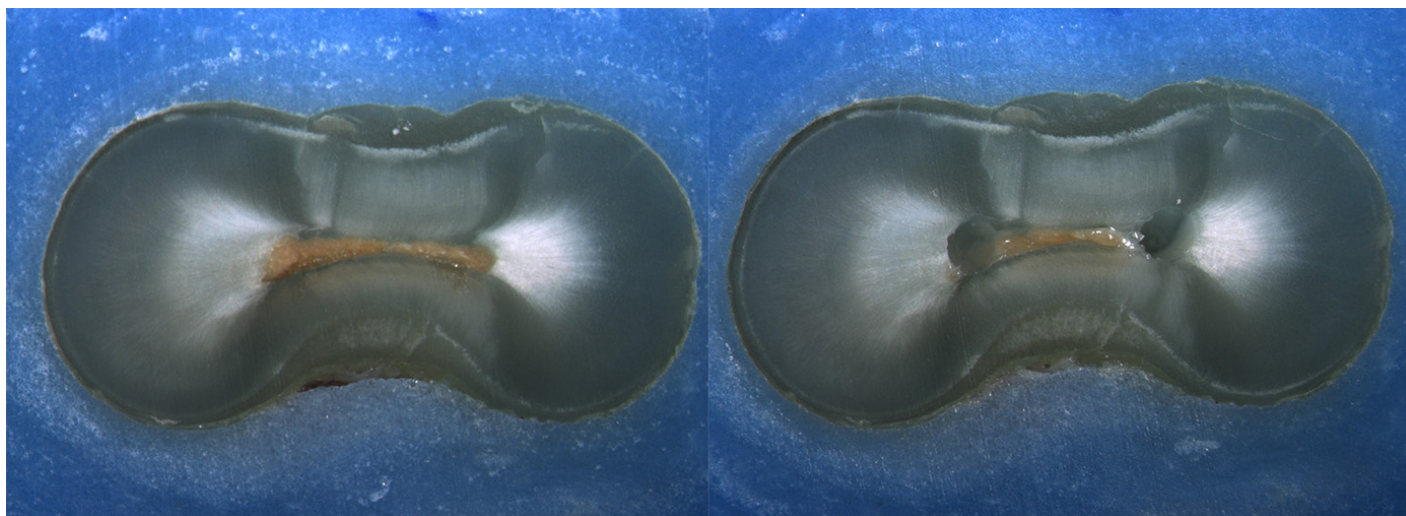
Is the crack seen in the Post-Op image:

- an Incomplete Crack from the canal towards the root surface
 an Incomplete Crack from the root surface towards the canal
 A complete crack

Done. Go to next page

Image: i143.jpg

Pre-Op on the left and Post-Op on the right



Is there any evidence of a dentinal crack prior to rotary instrumentation (Pre-Op)?

- Yes
 No

Does the crack in the Pre-Op image increase in size when viewed in the Post-Op image?

- Yes
 No

Is the crack that increased in the Pre-Op image now:

- an Incomplete Crack from the canal towards the root surface
 an Incomplete Crack from the root surface towards the canal
 A complete crack

Is there a new dentinal crack present in the instrumented (Post-Op) sample not seen in the Pre-Op image?

- Yes
 No

Is the new crack in the Post-Op image:

- an Incomplete Crack from the canal towards the root surface
 an Incomplete Crack from the root surface towards the canal
 A complete crack

Is there a dentinal crack present in the instrumented (Post-Op) sample not seen in the Pre-Op image?

- Yes
 No

Is there more than one crack seen in the Post-Op image?

- Yes
 No

For the longest crack seen in the Post-Op image, is the crack:

- an Incomplete Crack from the canal towards the root surface
 an Incomplete Crack from the root surface towards the canal
 A complete crack

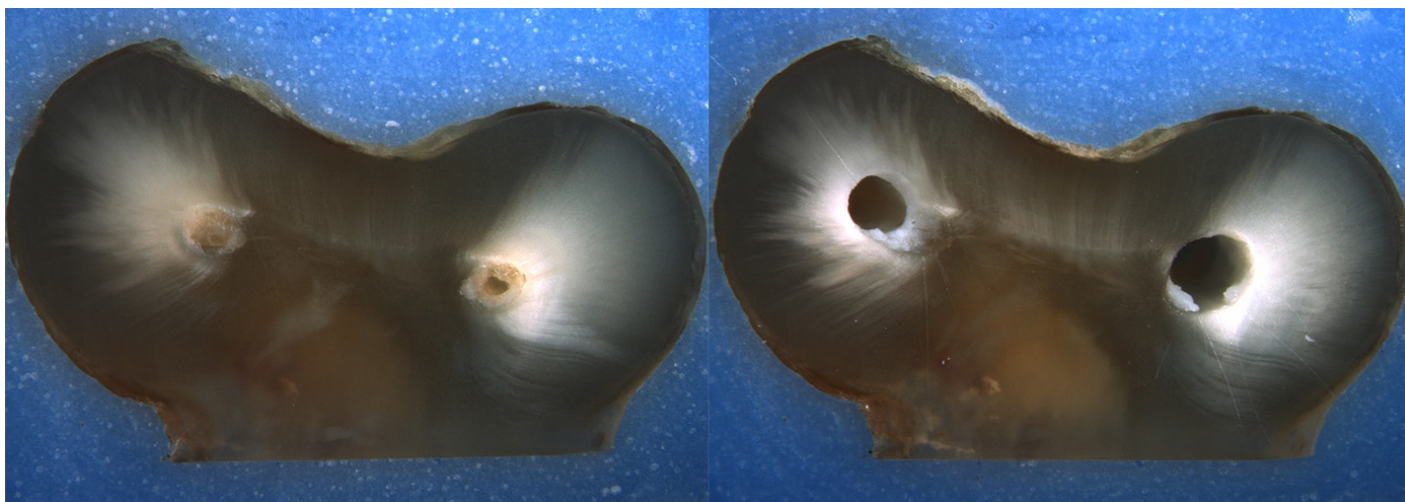
Is the crack seen in the Post-Op image:

- an Incomplete Crack from the canal towards the root surface
 an Incomplete Crack from the root surface towards the canal
 A complete crack

Done. Go to next page

Image: i144.jpg

Pre-Op on the left and Post-Op on the right



Is there any evidence of a dentinal crack prior to rotary instrumentation (Pre-Op)?

- Yes
 No

Does the crack in the Pre-Op image increase in size when viewed in the Post-Op image?

- Yes
 No

Is the crack that increased in the Pre-Op image now:

- an Incomplete Crack from the canal towards the root surface
 an Incomplete Crack from the root surface towards the canal
 A complete crack

Is there a new dentinal crack present in the instrumented (Post-Op) sample not seen in the Pre-Op image?

- Yes
 No

Is the new crack in the Post-Op image:

- an Incomplete Crack from the canal towards the root surface
 an Incomplete Crack from the root surface towards the canal
 A complete crack

Is there a dentinal crack present in the instrumented (Post-Op) sample not seen in the Pre-Op image?

- Yes
 No

Is there more than one crack seen in the Post-Op image?

- Yes
 No

For the longest crack seen in the Post-Op image, is the crack:

- an Incomplete Crack from the canal towards the root surface
 an Incomplete Crack from the root surface towards the canal
 A complete crack

Is the crack seen in the Post-Op image:

- an Incomplete Crack from the canal towards the root surface
 an Incomplete Crack from the root surface towards the canal
 A complete crack

Done with this batch. Yay!

Vita

Dr. Stephen Nicholas Schroeder was born on January 22, 1984 in South Boston, Virginia and is an American citizen. Dr. Schroeder received his Bachelor of Science in Biology from James Madison University in 2007 and Doctor of Dental Surgery from Virginia Commonwealth University School of Dentistry in 2012. Dr. Schroeder then entered private practice in Farmville, Virginia spending two years in general dental practice. In 2015, he enrolled in the Advanced Dental Program in Endodontics at Virginia Commonwealth University School of Dentistry. Dr. Schroeder is a member of the American Association of Endodontists, American Dental Association, and Virginia Dental Association. He will graduate with a Master of Science in Dentistry and a Certificate in Endodontics.