



Carreño, E., Moutray, T., Fotis, K., Lee, R. W. J., Dick, A. D., Ross, A. H., & Bailey, C. (2016). Phase IIb clinical trial of ranibizumab for the treatment of uveitic and idiopathic choroidal neovascular membranes. *British Journal of Ophthalmology*, 100(9), 1221-1226. DOI: 10.1136/bjophthalmol-2015-307806

Peer reviewed version

Link to published version (if available):
[10.1136/bjophthalmol-2015-307806](https://doi.org/10.1136/bjophthalmol-2015-307806)

[Link to publication record in Explore Bristol Research](#)
PDF-document

This is the author accepted manuscript (AAM). The final published version (version of record) is available online via BMJ at <http://bjo.bmj.com/content/100/9/1221>. Please refer to any applicable terms of use of the publisher.

University of Bristol - Explore Bristol Research

General rights

This document is made available in accordance with publisher policies. Please cite only the published version using the reference above. Full terms of use are available:
<http://www.bristol.ac.uk/pure/about/ebr-terms.html>

Title: Phase IIb clinical trial of Ranibizumab for the treatment of uveitic and idiopathic choroidal neovascular membranes.

Authors: Ester Carreño^{1,*}, Tanya Moutray¹, Konstantinos Fotis¹, Richard WJ Lee^{1,2,3}, Andrew D Dick^{1,2,3}, Adam H Ross¹, Clare Bailey¹.

¹ Bristol Eye Hospital, University Hospitals Bristol NHS Foundation Trust, Bristol, UK.

² School of Clinical Sciences, Faculty of Medicine and Dentistry, University of Bristol, Bristol, UK.

³ National Institute for Health Research Biomedical Research Centre at Moorfields Eye Hospital NHS Foundation Trust and UCL Institute of Ophthalmology, London, UK.

Subtitle: This study confirmed the efficacy of intravitreal Ranibizumab in assumed inflammatory mediated choroidal neovascular membranes, achieving a mean gain of 21 letters at 12 months of follow up.

***Corresponding author:**

Ester Carreño

Bristol Eye Hospital

Lower Maudlin Street

Bristol BS1 2LX

Phone: +44 (0) 117 342 4878

Fax: +44 (0) 117 342 4721

E-mail: Ester.Carreno-Salas@UHBristol.nhs.uk

Word count: 2,286

ABSTRACT

Aim: To assess the efficacy of intravitreal Ranibizumab for the treatment of new onset inflammatory choroidal neovascularization (iCNV), including both uveitic and idiopathic CNV.

Methods: Single-centre, open label, non-randomised phase IIb clinical trial. Patients fulfilling strict entry criteria of new onset iCNV were given monthly intravitreal Ranibizumab injections for 3 months. Thereafter, re-treatment was based on evidence of persisting activity. All patients completed trial follow-up. Optical coherence tomography (OCT) and best corrected visual acuity (BCVA) were performed at every visit. Fluorescein angiography was performed at baseline, months 4, and 12. Descriptive analysis and Wilcoxon non-parametric test were performed for analysis.

Results: Fifteen patients, 10 females with a mean age of 48.8 (range 24 to 85) years were included in the study. The mean number of injections was 4.33 (range 3 to 7). There was a statistically significant difference in the BCVA at month 4 ($p=0.001$) and at month 12 ($p=0.001$) compared with baseline. The mean gain in BCVA at month 4 compared with baseline was 20 ± 15.36 letters (mean \pm SD), and at month 12 was 21 ± 16.97 letters. There was a statistically significant difference in the mean central subfield thickness (CST) at baseline versus month 4 ($p=0.003$) and month 12 ($p=0.001$).

Conclusions: Patients gained vision (mean of 21 letters at 12 months) and showed reduced CST. These results support the continued use of Ranibizumab in the treatment of iCNV.

KEY WORDS: Choroidal neovascular membrane; Inflammatory; Uveitis; Idiopathic; Ranibizumab.

INTRODUCTION

Ocular Inflammatory mediated angiogenesis may manifest as choroidal neovascularization (CNV) in a variety of uveitic entities and in young patients with idiopathic CNV. In a recent large cohort multicentre study involving 15,137 patients with uveitis, the sight-threatening complication of CNV was present in 2.0% of patients with posterior segment intraocular inflammation (PSII – intermediate, posterior and panuveitis) in at least one eye at presentation. The cumulative 2-year incidence of CNV for those patients with PSII who did not have a CNV at presentation was 2.7% [1]. The incidence of a CNV is associated with significant loss of vision, with around 2-lines loss of visual acuity (VA) at presentation of CNV having been reported in PSII [1]. A corollary is that idiopathic CNV is an early manifestation of inflammatory chorioretinal disease [2]. This is corroborated by findings that whilst the global assessment of inflammatory activity and cell count in the anterior chamber is associated with increased risk of incident CNV, vitreous haze and vitreous cells were not. Furthermore, the development of new CNV is not always associated with clinically manifest intraocular inflammation [1].

Treatment of PSII-associated, inflammatory CNV (iCNV) have included laser photocoagulation [3], surgery [4], systemic or periocular steroids [5], systemic immunomodulatory treatment (IMT) [6], photodynamic therapy (PDT) [7], or a combination of the latter therapies [8]. There are also some anecdotal reports of the use of other therapeutic agents such as intravitreal methotrexate [9] and oral sirolimus [10]. The successful introduction of anti-VEGF drugs for the treatment of age-related and myopic CNV has led to an approach to consider anti-VEGF treatment for iCNV alone

or as an adjunct to those patients already on systemic IMT. Several retrospective studies in patients with iCNV have shown good outcomes with the use of Bevacizumab and Ranibizumab [11-17], and more recently in a prospective study with Bevacizumab [18].

Given the supportive but limited evidence of efficacy, the aim of this phase IIb trial was to provide evidence of efficacy of intravitreal Ranibizumab for the treatment of new onset iCNV secondary in patients with uveitis or presenting with idiopathic iCNV. The primary endpoint was the proportion of patients losing less than 15 ETDRS letters of BCVA from baseline at months 4 and 12.

MATERIALS AND METHODS

Patients

Patients over 18 years old presenting with new active inflammatory CNV, and fulfil the inclusion criteria and exclusion criteria (Table 1) were eligible for participation in the study. The study was performed at the Clinical Research Unit, Bristol Eye Hospital, where patients were recruited from the Regional Ocular Inflammation Service.

Patients taking oral corticosteroids and/or systemic IMT at the time of being included in the study, continued on treatment, but the dose was not altered whilst receiving Ranibizumab therapy.

All subjects signed a consent form to participate in the study. The study received UK National Health Service (NHS) research ethics committee approval (NHS REC reference: 09/H0106/5; EudraCT: 2008-007476-19).

Study design

The study was an open label non-randomised Phase IIb trial to evaluate the therapeutic response of intravitreal Ranibizumab on the treatment of inflammatory and idiopathic CNV. Patients were given monthly intravitreal Ranibizumab (0.5mg Lucentis® in 0.05ml) injections for 3 months. Thereafter, re-treatment was based on clinical evidence of persisting activity (using optical coherence tomography (OCT), best-corrected VA (BCVA) and fundus fluorescein angiography (FFA)). The patients were reviewed on a monthly basis for a total of 13 visits. All adverse events were reported.

OCT and BCVA were performed at every visit. BCVA was expressed as letter score (Early Treatment Diabetics Retinopathy Study (ETDRS) notation). FFA (Topcon TCR 50IX) was performed at baseline, months 0, 4, 12, and as required at other visits.

Central subfield thickness (CST) was determined by OCT imaging (Cirrus HD-OCT, Carl Zeiss Meditec AG, Germany), corresponding to the retinal thickness of the central 1 mm area as described in the ETDRS fields.

CNV size and area of leakage were determined manually with the IMAGENet 2000 v2.57 software at month 0, 4, and 12 by one medical retina specialist.

Outcomes

The primary outcome measure was defined as the proportion of patients who lost less than 15 letters of BCVA from baseline at months 4 and 12. Secondary outcome measures were the mean change from baseline in BCVA at months 4 and 12, mean change from baseline in CST measured by OCT at 4 and 12 months, mean change from baseline in total size of CNV complex at 4 and 12 months, change in area of leakage at 4 and 12 months and number of treatments required with Ranibizumab.

Statistical analysis

In patients where data were not available for a particular visit, no substitution of values was performed.

Probabilities of events after intravitreal Ranibizumab were presented as survival curves using the Kaplan Meier method. Descriptive analysis and Wilcoxon non-parametric test were performed for analysis. A p-value <0.05 was considered as statistically significant. Microsoft Excel 2011 (Microsoft Corporation, Redmond, US) and SPSS 20.0 (SPSS Inc., Chicago, US) were used for analysis. All values were expressed as the mean \pm standard deviation (SD).

RESULTS

Fifteen patients were included in the study. There were 10 females (66.7%) and 5 males (33.3%) with a mean age of 48.8 ± 20.5 (mean \pm SD) years, range 24 to 85 years. All the patients completed one-year follow-up. The right eye (OD) was involved in 10 cases (66.7%) and the left eye (OS) in 5 cases (33.3%). The most common diagnosis was uveitic CNV in 9 cases (60.0%). Up to 4 patients (26.7%) were treated with IMT at the beginning of the study and as per protocol continued without subsequent change to dose throughout the study period. Table 2 summarizes the patients' demographics and aetiology of the CNV.

Mean change from baseline in BCVA at months 4 and 12

100% of patients avoided loss of more than 15 letters of vision in the treated eye. The Wilcoxon non-parametric test for related-samples showed a statistically significant difference in BCVA at month 4 (p=0.001) and at month 12 (p=0.001) compared with baseline. The mean BCVA was 53 ± 14.56 letters (mean \pm SD), 73 ± 12.21 letters

(mean \pm SD), and 74 ± 15.02 letters (mean \pm SD) at baseline, 4 months and 12 months respectively. The mean gain in BCVA at month 4 compared with baseline was 20 ± 15.36 letters (mean \pm SD), and at month 12 was 21 ± 16.97 letters (mean \pm SD). Figure 1 shows the mean increase in letters from baseline (at month 0) at follow-up. Seven out of 15 patients (46.7%) improved 15 or more letters in the BCVA at month 4 compared with baseline BCVA and 10 (66.7%) at month 12. Figure 2 shows the Kaplan-Meier curves for the time to increase 15 letters in the BCVA. The median time to increase 15 letters in the BCVA was 5.07 months (95% confidence interval: 2.67 - 7.46). Fourteen out of 15 patients (93.3%) had a stable or improved BCVA at month 12 in comparison with baseline.

Mean change from baseline in CST measured by OCT at months 4 and 12

CST as measured by OCT demonstrated a statistically significant difference in the mean CST at baseline versus month 4 ($p=0.003$) and month 12 ($p=0.001$) with the Wilcoxon non-parametric test for related-samples. The mean CST was $395 \pm 93 \mu\text{m}$, $282.60 \pm 57.79 \mu\text{m}$ and $252 \pm 81 \mu\text{m}$ at baseline, 4 months and 12 months respectively. The mean change in the CST in comparison with the baseline measurement at month 4 was $-112 \pm 111 \mu\text{m}$ and at month 12 was $-143 \pm 109 \mu\text{m}$. Figure 3 shows the mean change in macular thickness from baseline during the follow-up.

Mean change from baseline in total size of CNV and area of leakage at 4 and 12 months

The mean size of the CNV complex at baseline was $1.37 \pm 1.27 \text{ mm}^2$. There was a mean change of the CNV complex at month 4 was of $-0.15 \pm 1.21 \text{ mm}^2$ and -0.67 ± 0.97 at month 12 with respect to baseline measurements. The mean area of leakage at baseline

was $1.88 \pm 1.42 \text{ mm}^2$. The mean change in the area of leakage at month 4 was $-0.72 \pm 1.02 \text{ mm}^2$ and $-1.12 \pm 1.06 \text{ mm}^2$ at month 12.

Number of treatments required with Ranibizumab

The mean number of Ranibizumab injections that patients received during the 12 months of follow-up was 4.33 ± 1.40 (mean \pm SD) injections (range 3 to 7 injections). Particularly the mean number of injections during the 12-months follow-up for the group of idiopathic CNV was 4 ± 1.10 (mean \pm SD) and 4.56 ± 1.59 (mean \pm SD) injections for the group of uveitic CNV. In cases where further injections were needed after the loading phase, the mean time for the 4th injection was 2.51 ± 2.34 (mean \pm SD) months. A total of 6 patients (40%) did not need any further injection after the loading dose, which included 4 uveitic CNV (44.4% of uveitic CNV) and 2 idiopathic CNV (33.3% of idiopathic CNV).

Adverse events

No adverse events or complications presumed related to the study treatment were observed during the study period. One patient reported increase in floaters at month 1, but had no evidence of vitritis on examination.

DISCUSSION

All patients avoided loss of more than 15 letters of vision, and there was a mean increase of 21 letters after treatment at month 12. This study has provided trial evidence to support the current practice and on-going use of Ranibizumab in the treatment of inflammatory CNV. In addition, the treated eyes showed a decrease in the

CST and in the size and leakage of CNV complex at month 4 and 12, supporting the functional improvement noted.

As the design of this phase IIb trial had expected low recruitment, given prevalence of iCNV, the approved protocol was not designed to recruit to permit subsequent determination of differential responses or not between the classes of iCNV (idiopathic versus uveitic CNV). There remains nonetheless in common to both subgroups an inflammatory mediated drive of the iCNV to validate and support our approach [2-19]. Patients were enrolled following a strict trial inclusion and exclusion criteria. Cases of inflammatory CNV with presence of intraretinal fluid only, for example, were excluded, leading to potential ascertainment bias.

Ranibizumab was approved in 2006 for the Food and Drug Administration for the treatment of neovascular age related macular degeneration (AMD). This approval was supported mainly in the outcomes of two pivotal phase III clinical trials: the ANCHOR and MARINA studies [20-21]. In these studies the Ranibizumab treatment group, the 0.5 mg dose, achieved an improvement of 11.3 and 7.2 letters with respect to baseline at 24 months [20-21]. The mean increase in letters in this study at month 12 was 21 letters, infers a superior outcome for the treatment of inflammatory CNV with Ranibizumab and is supported by similar good outcomes in retrospective reports for the treatment with Ranibizumab and Bevacizumab in inflammatory CNV. Some studies have demonstrated an increase of more than 3 lines after treatment [11-17]. The implication therefore from the positive results is that in presence of inflammation there remains a VEGF drive [22]. However, there are only a few histopathological studies and there is a lack of good animal models for inflammatory CNV to ascertain and dissect mechanisms at play. Nevertheless in the few studies that have been undertaken, one notable finding

was a significant expression of CXCR4 in the vascular network of inflammatory CNV [23]. CXCR4/SDF-1 axis is implicated in mTOR- mediated angiogenesis and pathological neovascularisation and expressed on RPE supporting the use of immunosuppression to reduce inflammatory CNV [24].

The specific role of inflammation in the pathogenesis of idiopathic and inflammatory CNV is also supported from other histological studies and the response observed following treatment of inflammatory CNV with immunosuppressive agents [5 6 9 10]. Before anti-VEGFs were available, corticosteroids were the first-line treatment for inflammatory CNV, and in particular corticosteroids in addition to photodynamic therapy were more effective than photodynamic therapy alone [25]. Similarly the combination of high dose of systemic steroids in combination with mycophenolate mofetil showed good control of iCNV, with improved in VA and stabilization of the CNV complex size [6]. In this study, to assess the effect of Ranibizumab alone on the CNV, we purposefully did not alter any immunomodulatory treatment during the 12 month follow-up, where appropriate.

Regarding the CNV complex size and area of leakage, better results than AMD-related CNV were achieved in this study. In the MARINA trial at month 12 in the 0.5mg ranibizumab-treated group there was a decrease in the area of leakage, and stabilisation but not a reduction in the lesion size [21]. In the ANCHOR study, reduction in leakage was also achieved in the 0.5mg ranibizumab-treated group, but there was no reduction in the area of the overall CNV complex. Only when the classic CNV component alone was assessed was there some reduction in CNV size demonstrated ($-0.67 \text{ mm}^2 \pm 1.10$ at 12 months) [20].

The mean number of injections in the previously reported series for Bevacizumab in iCNV was around 2 injections (range 1-4.25) and around 3 injections (range 1-4) in the

case of Ranibizumab [22]. There was a higher number of injections utilised in this trial (mean of 4.33 injections). This is likely to be related to the use of the loading doses and our strict follow up regimen [11 22].

Although this study has limitations inherent to small phase IIb trials where definitive evidence of efficacy cannot be determined with small numbers of patients and in this trial, the lack of a control group, there nonetheless remains further proof of concept to support the use of Ranibizumab alone (without additional increase in the baseline IMT).

ACKNOWLEDGEMENTS

Supported in part by a grant from Novartis Pharmaceuticals UK Limited, Frimley, UK.

No member or affiliate of Novartis had any input into data analysis, interpretation of the data, or writing the manuscript.

The research supported by the National Institute for Health Research (NIHR)

Biomedical Research Centre based at Moorfields Eye Hospital NHS Foundation Trust and UCL Institute of Ophthalmology. The views expressed are those of the authors and not necessarily those of the NHS, the NIHR or the Department of Health.

REFERENCES

1. Baxter SL, Pistilli M, Pujari SS, et al. Risk of choroidal neovascularization among the uveitides. *American journal of ophthalmology* 2013;**156**(3):468-77 e2 doi: 10.1016/j.ajo.2013.04.040[published Online First: Epub Date]].
2. Machida S, Fujiwara T, Murai K, Kubo M, Kurosaka D. Idiopathic choroidal neovascularization as an early manifestation of inflammatory chorioretinal diseases. *Retina* 2008;**28**(5):703-10 doi: 10.1097/IAE.0b013e318160798f[published Online First: Epub Date]].
3. Laser photocoagulation for juxtafoveal choroidal neovascularization. Five-year results from randomized clinical trials. Macular Photocoagulation Study Group. *Archives of ophthalmology* 1994;**112**(4):500-9
4. Olsen TW, Capone A, Jr., Sternberg P, Jr., Grossniklaus HE, Martin DF, Aaberg TM, Sr. Subfoveal choroidal neovascularization in punctate inner choroidopathy. Surgical management and pathologic findings. *Ophthalmology* 1996;**103**(12):2061-9
5. Rechtman E, Allen VD, Danis RP, Pratt LM, Harris A, Speicher MA. Intravitreal triamcinolone for choroidal neovascularization in ocular histoplasmosis syndrome. *Am J Ophthalmol* 2003;**136**(4):739-41
6. Neri P, Manoni M, Fortuna C, Lettieri M, Mariotti C, Giovannini A. Association of systemic steroids and mycophenolate mofetil as rescue therapy for uveitic choroidal neovascularization unresponsive to the traditional immunosuppressants: interventional case series. *Int Ophthalmol* 2010;**30**(5):583-90 doi: 10.1007/s10792-009-9323-x[published Online First: Epub Date]].
7. Leslie T, Lois N, Christopoulou D, Olson JA, Forrester JV. Photodynamic therapy for inflammatory choroidal neovascularisation unresponsive to immunosuppression. *Br J Ophthalmol* 2005;**89**(2):147-50 doi: 10.1136/bjo.2004.046623[published Online First: Epub Date]].
8. Giovannini A, Neri P, Mercanti L, Brue C. Photodynamic treatment versus photodynamic treatment associated with systemic steroids for idiopathic choroidal neovascularisation. *Br J Ophthalmol* 2007;**91**(5):620-3 doi: 10.1136/bjo.2006.103135[published Online First: Epub Date]].
9. Mateo-Montoya A, Baglivo E, de Smet MD. Intravitreal methotrexate for the treatment of choroidal neovascularization in multifocal choroiditis. *Eye* 2013;**27**(2):277-8 doi: 10.1038/eye.2012.262[published Online First: Epub Date]].
10. Nussenblatt RB, Coleman H, Jirawuthiworavong G, et al. The treatment of multifocal choroiditis associated choroidal neovascularization with sirolimus (rapamycin). *Acta ophthalmologica Scandinavica* 2007;**85**(2):230-1 doi: 10.1111/j.1600-0420.2006.00858.x[published Online First: Epub Date]].
11. Mansour AM, Mackensen F, Mahendradas P, Khairallah M, Lai TY, Bashshur Z. Five-year visual results of intravitreal bevacizumab in refractory inflammatory ocular neovascularization. *Clin Ophthalmol* 2012;**6**:1233-7 doi: 10.2147/OPTH.S34294[published Online First: Epub Date]].

12. Rouvas A, Petrou P, Douvali M, et al. Intravitreal ranibizumab for the treatment of inflammatory choroidal neovascularization. *Retina* 2011;**31**(5):871-9 doi: 10.1097/IAE.0b013e3182003ca8[published Online First: Epub Date]].
13. Julian K, Terrada C, Fardeau C, et al. Intravitreal bevacizumab as first local treatment for uveitis-related choroidal neovascularization: long-term results. *Acta Ophthalmol* 2011;**89**(2):179-84 doi: 10.1111/j.1755-3768.2010.02046.x[published Online First: Epub Date]].
14. Lott MN, Schiffman JC, Davis JL. Bevacizumab in inflammatory eye disease. *Am J Ophthalmol* 2009;**148**(5):711-17 e2 doi: 10.1016/j.ajo.2009.06.010[published Online First: Epub Date]].
15. Mansour AM, Arevalo JF, Ziemssen F, et al. Long-term visual outcomes of intravitreal bevacizumab in inflammatory ocular neovascularization. *Am J Ophthalmol* 2009;**148**(2):310-16 e2 doi: 10.1016/j.ajo.2009.03.023[published Online First: Epub Date]].
16. Tran TH, Fardeau C, Terrada C, Ducos De Lahitte G, Bodaghi B, Lehoang P. Intravitreal bevacizumab for refractory choroidal neovascularization (CNV) secondary to uveitis. *Graefes Arch Clin Exp Ophthalmol* 2008;**246**(12):1685-92 doi: 10.1007/s00417-008-0906-4[published Online First: Epub Date]].
17. Adan A, Mateo C, Navarro R, Bitrian E, Casaroli-Marano RP. Intravitreal bevacizumab (avastin) injection as primary treatment of inflammatory choroidal neovascularization. *Retina* 2007;**27**(9):1180-6 doi: 10.1097/IAE.0b013e31815e9834[published Online First: Epub Date]].
18. Iannetti L, Paroli MP, Fabiani C, Nardella C, Campanella M, Pivetti-Pezzi P. Effects of intravitreal bevacizumab on inflammatory choroidal neovascular membrane. *European journal of ophthalmology* 2012;0 doi: 10.5301/ejo.5000192[published Online First: Epub Date]].
19. Papadia M, Herbort CP. Idiopathic choroidal neovascularisation as the inaugural sign of multiple evanescent white dot syndrome. *Middle East Afr J Ophthalmol* 2010;**17**(3):270-4 doi: 10.4103/0974-9233.65490[published Online First: Epub Date]].
20. Brown DM, Michels M, Kaiser PK, et al. Ranibizumab versus verteporfin photodynamic therapy for neovascular age-related macular degeneration: Two-year results of the ANCHOR study. *Ophthalmology* 2009;**116**(1):57-65 e5 doi: 10.1016/j.opthta.2008.10.018[published Online First: Epub Date]].
21. Rosenfeld PJ, Brown DM, Heier JS, et al. Ranibizumab for neovascular age-related macular degeneration. *The New England journal of medicine* 2006;**355**(14):1419-31 doi: 10.1056/NEJMoa054481[published Online First: Epub Date]].
22. D'Ambrosio E, Tortorella P, Iannetti L. Management of uveitis-related choroidal neovascularization: from the pathogenesis to the therapy. *J Ophthalmol* 2014;**2014**:450428 doi: 10.1155/2014/450428[published Online First: Epub Date]].
23. Guerin E, Sheridan C, Assheton D, et al. SDF1-alpha is associated with VEGFR-2 in human choroidal neovascularisation. *Microvascular research* 2008;**75**(3):302-7 doi: 10.1016/j.mvr.2007.12.001[published Online First: Epub Date]].

24. Ziegler M, Hughes C. The SDF-1/CXCR4 axis utilizes mTOR signal transduction to promote angiogenesis (278.8). The FASEB Journal 2014;**28**(1 Supplement)
25. Dhingra N, Kelly S, Majid MA, Bailey CB, Dick AD. Inflammatory choroidal neovascular membrane in posterior uveitis-pathogenesis and treatment. Indian journal of ophthalmology 2010;**58**(1):3-10 doi: 10.4103/0301-4738.58467[published Online First: Epub Date]].

TABLE 1

| Inclusion criteria |
|--|
| <p>Patients with newly presenting idiopathic and inflammatory choroidal neovascularisation with:</p> <ul style="list-style-type: none"> ❖ Best-corrected ETDRS notation VA in the study eye between 73-24 letters. ❖ CNV lesion of any type in the study eye with the following characteristics as determined by fluorescein angiography. <ul style="list-style-type: none"> ➤ The lesion must be ≤ 5400 microns in greatest linear dimension. ➤ No subfoveal atrophic change, no subfoveal fibrosis. Area of fibrosis less than or equal to 50% of total lesion area. ➤ For occult with no classic CNV, the lesion must have presumed recent disease progression as assessed by the Investigator and defined as having at least one of the following criteria: <ul style="list-style-type: none"> ▪ Blood associated with the lesion at baseline. ▪ $\geq 10\%$ increase in the greatest linear dimension as assessed by fluorescein angiography in the previous 3 months. ▪ Loss of VA in the previous 3 months defined as either ≥ 5 letters logMAR vision as determined by protocol refraction and protocol measurement or 2 or more lines using a Snellen chart by standard examination. ❖ Presence of subretinal fluid on OCT ❖ Patients over the age of 18 |
| Exclusion criteria |
| <ul style="list-style-type: none"> ❖ Prior treatment with transpupillary thermotherapy, thermal laser, or PDT in the study eye. ❖ Treatment with verteporfin in the non-study eye less than 7 days preceding Day 0. ❖ Previous participation in a clinical trial (for either eye) involving anti-angiogenic drugs (Macugen®, Avastin®, anecortave acetate). ❖ History of vitrectomy surgery, greater than mild non-proliferative diabetic retinopathy or any diabetic maculopathy, retinal vascular occlusions, glaucoma filtering surgery, or corneal transplant in the study eye. ❖ Previous participation in any studies of investigational drugs within 1 month preceding Day 0 (excluding vitamins and minerals). ❖ Subretinal haemorrhage in the study eye that involves the centre of the fovea, if the size of the haemorrhage is either $>50\%$ of the total lesion area or >1 disc areas in size. ❖ Subfoveal fibrosis or atrophy in the study eye. Area of fibrosis $> 50\%$ of total lesion area. ❖ Retinal pigment epithelial tear involving the macula in the study eye. |

- ❖ Any concurrent intraocular condition in the study eye (e.g., cataract or diabetic retinopathy) that, in the opinion of the investigator, could either require medical or surgical intervention during the 12-month study period to prevent or treat visual loss that might result from that condition, or if allowed to progress untreated, could likely contribute to loss of at least 2 Snellen equivalent lines of best corrected visual acuity over the 12-month study period.
- ❖ Current vitreous haemorrhage in the study eye.
- ❖ History of rhegmatogenous retinal detachment or macular hole (Stage 3 or 4) in the study eye.
- ❖ Infectious conjunctivitis, keratitis, scleritis, or endophthalmitis in either eye.
- ❖ Aphakia or absence of the posterior capsule in the study eye.
- ❖ Previous violation of the posterior capsule in the study eye, unless it occurred as a result of YAG posterior capsulotomy in association with prior, posterior chamber intraocular lens implantation.
- ❖ Spherical equivalent of the refractive error in the study eye demonstrating more than -8 dioptres of myopia or signs of pathologic myopia with a refraction of (-4)-(-8) dioptres.
- ❖ For subjects who have undergone prior refractive or cataract surgery in the study eye, the preoperative refractive error in the study eye cannot exceed -8 dioptres of myopia.
- ❖ Intraocular surgery (including cataract surgery) in the study eye within 2 months preceding Day 0.
- ❖ Uncontrolled glaucoma in the study eye (defined as intraocular pressure >30 mmHg despite treatment with anti-glaucoma medication).
- ❖ Premenopausal women not using adequate contraception (considered effective means of contraception: surgical sterilisation; use of oral contraceptives; barrier contraception with either a condom or diaphragm in conjunction with spermicidal gel; an IUD; or contraceptive hormone implant or patch).
- ❖ Pregnant and lactating women.
- ❖ History of other disease, metabolic dysfunction, physical examination finding, or clinical laboratory finding giving reasonable suspicion of a disease or condition that contraindicates the use an investigational drug or that might affect interpretation of the results of the study or render the subject at high risk for treatment complications
- ❖ Current treatment for active systemic infection.
- ❖ Recent stroke, or cardiac event, uncontrolled angina or hypertension.
- ❖ History of allergy to fluorescein.
- ❖ Inability to obtain fundus photographs or fluorescein angiograms of sufficient quality to be analysed.
- ❖ Inability to comply with study or follow-up procedures.

Table 1.- Inclusion and exclusion criteria for the study. CNV: Choroidal neovascularization. ETDRS: Early Treatment Diabetic Retinopathy Study. VA: Visual acuity. PDT: Photodynamic therapy.

TABLE 2

| PATIENT ID | GENDER | STUDY EYE | AGE | DIAGNOSIS | Baseline VA | IMT | NI |
|------------|--------|-----------|-----|----------------|-------------|------|----|
| 1 | Male | OD | 57 | Idiopathic CNV | 71 | NO | 6 |
| 2 | Male | OS | 47 | Idiopathic CNV | 42 | YES* | 3 |
| 3 | Female | OD | 72 | Uveitic CNV | 54 | NO | 3 |
| 4 | Female | OS | 26 | Uveitic CNV | 29 | NO | 6 |
| 5 | Female | OS | 20 | Idiopathic CNV | 47 | NO | 3 |
| 6 | Female | OD | 36 | Idiopathic CNV | 59 | NO | 4 |
| 7 | Male | OS | 48 | Uveitic CNV | 48 | YES | 6 |
| 8 | Female | OD | 37 | Idiopathic CNV | 71 | NO | 4 |
| 9 | Male | OD | 80 | Uveitic CNV | 64 | YES | 5 |
| 10 | Female | OD | 31 | Uveitic CNV | 48 | NO | 3 |
| 11 | Female | OD | 56 | Uveitic CNV | 54 | NO | 3 |
| 12 | Male | OD | 68 | Uveitic CNV | 73 | YES | 3 |
| 13 | Female | OS | 45 | Uveitic CNV | 69 | NO | 5 |
| 14 | Female | OD | 24 | Idiopathic CNV | 34 | NO | 4 |
| 15 | Female | OD | 85 | Uveitic CNV | 34 | NO | 7 |

Table 2. Summary of patients' demographics, diagnosis, visual acuity at baseline visit (expressed in ETDRS notation), concomitant use of oral immunomodulatory treatment during study follow-up and number of intravitreal injections. Uveitic CNV included as phenotypic diagnosis: 3 - punctate inner choroidopathy, 2 - serpiginous choroidopathy, 1 - presumed ocular histoplasmosis syndrome, 1 - sarcoidosis, 1 - toxoplasma chorioretinitis, and 1 -multifocal choroiditis with panuveitis. OD: Right eye. OS: Left eye. CNV: Choroidal neovascularization. IMT: Immunomodulatory treatment. NI: number of injections.

*: Patient number 2 was on oral IMT due to kidney transplant.

FIGURE LEGENDS:

Figure 1.- Line diagrams representing mean change in BCVA at each study visit with respect to baseline. Mean change in BCVA is represented as the number of letters (ETDRS notation). Error bars represent +/- 2 of the standard error. BCVA: Best corrected visual acuity. ETDRS: Early Treatment Diabetic Retinopathy Study. SE: Standard Error.

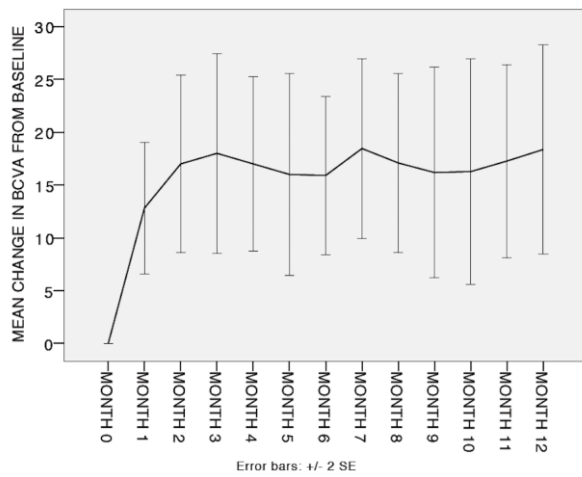


Figure 2.- Kaplan Meier representation of the time to increase BCVA in 15 letters. BCVA: Best corrected visual acuity.

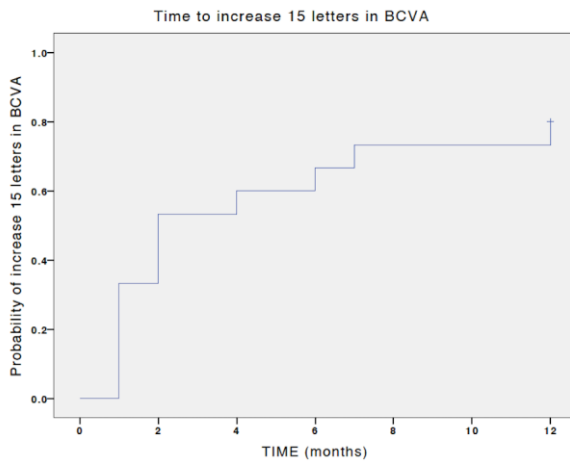


Figure 3.- Line diagrams representing mean change in CST at each study visit with respect to baseline. Mean change in CST is represented in μm . Error bars represent ± 2 of the standard error. CST: Central subfield thickness. SE: Standard Error.

