

THE EFFECTS OF CORTICOTOMIES ON FRONTAL NASAL SUTURE EXPANSION  
AND BONE MODELING IN MATURE RABBITS

A Thesis

by

BRITTANY M. WRIGHT

Submitted to the Office of Graduate and Professional Studies of  
Texas A&M University  
in partial fulfillment of the requirements for the degree of

MASTER OF SCIENCE

Chair of Committee,	Peter H. Buschang
Committee Members,	Phillip M. Campbell
	Lynne A. Opperman
Head of Department,	Phillip M. Campbell

May 2015

Major Subject: Oral Biology

Copyright 2015 Brittany Marcelle Wright

## ABSTRACT

The purpose of this split skull study was designed to evaluate whether corticotomies enhance bone modeling and reduces the resistance of surrounding articulations during expansion in mature rabbits.

Nine adult female New Zealand White (NZW) rabbits, 8 to 9 months old, had miniscrew implant (MSI) supported expansion devices with 150 g open-coil nickel-titanium springs placed bilaterally across the frontonasal sutures. Corticotomies were performed on one randomly chosen side, anterior and posterior to the frontonasal suture; the other side served as the control. Sutural separation was measured bi-weekly for 7 weeks. Using microCT scans of each specimens, bone material density (mg HA/ccm) and bone volume fraction (BV/TV) were measured. Qualitative histologic analyses of the suture tissues were performed using H&E staining.

Most (94.4%) of the MSIs remained stable throughout the experiment. There was significantly ( $p < .05$ ) more sutural separation on the corticotomy side (3.73 mm) than the control side (2.83 mm). There was no statistically significant side difference in bone volume fraction ( $p = .26$ ) and bone density ( $p = .11$ ). The amount of expansion that occurred was negatively correlated ( $R = -.860$ ;  $p < .001$ ) with bone density. Blinded histological examination showed an increased density of osteoblasts, with a blastema-like appearance, along the bone fronts on the corticotomy side. Numerous elongated Sharpey's fiber insertions and a mixture of immature woven bone, with numerous osteocytes, were visible at the sutural margins on the corticotomy side, indicating the formation of new bone.

In conclusion, mature sutures expanded with adjunctive corticotomies undergo 31% more separation than sutures expanded without corticotomies with the amount of expansion that occurs being inversely related to bone density.

## DEDICATION

“La casa no se reclina sobre la tierra, sino sobre una mujer.”

This thesis is dedicated to my grandmother, Myrtis McHardy, a woman with an eighth grade education who scrubbed floors and took in sewing to give her eight children a life she never knew. I barely remember her, but I know the sacrifices she made to give me the best life possible. She is my inspiration and I know her love got me to this point.

“The house does not rest upon the ground, but upon a woman.”

## ACKNOWLEDGEMENTS

I would like to thank my committee chair, Dr. Buschang, and my committee members, Dr. Campbell and Dr. Opperman, for their guidance and support throughout the course of this research. Thank you for sharing your incredible wisdom and insight with me and for helping me become the best researcher and clinician I can be.

Thank you to my friends and colleagues at BCD and the department faculty and staff for making my time at Texas A&M University a great experience. I also want to extend my gratitude to the Robert E. Gaylord Endowed chair and distinguished alumni Department of Orthodontics for making this research possible. Thank you to my co-residents for enduring this journey with me.

Finally, thanks to my parents and siblings for their encouragement; to my husband, Marvin, for his patience and love; and to my best friend, Simone, for listening.

## NOMENCLATURE

RME/RPE	Rapid maxillary expansion/ rapid palatal expansion
SARPE	Surgically assisted rapid palatal expansion
MSIs	Mini screw implants
RAP	Regional acceleratory phenomenon

## TABLE OF CONTENTS

	Page
ABSTRACT.....	ii
DEDICATION.....	iii
ACKNOWLEDGEMENTS.....	iv
NOMENCLATURE.....	v
TABLE OF CONTENTS.....	vi
LIST OF FIGURES.....	viii
LIST OF TABLES.....	ix
CHAPTER I INTRODUCTION AND LITERATURE REVIEW.....	1
History of sutural expansion.....	1
Biology of sutural expansion.....	2
Sutural growth.....	4
Anatomy and histologic structure of craniofacial sutures.....	4
Changes of the suture with age.....	5
Surgical options for transverse correction in adults.....	11
Attempts at non-surgical maxillary expansion in adults.....	13
Corticotomies as adjunct for non-surgical expansion.....	14
An animal model for evaluating adult expansion.....	18
CHAPTER II PURPOSE AND SIGNIFICANCE.....	20
CHAPTER III MATERIALS AND METHODS.....	22
Animals.....	22
Experimental design.....	22
MSI insertion, bone marker placement, and force delivery.....	22
Measurements.....	24
Tissue Preparation for $\mu$ CT analysis.....	25
Bone volume fraction and density measurements.....	25
Tissue preparation for histologic analysis.....	26
Statistical analysis.....	26

CHAPTER IV RESULTS.....	28
Biometric analysis and measurements.....	28
Bone volume fraction and bone density measurements.....	29
Histologic and histomorphometric comparisons.....	29
CHAPTER V DISCUSSION.....	31
CHAPTER VI CONCLUSIONS.....	38
REFERENCES.....	39
APPENDIX A FIGURES .....	45
APPENDIX B TABLES.....	48

## LIST OF FIGURES

	Page
Figure 1 Methodology, experimental design, and expansion apparatus.....	45
Figure 2 H&E stained Specimen A comparing control and corticotomy sides.....	46
Figure 3 H&E stained Specimen B comparing control and corticotomy sides.....	47



## LIST OF TABLES

	Page
Table 1 Sutural separation measured between bone markers.....	48
Table 2 Sutural separation measured between mini screws implants.....	49
Table 3 Correlation between bone material density and sutural separation.....	50
Table 4 Comparison of bone volume fraction of corticotomy and control sides.....	51
Table 5 Comparison of bone material density of corticotomy and control sides.....	52

## CHAPTER I

### INTRODUCTION AND LITERATURE REVIEW

This literature review consists of a brief overview of the history and biology of sutural expansion followed by a review of our current understanding of sutural growth and the histologic structure of craniofacial sutures. Next, a discussion of the changes of sutures associated with age and a review of proposed impediments to sutural expansion in adults including increased sutural complexity, sutural obliteration, resistance from circummaxillary sutures, and decreased cellular response. Afterwards, the current options for transverse corrections in adults including Lefort osteotomy and surgically assisted rapid palatal expansion (SARPE) are discussed followed by the available literature documenting attempts at non-surgical expansion in adults and its' limitations. The use of corticotomies as an adjunctive procedure is introduced as well as evidence for the regional acceleratory phenomenon, the biological justification for corticotomies. Finally, the selection of a rabbit animal model to separate the frontonasal suture is reviewed.

#### **History of sutural expansion**

Emerson C Angell first reported the use of an uncemented maxillary expansion device in 1860. He claimed formation of a diastema as evidence of sutural separation after two weeks. However, his report drew criticism among his dental colleagues due to the lack of the diastema in the published drawing. The prevailing belief at the time was

that expansion of the midpalatal suture was ‘exceedingly doubtful’ because it would render the maxilla loose [1]. At the time, many influential American orthodontists like Angle and Ketcham were indifferent to the procedure and most likely responsible for its discontinuance in the US. However, many Europeans continued to explore expansion and its possibilities. After a visit by a European orthodontist named Korkhaus to the University of Illinois, Allan Brodie and Andrew Haas became interested in the possibilities of maxillary expansion. Based on their subsequent animal experiment using pigs, they found the suture expanded up to 15 mm in 2 weeks [2]. They also noted the passive uprighting of mandibular teeth and an increase in nasal width. Haas then proceeded to maxillary expansion in humans. By 1965, he documented 80 cases that showed clinical and radiographic evidence of maxillary sutural separation[3]. Since the 1960s, rapid maxillary expansion (RME) has become widely used by orthodontists to correct crossbites resulting from maxillary transverse discrepancies, to gain arch length by reducing tooth size/arch length discrepancies [3], and even to decrease nasal airway resistance [4].

### **Biology of sutural expansion**

Cleall et al. described the tissue response that occurs during sutural expansion in 10 juvenile rhesus monkeys, which they compared to two control monkeys at 2 weeks and 3 months post expansion [5]. The sutural connective tissue adapts to the heavy forces by cell proliferation to physically separate the palatine processes followed by bone deposition in the suture to maintain its morphology. These authors confirmed

Angell's hypothesis that the midpalatal suture had been split and that the suture created new bone to eventually return to its original form [5].

Ten Cate et al. detailed that sutural expansion consists of osteogenesis and fibrillogenesis followed by remodeling during orthopedic expansion [6]. Studying the histology of rat sutures at several time points ranging from 1 hour to 42 days after expansion, they documented the chronology of orthopedically separated sutures on a cellular level. As an orthopedic force is applied the suture, torn collagen fibrils within the suture fill with an exudate, while the periosteum remained unaffected. Within 24 hours, an influx of fibroblasts form collagen and macrophages remove the exudate. After 3-4 days the existing osteoblasts lay down new bone at the margin of the expanding suture. During the next 14 days, lamellae form along the margin. Once the expansion force dissipated, remodeling of the bone and suture began until the sutural morphology returned to normal [6]. The authors suggested that a repair phenomenon occurred in the fibroblasts composing the suture's connective tissue, which allows remodeling and regeneration of the suture [6]. This distinguishes sutures from other tissues where scar tissue formation would normally occur.

The sutures allow the craniofacial complex to maintain its' adaptability through their remodeling potential. Brandt et al. noted the termination of active sutural growth is of little significance to the remodeling potential of sutural articulations and the morphologic adaptability of the facial skeletal complex [7]. The suture remodeling that occurs from palatal expansion is an example of how sutures adapt and respond to an orthopedic force. In the midpalatal suture, expansion promotes bone resorption through

increased osteoclast activity as well as active proliferation of periosteal cells to form new bone and cartilage [8]. All of these studies describe the biological mechanism of sutural expansion and provide evidence that expansion alone can induce suture remodeling.

### **Sutural growth**

Sutures are fully formed during the embryonic period by week 17 [9]. During postnatal craniofacial growth, the sutures separate in response to growing tissues or organs. For example, as the brain grows the calvaria has to expand to accommodate this growth. This separation stretches sutural fibers leading to differentiation of osteoprogenitor cells. Sutures must remain in an unossified state while new unmineralized bone, or osteoid, is added at advancing bone fronts to keep the suture the same width [10]. As intramembranous bone growth sites, sutures have no intrinsic growth potential. They only remodel or grow in response to their surrounding tissues. Signals sent from the expanding neurocranium stimulate bone growth at the edges of the sutures. These signals also allow the suture to remain unossified preventing sutural obliteration or fusion of the bone fronts on either side of the suture [10]. Depending on anatomic location, these sutures may overlap, as in beveled sutures or have abutting edges. Midline sutures, classified as butt-end sutures, do not overlap [9].

### **Anatomy and histologic structure of craniofacial sutures**

Craniofacial sutures unite the bones of the cranium and facial complex while allowing minor movement of bones in response to growth of the brain and the entire

craniofacial complex. The sutures are sites of growth that can absorb mechanical stress in order to protect osteogenic tissue [11]. Pritchard et al. examined six species throughout development (humans, sheep, pigs, rats, cats, and rabbits) and found that developing sutures contain two uniting layers of fibrous lamina (internal and external) and five intervening layers containing a middle zone of highly vascularized type I collagen and a highly cellular layer that is an osteogenic site [12]. The facial sutures develop in loose mesenchyme while the cranial sutures develop in preformed fibrous membrane surrounding the developing brain, but histologically the sutures are identical [12]. Kokich confirmed Pritchard's five intervening layers and showed that they became three condensed layers – two fibrous outer layers and a highly cellular middle zone after birth. This middle zone can be histologically separated into zones of ossification with an inner mineralized zone, a midzone of osteoid matrix, and a peripheral zone of differentiating cells [13].

### **Changes of the suture with age**

A survey conducted by Korbmacher et al. found that many clinicians regard patient age as a limiting factor for using a rapid palatal expander (RPE) [14]. Older patients with more complicated sutures present a particular challenge that may require surgical correction. The proposed impediments to adult sutural expansion include sutural complexity, sutural fusion, the surrounding articulations from the circummaxillary sutures, and the decreased cellular response of the adult suture.

### *Sutural complexity*

Orthopedic expansion is thought to be less successful in adults because the midpalatal suture increases in complexity as a person ages. In 1975, Melsen evaluated the sutures of 60 cadavers 0 to 18 years of age and found increasing interdigitation of the suture with age. In another histological study comprised of 30 skulls, numerous bridged formations were noted in these sutures [15]. Melsen concluded that separating the suture after a certain age would not be possible without fracturing these processes. Actually, the increasing interdigitation could relate more to functional demands and the force absorption of the suture [16]. The morphology of the suture and degree of interdigitation has been correlated with levels of cranial stress [17, 18]. Additionally, the direction of the force is responsible for the particular pattern of interdigitation and orientation of fibers [19]. Some authors think the broad, interdigitating structure of sutures may form to resist the vertical component of masticatory compressive forces while other authors speculate that tensional forces are responsible for the formation of bony bridges across the sutures [20-22]. Ultimately, the complexity and interdigitation seen in sutures is more related to the forces the sutures are subjected to rather than an intrinsic aging phenomenon.

### *Sutural obliteration*

Persson and Thilander related midpalatal sutural obliteration (areas of the suture with bone to bone contact) with age. They examined 24 necropsy specimens of various ages and calculated an obliteration index to quantify suture closure. To calculate the

obliteration index the oronasal length of the open suture was measured and compared to the length of the obliterated areas. They set an arbitrary limit of 5% obliteration for splitting the intermaxillary suture with RME and found that this threshold was not reached in most patients younger than 25 years of age. Due to large inter-individual variation, this may not be reached until much later [11].

A more recent study using microCT, however, showed less obliteration than previously thought. Korbmacher et al. used palate cadaver specimens aged 14 to 71 and found that age did not correlate with the obliteration index. The index of their entire sample ranged from 0% to 7.3%. These authors concluded that sutural obliteration does not play a role in increasing difficulty in obtaining orthopedic expansion in adults [23].

Based on their evaluation, Knaup et al. came to this same conclusion. They autopsied the palates of 22 individuals, who were separated into groups younger and older than 25 years of age. The obliteration index of the older group ranged from 0 to 8.9% with a median obliteration index of 3.11% [24]. Again, this supports the idea that sutural fusion is low in all age groups and that there is large inter-individual variability seen.

### *Circummaxillary sutures*

The maxilla articulates with a number of other bones that are affected by maxillary expansion. Just like the midpalatal suture, the complexity of these sutural articulations is another limiting factor. Comparing RPE therapy on a dry skull of an adult and a child with mixed dentition, Wertz found that he was able to split the mid-palatal



suture of both, but the response on the articulations differed. In the mixed dentition skull, 44 quarter turns (the limit of the device) were successful. Wertz noted that the maxilla was severely displaced from the nasal, frontal, and ethmoid bones and the vomer was dislodged. Occlusally, the midpalatal suture was separated completely from anterior nasal spine (ANS) to posterior nasal spine (PNS), with the anterior portion being significantly wider. The suture also widened more inferiorly (closer to the force of application) than superiorly. In the adult skull, the rigidity of the articulations prevented opening of the device beyond 22 quarter mm turns [25].

The results from Wertz's study are consistent with studies using finite element analysis to examine the effects of rapid maxillary expansion on dried adult human skulls. Shyamsunder et al. used a dried skull from a 20 year old female [26]. The transverse orthopedic forces produced high forces at the intermaxillary suture, as well as at surrounding articulations like the base of the sphenoid bone and frontal process of the zygomatic bone. They also noted lateral bending of the pterygoid plates suggesting that they resist expansion more than the zygomatic buttresses. Other authors have used similar methodologies and obtained similar results [27, 28]. Their conclusions indicate accumulating orthopedic expansive forces were resisted by surrounding articulations and those forces were dissipated to areas like the base of the sphenoid bone, frontal process of the zygomatic bone and pterygoid plates [25-28]. Thus, some of the resistance to expansion is attributable to surrounding articulations.

However, the literature also supports these same articulating sutures have remodeling potential as well. In 1978, Nanda evaluated the effects of maxillary

protraction using 9 rhesus monkeys (3 adult experimentals, 3 growing experimentals, and 3 growing controls). The circummaxillary sutures, which include the zygomaticomaxillary, zygomatico-temporal, zygomaticofrontal, and frontomaxillary, showed areas of new bone apposition and bone resorption following protraction. On one side, suture fibers were stretched and bone formation was seen at resting lines while other areas showed compressed fibers and osteoclastic activity. The direction of the stretched bundle fibers in the suture corresponded with the direction of the force application, which in the case of maxillary protraction is anterior-posterior [29].

In 1979, Jackson et al. performed a similar study using four late mixed dentition primates and found dramatic remodeling of the circummaxillary sutures as well as extensive resorption and bone formation of the pterygomaxillary fissure in response to extraoral maxillary protraction. They noted that the greatest amount of remodeling was seen in the sutures in closest proximity to the force [30]. Their results are consistent with Nanda's study. Essentially, the sutures adapt and respond to an orthopedic force through a cellular response leading to both bone deposition and bone resorption.

#### *Decreased cellular response of mature sutures*

Decreasing cellularity and remodeling potential has also been implicated as a limiting factor in maxillary expansion in adults. A biological explanation could be that the increasingly fibrous suture of mature individuals has fewer stem cells capable of proliferation. These stem cell populations may require a period of time to proliferate before expansion can occur. While the cellularity does seem limited compared to

younger individuals, it has been shown to still be present. Brin et al. expanded the sutures of young and mature cats and found that the cyclic nucleotides (cGMP and cAMP) found in osteoprogenitor cells, osteoblasts, and young osteocytes-- the cells responsible for bone formation, are decreased, but are still present [16]. The lack of intense staining for cyclic nucleotides of the osteoblasts in the older cats may signify a decline in the cellular ability to respond to mechanical stimuli. The decreased cellular response, which indicates reduced rates of protein synthesis and secretion, also explains the reduction of newly formed bone matrix in the expanded palate of the mature cats in comparison to the younger subjects. Others authors have found that the cells responsible for bone formation and resorption are still present in mature sutures [6].

Based on this information, suture patency which is necessary for maxillary expansion and nasomaxillary protraction should be feasible since only limited suture obliteration occurs. Additionally, the cellularity of mature sutures may be limited, but it has been shown that the necessary cells are still present. The challenge lies in separating the complex interdigitations and inducing the appropriate cellular response that will remodel the targeted sutures and any surrounding articulations. Currently, there are no predictable methods to achieve this and most orthodontists rely on surgical correction of maxillary transverse problems in mature individuals.

## **Surgical options for transverse correction in adults**

### *Lefort osteotomy*

The LeFort I osteotomy is commonly used for the correction of malocclusion and maxillomandibular deformities [31]. The segmentation and downfracture of the maxilla allows for movement in all three planes of space. The procedure is indicated for treating Class II and III malocclusions, as well as dentofacial asymmetries, midface hypoplasia and vertical maxillary excess. Using a reciprocating saw, transverse maxillary osteotomies directed towards the piriform rim are performed bilaterally on the maxillary buttress. A thin osteotome is used to complete posterior osteotomies on the medial and lateral maxillary buttress. After the nasal septum is separated from the maxilla, the procedure is completed by separating the pterygopalatine junction from the maxillary tuberosity with a curved osteotome [31]. As with any surgical procedure, there are a host of potentially life-altering complications including infections ranging from sinusitis to brain abscess, blindness, hemorrhage, palsy of the oculomotor nerve, and/or damage to the Eustachian tube. The surgical technique and type of movement also determines the amount of relapse. Widening the maxilla is considered the least stable and most problematic surgical procedure [32]. The amount of relapse is greater in the molar region than the premolar region, but 30% of patients have more than 3 mm of relapse in expansion across the molars due to the elastic rebounding force from stretching the palatal soft tissues [32].

*SARPE: The current treatment for maxillary expansion in adults*

Previous case reports have documented treatment of adult patients with ‘corticotomies’ and maxillary expansion. Lines documented cases of three non-growing patients successfully treated with corticotomies and maxillary expansion [33]. Mossaz et al. treated four adult patients with unilateral and bilateral transverse discrepancies with corticotomies and expansion with stable results 12 months post retention [34]. However, both of these case series define corticotomies differently than the proposed methodology this thesis will explore. Their surgical procedures involved horizontal and sagittal osteotomies that separated the maxilla into mobile segments, but did not downgraft the maxilla like a Lefort I osteotomy. Since the surgical procedures described in these respective case series are essentially the same as a surgically assisted rapid palatal expansion (SARPE) the morbidity of these procedures should be similar as well.

SARPE requires a horizontal osteotomy below the nasal aperture and a midsagittal osteotomy extending from the anterior alveolar crest through the palate that essentially separates the maxilla from the cranium. After the maxillary components are mobilized, an expansion device (tooth or bone borne) is placed. The morbidity as well as costs associated with this procedure can be a limiting factor in orthodontic treatment of mature patients. Reported complications include significant hemorrhage, gingival recession, root resorption, injury to branches of the maxillary nerve, infection, pain, and devitalization of teeth [35]. Many patients are simply unwilling to undergo surgery due to financial expense, fear of complications and the recovery time.

### **Attempts at nonsurgical maxillary expansion in adults**

The existing literature contains large variability regarding successful non surgical maxillary expansion in adults. Wertz reported unsuccessful rapid maxillary expansion (RME) in a 16 year old female [25]. Haas reported unsuccessful expansion in 17 and 19 year old males [3]. Alpern and Yurosoko attempted RME in a 20 year old female and a 25 year old male and were successful [36]. Capelloza et al. evaluated 38 consecutive adults who underwent RME therapy, with 81.5% success mostly from alveolar bending [37]. Despite the large jackscrew activation there was minimal sutural response and minimal diastema formation. Beyond the limited success, 69% of adults experienced complications including pain, edema and palatal lesions.

Handelman evaluated 52 adults aged 19 to 49 years [38]. His study showed no true sutural expansion and no signs of diastema formation, only alveolar bending and remodeling. He coined it rapid maxillary alveolar expansion (RMAE). Handelman reported a 9% decrease in arch width that did not result in relapse of crossbites after 5 years of maxillary retention most likely due to concomitant narrowing of the lower arch [39]. The authors did note buccal gingival recession of up to 2mm infrequently. He conceded that it was possible for the gingival tissue to remain intact while masking a bony dehiscence. Pressure from teeth tipping buccally during maxillary expansion induces microstrains that can cause dehiscence. The breakdown of bone on the alveolar crest, where the tipping forces are concentrated, is probably enhanced by the resorption occurring on the periosteal surface of the buccal bone during expansion and the subsequent buccal tipping of teeth [40] . Regardless of whether a crossbite relapses,

there are periodontal complications associated with alveolar expansion and buccal tipping that accompany adult maxillary expansion therapy.

Zimring and Isaacson found that the forces used in RME are extremely high in adults and could be responsible for the complications [41]. Unsuccessful RME in a 15 year old female produced forces of 34.8 pounds with complications including pain, periodontal problems and swelling. The rapid accumulation of forces in RME therapy dissipates once the suture is separated. The sutural separation was unsuccessful, thus, forces remained high and the study had to discontinue expansion.

### **Corticotomies as an adjunct for non-surgical expansion**

The benefits of corticotomies were documented as early as 1959 by Kole [42]. Kole began using vertical corticotomies on the buccal and lingual alveolar bone mesial and distal to teeth connected by horizontal osteotomies subapically to correct malocclusions. He left the medullary bone intact to preserve blood supply to the alveolus and the teeth. Kole thought the underlying mechanism involved the bony segments housing the teeth were being displaced as opposed to the teeth themselves. He surmised that the cortical bone was actually providing the resistance to tooth movement rather than medullary bone [42]. Other case reports documented the success of corticotomies in preserving the periodontium and teeth. Gantes et al. performed buccal and lingual corticotomies on five adult patients with narrow alveolar ridges due to previous extractions. They evaluated the periodontium after corticotomy facilitated orthodontics and found minimal gingival recession with no loss of vitality or other periodontal

complications [43]. Suya used buccal interdental corticotomies to treat 395 adult Japanese orthodontic patients in an average treatment time of 12 months with minimal discomfort, external apical root resorption, and good stability [44].

Corticotomies were re-popularized in the US by a case series documenting their benefits in accelerating tooth movement with reduced treatment time [45]. Wilcko and colleagues were the first to attribute the effects to the regional acceleratory phenomenon (RAP). In their case report, two patients who presented with moderate to severe crowding were treated with corticotomy assisted orthodontics. Following placement of orthodontic appliances, full thickness mucoperiosteal flaps were raised on the buccal and lingual aspects of all the maxillary and mandibular teeth. Interdental vertical corticotomies extending just below the alveolar crests were connected to subapical corticotomies scalloped around the roots. The depth of the corticotomies was made through cortical bone to just penetrate medullary bone and establish a bleeding point. After placing a mixture of allograft and synthetic grafting material, the soft tissue was reapproximated. Orthodontics proceeded with a progression of wire changes every two weeks. Alleviation of crowding and alignment were achieved in as little as six months. Post operative radiographs showed adequate zones of attached gingiva, no increases in periodontal pocketing, no significant bone loss, no loss of tooth vitality, and no clinically significant apical root resorption. The authors attributed the success of the corticotomies to a transient catabolic condition characterized by temporary osteoporosis, increased calcium mobilization, decreased bone density and increased bone turnover.



The RAP is a biological response to injury resulting in increased perfusion of blood, increased growth of bone and cartilage, and increased bone modeling and remodeling. Essentially, it exploits the normal bone healing phases – inflammation, reparative and remodeling --by using the body's own ability to heal. Frost commented that an injury such as a bone fracture accelerates these normal regional processes. Frost described RAP as a stimulated reaction involving both hard and soft tissues characterized by an acceleration of normal tissue processes [46, 47]. These were described as natural processes, those that occur often like bone fractures or an expected consequence of surgical interventions like tooth extractions. Since then, many clinicians have applied this theory by providing 'the injury' in the form of corticotomies and alveolar decortications to initiate and accelerate this process.

In bone, the RAP causes a temporary decrease of regional bone density due to the overall increased remodeling space. The RAP initiates a few days after the fracture, peaks within one to two months and last up to four months in humans. Frost suggested that with a severe stimulus like a long bone fracture, it may take 6 to 24 months for RAP to subside. However, it allows healing to occur two to ten times faster. In normal tissues, osteoblasts and osteoclasts, which are responsible for RAP, are not present in sufficient quantities to repair the injury. They are recruited by signals sent from the site of injury to initiate the repair phenomenon as well as revascularize the tissues [46, 47].

The initial response to injury is immediate constriction of blood vessels to stop the bleeding. The reactive phase is usually completed within 7 days of injury [48]. Granulation tissue -- a loose aggregate of fibroblasts, intercellular materials and small

blood vessel, forms. Within approximately 2 weeks, periosteal cells close to the injury site and fibroblasts within the granulation tissue develop into chondroblasts and form hyaline cartilage. Periosteal cells near the injury site develop into osteoblasts which form woven bone. This mass of hyaline cartilage and woven bone is called the callus. During the reparative phase, the hyaline cartilage and woven bone are replaced by lamellar bone (when the tissue becomes mineralized). The duration of time between callus formation and mineralization lasts 1-4 months depending on the extent of the injury. During the remodeling phase, the bone is remodeled into mature lamellar bone. The entire process may take 1-4 years.

Corticotomies and the subsequent RAP have been shown to increase the cellular response in the area of the site of injury. Sebaoun et al. found that selective alveolar decortications resulted in a three-fold increase in osteoclastic activity and bone apposition at the site of injury [49]. The increased cellular turnover resulting from corticotomies can produce twice as much tooth movement when used in the alveolus [50]. Because the literature shows that corticotomies and the subsequent regional acceleratory phenomenon can increase the cellular response, this thesis will explore their potential in enhancing the effects of expansion. Hou et al. demonstrated in rats that expansion alone promotes bone resorption through increased osteoclast activity and activates proliferation of periosteal cells to form new bone and cartilage [8]. Since expansion alone has the capacity to induce remodeling effects similar to the regional acceleratory phenomenon, then it may be possible to increase this effect by increasing the surgical insult with corticotomies. McBride et al. investigated the effect of the

amount of surgical insult on bone. Using dogs, they demonstrated increasing the surgical insult resulted in decreased bone density, increased osteoclast activity, decreased bone volume, and decreased bone maturity, but no difference in bone volume [51].

### **An animal model for evaluating adult expansion**

Since the goal of the present study is to simulate separation of a mature suture, a rabbit model was chosen. The rabbit model is appropriate for evaluating adult sutures because rabbits also exhibit increasing interdigitation with age [52]. Persson et al. confirmed the similarity of rabbit and human sutures based on their histologic comparisons of the adult rabbit sagittal suture with the adult human palatal suture [53]. The human material consisted of palatal autopsy specimens of 24 adults, aged 15-35. Their rabbit specimens included the sagittal and interfrontal sutures of rabbits 24-36 months of age. They demonstrated that the process of sutural closure in both humans and rabbits showed dense collagen bundles crossing the suture prior to the development of bony spicules crossing the suture with frequent presence of osteocytes and infrequent osteoblasts. The main difference that occurred almost exclusively in humans during the initial stages of sutural obliteration was the presence of a highly irregular and mostly acellular mass either attached to the bony spicules or unattached in the suture gap that was semi-calcified.

Most previous studies evaluating sutural expansion in New Zealand white rabbits have used the midsagittal suture. A 2010 study by Liu et al. found that continuous forces provided by nickel titanium coil springs were more effective for sutural expansion than

intermittent forces [54]. Their study used a MSI-supported expansion device and light continuous forces on younger animals. A 2011 follow-up study evaluated force levels for sutural expansion by applying variable forces --0, 50, 100, and 200 g. Their results showed that sagittal sutural widths in young rabbits increased by 0.6, 3.2, 5.1, and 6.2 mm, respectively. They determined that 100 g was the optimal force to induce sutural separation because it provided the greatest amount of bone formation [55].

A recently completed master's thesis has shown that it is possible to separate mature rabbit sutures using light continuous forces and skeletal anchorage. The same MSI expansion apparatus described in Liu's study was used to expand the midsagittal suture of sexually mature rabbits with more complex sutures. This study showed limited sutural separation (0.63 mm) and suggested that the surrounding bony articulations, the force level, and the decreased cellular response of mature rabbits could be responsible for the decreased rate of separation [56].

The proposed methodology of this thesis will apply an orthopedic force to the bilateral frontonasal suture of mature New Zealand white rabbits. The bilateral frontonasal sutures make it possible to use a split skull design, which allows each animal to serve as its own control. Self controlled studies provide more powerful designs and more reliable comparisons. Movassaghi et al. successfully expanded across the frontonasal suture of immature New Zealand white rabbits [57]. They found statistically significant increases in the growth across the frontonasal suture, with a mixture of woven and lamellar bone in the suture after 5 weeks of expansion.

## CHAPTER II

### PURPOSE AND SIGNIFICANCE

The first documentation of orthopedic maxillary expansion appeared in the literature in 1860. Initially the procedure was disregarded and would not become popular in the United States for several decades until extensive investigations into suture biology and understanding reactions of the suture to orthopedic force. Most clinicians reserve the use of maxillary expansion for juveniles and young adolescents with tooth borne expansion devices. The process involves the suture being mechanically, but gradually, separated with heavy forces and then being allowed to biologically repair itself. The procedure is limited in adults because the suture does not readily separate resulting in expansive forces being redistributed from a complex suture to teeth that can be pushed out of buccal bone. With more adults seeking orthodontic treatment, the current prescribed treatment for those individuals with a maxillary transverse problem is surgically assisted rapid palatal expansion (SARPE) or orthognathic surgery involving a multiple piece maxilla. Any surgery of this magnitude will have associated risks and morbidities. Practitioners attempting nonsurgical expansion in adults have reported limited success and accompanying complications.

Presently, there is not a predictable and efficient non-surgical approach to orthopedically separate the mature midpalatal suture in humans. A review of the literature contains convincing evidence that facial sutures maintain their patency until much later in life than cranial sutures. Although mature sutures are patent, they are very

complex and highly interdigitated. Use of a miniscrew implant (MSI) supported expansion appliance utilizing skeletal anchorage could increase orthopedic expansion while limiting the side effects of a tooth-borne appliance.

The purpose of the present study is to investigate the potential use of corticotomies to enhance suture remodeling and reduce the resistance of surrounding articulations during expansion in mature rabbits.

## CHAPTER III

### MATERIALS AND METHODS

#### **Animals**

Nine adult (8-9 months old) female New Zealand white rabbits were used in this study. The housing, care, and experimental protocol were in accordance with the guidelines set forth by the Institutional Animal Care and Use Committee, Texas A&M University Baylor College of Dentistry. The animals were initially quarantined for three days and maintained under standard laboratory conditions. They were provided a stock diet and water ad libitum.

#### **Experimental design**

This study was a split skull design where expansion devices were placed across the bilateral frontonasal suture. Corticotomies were performed on one randomly chosen side, anterior and posterior to the frontonasal suture; the other side served as a control.

#### **MSI insertion, bone marker placement, and force delivery**

All rabbits were anesthetized with ketamine: xylazine 50mg/kg:10mg/kg given intramuscularly and all procedures were performed under sterile conditions. Local anesthesia was obtained with 2% Lidocaine with epinephrine 1:100,000. Once anesthesia had been achieved, surgical sites were shaved and disinfected with iodine.

A full thickness flap with a pocket flap design was raised to expose cortical bone and locate the bilateral frontonasal sutures (Figure 1A). The first incision was made at the midline of the cranium in the general location of the frontonasal suture. The midline incision was expanded laterally using a pocket flap design with no releasing incisions to visualize the suture. It extended at least 10 mm anterior and 15mm posterior to each frontonasal suture. This design allowed for the base of the flap on the most lateral part of the rabbits' snout to maintain the blood supply to the soft tissue. The periosteum had to be reflected to visualize the sutures on both sides. Corticotomy cuts and decortication stippling were made parallel to the frontonasal suture on the experimental side. Corticotomies were performed with a .010 mm diameter round carbide bur (Hager & Meisinger, Neuss, Germany) and a slow speed handpiece under copious irrigation. On the experimental side, four cuts were made anterior and four cuts were made posterior to the frontonasal suture. The width of each bone cut was approximately 0.5 mm; the length of each cut was approximately 8-10 mm. The depth of the cuts extended through the cortical bone and just into the medullary space, confirmed by bleeding through the cut lines.

After the corticotomy was performed on the experimental side, four miniscrew implant sites were measured and marked (Figure 1B). Miniscrew implants (MSIs) (3 mm long, 1.7 mm diameter; Dentos Inc., Daegu, South Korea) were placed bilaterally approximately 4 mm anterior and posterior to each frontonasal suture. To ensure the MSI heads would align and a guide wire could be inserted passively, a spare MSI driver was attached to the first MSI placed and used as a gauge while placing the second MSI.



1/8-inch length, pan head, slotted stainless steel screws (Grainger Industrial Supply, Lake Forest, IL) were used as bone markers and were placed 3-4 mm behind each of the MSIs to allow for quantification of sutural width and implant movements radiographically (Figure 1C). The flaps were sutured with resorbable 4-0 Vicryl surgical sutures. The four MSIs were palpated through the soft tissue and exposed using a 3mm tissue punch.

A 20 mm long .020-inch stainless steel guide wire was inserted passively through the holes in the heads of the MSIs and loaded with a 15 mm Sentalloy nickel-titanium open coil spring with 150 g of force (Figure 1D). To keep the wire from sliding, stop loops were bent on both ends. Active force delivery was maintained up to 12 mm. Once activation exceeded these limits, the wires were reactivated with a crimpable stop. All rabbits were given subcutaneous Nalbuphine for pain and daily antibiotics twice a day for 1 week postoperatively. After 49 days, all rabbits were euthanized under surgical plane anesthesia after being anesthetized with ketamine: xylazine 50mg/kg:10mg/kg given intramuscularly and then exsanguinated by perfusion with saline. Fixation was performed with 4% paraformaldehyde.

## **Measurements**

Measurements were taken immediately after the initial surgery, at 14 days, at 29 days, and at the day of euthanasia. Measurements, which were taken under the same anesthesia protocol used for the initial surgery, included the rabbits' weights, ventro-dorsal radiographs and inter-MSI measurements with digital calipers (Radioshack, Fort

Worth, TX). All measurements were taken once by a single operator (B.W.).

Radiographs were exposed on phosphor plates at 68 kVp and 10 mA for 12 milliseconds from a fixed distance (40 cm) with the animal in the supine position. Images were transferred to Visix software. The radiographs were calibrated and inter-bone marker distances were measured by one examiner (B.W.).

### **Tissue preparation for $\mu$ CT analysis**

Approximately 1.5 cm x 1.5 cm x 1 cm section of each frontonasal suture and adjacent bone was dissected between the MSI's and scanned with a desktop  $\mu$ CT 35 system (Scanco Medical; AG, Switzerland) at 55 kVp and 10  $\mu$ m. The specimens were loaded into the 20 mm scanning tubes individually and separated with sections of foam to stabilize the specimens and fixated in 4% paraformaldehyde. The sutures were oriented vertically, parallel with the tube, to ensure ease of orientation during three-dimensional manipulation.

### **Bone volume fraction and density measurements**

The MicroCT scans were analyzed using Scanco software. Each specimen was examined by a single operator (B.W.) to identify a range of slices with clearly defined suture. The segment to be analyzed was approximately 3-4.5mm x 1 cm x 0.5 cm. Contours of the specimens were manually drawn to select a region of interest to be analyzed. The contours were applied to and adjusted to contain 300 to 450 slices of each specimen. The regions within the contour were analyzed for bone volume ( $\text{mm}^3$ ), total

volume ( $\text{mm}^3$ ), and mean bone material density ( $\text{mg HA/ccm}$ ). Bone volume fraction (BV/TV) is the ratio of the volume of bone present (BV) to the total tissue volume of interest (TV). Because cancellous bone contains marrow spaces between trabeculae, this ratio will be less than 1. The ratio for cortical bone should approach 1. All bone volume density measurements were conducted by a single operator (B.W).

### **Tissue preparation for histologic analysis**

Control and experimental sutures from four rabbits were selected for histological analysis. The specimens were decalcified, embedded with paraffin and ribbon sectioned ( $6\ \mu\text{m}$ ) sagittally into sections. Sections 1, 6,7,11, and 12 were selected for H&E staining. The sutures from the four rabbits submitted for H&E staining preparation were grouped into control side and experimental side and provided to a blinded operator (B.W). Using the SPOT 5.1 Advanced camera (SPOT Imaging Solutions, Sterling Heights, MI.), the operator analyzed the slides looking for suture characteristics such as orientation of collagen fibers, cellularity, thickness and density of Sharpey's fibers, and alterations in the bone surrounding the suture. Once the operator was unblinded, a list of characteristic findings was generated looking for differences between the two groups.

### **Statistical analysis**

Statistical analysis was performed by SPSS 22.0 (Chicago, IL). Non parametric tests were used due to small sample size. Wilcoxon signed ranks tests were used to compare differences between sides for amount of sutural separation between MSIs and

bone markers as well as differences for bone volume fraction and bone material density. Pearson correlations were used to evaluate the relationship between bone density and bone marker separation. Significance was set at  $p < 0.05$ .

## CHAPTER IV

### RESULTS

The animals were 7.5 to 8 months at the time of initial surgery. The weights of the animals at the beginning of the experiment ranged from 3.6 kg to 5.1 kg with a mean weight at the time of initial surgery 4.3 kg. At sacrifice, the mean weight was 4.6 kg with a range from 4.1 kg to 5.6 kg. Two rabbits had one of the four MSIs supporting the expansion apparatus fail. The MSI survival rate was 94.4% (34/36) with one of the failed MSIs on the corticotomy side and the other on the control side. The failed MSIs were replaced within two days after failure was noted and expansion continued.

#### **Biometric analysis and measurements**

The separation between bone markers, measured radiographically, increased 3.73 mm on the corticotomy side, while the control side increased 2.83 mm (Table 1). The difference was statistically significant ( $p=.048$ ). The distance between MSIs, or the amount of sutural expansion, measured with calipers increased 3.80 mm on the corticotomy side and 2.90 mm on the control side. The difference approached, but did not attain statistical significance due to the amount of variability (Table 2). Since MSIs are capable of tipping, the use of radiographic bone markers is considered a more accurate measurement than caliper measurements between MSIs. The caliper and bone marker measurements of separation between MSIs are essentially the same indicating that very little tipping of the MSIs occurred during expansion.

### **Bone volume fraction and bone density measurements**

Evaluating both corticotomy and control sutures, a highly significant inverse correlation exists between bone material density and total sutural separation ( $R=.860$ ,  $P<.001$ ) (Table 3). The mean bone volume fraction on the control side and corticotomy side was 26.8% and 28.2%, respectively (Table 4). The difference in bone volume fraction was not statistically significant ( $p=0.26$ ). The mean material densities on the control side and corticotomy side were 669.30 mg HA/ccm and 658.66 mg HA/ccm, respectively (Table 5). The difference in bone material density also was not statistically significant ( $p=0.11$ ). The four rabbits showing the most difference between control and corticotomy sides were evaluated to identify trends. Bone on the corticotomy side was significantly less dense ( $p=0.034$ ) while bone volume showed no statistically significant difference ( $p=0.72$ ).

### **Histologic and histomorphometric comparisons**

The H&E sections of the control and experimental sides showed complex sutural interdigitations. The unblinded examinations showed the control and corticotomy sides both demonstrated stretching and disruption of sutural collagen fibers consistent with expansion. Inflammatory cells were absent on control and corticotomy sides. An increased density of osteoblasts with a blastema-like appearance was noted along the bone fronts on the corticotomy side. Also, the lumen of blood vessels, delineated by endothelial cells, appeared larger and longer within both corticotomy and control sutures

(Figure 2). Additionally, numerous elongated Sharpey's fiber insertions and a mixture of immature woven bone with numerous osteocytes were visible at the sutural margins on the corticotomy side consistent with formation of new bone. The appearance of the control side was similar but the Sharpey's fibers were visible to a much lesser extent (Figure 3).

## CHAPTER V

### DISCUSSION

Corticotomies increase the potential to expand adult sutures. In the present study, sutures that were expanded with adjunctive corticotomies showed 31% more sutural separation than the control sutures. The histologic assessments confirmed greater amount of sutural separation on the experimental side. The differences in the amounts of separation that occurred were probably due to bony changes associated with the RAP. This presumption is based on the fact that there was less mature and less dense bone – albeit not significantly less - in the vicinity of the experimental suture compared to the control suture. The four rabbits showing the greatest differences in sutural separation between the control and corticotomy sides did have significantly less dense bone on the corticotomy side. The failure to attain statistical significance when all animals were included was probably due to the confounding effects of the RAP that occurred on the control side, in response to the surgical resection of the periosteum during marker and implant placement.

The placement of miniscrews and bone markers, elevation of a flap, and removal of the periosteum to visualize the sutures also might be expected to produce insults capable of inducing the RAP. Moreover, the effects of such insults appears to be cumulative; greater surgical insults have been shown to produce less dense and less mature bone [51]. The MSI failures that occurred and potential differences in force levels could have introduced variability. With increased variability and the RAP



occurring on both sides, the present study likely did not have the power to identify statistically significant differences in bone density or volume.

Individual differences in the amount of expansion that occurs is related to individual differences in bone density. The present results clearly showed that the greatest amounts of expansion—regardless of adjunctive corticotomies-- occurred in the sutures having the least dense bone. It has been previously shown that adolescent bone density decreases significantly during palatal expansion, and that it returns to pretreatment levels after 6 months of retention [58]. Similarly, seven months after SARPE, adult bone density in the midpalatal suture has been reported to range from 48% (anteriorly) to 75% (posteriorly) of the bone's preoperative value [59]. Together, these studies indicate that expansion by itself induces the RAP. Previous studies have suggested that increased sutural bone density may limit orthopedic expansion in adults because interdigitation and higher obliteration index were not age related changes in the suture [23]. Decreases in bone density associated with adolescent orthopedic or adult surgical expansion are likely needed to remodel and separate the articulating bones. The results of the present study found a similar association between decreased bone density and the greater amounts of suture expansion, suggest that successful expansion requires a cellular response to demineralize surrounding bone and remodel sutures. Adults with increased bone density will likely require additional time to induce this response.

It has been well established that corticotomies and the subsequent RAP can increase the cellular turnover needed for sutural separation and remodeling [46-50]. Histologically, the control and corticotomy sides in the present study both demonstrated

the stretching and a reorientation of sutural collagen fibers expected with expansion. Additionally, the lumen of blood vessels, delineated by endothelial cells, appeared larger and longer within corticotomy and control sutures, which is consistent with expansion rather than tearing of the vasculature.

What distinguished the corticotomy side was the increased density of osteoblasts with a blastema-like appearance lining the bones on either side of the sutures, longer Sharpey's fiber insertions, and greater amounts of immature woven bone at the sutural margins, which are all consistent with the formation of new bone. The control sutures also showed Sharpey's fiber insertions and immature woven bone, but to a noticeably lesser extent. Also notable was the extensive presence of osteocytes in the surrounding bone on both sides. These findings supports the suggestion that the RAP can increase cellular recruitment [46-48] and that osteocytes may play a crucial role in bone modeling and demineralization [60]. The cellular response could explain the increased sutural expansion and decreased bone density observed.

Another histological finding was the absence of inflammatory cells-- on either side -- that would normally be expected with a wound healing response like the RAP. The RAP associated with corticotomies and distraction osteogenesis is characterized by three phases – inflammation, repair, and remodeling [48]. Reactive wound healing responses during the inflammatory phase would last approximately 7 days as granulation tissue forms. Within approximately 2 weeks, newly differentiated chondroblasts and osteoblasts form a mass of hyaline cartilage and woven bone, known as the callus. During the reparative phase, the hyaline cartilage and woven bone are replaced by

mineralized lamellar bone. The bone is then remodeled into mature lamellar bone over the next 4 months. A previous study that expanded the midpalatal suture of rats also did not report inflammation [8]. The lack of inflammatory cells simply indicates that no infection was present. Ultimately, the present study did not demonstrate inflammation because this phase of the RAP is transient and would only be expected immediately post surgery. It would have subsided prior to the end of this experiment.

Because sutural separation of the frontonasal suture was possible in mature rabbits, the suture must still have been largely patent. A previous study showed that the sagittal sutures of adult rabbits can also be expanded [56]. More recent human studies have reported that 87% of the midpalatal suture of adults up to 71 years of age show no bony cross bridges [11, 23, 24], supporting the notion that sutural fusion is not an age-related phenomena.

Nevertheless, the ability to expand the frontonasal suture in growing rabbits is substantially greater than in adult rabbits. The control sutures in the present study were expanded at a rate of 0.40 mm/week. Eliminating the effects of growth reported by Movassaghi et al., the frontonasal suture expanded 1.2 mm/week using 55 grams of force in 4 week old rabbits [57]. The control sutures in the present study were expanded less than one-third as much, which may be due to functional related increases in sutural complexity [17, 18], restrictions from surrounding articulations [26-28], or age-related decreases in the cellular response needed for suture remodeling [6, 16]. Even though expansion was slower, the frontonasal suture of mature rabbits was able to be separated,

indicating that more time is required in adults to recruit the cells necessary remodel more complex sutures.

The frontonasal suture of mature rabbits appears to be more amenable to sutural separation than the mid-sagittal suture. The control sutures in the present study were expanded at rate of 0.40 mm/week. Pulver et al. separated the sagittal suture of similarly aged rabbits at a rate of 0.11 mm/week [56]. Thus, the rate of frontonasal sutural separation was almost four times greater the rate of sagittal suture separation. This indicates that the frontonasal suture is less restricted by surrounding articulations than the sagittal suture. Previous studies have cited surrounding articulations as a limiting factor in sutural separation [25, 26] . Additionally, the different response potentials to expansion may be due to differences in the regulatory tissues associated with the two sutures as they develop. It is commonly believed that facial sutures function the same as cranial sutures during growth because of their similar histologic appearance and maturation [61]. However, as patent growth sites, the cranial sutures maintain their morphology through regulations from the underlying dura mater. In contrast, the frontonasal suture, a facial suture, is closely associated with the nasal septal cartilage. Facial sutures and septal cartilage are essentially indiscernible due to the continuity between the periosteum of the frontal and nasal bones and the septal cartilage perichondrium [61]. Although the regulatory tissues of cranial and facial sutures differ during development, there is no evidence that this control extends into adulthood. It is reasonable to speculate that the frontonasal suture may be more similar to the midpalatal

suture, another facial suture, due their similar development and close association to the nasal septal cartilage.

Based on these findings, it appears possible to remodel and separate sutures in young adults using adjunctive corticotomies with continuous forces and skeletal anchorage. The available literature shows that adult sutures are more complex, but it also shows that they remain largely open. The impediments to sutural expansion in adults are the surrounding articulations and a limited cellular response potential to remodel those articulations.

A clinical implication of this study is that the RAP subsequent to corticotomies can remodel sutures and reduce resistance at the articulations to expansion. However, adults will require longer treatment times because of the cellular proliferation needed to remodel the suture. Although statistically significant, the 3.7 mm of expansion obtained after 49 days in this study may not be clinically relevant. More importantly, the possibility of 31% more sutural separation with corticotomies is promising and supports the need for continued research of less invasive procedures that might produce similar or greater effects.

Another clinical implication is that bone density can be considered an impediment to maxillary expansion. The results of this study clearly showed that increased expansion was correlated with decreased bone density. Theoretically, the use of localized short-acting corticosteroids could stimulate an osteopenic effect. They could increase osteoclast production and decrease osteoblast formation which would result in decreased bone density. The results of this study would support the potential use of a

physiological or pharmacological agent to decrease regional bone density to separate adult sutures.

CHAPTER VI  
CONCLUSIONS

Within the limits of this study, the results show:

1. The frontonasal suture of 8 to 9 month old adult rabbits is patent and able to be expanded.
2. Mature sutures expanded with adjunctive corticotomies undergo 31% more separation than sutures expanded without corticotomies.
3. The RAP subsequent to corticotomies has potential in remodeling sutures and reducing the resistance of surrounding articulations during expansion.
4. The amount of sutural expansion that occurs is inversely related to bone density.

## REFERENCES

1. Timms, D.J., *The dawn of rapid maxillary expansion*. Angle Orthod, 1999. 69(3): p. 247-50.
2. Haas, A.J., *Gross reactions to the widening of the maxillary dental arch of the pig by splitting the hard palate*, in *Orthodontics*. 1958, University of Illinois: Unpublished.
3. Haas, A.J., *The Treatment of Maxillary Deficiency by Opening the Midpalatal Suture*. Angle Orthod, 1965. 35: p. 200-17.
4. McNamara, J.A., Jr., et al., *Rapid maxillary expansion followed by fixed appliances: a long-term evaluation of changes in arch dimensions*. Angle Orthod, 2003. 73(4): p. 344-53.
5. Cleall, J.F., et al., *Expansion of the Midpalatal Suture in the Monkey*. Angle Orthod, 1965. 35: p. 23-35.
6. Ten Cate, A.R., E. Freeman, and J.B. Dickinson, *Sutural development: structure and its response to rapid expansion*. Am J Orthod, 1977. 71(6): p. 622-36.
7. Brandt, H., P. Shapiro, and V. Kokich, *Experimental and postexperimental effects of posteriorly directed extraoral traction in adult Macaca fascicularis*. Am J Orthod, 1979. 75(3): p. 301-317.
8. Hou, B., N. Fukai, and B.R. Olsen, *Mechanical force-induced midpalatal suture remodeling in mice*. Bone, 2007. 40(6): p. 1483-93.
9. V., K., *Biology of sutures*, in *Craniosynostosis: Diagnosis, evaluation, and management*, C. M., Editor. 1986, Raven Press New York. p. 81-103.
10. Opperman, L.A., *Cranial sutures as intramembranous bone growth sites*. Dev Dyn, 2000. 219(4): p. 472-85.
11. Persson, M. and B. Thilander, *Palatal suture closure in man from 15 to 35 years of age*. Am J Orthod, 1977. 72(1): p. 42-52.
12. Pritchard, J.J., J.H. Scott, and F.G. Girgis, *The structure and development of cranial and facial sutures*. J Anat, 1956. 90(1): p. 73-86.



13. Kokich, V.G., *Age changes in the human frontozygomatic suture from 20 to 95 years*. Am J Orthod, 1976. 69(4): p. 411-30.
14. Korbmacher, H., et al., *Clinical profile of rapid maxillary expansion--outcome of a national inquiry*. J Orofac Orthop, 2005. 66(6): p. 455-68.
15. Melsen, B. and F. Melsen, *The postnatal development of the palatomaxillary region studied on human autopsy material*. Am J Orthod, 1982. 82(4): p. 329-342.
16. Brin, I., et al., *Rapid palatal expansion in cats: effect of age on sutural cyclic nucleotides*. Am J Orthod, 1981. 79(2): p. 162-75.
17. Jaslow, C.R., *Mechanical properties of cranial sutures*. J Biomech, 1990. 23(4): p. 313-21.
18. Herring, S.W., *Mechanical influences on suture development and patency*. Front Oral Biol, 2008. 12: p. 41-56.
19. Herring, S.W. and R.J. Mucci, *In vivo strain in cranial sutures: the zygomatic arch*. J Morphol, 1991. 207(3): p. 225-39.
20. Moss, M.L., *Fusion of the frontal suture in the rat*. Am J Anat, 1958. 102(1): p. 141-65.
21. Moss, M.L., *Inhibition and stimulation of sutural fusion in the rat calvaria*. Anat Rec, 1960. 136: p. 457-67.
22. Herring, S.W., *A biometric study of suture fusion and skull growth in peccaries*. Anat Embryol (Berl), 1974. 146(2): p. 167-80.
23. Korbmacher, H., et al., *Age-dependent three-dimensional microcomputed tomography analysis of the human midpalatal suture*. J Orofac Orthop, 2007. 68(5): p. 364-76.
24. Knaup, B., F. Yildizhan, and H. Wehrbein, *Age-related changes in the midpalatal suture. A histomorphometric study*. J Orofac Orthop, 2004. 65(6): p. 467-74.
25. Wertz, R.A., *Skeletal and dental changes accompanying rapid midpalatal suture opening*. Am J Orthod, 1970. 58(1): p. 41-66.

26. Shyamsunder, B.R.a.A., B.P., *Effects of Transverse Orthopedic Forces on craniofacial complex in adult human skull - a three-dimensional finite element study*. Pravara Med Rev, 2011. 6(1): p. 12-18.
27. Iseri, H., et al., *Biomechanical effects of rapid maxillary expansion on the craniofacial skeleton, studied by the finite element method*. Eur J Orthod, 1998. 20(4): p. 347-56.
28. Jafari, A., K.S. Shetty, and M. Kumar, *Study of stress distribution and displacement of various craniofacial structures following application of transverse orthopedic forces--a three-dimensional FEM study*. Angle Orthod, 2003. 73(1): p. 12-20.
29. Nanda, R., *Protraction of maxilla in rhesus monkeys by controlled extraoral forces*. Am J Orthod, 1978. 74(2): p. 121-41.
30. Jackson, G.W., V.G. Kokich, and P.A. Shapiro, *Experimental and postexperimental response to anteriorly directed extraoral force in young Macaca nemestrina*. Am J Orthod, 1979. 75(3): p. 318-33.
31. Buchanan, E.P. and C.H. Hyman, *LeFort I Osteotomy*. Semin Plast Surg, 2013. 27(3): p. 149-54.
32. Proffit, W.R., T.A. Turvey, and C. Phillips, *The hierarchy of stability and predictability in orthognathic surgery with rigid fixation: an update and extension*. Head Face Med, 2007. 3: p. 21.
33. Lines, P.A., *Adult rapid maxillary expansion with corticotomy*. Am J Orthod, 1975. 67(1): p. 44-56.
34. Mossaz, C.F., F.K. Byloff, and M. Richter, *Unilateral and bilateral corticotomies for correction of maxillary transverse discrepancies*. Eur J Orthod, 1992. 14(2): p. 110-6.
35. Suri, L. and P. Taneja, *Surgically assisted rapid palatal expansion: a literature review*. Am J Orthod Dentofacial Orthop, 2008. 133(2): p. 290-302.
36. Alpern, M.C. and J.J. Yurosko, *Rapid palatal expansion in adults with and without surgery*. Angle Orthod, 1987. 57(3): p. 245-63.

37. Capelloza Filho, L.C.N., J.; Silva Filho, O., *Non-surgically assisted rapid maxillary expansion in adults*. Int. J. Orthod. Orthognatic Surg., 1996. 11: p. 57-66.
38. Handelman, C.S., *Nonsurgical rapid maxillary alveolar expansion in adults: a clinical evaluation*. Angle Orthod, 1997. 67(4): p. 291-305; discussion 306-8.
39. Handelman, C.S., et al., *Nonsurgical rapid maxillary expansion in adults: report on 47 cases using the Haas expander*. Angle Orthod, 2000. 70(2): p. 129-44.
40. Kraus, C.D., et al., *Bony adaptation after expansion with light-to-moderate continuous forces*. Am J Orthod Dentofacial Orthop, 2014. 145(5): p. 655-66.
41. Zimring, J.F. and R.J. Isaacson, *Forces Produced by Rapid Maxillary Expansion. 3. Forces Present during Retention*. Angle Orthod, 1965. 35: p. 178-86.
42. Kole, H., *Surgical operations on the alveolar ridge to correct occlusal abnormalities*. Oral Surg Oral Med Oral Pathol, 1959. 12(5): p. 515-29 concl.
43. Gantes, B., E. Rathbun, and M. Anholm, *Effects on the periodontium following corticotomy-facilitated orthodontics. Case reports*. J Periodontol, 1990. 61(4): p. 234-8.
44. Suya, H., *Corticotomy in orthodontics*, in *Mechanical and Biological Basis in Orthodontic Therapy*, B.A. Hosl E, Editor. 1991, Huthig Buch Verlag: Heidelberg, Germany: . p. 207-226.
45. Wilcko, W.M., et al., *Rapid orthodontics with alveolar reshaping: two case reports of decrowding*. Int J Periodontics Restorative Dent, 2001. 21(1): p. 9-19.
46. Frost, H.M., *The biology of fracture healing. An overview for clinicians. Part I*. Clin Orthop Relat Res, 1989(248): p. 283-93.
47. Frost, H.M., *The biology of fracture healing. An overview for clinicians. Part II*. Clin Orthop Relat Res, 1989(248): p. 294-309.
48. Buschang, P.H., P.M. Campbell, and S. Ruso, *Accelerating Tooth Movement With Corticotomies: Is It Possible and Desirable?* Seminars in Orthodontics, 2012. 18(4): p. 286-294.

49. Sebaoun, J.D., et al., *Modeling of trabecular bone and lamina dura following selective alveolar decortication in rats*. J Periodontol, 2008. 79(9): p. 1679-88.
50. Mostafa, Y.A., et al., *Comparison of corticotomy-facilitated vs standard tooth-movement techniques in dogs with miniscrews as anchor units*. Am J Orthod Dentofacial Orthop, 2009. 136(4): p. 570-7.
51. McBride, M.D., et al., *How does the amount of surgical insult affect bone around moving teeth?* Am J Orthod Dentofacial Orthop, 2014. 145(4 Suppl): p. S92-9.
52. Storey, E., *Tissue response to the movement of bones*. Am J Orthod, 1973. 64(3): p. 229-47.
53. Persson, M., B.C. Magnusson, and B. Thilander, *Sutural closure in rabbit and man: a morphological and histochemical study*. J Anat, 1978. 125(Pt 2): p. 313-21.
54. Liu, S.S., H.M. Kyung, and P.H. Buschang, *Continuous forces are more effective than intermittent forces in expanding sutures*. Eur J Orthod, 2010. 32(4): p. 371-80.
55. Liu, S.S., et al., *Is there an optimal force level for sutural expansion?* Am J Orthod Dentofacial Orthop, 2011. 139(4): p. 446-55.
56. Pulver, R., *Miniscrew assisted slow expansion of mature sutures*, in *Orthodontics*. 2014, Texas A&M University Baylor College of Dentistry.
57. Movassaghi, K., D.E. Altobelli, and H. Zhou, *Frontonasal suture expansion in the rabbit using titanium screws*. J Oral Maxillofac Surg, 1995. 53(9): p. 1033-42; discussion 1042-3.
58. Franchi, L., et al., *Modifications of midpalatal sutural density induced by rapid maxillary expansion: A low-dose computed-tomography evaluation*. Am J Orthod Dentofacial Orthop, 2010. 137(4): p. 486-8; discussion 12A-13A.
59. Petrick, S., et al., *Bone density of the midpalatal suture 7 months after surgically assisted rapid palatal expansion in adults*. Am J Orthod Dentofacial Orthop, 2011. 139(4 Suppl): p. S109-16.

60. Feng, J.Q., L. Ye, and S. Schiavi, *Do osteocytes contribute to phosphate homeostasis?* *Curr Opin Nephrol Hypertens*, 2009. 18(4): p. 285-91.
61. Adab, K., et al., *Tgf-beta1, Tgf-beta2, Tgf-beta3 and Msx2 expression is elevated during frontonasal suture morphogenesis and during active postnatal facial growth.* *Orthod Craniofac Res*, 2002. 5(4): p. 227-37.

**Figure 1. Methodology, experimental design, and expansion apparatus**

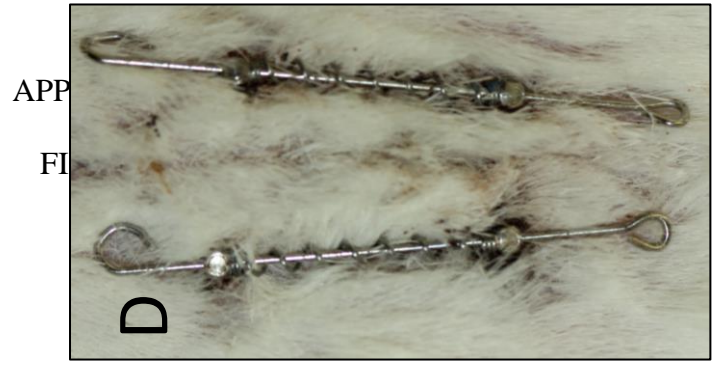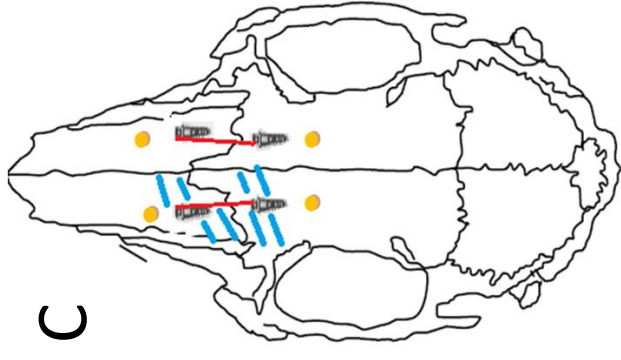
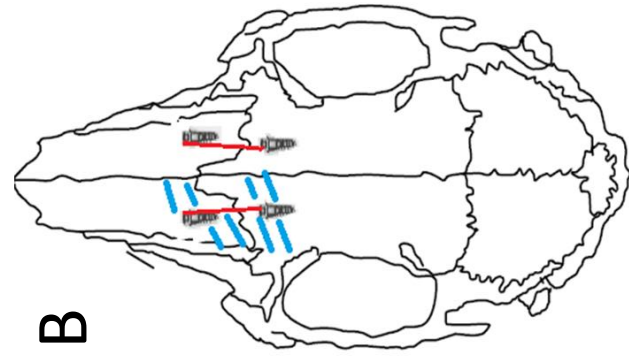
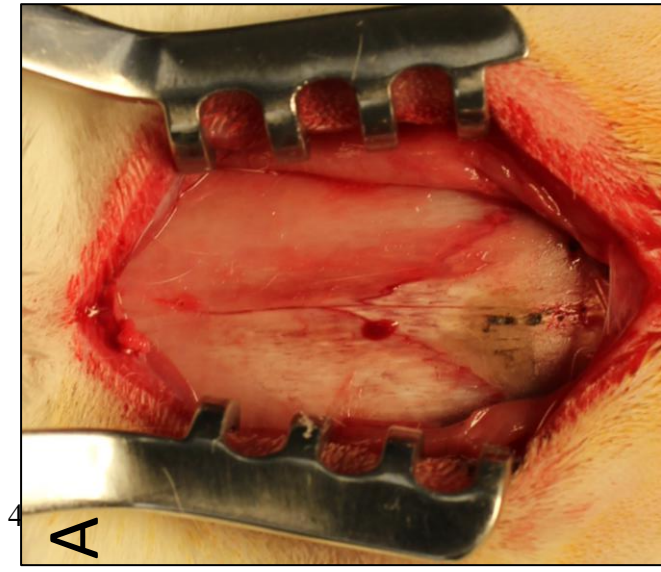


Figure 2. H&E stained specimens comparing control and corticotomy sutures

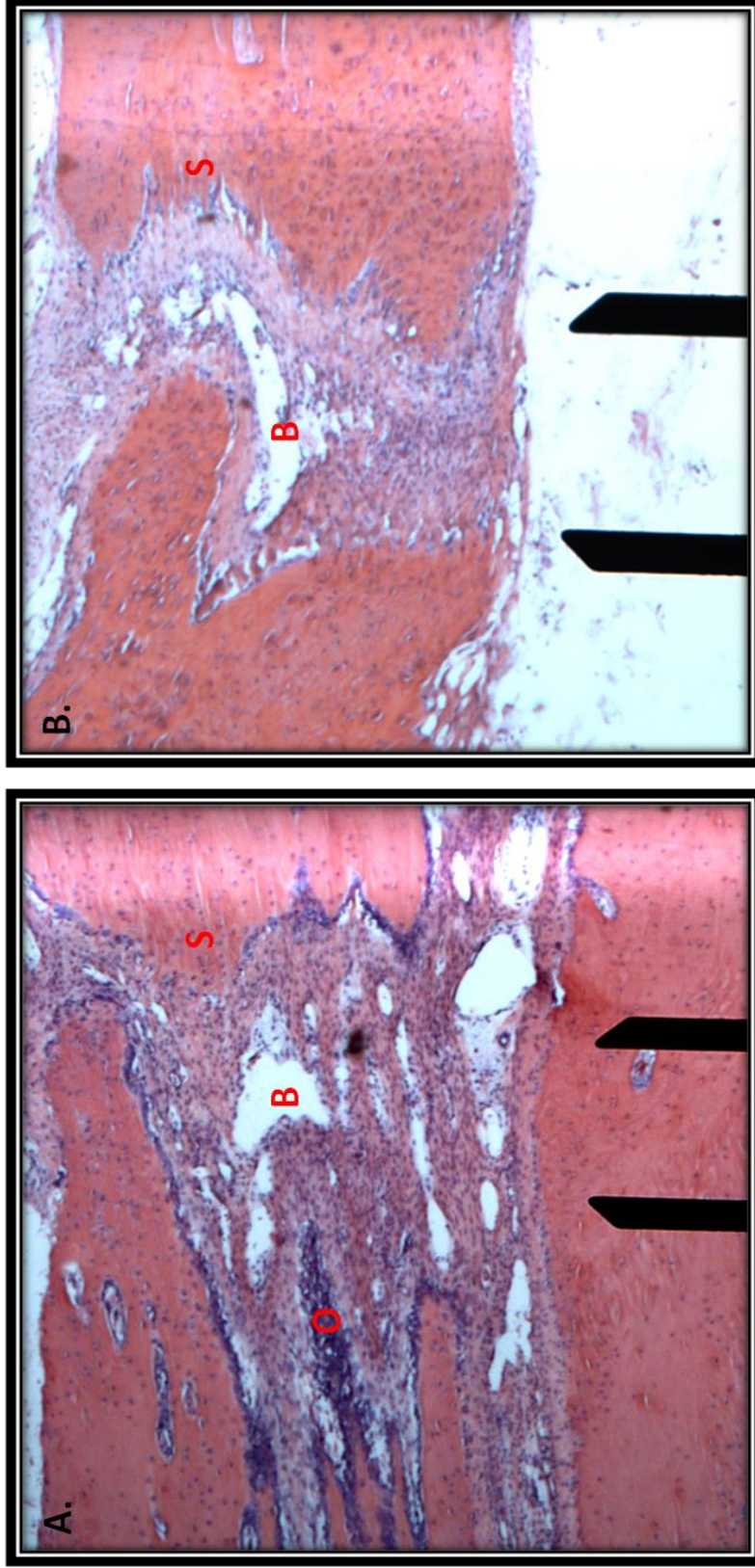


Figure 2. H&E stained sections (5x magnification) from the same rabbit. A) Corticotomy side. Note the increased density of osteoblasts (O) along the bone fronts lining the suture and longer Sharpey's fibers (S) consistent with expansion B) Control side. Note the lumen of blood vessels (B) delineated by endothelial cells, appeared larger and longer within both corticotomy and control sides.



Figure 3. H&E stained specimens comparing control and corticotomy sutures

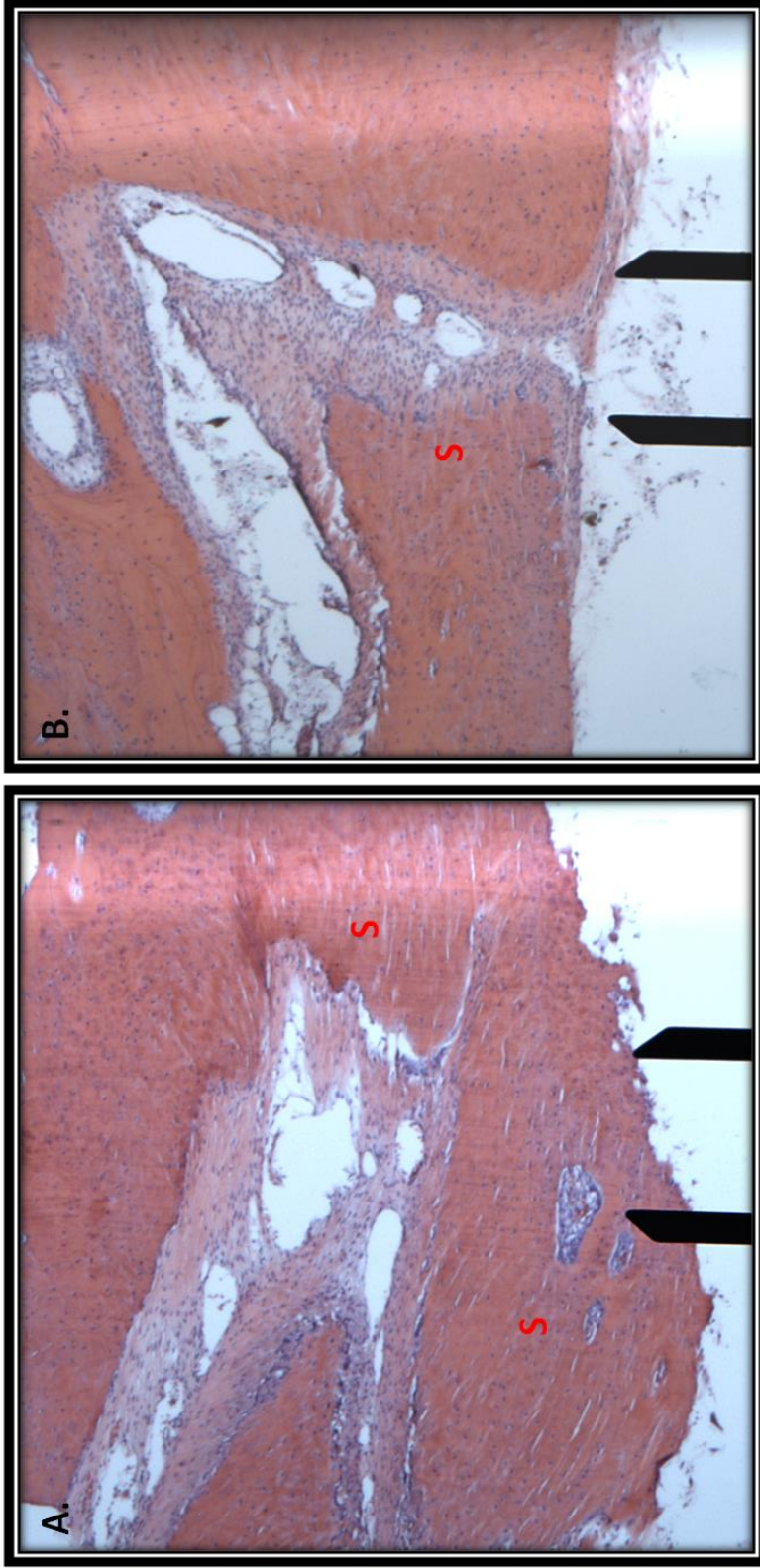


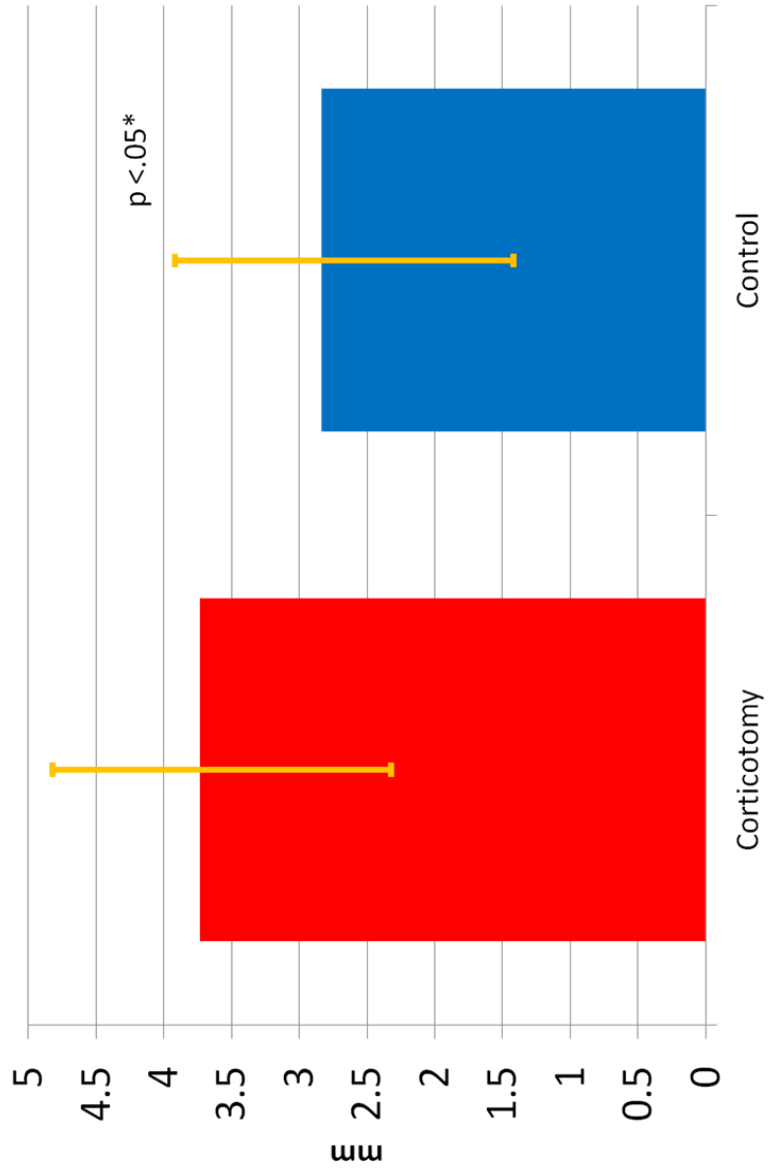
Figure 3. H&E stained sections (5x magnification) from the same rabbit. A) Corticotomy side. Note the elongated Sharpey's fiber insertions (S). B) Control side. The control side has a similar appearance, but the Sharpey's fibers were visible to a much lesser extent.



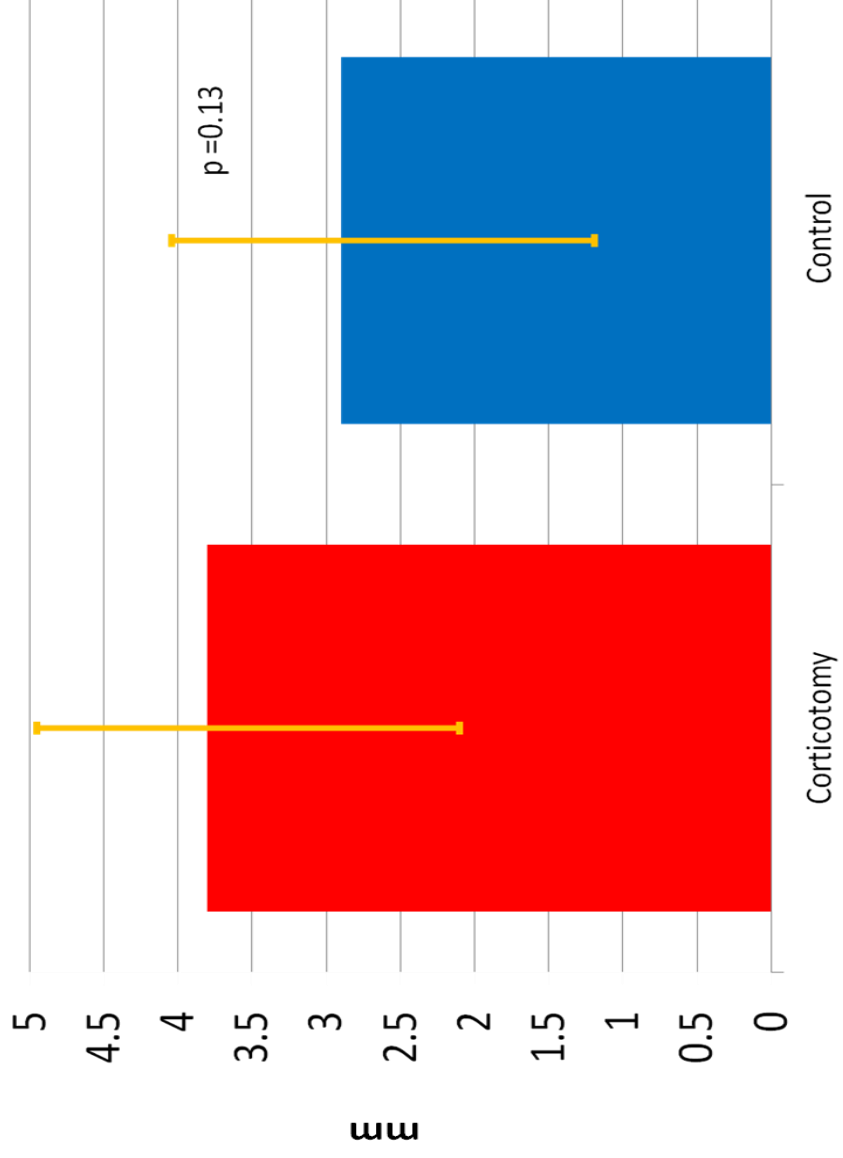
APPENDIX B

TABLES

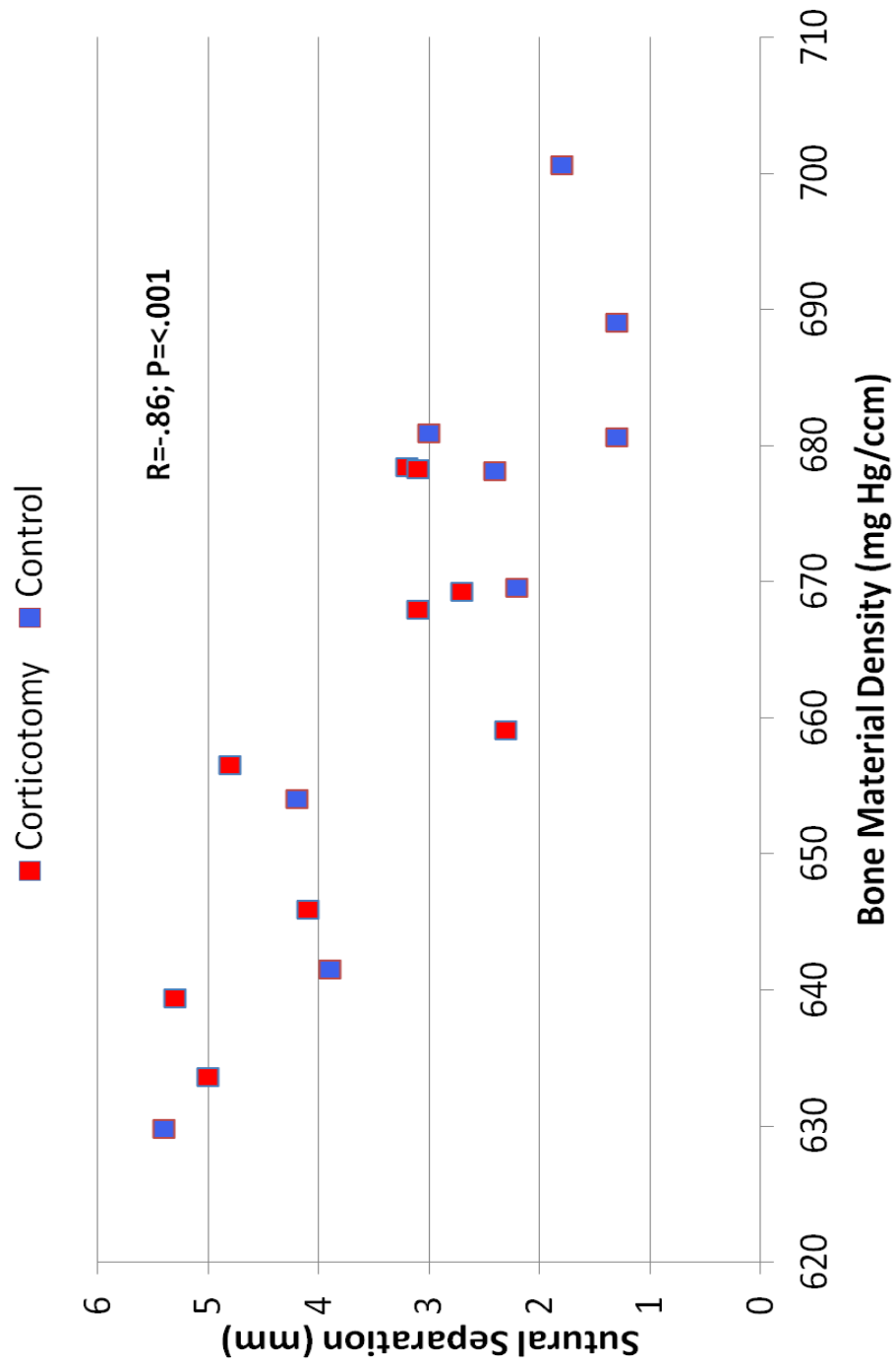
Table 1. Sutural separation measured between bone markers



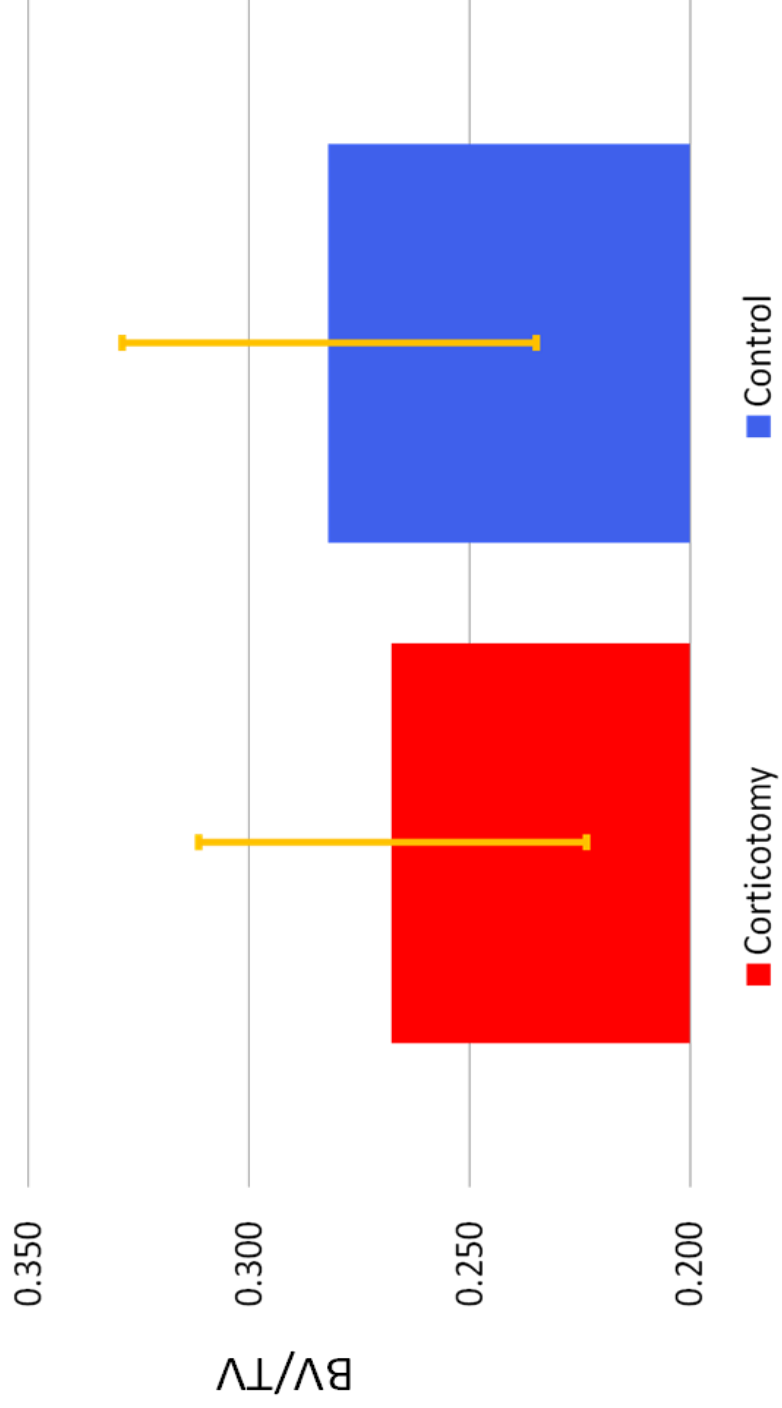
**Table 2. Sutural separation measured between MSIs with calipers**



**Table 3. Correlation between Bone Material Density and Sutural Separation**



**Table 4. Bone volume fraction for control and corticotomy sides**



**Table 5. Bone material density for control and corticotomy sides**

