

**Title:**

The 2016 World Health Organization Classification of Tumours of the Central Nervous System: What Paediatric Neuroradiologist Needs to Know.

**Running title:**

2016 WHO Classification of CNS Tumours.

**Manuscript category:**

Editorial.

**Authors:**

Sahil Chhabda<sup>1</sup>, Olivia Carney<sup>2</sup>, Felice D'Arco<sup>2</sup>, Thomas Jacques<sup>3</sup>, Kshitij Mankad<sup>2</sup>

1. Department of Radiology, Chelsea and Westminster Hospital NHS Foundation Trust, 369 Fulham Road, London SW10 9NH, United Kingdom.
2. Department of Paediatric Neuroradiology, Great Ormond Hospital NHS Foundation Trust, Great Ormond Street, London WC1N 3JH, United Kingdom.
3. Department of Pathology, Great Ormond Hospital NHS Foundation Trust, Great Ormond Street, London WC1N 3JH, United Kingdom.

**Correspondence details:**

Dr. Kshitij Mankad. Department of Paediatric Neuroradiology, Great Ormond Street Hospital NHS Foundation Trust, Great Ormond Street, London WC1N 3JH, United Kingdom.

**Abstract:**

The recently published 2016 World Health Organization (WHO) classification of tumours of the Central Nervous System (CNS) introduces a number of significant changes from the previous edition. Based on an improved understanding of the genetic and molecular basis of tumorigenesis there has been a shift towards defining tumours by means of these characteristics in addition to their histological features, thus providing an integrated diagnosis. In this article, we will provide a concise overview of the salient changes in the 2016 WHO classification of tumours of the CNS that are of relevance to the paediatric neuroradiologist when it comes to day-to-day reporting.

**Key words:**

Central nervous system neoplasms, Classification, Diagnostic imaging, Paediatric, World Health Organization

**Background:**

The 2007 WHO classification of CNS tumours was primarily based on histological features which presented a number of issues and limitations. In comparison, the 2016 WHO CNS tumour classification builds on developments and research in the molecular and genetic basis of tumorigenesis and aims to incorporate these molecular features alongside histological findings in tumour classification. The aim is to provide an integrated phenotypic and genotypic diagnosis thus more accurately defining real biological entities.

By means of an integrated approach to tumour classification narrower diagnostic criteria can be applied resulting in improved diagnostic accuracy and a reduction in inter-observer variability. This in turn will hopefully improve the reproducibility of results and better guide prognostication and treatment of CNS tumours.

As a result of this new method of classification, a number of new tumour entities have been described in this updated edition. There has also been significant restructuring of the classification of pre-existing tumour categories including the diffuse gliomas, medulloblastomas and other embryonal tumours. Entities such as *gliomatosis cerebri* have been downgraded to a pattern of spread rather than a distinct biological entity from the diffuse gliomas.

The nomenclature of tumours has subsequently changed, and now for several tumours consists of the histopathological name followed by the genetic determinant e.g. *medulloblastoma, SHH-activated, TP53-mutant*. The not otherwise specified or NOS suffix is reserved for situations where there is either insufficient material or the facilities for testing for the specific genotype are not available.

In cases where there is discordance between the histology and molecular genetic features the pathologist needs to judge the relevance of each piece of evidence but in an increasing number of tumours it is the genotype that will be the primary determinant of the tumour type. An example of this would be a diffuse glioma that is histologically astrocytic but is also found to have *IDH* mutation and *1p/19q* codeletion. Under the new classification this will fall under the diagnosis of *oligodendroglioma, IDH-mutant and 1p/19q codeleted*.

A recent review by Louis *et. al.* provides a comprehensive overview of the changes that that 2016 classification brings with it(1).

Whilst a large majority of changes relate to histological and molecular diagnostic criteria, an understanding of the new classification and nomenclature will be vital for the paediatric neuroradiologist when it comes to reporting.

**New Entities, Variants and Patterns that the Paediatric Neuroradiologist should be aware of including the following:**

Neuronal and mixed neuronal-glia tumours:

A new tumour entity of neuronal-glia origin commonly presenting in childhood and adolescence is the *diffuse leptomeningeal glioneuronal tumour*. These tumours are characterised by predominant and widespread leptomeningeal growth with or without a parenchymal component. Histologically these tumours frequently have oligodendroglial cytology with evidence of neuronal differentiation on immunohistochemistry, Whilst *IDH* mutations are typically absent, molecular findings may include *BRAF* fusion, isolated *1p* deletions or combined *1p/19q* codeletions(2).

### Medulloblastomas:

The commonest malignant brain tumours in childhood are now defined by integrated diagnoses which accounts for the genetic and histological features of the tumour. The histological classification is already well defined and includes classic, anaplastic/large cell, desmoplastic/nodular and extensive nodular variants. In terms of molecular classification, the subtypes of include WNT-activated, SHH-activated and non-WNT/non-SHH (group 3 and group 4)(3). Providing an integrated diagnosis is of clinical value as both the histological and molecular variants have distinct therapeutic and prognostic implications.

An entity of particular relevance is the *medulloblastoma, SHH-activated and TP53 mutant*. It is defined by the WHO as: 'A poorly differentiated embryonal tumour of the cerebellum with evidence of *SHH* pathway activation and either germline or somatic *TP53* mutation'(4). The clinical outcomes for this subgroup of medulloblastoma are very poor. These patients carry a significant risk of having a germline *TP53* mutation and should be offered genetic counselling.

### Diffuse gliomas:

This group has been restructured and now includes all the diffusely infiltrating gliomas regardless of whether they are astrocytic or oligodendroglial in origin. The restructuring is based on the genetic understanding of adult tumours, which are largely determined based on *IDH* gene mutations and the presence or absence of *1p/19q* codeletions(3). This is of limited value in paediatrics as both genetic changes are rare in paediatric tumours even when they are of the similar histological type to their adult counterparts.

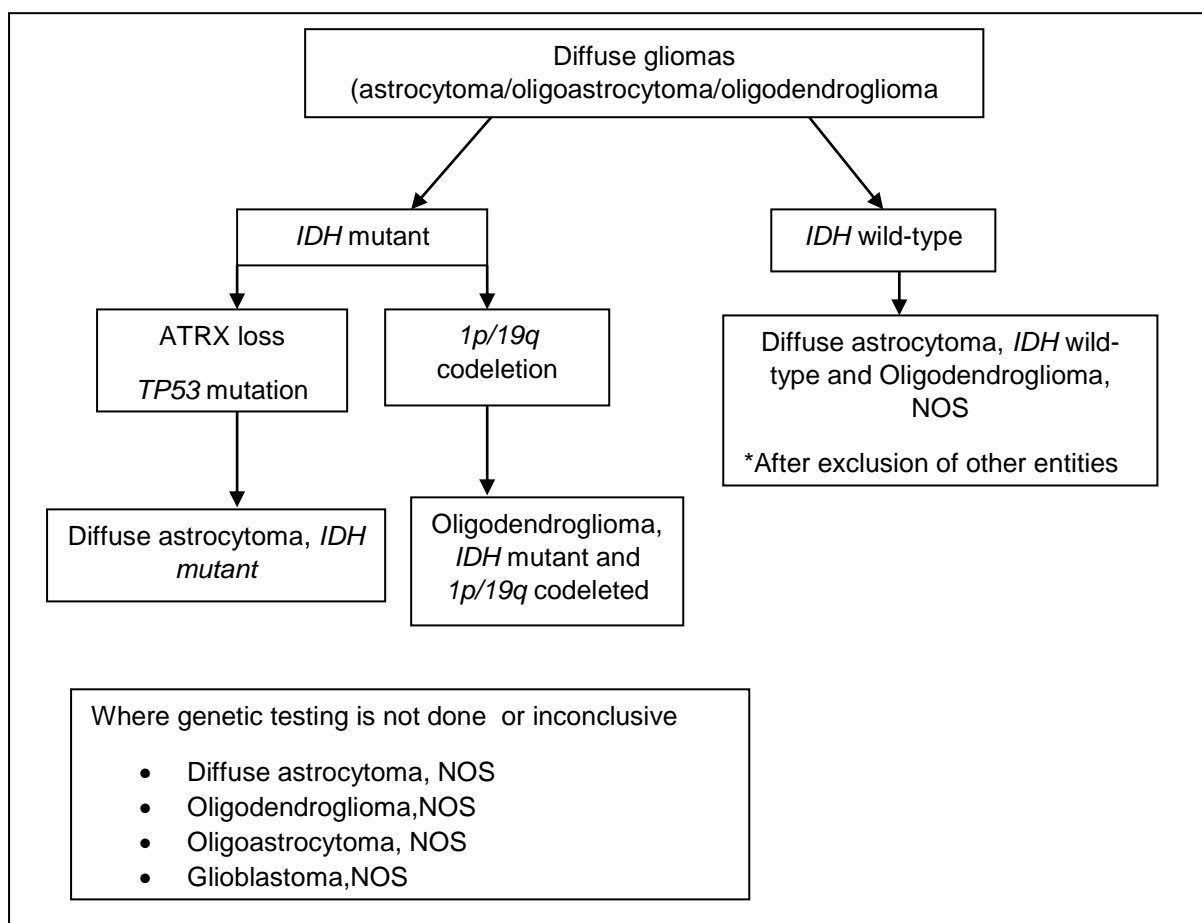


Figure 1: Flow diagram for diffuse glioma classification. Adapted from Louis et. al.(1)

### *Paediatric diffuse gliomas:*

There has been separation of paediatric diffuse gliomas from adult diffuse gliomas based on the presence of molecular markers thus allowing for more targeted therapies. A new entity in this group is *diffuse midline glioma, H3 K27M-mutant*. These midline tumours (typically of the thalamus, pons or spinal cord) with a diffuse pattern encompass many of the tumours recognised as diffuse intrinsic pontine glioma (DIPG) and many high-grade gliomas of the thalamus in children. These tumours have a poor prognosis(5).

### *Diffuse astrocytoma and anaplastic astrocytoma:*

The terms protoplasmic astrocytoma and fibrillary astrocytoma are no longer in the 2016 classification. *Gliomatosis cerebri* is no longer considered a distinct entity but is regarded as a growth pattern of other glial tumours(4).

### *Glioblastomas:*

Glioblastomas are classified based on *IDH* mutations into glioblastoma, *IDH-wild-type*, glioblastoma, *IDH-mutant* and glioblastoma, *NOS* (4).

One particular new entity of relevance to the paediatric neuroradiologist is the *epithelioid glioblastoma*. These tumours typically present as diencephalic or superficial cerebral masses. Histologically they are characterised by large epithelioid cells, vesicular chromatin and prominent nucleoli. Rhabdoid cells may also be present. Immunohistochemistry or sequencing often reveals a *BRAF* V600E mutation(6).

*Other astrocytomas:*

*Anaplastic pleomorphic xanthoastrocytoma* has been added as a distinct entity as opposed to the previously applied descriptive title of *pleomorphic xanthoastrocytoma with anaplastic features* (4).

Ependymomas:

These are the third commonest neuroepithelial tumours of childhood, after astrocytomas and medulloblastomas. There is increasing data suggesting that ependymomas can be divided into several subtypes on the basis of molecular profiling (particularly DNA methylation profiling).

With regards to the 2016 classification, one of the new molecularly defined entities in this category is *ependymoma, RELA fusion-positive*. *RELA* fused ependymomas constitute most of the supratentorial ependymomas encountered in children and have a poor prognosis (4).

Cellular ependymoma has been deleted in the 2016 classification.

Other embryonal tumours:

The term *CNS-primitive neuroectodermal tumour* (PNET) and supratentorial PNET have been removed from the diagnostic lexicon. This will avoid confusion with the peripheral-type PNET or Ewing's sarcoma that can still present with the skull or occasionally the CNS (1).

There has been a major restructuring of the classification of non-medulloblastoma embryonal tumours particularly taking account of a subgroup that display amplification of the C19MC region encoding an miRNA cluster of chromosome 19 (19q.13.42).



The entity previously recognised as *embryonal tumour with abundant neuropil and true rosettes (ETANTR)* or *embryonal tumour with multilayered rosettes (ETMR)*, *ependymoblastoma* and most cases of medulloepithelioma have been reclassified based on the presence or absence of C19MC amplification (7).

In cases of confirmed C19MC amplification, the term *embryonal tumour with multilayered rosettes (ETMR), C19MC-altered* should be applied. Most of the tumours previously described as medulloepithelioma will now be classified as *ETMR, C19MC-altered*. Tumours without the C19MC alteration will be classified under the category of medulloepithelioma (1).

*Atypical teratoid / rhabdoid tumour (AT/RT)* is now characterised by alterations in SMARCB1 (*INI1*) or rarely SMARCA4 (*BRG*) *CNS embryonal tumour with rhabdoid features* is used for tumours that have histological features of AT/RT without the specific genetic alterations (4, 8, 9).

There remain a group of embryonal tumours of the nervous system that do not have one of these characteristic features and these are described as CNS neuroblastoma, CNS ganglioneuroblastoma or embryonal tumour, NOS depending on the histological findings. However, it should be noted that some of the tumours historically described in this group can be reclassified into other tumour entities based on current diagnostic techniques (e.g. high grade glioma, *ETMR*, *AT/RT* and ependymoma) and these alternative diagnoses need to be actively excluded before a diagnosis of embryonal tumour is accepted.

There are some exciting new molecular data that indicate that there are new tumour entities that account for a number of the embryonal tumours and it is likely that future classifications will take account of these new CNS tumours (10).

**Conclusion:**

The 2016 WHO classification of CNS tumours introduces a number of significant changes, a large proportion of which relate to an improved understanding of the molecular and genetic basis of tumorigenesis. It is vital that the paediatric neuroradiologist is familiar with the new nomenclature, classification, patterns of spread and reclassification of entities that are no longer considered relevant as all these factors have implications with regards to patient management and prognostication. Whilst diagnoses can still be made for tumour variants that fall into a NOS category, ongoing research will hopefully enable further characterisation of these entities which are not yet fully defined.

**References:**

1. Louis DN, Perry A, Reifenberger G, von Deimling A, Figarella-Branger D, Cavenee WK, Ohgaki H, Wiestler OD, Kleihues P, Ellison DW. The 2016 World Health Organisation Classification of Tumours of the Central Nervous System: a summary. *Acta Neuropathol.* 2016; 131: 803-820.
2. Rodriguez FJ, Schniederjan MJ, Nicolaidis T, Tihan T, Burger PC, Perry A. High rate of concurrent *BRAF-KIAA1549* gene fusion and 1p deletion in disseminated oligodendroglioma-like leptomeningeal neoplasms (DOLN). *Acta Neuropathol.* 2015; 129(4): 609-610.
3. Kool M, Korshunov A, Remke M, Jones DT, Schlanstein M, Northcott PA, Cho YJ, Koster J, Schouten-van Meeteren A, van Vuurden D, Clifford SC, Pietsch T, von Bueren AO, Rutkowski S, McCabe M, Collins VP, Bäcklund ML, Haberler C, Bourdeaut F, Delattre O, Doz F, Ellison DW, Gilbertson RJ, Pomeroy SL, Taylor MD, Lichter P, Pfister SM. Molecular subgroups of medulloblastoma: an international meta-analysis of transcriptome, genetic aberrations, and clinical data of WNT, SHH, Group 3, and Group 4 medulloblastomas. *Acta Neuropathol.* 2012; 123(4): 473-484.
4. Louis DN, Ohgaki H, Wiestler OD, Cavenee WK. WHO Classification of Tumours of the Central Nervous System. WHO Press, Geneva, 2016.
5. Khuong-Quang DA<sup>1</sup>, Buczkowicz P, Rakopoulos P, Liu XY, Fontebasso AM, Bouffet E, Bartels U, Albrecht S, Schwartzentruber J, Letourneau L, Bourgey M, Bourque G, Montpetit A, Bourret G, Lepage P, Fleming A, Lichter P, Kool M, von Deimling A, Sturm D, Korshunov A, Faury D, Jones DT, Majewski J,

- Pfister SM, Jabado N, Hawkins C. K27M mutation in histone H3.3 defines clinically and biologically distinct subgroups of pediatric diffuse intrinsic pontine gliomas. *Acta Neuropathol.* 2012; 124(3): 439-447.
6. Broniscer A, Tatevossian RG, Sabin ND, Klimo P Jr, Dalton J, Lee R, Gajjar A, Ellison DW. Clinical, radiological, histological and molecular characteristics of paediatric epithelioid glioblastoma. *Neuropathol Appl Neurobiol.* 2014. 40(3). 327-336.
  7. Korshunov A, Sturm D, Ryzhova M, Hovestadt V, Gessi M, Jones DT, Remke M, Northcott P, Perry A, Picard D, Rosenblum M, Antonelli M, Aronica E, Schüller U, Hasselblatt M, Woehrer A, Zheludkova O, Kumirova E, Puget S, Taylor MD, Giangaspero F, Peter Collins V, von Deimling A, Lichter P, Huang A, Pietsch T, Pfister SM, Kool M. Embryonal tumor with abundant neuropil and true rosettes (ETANTR), ependymoblastoma, and medulloepithelioma share molecular similarity and comprise a single clinicopathological entity. *Acta Neuropathol.* 2014; 128(2): 278-289.
  8. Hasselblatt M, Gesk S, Oyen F, Rossi S, Viscardi E, Giangaspero F, Giannini C, Judkins AR, Frühwald MC, Obser T, Schneppenheim R, Siebert R, Paulus W. Nonsense mutation and activation of SMARCA4 (BRG1) in atypical teratoid/rhabdoid tumour showing retained SMARCB1 (INI1) expression. *Am J Surg Pathol.* 2011; 35(6): 933-935
  9. Judkins AR. Immunohistochemistry of INI1 expression: a new tool for old challenges in CNS and soft tissue pathology. *Adv Anat Pathol.* 2007. 14(5). 335-339

10. Sturm D, Orr BA, Toprak UH, Hovestadt V, Jones DT, Capper D, Sill M, Buchhalter I, Northcott PA, Leis I, Ryzhova M, Koelsche C, Pfaff E, Allen SJ, Balasubramanian G, Worst BC, Pajtler KW, Brabetz S, Johann PD, Sahm F, Reimand J, Mackay A, Carvalho DM, Remke M, Phillips JJ, Perry A, Cowdrey C, Drissi R, Fouladi M, Giangaspero F, Łastowska M, Grajkowska W, Scheurlen W, Pietsch T, Hagel C, Gojo J, Lötsch D, Berger W, Slavc I, Haberler C, Jouvett A, Holm S, Hofer S, Prinz M, Keohane C, Fried I, Mawrin C, Scheie D, Mobley BC, Schniederjan MJ, Santi M, Buccoliero AM, Dahiya S, Kramm CM, von Bueren AO, von Hoff K, Rutkowski S, Herold-Mende C, Frühwald MC, Milde T, Hasselblatt M, Wesseling P, Rößler J, Schüller U, Ebinger M, Schittenhelm J, Frank S, Grobholz R, Vajtai I, Hans V, Schneppenheim R, Zitterbart K, Collins VP, Aronica E, Varlet P, Puget S, Dufour C, Grill J, Figarella-Branger D, Wolter M, Schuhmann MU, Shalaby T, Grotzer M, van Meter T, Monoranu CM, Felsberg J, Reifenberger G, Snuderl M, Forrester LA, Koster J, Versteeg R, Volckmann R, van Sluis P, Wolf S, Mikkelsen T, Gajjar A, Aldape K, Moore AS, Taylor MD, Jones C, Jabado N, Karajannis MA, Eils R, Schlesner M, Lichter P, von Deimling A, Pfister SM, Ellison DW, Korshunov A, Kool M. New Brain Tumor Entities Emerge from Molecular Classification of CNS-PNETs. *Cell*. 2016; 164(5): 1060-1072.

**Conflicts of interest:**

None to declare.