

Accepted Manuscript

The accepted manuscript is defined here as the final draft author manuscript, as accepted for publication by a journal, including modifications based on referees' suggestions, before it has undergone copyediting and proof correction.

Authors may upload their accepted manuscript PDF to an institutional and/or centrally organized repository, provided that public availability is delayed until **12 months after first online publication** in the journal.

When uploading an accepted manuscript to a repository, authors should include the following acknowledgment as well as a link to the version of record. This will guarantee that the version of record is readily available to those accessing the article from public repositories, and means that the article is more likely to be cited correctly.

This is a pre-copyedited, author-produced PDF of an article accepted for publication in [Brain] following peer review. The version of record [Hope TMH, Price CJ. Why the left posterior inferior temporal lobe is needed for word finding. Brain 2016, 139 (11) pp. 2823-2826.]

is available online at: <http://dx.doi.org/10.1093/brain/aww240>

Why the left posterior inferior temporal lobe is needed for word finding

This commentary refers to "Converging evidence for a cortico-subcortical network mediating lexical retrieval" by Herbet *et al.* (doi...)

Word finding is a fundamental language skill, which can be severely impaired in patients with neurological disorders such as stroke, epilepsy, neurodegeneration, and after neurosurgical resection of tumours. The clinical treatment of these impairments, and of those at risk of developing them, would be substantially improved if we had a deeper understanding of the neural systems that sustain word finding – for example, if we knew which brain regions or white matter tracts must be protected during surgical resection of brain tumours to prevent subsequent word finding difficulties. In this issue of *Brain*, Herbet *et al.* investigate the neurosurgical cavities and residual tumour infiltrations that result in word finding impairments (Herbet *et al.*, 2016).

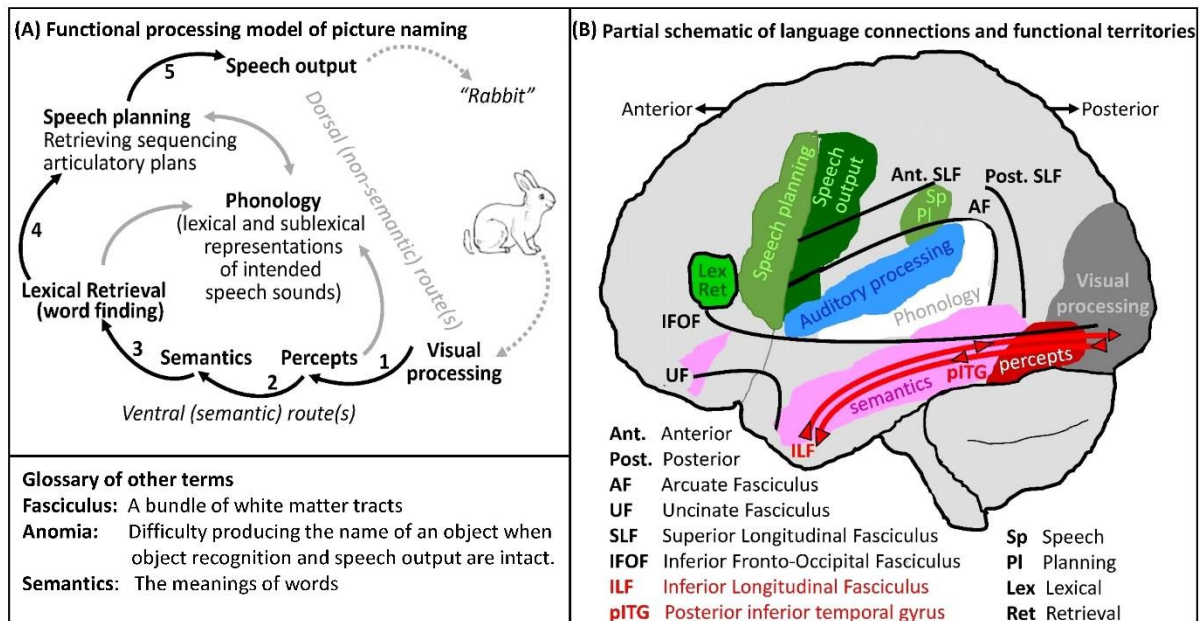
This study makes several valuable contributions to the field. First, word finding difficulties (anomia) are typically measured using tasks in which patients must name pictures of common objects. Many prior studies have reported a distributed set of brain regions where damage impairs object naming (Deleon *et al.*, 2007). However, object naming is a complex skill, thus the observed impairments could in principle be caused by perceptual, semantic or motor deficits. This makes it difficult to identify brain regions with particular cognitive functions. In their study, Herbet *et al.* make a great effort to focus on patients whose deficit is at the word finding stage. The authors classify patients as having anomia if their impaired object naming is improved when they are given a

clue as to how the name starts. For example, a patient would be classified as anomic if they were unable to name a picture of an object (e.g. a rabbit) until the experimenter provided the first sound of the name (e.g. “rrrrrr”). In this context, the patient must have recognised that the object was a rabbit (or something like a rabbit) in order to select “rabbit” from all other object names that also start with “r”. The patients’ ability to produce the correct word after a cue also indicates that failure to name was not the consequence of an inability to produce speech.

Herbet *et al.* aim for similar specificity when characterising the neural structures associated with word finding behaviour. They build on data from a large sample of 110 patients who had undergone surgical resection for diffuse low-grade glioma. Nearly one third of these patients were classified as having long-lasting anomia after surgery, and Herbet *et al.* describe how neurosurgical cavities and residual tumour infiltrations differed in those with and without anomia. They localise the most consistent neural abnormality to basal temporal structures in the left hemisphere: analysis of the surgical cavity identified the mid to posterior part of the left inferior temporal gyrus (pITG in Figure below), and a compelling series of ‘tractwise’ analyses, designed to capture white matter disconnections caused by residual tumour infiltration, identified posterior parts of the inferior longitudinal fasciculus (ILF in Figure below).

The association of damage to the left basal temporal lobe with object naming difficulties is consistent with many previous reports in patients with stroke (Deleon *et al.*, 2007), epilepsy (Mani *et al.*, 2008; Trebuchon-Da Fonseca *et al.*, 2009), neurodegeneration (Race *et al.*, 2013), tumour(s) (Shinoura *et al.* 2010) and after surgery (Wilson *et al.*, 2015). Indeed the area is sometimes referred to as the “basal temporal language area”. Herbet *et al.* are more specific by (i) pinpointing the unique contributions of particular parts of the basal temporal language area (pITG and ILF) to the lexical retrieval stage of object naming, and (ii) highlighting the importance of preserving these areas during surgery in order to minimise the likelihood of persistent anomia. Their conclusions also appear to agree with those of a functional imaging study of patients with left hemisphere stroke, whose recovery of word generation ability was associated with activation in the left posterior inferior temporal lobe (Warburton *et al.*, 1999).

However, the results reported by Herbet *et al.* also challenge current functional anatomical models of picture naming, as described below and illustrated in Figure 1.



Functionally, the ability to produce the name of a picture involves several stages of what might be called "information transformation". Part A of the Figure illustrates some of these transformations with an example of what is needed to name a picture of a rabbit. Stage 1 involves integrating visual inputs into a recognisable "percept" (i.e. a visual image of a rabbit). Stage 2 involves accessing semantic knowledge of the percept (animal, pet, fluffy, hops). Stage 3 involves retrieving the name (lexical retrieval) associated with the percept and the sounds associated with the name (phonology). Stage 4 involves the co-ordination of motor plans for the speech articulators that generate the intended sound (speech planning) and Stage 5 involves executing the motor plan to overtly produce the intended sound ("rabbit"). A non-semantic route to naming has also been described (grey arrows in Figure 1) but typically this is associated with reading when speech can be generated by assembling the sounds associated with familiar letter combinations that have no meaning (e.g. FLAVET).

The paradox in the Herbert *et al.* study is the location of the anatomical damage (from resection and tumour infiltration) that they associate with word finding impairments in the context of intact semantics. According to the model shown in part A of the Figure, damage that causes these difficulties should either be at Stage 3 or to the dorsal non-semantic routes that link percepts directly to their speech sounds. Anatomically, we would expect this damage to preserve perceptual and semantic processing areas in the inferior temporal lobe (red and pink areas in part B of the Figure). It is therefore surprising that Herbert *et al.* found that patients with long-lasting anomia had damage to parts of the inferior temporal lobe that are more typically associated with semantically mediated word retrieval (see Price, 2012 for a review).

How can this discrepancy in the new data and anatomical model be reconciled? Clearly, the neural systems that support picture naming are far more complex than those illustrated in the Figure. There are likely to be multiple neural processing areas and pathways involved, and our models are going to need to make a much clearer distinction between different types of “semantic” and “phonological” processing. For example, very specific semantic categorisations are required to identify and name an object (e.g. the picture shows a rabbit), but the ability to make semantic associations is possible with less precise identification (e.g. the picture is of a mammal with short legs and long upright ears). In this context, the patients reported by Herbert *et al.* might have imprecise semantic information (e.g. from a failure to suppress competing information from semantically related objects) that is sufficient to make semantic associations but insufficient to support the selection of the object’s name unless other cues are given (e.g. the first sound of the name). This would be consistent with a role for pITG and posterior ILF in precise object identification and the control of competition from other semantically related objects (Nugiel *et al.* 2016).

How might the ILF be involved in precise object recognition? Current models of visual perception emphasize that the process of generating a percept is likely to involve the interaction of bottom up visual processing (in posterior occipito-temporal regions) with top down constraints from semantic processing (in more anterior temporal regions). This would entail an iterative interaction between posterior and anterior temporal areas that involves both forward and backward processing along ILF (see the bidirectional ILF connections in part B of the Figure) and other white matter bundles. Indeed, it has previously been shown that damage to anterior temporal regions results in disconnection of posterior temporal regions (Mummery *et al.*, 1999) in the context of anomia. According to this model, partial damage to the posterior part of the ILF would result in noisy percepts and concepts that do not provide sufficient information for name retrieval via either a semantic or non-semantic route. This logic implies a different interpretation to that preferred by Herbert *et al.*; rather than identifying the pITG and pILF with lexical retrieval itself, we are proposing a more perceptual-semantic account (i.e. impaired top-down perceptual classification), founded on a current functional model of object naming skills.

As Herbert *et al.* note, semantic disturbances could not be rigorously controlled for in this study: further validation including such controls might arbitrate between these two accounts, because our account predicts that damage/infiltration to the same region/tract might hamper semantic processing as well as overt naming, whereas the account of Herbert *et al.* implies a link to the latter irrespective of the former. But whatever their precise function, the ITG and posterior ILF are clearly essential for naming, which has obvious clinical relevance for patients with tumours in and around these areas. And as the authors note, the association of damage to these regions with

persistent anomia suggests that they provide core support to that object naming skill, and that other brain regions cannot easily compensate for their loss.

Thomas M H Hope and Cathy J Price
Wellcome Trust Centre for Neuroimaging
Institute of Neurology
University College London
UK
Email: c.j.price@ucl.ac.uk

References:

DeLeon J, Gottesman RF, Kleinman JT, Newhart M, Davis C, Heidler-Gary J, *et al.* Neural regions essential for distinct cognitive processes underlying picture naming. *Brain* 2007;130(Pt 5):1408-22.

Herbet G, Moritz-Gasser S, Boisseau M, Duvaux S, Cochereau J, Duffau H. Converging evidence for a cortico-subcortical network mediating lexical retrieval. *Brain* 2016.

Mani J, Diehl B, Piao Z, Schuele SS, Lapresto E, Liu P, *et al.* Evidence for a basal temporal visual language center: cortical stimulation producing pure alexia. *Neurology* 2008;71(20):1621-7.

Mummery CJ, Patterson K, Wise RJ, Vandenberghe R, Price CJ, Hodges JR. Disrupted temporal lobe connections in semantic dementia. *Brain* 1999;122 (Pt 1):61-73.

(Erratum in: *Brain*. 2007 Mar;130(Pt 3):879. Vandenberghe, R [corrected to Vandenberghe, R].)

Nugiel T, Alm KH, Olson IR. Individual differences in white matter microstructure predict semantic control. *Cognitive, Affective and Behavioral Neuroscience* 2016; (Epub Jul 21).

Price CJ. A review and synthesis of the first 20 years of PET and fMRI studies of heard speech, spoken language and reading. *Neuroimage* 2012;62(2):816-47.

Race DS, Tsapkini K, Crinion J, Newhart M, Davis C, Gomez Y, *et al.*

An area essential for linking word meanings to word forms: evidence from primary progressive aphasia. *Brain and Language* 2013;127(2):167-76.

Shinoura N, Suzuki Y, Tsukada M, Yoshida M, Yamada R, Tabei Y, *et al.* Deficits in the left inferior longitudinal fasciculus results in impairments in object naming. *Neurocase* 2010; 16(2):135-9.

Trebuchon-Da Fonseca A, Guedj E, Alario FX, Laguitton V, Mundler O, Chauvel P, *et al.*

Brain regions underlying word finding difficulties in temporal lobe epilepsy. *Brain* 2009; 132(Pt 10):2772-84.

Warburton E, Price CJ, Swinburn K, Wise RJ. Mechanisms of recovery from aphasia: evidence from positron emission tomography studies. *Journal of Neurology, Neurosurgery and Psychiatry* 1999;66(2):155-61.

Wilson SM, Lam D, Babiak MC, Perry DW, Shih T, Hess CP, *et al.* Transient aphasias after left hemisphere resective surgery. *Journal of Neurosurgery* 2015;123(3):581-93.