

Facial Swelling in a child on chronic hemodialysis

¹Zinab A. Sawan, ¹Sherif M El-Desoky, ¹Mohamed A. Shalaby, ²Detlef Bockenhauer,
¹Jameela A.Kari,

¹Department of Pediatrics, King Abdulaziz University, Jeddah, Kingdom of Saudi Arabia

²Department of Paediatric Nephrology, , Great Ormond Street Hospital for Children NHS Trust,
London, WC1N 3JH, UK

Corresponding Author:

Name: Jameela A.Kari

Address: King Abdulaziz University, PO Box 80215, Jeddah 21589, Kingdom of Saudi Arabia

Phone number: +996 505677904

E-mail address: jkari@doctors.org.uk or jkari@kau.eu.sa

Case Report:

An 11-year old male hemodialysis patient developed a firm, painless mass on the right nasal bridge of insidious onset that gradually increased in size involving the left nasal bridge and the left mandible over 2-year duration, with difficulty in chewing (figure 1).

He had an underlying diagnosis of CAKUT with posterior-urethral valve and an absent left kidney. At 4-years of age, he commenced renal replacement therapy in the form of peritoneal dialysis (PD). This was complicated by recurrent peritonitis, catheter blockage and displacement which required change in modality to hemodialysis at 4 and a half years of age, with three sessions per week (12-hours/week).

He had severe growth failure (height SDS - 4.3) and commenced recombinant human growth hormone at 2-years of age. Growth hormone was continued for 8 years but he remained below the 3th percentile (height SDS - 3.3 at 11 years of age)

He developed chronic bone pain, with slowly progressive long bone deformities. He became confined to a wheel chair at 6-years of age. Besides hemodialysis, he was treated with bicarbonate to control his acid-base balance along with phosphate binders (sevelamer), 1-alpha hydroxylated vitamin D3 (orally and intravenously), and lastly calcimimetics (Cinacalcet), which was started at 10-years of age, resulting in cessation of tumor growth without regression in size. Table 1. give's summary of his bone profile and creatinine across the years.

Till the date of writing this quiz, the child is receiving regular hemodialysis sessions, with no apparent improvement in the biochemical markers or regression of the tumor size.

Age (years)	Normal Values	6	7	8	9	10	11
Calcium (mmol/l)	2.12-2.52	2.36 (2.02-2.57)	2.28 (1.84-2.59)	2.28 (1.98-2.71)	2.4 (1.97-2.31)	2.2 (1.97-2.37)	2.28 (2.04-2.66)
Phosphate (mmol/l)	0.81-1.58	2.05 (1.10-3.1)	2.7 (1.4-3.88)	1.86 (1.11-3.7)	1.71 (0.92-2.87)	2.89 (2.01-3.61)	2.8 (2.03-3.39)
Alkaline phosphatase (IU/l)	150-360	234 (203-266)	333 (205-432)	530 (277-721)	859 (680-1194)	504 (388-694)	363 (298-410)
PTH (pmol/l)	1.6-6.9	131 (108-154)	195 (117-295)	241 (55-401)	211 (77-287)	240 (198-274)	201 (201)
Albumin (gm/l)	34-50	21 (10-32)	31 (27-35)	31 (28-35)	32 (30-35)	28 (31-34)	30 (27-34)
Creatinine (mmol/l)	35-62	491 (259-737)	527 (257-834)	535 (199-865)	445 (182-795)	440 (241-729)	516 (228-837)
Bicarbonate (mmol/l)	22-26	19	16	22	18	23	17
Kt/V	>1.2	1.5 (1.39-1.59)	1.49 (1.32-1.79)	1.66 (1.46-1.9)	1.6 (1.34-1.79)	1.45 (1.08-1.75)	1.22 (1.10-1.32)

Questions:

1. Describe the findings In the computed tomography (CT)?
2. What is your diagnosis?
3. How would you manage this case?
4. What is the role of cinacalcet in managing this case?

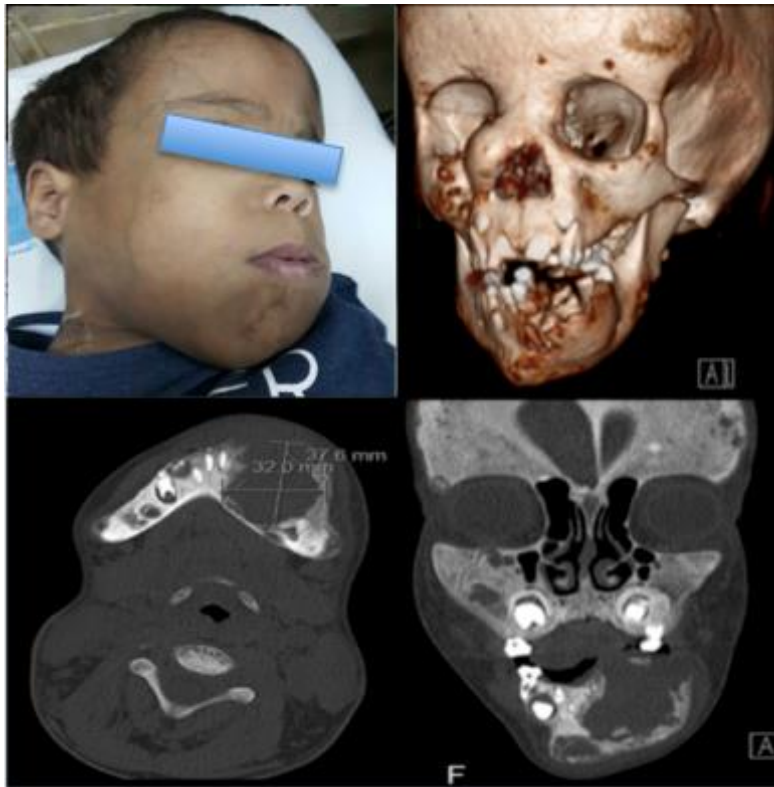


Figure 1: Photo of the child, computed tomography (CT) reconstruction and two CT slices

child, computed reconstruction and two CT slices