



Human Mutation

A new congenital disorder of glycosylation is associated to mutations in TRAPPC11

Journal:	<i>Human Mutation</i>
Manuscript ID	Draft
Wiley - Manuscript type:	Brief Report
Date Submitted by the Author:	n/a
Complete List of Authors:	<p>Matalonga, Leslie; Hospital Clínic, IDIBAPS, CIBERER, Biochemistry and Molecular Genetics</p> <p>Bravo, Miren; Hospital Clínic, IDIBAPS, CIBERER, Biochemistry and Molecular Genetics</p> <p>Serra-Peinado, Carla; Dep. Biomedicina, Universitat de Barcelona and Institut d'Investigacions Mèdiques August Pi i Sunyer (IDIBAPS)</p> <p>García-Pelegrí, Elisabeth; Hospital Clínic, IDIBAPS, CIBERER, Biochemistry and Molecular Genetics</p> <p>Ugarteburu, Olatz; Hospital Clínic, IDIBAPS, CIBERER, Biochemistry and Molecular Genetics</p> <p>Vidal, Silvia; Hospital Clínic, IDIBAPS, CIBERER, Biochemistry and Molecular Genetics</p> <p>Llambrich, Maria; Hospital Clínic, IDIBAPS, CIBERER, Biochemistry and Molecular Genetics</p> <p>Quintana, Ester; Hospital Clínic, IDIBAPS, CIBERER, Biochemistry and Molecular Genetics</p> <p>Fuster-Jorge, Pedro; .Hospital Universitario de Canarias, La Laguna</p> <p>Gonzalez-Bravo, Maria Nieves; .Hospital Universitario de Canarias, La Laguna</p> <p>Beltran, Sergi; CNAG-CRG, Centre for Genomic Regulation (CRG), Barcelona Institute of Science and Technology (BIST); Universitat Pompeu Fabra (UPF),</p> <p>Dopazo, Joaquín; CIPF, Bioinformatics Department</p> <p>García-García, Francisco; Centro de Investigación Príncipe Felipe (CIPF), ; Centro de Investigación Biomédica en Red de Enfermedades Raras (CIBERER),</p> <p>FOULQUIER, Francois; CNRS/USTL, UMR8576 Structural and Functional Glycobiology Unit</p> <p>Matthijs, Gert; University of Leuven, Center for Human Genetics;</p> <p>Mills, Philippa; Institute of Child Health, Clinical Molecular Genetics</p> <p>Ribes, Antonia; Hospital Clinic and CIBERER, Department of Biochemistry and Molecular Genetics</p> <p>Egea, Gustavo; Dep. Biomedicina, Universitat de Barcelona and Institut d'Investigacions Mèdiques August Pi i Sunyer (IDIBAPS)</p> <p>Briones, Paz; Hospital Clínic, IDIBAPS, CIBERER, Biochemistry and Molecular Genetics</p> <p>Tort, Frederic; Hospital Clínic, IDIBAPS, CIBERER, Biochemistry and Molecular Genetics</p>

1
2
3
4
5
6
7
8
9
10
11
12
13
14
15
16
17
18
19
20
21
22
23
24
25
26
27
28
29
30
31
32
33
34
35
36
37
38
39
40
41
42
43
44
45
46
47
48
49
50
51
52
53
54
55
56
57
58
59
60

	Giros, Marisa; Hospital Clínic, IDIBAPS, CIBERER, Biochemistry and Molecular Genetics
Key Words:	CDG, TRAPPC11, Golgi, endoplasmic reticulum, vesicle trafficking

SCHOLARONE™
Manuscripts

For Peer Review

A new congenital disorder of glycosylation is associated to mutations in TRAPPC11

Leslie Matalonga^{1,†}, Miren Bravo^{1,†}, Carla Serra Peinado², Elisabeth García-Pelegri¹, Olatz Ugarteburu¹, Silvia Vidal¹, Maria Llambrich¹, Ester Quintana¹, Pedro Fuster-Jorge³, Maria Nieves Gonzalez-Bravo³, Sergi Beltran^{4,5}, Joaquin Dopazo⁶, Francisco Garcia-Garcia⁶, François Foulquier⁷, Gert Matthijs⁸, Philippa Mills⁹, Antonia Ribes¹, Gustavo Egea², Paz Briones¹, Frederic Tort^{1,*}, Marisa Girós^{1,*}

¹ Secció d'Errors Congènits del Metabolisme -IBC, Servei de Bioquímica i Genètica Molecular, Hospital Clínic, IDIBAPS, CIBERER, Barcelona, Spain.

² Dep. Biomedicina, Universitat de Barcelona and Institut d'Investigacions Mèdiques August Pi i Sunyer (IDIBAPS), 08036 Barcelona, Spain.

³ Neonatologia .Hospital Universitario de Canarias, La Laguna, Sta Cruz de Tenerife, Canarias, Spain

⁴ CNAG-CRG, Centre for Genomic Regulation (CRG), Barcelona Institute of Science and Technology (BIST), Baldori i Reixac 4, 08028 Barcelona, Spain

⁵ Universitat Pompeu Fabra (UPF), Barcelona, Spain

⁶ Centro de Investigación Príncipe Felipe (CIPF, CIBERER), c/Eduardo Primo Yufera 3, 46012 Valencia.

⁷ Université de Lille, CNRS, UMR 8576 – UGSF – Unité de Glycobiologie Structurale et Fonctionnelle, F- 59000 Lille, France

⁸ Centre for Human Genetics, KU Leuven, Leuven, Belgium

⁹ Genetics and Genomic Medicine UCL Great Ormond Street Institute of Child Health, 30 Guilford Street, London WC1N 1EH, United Kingdom

† Equal contribution

*co-corresponding authors

Key words: CDG, TRAPPC11, Golgi, endoplasmic reticulum, vesicle trafficking

Word count: 1861

Address correspondence to:

Marisa Girós and Frederic Tort

Secció d'Errors Congènits del Metabolisme -IBC, Servei de Bioquímica i Genètica Molecular, Hospital Clínic, IDIBAPS, CIBERER

C/Mejía Lequerica s/n, Edifici Helios III, planta baixa, 08028 Barcelona, Spain

e-mail: mgiros@clinic.ub.es, ftort@ciberer.es

Summary

Congenital disorders of glycosylation (CDG) are a heterogeneous and rapidly growing group of diseases caused by abnormal glycosylation of proteins and/or lipids. Mutations in genes involved in the homeostasis of the endoplasmic reticulum (ER), the Golgi apparatus and the vesicular trafficking from the ER to the ER-Golgi intermediate compartment (ERGIC) have been found to be associated with CDG.

Here, we report the first description of a patient with defects in both N- and O-glycosylation combined with a delayed vesicular transport in the Golgi apparatus due to mutations in *TRAPPC11*, a subunit of the TRAPPIII complex. TRAPPIII is implicated in the anterograde transport from the ER to the ERGIC as well as in the vesicle export from the Golgi apparatus. This report expands the spectrum of genetic alterations associated with CDG, providing new insights for the diagnosis and the understanding of the physiopathological mechanisms underlying glycosylation disorders.

1
2
3 Congenital disorders of glycosylation (CDG) are a heterogeneous and rapidly growing group of diseases caused
4 by abnormal glycosylation of proteins and/or lipids. Human CDG include mutations in genes involved in the
5 homeostasis of the endoplasmic reticulum (ER) and the Golgi apparatus (GA) machinery. CDG patients show a
6 highly heterogeneous clinical phenotype, usually presenting with symptoms during the neonatal period or
7 infancy. The course of the disease is generally severe and the affected individuals show multiorgan involvement
8 including central nervous system, muscle, liver, endocrine system, and coagulation abnormalities (Willett et al.,
9 2013; Freeze et al., 2015). Although the altered glycoconjugates are diverse, the diagnosis of these individuals
10 relies on the analysis of the glycosylation pattern of serum proteins. Serum transferrin (Tf) is the N-
11 glycoprotein most widely used as a tool to detect N-glycosylation defects. In addition, apoCIII analysis, a
12 mucin-type O-glycoprotein, is also useful to detect O-glycosylation defects. In fact, the aberrant glycosylation
13 patterns of these proteins are reliable biomarkers that point to the potential molecular defects underlying these
14 diseases: defects of N-glycan assembly (CDG-I), or N-glycan processing (CDG-II), or combined defects of N-
15 and O-glycosylation.

16
17
18
19
20
21
22
23
24
25
26
27
28
29
30
31
32 Mutations in genes involved in the homeostasis of the ER and the GA as well as those implicated in the vesicle
33 trafficking from the ER to the ER-Golgi intermediate compartment (ERGIC) have been found to be associated
34 with CDGs. Indeed, mutations in genes encoding for proteins implicated in vesicular Golgi transport, such as
35 the Conserved Oligomeric Golgi (COG) complex subunits [*COG1* (MIM 606973), *COG2* (MIM 606974),
36 *COG3* (MIM606975), *COG4* (MIM606976), *COG5* (MIM606821), *COG6* (MIM606977), *COG7* (MIM
37 606978), *COG8* (MIM606979)] were first described as a cause of N-glycosylation type II and O-glycosylation
38 defects (Rosnoblet et al., 2013). In recent years, the implementation of next generation sequencing
39 technologies has contributed decisively to the description of new CDGs and allowed the identification of new
40 disease-causing mutations in genes encoding for proteins implicated in the homeostasis of the Golgi apparatus
41 [*ATP6V0A2* (MIM 611716), *TMEM165* (MIM 614726) and *TMEM199*, (MIM 616815)].

42
43
44
45
46
47
48
49
50
51
52
53
54 Using whole exome sequencing we have identified the first CDG patient with a defect in N- and O-
55 glycosylation combined with a delayed ER to Golgi trafficking due to mutations in *TRAPPC11* (MIM 615356),
56 a subunit of the TRAPP III complex.
57
58
59
60

1
2
3 The patient was a boy from non-consanguineous parents. He was born prematurely at 33 weeks of gestation and
4 weighed 1,550g. He presented hypotonia and a malformation syndrome, with microcephaly, retrognathia,
5 campyactilia, high foot arches (pes cavus) and abnormal facies. MRI showed brain atrophy. Later on, he
6 developed cholestatic liver, recurrent thrombopenia, nephropathy with polyuria, alkalosis, hypernatremia and
7 hypercalciuria, and also osteopathy with osteopenia and spontaneous fracture of the tibia. Neurophysiologic
8 studies revealed motor and sensitive peripheral neuropathy and an altered central auditory discrimination. He
9 had recurrent infections, with moderate elevation of lactate. He died at 5 months of age.

10
11 Extensive metabolic studies were performed at 4 months of age. Metabolite analysis of plasma and urine
12 included amino acids, organic acids, acyl carnitines, free fatty acids, very long chain fatty acids,
13 polyunsaturated fatty acids, branched chain fatty acids and sterols. All of them showed normal results. Spleen
14 necropsy showed hyperactivities of some lysosomal enzymes (β -galactosidase, β -hexosaminidase and β -
15 glucuronidase). However, β -glucocerebrosidase, galactocerebrosidase, β -hexosaminidase, arilsulfatase and N-
16 acetyl- α -galactosaminidase activities were normal in cultured fibroblasts.

17
18 Isoelectric focusing of serum Tf showed a glycosylation pattern compatible with CDG type II (Figure 1A).
19 SELDI-TOF-MS analysis of plasma glycans revealed an abnormal percentage of N-glycan structures compared
20 to control values, with low biantennary and high monoantennary types of glycans (Supplementary Figure 1).
21 These results were in agreement with those found through the analysis of serum Tf. Moreover, the apoCIII
22 glycosylation pattern showed a clear increase of the non-sialylated forms (Figure 1A). These observations
23 suggested a combined defect of both N- and O-glycosylation, pointing to a defect of the GA function. Therefore,
24 alterations in the subunits of the COG complex (COG1-8) were analyzed by western blot and Sanger
25 sequencing but no alterations were found in any of the COG subunits (data not shown). Consequently, we
26 performed whole-exome sequencing of the patient and his healthy parents (Figure 1B). Since the biochemical
27 phenotype showed a defect in both N- and O-glycosylation we filtered for variants of genes encoding for
28 proteins involved in vesicles transport as well as in ER and GA functions. We used several filtering strategies
29 and when a recessive inheritance pattern was postulated we identified two heterozygous missense mutations in
30 *TRAPPC11* (transport protein particle complex 11). These mutations (c.1141C>G and c.3311A>G) were
31
32
33
34
35
36
37
38
39
40
41
42
43
44
45
46
47
48
49
50
51
52
53
54
55
56
57
58
59
60

1
2
3 predicted to change proline 381 to alanine (p.Pro381Ala) and threonine 1104 to alanine (p.Thr1104Ala),
4
5 respectively (Figure 1B-C). The c.1141C>G mutation was not annotated in the Exome Aggregation Consortium
6
7 (ExAC) database. Interestingly, the c.3311A>G substitution (rs78663235) has already been reported in the
8
9 ExAC database with a global allele frequency of 0.0015, but no homozygous individuals for this change have
10
11 been reported in European population. Compound heterozygosity was corroborated by the carrier status of the
12
13 father (c.[3311A>G]+[=]) and the mother (c.[1141C>G]+[=]). Results were confirmed by Sanger sequencing.
14
15
16 *TRAPPC11* encodes for a large protein of 1133 amino acids with two conserved functional regions: the foie gras
17
18 and gryzum domains (Figure 1C). TRAPPC11 has been described to be involved in the assembly and integrity
19
20 of the TRAPP III complex, which is implicated in the anterograde vesicular membrane transport from the ER to
21
22 the ERGIC as well as in vesicle mediated export from the Golgi in mammals (Kim et al., 2006; Scrivens et al.,
23
24 2011; Brunet et al., 2014). The two missense variants identified in our patient correspond to highly conserved
25
26 amino acids in higher eukaryotes, one of them within the foie gras domain (Figure 1C and Supplementary
27
28 Figure 2). The fact that the TRAPPC11 protein levels in fibroblasts of the patient were similar to those seen in
29
30 control cells suggest that these mutations do not compromise the stability of the protein but likely its function in
31
32 the whole complex (Figure 1D). Moreover, the subcellular localization of TRAPPC11 was not affected by the
33
34 mutations reported in this patient, since the protein properly localizes in the GA, as expected (Supplementary
35
36 Figure 3).

37
38
39
40 Previous studies identified mutations in *TRAPPC11* in three families with a clinical phenotype of muscular
41
42 dystrophy and myopathy with movement disorders and intellectual disability (Bögershausen et al., 2013) and in
43
44 another patient with congenital muscular dystrophy with fatty liver and infantile-onset cataracts (Liang et al.,
45
46 2015), but none of these patients were identified to be associated with an abnormal Tf or ApoCIII profile, nor
47
48 with a CDG syndrome. Immunofluorescence studies using antibodies against *cis* and *trans*-Golgi markers
49
50 demonstrated a severe fragmentation of the GA in one of the previous reports (Bögershausen et al., 2013).
51
52 Intriguingly, the morphology of the GA was normal in fibroblasts from our patient, as no significant differences
53
54 were found in the degree of Golgi compaction compared to control cells (Figure 1A). As TRAPPC11 is known
55
56 to be involved in ER to Golgi vesicular trafficking, we therefore tested whether this pathway was affected by
57
58
59
60

1
2
3 *TRAPPC11* mutations. Thus, cells were treated with brefeldin A (BFA), an inhibitor of the ER-Golgi
4 anterograde transport (Jackson et al., 2000). Upon BFA treatment both, patient and control fibroblasts showed
5 the complete disassembly of the GA (Figure 1A). Interestingly, after the removal of BFA, a significant delay in
6 the reassembly of the GA was observed in patient fibroblasts. These results revealed a defect in the anterograde
7 vesicular transport in the *TRAPPC11* patient reported here (Figure 1A). In addition, the functionality of the
8 retrograde Golgi vesicle transport was also assessed in our patient but no abnormalities were observed (data not
9 shown). These results are in agreement with the vesicular stomatitis virus (VSV-G) trafficking defect observed
10 in the patients reported by Bögershausen et al (2013).

11
12 Previous studies in mammalian cellular models have demonstrated that the presence of *TRAPPC11* is critical to
13 keep the integrity of the TRAPP III complex, as its total depletion resulted in strong fragmentation of both, the
14 Golgi apparatus and the ERGIC (Scrivens et al., 2011). However, in our patient an alteration in the GA dynamics
15 was only detected upon BFA treatment. We hypothesise that the normal expression levels and the correct
16 subcellular localization of the mutant *TRAPPC11* protein of our patient may be sufficient to maintain, at least
17 partially, the integrity of the TRAPP III complex and, subsequently, the structure of the Golgi apparatus
18 regardless of the evident ER-Golgi anterograde transport defect (Figure 1D, Supplementary Figure 3A).
19 However, the question whether the slight *TRAPPC11* alteration resulted in such a severe clinical phenotype
20 remains unanswered.

21
22 The main biochemical feature of the *TRAPPC11* patient reported here is the abnormal N and O-glycosylation
23 pattern detected in plasma Tf and apoCIII proteins (Figure 1A). This finding is novel and provides a reliable
24 biochemical marker for the diagnosis of this disorder. Moreover, our observations are supported by a recently
25 published study using a zebrafish model carrying a mutation in the *TRAPPC11* foie gras domain (DeRossi et al.,
26 2016). In that work, the authors demonstrated that lipid-linked oligosaccharides were decreased in the
27 *TRAPPC11* mutant animals and hypothesised that *TRAPPC11* deficiency causes a dysfunction in the synthesis
28 of dolichol, a substrate required for the protein N-glycosylation, and the induction of the unfolded-protein
29 response (UPR). Moreover, HeLa cells treated with siRNA against *TRAPPC11* showed an abnormal
30 accumulation of the non-glycosylated form of the signal sequence receptor α (SSR1), a protein marker with two
31
32
33
34
35
36
37
38
39
40
41
42
43
44
45
46
47
48
49
50
51
52
53
54
55
56
57
58
59
60

1
2
3 glycosylation sites not processed in the GA (DeRossi et al., 2016). Interestingly, the downregulation of other
4
5 TRAPP III subunits showed no defects in protein glycosylation. In fact, it is known that several TRAPP III
6
7 complex subunits have additional functions other than vesicle trafficking (Gedeon et al., 1999; Milev et al.,
8
9 2015). Thus, in addition to the role in maintaining TRAPP III complex integrity, TRAPPC11 may also be
10
11 involved in the regulation of N-linked glycosylation and, as a consequence, protein glycosylation might be
12
13 altered in patients with *TRAPPC11* mutations.
14
15

16 The patient reported here showed a constitutive activation of the UPR, mimicking the observations made in
17
18 TRAPPC11-deficient cellular and animal models (Figure 2) (DeRossi et al., 2016). Moreover, our results
19
20 suggested that the N-glycosylation defects observed in our patient cannot only be attributed to a dysfunction in
21
22 the dolichol synthesis pathway, as previously hypothesised (DeRossi et al., 2016), since dolichol levels in liver
23
24 necropsy from our patient were similar to those found in age matched controls (Supplementary Figure 4).
25
26 Therefore, the strong UPR activation observed in our patient suggests that the glycosylation defects may result
27
28 in the accumulation of unfolded/misfolded proteins in the ER regardless of the dolichol levels. Altogether these
29
30 observations point to a widespread role of TRAPPC11 in the molecular and cellular pathways involved in
31
32 protein glycosylation and Golgi vesicular transport.
33
34
35

36 In summary, this report expands the spectrum of genetic alterations associated with CDG, providing new
37
38 insights into the diagnosis as well as for the understanding of the physiopathological mechanisms underlying
39
40 vesicle trafficking defects and glycosylation disorders. We highlight the importance of an accurate biochemical
41
42 characterization to direct the genetic data analysis when using next generation sequencing tools. Our study
43
44 demonstrates that TRAPPC11 deficiency could lead to a disorder targeting the GA function which might be
45
46 readily identified by routine screening for abnormal glycosylation patterns of plasma proteins.
47
48
49
50
51
52
53
54
55
56
57
58
59
60

REFERENCES

- Bögershausen N, Shahrzad N, Chong JX, von Kleist-Retzow JC, Stanga D, Li Y, Bernier FP, Loucks CM, Wirth R, Puffenberger EG, Hegele RA, Schreml J, et al. 2013 Recessive TRAPPC11 mutations cause a disease spectrum of limb girdle muscular dystrophy and myopathy with movement disorder and intellectual disability. *Am J Hum Genet* 93(1):181-190.
- Brunet S, Sacher M. 2014. In sickness and in health: the role of TRAPP and associated proteins in disease. *Traffic* 15(8):803-818.
- DeRossi C, Vacaru A, Rafiq R, Cinaroglu A, Imrie D, Nayar S, Baryshnikova A, Milev MP, Stanga D, Kadakia D, Gao N, Chu J, et al. 2016. Trappc11 is required for protein glycosylation in zebrafish and humans. *Mol Biol Cell* 27(8):1220-1234.
- Freeze HH, Eklund EA, Ng BG, Patterson MC. 2015. Neurological aspects of human glycosylation disorders. *Annu Rev Neurosci* 38:105-125.
- Gedeon AK, Colley A, Jamieson R, Thompson EM, Rogers J, Sillence D, Tiller GE, Mulley JC, Géczi J. 1999. Identification of the gene (SEDL) causing X-linked spondyloepiphyseal dysplasia tarda. *Nat Genet* 22(4):400-404.
- Jackson CL. 2000. Brefeldin A revealing the fundamental principles governing membrane dynamics and protein transport. *Subcell Biochem* 34:233-272.
- Kim YG, Raunser S, Munger C, Wagner J, Song YL, Cygler M, Walz T, Oh BH, Sacher M. 2006. The architecture of the multisubunit TRAPP I complex suggests a model for vesicle tethering. *Cell* 127(4):817-830.
- Liang WC, Zhu W, Mitsuhashi S, Noguchi S, Sacher M, Ogawa M, Shih HH, Jong YJ, Nishino I. 2015. Congenital muscular dystrophy with fatty liver and infantile-onset cataract caused by TRAPPC11 mutations: broadening of the phenotype. *Skelet Muscle* 5:29.
- Marino M, Dolfi C, Paradiso C, Cavallini G, Masini M, Gori Z, Pollera M, Trentalance A, Bergamini E. 1998. Age-dependent accumulation of dolichol in rat liver: is tissue dolichol a biomarker of aging? *J Gerontol A Biol Sci Med Sci* 53(2):B87-93.
- Milev MP, Hasaj B, Saint-Dic D, Snounou S, Zhao Q, Sacher M. 2015. TRAMM/TrappC12 plays a role in chromosome congression, kinetochore stability, and CENP-E recruitment. *J Cell Biol* 209(2):221-234.
- Rosnoblet C, Peanne R, Legrand D, Foulquier F. 2013. Glycosylation disorders of membrane trafficking. *Glycoconj J* 30(1):23-31.

1
2
3 Schindelin J, Arganda-Carreras I, Frise E, Kaynig V, Longair M, Pietzsch T, Preibisch S, Rueden C, Saalfeld S,
4 Schmid B, Tinevez JY, White DJ. 2012. Fiji: an open-source platform for biological-image analysis. Nat
5 Methods 9(7):676-682.
6
7

8
9 Scrivens PJ, Noueihed B, Shahrzad N, Hul S, Brunet S, Sacher M. 2011. C4orf41 and TTC-15 are mammalian
10 TRAPP components with a role at an early stage in ER-to-Golgi trafficking. Mol Biol Cell 22(12):2083-2093.
11

12
13 Willett R, Ungar D, Lupashin V. 2013. The Golgi puppet master: COG complex at center stage of membrane
14 trafficking interactions. Histochem Cell Biol 140(3):271-283.
15
16

17
18 **Funding:** This research was supported by the Instituto de Salud Carlos III (PI/1101096) and the Centro de
19 Investigación Biomédica en Red de Enfermedades Raras (CIBERER), an initiative of the Instituto de Salud
20 Carlos III (Ministerio de Ciencia e Innovación, Spain). This study was supported by the Agència de Gestió
21 d'Ajuts Universitaris i de Recerca (AGAUR) (2014: SGR 393). PBM is in receipt of a Great Ormond Street
22 Hospital (GOSH) Children's Charity Leadership award and is supported by the National Institute for Health
23 Research Biomedical Research Centre at GOSH for Children NHS Foundation Trust and University College
24 London.
25
26
27
28
29
30
31
32
33

34
35
36 **Acknowledgements:** Thank you to Dr. Angela Arias (Hospital Clínic de Barcelona) for fibroblasts culturing
37 and Dr. Margarita Rodés (Hospital Clínic de Barcelona) to perform the amino acids analyses. We also thank Dr.
38 Amparo Chabás (Hospital Clínic de Barcelona) for performing the lysosomal enzymatic activities. Library
39 preparation and whole exome sequencing was performed at the Centro Nacional de Análisis Genómico
40 (CNAG-CRG, Barcelona, Spain). We are grateful to the family involved in this study.
41
42
43
44
45
46
47

48
49 **Potential conflicts of Interest:** The authors have no conflicts of interest to disclose.
50
51

52 **Ethics:** All the procedures were approved by the ethics committee of the Hospital Clínic, Barcelona. All
53 procedures followed were in accordance with the ethical standards of the responsible committee on human
54 experimentation (Hospital Clínic de Barcelona) and with the Helsinki Declaration of 1975, as revised in 2000.
55
56
57
58
59
60

FIGURE LEGENDS

Figure 1. Identification of *TRAPPC11* mutations in a patient with defects in N- and O-glycosylation. (A) Transferrin and Apo CIII glycosylation patterns of a control individual (C), a CDG type I patient (CDG-I) and the TRAPPC11 patient (P). (B) Exome data analysis and filtering steps leading to the identification of *TRAPPC11* as a putative genetic cause of the disease. (C) Human TRAPPC11 protein scheme showing the position of the identified mutations. (D) Western blot analysis of TRAPPC11 in patient fibroblasts (P) and in a control individual (C). SDHA was used as loading control.

Figure 2. ER-to-Golgi anterograde membrane flow is defective in the TRAPPC11 patient. (A) Fibroblasts from the TRAPPC11 patient and from a control individual were treated with brefeldin A (BFA) for 15 min to block ER-Golgi anterograde transport. (B) After BFA removal, the percentage of cells with assembled Golgi apparatus together with the (C) Golgi compactation index (calculated as $4\pi \cdot \Sigma(\text{areas}) / \Sigma(\text{perimeter})^2$) were analyzed at different time points, using the Fiji image processing package (Schindelin et al., 2012). Antibody against GM130 was used to stain the Golgi apparatus. (D) Fibroblasts from TRAPPC11 patient and from a control individual were analyzed by qPCR for expression of four UPR (unfolded protein response) effectors and target genes using the comparative Ct method. *GAPDH* gene was used as an internal control. Results are expressed in relative units (RU), * $p < 0.05$.

Supplementary Figure 1. Analysis of glycans in negative ion mode by SELDI-TOF-MS in plasma from the TRAPPC11 patient showed an altered percentage of N-glycan structures compared to control values. The major abnormal species corresponds to biantennary N-linked glycan that lacks a single SA residue and a single Gal residue. Relative amounts are presented as a percentage of the total identified N-linked glycans structures compared to control values. n.d.: not detectable; SA: sialic acid; Gal: galactose; GlcNac: N-Acetylglucosamine.

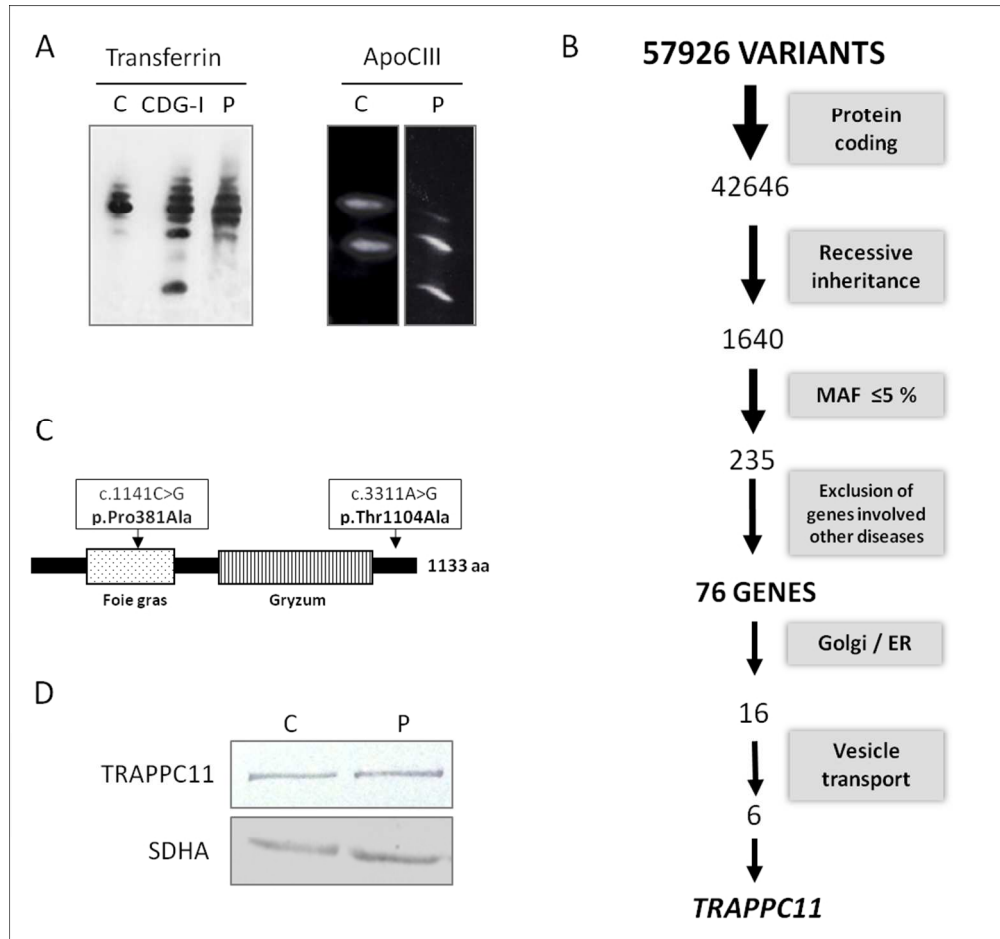
Supplementary Figure 2. Conservation of the aminoacids mutated in the TRAPPC11 patient among different species. The mutated aminoacids are indicated by an arrow.

1
2
3 **Supplementary Figure 3.** Subcellular localization of the TRAPC11 protein in fibroblasts from the TRAPPC11
4 patient and in a control individual. Antibodies were anti-TRAPPC11, anti-GM130 (Golgi) and anti-PDI (ER).
5
6
7
8

9
10 **Supplementary Figure 4.** Analysis of dolichol in liver necropsy from the TRAPPC11 patient and control
11 individuals by HPLC according to Marino et al (1998). Values of dolichol are expressed in ng/mg frozen liver.
12
13
14
15
16
17
18
19
20
21
22
23
24
25
26
27
28
29
30
31
32
33
34
35
36
37
38
39
40
41
42
43
44
45
46
47
48
49
50
51
52
53
54
55
56
57
58
59
60

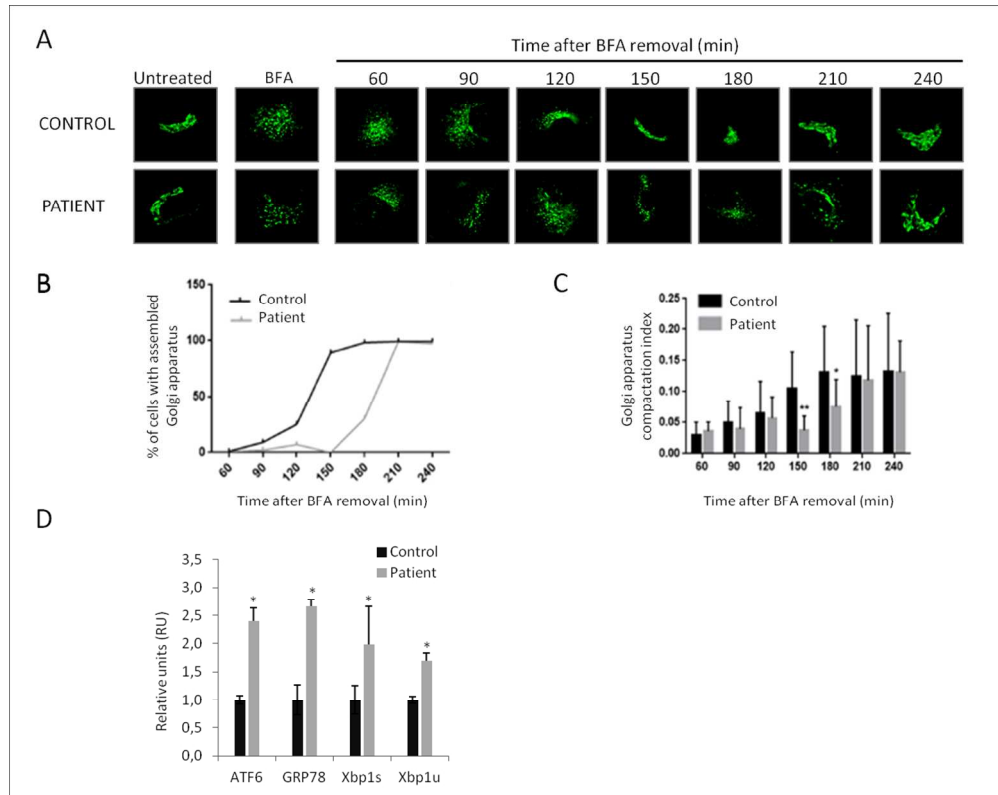
For Peer Review

1
2
3
4
5
6
7
8
9
10
11
12
13
14
15
16
17
18
19
20
21
22
23
24
25
26
27
28
29
30
31
32
33
34
35
36
37
38
39
40
41
42
43
44
45
46
47
48
49
50
51
52
53
54
55
56
57
58
59
60



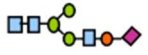




182x170mm (150 x 150 DPI)





220x174mm (150 x 150 DPI)

1
2
3
4
5
6
7
8
9
10
11
12
13
14
15
16
17
18
19
20
21
22
23
24
25
26
27
28
29
30
31
32
33
34
35
36
37
38
39
40
41
42
43
44
45
46
47
48
49
50
51
52
53
54
55
56
57
58
59
60

		<u>Control</u>	<u>Patient</u>
Biantennary-SA-Gal-GlcNac		n.d.	5%
Biantennary-SA-Gal		n.d.	9%
Biantennary-SA		11%	21%
Biantennary		50%	36%
Triantennary		6%	n.d.

118x76mm (150 x 150 DPI)

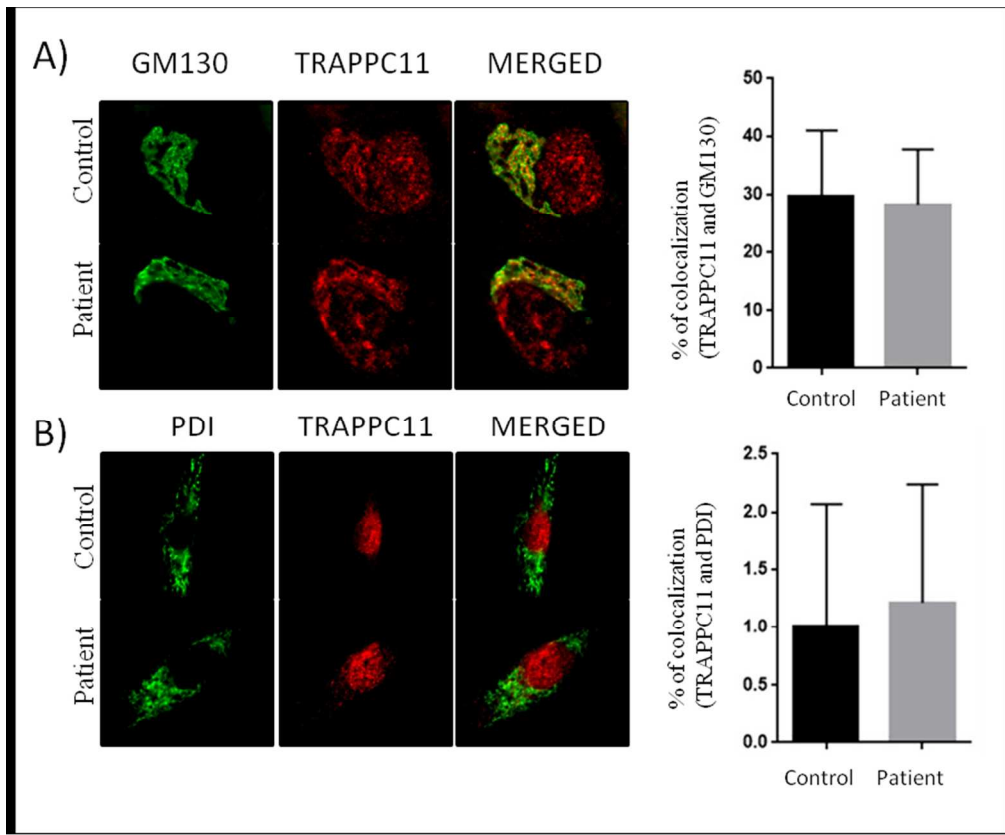
Review

1
2
3
4
5
6
7
8
9
10
11
12
13
14
15
16
17
18
19
20
21
22
23
24
25
26
27
28
29
30
31
32
33
34
35
36
37
38
39
40
41
42
43
44
45
46
47
48
49
50
51
52
53
54
55
56
57
58
59
60

		c.3311A>G p.Thr1104Ala			
H. Sapiens	1101	-----	PNF T NQLLRRFIPTSIFVKP	1120	
P. Troglodytes	1075	-----	-----QYFCQA	1080	
M. mulatta	1101	-----	PNF T NQLLRRFIPTSIFGQA	1120	
C. Lupus	1101	-----	PHF T NQLLRRFIPTSIFVKP	1120	
B. Taurus	1101	-----	PNF T NQLLRRFIPTSIFVKP	1120	
M. Musculus	1101	-----	PNF T NQLLRRFIPTSIFVKP	1120	
R. Norvegicus	1101	-----	PNF T NQLLRRFIPTSIFVKP	1120	
G. Gallus	1100	-----	PNF T NQLLRRFIPTHIFVKP	1119	
D. Rerio	1101	-----	PNI S SQLLRRLFPSRIFVKP	1120	
		c.1141C>G p.Pro381Ala			
H. Sapiens	345	-----	NPGFYYQQAAY-YAQERKQLAKTLCNHEASVMYPNP D LET	384	
P. Troglodytes	345	-----	NPGFYYQQAAY-YAQERKQLAKTLCNHEASVMYPNP D LET	384	
M. mulatta	345	-----	NPGFYYQQAAY-YAQERKQLAKSLCNHEASIMYPNP D LET	384	
C. Lupus	345	-----	NPGFYYQQAAY-YAQERKQLAKSLCNHEASVTYPNP D LET	384	
B. Taurus	345	-----	NPGFYYQQAAY-YAQERKQLAKALCNHEASVTYPNP D LET	384	
M. Musculus	345	-----	NPGFYYQQAAY-YAQERKQHAKALCNHDAAVMYPNP D LET	384	
R. Norvegicus	345	-----	NPGFYYQQAAY-YAQERKQHAKALCNHDAAVVYVSP D LET	384	
G. Gallus	345	-----	NPGFYYQQAAY-YAQERKQLASMLCNHDSVVYPNP D LET	384	
D. Rerio	345	-----	NPGFYYQQAAY-YAQERKQQAGQLCSHEPGVGYPP D LET	384	
D. Melanogaster	347	-----	HPGIYYHKAAE-FVMKRRDAAMEAYAA M QASSEATP F IQN	386	

163x179mm (150 x 150 DPI)

1
2
3
4
5
6
7
8
9
10
11
12
13
14
15
16
17
18
19
20
21
22
23
24
25
26
27
28
29
30
31
32
33
34
35
36
37
38
39
40
41
42
43
44
45
46
47
48
49
50
51
52
53
54
55
56
57
58
59
60



152x126mm (150 x 150 DPI)

view

	Age	Dolichols (ng/mg)
TRAPPC11	5 m	11,8
Control 1	11 d	14,1
Control 2	29 d	13,8
Control 3	30 d	11,4
Control 4	2 y	11,3

82x40mm (150 x 150 DPI)

Peer Review