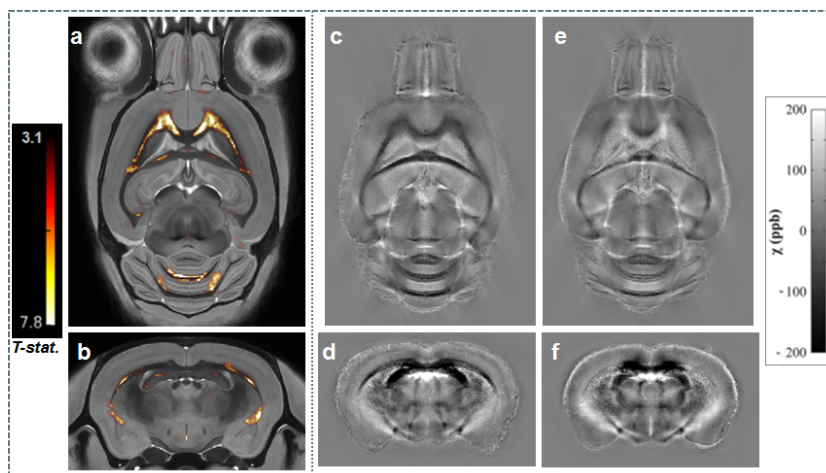


Gadolinium-enhanced magnetic susceptibility contrast is reduced in the corpus callosum of a mouse model of TauopathyJames O'Callaghan¹, Holly Holmes¹, Nicholas Powell¹, Ozama Ismail¹, Niall Colgan¹, Jack Wells¹, Bernard Siow¹, Michael O'Neill², Emily Collins³, Karin Shmueli⁴, and Mark Lythgoe¹¹Centre for Advanced Biomedical Imaging, University College London, London, Greater London, United Kingdom, ²Eli Lilly & Co. Ltd, Windlesham, Surrey, United Kingdom, ³Eli Lilly and Company, Indianapolis, United States, ⁴Department of Medical Physics and Biomedical Engineering, University College London, London, United Kingdom**Target Audience** Researchers with an interest in neurodegenerative diseases and neuroimaging of the mouse brain.**Purpose** Tauopathy is an umbrella term used to describe a group of neurodegenerative diseases linked by the presence of aggregated tau protein in the brains of sufferers. In a subset of these diseases, abnormalities in the white matter, including proteinaceous inclusions and reductions in myelin, have been found in patients [1, 2]. Myelin has been identified as the main source of contrast between grey and white matter in MRI magnetic susceptibility maps of the mouse brain [3, 4]. Furthermore, this effect has been shown to be amplified through the use of gadolinium contrast agents [5]. The rTG4510 mouse model exhibits selective tau pathology [6] and compared to wild type littermates, differences have been shown in Diffusion Tensor Imaging measures in the corpus callosum [7]. Unmyelinated processes are visible in this model through electron microscopy from four months of age [7]. We have developed a novel methodology by combining gadolinium-enhanced magnetic susceptibility mapping with atlas based statistical parametric mapping to investigate white matter pathology in the rTG4510 mice at high resolution. Maps were generated for ex vivo mouse brains which were then registered into a common space where a voxel-wise comparison of magnetic susceptibility values was carried out in a mouse model of tauopathy for the first time.**Methods** Imaging: 10 rTG4510 mice and 8 wild-type littermates were culled at 7.5 months and perfuse-fixed with 0.9% saline (15 – 20 mL) followed by 10% Buffered Formalin (50 mL) doped with Magnevist (8 mM). High resolution ex vivo images of three brains were acquired simultaneously at 9.4T (Agilent Inc. Palo Alto, CA, USA) by securing brains in a purpose built holder. A 35 mm diameter birdcage RF coil was used for RF transmission and signal detection using a gradient echo sequence with the following parameters: FOV = 32 mm x 25 mm x 25 mm; resolution = 40 μ m x 40 μ m x 40 μ m; TR = 17 ms; TE = 4.54 ms; flip angle = 51°; NSA = 6. Total imaging time was approx. 11 h.Magnetic susceptibility mapping: Phase images were reconstructed and brains were separated automatically using a fully automated software pipeline developed in house before spatial unwrapping using FSL Prelude (fsl.fmrib.ox.ac.uk/fsl/fsl-4.1.9/fugue/prelude.html). Background field effects were removed using the Projection on to Dipole Fields method (PDF.m, MEDI toolbox, Cornell MRI Research Lab) [8, 9]. Susceptibility maps were calculated (Fig. 1c-f) by thresholded k-space division ($t=1$) [10]. The mean susceptibility in the grey matter of each mouse brain was used as a reference value for its susceptibility map. A grey matter mask (Figure 2) was generated automatically for this purpose by intensity thresholding in the magnitude atlas image.Image Registration and Statistical Parametric Mapping: A group-wise registration was performed on the reconstructed magnitude images using a fully automated software pipeline. The brains were separated and oriented before affine and then non-rigid registration using NiftyReg [11]. The affine matrices and deformation fields from the group-wise registration were then applied to the corresponding magnetic susceptibility maps to transform them into the same space for voxel-wise analysis.Statistical Parametric Mapping (SPM, <http://www.fil.ion.ucl.ac.uk/spm/>) was used to investigate susceptibility differences between the wild-type and transgenic groups. Images were smoothed to remove any registration errors using a gaussian kernel (0.1mm FWHM). This was followed by a two sample t-test for statistical significance ($P < 0.05$, False Discovery Rate corrected for multiple comparisons).**Results** Marked, region-specific, increases in susceptibility were observed in the corpus callosum as shown in the Statistical Parametric Map in Figure 1 (a and b). Mean images of the registered susceptibility maps were calculated for the wild-type (Figure 1 c,d) and rTG4510 mice (Figure 1 e,f). In both the coronal and axial slices presented in Figure 1, a reduction of white matter contrast is observed in the rTG4510 susceptibility maps in regions that correspond to increases in the SPM. This appears to be due to an increase in the mean susceptibility in these white matter regions in the rTG4510.**Discussion** Magnetic susceptibility maps of the ex vivo mouse brain were registered using the transformations from the non-rigid registration of the magnitude data. Significant increases in susceptibility in the white matter of the rTG4510 mouse were observed using a voxel-wise group comparison. This technique may provide improved sensitivity to group differences in magnetic susceptibility in the mouse brain when compared to regional estimates used previously [12, 13]. Refinement of the thresholded k-space division protocol should improve estimates of magnetic susceptibility and will be accomplished through both optimization of the threshold used and application of a correction for systematic underestimation [14].

In this study, we have shown that contrast enhanced magnetic susceptibility mapping is sensitive to white matter changes in the rTG4510. The increases observed in these regions may be due decreased levels of myelin, known to be diamagnetic relative to grey matter, or alternatively the increased uptake of paramagnetic Gadolinium caused by a breakdown of the biological membranes in the white matter. Further work to detect the root cause will involve histological staining for myelin in the implicated regions and imaging of samples that have not been doped with Gadolinium.

Conclusions This work highlights the potential of atlas based magnetic susceptibility mapping as an imaging biomarker sensitive to white matter changes driven by Tau pathology in neurodegenerative diseases.**References** [1] Spillantini, M.G., T.D. Bird, and B. Ghetti, *Brain Pathology*, 1998. **8**(2): p. 387-402. [2] Kovacs, G.G., et al, *Journal of Neuropathology & Experimental Neurology*, 2008. **67**(10): p. 963-975. [10.1097/NEN.0b013e3181817a80f](https://doi.org/10.1097/NEN.0b013e3181817a80f). [3] Argyridis, I., et al., *NeuroImage*, 2014. **88**(0): p. 134-142. [4] Liu, C., et al., *NeuroImage*, 2011. **56**(3): p. 930-938. [5] Dibb, R., et al., *Magnetic Resonance in Medicine*, 2014: p. n/a-n/a. [6] Ramsden, M., et al., *The Journal of Neuroscience*, 2005. **25**(46): p. 10637-10647. [7] Sahara, N., et al., *Neurobiology of Aging*, 2014. **35**(6): p. 1364-1374. [8] Liu, T., et al., *NMR in Biomedicine*, 2011. **24**(9): p. 1129-1136. [9] Rochefort, L., et al., *Magnetic Resonance in Medicine*, 2010. **63**(1): p. 194-206. [10] Shmueli, K., et al., *Magnetic Resonance in Medicine*, 2009. **62**(6): p. 1510-1522. [11] Modat, M., et al., *Computer Methods and Programs in Biomedicine*, 2010. **98**(3): p. 278-284. [12] Klohs, J., et al., *J Cereb Blood Flow Metab*, 2011. **31**(12): p. 2282-2292. [13] Klohs, J., et al., *PLoS ONE*, 2013. **8**(6): p. e66097. [14] Schweser, F., et al., *Magnetic Resonance in Medicine*, 2013. **69**(6): p. 1581-1593.**Figure 1.** SPM (FDR corrected) overlaid on magnitude image atlas, indicating increases in magnetic susceptibility in the rTG4510 mice (a,b) and mean magnetic susceptibility maps in the WT (c,d) and rTG4510 mice (e,f).**Figure 2.** Grey matter mask