

Journal of Glaucoma

A novel method of extending glaucoma drainage tube - 'Tube-in-tube' technique --Manuscript Draft--

Manuscript Number:	JOG-D-16-0360
Full Title:	A novel method of extending glaucoma drainage tube - 'Tube-in-tube' technique
Article Type:	Original Study
Keywords:	Glaucoma drainage implants, tube extension, glaucoma surgery
Corresponding Author:	Mark Chiang, MBBS, MPhil, FRANZCO Queensland Eye Institute South Brisbane, Queensland AUSTRALIA
Corresponding Author Secondary Information:	
Corresponding Author's Institution:	Queensland Eye Institute
Corresponding Author's Secondary Institution:	
First Author:	Mark Chiang, MBBS, MPhil, FRANZCO
First Author Secondary Information:	
Order of Authors:	Mark Chiang, MBBS, MPhil, FRANZCO Jayne Elizabeth Camuglia, Bsc, MBBS Peng Tee Khaw, PhD, FRCOphth
Order of Authors Secondary Information:	
Manuscript Region of Origin:	AUSTRALIA
Abstract:	<p>Purpose To describe a new and simple technique of glaucoma tube extension which carries several advantages over previously described techniques.</p> <p>Patients and Methods A retrospective non-comparative case series of 3 patients (1 adult and 2 pediatric cases) with glaucoma tube retraction managed by the 'tube-in-tube' technique. The follow-up duration ranges from 1 month to 3 years.</p> <p>Results Adequate tube position and length were seen in all cases throughout the follow-up period. No tube migration was seen. The intraocular pressures (IOP) were significantly reduced and maintained in all cases. There was no visual loss as a result of the procedure.</p> <p>Conclusion This new 'tube-in-tube' GDD tube extension technique is safe and simple to perform, and has many advantages over previously reported techniques. It can be used in both the adult and pediatric glaucoma population, and is not limited to the type of drainage implants.</p>

Cover Letter

Dear Editor,

We would like to submit a surgical technique paper regarding glaucoma drainage tube extension:

Title: A novel method of extending glaucoma drainage tube – ‘Tube-in-tube’ technique

Authors: MY.Chiang, JE. Camuglia, PT.Khaw

Summary:

Glaucoma drainage tube retraction is a well-recognised but uncommon complication after glaucoma drainage device (GDD) surgery. It occurs more frequently in the paediatric glaucoma population and can be a complex and difficult complication to manage. Several techniques have been used to extend the retracted tube, all with their own potential shortcomings. We describe a novel ‘tube-in-tube’ technique which was successfully used to treat GDD tube retraction in three consecutive patients (3 eyes). This new method of extending GDD tube is simple to perform, and has many advantages over previously reported techniques.

We feel this new technique could alleviate many of the problems associated with previous tube drainage extension techniques and will benefit the glaucoma community and patients. Please consider this article for publication.

We are the original authors of this work and have no financial disclosures. Also, there is no conflict of interest to disclose.

Kind Regards,

Mark Chiang.

Title: A novel method of extending glaucoma drainage tube – ‘Tube-in-tube’ technique

MY.Chiang, JE. Camuglia, PT.Khaw

Word Count: 989

Mark Yu-Ming Chiang

MBBS, MPhil, FRANZCO

Consultant Ophthalmologist

Queensland Eye Institute

Lady Cilento Children’s Hospital

Brisbane, Queensland, Australia

No Financial Disclosure

Jayne Elizabeth Camuglia

BSc, MBBS

Paediatric Ophthalmology Fellow

Lady Cilento Children’s Hospital

Brisbane, Queensland, Australia

No Financial Disclosure

Peng Tee Khaw

PhD, FRCOphth

NIHR Biomedical Research Centre at Moorfields Eye Hospital NHS Foundation Trust & UCL Institute of Ophthalmology

London, United Kingdom

No Financial Disclosure

Corresponding Author

Dr Mark Yu-Ming Chiang

Queensland Eye Institute

140 Melbourne Street, South Brisbane, 4101, QLD, Australia

Telephone: +61-732395000, Fax: +61-738442246, Email: ym_chiang@hotmail.com

ABSTRACT

Purpose

To describe a new and simple technique of glaucoma tube extension which carries several advantages over previously described techniques.

Patients and Methods

A retrospective non-comparative case series of 3 patients (1 adult and 2 pediatric cases) with glaucoma tube retraction managed by the 'tube-in-tube' technique. The follow-up duration ranges from 1 month to 3 years.

Results

Adequate tube position and length were seen in all cases throughout the follow-up period. No tube migration was seen. The intraocular pressures (IOP) were significantly reduced and maintained in all cases. There was no visual loss as a result of the procedure.

Conclusion

This new 'tube-in-tube' GDD tube extension technique is safe and simple to perform, and has many advantages over previously reported techniques. It can be used in both the adult and pediatric glaucoma population, and is not limited to the type of drainage implants.

Keywords:

Glaucoma drainage implants, tube extension, glaucoma surgery

INTRODUCTION

The use of glaucoma drainage implants is increasing, especially in the post-TVT study era.^{1,2} The post-operative complications such as hypotony, corneal decompensation and tube exposure still occur despite improved surgical techniques and across all commercially available implants. In addition, tube retraction can occur at any stage post operatively leading to drainage failure, raised intraocular pressure and progressive glaucomatous optic neuropathy. Tube retraction occurs more frequently in the paediatric population due to the exaggerated scarring response and ocular/axial length growth. Many extension techniques for tube retraction have been described including re-routing the tube using a commercially available Tube Extender (New World Medical, CA),^{3,4} using 22-gauge intravenous angiocatheter⁵⁻⁸ or Crawford tubing⁹. Alternatively, a second GDD can be inserted at a different site.

Patients and Methods

We describe a novel 'tube-in-tube' technique to extend the existing tube on Baerveldt GDD and report its success in treating GDD failure due to tube retraction in three consecutive patients. (Table 1)

SURGICAL TECHNIQUE

Using minimal dissection, the anterior portion of the drainage tube was surgically exposed. The tube was then flushed with Balanced Salt Solution to assess patency. A tube segment was obtained from either a new GDD or a Tube Extender. A Kelman-McPherson forceps was then inserted into one end of the tube with the tip closed.(Figure 1A) The tip was then opened to stretch the tube allowing adequate opening for second tube insertion. The technique in principle is similar to inserting a

scleral band into silicone sleeve in scleral buckling.(Figure 1B and 1C) To facilitate the withdraw of the Kelman-McPherson forceps, a non-toothed forceps (to avoid tube trauma) may be required to maintain the two tube segment fixation.(Figure 1D,E) The joined tube was stretched to check strength and flushed to ensure patency and watertight interface.(Figure 1F) Depending on the surgical exposure and mobility of the pre-existing tube, either the original tube can be inserted into a stretched second tube or vice-versa.(Figure 2) The extended tube was then inserted into the anterior chamber (AC) using a 25-gauge tract to minimise peritubular leakage. A new entry site can be created if required. 10-0 nylon or polypropylene suture was used to fixate the tube to the underlying sclera. Either an AC maintainer or viscoelastic was used to prevent intraoperative hypotony. Depending on the state of the pre-existing scleral graft, a new scleral graft can be placed but it is usually not required. The Tenon's and conjunctiva were then closed.

CASE 1

A 55-year-old male with bilateral sclerocornea was referred for right only-eye Baerveldt tube retraction with uncontrolled intraocular pressure (IOP). The right eye had 6/15 vision and IOP of 33 mmHg on maximally tolerated therapy. The right cup-to-disc ratio was 0.9. The left eye lost all vision due to advanced glaucoma. Past history included a right superotemporal Baerveldt GDD and subsequent removal due to tube exposure. A second Baerveldt GDD was placed superonasally with good IOP control for 6 months but the tube retracted out of the AC. Tube extension was performed in September 2013 using the 'tube-in-tube' technique without additional scleral grafting. At 2.5 years, there was no tube exposure and IOP remained controlled at 10 mmHg.

CASE 2

A 4-year-old male with aphakic glaucoma requiring a second left superonasal Baerveldt GDD for IOP control. At 6 months post-operatively, the left IOP remained high despite maximal medical therapy, steroid cessation and removal of the intraluminal stent suture. Further examination under anaesthesia (EUA) was carried out which confirmed a retracted tube and he underwent 'tube-in-tube' extension procedure in November 2015. At 6 months, the left vision remained stable at 6/24 with IOP of 15 mmHg on no glaucoma medications.

CASE 3

A 6-year-old male with bilateral congenital glaucoma. A right superotemporal Baerveldt GDD was implanted which controlled the right IOP at 10 mmHg. At 13 months, the right IOP became elevated at 30mmHg with the tube not visible in AC. The vision was 4/120 in the right eye. Additional topical therapy was commenced and an EUA confirmed tube retraction. The 'tube-in-tube' extension was carried out in June 2016. At 1 month post-operatively, the right eye had IOP of 9 mmHg off all glaucoma medications and stable vision.

DISCUSSION

Several GDD extension techniques have been described with good long term success. The most widely used methods include the use of a 22-gauge angiocatheter and the commercially available Tube Extender.³⁻⁷ The entire tube-plate complex can also be moved anteriorly but extensive tissue dissection is often required which can promote further fibrosis leading to GDD failure. Alternatively, a second GDD can be implanted but it is not always desired.

Tube joined using an angiocatheter is an economical technique but AC migration have been reported following trauma without a fixation through-and-through suture.¹⁰ Tube Extender implantation requires posterior dissection and fixation closer to GDD plate to avoid erosion or exposure. Its use

also adds bulk to the eye which can make tissue closure problematic especially with extensive tissue shortage or scarring.

The tube-in-tube technique offers significant advantages over previously reported techniques as outlined below:

1. Minimal surgical dissection and exposure required to avoid disruption of the pre-existing GDD bleb which can cause early hypotony and longer-term GDD failure.
2. The joined tube carries high tensile strength and does not migrate. It behaves very similar to a new GDD tube.
3. Fixation suture is not required at the watertight 'tube-in-tube' interface which prevents post-operative hypotony.
4. It does not add bulk to the globe and additional scleral grafting is usually not required. This facilitates easier tissue closure.
5. Simple and quick to perform with a short learning curve, and does not require any specialised equipment.

The only disadvantage with the tube-in-tube technique is the higher economic cost compared to the use of angiocatheter. Currently there is no single medical-grade sterile silicone tube commercially available so either a new GDD or Tube Extender is needed each time. Given our experience, we would encourage the manufacturers to consider packaging single tube segments for this purpose.

Acknowledgement:

"Dr Peng Tee Khaw is supported by the National Institute for Health Research (NIHR) Biomedical Research Centre at Moorfields Eye Hospital NHS Foundation Trust and UCL Institute of Ophthalmology, the Medical Research Council, Moorfields Eye Charity, the Helen Hamlyn Trust in memory of Paul Hamlyn, the Michael and Ilse Katz Foundation, Ron and Liora Moskovitz, and Fight for Sight (UK)."

Legends

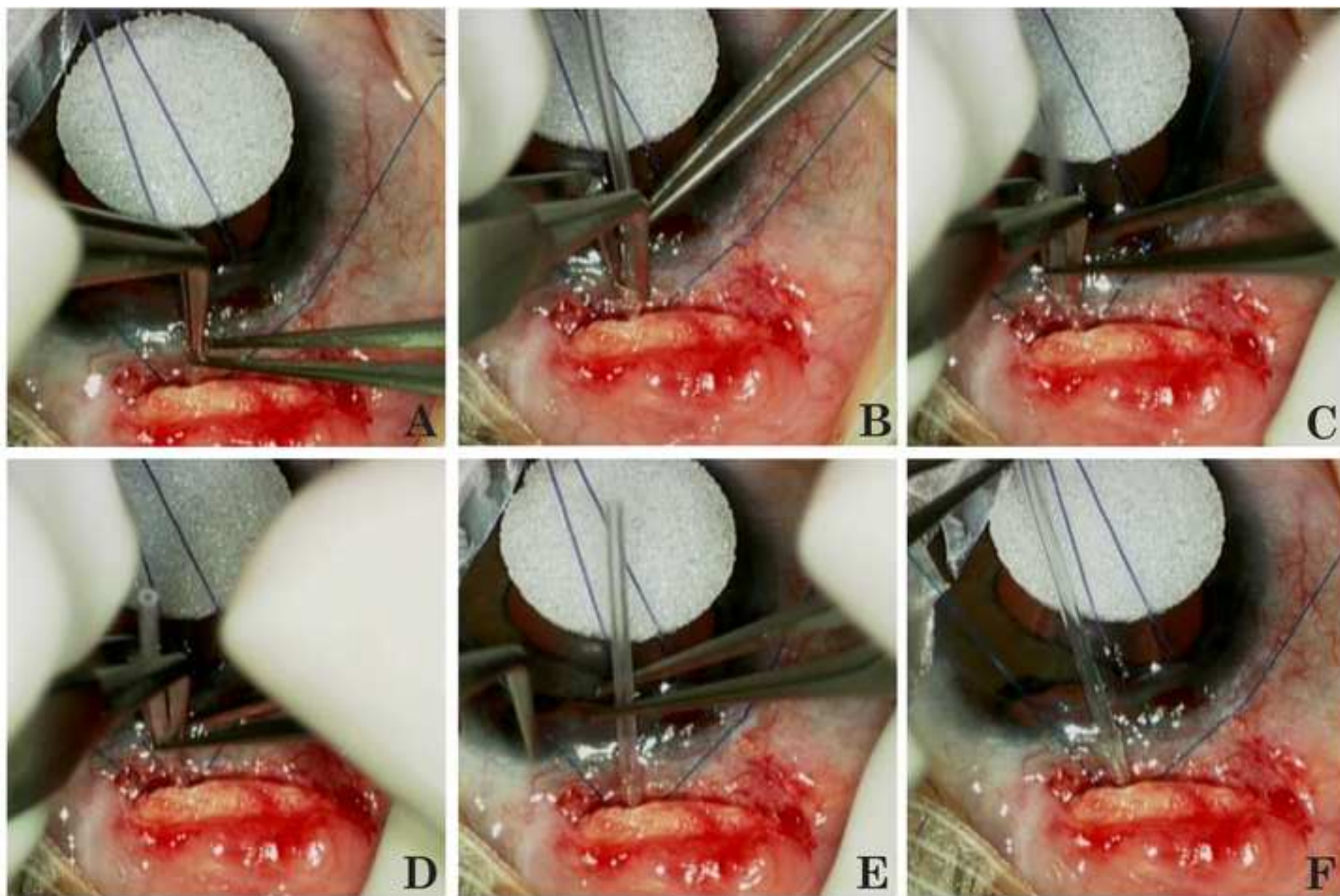
Figure 1. A, A Kelman-McPherson forceps was inserted into pre-existing tube with closed tip. B, The tube was stretched to allow insertion of new tube. C, The second tube was inserted. D, A non-toothed forceps was used to facilitate removal of the Kelman-McPherson forceps. E, Completion of tube-in-tube extension. F, The joined tube was stretched to check tensile strength.

Figure 2. Diagrammatic illustration of Tube-in-tube technique with Kelman-McPherson forceps

Table 1. Summary of 3 cases that underwent tube-in-tube extension technique

REFERENCE

1. Chadha N, Liu J, Teng CC. Resident and Fellow Glaucoma Surgical Experience Following the Tube Versus Trabeculectomy Study. *Ophthalmology* 2015;122:1953-1954.
2. Gedde SJ, Schiffman JC, Feuer WJ, et al. Treatment outcomes in the Tube Versus Trabeculectomy (TVT) study after five years of follow-up. *Am J Ophthalmol* 2012;153:789-803 e782.
3. Sarkisian SR, Netland PA. Tube extender for revision of glaucoma drainage implants. *J Glaucoma* 2007;16:637-639.
4. Merrill KD, Suhr AW, Lim MC. Long-term success in the correction of exposed glaucoma drainage tubes with a tube extender. *Am J Ophthalmol* 2007;144:136-137.
5. Moghimi S, Mohammadi M. Extension of a retracted ciliary sulcus tube of Ahmed glaucoma implant with angiocatheter segment. *Int Ophthalmol* 2012;32:409-412.
6. Mustafa MS, Azuara-Blanco A. Surgical technique: complex glaucoma case requiring Molteno drainage tube extension. *Clin Ophthalmol* 2011;5:307-310.
7. Bansal A, Fenerty CH. Extension of retracted glaucoma drainage tube using a 22-gauge intravenous catheter in complex pediatric glaucoma. *J Glaucoma* 2010;19:248-251.
8. Smith MF, Doyle JW. Results of another modality for extending glaucoma drainage tubes. *J Glaucoma* 1999;8:310-314.
9. Fechter H, Sarkisian S, Budenz D, et al. How Do I Extend a Tube? *Glaucoma Today* January/February 2009:37-40.
10. Sheets CW, Ramjattan TK, Smith MF, et al. Migration of glaucoma drainage device extender into anterior chamber after trauma. *J Glaucoma* 2006;15:559-561.



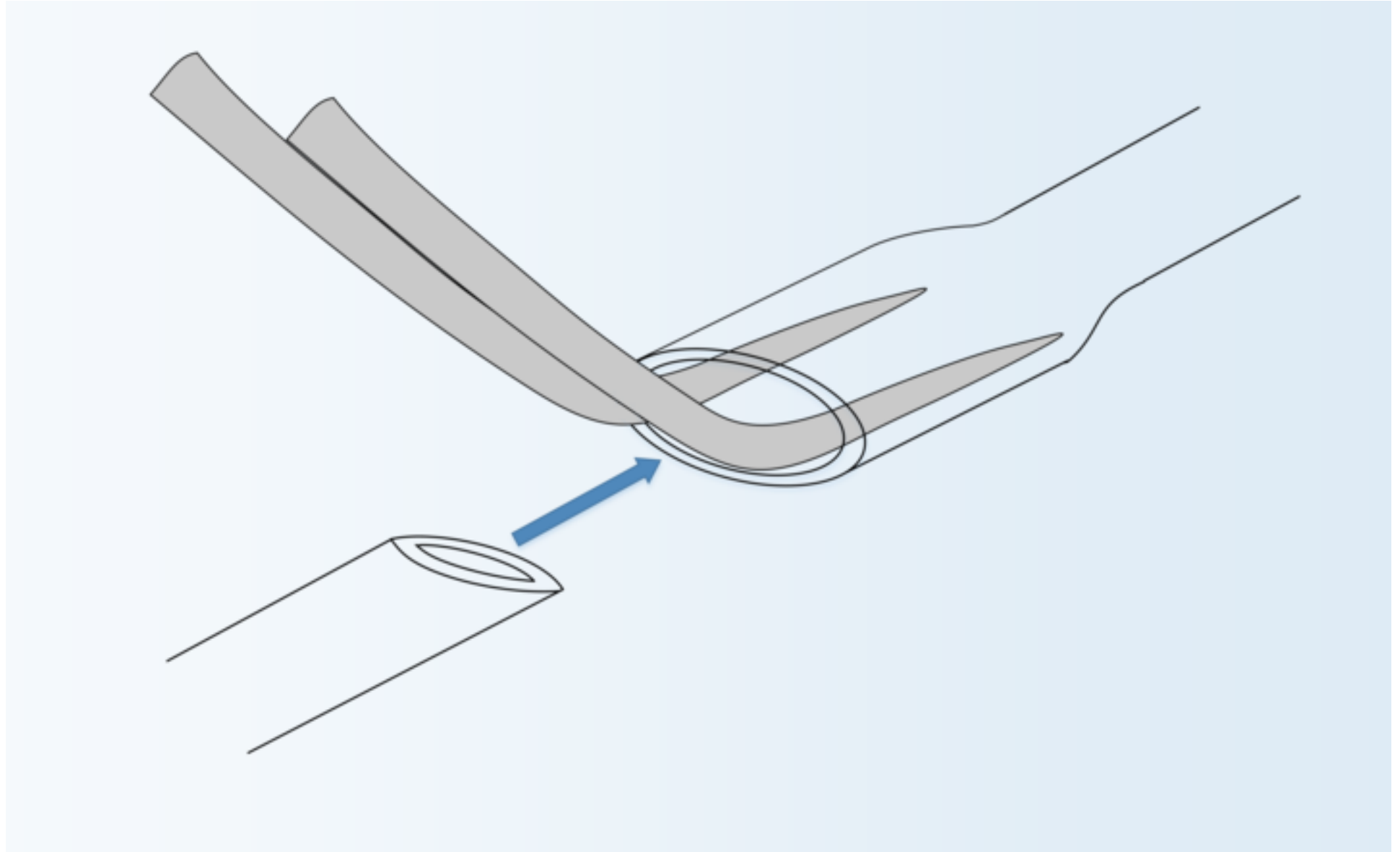


Table 1

	Glaucoma type	Previous treatment	Visual Acuity (Snellen)		IOP (mmHg)		Medications		Follow up (months)
			Pre-op	Post-op	Pre-op	Post-op	Pre-op	Post-op	
Case 1 55 y/o ♂ Right eye	Sclerocornea	Baerveldt GDD & removal, Second Baerveldt GDD	6/15	6/15	33	10	Cosopt Bimatoprost	Cosopt	30 months
Case 2 4 y/o ♂ Left eye	Aphakic glaucoma	Trabeculotomy Baerveldt GDD, Second Baerveldt GDD	6/24	6/24	32	15	Cosopt Bimatoprost	Nil	6 months
Case 3 6 y/o ♂ Right eye	Congenital glaucoma	Trabeculotomy, Moltano GDD, cyclodiode, Baerveldt GDD	4/120	4/120	30	9	Bimatoprost Dorzolamide Timolol	Nil	1 month

Table 1. Summary of 3 cases that underwent tube-in-tube extension technique