

**Clinical spectrum of sporadic and familial FTD**

Journal:	<i>Journal of Neurochemistry</i>
Manuscript ID	JNC-2016-0138.R1
Manuscript Type:	Review
Date Submitted by the Author:	10-Apr-2016
Complete List of Authors:	Woollacott, Ione; UCL, - Rohrer, Jonathan; University College London Institute of Neurology, UCL
Area/Section:	Clinical Studies, Biomarkers & Imaging
Keywords:	frontotemporal dementia, amyotrophic lateral sclerosis, progranulin, tau, C9orf72

SCHOLARONE™
Manuscripts

review

1
2
3 *Main title*

4
5 **The clinical spectrum of sporadic and familial forms of frontotemporal dementia**

6
7
8
9 *Running title*

10
11 **Clinical FTD**

12
13
14
15 *Authors*

16
17 Ione OC Woollacott MRCP¹, Jonathan D Rohrer MRCP PhD¹

18
19
20
21 *Affiliations*

22
23 ¹Dementia Research Centre, Department of Neurodegenerative Disease, UCL Institute of
24 Neurology, Queen Square, London, UK

25
26
27
28
29 *Corresponding author*

30
31 Dr Jonathan Rohrer, Dementia Research Centre, Department of Neurodegenerative
32 Disease, UCL Institute of Neurology, Queen Square, London, WC1N 3BG,
33 j.rohrer@ucl.ac.uk

34
35
36
37
38
39 *Keywords*

40
41 frontotemporal dementia, amyotrophic lateral sclerosis, progranulin, tau, C9orf72

42
43
44
45
46 Number of words: 14,194 (including tables and table legends)

47
48
49 *Acknowledgements and funding*

50
51 IOCW is funded by an MRC Clinical Research Training Fellowship. JDR is an MRC Clinician
52 Scientist and has also received funding from the NIHR Rare Diseases Translational
53 Research Collaboration

Abstract

The term frontotemporal dementia (FTD) describes a clinically, genetically and pathologically diverse group of neurodegenerative disorders. Symptoms of FTD can present in individuals in their twenties through to their nineties, but the mean age at onset is in the sixth decade. The most common presentation is with a change in personality and impaired social conduct (behavioural variant FTD). Less frequently patients present with language problems (primary progressive aphasia). Both of these groups of patients can develop motor features consistent with either motor neuron disease (usually the amyotrophic lateral sclerosis variant) or parkinsonism (most commonly a progressive supranuclear palsy or corticobasal syndrome). In about a third of cases FTD is familial, with mutations in the progranulin, microtubule-associated protein tau and chromosome 9 open reading frame 72 genes being the major causes. Mutations in a number of other genes including TANK-binding kinase 1 are rare causes of familial FTD. This review aims to clarify the often confusing terminology of FTD, and outline the various clinical features and diagnostic criteria of sporadic and familial FTD syndromes. It will also discuss the current major challenges in FTD research and clinical practice, and potential areas for future research.

Introduction

Frontotemporal dementia (FTD) is a clinically and pathologically diverse group of progressive neurodegenerative disorders leading to changes in behaviour, social conduct, language or speech, due to atrophy of the frontal or anterior temporal lobes of the brain (or both). Although it occurs less frequently than Alzheimer's disease (AD), FTD is a common cause of young onset dementia, often affecting individuals below the age of 65 years. However, it also affects older individuals, and may be under-diagnosed due to individuals being misdiagnosed with AD or other types of dementia (Onyike & Diehl-Schmid 2013). The majority of cases have no known cause ('sporadic' FTD), but approximately a third is familial, secondary to autosomal dominant mutations in one of several FTD-associated genes. There are two main clinical subtypes found in patients presenting with FTD: behavioural variant FTD (bvFTD), which primarily affects behaviour and social interaction, and primary progressive aphasia (PPA), which causes progressive impairment of speech and language. Both sporadic and familial FTD patients can also develop concurrent motor neuron disease (MND) (Devenney *et al.* 2015), or an atypical parkinsonian disorder such as corticobasal syndrome (CBS) or a progressive supranuclear palsy syndrome (PSPS) (Espay & Litvan 2011, Kertesz *et al.* 2011, Park & Chung 2013).

Despite a wealth of studies on FTD, much remains unknown about the disease, including the cause of the sporadic form. This is partly due to the heterogeneity of clinical presentation, age at disease onset and speed of progression. In addition there is a wide diversity of underlying neuropathology in patients with similar clinical presentations, and lack of clinicopathological correlation in the majority of patients. The overlap with other neurological syndromes makes the disease even more complex. In this review we aim to clarify the terminology of FTD, outline the various clinical features and diagnostic criteria of sporadic

1
2
3 and familial FTD syndromes and discuss the current major challenges in FTD research and
4 clinical practice. We also outline potential areas for future research.
5
6
7

8 9 **Terminology**

10 11 12 **Frontotemporal dementia and frontotemporal lobar degeneration**

13
14
15 The terminology of FTD can be confusing, and has evolved significantly since the first
16 description of a patient with progressive language disturbance and left superior temporal
17 gyrus atrophy by Arnold Pick in 1892 (Pick 1892). Histopathological presence of argyrophilic
18 globular neuronal cytoplasmic inclusions (later termed Pick bodies) was actually described
19 not by Pick but by Alois Alzheimer in 1911 (Alzheimer 1911) and the concept of FTD as
20 'Pick's disease' by a Dutch group in 1925 (Gans 1925) and by a German group in 1926
21 (Onari & Spatz 1926). By 1956 it had become evident that true Pick's pathology was
22 underlying only around 20% of clinical FTD cases (Escourolle 1958) and subsequent studies
23 confirmed that there were multiple other pathologies associated with atrophy of the frontal
24 and/or temporal lobes in patients with the clinical syndrome of FTD (Brun 1987, Mann *et al.*
25 1993). The historical term for bvFTD, Pick's disease, is now reserved for cases of FTD with
26 Pick type pathology. The term 'frontotemporal lobar degeneration' (FTLD) was therefore
27 designated to describe a heterogeneous group of neurodegenerative diseases characterized
28 by selective frontal and/or temporal lobe atrophy (Neary *et al.* 1998), and who have non-
29 Alzheimer's disease neuropathology (Lashley *et al.* 2015).
30
31
32
33
34
35
36
37
38
39
40
41
42
43
44
45

46 47 **Behavioral and language variants**

48
49 It is now well recognized that there are two main initial clinical presentations seen in patients
50 with FTD: bvFTD describes those who develop progressive behavioral change, inappropriate
51 social conduct and executive dysfunction, and PPA those who have progressive language
52 decline and speech difficulties. There are three variants of PPA: semantic variant PPA
53 (svPPA) leading to fluent speech with anomia, impaired single word comprehension and
54
55
56
57
58
59
60

1
2
3 surface dyslexia, due to loss of semantic memory, nonfluent (or agrammatic) variant PPA
4 (nfvPPA), leading to effortful speech production with agrammatism, apraxia of speech, and
5 impaired sentence comprehension, and logopenic variant PPA (lvPPA) leading to word-
6 finding pauses and impaired sentence repetition (Gorno-Tempini *et al.* 2011). LvPPA is
7 mostly associated with AD pathology and is therefore not always included within the FTD
8 spectrum, although in a minority of cases it can be associated with FTLN pathology (Lashley
9 *et al.* 2015).
10
11
12
13
14
15
16
17
18

19 FTD is now used as an umbrella term to describe the overall group of clinical syndromes,
20 although has previously been used to just mean the progressive behavioural syndrome now
21 called bvFTD (Neary *et al.* 2005). Other terms used previously for this include frontal lobe
22 dementia (Lund and Manchester Groups 1994) and frontal variant FTD. Evolution of PPA
23 terminology has been more tortuous. Despite Pick's original FTD case being a patient with
24 language difficulties (Pick 1892) and reports of a variant of FTD with predominant language
25 or speech decline published in the early 20th century, explicit description and widespread
26 acceptance of a language-led variant of FTD remained elusive until the 1970s. In 1975
27 Warrington characterized the presentation of patients with selective deficits in semantic
28 memory (Warrington 1975), leading to the later description of semantic dementia (Snowden
29 *et al.* 1989, Hodges *et al.* 1992). Mesulam also described a slowly progressive selective
30 aphasia (Mesulam 1982), later labelling this syndrome as PPA (Mesulam 1987). In an early
31 consensus document of diagnostic criteria for behavioral and language variants of FTD, PPA
32 was initially split into a fluent subtype (semantic dementia) and a non-fluent subtype
33 (progressive nonfluent aphasia, PNFA) (Neary *et al.* 1998). However, another subtype of
34 PPA was subsequently recognized, called logopenic aphasia (LPA) or the
35 logopenic/phonological variant of PPA (Gorno-Tempini *et al.* 2004, Gorno-Tempini *et al.*
36 2008), and this was subsumed into the most recent consensus diagnostic criteria for PPA
37 (Gorno-Tempini *et al.* 2011) which recognizes three variants: nfvPPA, svPPA and lvPPA.
38
39
40
41
42
43
44
45
46
47
48
49
50
51
52
53
54
55
56
57
58
59
60

1
2
3 identified a group of patients that do not fit criteria for any of the three described variants
4
5 (Sajjadi *et al.* 2012, Wicklund *et al.* 2014, Sajjadi *et al.* 2014).
6

7 **Overlap syndromes**

8
9 In patients with overlap syndromes of FTD with MND, PSPS or CBS, behavioural and
10 cognitive symptoms can develop before, after or simultaneously with motor symptoms
11 (Kertesz *et al.* 2011, Park & Chung 2013, Siuda *et al.* 2014, Devenney *et al.* 2015). In clinical
12 practice, there is often controversy or indecision about what diagnosis to give, or whether to
13 revise the diagnosis when new symptoms appear, to capture this development of a new
14 mixed phenotype. For example, a patient presenting with behavioral changes consistent with
15 bvFTD who later develops falls, supranuclear gaze palsy and axial rigidity, may have their
16 diagnosis changed to PSPS. Similarly, a patient with initial language dysfunction
17 characterized by effortful and agrammatic speech, who is first diagnosed with nfvPPA, but
18 later develops asymmetric limb apraxia, rigidity and myoclonus, may be later rediagnosed
19 with CBS. In our experience this changing of the diagnosis can be confusing for patients and
20 their families ('was the initial diagnosis wrong?'), and from a research point of view can lead
21 to loss of important phenotypic information (e.g. in pathological or genetic studies it may be
22 important to distinguish between PSPS cases who develop PPA and those who develop
23 bvFTD). We would advocate the use of overlap terms such as PPA-CBS or FTD-PSPS to
24 help clarify such confusion, as has been done with MND: patients with FTD who later
25 develop MND are usually diagnosed with FTD-MND (or FTD-ALS), and those with initial
26 MND and symptoms that later fit criteria for bvFTD or PPA are labelled as MND-FTD (or
27 ALS-FTD). However, overlap of these disorders can be variable and one unresolved
28 dilemma is how to classify patients that do not quite fulfill criteria for a particular disorder but
29 have mild features. Although around 10-15% of patients with FTD develop MND (Lomen-
30 Hoerth *et al.* 2002, Burrell *et al.* 2011) there is an even higher prevalence of 'subclinical'
31 evidence of MND, with electromyogram (EMG) evidence of MND or subtle MND-like clinical
32 signs, such as fasciculations, in 60% of FTD patients (Lomen-Hoerth *et al.* 2002).
33
34
35
36
37
38
39
40
41
42
43
44
45
46
47
48
49
50
51
52
53
54
55
56
57
58
59
60

1
2
3 Conversely, whilst 10-20% of MND patients meet diagnostic criteria for FTD, at least fifty
4 percent of patients presenting with MND develop cognitive or behavioural impairment,
5 termed MNDci (or ALSci) and MNDbi (or ALSbi) (Strong et al., 2009). Of the various MND
6 phenotypes seen in FTD patients, the majority usually develop the ALS variant, but lower
7 motor neuron (primary muscular atrophy) or upper motor neuron (primary lateral sclerosis)
8 phenotypes are also seen rarely (Devenney et al. 2015). As with MND, patients with FTD
9 may develop parkinsonian features (bradykinesia, rigidity, tremor and/or postural instability)
10 not fully consistent with a particular clinical syndrome such as PSPS or CBS, and are often
11 diagnosed with FTD with parkinsonism (FTDP). Parkinsonism is seen in around 20% of
12 patients, although a larger proportion may eventually develop this in end-stage disease
13 (Park & Chung 2013). One large study of 364 FTD cases (35 with pathological confirmation),
14 demonstrated the presence of parkinsonism as an early feature in 16% (18% of bvFTD, 14%
15 of nfvPPA and 11% of svPPA) (Seelaar et al. 2008). Very rarely, patients develop FTD, MND
16 and parkinsonism, including some patients with an underlying *C9ORF72* expansion mutation
17 (Coon et al. 2011, Boeve et al. 2012, Mahoney et al. 2012, Snowden et al. 2012, O'Dowd et
18 al. 2012).

37 Sporadic versus familial FTD

38
39 Currently, the only confirmed risk factors for FTD are mutations in certain genes. Between
40 30 and 50% of patients report a positive family history of FTD in at least one family member
41 and a clearly autosomal dominant inheritance pattern is seen in 10-15% of patients
42 (Goldman et al. 2005, Rohrer et al. 2009a). BvFTD is significantly more heritable than PPA,
43 with nfvPPA being much more likely to be familial than svPPA (Rohrer et al. 2009a). CBS
44 can be familial in some cases, and PSP is only very rarely familial. Estimates of heritability of
45 FTD-MND vary widely between studies and it remains unclear how many cases are genetic.
46
47
48
49
50
51
52
53
54
55
56
57
58
59
60

1
2
3 Mutations in three genes account for the majority of familial FTD, predominantly through
4 autosomal dominant inheritance: progranulin (*GRN*) (Baker *et al.* 2006, Cruts *et al.* 2006),
5
6 microtubule-associated protein tau (*MAPT*) (Wilhelmsen *et al.* 1994, Hutton *et al.* 1998) and
7
8 the chromosome 9 open reading frame 72 (*C9ORF72*) (DeJesus-Hernandez *et al.* 2011,
9
10 Renton *et al.* 2011). More recently, mutations in TRAF family member-associated NF-kappa-
11
12 B activator (TANK)-binding kinase 1 (*TBK1*) have been identified in association with familial
13
14 FTD (Freischmidt *et al.* 2015, Gijssels *et al.* 2015, Le Ber *et al.* 2015, Pottier *et al.* 2015).
15
16 Small numbers of patients possess mutations in other rare, FTD-associated genes.
17
18 Mutations in valosin containing protein (*VCP*)-1 are usually associated with a multisystem
19
20 proteinopathy manifesting as inclusion body myopathy and Paget's disease of the bone
21
22 (IBMPFD) (Watts *et al.* 2004), and mutations in charged multivesicular body protein 2B
23
24 (*CHMP2B*) (Skibinski *et al.* 2005) are found mainly in a Danish cohort. Rare genetic causes
25
26 of FTD include transactive response DNA binding protein-43 (*TARDBP*) (Synofzik *et al.*
27
28 2014), ubiquilin 2 (*UBQLN2*) (Gellera *et al.* 2013), p62/sequestome1 (*SQSTM1*) (Rubino *et al.*
29
30 2012, Le Ber *et al.* 2013, Miller *et al.* 2015), fused in sarcoma (*FUS*) (Kwiatkowski *et al.*
31
32 2009, Vance *et al.* 2009), dynactin-1 (*DCTN1*), associated with Perry syndrome (Munch *et al.*
33
34 2005) and coiled-coil-helix-coiled-coil-helix domain containing 10 (*CHCHD10*) (Bannwarth
35
36 *et al.* 2014). Mutations in presenilin 1 (*PSEN1*) or amyloid precursor protein (*APP*), both
37
38 associated with familial AD, and prion protein (*PRNP*), associated with familial prion disease,
39
40 have also been associated with a clinical FTD syndrome (Rohrer & Warren 2011). A small
41
42 proportion of patients (1.2% in one study of 334 patients) (van Blitterswijk *et al.* 2013) have
43
44 dual mutations, for example the *C9ORF72* expansion as well as another mutation in one of
45
46 the other FTD genes e.g. *GRN* (Lashley *et al.* 2014).
47
48
49
50
51

52 Clinical syndromes of FTD

53
54

55 In this section we summarize the clinical features of bvFTD and PPA variants, with reference
56
57 to most recent diagnostic consensus criteria (Rascovsky *et al.* 2011, Gorno-Tempini *et al.*
58
59
60

2011). Specific features of the various familial FTD phenotypes will be discussed in the later section entitled 'Clinical syndromes of familial FTD'.

Behavioural variant FTD

BvFTD presents with progressive decline in social skills, difficulties with planning and higher level thinking due to executive dysfunction, and distinct changes in behaviour, with relative preservation of other cognitive areas such as episodic memory and visuospatial function in the early stages. Patients with a PPA subtype or PSPS/CBS overlap disorder can also display similar behavioural features, as discussed below, but by definition they are not predominant at initial presentation. Patients with bvFTD often lack insight into their problems, and may seem indifferent or annoyed when brought to medical attention as they feel that there is nothing the matter with them. It is usually the patients' relatives or close friends who notice that something is wrong, usually due to a breakdown in their relationship with the patient or complaints from friends or work colleagues about odd behavior or increasingly poor performance at work. Relatives' reports of the patient having a 'poor memory' usually refer more to their perception of a change in the patient's level of personal and social functioning rather than true memory problems, and unfortunately can lead to a misdiagnosis of AD or repeated misdiagnoses such as 'stress', anxiety or depression by the non-specialist. Careful questioning in clinic, and particularly of the accompanying relative when they are alone, will reveal the true nature of cognitive changes and a history of progression of symptoms over time, both essential for aiding correct diagnosis.

Behavioural/cognitive symptoms – diagnosis of possible bvFTD requires at least 3 of the following symptoms to be fulfilled:	Examples of specific symptoms
Early behavioural disinhibition \geq 1 of:	
<ul style="list-style-type: none"> • Socially inappropriate behaviour 	Staring, inappropriate physical contact with strangers, inappropriate sexual behaviour, verbal or physical aggression

<ul style="list-style-type: none"> Loss of manners or decorum 	Lack of social etiquette, insensitive or rude comments, preference for crass jokes and slapstick humour, inappropriate choices of clothing or gifts
<ul style="list-style-type: none"> Impulsive, rash or careless actions 	New gambling behaviour, driving or investing recklessly, overspending, gullibility to phishing/internet scams
Early apathy or inertia ≥ 1 of:	
<ul style="list-style-type: none"> Apathy 	Reduced drive, stops previous hobbies, stops going out, reduced bathing or personal care
<ul style="list-style-type: none"> Inertia 	Lack of persistence or completion of an activity, does not initiate activities or conversations
Early loss of sympathy or empathy ≥ 1 of:	
<ul style="list-style-type: none"> Diminished response to other people's needs and feelings 	Selfish or hurtful comments or actions, inability to perceive when someone is upset, embarrassed, or in pain, reduced appreciation of sarcasm or sophisticated humor
<ul style="list-style-type: none"> Diminished social interest, interrelatedness, or personal warmth 	Emotionally cold or detached, lack of rapport in conversation, loss of interest or affection in relationships with friends or family members, reduced interest in sex
Early perseverative, stereotyped or compulsive or ritualistic behavior ≥ 1 of:	
<ul style="list-style-type: none"> Simple repetitive movements 	Repetitive rocking, tapping, clapping, or rubbing
<ul style="list-style-type: none"> Complex compulsive or ritualistic behaviours 	Hoarding, strict grooming or walking routines, timekeeping and counting, checking or sorting items, cleaning or tidying, new obsessions or interests (usually spiritual, religious, artistic, or musical)
<ul style="list-style-type: none"> Stereotypy of speech 	Habitual repetition of particular words, sentences or topics
Hyperorality and dietary changes ≥ 1 of:	
<ul style="list-style-type: none"> Altered food preferences 	Sweet tooth (sweets, biscuits, ice cream), carbohydrates, or obsessive food fads

<ul style="list-style-type: none"> Binge eating, increased consumption of alcohol or cigarettes 	Cramming food into mouth, overeating or messy eating, new addictions to alcohol or smoking
<ul style="list-style-type: none"> Oral exploration or consumption of inedible objects 	Pica
Neuropsychological profile – all 3 of:	
<ul style="list-style-type: none"> Deficits in executive tasks 	Vary as per neuropsychological assessment used
<ul style="list-style-type: none"> Relative sparing of episodic memory 	
<ul style="list-style-type: none"> Relative sparing of visuospatial skills 	
Other features of bvFTD (not in diagnostic criteria)	Examples of specific symptoms
<ul style="list-style-type: none"> Loss of insight 	Lack of awareness of own condition or symptoms
<ul style="list-style-type: none"> Impaired social cognition 	Poor response to social or emotional cues; impaired performance on tests of theory of mind or emotion recognition
<ul style="list-style-type: none"> Altered sensitivity to pain 	Heightened perception of a non-painful stimulus or reduced response to painful stimulus; hypochondriasis or overly focusing on mild physical complaints
<ul style="list-style-type: none"> Altered tolerance of temperature 	Inappropriate clothing for the ambient temperature, such as wearing multiple coats or blankets
<ul style="list-style-type: none"> Psychotic features 	Delusions (usually somatic or paranoid) and hallucinations (usually visual or tactile)

Table 1. Summary of behavioural and cognitive symptoms within the current diagnostic criteria for behavioral variant frontotemporal dementia (bvFTD), and other commonly seen features. Table content is adapted from Rascovsky et al. (2011) and Warren *et al.* (2013). To qualify for a diagnosis of possible bvFTD, patients need to have a progressive deterioration of behaviour and/or cognition as per observation or history from an informant, and must possess persistent evidence of least 3 of the 6 main groups of behavioural/cognitive symptoms listed in the pale grey boxes above. The term 'early' refers to within 3 years of initial symptom onset as per Rascovsky et al. (2011).

The most recent diagnostic criteria for bvFTD (Rascovsky et al. 2011) were developed by the FTDC (Frontotemporal Dementia Consortium) to summarize more succinctly the key features of behavioral change seen in this subtype, while recognizing that other cognitive features such as episodic memory can be affected, albeit less commonly. Criteria for a

1
2
3 diagnosis of possible bvFTD are displayed in **Table 1**; patients must attain any three of six
4 key clinical features: five behavioural (disinhibition, apathy or inertia, loss of sympathy or
5 empathy, stereotyped or compulsive behaviors, or hyperorality) and one cognitive
6 (predominant executive dysfunction on neuropsychological assessment). The sensitivity and
7 specificity of these diagnostic criteria for correct diagnosis of bvFTD have been reviewed in a
8 number of studies with confirmation of FTLN or non-FTLN pathology, which have
9 established that the criteria have 85-95% sensitivity and 82% specificity for a diagnosis of
10 possible bvFTD and 75-85% sensitivity and 95% specificity for probable bvFTD (Rascovsky
11 et al. 2011, Harris *et al.* 2013b).

22
23 There are a number of clinical features, however, which are not part of the Rascovsky
24 criteria and yet are relatively common in bvFTD. In particular, virtually all patients with
25 bvFTD have impaired social cognition, with reduced ability to use a 'theory of mind' to see
26 another person's point of view or imagine their feelings (Kumfor & Piguet 2012). Several
27 studies have shown that patients with bvFTD also display significant impairments in emotion
28 recognition, even when tested across multiple modalities, and have more difficulty
29 recognizing negative emotions (Lavenu *et al.* 1999, Rosen *et al.* 2004, Fernandez-Duque &
30 Black 2005, Lough *et al.* 2006). They also have difficulty in expressing meaningful emotions,
31 resulting in 'emotional blunting' (Neary et al. 1998, Sturm *et al.* 2011).

43
44 Several groups have observed altered perception of surrounding environmental and internal
45 somatosensory stimuli, including changes in tolerance of pain or temperature. Patients with
46 bvFTD tend to have blunted perception of pain (Bathgate *et al.* 2001, Snowden *et al.* 2001,
47 Carlino *et al.* 2010, Fletcher *et al.* 2015) and temperature (Ahmed *et al.* 2015, Fletcher et al.
48 2015). In bvFTD patients this can anecdotally manifest as wearing inappropriately heavy
49 clothing or blankets in a warm clinic. Others have developed altered perception of sound or
50 music (Seeley *et al.* 2008, Warren & Rohrer 2009, Barquero *et al.* 2010, Mahoney *et al.*
51 2011, Fletcher *et al.* 2013), with some patients merely developing heightened sensitivity to
52
53
54
55
56
57
58
59
60

1
2
3 noise (Fletcher et al. 2013) and others frank musicophilia (Fletcher et al. 2013) or amusia
4 (Barquero et al. 2010). These phenomena suggest that a variety of networks involved in
5 sensory input processing and integration may be affected in FTD.
6
7
8
9

10
11 Neuropsychiatric manifestations such as delusions or hallucinations are found in sporadic
12 bvFTD and may be the sole presentation in patients with familial bvFTD (particularly those
13 with *C9ORF72* or *GRN* mutations, as discussed later). In a review of 751 cases of FTD
14 published in 199 publications from 1950-2007, 46 (6%) of patients presented with
15 schizophrenia, schizoaffective disorder, bipolar affective disorder, psychotic depression or
16 another psychotic disorder; with 98% of these patients presenting aged less than 60
17 (Velakoulis *et al.* 2009). In another large study of patients with a variety of
18 neurodegenerative disorders, including bvFTD, nfvPPA, svPPA, AD, PSPS, CBS and ALS,
19 28.5% of patients had received a previous psychiatric diagnosis (usually depression), and
20 this was much more common in patients who turned out to have bvFTD (50.7%) than
21 nfvPPA (11.8%), svPPA (24.4%) or AD (23.1%) (Woolley *et al.* 2011). The typical previous
22 psychiatric diagnosis in bvFTD patients in this study was schizophrenia or bipolar disorder.
23
24 Young onset apparently sporadic bvFTD cases with FUS pathology have a particularly high
25 (up to 50%) rate of psychiatric symptoms. The lack of other cognitive or neurological
26 features early on commonly leads to young and older patients with sporadic and familial
27 bvFTD being referred to and assessed within a psychiatric or psychogeriatric setting rather
28 than in a specialist cognitive neurology or memory clinic (Lanata & Miller 2015). The obvious
29 overlap between early bvFTD symptoms (lack of insight, prominent apathy, obsessive or
30 compulsive behaviours, inappropriate sexual behaviour, binge-eating, gambling and
31 substance misuse, emotional lability or blunting, delusions and hallucinations) and
32 psychiatric presentations (depression, obsessive compulsive disorder, bipolar affective
33 disorder, and schizophrenia and other psychotic disorders) can initially lead to misdiagnosis
34 of a neurodegenerative disease as a psychiatric disorder. Younger patients with 'later than
35 usual' onset of neuropsychiatric disease, atypical or prominent behavioural features and any
36
37
38
39
40
41
42
43
44
45
46
47
48
49
50
51
52
53
54
55
56
57
58
59
60

1
2
3 suggestion of multiple family members with significant psychiatric disease (for example
4 needing long-term or permanent admission to a mental health facility), 'early onset
5 dementia', AD, FTD or MND, should be carefully assessed with a neurological examination,
6
7 detailed family history and, wherever possible, formal neuropsychology and detailed MRI
8
9 imaging.
10
11

12
13
14
15 Patients with bvFTD classically have preserved episodic memory, at least early on in
16 disease, helping differentiation from AD, but this is not always the case. Patients often have
17 deficits in verbal and visual memory on neuropsychological assessment, even if they do not
18 report memory problems; their performance is often worsened by poor strategy during
19 assessments due to concurrent executive dysfunction and distractibility. However, a
20 significant proportion of pathologically confirmed bvFTD cases have presented with a
21 predominant amnesic syndrome (Hodges *et al.* 2004, Graham *et al.* 2005, Piguet *et al.*
22 2009, Irish *et al.* 2013), perhaps due to a higher occurrence of hippocampal sclerosis in the
23 older age group (Baborie *et al.* 2011, Balasa *et al.* 2015) or mixed pathology (Balasa *et al.*
24 2015). This emphasizes the difficulties clinicians face in making a correct diagnosis,
25 particularly in later onset cases, despite using currently available consensus criteria.
26
27
28
29
30
31
32
33
34
35
36
37

38
39 The requirements for functional decline and neuroimaging abnormalities for diagnosing
40 probable bvFTD, compared with previous diagnostic criteria (Neary *et al.* 1998), are
41 particularly useful for excluding patients with a so-called phenocopy syndrome, who may
42 have bvFTD-like symptoms but do not have bvFTD. Relatives of patients with phenocopies
43 often seem certain that there is progression over time, but most neuropsychological
44 assessments tend to dispute this, often showing normal values or mild but stable impairment
45 (Hornberger *et al.* 2009). These patients have no or minimal atrophy on MRI and normal
46 nuclear medicine imaging with PET or SPECT scans, and either remain stable or improve
47 over time, without significant disruption of function (Davies *et al.* 2006). Previous diagnostic
48 criteria for bvFTD (Neary *et al.* 1998) potentially allowed phenocopy cases to be falsely
49
50
51
52
53
54
55
56
57
58
59
60

1
2
3 diagnosed as having bvFTD, as they presented almost identically on core diagnostic criteria
4 (Hornberger et al. 2009), and these cases are notoriously difficult to tell apart, particularly at
5 initial assessment. Repeated assessments of functional abilities over a 12 month period
6 (Mioshi & Hodges 2009), neuropsychological assessments of executive function (Hornberger
7 et al. 2008) and social cognition (Kipps et al. 2009b), and neuroimaging using combined MRI
8 and FDG-PET (Kipps et al. 2009a) appeared most helpful in differentiating phenocopy
9 syndromes from true bvFTD, hence their incorporation into the revised criteria (Rascovsky et
10 al. 2011). One proviso to this is that some patients can occasionally actually have an
11 atypical, very slowly progressive form of FTD, with very slow deterioration on repeated
12 neuropsychological assessments over at least 15 years, and neuropathological confirmation
13 of typical FTLD pathology (Brodtmann et al. 2013), which further confuses the clinical
14 picture.
15
16
17
18
19
20
21
22
23
24
25
26
27
28
29
30

31 **Primary progressive aphasia**

32 The key clinical characteristic of PPA is progressive and insidious language decline affecting
33 at least one of speech production, object naming, syntax, or word comprehension (Gorno-
34 Tempini et al. 2011). Other cognitive or behavioural deficits can develop either early on or in
35 late disease but must not be the initial and predominant complaint and language must also
36 remain the most impaired domain throughout the disease course (Mesulam 1982, Mesulam
37 2003). The most recent diagnostic criteria for PPA have specified that three inclusion criteria,
38 based on criteria developed by Mesulam (Mesulam 1982, Mesulam 2001, Mesulam 2003),
39 must first be fulfilled for its diagnosis (Gorno-Tempini et al. 2011): 1) the most prominent
40 clinical feature is difficulty with language; 2) these deficits are the principal cause of impaired
41 daily living activities, and 3) aphasia should be the most prominent deficit at symptom onset
42 and for the initial phases of the disease. In addition, none of the following criteria should be
43 met: 1) the pattern of deficits is better accounted for by other non-degenerative nervous
44 system or medical disorders (e.g. tumour or stroke); 2) the cognitive disturbance is better
45
46
47
48
49
50
51
52
53
54
55
56
57
58
59
60

1
2
3 accounted for by a psychiatric diagnosis; 3) there are prominent initial episodic memory,
4 visual memory, and visuoperceptual impairments, and 4) there is prominent, initial
5 behavioural disturbance. Once these inclusion and exclusion criteria have been satisfied,
6 one can go on to sub-diagnose the syndrome as one of three PPA variants (svPPA, nfvPPA
7 or lvPPA), as per diagnostic criteria for each variant [see (Gorno-Tempini et al. 2011) for a
8 summary]. Clinical diagnosis can be supplemented by information from neuroimaging
9 analyses (leading to the more firm category, 'imaging-supported diagnosis'). If there is a
10 clinical diagnosis of PPA (with or without neuroimaging support) and presence of either a
11 known pathogenic gene mutation on DNA analysis or specific neurodegenerative pathology
12 on histopathological analysis, this leads to a diagnosis of PPA 'with definite pathology'.
13
14
15
16
17
18
19
20
21
22
23

24
25 Different language features can be used to differentiate between the three variants and
26 these are summarized these in **Table 2**. However, not all patients clearly fit into a particular
27 variant as they present with a number of features from across the spectrum of language
28 dysfunction, and previously have been termed as having mixed disease (PPA-M) (Mesulam
29 *et al.* 2009). More recently patients have been diagnosed with 'PPA-unclassifiable' (PPA-U)
30 and over time the evolving syndrome may or may not become clearer (Harris *et al.* 2013b),
31 although some are associated with a *GRN* mutation (Rohrer *et al.* 2010a). There is also a
32 syndrome within the nonfluent aphasia spectrum called progressive primary apraxia of
33 speech (PPAOS), which progressively affects speech articulation and production due to
34 impaired motor programming, but typically patients lack aphasia initially (Josephs *et al.*
35 2012). It can be associated with development of features of PSPS (Rohrer *et al.* 2010b,
36 Josephs *et al.* 2014) or, less frequently, CBS (Josephs & Duffy 2008, Assal *et al.* 2012).
37 Here we discuss the clinical features of each PPA variant in turn, the language and
38 behavioural features that overlap between them and with bvFTD, the presence of other
39 common clinical features, and the overlap with other conditions such as PSPS, CBS and
40 MND.
41
42
43
44
45
46
47
48
49
50
51
52
53
54
55
56
57
58
59
60

Clinical features	svPPA	nfvPPA	lvPPA
Spontaneous speech (fluency; errors; grammar; prosody)	Fluent, garrulous and circumlocutory; semantic errors; intact grammar and prosody	Slow and hesitant, effortful +/- apraxic; phonetic errors; may be agrammatic; aprosodic	Hesitant; not effortful or apraxic; frequent word-finding pauses and loss of train of sentence; intact grammar; intact prosody
Naming	Severe anomia with semantic paraphasias	Moderate anomia with phonetic errors and phonemic paraphasias	Mild to moderate anomia with occasional phonemic paraphasias
Single word comprehension	Poor	Intact early on, but affected later on	Intact early on, but affected later on
Sentence comprehension	Initially preserved, later on becomes impaired as word comprehension is impaired	Impaired if grammatically complex	Impaired, especially if long
Single word repetition	Relatively intact	Mild to moderately impaired if polysyllabic, otherwise intact	Relatively intact (compared with sentence repetition)
Sentence repetition	Relatively intact	Can be effortful; impaired if grammatically complex	Impaired, with length effect
Reading	Surface dyslexia	Phonological dyslexia +/- phonetic errors on reading aloud	Phonological dyslexia
Writing	Surface dysgraphia	Phonological dysgraphia	Phonological dysgraphia

Table 2 Summary of clinical features across the syndromes of primary progressive aphasia. svPPA = semantic variant primary progressive aphasia; nfvPPA = nonfluent variant primary progressive aphasia; lvPPA = logopenic variant primary progressive aphasia. Clinical features are adapted from tables in: Rohrer *et al.* (2008), Rohrer *et al.* (2010a), Seelaar *et al.* (2011), Gorno-Tempini *et al.* (2011).

SvPPA

SvPPA accounts for around 20% of cases of FTD (Johnson *et al.* 2005). It is a predominantly sporadic disorder (Rohrer *et al.* 2009a) and presents with a mean age of onset of 60, with a range of 40-79 years (Hodges *et al.* 2010), although is likely under-diagnosed in older people, particularly as the semantic memory deficits can develop insidiously and are usually well-masked by the perception of fluent speech, and use of

1
2
3 commonly-used empty speech terms such as 'thing' (Fletcher & Warren 2011, Hsieh *et al.*
4 2012). It is associated with bilateral but markedly asymmetrical anterior temporal lobe
5 atrophy at presentation, particularly affecting the inferior and middle temporal gyri, but also
6 the anterior hippocampus and amygdala (Hodges *et al.* 1992, Mummery *et al.* 1999,
7 Mummery *et al.* 2000, Whitwell *et al.* 2005, Rohrer *et al.* 2009b). The majority of patients
8 present with predominant left temporal lobe atrophy, which leads to the classical language
9 disorder of svPPA, characterized by early loss of semantic memory and resultant language
10 dysfunction (Snowden *et al.* 1989, Hodges *et al.* 1992). Less frequently patients present
11 with predominant right temporal lobe atrophy at onset, often called right temporal lobe
12 atrophy (RTLA) FTD or 'right SD' cases (Evans *et al.* 1995, Thompson *et al.* 2003, Chan *et*
13 *al.* 2009). The language impairment in svPPA initially manifests as reduced semantic
14 knowledge for words, objects and concepts, which affects spoken and written language
15 through development of a reduced vocabulary and resultant anomia (Warrington 1975). As
16 atrophy worsens and extends across to the right temporal lobe and to the inferior frontal
17 lobe, insula, and more posterior left temporal lobe (Seeley *et al.* 2005, Brambati *et al.* 2009),
18 it impairs semantic function across multiple modalities, leading to associative agnosia for
19 visual, auditory, (Bozeat *et al.* 2000, Goll *et al.* 2010), tactile (Coccia *et al.* 2004), olfactory
20 (Rami *et al.* 2007) and gustatory (Piwnica-Worms *et al.* 2010) stimuli. Patients lose their
21 grasp for increasingly imprecise or broad semantic terms and concepts, with responses to
22 stimuli becoming more general (e.g. 'poodle'→'dog'→ 'animal'→ 'don't know') over time.
23
24
25
26
27
28
29
30
31
32
33
34
35
36
37
38
39
40
41
42
43
44

45 Patients with svPPA generally report word-finding difficulties, which may start off as being
46 only for specialist, low frequency (rarely used) words (such as names of flowers for a
47 gardener, or facial anatomical terms for a dentist). This worsens to affect commonly used
48 words. Patients may ask relatives to explain the meaning of a word someone has said or
49 that they have read (Fletcher & Warren 2011, Warren *et al.* 2013), which at first is usually an
50 unusual word, such as 'orangutan'. Relatives may report the patient does not seem to
51 understand what is being said to them, or 'appears deaf', asking for instructions to be
52
53
54
55
56
57
58
59
60

1
2
3 repeated several times (Rohrer et al. 2008). Clinically, the language dysfunction in svPPA is
4 characterized by fluent speech, which is often garrulous or difficult to interrupt but has
5 frequent circumlocutions (e.g. 'thing' or 'whatsit'), circumlocutory phrases (imprecise phrases
6 that contain vague descriptions or explanations of the word aimed for, e.g. 'the thing with the
7 tail that you ride' for 'horse') and semantic paraphasias (similar but incorrect words often
8 from within the same category, .e.g. 'cat' for 'dog'), used by the patient to work around their
9 lack of vocabulary (Hodges & Patterson 2007). There can be brief hesitations during word-
10 finding moments, but overall the speech is much more fluent than the effortful speech in
11 nfvPPA or speech with significant pauses in lvPPA. On assessment, patients have anomia
12 on confrontation naming tasks (which may appear subtle without detailed probing by a full
13 neuropsychological assessment), and impaired comprehension of the meaning of single
14 words, particularly on low-frequency items such as 'monocle'. Later on, there is anomia and
15 impaired comprehension of pictures, sounds, smells and tastes. Patients often have
16 difficulties with reading and writing, particularly with irregularly spelt words, leading to the
17 phenomenon of a surface dyslexia or surface dysgraphia (Warrington 1975, Baxter &
18 Warrington 1987). For example, patients will pronounce 'sew' as 'soo' or 'yacht' as 'yatched',
19 as they have lost semantic knowledge of the word meaning (and hence the atypical rule for
20 how it should be pronounced), relying on sounding out the word as written using superficial
21 rules only (Rohrer et al. 2008). Other cognitive domains are usually unaffected, including
22 episodic and topographical memory, visuoperceptual function, praxis, calculation, and non-
23 verbal executive function (Warrington 1975, Gordon *et al.* 2010, Cipolotti & Maguire 2003).
24 Other aspects of language such as speech articulation and prosody, and repetition of
25 spoken words and phrases are also usually preserved. Grammar is intact, although as
26 vocabulary declines, grammar can sound abnormal, due to use of 'paragrammatic',
27 circumlocutory phrases and broad classes of terms, which disrupt the normal flow of the
28 sentence (Gorno-Tempini et al. 2011).
29
30
31
32
33
34
35
36
37
38
39
40
41
42
43
44
45
46
47
48
49
50
51
52
53
54
55
56
57
58
59
60

1
2
3 Patients with typical svPPA evolve over time (due to spread of disease) to develop
4 behavioural changes, which can make it difficult to differentiate these patients from bvFTD
5 patients clinically if presenting late in the disease. However, behavioural changes particularly
6 found in typical svPPA include obsessionality, mental rigidity, narrowed interests (often
7 affecting eating behavior, daily routines and fixations on specific activities e.g. jigsaw
8 puzzles) (Snowden et al. 2001, Thompson et al. 2003), more compulsive and complex
9 repetitive behaviors (Snowden et al. 2001), heightened perception of pain and sensory
10 stimuli leading to hypochondriasis, and increased sensitivity to temperature (Fletcher et al.
11 2015). Cases of svPPA with altered auditory perception such as hyperacusis and persistent
12 tinnitus (of central rather than peripheral origin) have also been observed (Mahoney et al.
13 2011).

14
15
16
17
18
19
20
21
22
23
24
25
26
27 Patients with the right temporal variant can be difficult to identify purely from a clinical
28 assessment as they often have early behavioural changes and less prominent semantic
29 difficulties initially (Chan et al. 2009). The key distinguishing feature of RTLA cases is early
30 prosopagnosia (impaired recognition of familiar faces) (Tyrrell *et al.* 1990, Evans et al. 1995,
31 Gainotti *et al.* 2003, Thompson et al. 2003, Joubert *et al.* 2006), but when compared with
32 cases with predominant left temporal lobe atrophy, RTLA cases also report more difficulties
33 with topographical memory (potentially due to right hippocampal atrophy) (Chan et al. 2009),
34 and may have a more bizarre affect (Thompson et al. 2003). They also tend to have less
35 insight into their disease (Thompson et al. 2003) and can develop other unusual features
36 such as hyper-religiosity (Edwards-Lee *et al.* 1997, Chan et al. 2009). Not all RTLA patients
37 will develop semantic impairment and initial studies have suggested that there are at least
38 two RTLA variants: one that is the mirror analogue of svPPA with disease spread occurring
39 interhemispherically to the left temporal lobe, and another with behavioural symptoms where
40 atrophy spreads intrahemispherically, predominantly affecting the right frontal and parietal
41 lobe (Kamminga *et al.* 2015). These tend to have differing underlying pathologies as well:
42 the right SD cases have FTLD-TDP Type C pathology, whereas patients with bvFTD rarely
43
44
45
46
47
48
49
50
51
52
53
54
55
56
57
58
59
60

1
2
3 have this subtype (Rohrer *et al.* 2011a, Lashley *et al.* 2015) potentially affecting accurate
4 targeting of future treatments towards the different disease groups.
5
6

7 8 **NfvPPA**

9
10 Approximately 25% of patients with FTD present with nfvPPA (Johnson *et al.* 2005). The
11 classical neuroimaging feature is atrophy of the left posterior (and inferior) frontal lobe and
12 insular cortex (Rohrer *et al.* 2009b). In contrast to the fluent aphasia observed in svPPA,
13 patients with nfvPPA have non-fluent speech, with the two core features being agrammatism
14 and slow labored speech production ('effortful speech') (Gorno-Tempini *et al.* 2011). In some
15 patients the former impediment is dominant, and in others, the latter, but in most cases the
16 disease evolves to result in both features (Rohrer *et al.* 2010c). Patients with nfvPPA tend to
17 present earlier than patients with svPPA, as speech is obviously disrupted and sounds
18 abnormal early on (Hsieh *et al.* 2012). Importantly, single word comprehension and object
19 knowledge are preserved, as semantic memory is intact, and this particularly helps to
20 differentiate from the semantic variant in early disease (Gorno-Tempini *et al.* 2011). Patients
21 report word-finding difficulties and do display anomia, but the anomia is less severe than
22 svPPA cases. Speech agrammatism manifests as use of short, simple phrases which can
23 sound muddled and 'telegraphic', due to omission of short connecting words and other
24 function words, use of words in the wrong order, and misuse of word endings, verb tenses,
25 pronouns, prepositions and conjunctions (Mesulam 2003, Rohrer *et al.* 2008). There is also
26 difficulty in comprehending grammar, leading to impaired sentence comprehension,
27 particularly if sentences are long and syntactically complex (Grossman & Moore 2005).
28 Patients can develop binary word reversals (typically yes/no, or pronouns e.g. he/she)
29 saying the opposite word to what they intended (Frattali *et al.* 2003) or utter sudden,
30 unintended, stereotyped responses such as 'don't know' to different questions before giving
31 the correct answer (Snowden & Neary 1993).
32
33
34
35
36
37
38
39
40
41
42
43
44
45
46
47
48
49
50
51
52
53
54
55
56
57
58
59
60

1
2
3 Speech apraxia impairs the patient's ability to program and plan the motor aspects of speech
4 production properly, leading to effortful trial and error 'groping' of orofacial movements in the
5 effort to produce the correct sounds (Duffy 2006, Josephs *et al.* 2006). Some patients
6
7 perseverate on consonants or syllables, leading to a new 'stuttering' quality to speech as the
8
9 initial presenting symptom (Kertesz *et al.* 2003). The variability of an apraxia of speech can
10
11 lead to a misdiagnosis of a 'functional stutter' or functional speech disorder i.e. of a non-
12
13 organic basis by non-specialists, particularly as symptoms can fluctuate and become worse
14
15 with anxiety or effort. The prosody of speech is also disrupted, thereby affecting its natural
16
17 rhythm, rate (commonly leading to slowing), volume, or intonation (Josephs *et al.* 2006).
18
19 There are typically distorted speech sounds (phonetic errors) due to errors in execution of
20
21 programmed speech sounds, typified by syllable or consonant deletions, insertions,
22
23 substitutions, distortions, repetitions and prolongations such as 'capititain' rather than
24
25 'captain' (Duffy 2006, Gorno-Tempini *et al.* 2011), which can all make speech sound
26
27 'jumbled up' to the patient and their relatives. Writing can be intact, or show grammatical
28
29 errors later on in disease.
30
31
32
33
34

35
36 As well as these core speech production features, the agrammatism affects language in a
37
38 broader sense. Repetition of single words is relatively preserved (except for more complex
39
40 multi-syllabic words which becomes effortful), but repetition of longer sentences that are
41
42 grammatically complex is affected. Over time speech deteriorates to a point where the
43
44 patient has extreme difficulty making themselves understood and eventually mutism ensues,
45
46 although this can be an early feature in some cases (Gorno-Tempini *et al.* 2006). Many
47
48 patients switch to non-oral methods of communication such as writing on a notepad, or
49
50 electronic language applications on handheld tablet computers. Orofacial/buccofacial
51
52 apraxia, is also seen, which impairs the patient's ability to plan oral movements, leading to
53
54 difficulty initiating swallowing, coughing, and yawning (Tyrrell *et al.* 1991). On bedside
55
56 testing, patients are unable to perform these actions to command, usually responding by
57
58 repeating the word 'cough' or 'yawn' rather than the action itself (Tyrrell *et al.* 1991). Many
59
60

1
2
3 patients display limb apraxia, particularly affecting the right side. Although subtle initially, this
4
5 often worsens, progressively impairing hand function (Mesulam 2003).
6
7

8 **LvPPA**

9
10 Around 30% of patients with PPA have the more recently described syndrome lvPPA
11
12 (Kertesz et al. 2003, Gorno-Tempini et al. 2004, Rosen *et al.* 2006, Gorno-Tempini et al.
13
14 2008). The hallmark imaging feature is left posterior temporoparietal atrophy encompassing
15
16 the posterior superior temporal lobe, inferior parietal lobe, precuneus and mesial temporal
17
18 lobe (Gorno-Tempini et al. 2004, Rohrer *et al.* 2013a). The syndrome is thought by some to
19
20 be an atypical and uni-hemispheric presentation of AD (Ahmed *et al.* 2012, Rohrer *et al.*
21
22 2012), although associated pathology is not universally 'AD-like' (Harris *et al.* 2013a,
23
24 Mesulam *et al.* 2014) and it is difficult to predict based on clinical features which patients
25
26 have underlying AD versus other pathology (Chare *et al.* 2014). The key clinical features of
27
28 lvPPA are frequent word-finding pauses, anomia and impaired sentence (rather than single
29
30 word) repetition (Gorno-Tempini et al. 2004, Gorno-Tempini et al. 2008). There is also
31
32 preserved single word comprehension and object knowledge as semantic memory is intact,
33
34 but impaired comprehension of longer sentences, without agrammatism or apraxia of speech
35
36 (Gorno-Tempini et al. 2008, Rohrer et al. 2012). On speech assessment, there are frequent
37
38 pauses (as the patient tries to retrieve the right word rather than apraxia of speech), and
39
40 phonological errors (which are well articulated and not distorted, but definitely incorrect, such
41
42 as 'coptain' rather than 'captain') due to difficulty with the phonology of the anticipated word.
43
44 These phonological errors also appear in writing, and there may be a phonological dyslexia,
45
46 affecting reading of new or nonsense words. The short-term, phonological memory deficit in
47
48 lvPPA also characteristically impairs sentence repetition in a length-dependent manner, but
49
50 spares single word repetition (Gorno-Tempini et al. 2008). Although comprehension of single
51
52 words is intact, there can be difficulty in comprehending longer sentences, due to the deficit
53
54 in phonological memory, but this is not affected by grammatical complexity like in nvPPA.
55
56 Patients with severe lvPPA can be difficult to differentiate from patients with nonfluent PPA.
57
58
59
60

1
2
3 However, the key differentiating features for lvPPA are lack of agrammatism, lack of apraxia
4 speech, lack of orofacial apraxia, preserved prosody and impaired sentence repetition
5 (Gorno-Tempini et al. 2008, Chare et al. 2014). Limb apraxia is often present due to parietal
6 involvement (Rohrer et al. 2012).
7
8
9

10 11 12 13 **Parkinsonism and motor features in PPA**

14
15
16 Subtle signs of parkinsonism are observed in a large proportion of patients with PPA, mostly
17 in patients with nfvPPA. Typically this is on the right hand side (i.e. contralateral to
18 predominant left hemispheric involvement) and leads to mild cogwheeling, bradykinesia or
19 rigidity on examination when the other hand is engaged in repetitive and simultaneous
20 tapping, or subtle dystonia or asymmetrical posturing of the hand when distracted (Mesulam
21 2013). As disease progresses, parkinsonism can worsen and lead to a frank parkinsonian
22 syndrome, most commonly with features of CBS (Graham *et al.* 2003, Josephs et al. 2006,
23 Josephs & Duffy 2008) and less commonly PSPS (Josephs *et al.* 2005, Josephs et al. 2006).
24 Overlap of svPPA with PSPS or CBS is rare, and if present is usually associated with
25 atypical FTLD-tau pathology (Clerc *et al.* 2013), although parkinsonism can appear late on in
26 disease (Hodges & Patterson 2007, Kremen *et al.* 2011). Patients with lvPPA typically do not
27 develop florid parkinsonism (unless there is underlying CBD pathology).
28
29
30
31
32
33
34
35
36
37
38
39
40
41
42

43 Similar to the bvFTD/MND spectrum, there are also patients with PPA that develop MND or
44 clinical features suggestive of MND but not fully meeting criteria e.g. mild wasting or
45 fasciculations were seen in a small proportion of patients with nfvPPA in one study (Burrell et
46 al. 2011). Although most cases of PPA-MND have nfvPPA there is a subgroup of patients
47 with RTLA who can rarely develop MND, typically associated with FTLD-TDP type B
48 pathology and predominant lower motor neuron features (Coon *et al.* 2012), or prominent
49 upper motor neuron signs and pathological evidence of corticospinal tract degeneration and
50 FTLD-TDP type C pathology (Josephs *et al.* 2013). MND in typical svPPA and lvPPA is rare.
51
52
53
54
55
56
57
58
59
60

1
2
3 Some MND patients develop language impairment not fully meeting criteria for PPA.
4
5 Detection of aphasia in the presence of dysarthria can be difficult however, so it may be
6
7 under-reported; one recent study suggested language dysfunction in 43% of MND patients
8
9 (Taylor *et al.* 2012). This needs further study, as these language difficulties will affect use of
10
11 alternative communication methods such as electronic writing boards, in patients who have
12
13 lost motor speech due to bulbar involvement.
14
15

16 17 **Clinical syndromes of familial FTD** 18

19
20
21 Familial FTD is observed in around a third of all FTD cases, and more commonly presents
22
23 as bvFTD than other FTD subtypes. Mutations in *MAPT*, *GRN* and *C9ORF72* are the most
24
25 commonly identified causes of familial FTD, and in this section we summarize the clinical
26
27 syndromes observed in these cases. We also describe the phenotype of patients with
28
29 pathogenic mutations in rarer genes (*VCP*, *CHMP2B*, *TREM2*, *TARDBP*, *FUS*, *UBQLN2*,
30
31 and *SQSTM1*) and provide an overview of clinical syndromes recently discovered to be
32
33 associated with mutations in the gene TRAF family member-associated NF-kappa-B
34
35 activator (TANK)-binding kinase 1 (*TBK1*). A summary of the various features of the clinical
36
37 syndromes associated with these genes is presented in Table 3.
38

39 40 ***MAPT*** 41

42
43 To date there have been 55 pathogenic mutations identified in *MAPT*. Mean age at onset is
44
45 in the mid-fifties (Snowden *et al.* 2015), with a peak age at onset between 45 and 65 years.
46
47 On average, patients present younger than those with *GRN* or *C9ORF72* mutations, with an
48
49 age at onset of less than 50 years in around 50% of cases (Snowden *et al.* 2015). However,
50
51 patients with *MAPT* mutations may have a broad range at onset from their 20s to their 80s
52
53 (van Swieten & Spillantini 2007). Mean disease duration is 8 years (Snowden *et al.* 2015),
54
55 but with a wide range of 5 to 30 years (Seelaar *et al.* 2011).
56
57
58
59
60

1
2
3 The typical clinical picture in *MAPT*-associated FTD is bvFTD with or without parkinsonism,
4 with or without a degree of language decline (usually mild semantic impairment) later on in
5 disease (Seelaar et al. 2011, Benussi et al. 2015). However, patients can present with a
6 wide range of features, and there is generally poor correlation of clinical features with the
7 underlying gene mutation (Benussi et al. 2015).
8
9
10
11
12

13
14
15 Parkinsonism can occasionally be the sole presenting feature of disease, but more typically
16 develops after onset of bvFTD (van Swieten & Spillantini 2007, Kertesz et al. 2011, Rohrer &
17 Warren 2011). Parkinsonism usually manifests as bradykinesia, rigidity (limb and/or axial),
18 postural instability, and poor response to levodopa (Park & Chung 2013, Siuda et al. 2014).
19 However, a levodopa-responsive asymmetrical resting tremor has been observed in some
20 patients (Tsuboi et al. 2002), although response is rarely sustained. Parkinsonism can be
21 part of an isolated CBS (Rossi et al. 2008, Kouri et al. 2014) or less frequently PSPS (Rohrer
22 et al. 2011b). Pyramidal signs, postural tremor, myoclonus, dystonia, dysarthria and
23 abnormal eye movements have also been observed (Siuda et al. 2014). MND is rare, but
24 lower motor neuron signs such as muscle wasting and fasciculations have also been
25 reported (Zarranz et al. 2005, Di Fonzo et al. 2014).
26
27
28
29
30
31
32
33
34
35
36
37
38

39 Prominent behavioural features in patients with *MAPT* mutations include disinhibition,
40 obsessiveness and stereotyped repetitive behaviors, but apathy is less common than in *GRN*
41 or *C9ORF72* cases (van Swieten & Spillantini 2007, Snowden et al. 2015). Executive
42 dysfunction is well recognized in *MAPT* cases but does not differentiate from patients with
43 *GRN* or *C9ORF72* mutations (Snowden et al. 2015). Neuropsychiatric presentations are less
44 common than in cases with *GRN* or *C9ORF72* mutations, but are still seen: a patient with
45 the S356T mutation who had been diagnosed as schizophrenia aged 27 had confirmed
46 FTLD-tau at post-mortem and a family history of 'schizophrenia' in her father, who died aged
47 42 (Momeni et al. 2010b). Semantic impairment and anomia are common later in disease,
48 (Pickering-Brown et al. 2008, Rohrer et al. 2009a) and more common than in *GRN* cases
49
50
51
52
53
54
55
56
57
58
59
60

1
2
3 (Snowden et al. 2015). Although a PPA presentation is much less common than in patients
4 with *GRN* mutations (Pickering-Brown et al. 2008), a few patients have been described, for
5 example, with nfvPPA associated with V363I (Munoz *et al.* 2007, Rossi *et al.* 2014) and
6 G304S (Villa *et al.* 2011) mutations and svPPA associated with V363I (Bessi *et al.* 2010) and
7 P301L (Ishizuka *et al.* 2011) mutations. A novel mutation (C291R) has also been recently
8 identified in a patient with PPA-CBS who had a prominent apraxia of speech (Marshall *et al.*
9 2015). Episodic memory loss can be prominent in some cases and has been found in
10 association with profound hippocampal atrophy in patients with a R406W mutation (Tolboom
11 *et al.* 2010), mimicking (and therefore mistakenly diagnosed as) early onset familial AD.
12
13
14
15
16
17
18
19
20
21

22 *GRN*

23
24 There are currently 82 pathogenic mutations described in *GRN*. Mean age at onset is later
25 than *MAPT*, between 59 and 65 years, with a range of 35 to 89 years (Gass *et al.* 2006, van
26 Swieten & Heutink 2008, Le Ber 2013) but this can vary widely even within the same family.
27 A polymorphism in the *TMEM106B* gene has been shown to affect age at onset in *GRN*
28 mutation carriers (Cruchaga *et al.* 2011, Finch *et al.* 2011, van der Zee *et al.* 2011). Disease
29 duration is similar to *MAPT*, with a mean of 9 years (Snowden et al. 2015) and ranges from
30 3-22 years (Beck *et al.* 2008).
31
32
33
34
35
36
37
38
39
40

41 The clinical picture is variable and the identified mutation correlates poorly with the clinical
42 syndrome. The most common presentation is bvFTD and less commonly PPA (Beck et al.
43 2008, Le Ber *et al.* 2008) and these two syndromes can occur within the same family. Cases
44 with *GRN*-associated bvFTD can have a range of features as seen in sporadic bvFTD, but
45 tend to have prominent apathy (Beck et al. 2008, Snowden et al. 2015) and social
46 withdrawal. Between 10 to 30% of patients can present with episodic memory impairment
47 (Le Ber et al. 2008), and, when combined with evidence of apraxia, dyscalculia, and
48 visuospatial dysfunction secondary to early parietal atrophy, this may appear similar to AD.
49 Neuropsychiatric manifestations are quite common, with patients displaying delusions,
50
51
52
53
54
55
56
57
58
59
60

1
2
3 hallucinations, or ritualistic and obsessive behaviors (Le Ber et al. 2008, Momeni *et al.*
4 2010a). In contrast to *MAPT* and *C9ORF72* cases, there is often predominant early
5 language involvement or a language-only presentation. Around 10% of cases present with
6
7 language involvement or a language-only presentation. Around 10% of cases present with
8
9 PPA, which can occasionally precede development of CBS (Baker et al. 2006, Cruts et al.
10
11 2006). Although the phenotype of speech disturbance is often described as nfvPPA, patients
12
13 can often have widespread language dysfunction with features that do not neatly fit into one
14
15 of the three main PPA phenotypes, more commonly fitting in to the PPA-U (unclassified)
16
17 group (Rohrer et al. 2010a). Patients with PPA that appears 'mixed' or hard to classify,
18
19 should therefore be investigated for the presence of a family history, or other supportive
20
21 clinical or imaging features of a *GRN* mutation.
22

23
24
25 Extrapyramidal features are present in around 40-60% of cases with a *GRN* mutation, either
26
27 just as asymmetrical parkinsonism, or as a typical CBS-like presentation with limb apraxia
28
29 and dystonia (Kelley *et al.* 2009, Siuda et al. 2014). Unlike in *MAPT* cases, parkinsonism is
30
31 not often an early feature, becoming evident well after bvFTD develops (Kelley et al. 2009).
32
33 Parkinsonism does not usually improve with levodopa (Di Fabio *et al.* 2010), but can
34
35 occasionally have an initial response.
36

37
38
39 MND is rarely seen, although in one large study, features of MND were found in 5.4% of
40
41 patients with a *GRN* mutation (Chen-Plotkin *et al.* 2011).
42

43 *C9ORF72*

44
45
46 In 2011 two groups identified a hexanucleotide repeat expansion mutation in a non-coding
47
48 region of the *C9ORF72* gene (DeJesus-Hernandez et al. 2011, Renton et al. 2011). Healthy
49
50 individuals without the mutation usually carry 2-20 repeats on each allele. The number of
51
52 repeats in mutation carriers is difficult to size accurately as it is so large, but most studies
53
54 suggest patients usually possess 400-4400 repeats (Beck *et al.* 2013), with most possessing
55
56 thousands. Although the minimum repeat number for disease is not clear, most consider
57
58
59
60

1
2
3 greater than 30 repeats pathogenic (Simon-Sanchez *et al.* 2012, Beck *et al.* 2013,
4 Woollacott & Mead 2014). The age at onset is extremely variable, ranging from 21-83 (mean
5 50) years (Hsiung *et al.* 2012, Majounie *et al.* 2012, Snowden *et al.* 2012). Similarly to cases
6 with *GRN* mutations, a *TMEM106B* variant may also modify age at onset in *C9ORF72*
7 expansion carriers (van Blitterswijk *et al.* 2014, Gallagher *et al.* 2014). Disease duration is
8 highly variable, ranging from 1-22 years, with a mean of 8-9 years (Hsiung *et al.* 2012,
9 Mahoney *et al.* 2012). Some studies have observed more rapid progression in patients with
10 *C9ORF72*-associated FTD or MND, although slowly progressive FTD cases have been
11 observed who survive for 15-20 years (Khan *et al.* 2012, Gomez-Tortosa *et al.* 2014,
12 Suhonen *et al.* 2014), perhaps accounting for some cases previously thought to be bvFTD
13 phenocopies (Rohrer *et al.* 2015a).
14
15
16
17
18
19
20
21
22
23
24

25
26
27 The typical presentation in *C9ORF72* expansion carriers is bvFTD, MND or a combination of
28 FTD and MND. Prominent behavioural features include apathy, disinhibition and loss of
29 empathy (Mahoney *et al.* 2012), although one study observed more emotional warmth in
30 patients with bvFTD secondary to *C9ORF72* expansions than due to *MAPT* or *GRN*
31 mutations (Snowden *et al.* 2015). Although many *C9ORF72* bvFTD patients have food fads
32 or overeating, patients appear to have a relatively absent sweet tooth compared with non-
33 *C9ORF72* associated FTD cases (Snowden *et al.* 2012). Complex, unusual, repetitive or
34 stereotyped behaviors are common: 59% of patients in one study displayed complex
35 behavioural routines involving sorting, washing hands or cleaning (Snowden *et al.* 2012).
36
37
38
39
40
41
42
43
44
45

46
47 Language decline appears to be rarer than in patients with *GRN* and *MAPT* mutations;
48 although *C9ORF72* expansions have been identified infrequently in PPA cases, including
49 nfvPPA (Renton *et al.* 2011, Hsiung *et al.* 2012, Mahoney *et al.* 2012, Snowden *et al.* 2012)
50 and svPPA (Renton *et al.* 2011, Snowden *et al.* 2012, Cerami *et al.* 2013, Josephs *et al.*
51 2013), these have not been described in detail and the PPA phenotype of *C9ORF72*
52 expansion cases remains unclear.
53
54
55
56
57
58
59
60

1
2
3
4
5 On neuropsychological assessment, the key findings are profound executive dysfunction,
6 reduced spontaneous/propositional speech, echolalia, perseveration, impaired verbal and
7 visual episodic memory, anomia, and dominant parietal deficits, particularly apraxia and
8 dyscalculia (Mahoney et al. 2012, Snowden et al. 2012). Similarly to *MAPT* and *GRN*
9 mutation-associated FTD, memory impairment can be a prominent and early feature
10 (Mahoney et al. 2012), as can anxiety, which can lead to misdiagnosis of 'early-onset AD'.
11 An amnesic presentation has been observed in several large cohort studies of *C9ORF72*
12 expansion carriers (Dobson-Stone et al. 2012, Mahoney et al. 2012), perhaps due to
13 involvement of the parietal lobes and posterior cingulate gyrus (Irish et al. 2013). Patients
14 presenting with prominent episodic memory impairment also have a later age at onset than
15 those with *C9ORF72*-associated bvFTD (Wojtas et al. 2012, Cacace et al. 2013), which
16 makes patients look even more similar to AD. In one study 2.6% of patients initially
17 diagnosed with sporadic or familial AD possessed *C9ORF72* expansions; confusingly all had
18 AD-like biomarkers in cerebrospinal fluid (although without histopathological confirmation),
19 which further complicated the diagnostic picture (Wallon et al. 2012).
20
21
22
23
24
25
26
27
28
29
30
31
32
33
34
35
36

37 Psychiatric presentations are common, particularly psychosis (Arighi et al. 2012, Boeve et al.
38 2012, Calvo et al. 2012, Dobson-Stone et al. 2012, Englund et al. 2012, Mahoney et al.
39 2012, Galimberti et al. 2013, Kertesz et al. 2013, Devenney et al. 2014, Snowden et al.
40 2015). Typical features include delusions, visual or auditory hallucinations, odd somatoform
41 or tactile hallucinations, and prominent agitation and anxiety, perhaps due to altered body
42 schema processing associated with cortico-thalamo-cerebellar network involvement
43 (Downey et al. 2014). Bipolar disorder and obsessive-compulsive-like presentations are also
44 seen: in a study of 32 patients with FTD or FTD-MND and the *C9ORF72* expansion, 38%
45 had prominent psychotic features at presentation and had been diagnosed with paranoid
46 schizophrenia, delusional psychosis or a somatoform psychosis (Snowden et al. 2012).
47 However, cases with a *C9ORF72* expansion have been only very rarely identified in
48
49
50
51
52
53
54
55
56
57
58
59
60

1
2
3 individuals with typical schizophrenia (0.67%) (Galimberti *et al.* 2014a) or bipolar disorder
4
5 (0.5-1%) (Meisler *et al.* 2013, Galimberti *et al.* 2014b).
6
7

8
9 Parkinsonism is also common and in some studies detectable in up to a third of patients
10
11 (Boeve *et al.* 2012). It typically manifests as a symmetrical akinetic-rigid syndrome with gait
12
13 disturbance, with or without a tremor that is usually postural or action, but rarely resting, in
14
15 nature. Occasionally parkinsonism can be the sole manifestation for over 10 years, only later
16
17 morphing into more typical bvFTD. Most patients do not benefit from levodopa. The
18
19 expansion has also been detected in a few patients who have been clinically diagnosed with
20
21 another neurodegenerative disorder including idiopathic Parkinson's disease, (O'Dowd *et al.*
22
23 2012, Cooper-Knock *et al.* 2013, Lesage *et al.* 2013), Lewy body dementia (Robinson *et al.*
24
25 2014), multiple system atrophy (Goldman *et al.* 2014), PSPS (Origone *et al.* 2013), CBS
26
27 (Lindquist *et al.* 2013), prion disease (Majounie *et al.* 2012, Beck *et al.* 2013), and
28
29 Huntington's disease phenocopies (Hensman Moss *et al.* 2014). There have been a small
30
31 number of cases with prominent (Lindquist *et al.* 2013) or isolated (Corcia *et al.* 2015)
32
33 cerebellar ataxia associated with the *C9ORF72* expansion.
34
35

36
37 All subtypes of MND have been observed in association with the expansion although adult-
38
39 onset ALS is by far the most common, and often indistinguishable from sporadic ALS
40
41 (Cooper-Knock *et al.* 2012, Snowden *et al.* 2013). Patients with *C9ORF72*-associated MND
42
43 tend to have a higher prevalence of behavioural changes and cognitive impairment
44
45 (Millecamps *et al.* 2012, Montuschi *et al.* 2015).
46
47

48 49 *VCP*

50
51 In 2004, mutations in *VCP* on chromosome 9p13.3 were identified in cases of inclusion body
52
53 myositis with Paget's disease of the bone and FTD (IBMPFD), an autosomal dominant
54
55 'multisystem proteinopathy' (Watts *et al.* 2004, Benatar *et al.* 2013). *VCP* mutations have
56
57
58
59
60

1
2
3 very rarely been described as causing isolated FTD (van der Zee *et al.* 2009). Although at
4
5 least 19 mutations exist they account for less than 1% of cases of FTD overall (Cruts *et al.*
6
7 2012). The clinical presentation tends to start with a myopathy in the fourth decade in 90% of
8
9 cases, with subsequent cognitive decline from the fifth decade onwards in 30% of patients
10
11 and Paget's disease in 45%. Most patients develop bvFTD, although early semantic and
12
13 other language deficits are also observed (Kim *et al.* 2011), and an MND phenotype, with or
14
15 without FTD overlap (Miller *et al.* 2012, Hirano *et al.* 2015) is seen more rarely. Although
16
17 parkinsonism is rare, several mutations are associated with development of an akinetic-rigid
18
19 syndrome in later disease stages (Watts *et al.* 2004, van der Zee *et al.* 2009, Spina *et al.*
20
21 2013), and rare cases present as idiopathic Parkinson's disease with levodopa
22
23 responsiveness (Chan *et al.* 2012).
24

25 26 **CHMP2B**

27
28 Study of a large Danish kindred with familial FTD (Skibinski *et al.* 2005) led to the discovery
29
30 of the *CHMP2B* gene mutation on chromosome 3p11.2. Outside of this family, variants in
31
32 *CHMP2B* have been identified only extremely rarely. Most cases have FTLD-UPS,
33
34 characterized by inclusions that are positive for ubiquitin and p62 but negative for TDP-43
35
36 and FUS on histopathological analysis of brain tissue (Holm *et al.* 2009). Average age at
37
38 onset of FTD is 58 (range 46-65) years, with average disease duration of around 10 years,
39
40 although disease often presents insidiously and can be slowly progressive. The typical
41
42 clinical presentation is bvFTD, often with more widespread cognitive impairment, combined
43
44 with prominent late parkinsonism (usually an asymmetrical akinetic-rigid syndrome),
45
46 dystonia, pyramidal signs and myoclonus (Gydesen *et al.* 2002, Stockholm *et al.* 2013). MND
47
48 has been reported in a few cases (Parkinson *et al.* 2006, Cox *et al.* 2010).
49
50
51
52
53
54
55
56
57
58
59
60

TARDBP

Mutations in the *TARDBP* gene on chromosome 1 were initially identified in familial and sporadic ALS cases (Kabashi *et al.* 2008, Rutherford *et al.* 2008, Sreedharan *et al.* 2008, Van Deerlin *et al.* 2008), and account for 4-6% of familial ALS cases and 1% of sporadic ALS cases. They also account for a small proportion of cases with combined FTD-MND (Benajiba *et al.* 2009, Chio *et al.* 2010), associated with a broad phenotype including features of parkinsonism or an overlap syndrome of MND/PSPS (Moreno *et al.* 2015). One case of bvFTD with a supranuclear gaze palsy and chorea has been observed (Kovacs *et al.* 2009). *TARDBP* mutations are very rare in pure FTD, with less than 20 cases currently identified; even fewer have had neuropathological confirmation of FTLN (Gitcho *et al.* 2009, Gelpi *et al.* 2014, Moreno *et al.* 2015). FTD cases have had bvFTD or svPPA, with a wide range of age at onset (29-77 years) (Borroni *et al.* 2009, Gitcho *et al.* 2009, Gelpi *et al.* 2014, Synofzik *et al.* 2014, Moreno *et al.* 2015).

SQSTM1

Mutations in *SQSTM1* (encoding for p62/sequestome 1) on chromosome 5q35 lead to isolated Paget's disease of the bone (Gennari *et al.* 2010), which is a clinical feature also found in cases of multisystem proteinopathy associated with *VCP-1* mutations. More recently, *SQSTM1* mutations have also been identified in familial and sporadic MND and FTD-MND (Fecto *et al.* 2011, Rubino *et al.* 2012, Chen *et al.* 2014). However, they have recently been identified in a small number of patients with pure FTD without associated ALS (Le Ber *et al.* 2013, Miller *et al.* 2015). The clinical phenotype of FTD with underlying *SQSTM1* mutations appears to be highly variable. The average age at onset is 60 years (range 48-73), with an average disease duration of 10 years (range 2-29) (Le Ber *et al.* 2013). The majority of patients present with a bvFTD-like syndrome, with a third having concurrent Paget's disease of the bone. In a more recent case series of 465 FTLN patients, four patients had *SQSTM1* mutations (0.85%), all of whom presented with atypical FTD

1
2
3 syndromes including bvFTD, RTLA with prominent semantic impairment and CBS (Miller et
4 al. 2015).

8 *FUS*

9
10 Similarly to *TARDBP*, *FUS* mutations are far more prevalent in familial ALS (4%) and
11 sporadic ALS (<1%) than in FTD-MND or FTD alone (Ng *et al.* 2015). The first ALS-
12 associated mutation in *FUS* on chromosome 16p11.2 was identified in 2009 (Kwiatkowski et
13 al. 2009, Vance et al. 2009), and was associated with characteristic *FUS*-positive protein
14 inclusions in spinal cord neurons. However, *FUS* mutations are rarely seen in patients with
15 FTD who have this pathology in brain tissue. Currently 4 mutations linked to FTD-MND exist
16 (Blair *et al.* 2010, Ticozzi *et al.* 2009, Broustal *et al.* 2010, Yan *et al.* 2010) and 2 cases of
17 pure bvFTD with a *FUS* variant have been reported (Van Langenhove *et al.* 2010, Huey *et*
18 *al.* 2012).

28 *UBQLN2*

29
30 Originally identified in association with X-linked familial ALS, 4 further mutations in *UBQLN2*
31 were identified in a study of another 40 patients with MND with an apparently X-linked mode
32 of transmission (Deng *et al.* 2011). 23% of these patients had FTD-MND, usually with a
33 bvFTD phenotype which occasionally preceded onset of motor symptoms, and age at onset
34 varied widely (16-71 years) with a disease duration usually less than 4 years. A more recent
35 study found *UBQLN2* mutations in 2/161 ALS patients and 1/45 FTD patients, with all
36 patients presenting with apparently sporadic disease (Synofzik *et al.* 2012).

46 *TREM2*

47
48 Mutations in the gene *TREM2* on chromosome 6p21.1 were first identified in association with
49 an autosomal recessive, rare condition called polycystic lipomembranous osteodysplasia
50 with sclerosing leukoencephalopathy (PLOS or Nasu-Hakola disease) (Paloneva *et al.*
51 2000). Patients with Nasu-Hakola disease develop multifocal bony cysts, ankle swelling and
52 fractures in the third decade, followed by an FTD-like cognitive decline in the fourth decade
53
54
55
56
57
58
59
60

1
2
3 and death in the fifth decade. More recently there have been observations of patients with
4
5 homozygous or compound heterozygous *TREM2* mutations who develop dementia without
6
7 bony involvement (Chouery *et al.* 2008, Giraldo *et al.* 2013, Guerreiro *et al.* 2013a, Guerreiro
8
9 *et al.* 2013c, Lattante *et al.* 2013, Rayaprolu *et al.* 2013, Le Ber *et al.* 2014). Patients
10
11 developed cognitive and neuropsychiatric symptoms in their thirties to late forties,
12
13 characterized by a frontal dysexecutive syndrome, reduced empathy, disinhibition, and
14
15 overeating, as well as language dysfunction, episodic memory problems, parietal deficits,
16
17 parkinsonism (mainly bradykinesia) and seizures. Death ensued by late forties or fifties in
18
19 most cases. Heterozygous *TREM2* variants have recently been described as a risk factor for
20
21 AD (Benitez *et al.* 2013, Guerreiro *et al.* 2013b, Jonsson *et al.* 2013, Pottier *et al.* 2013) but
22
23 studies have been mixed as to whether this is also the case for FTD (Lattante *et al.* 2013,
24
25 Rayaprolu *et al.* 2013, Borroni *et al.* 2014, Cuyvers *et al.* 2014, Ruiz *et al.* 2014, Slattery *et*
26
27 *al.* 2014, Thelen *et al.* 2014, Lill *et al.* 2015).
28
29
30
31

32 *TBK1*

33
34 Mutations in the gene *TBK1* were recently identified in cohorts of MND, FTD and FTD-MND
35
36 patients (Cirulli *et al.* 2015, Freischmidt *et al.* 2015, Gijssels *et al.* 2015, Le Ber *et al.* 2015,
37
38 Pottier *et al.* 2015). The overall prevalence of *TBK1* mutations across the FTD and MND
39
40 spectrum ranges from 0.4-4.5%, but mutations are more common in FTD-MND and rare in
41
42 FTD alone. For example, one recent study identified a *TBK1* mutation in 0.5% of patients
43
44 with isolated MND but 10.8% of familial FTD-MND patients, although mutations were rare in
45
46 isolated FTD (1 patient only) (Le Ber *et al.* 2015). In a Belgian study, loss-of-function
47
48 mutations were identified in 1.1% (5/460) with isolated FTD, 3.4% (5/147) with isolated MND
49
50 and 4.5% (1/22) with FTD-MND (Gijssels *et al.* 2015). Dual mutations seem to be common
51
52 including concurrent *C9ORF72* expansions (Gijssels *et al.* 2015) and mutations in the
53
54 optineurin (*OPTN*) (Pottier *et al.* 2015) or *FUS* (Freischmidt *et al.* 2015) genes. In one study
55
56 of patients with confirmed FTLT-TDP and clinical FTD, age at onset of cognitive symptoms
57
58
59
60

1
2
3 ranged from 64 to 80 years, with an average disease duration of 5.6 years (range 2-10
4 years) (Pottier et al. 2015). Clinical diagnoses of those presenting with dementia were
5 heterogeneous, including bvFTD, nfvPPA, AD or FTD-ALS. In another study of seven
6 patients with *TBK1* mutations and FTD (one with concurrent MND), the average age at onset
7 was 66.3 years (Van Mossevelde et al. 2015): five out of six cases with isolated FTD had
8 bvFTD but with early episodic memory impairment as well as prominent parkinsonism
9 (Gijssels et al. 2015, Van Mossevelde et al. 2015) whilst the other case developed PPA
10 aged 70 with reduced speech output, word retrieval difficulties and semantic paraphasias
11 (Van Mossevelde et al. 2015). NfvPPA with prominent agrammatism has also been
12 described in a patient with combined *TBK1/OPTN* mutations (Pottier et al. 2015). Similar to
13 *C9ORF72* expansion carriers, a high proportion of MND cases with a *TBK1* mutation (~50%
14 in one study) demonstrated cognitive impairment (Freischmidt et al. 2015). Further studies in
15 larger cohorts with detailed clinical phenotyping and clinicopathological correlation will be
16 invaluable to clarify the spectrum of *TBK1*-associated neurodegenerative disease and to
17 inform clinicians about which patients they should test for these mutations.
18
19
20
21
22
23
24
25
26
27
28
29
30
31
32
33
34
35
36
37
38
39
40
41
42
43
44
45
46
47
48
49
50
51
52
53
54
55
56
57
58
59
60

1
2
3
4
5
6
7
8
9
10
11
12
13
14
15
16
17
18
19
20
21
22
23
24
25
26
27
28
29
30
31
32
33
34
35
36
37
38
39
40
41
42
43
44
45
46
47
48
49
50
51
52
53
54
55
56
57
58
59
60

FTD gene	Age at onset (years)	Disease duration (years)	Typical clinical presentation	Prominent behavioural and psychiatric features	Language impairment	Other cognitive deficits	Parkinsonism/extrapyramidal features	Motor neuron features
----------	----------------------	--------------------------	-------------------------------	--	---------------------	--------------------------	--------------------------------------	-----------------------

For Peer Review

MAPT	Mean: mid 50s Range: 20s-80s	Mean: 8 Range: 5-30	BvFTD +/- parkinsonism +/- mild late language impairment	Disinhibition, obsessionality, stereotyped repetitive behaviour; less apathy Psychiatric symptoms less common	Usually late semantic impairment and anomia; typical PPA presentation much less common	Episodic memory impairment in some cases	Common early on; usually limb/axial rigidity, bradykinesia, and tremor; poorly responsive to levodopa Can have frank PSPS/CBS	Rare
GRN	Mean: 59-65 Range: 35-89	Mean: 9 Range: 3-22	Variable; typically bvFTD>PPA >CBS. Can mimic AD	Apathy and social withdrawal Psychiatric common: delusions, hallucinations, obsessionality, rituals	Common; either bvFTD with prominent early language impairment or frank PPA (e.g. nfvPPA or atypical presentation with PPA-U)	Episodic memory impairment, apraxia, dyscalculia, visuospatial dysfunction (parietal)	Common later on (found in 40-60%); asymmetrical parkinsonism with poor levodopa response, or CBS-like (limb apraxia and dystonia)	Rare
C9ORF72	Mean: 50 Range: 21-83	Mean 8-9 Range: 1-22	Typically bvFTD +/- MND or MND alone; less commonly nfvPPA	Apathy, disinhibition, less sweet tooth, more complex unusual repetitive behaviours Psychosis and anxiety very common: odd delusions or auditory/tactile hallucinations; may mimic bipolar or schizophrenia	Less common, few have nfvPPA/svPPA	Early episodic memory impairment Profound executive dysfunction, impaired verbal and visual episodic memory, anomia, apraxia and dyscalculia	Common (30%); symmetrical akinetic rigid syndrome +/- postural or rest tremor; gait disturbance Few cases with cerebellar ataxia	Common in bvFTD>PPA cases Typically ALS (bulbar onset in >40%); PLS and PMA rare
TBK1	Mean: 65.5-72 Range: 48-80	Mean 7.1 Range 2-13	FTD-MND or MND alone > FTD alone Usually bvFTD, some cases of PPA	Disinhibition, aggression, motor agitation, apathy Psychiatric diagnoses common: bipolar disorder, schizophrenia, alcoholism, depression	bvFTD: word retrieval difficulties, reduced spontaneous speech PPA: reduced speech output, repetition difficulties, semantic paraphasias or nfvPPA with agrammatism	Early prominent episodic memory impairment	Very common; rigidity, postural or resting tremor, bradykinesia	Common; often with FTD but also MND alone Typically ALS with bulbar onset and prominent upper motor neuron signs
VCP	FTD Mean: 57 Range: 49-60 Myopathy Mean: 42 Range: 24-61	Death in 40s-60s	Progressive myopathy, Paget's disease, FTD in 30%	Apathy and disinhibition; psychotic features seen rarely	Aphasia and early semantic impairment common	Episodic memory impairment in a few cases	Rare, but can have late stage akinetic-rigid syndrome or early typical parkinsonism in some cases	Rare, usually myopathy or IBM-like, but can have MND
CHMP2B	Mean: 58 Range: 46-65	Mean: 10	Usually bvFTD; rare; mainly in single Danish family	Insidious onset of early behavioural change	Dynamic aphasia	Limited information available	Prominent late stage; asymmetrical akinetic-rigid syndrome, dystonia, myoclonus	Rare, can be PMA
TARDBP	Range: 29-77	Limited information available	Rare in FTD alone, more common in FTD-MND or MND alone	Variable, usually bvFTD/ svPPA	Prominent semantic impairment in a few cases	Limited information available	Parkinsonism (including PSPS) seen in combination with MND	FTD-MND and MND much more common than FTD
SQSTM1	Mean: 60 Range 48-73	Mean 10.2 Range 2-29	Rare in FTD alone, more common in FTD-MND or MND alone; can have concurrent Paget's disease of bone	BvFTD-like; some are atypical e.g. right temporal FTD with semantic impairment, or CBS-like	Limited information available	Limited information available	Limited information available	FTD-MND and MND much more common than FTD

FUS	Mean: 40's to 50's	Mean 2-4	Rare in FTD alone, more common in MND alone, or FTD-MND	BvFTD-like	Limited information available	Limited information available	Limited information available	MND much more common than FTD
UBQLN2	Mean 40.6 Range: 16-71	Mean 3.8	Adult ALS-FTD or juvenile X-linked ALS; may appear sporadic	BvFTD-like, sometimes prior to motor symptoms	Limited information available	Limited information available	Limited information available	FTD-MND and MND much more common than FTD; limb/bulbar onset ALS
TREM2	Nasu-Hakola disease: 30s FTD-like syndrome: 30s-40s	Death in 50s	Homozygous mutations cause Nasu-Hakola disease, or FTD-like syndrome without bony involvement. Heterozygous variants associated with AD	Nasu-Hakola disease causes bony cysts, ankle swelling and fractures FTD-like syndrome with compound heterozygous mutations is bvFTD-like; seizures and visual hallucinations also observed	Present, including non-fluency, anomia, semantic paraphasias	Episodic memory and parietal impairment observed	Common; bradykinesia, postural instability	Brisk tendon reflexes seen

Table 3 Summary of clinical features of familial frontotemporal dementia (FTD) syndromes. AD = Alzheimer's disease; ALS = amyotrophic lateral sclerosis; bvFTD = behavioural variant FTD; CBS = corticobasal syndrome; MND = motor neuron disease; nfvPPA = nonfluent variant primary progressive aphasia; PMA = progressive muscular atrophy; PPA-U = primary progressive aphasia unclassified; PSPS = progressive supranuclear palsy syndrome; svPPA = semantic variant primary progressive aphasia. Clinical features are adapted from tables in: Rohrer and Warren (2011) and Ng et al. (2015).

Presymptomatic individuals

With an increasing number of gene mutations linked to FTD, and as potential treatments for FTD appear on the horizon, we need sensitive and reliable biomarkers of disease for use in clinical trials of patients with sporadic and familial FTD. In other diseases such as AD and Huntington's disease, there is evidence of change in a number of biomarkers several years prior to symptom onset (Scahill *et al.* 2002, Tabrizi *et al.* 2009, Bateman *et al.* 2012), suggesting that one needs to intervene well before clinical symptoms develop to significantly ameliorate disease. Up until now, large scale analyses of neuropsychological and neuroimaging biomarkers have been notably absent in both sporadic and familial FTD (Rohrer *et al.* 2013b), and there are no reliable fluid (blood, cerebrospinal fluid or urine) biomarkers of FTD itself, or of its underlying pathology, except for reduced serum and cerebrospinal fluid (CSF) progranulin levels in the majority of symptomatic patients and presymptomatic carriers of the *GRN* mutation (Finch *et al.* 2009, Carecchio *et al.* 2009). However, through monitoring families with FTD-associated gene mutations over many years, we will start to gain invaluable insights into these patterns and enable detection and validation of such biomarkers. Several studies have examined presymptomatic changes in individuals with familial FTD mutations, but most studies were on a case series basis. More recently, a large study of 220 individuals recruited from 11 research sites across Europe and Canada within the Genetic Frontotemporal Dementia Initiative (GENFI) demonstrated that cognitive and structural imaging changes can be detected 5-10 years before expected onset of symptoms (calculated from the mean familial age at onset) in adults at risk of familial FTD (Rohrer *et al.* 2015b). This study examined 118 mutation carriers (40 symptomatic: 11 with mutations in *MAPT*, 13 in *GRN* and 16 with the *C9ORF72* expansion), 78 presymptomatic mutation carriers, (15 with *MAPT* mutations, 45 with *GRN* mutations and 18 with the *C9ORF72* expansion) and 102 individuals without the mutation ('non-carriers'). Carriers displayed deficits on neuropsychological assessment across a wide range of tests as early

1
2
3 as 5 years before predicted symptom onset. Deficits were particularly pronounced on tests of
4
5 naming and executive function. There were differences between groups in which test
6
7 detected changes the earliest: the Boston Naming Test and the Cambridge Behavioral
8
9 Inventory-Revised (CBI-R) version showed abnormalities earliest for *MAPT* mutation
10
11 carriers, the backwards Digit Span for *GRN* mutation carriers and the CBI-R for *C9ORF72*
12
13 expansion carriers. There also appeared to be an ordered series of neuroimaging changes
14
15 across all mutation groups prior to expected onset of symptoms. Insular atrophy was evident
16
17 on volumetric analysis of MRI brain scans of mutation carriers 10 years before expected
18
19 onset of symptoms, followed by temporal lobe atrophy (also at 10 years before expected
20
21 onset), then reduced frontal lobe, subcortical, and whole brain volumes at 5 years before
22
23 expected onset. There were also specific patterns of sequential atrophy within each group:
24
25 *MAPT* mutation carriers first showed atrophy of the hippocampus and amygdala, *GRN*
26
27 mutation carriers showed early insular atrophy (15 years prior to expected onset), and
28
29 *C9ORF72* expansion carriers had very early subcortical (thalamic), insular, and posterior
30
31 cortical atrophy (25 years prior to expected onset). The long 'run-in' of changes prior to
32
33 clinical onset of symptoms emphasizes the urgent need for identification and validation of
34
35 other biomarkers of the disease process in familial and sporadic FTD, such as blood or CSF
36
37 biomarkers, which can be measured over time.
38
39
40

41 **Current challenges and future research**

42
43
44 In a disease as complex as FTD, there are multiple challenges for the clinician and scientist.
45
46 These are inherent in research studies aiming to improve our understanding of disease
47
48 pathogenesis and disease presentation, identify novel treatments and implement better care
49
50 for these patients and their families. However, in this section we have focused on
51
52 summarizing challenges commonly encountered by clinicians managing patients with FTD
53
54 and suggest future avenues for research in order to address these.
55
56
57
58
59
60

Diagnosis and prognosis of FTD syndromes

Making a correct and early diagnosis is essential for both the clinician and the patient with FTD, as it allows access to information about current and future symptoms, likely disease course and avoidance of unnecessary or inappropriate treatments. As discussed above, there are several features of the various FTD syndromes that are also seen in other neurodegenerative diseases such as AD or idiopathic Parkinson's disease and in psychiatric disease. In PPA, it can also be difficult to differentiate between patients with lvPPA (around 70% of whom have AD pathology) and nvPPA (the majority of whom have FTLN pathology). Patients misdiagnosed as AD, Parkinson's disease or an atypical psychiatric syndrome may be offered treatment with acetylcholinesterase inhibitors, levodopa preparations or antidepressant or anti-psychotic medications that are at best ineffective in FTD or at worst offer no benefit with significant and unnecessary side effects. As well as guiding appropriate pharmacological treatments, a correct diagnosis allows appreciation of the support needed by patients with different features of FTD, for example access to a specialist speech and language therapist for management of PPA, or a specialist nurse with detailed knowledge of common practical issues or symptoms that patients and their relatives with FTD face on a daily basis. There are also several national support groups for patients with FTD and their relatives, which can be invaluable for informal advice, support and social contact. The main barriers preventing correct and timely diagnosis of FTD are a lack of awareness about and understanding of the clinical and pathological overlap between a variety of neurodegenerative diseases, and the lack of available reliable biomarkers to differentiate between these. Some clinicians may not be aware that AD pathology can lead to a clinical presentation of FTD or AD, and that FTLN pathology can lead to symptoms of episodic memory loss in FTD, thus present like AD in a small proportion of cases. In primary care, where FTD is rare, and AD is common, an AD diagnosis might have been made several years ago, before new symptoms prompt onward specialist referral and reconsideration of diagnosis. The use of CSF biomarkers of amyloid-beta and tau, and in some centres

1
2
3 amyloid PET imaging, can be helpful in differentiating cases with underlying AD pathology.
4
5 However, these types of biomarkers do not currently exist for FTLD pathology, and unless
6
7 there is a known FTD-associated gene mutation, patients with FTD and prominent memory
8
9 symptoms may still be diagnosed with AD even in the absence of definite biomarker
10
11 evidence. Future research should elucidate biomarkers of FTD that could be used in
12
13 combination with AD and markers of other neurodegenerative diseases to characterize these
14
15 different syndromes more carefully.
16

17
18
19 As discussed above, many of the familial FTD syndromes also include parkinsonism or
20
21 psychiatric phenomena either early on or at some point in the disease course. This may
22
23 occur in the context of a strong family history of psychiatric disease (which in itself is also
24
25 common) or with seemingly 'unrelated' cases of MND or dementia in the family (also
26
27 common) or, if there is incomplete penetrance of a mutation, or a small family, a complete
28
29 absence of family history. This clinical and familial heterogeneity makes it even more difficult
30
31 to decide if a patient has sporadic or familial FTD, and research should focus on longitudinal
32
33 phenotyping of large cohorts of patients with sporadic and familial FTD, with varying degrees
34
35 of family history and clinical presentations, to expand our knowledge of what could be used
36
37 to indicate genetic risk of disease. In the current absence of consistently reliable indicators of
38
39 familial disease (other than a known gene mutation within the family), it may be prudent to
40
41 consider offering genetic testing to all newly diagnosed (and previously diagnosed) patients
42
43 with FTD, particularly bvFTD and FTD-MND.
44
45

46
47
48 Recent advances in diagnostic techniques in FTD, particularly neuroimaging, have enabled
49
50 earlier and more accurate visual detection of FTD. There have also been significant
51
52 improvements in recent understanding of the various patterns of atrophy across subtypes of
53
54 sporadic and familial FTD. However, it is still difficult to categorize some patients clinically
55
56 into which subtype of FTD they have, despite use of recently revised diagnostic criteria
57
58 (Gorno-Tempini et al. 2011, Rascovsky et al. 2011). The key purpose of such precise clinical
59
60

1
2
3 subtyping (particularly in patients with sporadic FTD) is to predict underlying pathology and
4 hence target future treatments appropriately. This is also necessary to enable accurate
5 advice about disease course, predicted survival and awareness of possible new symptoms
6 or diseases (for example orofacial apraxia and dysphagia in nfvPPA and risk of
7 parkinsonism in FTD with *MAPT* mutations). A practical problem also arises in patients with
8 overlap syndromes such as FTD-MND or PSPS-nfvPPA. The increasing sub-specialisation
9 of neurologists, particularly in tertiary centers, means that although patients get expert care
10 for each aspect of their disease, they end up with multiple appointments with more than one
11 specialist (cognitive, motor nerve and movement disorder). It is not clear which model of
12 care is best. Should there be multidisciplinary clinics with experts from each FTD-associated
13 syndrome present? These questions about best pathways for care and patient preference
14 need addressing in future research.
15
16
17
18
19
20
21
22
23
24
25
26
27
28

29 Assessing disease severity and stage in FTD is important for guiding patient selection for
30 inclusion in future clinical trials and for sensitive assessment of response to treatments in
31 trials and in practice. Predicting disease onset and progression accurately is vital for
32 advising patients and their relatives about prognosis, and for advising presymptomatic
33 individuals who possess FTD-associated gene mutations when they are likely to develop
34 symptoms. However, how best to assess disease severity is currently unclear: should it be
35 through scores on neuropsychological batteries, impairment on functional rating scales, use
36 of dementia staging scales currently available for use in AD, duration of symptoms, or a
37 combination of these? At present, clinicians are unable to provide reliable information to
38 patients about how quickly their symptoms will progress, when they will lose specific
39 functions and when they might develop new behavioural, language or motor changes. In
40 practice, clinicians often tend to advise that the disease is likely to continue to progress at
41 the previous rate of symptom progression seen in that patient so far, but this is rather non-
42 specific, and not all patients will develop all features of their disease phenotype. This makes
43 planning for the future very difficult and this uncertainty is likely to have a significant
44
45
46
47
48
49
50
51
52
53
54
55
56
57
58
59
60

1
2
3 psychological (and potentially financial) impact on patients, their carers and genetically at-
4 risk relatives. If we were able to predict these milestones more accurately, this would allow
5 appropriate and practical advanced decisions to be made about care and finances and
6
7
8
9 timely introduction of currently available management strategies, such as alternative (non-
10 oral) methods of communication.
11
12
13

14 15 16 **Dilemmas in familial FTD**

17
18 Several specific challenges remain for clinicians managing patients with familial FTD and
19 their relatives, and future work should be directed towards addressing these. The first
20 challenge is to be able to detect presence of disease well before the onset of symptoms and
21 before significant atrophy is evident on neuroimaging, and in particular to understand the
22 nature and timing of the series of changes that occur. This would enable us to predict more
23 accurately when presymptomatic gene carriers will develop clinically relevant symptoms,
24 intervene before this with timely treatment, and monitor for response or progression over
25 time. It will also inform families with mutations like the *C9ORF72* expansion, which have
26 highly variable clinical features, age at onset and penetrance, about which individuals will
27 develop symptoms, which symptoms are likely and at what age these may start. This will
28 allow better genetic counselling of 'at-risk' relatives of patients with familial FTD who might
29 wish to pursue genetic testing, and useful advice for individuals who test positive for a gene
30 mutation but are currently presymptomatic, about what lies ahead of them. In particular,
31 even before successful treatments are developed, better knowledge about disease risk and
32 likelihood of familial disease may encourage more individuals at risk to opt for pre-
33 implantation genetic diagnosis, to reduce transmission of the gene mutation in successive
34 generations. Greater awareness of the risk of familial disease within these syndromes is
35 also needed across the spectrum of clinicians managing patients with FTD and MND,
36 particularly for non-specialists who may feel that the absence of a family history precludes
37 genetic risk. As the spectrum of neurodegenerative genes widens, there is an urgent need
38
39
40
41
42
43
44
45
46
47
48
49
50
51
52
53
54
55
56
57
58
59
60

1
2
3 for production of comprehensive and regularly updated guidelines for clinicians managing
4 patients with potentially familial diseases, and for greater public awareness of these
5 conditions.
6
7

8
9
10
11 The second challenge is to understand why individuals with the same gene mutation develop
12 either FTD, or MND, or both, and why some develop additional features such as
13 parkinsonism or psychosis. If we understood this, it could elucidate the networks or
14 pathways involved in pathogenesis of familial FTD, sporadic FTD and neurodegeneration in
15 general.
16
17
18
19

20
21
22
23 Finally, we should use familial FTD as a paradigm (due to a relatively good link between
24 typical pathology and underlying gene mutation) for clinicopathological study to clarify the
25 complex pathological heterogeneity of FTLN and understand how this leads to various
26 phenotypes of clinical disease. We need to be able to correlate histopathology with disease
27 course and other biomarkers of FTD so we can be more certain that any future biomarkers
28 used for disease detection, monitoring or categorization in life are associated with the actual
29 pathology leading to disease. This may also enable translation of biomarkers identified in
30 familial disease for use in individuals with sporadic FTD, whose pathology and clinical
31 presentations remain even more complex and heterogeneous than in familial FTD. All of
32 these avenues of research will be easier to pursue through collaborative studies of large
33 cohorts of patients and presymptomatic individuals with familial FTD gene mutations, who
34 undergo detailed phenotyping in a structured and homogeneous manner over time, such as
35 within GENFI (Rohrer et al. 2015b).
36
37
38
39
40
41
42
43
44
45
46
47
48
49

50
51
52 In summary, we have made huge progress in recent years in understanding the clinical
53 heterogeneity of FTD and how it relates to its underlying molecular cause but there are still a
54 number of challenges ahead for the field. As the focus of FTD research switches to the
55 development of disease-modifying therapy and trials of such treatments, it will be important
56
57
58
59
60

not to forget that the study of how to improve the day-to-day care of symptomatic FTD patients, including finding better symptomatic medications, will need to remain a major research target.

References

- Ahmed, R. M., Iodice, V., Daveson, N., Kiernan, M. C., Piguet, O. and Hodges, J. R. (2015) Autonomic dysregulation in frontotemporal dementia. *J. Neurol. Neurosurg. Psychiatry*, **86**, 1048-1049.
- Ahmed, S., de Jager, C. A., Haigh, A. M. and Garrard, P. (2012) Logopenic aphasia in Alzheimer's disease: clinical variant or clinical feature? *J. Neurol. Neurosurg. Psychiatry*, **83**, 1056-1062.
- Alzheimer, A. (1911) Über eigenartige Krankheitsfälle des späteren Alters. *Zeitschrift für die gesamte Neurologie und Psychiatrie*, **4**, 356-385.
- Arighi, A., Fumagalli, G. G., Jacini, F. et al. (2012) Early onset behavioral variant frontotemporal dementia due to the C9ORF72 hexanucleotide repeat expansion: psychiatric clinical presentations. *J. Alzheimers Dis.*, **31**, 447-452.
- Assal, F., Laganaro, M., Remund, C. D. and Ragno Paquier, C. (2012) Progressive crossed-apraxia of speech as a first manifestation of a probable corticobasal degeneration. *Behav. Neurol.*, **25**, 285-289.
- Baborie, A., Griffiths, T. D., Jaros, E. et al. (2011) Pathological correlates of frontotemporal lobar degeneration in the elderly. *Acta Neuropathol.*, **121**, 365-371.
- Baker, M., Mackenzie, I. R., Pickering-Brown, S. M. et al. (2006) Mutations in progranulin cause tau-negative frontotemporal dementia linked to chromosome 17. *Nature*, **442**, 916-919.
- Balasa, M., Gelpi, E., Martin, I. et al. (2015) Diagnostic accuracy of behavioral variant frontotemporal dementia consortium criteria (FTDC) in a clinicopathological cohort. *Neuropathol. Appl. Neurobiol.*, **41**, 882-892.
- Bannwarth, S., Ait-El-Mkadem, S., Chausseot, A. et al. (2014) A mitochondrial origin for frontotemporal dementia and amyotrophic lateral sclerosis through CHCHD10 involvement. *Brain*, **137**, 2329-2345.
- Barquero, S., Gomez-Tortosa, E., Baron, M., Rabano, A., Munoz, D. G. and Jimenez-Escrig, A. (2010) Amusia as an early manifestation of frontotemporal dementia caused by a novel progranulin mutation. *J. Neurol.*, **257**, 475-477.
- Bateman, R. J., Xiong, C., Benzinger, T. L. et al. (2012) Clinical and biomarker changes in dominantly inherited Alzheimer's disease. *N. Engl. J. Med.*, **367**, 795-804.
- Bathgate, D., Snowden, J. S., Varma, A., Blackshaw, A. and Neary, D. (2001) Behaviour in frontotemporal dementia, Alzheimer's disease and vascular dementia. *Acta Neurol. Scand.*, **103**, 367-378.
- Baxter, D. M. and Warrington, E. K. (1987) Transcoding sound to spelling: single or multiple sound unit correspondence? *Cortex*, **23**, 11-28.

- 1
2
3 Beck, J., Poulter, M., Hensman, D. et al. (2013) Large C9orf72 hexanucleotide repeat
4 expansions are seen in multiple neurodegenerative syndromes and are more
5 frequent than expected in the UK population. *Am. J. Hum. Genet.*, **92**, 345-353.
- 6
7 Beck, J., Rohrer, J. D., Campbell, T. et al. (2008) A distinct clinical, neuropsychological
8 and radiological phenotype is associated with progranulin gene mutations in a
9 large UK series. *Brain*, **131**, 706-720.
- 10 Benajiba, L., Le Ber, I., Camuzat, A. et al. (2009) TARDBP mutations in motoneuron
11 disease with frontotemporal lobar degeneration. *Ann. Neurol.*, **65**, 470-473.
- 12 Benatar, M., Wu, J., Fernandez, C., Weihl, C. C., Katzen, H., Steele, J., Oskarsson, B. and
13 Taylor, J. P. (2013) Motor neuron involvement in multisystem proteinopathy:
14 implications for ALS. *Neurology*, **80**, 1874-1880.
- 15 Benitez, B. A., Cooper, B., Pastor, P., Jin, S. C., Lorenzo, E., Cervantes, S. and Cruchaga, C.
16 (2013) TREM2 is associated with the risk of Alzheimer's disease in Spanish
17 population. *Neurobiol. Aging*, **34**, 1711 e1715-1717.
- 18 Benussi, A., Padovani, A. and Borroni, B. (2015) Phenotypic Heterogeneity of Monogenic
19 Frontotemporal Dementia. *Front. Aging Neurosci.*, **7**, 171.
- 20 Bessi, V., Bagnoli, S., Nacmias, B., Tedde, A., Sorbi, S. and Bracco, L. (2010) Semantic
21 dementia associated with mutation V363I in the tau gene. *J. Neurol. Sci.*, **296**,
22 112-114.
- 23
24 Blair, I. P., Williams, K. L., Warraich, S. T. et al. (2010) FUS mutations in amyotrophic
25 lateral sclerosis: clinical, pathological, neurophysiological and genetic analysis. *J.*
26 *Neurol. Neurosurg. Psychiatry*, **81**, 639-645.
- 27 Boeve, B. F., Boylan, K. B., Graff-Radford, N. R. et al. (2012) Characterization of
28 frontotemporal dementia and/or amyotrophic lateral sclerosis associated with
29 the GGGGCC repeat expansion in C9ORF72. *Brain*, **135**, 765-783.
- 30 Borroni, B., Bonvicini, C., Alberici, A. et al. (2009) Mutation within TARDBP leads to
31 frontotemporal dementia without motor neuron disease. *Hum. Mutat.*, **30**, E974-
32 983.
- 33 Borroni, B., Ferrari, F., Galimberti, D. et al. (2014) Heterozygous TREM2 mutations in
34 frontotemporal dementia. *Neurobiol. Aging*, **35**, 934 e937-910.
- 35 Bozeat, S., Lambon Ralph, M. A., Patterson, K., Garrard, P. and Hodges, J. R. (2000) Non-
36 verbal semantic impairment in semantic dementia. *Neuropsychologia*, **38**, 1207-
37 1215.
- 38 Brambati, S. M., Rankin, K. P., Narvid, J., Seeley, W. W., Dean, D., Rosen, H. J., Miller, B. L.,
39 Ashburner, J. and Gorno-Tempini, M. L. (2009) Atrophy progression in semantic
40 dementia with asymmetric temporal involvement: a tensor-based morphometry
41 study. *Neurobiol. Aging*, **30**, 103-111.
- 42 Brodtmann, A., Cowie, T., McLean, C. and Darby, D. (2013) Phenocopy or variant: a
43 longitudinal study of very slowly progressive frontotemporal dementia. *BMJ Case*
44 *Rep.*, **2013**.
- 45 Broustal, O., Camuzat, A., Guillot-Noel, L. et al. (2010) FUS mutations in frontotemporal
46 lobar degeneration with amyotrophic lateral sclerosis. *J. Alzheimers Dis.*, **22**, 765-
47 769.
- 48 Brun, A. (1987) Frontal lobe degeneration of non-Alzheimer type. I. Neuropathology.
49 *Arch. Gerontol. Geriatr.*, **6**, 193-208.
- 50 Burrell, J. R., Kiernan, M. C., Vucic, S. and Hodges, J. R. (2011) Motor neuron dysfunction
51 in frontotemporal dementia. *Brain*, **134**, 2582-2594.
- 52
53
54
55
56
57
58
59
60

- 1
2
3 Cacace, R., Van Cauwenberghe, C., Bettens, K. et al. (2013) C9orf72 G4C2 repeat
4 expansions in Alzheimer's disease and mild cognitive impairment. *Neurobiol.*
5 *Aging*, **34**, 1712 e1711-1717.
6
7 Calvo, A., Moglia, C., Canosa, A. et al. (2012) Amyotrophic lateral
8 sclerosis/frontotemporal dementia with predominant manifestations of
9 obsessive-compulsive disorder associated to GGGGCC expansion of the c9orf72
10 gene. *J. Neurol.*, **259**, 2723-2725.
11
12 Carecchio, M., Fenoglio, C., De Riz, M. et al. (2009) Progranulin plasma levels as potential
13 biomarker for the identification of GRN deletion carriers. A case with atypical
14 onset as clinical amnesic Mild Cognitive Impairment converted to Alzheimer's
15 disease. *J. Neurol. Sci.*, **287**, 291-293.
16
17 Carlino, E., Benedetti, F., Rainero, I., Asteggiano, G., Cappa, G., Tarenzi, L., Vighetti, S. and
18 Pollo, A. (2010) Pain perception and tolerance in patients with frontotemporal
19 dementia. *Pain*, **151**, 783-789.
20
21 Cerami, C., Marcone, A., Galimberti, D., Zamboni, M., Fenoglio, C., Serpente, M., Scarpini,
22 E. and Cappa, S. F. (2013) Novel evidence of phenotypical variability in the
23 hexanucleotide repeat expansion in chromosome 9. *J. Alzheimers Dis.*, **35**, 455-
24 462.
25
26 Chan, D., Anderson, V., Pijnenburg, Y. et al. (2009) The clinical profile of right temporal
27 lobe atrophy. *Brain*, **132**, 1287-1298.
28
29 Chan, N., Le, C., Shieh, P., Mozaffar, T., Khare, M., Bronstein, J. and Kimonis, V. (2012)
30 Valosin-containing protein mutation and Parkinson's disease. *Parkinsonism*
31 *Relat. Disord.*, **18**, 107-109.
32
33 Chare, L., Hodges, J. R., Leyton, C. E., McGinley, C., Tan, R. H., Kril, J. J. and Halliday, G. M.
34 (2014) New criteria for frontotemporal dementia syndromes: clinical and
35 pathological diagnostic implications. *J. Neurol. Neurosurg. Psychiatry*, **85**, 865-
36 870.
37
38 Chen-Plotkin, A. S., Martinez-Lage, M., Sleiman, P. M. et al. (2011) Genetic and clinical
39 features of progranulin-associated frontotemporal lobar degeneration. *Arch.*
40 *Neurol.*, **68**, 488-497.
41
42 Chen, Y., Zheng, Z. Z., Chen, X., Huang, R., Yang, Y., Yuan, L., Pan, L., Hadano, S. and Shang,
43 H. F. (2014) SQSTM1 mutations in Han Chinese populations with sporadic
44 amyotrophic lateral sclerosis. *Neurobiol. Aging*, **35**, 726 e727-729.
45
46 Chio, A., Calvo, A., Moglia, C. et al. (2010) Amyotrophic lateral sclerosis-frontotemporal
47 lobar dementia in 3 families with p.Ala382Thr TARDBP mutations. *Arch. Neurol.*,
48 **67**, 1002-1009.
49
50 Chouery, E., Delague, V., Bergougnoux, A., Koussa, S., Serre, J. L. and Megarbane, A.
51 (2008) Mutations in TREM2 lead to pure early-onset dementia without bone
52 cysts. *Hum. Mutat.*, **29**, E194-204.
53
54 Cipelotti, L. and Maguire, E. A. (2003) A combined neuropsychological and
55 neuroimaging study of topographical and non-verbal memory in semantic
56 dementia. *Neuropsychologia*, **41**, 1148-1159.
57
58 Cirulli, E. T., Lasseigne, B. N., Petrovski, S. et al. (2015) Exome sequencing in
59 amyotrophic lateral sclerosis identifies risk genes and pathways. *Science*, **347**,
60 1436-1441.
61
62 Clerc, M. T., Deprez, M., Leuba, G., Lhermitte, B., Lopez, U. and von Gunten, A. (2013)
63 Atypical association of semantic dementia, corticobasal syndrome, and 4R
64 tauopathy. *Neurocase*, **21**, 1-15.

- 1
2
3 Coccia, M., Bartolini, M., Luzzi, S., Provinciali, L. and Ralph, M. A. (2004) Semantic
4 memory is an amodal, dynamic system: Evidence from the interaction of naming
5 and object use in semantic dementia. *Cogn. Neuropsychol.*, **21**, 513-527.
- 6 Coon, E. A., Sorenson, E. J., Whitwell, J. L., Knopman, D. S. and Josephs, K. A. (2011)
7 Predicting survival in frontotemporal dementia with motor neuron disease.
8 *Neurology*, **76**, 1886-1893.
- 9 Coon, E. A., Whitwell, J. L., Parisi, J. E., Dickson, D. W. and Josephs, K. A. (2012) Right
10 temporal variant frontotemporal dementia with motor neuron disease. *J. Clin.*
11 *Neurosci.*, **19**, 85-91.
- 12 Cooper-Knock, J., Frolov, A., Highley, J. R. et al. (2013) C9ORF72 expansions,
13 parkinsonism, and Parkinson disease: a clinicopathologic study. *Neurology*, **81**,
14 808-811.
- 15 Cooper-Knock, J., Hewitt, C., Highley, J. R. et al. (2012) Clinico-pathological features in
16 amyotrophic lateral sclerosis with expansions in C9ORF72. *Brain*, **135**, 751-764.
- 17 Corcia, P., Vourc'h, P., Guennoc, A. M., Del Mar Amador, M., Blasco, H., Andres, C.,
18 Couratier, P., Gordon, P. H. and Meininger, V. (2015) Pure cerebellar ataxia linked
19 to large C9orf72 repeat expansion. *Amyotrophic lateral sclerosis & frontotemporal*
20 *degeneration*, 1-3.
- 21 Cox, L. E., Ferraiuolo, L., Goodall, E. F. et al. (2010) Mutations in CHMP2B in lower motor
22 neuron predominant amyotrophic lateral sclerosis (ALS). *PLoS One*, **5**, e9872.
- 23 Cruchaga, C., Graff, C., Chiang, H. H. et al. (2011) Association of TMEM106B gene
24 polymorphism with age at onset in granulin mutation carriers and plasma
25 granulin protein levels. *Arch. Neurol.*, **68**, 581-586.
- 26 Cruts, M., Gijssels, I., van der Zee, J. et al. (2006) Null mutations in progranulin cause
27 ubiquitin-positive frontotemporal dementia linked to chromosome 17q21.
28 *Nature*, **442**, 920-924.
- 29 Cruts, M., Theuns, J. and Van Broeckhoven, C. (2012) Locus-specific mutation databases
30 for neurodegenerative brain diseases. *Hum. Mutat.*, **33**, 1340-1344.
- 31 Cuyvers, E., Bettens, K., Philtjens, S. et al. (2014) Investigating the role of rare
32 heterozygous TREM2 variants in Alzheimer's disease and frontotemporal
33 dementia. *Neurobiol. Aging*, **35**, 726 e711-729.
- 34 Davies, R. R., Kipps, C. M., Mitchell, J., Kril, J. J., Halliday, G. M. and Hodges, J. R. (2006)
35 Progression in frontotemporal dementia: identifying a benign behavioral variant
36 by magnetic resonance imaging. *Arch. Neurol.*, **63**, 1627-1631.
- 37 DeJesus-Hernandez, M., Mackenzie, I. R., Boeve, B. F. et al. (2011) Expanded GGGGCC
38 hexanucleotide repeat in noncoding region of C9ORF72 causes chromosome 9p-
39 linked FTD and ALS. *Neuron*, **72**, 245-256.
- 40 Deng, H. X., Chen, W., Hong, S. T. et al. (2011) Mutations in UBQLN2 cause dominant X-
41 linked juvenile and adult-onset ALS and ALS/dementia. *Nature*, **477**, 211-215.
- 42 Devenney, E., Hornberger, M., Irish, M., Mioshi, E., Burrell, J., Tan, R., Kiernan, M. C. and
43 Hodges, J. R. (2014) Frontotemporal dementia associated with the C9ORF72
44 mutation: a unique clinical profile. *JAMA neurology*, **71**, 331-339.
- 45 Devenney, E., Vucic, S., Hodges, J. R. and Kiernan, M. C. (2015) Motor neuron disease-
46 frontotemporal dementia: a clinical continuum. *Expert Rev. Neurother.*, **15**, 509-
47 522.
- 48 Di Fabio, R., Tessa, A., Simons, E. J., Santorelli, F. M., Casali, C., Serrao, M., Pierelli, F. and
49 Bonifati, V. (2010) Familial frontotemporal dementia with parkinsonism
50 associated with the progranulin c.C1021T (p.Q341X) mutation. *Parkinsonism*
51 *Relat. Disord.*, **16**, 484-485.
- 52
53
54
55
56
57
58
59
60

- 1
2
3 Di Fonzo, A., Ronchi, D., Gallia, F. et al. (2014) Lower motor neuron disease with
4 respiratory failure caused by a novel MAPT mutation. *Neurology*, **82**, 1990-1998.
- 5 Dobson-Stone, C., Hallupp, M., Bartley, L., Shepherd, C. E., Halliday, G. M., Schofield, P. R.,
6 Hodges, J. R. and Kwok, J. B. (2012) C9ORF72 repeat expansion in clinical and
7 neuropathologic frontotemporal dementia cohorts. *Neurology*, **79**, 995-1001.
- 8 Downey, L. E., Fletcher, P. D., Golden, H. L. et al. (2014) Altered body schema processing
9 in frontotemporal dementia with C9ORF72 mutations. *J. Neurol. Neurosurg.*
10 *Psychiatry*, **85**, 1016-1023.
- 11 Duffy, J. R. (2006) Apraxia of speech in degenerative neurologic disease. *Aphasiology*,
12 **20**, 511-527.
- 13 Edwards-Lee, T., Miller, B. L., Benson, D. F., Cummings, J. L., Russell, G. L., Boone, K. and
14 Mena, I. (1997) The temporal variant of frontotemporal dementia. *Brain*, **120** (
15 **Pt 6**), 1027-1040.
- 16 Englund, E., Gustafson, L., Passant, U., Majounie, E., Renton, A. E., Traynor, B. J., Rohrer, J.
17 D., Mok, K. and Hardy, J. (2012) Familial Lund frontotemporal dementia caused
18 by C9ORF72 hexanucleotide expansion. *Neurobiol. Aging*, **33**, 1850 e1813-1856.
- 19 Escourrolle, R. (1958) La maladie de Pick. *Etude critique d'ensemble et synthèse anatomo-*
20 *clinique. Paris: R. Foulon.*
- 21 Espay, A. J. and Litvan, I. (2011) Parkinsonism and frontotemporal dementia: the clinical
22 overlap. *J. Mol. Neurosci.*, **45**, 343-349.
- 23 Evans, J. J., Higgs, A. J., Antoun, N. and Hodges, J. R. (1995) Progressive prosopagnosia
24 associated with selective right temporal lobe atrophy. A new syndrome? *Brain*,
25 **118** (**Pt 1**), 1-13.
- 26 Fecto, F., Yan, J., Vemula, S. P. et al. (2011) SQSTM1 mutations in familial and sporadic
27 amyotrophic lateral sclerosis. *Arch. Neurol.*, **68**, 1440-1446.
- 28 Fernandez-Duque, D. and Black, S. E. (2005) Impaired recognition of negative facial
29 emotions in patients with frontotemporal dementia. *Neuropsychologia*, **43**, 1673-
30 1687.
- 31 Finch, N., Baker, M., Crook, R. et al. (2009) Plasma progranulin levels predict
32 progranulin mutation status in frontotemporal dementia patients and
33 asymptomatic family members. *Brain*, **132**, 583-591.
- 34 Finch, N., Carrasquillo, M. M., Baker, M. et al. (2011) TMEM106B regulates progranulin
35 levels and the penetrance of FTL in GRN mutation carriers. *Neurology*, **76**, 467-
36 474.
- 37 Fletcher, P. D., Downey, L. E., Golden, H. L. et al. (2015) Pain and temperature processing
38 in dementia: a clinical and neuroanatomical analysis. *Brain*, **138**, 3360-3372.
- 39 Fletcher, P. D., Downey, L. E., Witoonpanich, P. and Warren, J. D. (2013) The brain basis
40 of musicophilia: evidence from frontotemporal lobar degeneration. *Front.*
41 *Psychol.*, **4**, 347.
- 42 Fletcher, P. D. and Warren, J. D. (2011) Semantic dementia: a specific network-opathy. *J.*
43 *Mol. Neurosci.*, **45**, 629-636.
- 44 Frattali, C., Duffy, J. R., Litvan, I., Patsalides, A. D. and Grafman, J. (2003) Yes/no reversals
45 as neurobehavioral sequela: a disorder of language, praxis, or inhibitory control?
46 *Eur. J. Neurol.*, **10**, 103-106.
- 47 Freischmidt, A., Wieland, T., Richter, B. et al. (2015) Haploinsufficiency of TBK1 causes
48 familial ALS and fronto-temporal dementia. *Nat. Neurosci.*, **18**, 631-636.
- 49 Gainotti, G., Barbier, A. and Marra, C. (2003) Slowly progressive defect in recognition of
50 familiar people in a patient with right anterior temporal atrophy. *Brain*, **126**,
51 792-803.
- 52
53
54
55
56
57
58
59
60

- 1
2
3 Galimberti, D., Fenoglio, C., Serpente, M. et al. (2013) Autosomal dominant
4 frontotemporal lobar degeneration due to the C9ORF72 hexanucleotide repeat
5 expansion: late-onset psychotic clinical presentation. *Biol. Psychiatry*, **74**, 384-
6 391.
- 7 Galimberti, D., Reif, A., Dell'osso, B. et al. (2014a) C9ORF72 hexanucleotide repeat
8 expansion is a rare cause of schizophrenia. *Neurobiol. Aging*, **35**, 1214 e1217-
9 1214 e1210.
- 10 Galimberti, D., Reif, A., Dell'Osso, B. et al. (2014b) C9ORF72 hexanucleotide repeat
11 expansion as a rare cause of bipolar disorder. *Bipolar disorders*, **16**, 448-449.
- 12 Gallagher, M. D., Suh, E., Grossman, M. et al. (2014) TMEM106B is a genetic modifier of
13 frontotemporal lobar degeneration with C9orf72 hexanucleotide repeat
14 expansions. *Acta Neuropathol.*, **127**, 407-418.
- 15 Gans, A. (1925) De Ziekten van Pick en van Alzheimer. *Ned. Tijdschr. Geneesk.*, **68**,
16 1953.
- 17 Gass, J., Cannon, A., Mackenzie, I. R. et al. (2006) Mutations in progranulin are a major
18 cause of ubiquitin-positive frontotemporal lobar degeneration. *Hum. Mol. Genet.*,
19 **15**, 2988-3001.
- 20 Gellera, C., Tiloca, C., Del Bo, R. et al. (2013) Ubiquilin 2 mutations in Italian patients
21 with amyotrophic lateral sclerosis and frontotemporal dementia. *J. Neurol.*
22 *Neurosurg. Psychiatry*, **84**, 183-187.
- 23 Gelpi, E., van der Zee, J., Turon Estrada, A., Van Broeckhoven, C. and Sanchez-Valle, R.
24 (2014) TARDBP mutation p.Ile383Val associated with semantic dementia and
25 complex proteinopathy. *Neuropathol. Appl. Neurobiol.*, **40**, 225-230.
- 26 Gennari, L., Gianfrancesco, F., Di Stefano, M. et al. (2010) SQSTM1 gene analysis and
27 gene-environment interaction in Paget's disease of bone. *J. Bone Miner. Res.*, **25**,
28 1375-1384.
- 29 Gijssels, I., Van Mossevelde, S., van der Zee, J. et al. (2015) Loss of TBK1 is a frequent
30 cause of frontotemporal dementia in a Belgian cohort. *Neurology*, **85**, 2116-2125.
- 31 Giraldo, M., Lopera, F., Siniard, A. L. et al. (2013) Variants in triggering receptor
32 expressed on myeloid cells 2 are associated with both behavioral variant
33 frontotemporal lobar degeneration and Alzheimer's disease. *Neurobiol. Aging*,
34 **34**, 2077 e2011-2078.
- 35 Gitcho, M. A., Bigio, E. H., Mishra, M. et al. (2009) TARDBP 3'-UTR variant in autopsy-
36 confirmed frontotemporal lobar degeneration with TDP-43 proteinopathy. *Acta*
37 *Neuropathol.*, **118**, 633-645.
- 38 Goldman, J. S., Farmer, J. M., Wood, E. M. et al. (2005) Comparison of family histories in
39 FTLD subtypes and related tauopathies. *Neurology*, **65**, 1817-1819.
- 40 Goldman, J. S., Quinzii, C., Dunning-Broadbent, J. et al. (2014) Multiple system atrophy
41 and amyotrophic lateral sclerosis in a family with hexanucleotide repeat
42 expansions in C9orf72. *JAMA neurology*, **71**, 771-774.
- 43 Goll, J. C., Crutch, S. J., Loo, J. H., Rohrer, J. D., Frost, C., Bamiou, D. E. and Warren, J. D.
44 (2010) Non-verbal sound processing in the primary progressive aphasia. *Brain*,
45 **133**, 272-285.
- 46 Gomez-Tortosa, E., Serrano, S., de Toledo, M., Perez-Perez, J. and Sainz, M. J. (2014)
47 Familial benign frontotemporal deterioration with C9ORF72 hexanucleotide
48 expansion. *Alzheimer's & dementia : the journal of the Alzheimer's Association*, **10**,
49 S284-289.
- 50
51
52
53
54
55
56
57
58
59
60

- 1
2
3 Gordon, E., Rohrer, J. D., Kim, L. G., Omar, R., Rossor, M. N., Fox, N. C. and Warren, J. D.
4 (2010) Measuring disease progression in frontotemporal lobar degeneration: a
5 clinical and MRI study. *Neurology*, **74**, 666-673.
- 6 Gorno-Tempini, M. L., Brambati, S. M., Ginex, V. et al. (2008) The logopenic/phonological
7 variant of primary progressive aphasia. *Neurology*, **71**, 1227-1234.
- 8 Gorno-Tempini, M. L., Dronkers, N. F., Rankin, K. P., Ogar, J. M., Phengrasamy, L., Rosen,
9 H. J., Johnson, J. K., Weiner, M. W. and Miller, B. L. (2004) Cognition and anatomy
10 in three variants of primary progressive aphasia. *Ann. Neurol.*, **55**, 335-346.
- 11 Gorno-Tempini, M. L., Hillis, A. E., Weintraub, S. et al. (2011) Classification of primary
12 progressive aphasia and its variants. *Neurology*, **76**, 1006-1014.
- 13 Gorno-Tempini, M. L., Ogar, J. M., Brambati, S. M., Wang, P., Jeong, J. H., Rankin, K. P.,
14 Dronkers, N. F. and Miller, B. L. (2006) Anatomical correlates of early mutism in
15 progressive nonfluent aphasia. *Neurology*, **67**, 1849-1851.
- 16 Graham, A., Davies, R., Xuereb, J., Halliday, G., Kril, J., Creasey, H., Graham, K. and Hodges,
17 J. (2005) Pathologically proven frontotemporal dementia presenting with severe
18 amnesia. *Brain*, **128**, 597-605.
- 19 Graham, N. L., Bak, T., Patterson, K. and Hodges, J. R. (2003) Language function and
20 dysfunction in corticobasal degeneration. *Neurology*, **61**, 493-499.
- 21 Grossman, M. and Moore, P. (2005) A longitudinal study of sentence comprehension
22 difficulty in primary progressive aphasia. *J. Neurol. Neurosurg. Psychiatry*, **76**,
23 644-649.
- 24 Guerreiro, R., Bilgic, B., Guven, G., Bras, J., Rohrer, J., Lohmann, E., Hanagasi, H., Gurvit, H.
25 and Emre, M. (2013a) Novel compound heterozygous mutation in TREM2 found
26 in a Turkish frontotemporal dementia-like family. *Neurobiol. Aging*, **34**, 2890
27 e2891-2895.
- 28 Guerreiro, R., Wojtas, A., Bras, J. et al. (2013b) TREM2 variants in Alzheimer's disease. *N.*
29 *Engl. J. Med.*, **368**, 117-127.
- 30 Guerreiro, R. J., Lohmann, E., Bras, J. M. et al. (2013c) Using exome sequencing to reveal
31 mutations in TREM2 presenting as a frontotemporal dementia-like syndrome
32 without bone involvement. *JAMA neurology*, **70**, 78-84.
- 33 Gydesen, S., Brown, J. M., Brun, A. et al. (2002) Chromosome 3 linked frontotemporal
34 dementia (FTD-3). *Neurology*, **59**, 1585-1594.
- 35 Harris, J. M., Gall, C., Thompson, J. C. et al. (2013a) Classification and pathology of
36 primary progressive aphasia. *Neurology*, **81**, 1832-1839.
- 37 Harris, J. M., Gall, C., Thompson, J. C. et al. (2013b) Sensitivity and specificity of FTDC
38 criteria for behavioral variant frontotemporal dementia. *Neurology*, **80**, 1881-
39 1887.
- 40 Hensman Moss, D. J., Poulter, M., Beck, J. et al. (2014) C9orf72 expansions are the most
41 common genetic cause of Huntington disease phenocopies. *Neurology*, **82**, 292-
42 299.
- 43 Hirano, M., Nakamura, Y., Saigoh, K., Sakamoto, H., Ueno, S., Isono, C., Mitsui, Y. and
44 Kusunoki, S. (2015) VCP gene analyses in Japanese patients with sporadic
45 amyotrophic lateral sclerosis identify a new mutation. *Neurobiol. Aging*, **36**, 1604
46 e1601-1606.
- 47 Hodges, J. R., Davies, R. R., Xuereb, J. H., Casey, B., Broe, M., Bak, T. H., Kril, J. J. and
48 Halliday, G. M. (2004) Clinicopathological correlates in frontotemporal dementia.
49 *Ann. Neurol.*, **56**, 399-406.
- 50
51
52
53
54
55
56
57
58
59
60

- 1
2
3 Hodges, J. R., Mitchell, J., Dawson, K., Spillantini, M. G., Xuereb, J. H., McMonagle, P.,
4 Nestor, P. J. and Patterson, K. (2010) Semantic dementia: demography, familial
5 factors and survival in a consecutive series of 100 cases. *Brain*, **133**, 300-306.
- 6 Hodges, J. R. and Patterson, K. (2007) Semantic dementia: a unique clinicopathological
7 syndrome. *Lancet Neurol.*, **6**, 1004-1014.
- 8 Hodges, J. R., Patterson, K., Oxbury, S. and Funnell, E. (1992) Semantic dementia.
9 Progressive fluent aphasia with temporal lobe atrophy. *Brain*, **115 (Pt 6)**, 1783-
10 1806.
- 11 Holm, I. E., Isaacs, A. M. and Mackenzie, I. R. (2009) Absence of FUS-immunoreactive
12 pathology in frontotemporal dementia linked to chromosome 3 (FTD-3) caused
13 by mutation in the CHMP2B gene. *Acta Neuropathol.*, **118**, 719-720.
- 14 Hornberger, M., Piguet, O., Kipps, C. and Hodges, J. R. (2008) Executive function in
15 progressive and nonprogressive behavioral variant frontotemporal dementia.
16 *Neurology*, **71**, 1481-1488.
- 17 Hornberger, M., Shelley, B. P., Kipps, C. M., Piguet, O. and Hodges, J. R. (2009) Can
18 progressive and non-progressive behavioural variant frontotemporal dementia
19 be distinguished at presentation? *J. Neurol. Neurosurg. Psychiatry*, **80**, 591-593.
- 20 Hsieh, S., Hodges, J. R., Leyton, C. E. and Mioshi, E. (2012) Longitudinal changes in
21 primary progressive aphasias: differences in cognitive and dementia staging
22 measures. *Dement. Geriatr. Cogn. Disord.*, **34**, 135-141.
- 23 Hsiung, G. Y., DeJesus-Hernandez, M., Feldman, H. H. et al. (2012) Clinical and
24 pathological features of familial frontotemporal dementia caused by C9ORF72
25 mutation on chromosome 9p. *Brain*, **135**, 709-722.
- 26 Huey, E. D., Ferrari, R., Moreno, J. H. et al. (2012) FUS and TDP43 genetic variability in
27 FTD and CBS. *Neurobiol. Aging*, **33**, 1016 e1019-1017.
- 28 Hutton, M., Lendon, C. L., Rizzu, P. et al. (1998) Association of missense and 5'-splice-site
29 mutations in tau with the inherited dementia FTDP-17. *Nature*, **393**, 702-705.
- 30 Irish, M., Devenney, E., Wong, S., Dobson-Stone, C., Kwok, J. B., Piguet, O., Hodges, J. R.
31 and Hornberger, M. (2013) Neural substrates of episodic memory dysfunction in
32 behavioural variant frontotemporal dementia with and without C9ORF72
33 expansions. *NeuroImage. Clinical*, **2**, 836-843.
- 34 Ishizuka, T., Nakamura, M., Ichiba, M. and Sano, A. (2011) Familial semantic dementia
35 with P301L mutation in the Tau gene. *Dement. Geriatr. Cogn. Disord.*, **31**, 334-
36 340.
- 37 Johnson, J. K., Diehl, J., Mendez, M. F. et al. (2005) Frontotemporal lobar degeneration:
38 demographic characteristics of 353 patients. *Arch. Neurol.*, **62**, 925-930.
- 39 Jonsson, T., Stefansson, H., Steinberg, S. et al. (2013) Variant of TREM2 associated with
40 the risk of Alzheimer's disease. *N. Engl. J. Med.*, **368**, 107-116.
- 41 Josephs, K. A., Boeve, B. F., Duffy, J. R., Smith, G. E., Knopman, D. S., Parisi, J. E., Petersen,
42 R. C. and Dickson, D. W. (2005) Atypical progressive supranuclear palsy
43 underlying progressive apraxia of speech and nonfluent aphasia. *Neurocase*, **11**,
44 283-296.
- 45 Josephs, K. A. and Duffy, J. R. (2008) Apraxia of speech and nonfluent aphasia: a new
46 clinical marker for corticobasal degeneration and progressive supranuclear
47 palsy. *Curr. Opin. Neurol.*, **21**, 688-692.
- 48 Josephs, K. A., Duffy, J. R., Strand, E. A. et al. (2014) The evolution of primary progressive
49 apraxia of speech. *Brain*, **137**, 2783-2795.
- 50 Josephs, K. A., Duffy, J. R., Strand, E. A., Machulda, M. M., Senjem, M. L., Master, A. V.,
51 Lowe, V. J., Jack, C. R., Jr. and Whitwell, J. L. (2012) Characterizing a
52
53
54
55
56
57
58
59
60

- 1
2
3 neurodegenerative syndrome: primary progressive apraxia of speech. *Brain*,
4 **135**, 1522-1536.
- 5 Josephs, K. A., Duffy, J. R., Strand, E. A. et al. (2006) Clinicopathological and imaging
6 correlates of progressive aphasia and apraxia of speech. *Brain*, **129**, 1385-1398.
- 7 Josephs, K. A., Whitwell, J. L., Murray, M. E. et al. (2013) Corticospinal tract degeneration
8 associated with TDP-43 type C pathology and semantic dementia. *Brain*, **136**,
9 455-470.
- 10
11 Joubert, S., Felician, O., Barbeau, E., Ranjeva, J. P., Christophe, M., Didic, M., Poncet, M.
12 and Ceccaldi, M. (2006) The right temporal lobe variant of frontotemporal
13 dementia: cognitive and neuroanatomical profile of three patients. *J. Neurol.*,
14 **253**, 1447-1458.
- 15
16 Kabashi, E., Valdmanis, P. N., Dion, P. et al. (2008) TARDBP mutations in individuals with
17 sporadic and familial amyotrophic lateral sclerosis. *Nat. Genet.*, **40**, 572-574.
- 18 Kamminga, J., Kumfor, F., Burrell, J. R., Piguet, O., Hodges, J. R. and Irish, M. (2015)
19 Differentiating between right-lateralised semantic dementia and behavioural-
20 variant frontotemporal dementia: an examination of clinical characteristics and
21 emotion processing. *J. Neurol. Neurosurg. Psychiatry*, **86**, 1082-1088.
- 22 Kelley, B. J., Haidar, W., Boeve, B. F. et al. (2009) Prominent phenotypic variability
23 associated with mutations in Progranulin. *Neurobiol. Aging*, **30**, 739-751.
- 24 Kertesz, A., Ang, L. C., Jesso, S., MacKinley, J., Baker, M., Brown, P., Shoemith, C.,
25 Rademakers, R. and Finger, E. C. (2013) Psychosis and hallucinations in
26 frontotemporal dementia with the C9ORF72 mutation: a detailed clinical cohort.
27 *Cogn. Behav. Neurol.*, **26**, 146-154.
- 28
29 Kertesz, A., Davidson, W., McCabe, P., Takagi, K. and Munoz, D. (2003) Primary
30 progressive aphasia: diagnosis, varieties, evolution. *J. Int. Neuropsychol. Soc.*, **9**,
31 710-719.
- 32
33 Kertesz, A., McMonagle, P. and Jesso, S. (2011) Extrapyrmidal syndromes in
34 frontotemporal degeneration. *J. Mol. Neurosci.*, **45**, 336-342.
- 35 Khan, B. K., Yokoyama, J. S., Takada, L. T. et al. (2012) Atypical, slowly progressive
36 behavioural variant frontotemporal dementia associated with C9ORF72
37 hexanucleotide expansion. *J. Neurol. Neurosurg. Psychiatry*, **83**, 358-364.
- 38 Kim, E. J., Park, Y. E., Kim, D. S. et al. (2011) Inclusion body myopathy with Paget disease
39 of bone and frontotemporal dementia linked to VCP p.Arg155Cys in a Korean
40 family. *Arch. Neurol.*, **68**, 787-796.
- 41
42 Kipps, C. M., Hodges, J. R., Fryer, T. D. and Nestor, P. J. (2009a) Combined magnetic
43 resonance imaging and positron emission tomography brain imaging in
44 behavioural variant frontotemporal degeneration: refining the clinical
45 phenotype. *Brain*, **132**, 2566-2578.
- 46 Kipps, C. M., Nestor, P. J., Acosta-Cabronero, J., Arnold, R. and Hodges, J. R. (2009b)
47 Understanding social dysfunction in the behavioural variant of frontotemporal
48 dementia: the role of emotion and sarcasm processing. *Brain*, **132**, 592-603.
- 49 Kouri, N., Carlomagno, Y., Baker, M. et al. (2014) Novel mutation in MAPT exon 13
50 (p.N410H) causes corticobasal degeneration. *Acta Neuropathol.*, **127**, 271-282.
- 51 Kovacs, G. G., Murrell, J. R., Horvath, S., Haraszti, L., Majtenyi, K., Molnar, M. J., Budka, H.,
52 Ghetti, B. and Spina, S. (2009) TARDBP variation associated with frontotemporal
53 dementia, supranuclear gaze palsy, and chorea. *Mov. Disord.*, **24**, 1843-1847.
- 54
55 Kremen, S. A., Mendez, M. F., Tsai, P. H. and Teng, E. (2011) Extrapyrmidal signs in the
56 primary progressive aphasias. *Am. J. Alzheimers Dis. Other Demen.*, **26**, 72-77.
- 57
58
59
60

- 1
2
3 Kumfor, F. and Piguet, O. (2012) Disturbance of emotion processing in frontotemporal
4 dementia: a synthesis of cognitive and neuroimaging findings. *Neuropsychol. Rev.*,
5 **22**, 280-297.
- 6 Kwiatkowski, T. J., Jr., Bosco, D. A., Leclerc, A. L. et al. (2009) Mutations in the FUS/TLS
7 gene on chromosome 16 cause familial amyotrophic lateral sclerosis. *Science*,
8 **323**, 1205-1208.
- 9 Lanata, S. C. and Miller, B. L. (2015) The behavioural variant frontotemporal dementia
10 (bvFTD) syndrome in psychiatry. *J. Neurol. Neurosurg. Psychiatry*.
- 11 Lashley, T., Rohrer, J. D., Mahoney, C., Gordon, E., Beck, J., Mead, S., Warren, J., Rossor, M.
12 and Revesz, T. (2014) A pathogenic progranulin mutation and C9orf72 repeat
13 expansion in a family with frontotemporal dementia. *Neuropathol. Appl.*
14 *Neurobiol.*, **40**, 502-513.
- 15 Lashley, T., Rohrer, J. D., Mead, S. and Revesz, T. (2015) Review: an update on clinical,
16 genetic and pathological aspects of frontotemporal lobar degenerations.
17 *Neuropathol. Appl. Neurobiol.*, **41**, 858-881.
- 18 Lattante, S., Le Ber, I., Camuzat, A. et al. (2013) TREM2 mutations are rare in a French
19 cohort of patients with frontotemporal dementia. *Neurobiol. Aging*, **34**, 2443
20 e2441-2442.
- 21 Lavenu, I., Pasquier, F., Lebert, F., Petit, H. and Van der Linden, M. (1999) Perception of
22 emotion in frontotemporal dementia and Alzheimer disease. *Alzheimer Dis. Assoc.*
23 *Disord.*, **13**, 96-101.
- 24 Le Ber, I. (2013) Genetics of frontotemporal lobar degeneration: an up-date and
25 diagnosis algorithm. *Rev. Neurol. (Paris)*, **169**, 811-819.
- 26 Le Ber, I., Camuzat, A., Guerreiro, R. et al. (2013) SQSTM1 mutations in French patients
27 with frontotemporal dementia or frontotemporal dementia with amyotrophic
28 lateral sclerosis. *JAMA neurology*, **70**, 1403-1410.
- 29 Le Ber, I., Camuzat, A., Hannequin, D. et al. (2008) Phenotype variability in progranulin
30 mutation carriers: a clinical, neuropsychological, imaging and genetic study.
31 *Brain*, **131**, 732-746.
- 32 Le Ber, I., De Septenville, A., Guerreiro, R. et al. (2014) Homozygous TREM2 mutation in
33 a family with atypical frontotemporal dementia. *Neurobiol. Aging*, **35**, 2419
34 e2423-2415.
- 35 Le Ber, I., De Septenville, A., Millecamps, S. et al. (2015) TBK1 mutation frequencies in
36 French frontotemporal dementia and amyotrophic lateral sclerosis cohorts.
37 *Neurobiol. Aging*, **36**, 3116 e3115-3118.
- 38 Lesage, S., Le Ber, I., Condroyer, C. et al. (2013) C9orf72 repeat expansions are a rare
39 genetic cause of parkinsonism. *Brain*, **136**, 385-391.
- 40 Lill, C. M., Rengmark, A., Pihlstrom, L. et al. (2015) The role of TREM2 R47H as a risk
41 factor for Alzheimer's disease, frontotemporal lobar degeneration, amyotrophic
42 lateral sclerosis, and Parkinson's disease. *Alzheimer's & dementia : the journal of*
43 *the Alzheimer's Association*, **11**, 1407-1416.
- 44 Lindquist, S. G., Duno, M., Batbayli, M. et al. (2013) Corticobasal and ataxia syndromes
45 widen the spectrum of C9ORF72 hexanucleotide expansion disease. *Clin. Genet.*,
46 **83**, 279-283.
- 47 Lomen-Hoerth, C., Anderson, T. and Miller, B. (2002) The overlap of amyotrophic lateral
48 sclerosis and frontotemporal dementia. *Neurology*, **59**, 1077-1079.
- 49 Lough, S., Kipps, C. M., Treise, C., Watson, P., Blair, J. R. and Hodges, J. R. (2006) Social
50 reasoning, emotion and empathy in frontotemporal dementia. *Neuropsychologia*,
51 **44**, 950-958.
- 52
53
54
55
56
57
58
59
60

- 1
2
3 Lund and Manchester Groups (1994) Consensus Statement. Clinical and
4 neuropathological criteria for frontotemporal dementia. *J. Neurol. Neurosurg.*
5 *Psychiatry*, **57**, 416-418.
- 6
7 Mahoney, C. J., Beck, J., Rohrer, J. D. et al. (2012) Frontotemporal dementia with the
8 C9ORF72 hexanucleotide repeat expansion: clinical, neuroanatomical and
9 neuropathological features. *Brain*, **135**, 736-750.
- 10 Mahoney, C. J., Rohrer, J. D., Goll, J. C., Fox, N. C., Rossor, M. N. and Warren, J. D. (2011)
11 Structural neuroanatomy of tinnitus and hyperacusis in semantic dementia. *J.*
12 *Neurol. Neurosurg. Psychiatry*, **82**, 1274-1278.
- 13 Majounie, E., Renton, A. E., Mok, K. et al. (2012) Frequency of the C9orf72
14 hexanucleotide repeat expansion in patients with amyotrophic lateral sclerosis
15 and frontotemporal dementia: a cross-sectional study. *Lancet Neurol.*, **11**, 323-
16 330.
- 17
18 Mann, D., South, P., Snowden, J. and Neary, D. (1993) Dementia of frontal lobe type:
19 neuropathology and immunohistochemistry. *J. Neurol. Neurosurg. Psychiatry*, **56**,
20 605-614.
- 21 Marshall, C. R., Guerreiro, R., Thust, S., Fletcher, P., Rohrer, J. D. and Fox, N. C. (2015) A
22 Novel MAPT Mutation Causing Corticobasal Syndrome Led by Progressive
23 Apraxia of Speech. *J. Alzheimers Dis.*, **48**, 923-926.
- 24 Meisler, M. H., Grant, A. E., Jones, J. M. et al. (2013) C9ORF72 expansion in a family with
25 bipolar disorder. *Bipolar disorders*, **15**, 326-332.
- 26
27 Mesulam, M. (2013) Primary progressive aphasia: A dementia of the language network.
28 *Dementia & neuropsychologia*, **7**, 2-9.
- 29 Mesulam, M., Wieneke, C., Rogalski, E., Cobia, D., Thompson, C. and Weintraub, S. (2009)
30 Quantitative template for subtyping primary progressive aphasia. *Arch. Neurol.*,
31 **66**, 1545-1551.
- 32
33 Mesulam, M. M. (1982) Slowly progressive aphasia without generalized dementia. *Ann.*
34 *Neurol.*, **11**, 592-598.
- 35
36 Mesulam, M. M. (1987) Primary progressive aphasia--differentiation from Alzheimer's
37 disease. *Ann. Neurol.*, **22**, 533-534.
- 38
39 Mesulam, M. M. (2001) Primary progressive aphasia. *Ann. Neurol.*, **49**, 425-432.
- 40
41 Mesulam, M. M. (2003) Primary progressive aphasia--a language-based dementia. *N.*
42 *Engl. J. Med.*, **349**, 1535-1542.
- 43
44 Mesulam, M. M., Weintraub, S., Rogalski, E. J., Wieneke, C., Geula, C. and Bigio, E. H.
45 (2014) Asymmetry and heterogeneity of Alzheimer's and frontotemporal
46 pathology in primary progressive aphasia. *Brain*, **137**, 1176-1192.
- 47
48 Millicamps, S., Boillee, S., Le Ber, I. et al. (2012) Phenotype difference between ALS
49 patients with expanded repeats in C9ORF72 and patients with mutations in other
50 ALS-related genes. *J. Med. Genet.*, **49**, 258-263.
- 51
52 Miller, J. W., Smith, B. N., Topp, S. D., Al-Chalabi, A., Shaw, C. E. and Vance, C. (2012)
53 Mutation analysis of VCP in British familial and sporadic amyotrophic lateral
54 sclerosis patients. *Neurobiol. Aging*, **33**, 2721 e2721-2722.
- 55
56 Miller, L., Rollinson, S., Callister, J. B. et al. (2015) p62/SQSTM1 analysis in
57 frontotemporal lobar degeneration. *Neurobiol. Aging*, **36**, 1603 e1605-1609.
- 58
59 Mioshi, E. and Hodges, J. R. (2009) Rate of change of functional abilities in
60 frontotemporal dementia. *Dement. Geriatr. Cogn. Disord.*, **28**, 419-426.
- Momeni, P., DeTucci, K., Straub, R. E., Weinberger, D. R., Davies, P., Grafman, J., Hardy, J.
and Huey, E. D. (2010a) Progranulin (GRN) in two siblings of a Latino family and
in other patients with schizophrenia. *Neurocase*, **16**, 273-279.

- 1
2
3 Momeni, P., Wickremaratchi, M. M., Bell, J., Arnold, R., Beer, R., Hardy, J., Revesz, T., Neal,
4 J. W. and Morris, H. R. (2010b) Familial early onset frontotemporal dementia
5 caused by a novel S356T MAPT mutation, initially diagnosed as schizophrenia.
6 *Clin. Neurol. Neurosurg.*, **112**, 917-920.
- 7
8 Montuschi, A., Iazzolino, B., Calvo, A. et al. (2015) Cognitive correlates in amyotrophic
9 lateral sclerosis: a population-based study in Italy. *J. Neurol. Neurosurg.*
10 *Psychiatry*, **86**, 168-173.
- 11 Moreno, F., Rabinovici, G. D., Karydas, A. et al. (2015) A novel mutation P112H in the
12 TARDBP gene associated with frontotemporal lobar degeneration without motor
13 neuron disease and abundant neuritic amyloid plaques. *Acta neuropathologica*
14 *communications*, **3**, 19.
- 15 Mummery, C. J., Patterson, K., Price, C. J., Ashburner, J., Frackowiak, R. S. and Hodges, J. R.
16 (2000) A voxel-based morphometry study of semantic dementia: relationship
17 between temporal lobe atrophy and semantic memory. *Ann. Neurol.*, **47**, 36-45.
- 18 Mummery, C. J., Patterson, K., Wise, R. J., Vandenberghe, R., Price, C. J. and Hodges, J. R.
19 (1999) Disrupted temporal lobe connections in semantic dementia. *Brain*, **122** (
20 **Pt 1**), 61-73.
- 21
22 Munch, C., Rosenbohm, A., Sperfeld, A. D. et al. (2005) Heterozygous R1101K mutation
23 of the DCTN1 gene in a family with ALS and FTD. *Ann. Neurol.*, **58**, 777-780.
- 24 Munoz, D. G., Ros, R., Fatas, M., Bermejo, F. and de Yébenes, J. G. (2007) Progressive
25 nonfluent aphasia associated with a new mutation V363I in tau gene. *Am. J.*
26 *Alzheimers Dis. Other Demen.*, **22**, 294-299.
- 27
28 Neary, D., Snowden, J. and Mann, D. (2005) Frontotemporal dementia. *Lancet Neurol.*, **4**,
29 771-780.
- 30 Neary, D., Snowden, J. S., Gustafson, L. et al. (1998) Frontotemporal lobar degeneration:
31 a consensus on clinical diagnostic criteria. *Neurology*, **51**, 1546-1554.
- 32 Ng, A. S., Rademakers, R. and Miller, B. L. (2015) Frontotemporal dementia: a bridge
33 between dementia and neuromuscular disease. *Ann. N. Y. Acad. Sci.*, **1338**, 71-93.
- 34 O'Dowd, S., Curtin, D., Waite, A. J. et al. (2012) C9ORF72 expansion in amyotrophic
35 lateral sclerosis/frontotemporal dementia also causes parkinsonism. *Mov.*
36 *Disord.*, **27**, 1072-1074.
- 37
38 Onari, K. and Spatz, H. (1926) Anatomische beiträge zur lehre von der pickschen
39 umschriebenen grosshirnrinden-atrophie („picksche krankheit“). In: *Arbeiten*
40 *aus der Deutschen Forschungsanstalt für Psychiatrie in München (Kaiser-Wilhelm-*
41 *Institut)*, pp. 546-587. Springer.
- 42
43 Onyike, C. U. and Diehl-Schmid, J. (2013) The epidemiology of frontotemporal dementia.
44 *International review of psychiatry*, **25**, 130-137.
- 45 Origone, P., Verdiani, S., Ciotti, P., Gulli, R., Bellone, E., Marchese, R., Abbruzzese, G. and
46 Mandich, P. (2013) Enlarging the clinical spectrum associated with C9orf 72
47 repeat expansions: findings in an Italian cohort of patients with parkinsonian
48 syndromes and relevance for genetic counselling. *Amyotrophic lateral sclerosis &*
49 *frontotemporal degeneration*, **14**, 479-480.
- 50 Paloneva, J., Kestila, M., Wu, J. et al. (2000) Loss-of-function mutations in TYROBP
51 (DAP12) result in a presenile dementia with bone cysts. *Nat. Genet.*, **25**, 357-361.
- 52 Park, H. K. and Chung, S. J. (2013) New perspective on parkinsonism in frontotemporal
53 lobar degeneration. *Journal of movement disorders*, **6**, 1-8.
- 54 Parkinson, N., Ince, P. G., Smith, M. O. et al. (2006) ALS phenotypes with mutations in
55 CHMP2B (charged multivesicular body protein 2B). *Neurology*, **67**, 1074-1077.
- 56
57
58
59
60

- 1
2
3 Pick, A. (1892) Über die Beziehungen der senilen Hirnatrophie zur Aphasie. *Prager Med*
4 *Wochenschr*, **17**, 165-167.
- 5 Pickering-Brown, S. M., Rollinson, S., Du Plessis, D., Morrison, K. E., Varma, A.,
6 Richardson, A. M., Neary, D., Snowden, J. S. and Mann, D. M. (2008) Frequency
7 and clinical characteristics of progranulin mutation carriers in the Manchester
8 frontotemporal lobar degeneration cohort: comparison with patients with MAPT
9 and no known mutations. *Brain*, **131**, 721-731.
- 10 Piguet, O., Halliday, G. M., Creasey, H., Broe, G. A. and Kril, J. J. (2009) Frontotemporal
11 dementia and dementia with Lewy bodies in a case-control study of Alzheimer's
12 disease. *Int. Psychogeriatr.*, **21**, 688-695.
- 13 Piwnica-Worms, K. E., Omar, R., Hailstone, J. C. and Warren, J. D. (2010) Flavour
14 processing in semantic dementia. *Cortex*, **46**, 761-768.
- 15 Pottier, C., Bieniek, K. F., Finch, N. et al. (2015) Whole-genome sequencing reveals
16 important role for TBK1 and OPTN mutations in frontotemporal lobar
17 degeneration without motor neuron disease. *Acta Neuropathol.*, **130**, 77-92.
- 18 Pottier, C., Wallon, D., Rousseau, S., Rovelet-Lecrux, A., Richard, A. C., Rollin-Sillaire, A.,
19 Frebourg, T., Campion, D. and Hannequin, D. (2013) TREM2 R47H variant as a
20 risk factor for early-onset Alzheimer's disease. *J. Alzheimers Dis.*, **35**, 45-49.
- 21 Rami, L., Loy, C. T., Hailstone, J. and Warren, J. D. (2007) Odour identification in
22 frontotemporal lobar degeneration. *J. Neurol.*, **254**, 431-435.
- 23 Rascovsky, K., Hodges, J. R., Knopman, D. et al. (2011) Sensitivity of revised diagnostic
24 criteria for the behavioural variant of frontotemporal dementia. *Brain*, **134**,
25 2456-2477.
- 26 Rayaprolu, S., Mullen, B., Baker, M. et al. (2013) TREM2 in neurodegeneration: evidence
27 for association of the p.R47H variant with frontotemporal dementia and
28 Parkinson's disease. *Mol. Neurodegener.*, **8**, 19.
- 29 Renton, A. E., Majounie, E., Waite, A. et al. (2011) A hexanucleotide repeat expansion in
30 C9ORF72 is the cause of chromosome 9p21-linked ALS-FTD. *Neuron*, **72**, 257-
31 268.
- 32 Robinson, A., Davidson, Y., Snowden, J. S. and Mann, D. M. (2014) C9ORF72 in dementia
33 with Lewy bodies. *J. Neurol. Neurosurg. Psychiatry*, **85**, 1435-1436.
- 34 Rohrer, J. D., Caso, F., Mahoney, C. et al. (2013a) Patterns of longitudinal brain atrophy in
35 the logopenic variant of primary progressive aphasia. *Brain Lang.*, **127**, 121-126.
- 36 Rohrer, J. D., Crutch, S. J., Warrington, E. K. and Warren, J. D. (2010a) Progranulin-
37 associated primary progressive aphasia: a distinct phenotype? *Neuropsychologia*,
38 **48**, 288-297.
- 39 Rohrer, J. D., Guerreiro, R., Vandrovцова, J. et al. (2009a) The heritability and genetics of
40 frontotemporal lobar degeneration. *Neurology*, **73**, 1451-1456.
- 41 Rohrer, J. D., Isaacs, A. M., Mizielinska, S. et al. (2015a) C9orf72 expansions in
42 frontotemporal dementia and amyotrophic lateral sclerosis. *Lancet Neurol.*, **14**,
43 291-301.
- 44 Rohrer, J. D., Knight, W. D., Warren, J. E., Fox, N. C., Rossor, M. N. and Warren, J. D. (2008)
45 Word-finding difficulty: a clinical analysis of the progressive aphasias. *Brain*,
46 **131**, 8-38.
- 47 Rohrer, J. D., Lashley, T., Schott, J. M. et al. (2011a) Clinical and neuroanatomical
48 signatures of tissue pathology in frontotemporal lobar degeneration. *Brain*, **134**,
49 2565-2581.
- 50 Rohrer, J. D., Nicholas, J. M., Cash, D. M. et al. (2015b) Presymptomatic cognitive and
51 neuroanatomical changes in genetic frontotemporal dementia in the Genetic
52
53
54
55
56
57
58
59
60

- 1
2
3 Frontotemporal dementia Initiative (GENFI) study: a cross-sectional analysis.
4 *Lancet Neurol.*, **14**, 253-262.
- 5 Rohrer, J. D., Paviour, D., Bronstein, A. M., O'Sullivan, S. S., Lees, A. and Warren, J. D.
6 (2010b) Progressive supranuclear palsy syndrome presenting as progressive
7 nonfluent aphasia: a neuropsychological and neuroimaging analysis. *Mov. Disord.*,
8 **25**, 179-188.
- 9
10 Rohrer, J. D., Paviour, D., Vandrovцова, J., Hodges, J., de Silva, R. and Rossor, M. N.
11 (2011b) Novel L284R MAPT mutation in a family with an autosomal dominant
12 progressive supranuclear palsy syndrome. *Neurodegener. Dis.*, **8**, 149-152.
- 13 Rohrer, J. D., Rossor, M. N. and Warren, J. D. (2010c) Syndromes of nonfluent primary
14 progressive aphasia: a clinical and neurolinguistic analysis. *Neurology*, **75**, 603-
15 610.
- 16
17 Rohrer, J. D., Rossor, M. N. and Warren, J. D. (2012) Alzheimer's pathology in primary
18 progressive aphasia. *Neurobiol. Aging*, **33**, 744-752.
- 19 Rohrer, J. D. and Warren, J. D. (2011) Phenotypic signatures of genetic frontotemporal
20 dementia. *Curr. Opin. Neurol.*, **24**, 542-549.
- 21 Rohrer, J. D., Warren, J. D., Fox, N. C. and Rossor, M. N. (2013b) Presymptomatic studies
22 in genetic frontotemporal dementia. *Rev. Neurol. (Paris)*, **169**, 820-824.
- 23 Rohrer, J. D., Warren, J. D., Modat, M., Ridgway, G. R., Douiri, A., Rossor, M. N., Ourselin, S.
24 and Fox, N. C. (2009b) Patterns of cortical thinning in the language variants of
25 frontotemporal lobar degeneration. *Neurology*, **72**, 1562-1569.
- 26
27 Rosen, H. J., Allison, S. C., Ogar, J. M., Amici, S., Rose, K., Dronkers, N., Miller, B. L. and
28 Gorno-Tempini, M. L. (2006) Behavioral features in semantic dementia vs other
29 forms of progressive aphasia. *Neurology*, **67**, 1752-1756.
- 30 Rosen, H. J., Pace-Savitsky, K., Perry, R. J., Kramer, J. H., Miller, B. L. and Levenson, R. W.
31 (2004) Recognition of emotion in the frontal and temporal variants of
32 frontotemporal dementia. *Dement. Geriatr. Cogn. Disord.*, **17**, 277-281.
- 33
34 Rossi, G., Bastone, A., Piccoli, E. et al. (2014) Different mutations at V363 MAPT codon
35 are associated with atypical clinical phenotypes and show unusual structural and
36 functional features. *Neurobiol. Aging*, **35**, 408-417.
- 37 Rossi, G., Marelli, C., Farina, L., Laura, M., Maria Basile, A., Ciano, C., Tagliavini, F. and
38 Pareyson, D. (2008) The G389R mutation in the MAPT gene presenting as
39 sporadic corticobasal syndrome. *Mov. Disord.*, **23**, 892-895.
- 40 Rubino, E., Rainero, I., Chio, A. et al. (2012) SQSTM1 mutations in frontotemporal lobar
41 degeneration and amyotrophic lateral sclerosis. *Neurology*, **79**, 1556-1562.
- 42
43 Ruiz, A., Dols-Icardo, O., Bullido, M. J. et al. (2014) Assessing the role of the TREM2
44 p.R47H variant as a risk factor for Alzheimer's disease and frontotemporal
45 dementia. *Neurobiol. Aging*, **35**, 444 e441-444.
- 46 Rutherford, N. J., Zhang, Y. J., Baker, M. et al. (2008) Novel mutations in TARDBP (TDP-
47 43) in patients with familial amyotrophic lateral sclerosis. *PLoS genetics*, **4**,
48 e1000193.
- 49 Sajjadi, S. A., Patterson, K., Arnold, R. J., Watson, P. C. and Nestor, P. J. (2012) Primary
50 progressive aphasia: a tale of two syndromes and the rest. *Neurology*, **78**, 1670-
51 1677.
- 52
53 Sajjadi, S. A., Patterson, K. and Nestor, P. J. (2014) Logopenic, mixed, or Alzheimer-
54 related aphasia? *Neurology*, **82**, 1127-1131.
- 55 Scahill, R. I., Schott, J. M., Stevens, J. M., Rossor, M. N. and Fox, N. C. (2002) Mapping the
56 evolution of regional atrophy in Alzheimer's disease: unbiased analysis of fluid-
57 registered serial MRI. *Proc. Natl. Acad. Sci. U. S. A.*, **99**, 4703-4707.
- 58
59
60

- 1
2
3 Seelaar, H., Kamphorst, W., Rosso, S. M. et al. (2008) Distinct genetic forms of
4 frontotemporal dementia. *Neurology*, **71**, 1220-1226.
- 5 Seelaar, H., Rohrer, J. D., Pijnenburg, Y. A., Fox, N. C. and van Swieten, J. C. (2011) Clinical,
6 genetic and pathological heterogeneity of frontotemporal dementia: a review. *J.*
7 *Neurol. Neurosurg. Psychiatry*, **82**, 476-486.
- 8 Seeley, W. W., Bauer, A. M., Miller, B. L., Gorno-Tempini, M. L., Kramer, J. H., Weiner, M.
9 and Rosen, H. J. (2005) The natural history of temporal variant frontotemporal
10 dementia. *Neurology*, **64**, 1384-1390.
- 11 Seeley, W. W., Matthews, B. R., Crawford, R. K., Gorno-Tempini, M. L., Foti, D., Mackenzie,
12 I. R. and Miller, B. L. (2008) Unravelling Bolero: progressive aphasia, transmodal
13 creativity and the right posterior neocortex. *Brain*, **131**, 39-49.
- 14 Simon-Sanchez, J., Dopfer, E. G., Cohn-Hokke, P. E. et al. (2012) The clinical and
15 pathological phenotype of C9ORF72 hexanucleotide repeat expansions. *Brain*,
16 **135**, 723-735.
- 17 Siuda, J., Fujioka, S. and Wszolek, Z. K. (2014) Parkinsonian syndrome in familial
18 frontotemporal dementia. *Parkinsonism Relat. Disord.*, **20**, 957-964.
- 19 Skibinski, G., Parkinson, N. J., Brown, J. M. et al. (2005) Mutations in the endosomal
20 ESCRTIII-complex subunit CHMP2B in frontotemporal dementia. *Nat. Genet.*, **37**,
21 806-808.
- 22 Slattery, C. F., Beck, J. A., Harper, L. et al. (2014) R47H TREM2 variant increases risk of
23 typical early-onset Alzheimer's disease but not of prion or frontotemporal
24 dementia. *Alzheimer's & dementia : the journal of the Alzheimer's Association*, **10**,
25 602-608 e604.
- 26 Snowden, J. S., Adams, J., Harris, J. et al. (2015) Distinct clinical and pathological
27 phenotypes in frontotemporal dementia associated with MAPT, PGRN and
28 C9orf72 mutations. *Amyotrophic lateral sclerosis & frontotemporal degeneration*,
29 **16**, 497-505.
- 30 Snowden, J. S., Bathgate, D., Varma, A., Blackshaw, A., Gibbons, Z. C. and Neary, D. (2001)
31 Distinct behavioural profiles in frontotemporal dementia and semantic dementia.
32 *J. Neurol. Neurosurg. Psychiatry*, **70**, 323-332.
- 33 Snowden, J. S., Goulding, P. and Neary, D. (1989) Semantic dementia: a form of
34 circumscribed cerebral atrophy. *Behav. Neurol.*
- 35 Snowden, J. S., Harris, J., Richardson, A., Rollinson, S., Thompson, J. C., Neary, D., Mann, D.
36 M. and Pickering-Brown, S. (2013) Frontotemporal dementia with amyotrophic
37 lateral sclerosis: a clinical comparison of patients with and without repeat
38 expansions in C9orf72. *Amyotrophic lateral sclerosis & frontotemporal*
39 *degeneration*, **14**, 172-176.
- 40 Snowden, J. S. and Neary, D. (1993) Progressive language dysfunction and lobar atrophy.
41 *Dementia*, **4**, 226-231.
- 42 Snowden, J. S., Rollinson, S., Thompson, J. C. et al. (2012) Distinct clinical and
43 pathological characteristics of frontotemporal dementia associated with
44 C9ORF72 mutations. *Brain*, **135**, 693-708.
- 45 Spina, S., Van Laar, A. D., Murrell, J. R. et al. (2013) Phenotypic variability in three
46 families with valosin-containing protein mutation. *Eur. J. Neurol.*, **20**, 251-258.
- 47 Sreedharan, J., Blair, I. P., Tripathi, V. B. et al. (2008) TDP-43 mutations in familial and
48 sporadic amyotrophic lateral sclerosis. *Science*, **319**, 1668-1672.
- 49 Stokholm, J., Teasdale, T. W., Johannsen, P., Nielsen, J. E., Nielsen, T. T., Isaacs, A., Brown,
50 J. M. and Gade, A. (2013) Cognitive impairment in the preclinical stage of
51
52
53
54
55
56
57
58
59
60

- dementia in FTD-3 CHMP2B mutation carriers: a longitudinal prospective study. *J. Neurol. Neurosurg. Psychiatry*, **84**, 170-176.
- Sturm, V. E., McCarthy, M. E., Yun, I. et al. (2011) Mutual gaze in Alzheimer's disease, frontotemporal and semantic dementia couples. *Soc. Cogn. Affect. Neurosci.*, **6**, 359-367.
- Suhonen, N. M., Kaivorinne, A. L., Moilanen, V., Bode, M., Takalo, R., Hanninen, T. and Remes, A. M. (2014) Slowly progressive frontotemporal lobar degeneration caused by the C9ORF72 repeat expansion: a 20-year follow-up study. *Neurocase*, **21**, 85-89.
- Synofzik, M., Born, C., Rominger, A. et al. (2014) Targeted high-throughput sequencing identifies a TARDBP mutation as a cause of early-onset FTD without motor neuron disease. *Neurobiol. Aging*, **35**, 1212 e1211-1215.
- Synofzik, M., Maetzler, W., Grehl, T. et al. (2012) Screening in ALS and FTD patients reveals 3 novel UBQLN2 mutations outside the PXX domain and a pure FTD phenotype. *Neurobiol. Aging*, **33**, 2949 e2913-2947.
- Tabrizi, S. J., Langbehn, D. R., Leavitt, B. R. et al. (2009) Biological and clinical manifestations of Huntington's disease in the longitudinal TRACK-HD study: cross-sectional analysis of baseline data. *Lancet Neurol.*, **8**, 791-801.
- Taylor, L. J., Brown, R. G., Tsermentseli, S., Al-Chalabi, A., Shaw, C. E., Ellis, C. M., Leigh, P. N. and Goldstein, L. H. (2012) Is language impairment more common than executive dysfunction in amyotrophic lateral sclerosis? *J. Neurol. Neurosurg. Psychiatry*, **84**, 494-498.
- Thelen, M., Razquin, C., Hernandez, I. et al. (2014) Investigation of the role of rare TREM2 variants in frontotemporal dementia subtypes. *Neurobiol. Aging*, **35**, 2657 e2613-2659.
- Thompson, S. A., Patterson, K. and Hodges, J. R. (2003) Left/right asymmetry of atrophy in semantic dementia: behavioral-cognitive implications. *Neurology*, **61**, 1196-1203.
- Ticozzi, N., Silani, V., LeClerc, A. L. et al. (2009) Analysis of FUS gene mutation in familial amyotrophic lateral sclerosis within an Italian cohort. *Neurology*, **73**, 1180-1185.
- Tolboom, N., Koedam, E. L., Schott, J. M. et al. (2010) Dementia mimicking Alzheimer's disease Owing to a tau mutation: CSF and PET findings. *Alzheimer Dis. Assoc. Disord.*, **24**, 303-307.
- Tsuboi, Y., Baker, M., Hutton, M. L. et al. (2002) Clinical and genetic studies of families with the tau N279K mutation (FTDP-17). *Neurology*, **59**, 1791-1793.
- Tyrrell, P. J., Kartsounis, L. D., Frackowiak, R. S., Findley, L. J. and Rossor, M. N. (1991) Progressive loss of speech output and orofacial dyspraxia associated with frontal lobe hypometabolism. *J. Neurol. Neurosurg. Psychiatry*, **54**, 351-357.
- Tyrrell, P. J., Warrington, E. K., Frackowiak, R. S. and Rossor, M. N. (1990) Progressive degeneration of the right temporal lobe studied with positron emission tomography. *J. Neurol. Neurosurg. Psychiatry*, **53**, 1046-1050.
- van Blitterswijk, M., Baker, M. C., DeJesus-Hernandez, M. et al. (2013) C9ORF72 repeat expansions in cases with previously identified pathogenic mutations. *Neurology*, **81**, 1332-1341.
- van Blitterswijk, M., Mullen, B., Nicholson, A. M. et al. (2014) TMEM106B protects C9ORF72 expansion carriers against frontotemporal dementia. *Acta Neuropathol.*, **127**, 397-406.

- 1
2
3 Van Deerlin, V. M., Leverenz, J. B., Bekris, L. M. et al. (2008) TARDBP mutations in
4 amyotrophic lateral sclerosis with TDP-43 neuropathology: a genetic and
5 histopathological analysis. *Lancet Neurol.*, **7**, 409-416.
- 6 van der Zee, J., Pirici, D., Van Langenhove, T. et al. (2009) Clinical heterogeneity in 3
7 unrelated families linked to VCP p.Arg159His. *Neurology*, **73**, 626-632.
- 8 van der Zee, J., Van Langenhove, T., Kleinberger, G. et al. (2011) TMEM106B is
9 associated with frontotemporal lobar degeneration in a clinically diagnosed
10 patient cohort. *Brain*, **134**, 808-815.
- 11 Van Langenhove, T., van der Zee, J., Sleegers, K. et al. (2010) Genetic contribution of FUS
12 to frontotemporal lobar degeneration. *Neurology*, **74**, 366-371.
- 13 Van Mossevelde, S., van der Zee, J., Gijssels, I. et al. (2015) Clinical features of TBK1
14 carriers compared with C9orf72, GRN and non-mutation carriers in a Belgian
15 cohort. *Brain*.
- 16 van Swieten, J. and Spillantini, M. G. (2007) Hereditary frontotemporal dementia caused
17 by Tau gene mutations. *Brain Pathol.*, **17**, 63-73.
- 18 van Swieten, J. C. and Heutink, P. (2008) Mutations in progranulin (GRN) within the
19 spectrum of clinical and pathological phenotypes of frontotemporal dementia.
20 *Lancet Neurol.*, **7**, 965-974.
- 21 Vance, C., Rogelj, B., Hortobagyi, T. et al. (2009) Mutations in FUS, an RNA processing
22 protein, cause familial amyotrophic lateral sclerosis type 6. *Science*, **323**, 1208-
23 1211.
- 24 Velakoulis, D., Walterfang, M., Mocellin, R., Pantelis, C. and McLean, C. (2009)
25 Frontotemporal dementia presenting as schizophrenia-like psychosis in young
26 people: clinicopathological series and review of cases. *Br. J. Psychiatry*, **194**, 298-
27 305.
- 28 Villa, C., Ghezzi, L., Pietroboni, A. M. et al. (2011) A novel MAPT mutation associated
29 with the clinical phenotype of progressive nonfluent aphasia. *J. Alzheimers Dis.*,
30 **26**, 19-26.
- 31 Wallon, D., Rovelet-Lecrux, A., Deramecourt, V. et al. (2012) Definite behavioral variant
32 of frontotemporal dementia with C9ORF72 expansions despite positive
33 Alzheimer's disease cerebrospinal fluid biomarkers. *J. Alzheimers Dis.*, **32**, 19-22.
- 34 Warren, J. D. and Rohrer, J. D. (2009) Ravel's last illness: a unifying hypothesis. *Brain*,
35 **132**, e114.
- 36 Warren, J. D., Rohrer, J. D. and Rossor, M. N. (2013) Clinical review. Frontotemporal
37 dementia. *BMJ*, **347**, f4827.
- 38 Warrington, E. K. (1975) The selective impairment of semantic memory. *Q. J. Exp.*
39 *Psychol.*, **27**, 635-657.
- 40 Watts, G. D., Wymer, J., Kovach, M. J., Mehta, S. G., Mumm, S., Darvish, D., Pestronk, A.,
41 Whyte, M. P. and Kimonis, V. E. (2004) Inclusion body myopathy associated with
42 Paget disease of bone and frontotemporal dementia is caused by mutant valosin-
43 containing protein. *Nat. Genet.*, **36**, 377-381.
- 44 Whitwell, J. L., Sampson, E. L., Watt, H. C., Harvey, R. J., Rossor, M. N. and Fox, N. C.
45 (2005) A volumetric magnetic resonance imaging study of the amygdala in
46 frontotemporal lobar degeneration and Alzheimer's disease. *Dement. Geriatr.*
47 *Cogn. Disord.*, **20**, 238-244.
- 48 Wicklund, M. R., Duffy, J. R., Strand, E. A., Machulda, M. M., Whitwell, J. L. and Josephs, K.
49 A. (2014) Quantitative application of the primary progressive aphasia consensus
50 criteria. *Neurology*, **82**, 1119-1126.
- 51
52
53
54
55
56
57
58
59
60

- 1
2
3 Wilhelmssen, K. C., Lynch, T., Pavlou, E., Higgins, M. and Nygaard, T. G. (1994)
4 Localization of disinhibition-dementia-parkinsonism-amyotrophy complex to
5 17q21-22. *Am. J. Hum. Genet.*, **55**, 1159-1165.
- 6 Wojtas, A., Heggeli, K. A., Finch, N., Baker, M., DeJesus-Hernandez, M., Younkin, S. G.,
7 Dickson, D. W., Graff-Radford, N. R. and Rademakers, R. (2012) C9ORF72 repeat
8 expansions and other FTD gene mutations in a clinical AD patient series from
9 Mayo Clinic. *American journal of neurodegenerative disease*, **1**, 107-118.
- 10 Woollacott, I. O. and Mead, S. (2014) The C9ORF72 expansion mutation: gene structure,
11 phenotypic and diagnostic issues. *Acta Neuropathol.*, **127**, 319-332.
- 12 Woolley, J. D., Khan, B. K., Murthy, N. K., Miller, B. L. and Rankin, K. P. (2011) The
13 diagnostic challenge of psychiatric symptoms in neurodegenerative disease:
14 rates of and risk factors for prior psychiatric diagnosis in patients with early
15 neurodegenerative disease. *J. Clin. Psychiatry*, **72**, 126-133.
- 16 Yan, J., Deng, H. X., Siddique, N. et al. (2010) Frameshift and novel mutations in FUS in
17 familial amyotrophic lateral sclerosis and ALS/dementia. *Neurology*, **75**, 807-
18 814.
- 19 Zarranz, J. J., Ferrer, I., Lezcano, E. et al. (2005) A novel mutation (K317M) in the MAPT
20 gene causes FTDP and motor neuron disease. *Neurology*, **64**, 1578-1585.
- 21
22
23
24
25
26
27
28
29
30
31
32
33
34
35
36
37
38
39
40
41
42
43
44
45
46
47
48
49
50
51
52
53
54
55
56
57
58
59
60

Brief description:

This review clarifies the terminology of frontotemporal dementia (FTD) and summarises the various clinical features and most recent diagnostic criteria of sporadic and familial FTD syndromes. It also discusses the current major challenges in FTD research and clinical practice, and highlights potential areas for future research.

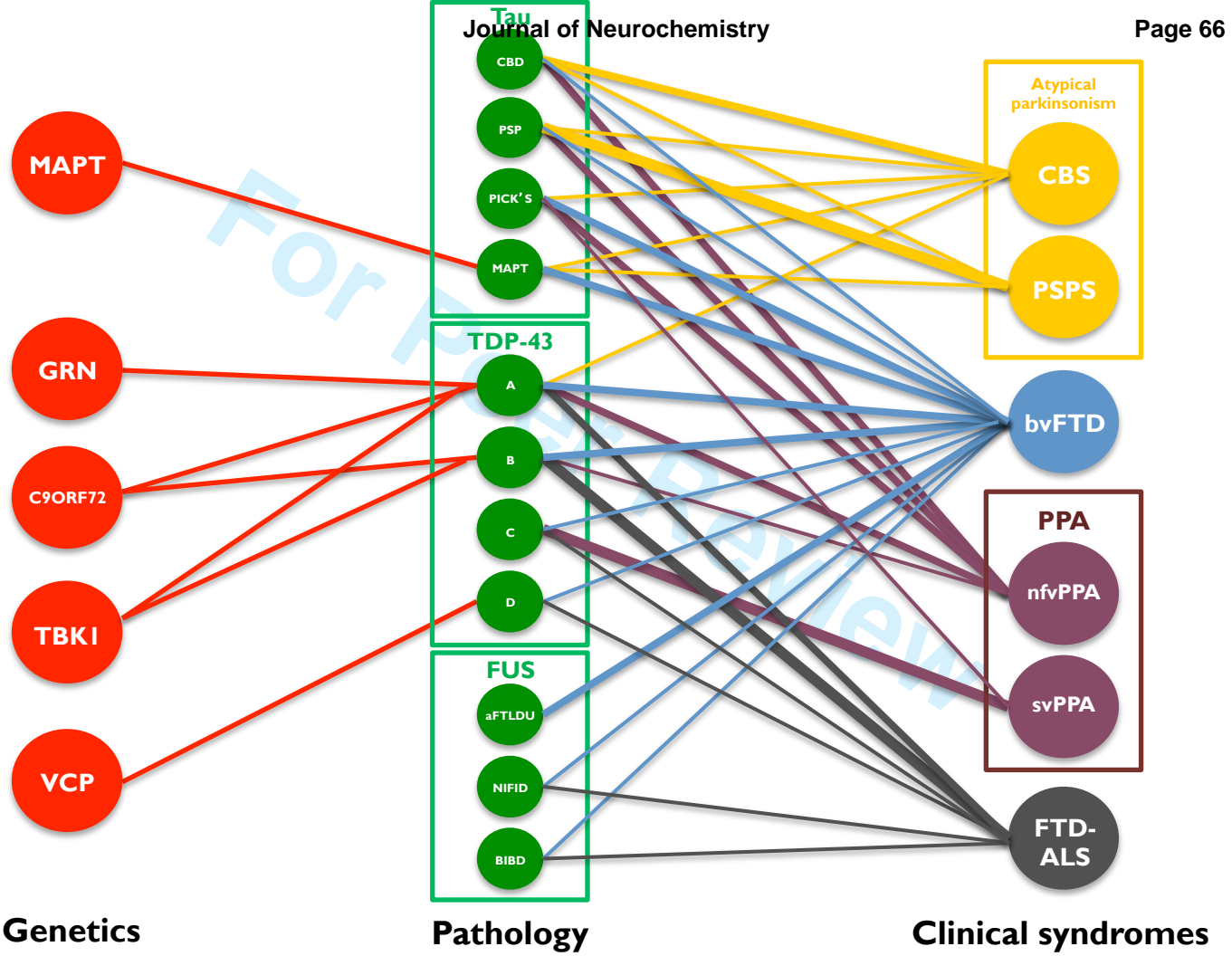
46 words

Summarising schematic:

See attached PDF document

For Peer Review

1
2
3
4
5
6
7
8
9
10
11
12
13
14
15
16
17
18
19
20
21
22
23
24
25
26
27
28
29
30
31



For Review

MS number	Full Paper	Date received
JNC-2016-0138.R1	Review	18/02/16
Special issue / comments		
Special issue: FTD (2015-FTD-51-Rohrer)		
All authors		
Rohrer, Jonathan (contact); Woollacott, lone		
Title		
Clinical spectrum of sporadic and familial FTD		
Corresponding author		
Dr. Jonathan Rohrer		
Address		
Tel		
FAX		
E-mail		
j.rohrer@ucl.ac.uk		
Date of first decision	Date received 1st revision	Date received 2nd and further revisions
12/03/16	10/04/16	
Final Decision	Days to 1st decisio	Days submission to final decisio
Accepted on 27/04/16	22	38
Copyright Form	Disk Enclosed	Colour Figures
		No
ISN member - Confirmation	Category	
No	Clinical Studies, Biomarkers & Imaging	

View

1
2
3
4
5
6
7
8
9
10
11
12
13
14
15
16
17
18
19
20
21
22
23
24
25
26
27
28
29
30
31
32
33
34
35
36
37
38
39
40
41
42
43
44
45
46
47
48
49
50
51
52
53
54
55
56
57
58
59
60