

Characterizing microstructure and shape of the extremely preterm 19 year-old corpus callosum

Andrew Melbourne¹, Eliza Orasanu¹, Zach Eaton-Rosen¹, Joanne Beckmann², Alexandra Saborowska³, David Atkinson¹, Neil Marlow², and Sebastien Ourselin¹

¹University College London, London, United Kingdom, ²Institute for Women's Health, University College London, London, United Kingdom, ³University College Hospital, London, United Kingdom

Synopsis

This work investigates the appearance of the corpus callosum using multiple MR imaging contrasts between a population of extremely preterm born adolescents and their term-born peers.

Introduction

Extreme preterm birth (less than 28 weeks completed gestation) is associated with an increased risk of poor neurocognitive outcome [1,2]. The effects of extreme prematurity on long-term brain development are not well understood, although research studies are now available which are beginning to address these questions. In this work we present some initial results from a neuroimaging study of extreme prematurity carried out on preterm survivors and term-born controls at 19 years of age. We use multi-contrast MRI to specifically investigate structure and shape of the corpus callosum. The appearance of this structure has long been described as a notable neurological feature of the preterm phenotype on neonatal studies and here we investigate to what extent these difference remain in adolescence.

Data

Imaging data were acquired for a cohort of 119 adolescents at 19 years of age. Data for 69 extremely preterm adolescents (FM=41/28, mean birth gestation=25.0±0.8wks) and 50 (FM=30/20) term-born socioeconomically matched peers were acquired on a 3T Philips Achieva. We acquired 3D T1-weighted (TR/TE=6.93/3.14ms) volume at 1mm isotropic resolution. Diffusion weighted data was acquired across four b-values at $b = (0, 300, 700, 2000) \text{ s.mm}^{-2}$ with $n=(4, 8, 16, 32)$ directions respectively at TE=70ms (2.5x2.5x3.0mm). T2 weighted data was acquired in the same space as the diffusion imaging with ten echo times at TE=(13, 16, 19, 25, 30, 40, 50, 85, 100, 150)ms (2.5x2.5x3.0mm). B0 field maps were acquired to correct for EPI-based distortions between the diffusion imaging and the T1-weighted volumes.

Methods

After brain segmentation using a combined multi-atlas, Gaussian mixture model segmentation routine [1], we extract the corpus callosum from the mid-sagittal corpus callosum slice by identification of the cerebral aqueduct. After manual removal of the fornix we apply an affine transformation followed by a non-rigid (fluid-based) registration algorithm to investigate local differences in corpus callosum volume and shape by registration to a groupwise coordinate system of the individual control with the median corpus callosum volume [2]. After segmentation, we investigate the spatial microstructure by combining the results with an analysis of the diffusion imaging data using the NODDI model which provides an estimate of the intra-axonal volume fraction [3]. We also fit single and multi-component T2 relaxometry to the multi-echo T2 weighted data in order to estimate both the tissue T2 and to extract a short-T2 component that we attribute to myelin water [4]. This facilitates an estimation of the multi-modal g-ratio in the preterm corpus callosum.

Results

Analysing the volume of the segmentation suggests that the corpus callosum is significantly smaller in preterms (506±96mm³) than their term-born peers (669±104mm³) (95% ci: (-123-204)mm³) Average mid-sagittal corpus callosum values for the FA are higher in the term group (0.58±0.07) than in the preterm group (0.52±0.10, 95% ci: (-0.02-0.10)) whilst T2 is higher at 74.2±7.4ms in the term group than in the preterm group (88.2±17.5ms, 95% ci: (7.9-20.0)ms). Using intra-axonal and myelin water models, the intra-axonal and myelin water fractions are both lower (0.51±0.12 / 0.61±0.08 and 0.25±0.05 / 0.29±0.04 respectively 95%ci: (-0.05-0.14) and (-0.02-0.06) respectively) in the preterm group than the term group. Despite reaching significance between preterm and term groups, these biomarkers do not translate into a significant difference (term=0.77±0.04 preterm=0.77±0.06) in the measured emergent g-ratio (p=0.87), either due to measurement insensitivity or perhaps developmental compensation. These results are summarised in the boxplots of Figure 2.

We also analysed differences in corpus callosum shape using the results of the non-rigid registration. Figure 3 summarises these results. Within group average segmentations are shown for term controls (Fig 3a) and for extreme-preterms (Fig 3b). Figures 3b and e show the colour coded 2D average absolute deformation (red represents anterior-posterior displacement and green superior-inferior) Finding the Jacobian determinant of the transformations suggests that the major differences in shape between the term and preterm cohorts is the posterior section of the corpus callosum. Both Figure 3 and Figure 1 show marked thinning of the posterior segment of the main body of the corpus callosum with involvement of the splenium.

Conclusion

We have shown that the corpus callosum of extreme preterm survivors remains altered at 19 years of age. Of note, the mid-sagittal corpus callosum area is lower, and remains lower when correcting for an overall lower brain volume in EPs. Notably, the posterior portion of the corpus callosum is most affected, particularly the splenium and this may have a consequence for those areas for which intra-hemispheric communication depends upon this pathway. Our future work will devise functional tests to attempt to validate this hypothesis, but work such as this, characterising the extremely preterm brain phenotype at adolescence is crucial for understanding the long term impact on structural appearance.

Acknowledgements

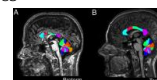
We would also like to acknowledge the MRC (MR/J01107X/1), the National Institute for Health Research (NIHR), the EPSRC (EP/H046410/1) and the National Institute for Health Research University College London Hospitals Biomedical Research Centre (NIHR BRC UCLH/UCL High Impact Initiative- BW.mn.BRC10269). This work is supported by the EPSRC-funded UCL Centre for Doctoral Training in Medical Imaging (EP/L016478/1).

References


- [1] Volpe, J. J., 2009. Brain injury in premature infants: a complex amalgam of destructive and developmental disturbances. *Lancet Neurol* 8 (1), 110-124.
- [2] Moore, T., et al 2012. Neurological and developmental outcome in extremely preterm children born in England in 1995 and 2006: the EPICure studies. *BMJ* 345, e7961.
- [3] Cardoso, M. J., et al. Geodesic Information Flows: Spatially-Variant Graphs and Their Application to Segmentation and Fusion. *IEEE Trans Med Imaging*, 2015, 34, 1976-1988
- [4] Cahill, N.D., et al. Fourier Methods for Nonparametric Image Registration. *Proc. CVPR Workshop on Image Registration and Fusion*, pp. 1-8, June 2007
- [6] Raj, A. et al. Multi-compartment T2 relaxometry using a spatially constrained multi-Gaussian model. *PLoS One*, 2014, 9, e98391
- [7] Melbourne, A. et al. Multi-modal measurement of the myelin-to-axon diameter g-ratio in preterm-born neonates and adult controls. *Med Image Comput Assist Interv.* 2014;17(Pt 2):268-75.

Abstract ID: 3155


Figures



Example mid-sagittal corpus callosum segmentations.



Average parameter values for preterm and term groups in the mid-sagittal corpus callosum



Results of image registration, showing average control and preterm corpus callosum (A/D), Colour-coded deformation magnitude (B/E), Jacobian determinant maps (C/F).