

A DIFFICULT CASE

Trapped without a diagnosis: a case report of a relapsing remitting disorder causing transient paraparesis

Ali Kirresh¹, Alex Everitt¹, Onn Min Kon¹, Ranan DasGupta¹, Matthew C. Pickering²,
Helen J Lachmann³

¹Imperial College Healthcare NHS Trust, St Mary's Hospital, London, United Kingdom

²Centre for Complement and Inflammation Research, Imperial College, London,
United Kingdom

³National Amyloidosis Centre, University College London, Royal Free Hospital, London,
United Kingdom

Corresponding author: Dr Ali Kirresh, Imperial College NHS Trust, St Mary's Hospital,
London, W2 1NY; ali.kirresh@doctors.org.uk

Keywords: paraparesis, TRAPS, periodic fever syndromes

ABSTRACT

Tumour necrosis factor receptor associated periodic syndrome (TRAPS) is an autosomal dominant condition caused by mutations in the TNFRSF1A gene. It is characterised by recurrent episodes of myalgia, followed by prolonged pyrexia, migratory rashes, headache, serositis, arthralgia, abdominal pain and periorbital oedema. We describe the case of a 49 year old patient who presented with a self-limiting episode of paraparesis on a background of recurrent bouts of abdominal symptoms and headaches since childhood. He had a persistent inflammatory response associated with night sweats and weight loss. A diagnosis of TRAPS was made two years later when a mutation was identified in the TNFRSF1A gene. The patient's symptoms and inflammatory response resolved dramatically following treatment with the interleukin-1 receptor antagonist anakinra.

CASE REPORT

A 49 year old right handed male presented with a 3 day history of bilateral leg weakness, altered sensation in both feet later ascending to the thighs, unsteadiness, urinary and faecal retention. A few days earlier he described transient severe left frontal and retro-orbital headache without photophobia. He had been bitten by a dog 4 weeks earlier.

He had a lifelong history of unexplained episodic abdominal pains. These episodes followed a typical pattern lasting up to 2 weeks and increased in frequency with age. During adulthood they were occurring every 2 to 3 months. An episode would start

with headaches and a dull central abdominal pain. Over 24 hours he would develop severe abdominal cramps with abdominal distension. Resolution of the episode was preceded by diarrhoea. Investigations excluded autoimmune disease, porphyria and hereditary angioedema. During one of these episodes he was noted to have a marked acute phase response: ESR 80-100 mm/hr and CRP 130 mg/L and an exploratory laparotomy revealed small bowel adhesions, inflamed small bowel mesentery and mildly reactive lymph nodes. Histology of resected bowel revealed inflammation only. Surgical history included: tonsillectomy, adenoidectomy, appendicectomy and bilateral inguinal hernia repairs.

. His half sibling had biopsy confirmed pulmonary sarcoidosis.

Examination revealed normal cranial nerves. His gait was ataxic but Romberg's test was negative. Limb tone was normal. He had a mild paraparesis (hip flexion MRC 4/5, knee flexion 4+/5), symmetrically brisk reflexes in all four limbs, and bilateral extensor plantar responses. Abdominal reflexes were absent. He had mild bilateral heel-shin ataxia. Joint position sense was preserved but vibration sense was reduced below the sternum bilaterally. Pinprick sensation was reduced below T7. Anal tone was reduced. Neurological examination was otherwise unremarkable. A urethral catheter was inserted and there was a residual of greater than 500 millilitres.

INVESTIGATIONS

He had a marked acute phase response: CRP 230mg/L (NR<5), ESR 85 mm/hr; microcytic anaemia (Hb 111g/L, MCV 70fL), thrombocytosis (481x10⁹/L, NR 150-400) and neutrophilia (9.8x10⁹/L, NR 1.5-8). Normal or negative blood tests included: renal, liver and bone profiles, vitamin B12, folate, ANA, ANCA, rheumatoid factor, complement C3 and C4, antiphospholipid antibodies, anticardiolipin antibodies, serum ACE, LDH, JAK-2 mutation, AFP, CA19-9, CEA, and IgG subsets. Serological tests for HIV, syphilis, brucella, borrelia, toxocara, hepatitis B/C toxoplasma, yersinia, bartonella and atypical pneumonia were negative. T-spot.TB was non-reactive.

MRI brain demonstrated multiple non-specific white matter lesions, reported as minor microangiopathic change (Figure 1). MRI whole spine excluded cord compression and revealed no cord signal change. Vertebral bone marrow was diffusely hypointense with multiple vertebral haemangiomas. Cerebrospinal fluid (CSF) was acellular with an elevated protein of 1.05g/L (NR 0.15-0.45), normal glucose differential, sterile culture (fungal and bacterial) and matched CSF/serum oligoclonal bands.

A CT scan of the chest, abdomen and pelvis revealed diffuse lymphadenopathy with hepatosplenomegaly, signs of portal hypertension, prominent right renal pelvis and an inferior mesenteric vein (IMV) thrombosis. Inguinal lymph node aspiration revealed reactive changes only, without evidence of lymphoma or granulomatous inflammation. Bone marrow biopsy and trephine showed a hypercellular bone marrow aspirate with no lymphoid infiltrate.

TREATMENT AND PROGRESS

He was initially treated with ceftriaxone and metronidazole due to suspected sepsis. However, investigations did not reveal sepsis and his condition spontaneously improved over the next 2 weeks. Following exclusion of oesophageal varices on endoscopy, the patient was warfarinised for 6 months for the IMV thrombosis. He was discharged with a final diagnosis of self-limiting acellular transverse myelitis.

His paroxysms of abdominal pain continued and were associated with weight loss. ESR and CRP remained persistently elevated. He continued to suffer from episodes of recurrent subacute small bowel obstruction due to small bowel adhesions. Whole body FDG-PET-CT scan 2 years after his neurological illness showed persistent diffuse lymphadenopathy; multiple loops of adherent thickened bowel in the left iliac fossa; increased peritoneal activity and free fluid. An omental biopsy showed acute inflammation and organizing adhesions, with negative cultures. Additional features included the development of a sterile right-sided pleural effusion and the appearance of epicardial calcification on imaging.

In view of his recurrent unexplained symptoms, together with childhood onset, screening for the presence of a periodic fever associated genetic change was performed. This revealed a TNFRSF1A N65K mutation, confirming a diagnosis of Tumour Necrosis Factor Receptor Associated Periodic Syndrome (TRAPS) and excluded mutations in MEFV (the gene responsible for familial Mediterranean fever), MVK (the gene responsible for the mevalonate kinase deficiencies) and NOD2 (which can cause both familial Crohn's and Blau syndrome).

The patient was commenced on specific IL-1 blockade using anakinra, a recombinant IL-1 receptor antagonist, at a dose of 100 milligrams daily with complete normalisation of his acute phase response within 2 weeks and complete resolution of his systemic symptoms.

DISCUSSION

Tumour necrosis factor receptor associated periodic syndrome (TRAPS) is an autosomal dominant condition caused by mutations in the TNFRSF1A gene. It is characterised by recurrent episodes of myalgia, followed by prolonged pyrexia, migratory rashes, headache, serositis, arthralgia, abdominal pain and periorbital oedema. These episodes occur either spontaneously or following triggers such as stress or infection and usually last 1-3 weeks and recur monthly-yearly. More than 10% of patients develop systemic amyloid AA amyloidosis, which confers a poor prognosis.[1]

Mutations in the TNFRSF1A gene result in aberrant protein folding with accumulation in the endoplasmic reticulum. This causes both ER stress and increased production of reactive oxygen species and hence persistent inflammation.[2] In addition there is some evidence that the lack of TNF signalling may result in decreased activity in the NF-kappa beta transcription pathway, leading to a reduction in apoptosis and therefore prolonged survival of the activated inflammatory cells.[3] The effect is an excess production of cytokines such as interleukin-1 which promotes the release of a cascade of inflammatory cytokines.

The patient in this case demonstrated many of the characteristic features of TRAPS. However, the presumed inflammatory transverse myelitis suspected in this case has not previously been described. It is not presently understood why only a small proportion of patients develop neurological symptoms. One possibility is that only some TNFRSF1A allelic mutations predispose to neurological involvement. The R92Q mutation is associated with TRAPS and an increased risk of multiple sclerosis. It is possible that this mutation results in an alteration of downstream signalling pathways, which may confer an increased susceptibility to neural tissue.[4]

Chronic IL-1 stimulation within the central nervous system (CNS) is known to mediate several neuroinflammatory processes.[5] Within animal models, chronic IL-1 exposure within the CNS caused a marked recruitment of neutrophils, extensive demyelination and breakdown of the blood brain barrier (BBB).[6] The patient in this case demonstrated CSF albuminocytologic dissociation (a normal cell count with raised protein) which is associated with BBB dysfunction. Furthermore, the non-specific white matter lesions demonstrated on the MRI of the brain may have been a result of this inflammatory process (Figure 1).

The aetiology of the transient paraparesis is perhaps less clear. Spinal cord venous infarction or congestion is a possibility, given the presence of an IMV thrombosis on abdominal imaging. However, the IMV drains into the inferior vena cava whereas the spinal cord drains into the superior vena cava. It therefore seems unlikely that spinal cord venous infarction or congestion is responsible for the patient's transient myelopathy, especially given the rapid recovery prior to anticoagulation.

IL-1 over-expression and demyelination within the spinal cord may offer a more plausible explanation, despite the lack of visible inflammation on MRI spine. It is conceivable that the transient nature of the paraparesis may have been due to CNS tachyphylaxis following chronic IL-1 stimulation. In rodents exposed to an IL-1 viral vector, peak cytokine expression and central nervous system dysfunction occurred at days eight and fourteen. However, at day thirty, despite IL-1 expression remaining high, all signs of inflammation were no longer present, remyelination was noted and the blood brain barrier was intact.[6] This supports the theory that tachyphylaxis may be responsible for the spontaneous resolution of the patient's myelopathy.

Treatment with the interleukin-1 antagonist anakinra was highly successful in this case. Anakinra provides complete resolution of symptoms and inflammatory response in more than 80% of patients with TRAPS and is therefore indicated as first line treatment, in patients requiring long term steroids.[7] In a population of paediatric patients, when anakinra was withdrawn after 15 days of treatment, the disease relapsed within an average of 5 days but resolved with reintroduction of anakinra. Therefore, long term treatment is required for continued disease remission.[8]

Key Points

1. In patients with relapsing-remitting systemic disorders and central nervous system involvement, very rare periodic fever syndromes such as TRAPS should be considered in the differential diagnosis.

2. A thorough history and examination is required to correctly diagnose TRAPS and other systemic autoinflammatory diseases.
3. Long term IL-1 blockade is completely effective in terms of controlling both symptoms and biomarkers of inflammation in more than 80% of TRAPS patients
4. Patients with TRAPS should be managed in specialist centres.

REFERENCES

1 Lachmann HJ, Papa R, Gerhold K, et al. The phenotype of TNF receptor-associated autoinflammatory syndrome (TRAPS) at presentation: a series of 158 cases from the Eurofever/EUROTRAPS international registry. *Ann Rheum Dis* 2014;73:2160-2167.

2 Bachetti T, Ceccherini I. Tumor necrosis factor receptor-associated periodic syndrome as a model linking autophagy and inflammation in protein aggregation diseases. *J Mol Med* 2014;92(6):583-94.

3 Rebelo SL, Bainbridge SE, Amel-Kashipaz MR, et al. Modeling of tumor necrosis factor receptor superfamily 1A mutants associated with tumor necrosis factor receptor-associated periodic syndrome indicates misfolding consistent with abnormal function. *Arthritis Rheum* 2006;54:2674–87.

4 Caminero A, Comabella M, Montalban X. Role of tumour necrosis factor (TNF)- α and TNFRSF1A R92Q mutation in the pathogenesis of TNF receptor-associated periodic syndrome and multiple sclerosis. *Clin Exp Immunol* 2011;166:338–345.

5 Allan SM, Rothwell NJ. Cytokines and acute neurodegeneration. *Nat Rev Neurosci* 2001;2:734–744.

6 Ferrari CC, Depino AM, Prada F, et al. Reversible demyelination, blood-brain barrier breakdown, and pronounced neutrophil recruitment induced by chronic IL-1 expression in the brain. *Am J Pathol* 2004;165:1827–37.

7 Ter Haar N, Lachmann H, Özen S, et al. Treatment of autoinflammatory diseases: results from the Eurofever Registry and a literature review. *Ann Rheum Dis* 2013;72:678-8.

8 Gattorno M, Pelagatti MA, Meini A et al. Persistent efficacy of anakinra in patients with tumor necrosis factor receptor-associated periodic syndrome. *Arthritis Rheum* 2008;58:1516-20.

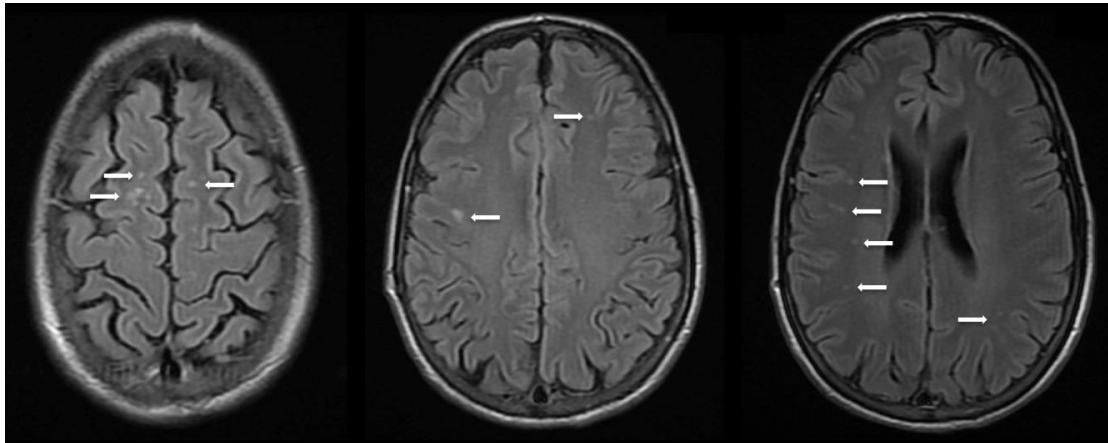


Figure 1. MRI brain sections demonstrating non specific white matter lesions (white arrows).