



Circulation

Manuscript Submission and Peer Review System

Disclaimer: The manuscript and its contents are confidential, intended for journal review purposes only, and not to be further disclosed.

URL: <http://circ-submit.aha-journals.org>

Title: Global myocardial edema in anti-synthetase syndrome detected by cardiovascular magnetic resonance mapping techniques

Manuscript number: CIRCULATIONAHA/2015/017430R2

Author(s): James Moon, The Heart Hospital

Daniel Sado, The Heart Hospital

Rebecca Kozor, The Heart Hospital

Laura Corr, The Harley Street Clinic

Global Myocardial Edema in Anti-Synthetase Syndrome Detected by Cardiovascular Magnetic Resonance Mapping Techniques

Running title: *Sado et al.; CMR in anti-synthetase syndrome*

Daniel M. Sado, MD^{1,2}; Rebecca Kozor, MBBS¹; Laura Corr, MBBS PhD³; James C. Moon,
MD^{1,2}

¹The Barts Heart Centre, London, United Kingdom; ²Institute of Cardiovascular Science,
University College London, United Kingdom; ³The Harley Street Clinic, London, United
Kingdom

Correspondence:

James C. Moon, MD

Barts Heart Centre

St. Bartholomew's Hospital

West Smithfield, London EC1A 7BE

Phone: +44 2034563081

Fax: +44 2034563086

Email: J.moon@ucl.ac.uk

Journal Subject Term: Magnetic Resonance Imaging (MRI)

Key words: anti-synthetase, myocardial edema, cardiovascular magnetic resonance imaging;
cardiac magnetic resonance imaging

A 56 year old man presented with 7 months of fever, breathlessness, cough, and proximal muscle weakness with tenderness. His past history was of hypertension. Examination was unremarkable apart from peripheral oedema and a new scaly fissured erythematous rash on the hands and fingers (Figure 1). Blood tests revealed normocytic anaemia, low total protein, raised inflammatory markers (CRP 59 mg/L (normal 0-5 mg/L) and ESR 43 mm/hr (normal 1-20 mm/hr)) and negative infective screen. Electrocardiogram was normal. Chest radiography and subsequent computed tomography showed interstitial lung disease. Echocardiography was normal (Movie 1A) but NT-proBNP was very raised at 245pmol/L (normal <47 pmol/L, high levels >236pmol/L).

Conventional cardiovascular magnetic resonance (CMR) showed a small pericardial effusion but normal cardiac size and function (Movie 2A). There was no edema or focal fibrosis on T2-weighted imaging and late gadolinium enhancement, respectively. However, using novel CMR parametric mapping techniques to assess T1, T2 and the extracellular volume (ECV), abnormalities were found - elevated native myocardial T1 (1090ms; normal 968±32ms; Figure 2A) using a shortened modified look locker inversion recovery (ShMOLLI) sequence; elevated T2 (62ms; normal 52±3ms; Figure 2B) using T2 mapping, and increased ECV at 15 minutes post contrast administration (0.40; normal 0.25±0.04), the values obtained from averaging all size segments on the mid short axis stack, suggesting global myocardial edema. Rheumatology review raised the clinical suspicion of antisynthetase syndrome, confirmed by a positive anti-PL12 antibody. An RV biopsy showed a mild interstitial cellular infiltrate, no vasculitis, no granulomas, and no fibrosis. The patient was treated with oral steroid therapy with dramatic clinical improvement. His CMR was repeated 2 months later with all mapping parameters returning to normal (T1=994ms, T2=53ms, ECV=0.29)(Figure 2C-D; Movie 2B), as well as a fall in NT-proBNP to near normal at 53 pmol/L, and normalization of inflammatory markers (CRP 2 mg/L, ESR 7mm/hr).

Antisynthetase is a rare autoimmune disease where antibodies are generated to the machinery of protein synthesis. Autoantibodies to aminoacyl-transfer RNA (tRNA) synthetases (antisynthetase antibodies) are implicated in the pathogenesis and correlate with disease activity[1]. Multi-system involvement includes interstitial lung disease, myositis, arthropathy, fever, Raynaud's phenomenon, and skin ("mechanic's hands" – as seen in this patient; Figure 1). Cardiac involvement has only previously been described in the right ventricle of one patient [2]. The disease can be treated, as here, by immunosuppression. CMR has become the gold standard method for the evaluation of myocardial oedema, but conventional CMR can miss diffuse, global disease. Here, mapping techniques permitted the detection of previously undefined cardiac involvement, manifesting as global myocardial edema, providing new insights into the disease and potential methods for diagnosis and monitoring therapy in clinical practice. Developments in CMR imaging techniques are enabling rapid clinically-feasible parametric mapping [3, 4], as in this case.

Disclosures: None.

References:

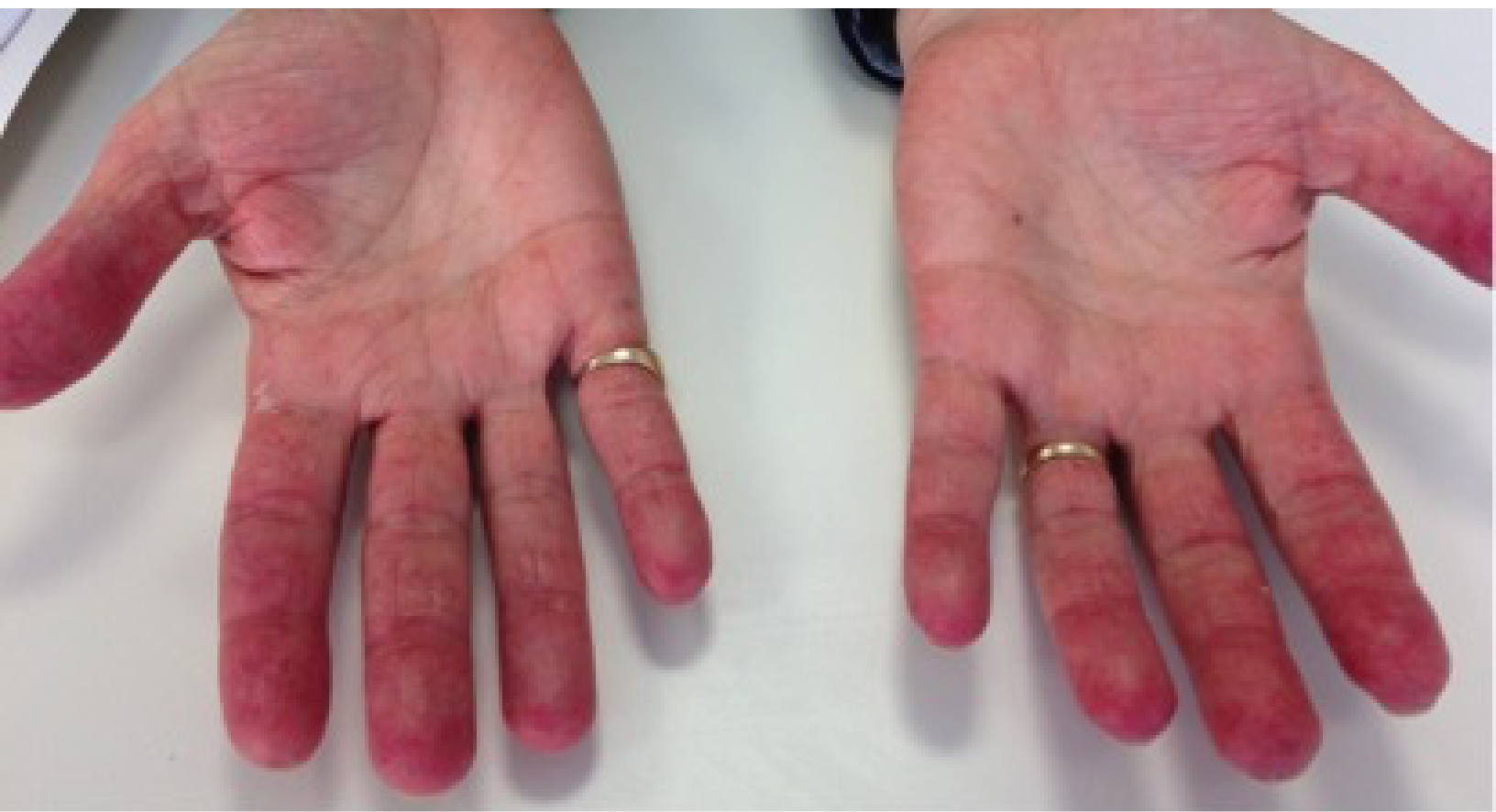1. Katzap E, Barilla-LaBarca ML, Marder G. Antisynthetase syndrome. *Curr Rheumatol Rep.* 2011, 13: 175-181.
2. Tahiri L, Guignard S, Pinto P, Duclos M, Dougados M. Antisynthetases syndrome associated with right heart failure. *Joint Bone Spine.* 2009, 76: 715-717.
3. Salerno M, Kramer CM. Advances in parametric mapping with CMR imaging. *JACC Cardiovasc Imaging.* 2013, 6: 806-822.
4. Moon JC, Messroghli DR, Kellman P, Piechnik SK, Robson MD, Ugander M, Gatehouse PD, Arai AE, Friedrich MG, Neubauer S, Schulz-Menger J, Schelbert EB, Society for Cardiovascular Magnetic Resonance I, Cardiovascular Magnetic Resonance Working Group of the European Society of C. Myocardial T1 mapping and extracellular volume quantification: a Society for Cardiovascular Magnetic Resonance (SCMR) and CMR Working Group of the European Society of Cardiology consensus statement. *J Cardiovasc Magn Reson.* 2013, 15: 92.

Figure Legends:

Figure 1. Classic “mechanic’s hands.”

Figure 2. Mapping images in antisynthetase syndrome showing (A) increased myocardial T2 and (B) elevated native T1, which normalised after 2 months of steroid therapy (C,D).

Disclaimer: The manuscript and its contents are confidential, intended for journal review purposes only, and not to be further disclosed.



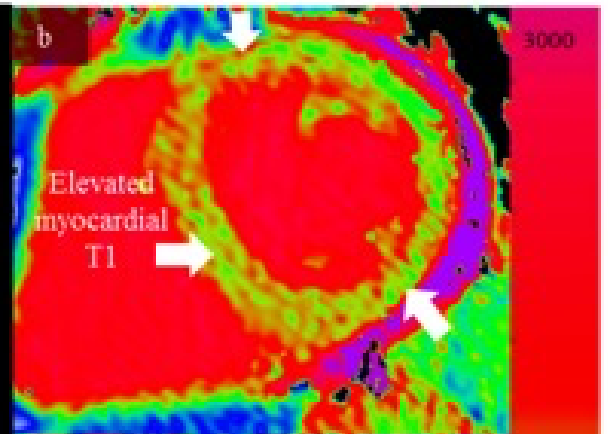
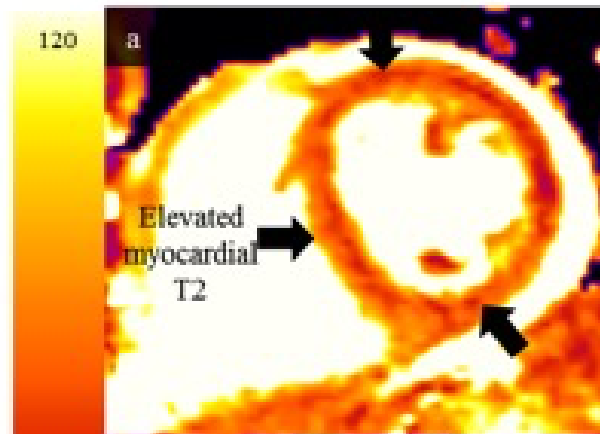
T2 MAP

T1 MAP

T2 Color
Scale (ms)

T1 Color
Scale (ms)

Scan 1



**Scan 2
(after 2 months
oral steroid)**

