

Available online at [www.sciencedirect.com](http://www.sciencedirect.com)

ScienceDirect

journal homepage: [www.elsevier.com/locate/jpor](http://www.elsevier.com/locate/jpor)

## Technical procedure

# A digital approach for one-step formation of the supra-implant emergence profile with an individualized CAD/CAM healing abutment



Tim Joda DMD, MSc <sup>a,\*</sup>, Marco Ferrari MD, DDS, PhD <sup>b</sup>, Urs Braegger DMD <sup>a</sup>

<sup>a</sup> Department of Reconstructive Dentistry & Gerodontology, School of Dental Medicine, University of Bern, Switzerland

<sup>b</sup> Department of Prosthodontics & Dental Materials and Dean, School of Dental Medicine, University of Siena, Italy

### ARTICLE INFO

#### Article history:

Received 14 October 2015

Received in revised form

30 November 2015

Accepted 16 January 2016

Available online 9 February 2016

#### Keywords:

Dental implant

Cone beam computed tomography

(DICOM)

Emergence profile

Superimposition

CAD/CAM

### ABSTRACT

**Purpose:** This *Technical Procedure* describes a novel workflow for a one-step formation of the supra-implant emergence profile in the esthetic zone – the ‘Digitally Flip Technique’ (DFT). **Methods:** After implant placement, a post-operative intra-oral optical scan (IOS) was performed to capture the final three-dimensional implant position. Based on the superimposition of the digitally slice-wise DICOM-segmentation of the digitally flipped (mirrored) contra-lateral tooth and the STL-file of the IOS, an individualized healing abutment was CAD/CAM-fabricated out of PMMA-based restoration material in a fully digital workflow and seated at the stage of reopening surgery. One single treatment step was necessary for final modulation of the supra-implant mucosa architecture in order to mimic the morphological emergence profile of the contra-lateral tooth within a short-span time frame of four days after insertion of the individualized healing abutment.

**Conclusions:** The implant crown emergence profile could be shaped immediately after reopening according to the three-dimensional radiographic contour of the digitally flipped contra-lateral tooth. Estimating the emergence profile or time-consuming step-by-step conditioning of the mucosa through an additionally produced implant provisional was therefore avoided.

© 2016 Japan Prosthodontic Society. Published by Elsevier Ltd. This is an open access article under the CC BY-NC-ND license (<http://creativecommons.org/licenses/by-nc-nd/4.0/>).

## 1. Introduction

The successful treatment with implant-supported reconstructions in the esthetic zone remains one of the biggest challenges in fixed prosthodontics. In addition to the

exact three-dimensional implant positioning, the creation of individually shaped supra-implant mucosa architecture is crucial for a predictable esthetic outcome [1]. The development of the supra-implant soft tissue can be achieved by step-wise conditioning using a provisional crown [2].

\* Corresponding author at: Section for Digital Reconstructive Technology +Implant Dentistry [DiRecT+ID], Department of Reconstructive Dentistry & Gerodontology, School of Dental Medicine, University of Bern, Freiburgstr. 7, 3010 Bern, Switzerland. Tel.: +41 031 632 0910; fax: +41 031 632 4931.

E-mail address: [tim.joda@zmk.unibe.ch](mailto:tim.joda@zmk.unibe.ch) (T. Joda).

<http://dx.doi.org/10.1016/j.jpor.2016.01.005>

1883-1958/© 2016 Japan Prosthodontic Society. Published by Elsevier Ltd. This is an open access article under the CC BY-NC-ND license (<http://creativecommons.org/licenses/by-nc-nd/4.0/>).

However, multiple sessions are necessary for the successive modifications of the implant provisional [3]. Time-consuming work steps result in a high number of clinical appointments for the patient and the dentist [4] as well as possible biologic trauma of the fragile implant soft tissue due to repeatable changes of the implant provisional [5].

It would be of great benefit for a predictable therapy outcome if it would be possible to presume the desired prosthetic emergence profile prior to implant surgery [6]. The entire treatment sequence could be shortened knowing the morphologically correct design to stabilize and form the implant mucosa with a patient-specific healing abutment at the time of reopening or in case of immediate loading.

Therefore, the aim of this *Technical Procedure* is to introduce a novel one-step approach for CAD/CAM-production of an individualized healing abutment by means of digital segmenting the emergence profile of the contra-lateral tooth based on cone beam computed tomography (CBCT).

## 2. Material and methods

A clinical case, requiring a single implant reconstruction for the replacement of tooth 21 (Bone Level Implant Roxolid RC, Institut Straumann AG, Basel, Switzerland), was chosen to present the novel ‘Digitally Flip Technique’ (DFT) for supra-implant emergence profile formation with an individualized CAD/CAM-generated healing abutment (Fig. 1a).

After computer-assisted implant planning and placement according to a prosthetic-driven backward planning (coDiagnostiX, Dental Wings, Chemnitz, Germany), a post-operative intra-oral optical scan (IOS) was made with an implant-compatible scanbody to capture the final three-dimensional implant position (iTero Scan System, Aligentech Inc., San Jose, USA) (Fig. 1b).

During the healing phase of osseointegration, the contra-lateral tooth was used as a template for the emergence profile of the future implant reconstruction. Three-dimensional radiographic DICOM-data of the maxilla and the transferred implant information of the IOS were superimposed in the implant planning software (Fig. 1c). Based on the digitally slice-wise CBCT-segmentation of the corresponding mirrored tooth in position 11 combined with the STL-file of the IOS, an individualized healing abutment was virtually designed and CAD/CAM-fabricated out of PMMA-based restoration material in a fully digital workflow (Polycon ae, CARES Digital Solutions, Institut Straumann AG, Basel, Switzerland) (Fig. 1d). Then, a pre-fabricated bonding base (Variobase, CARES Digital Solutions, Institut Straumann AG, Basel, Switzerland) was prepared with a specialized primer and luted to the individualized PMMA-abutment with resin cement (Panavia F 2.0, Kuraray Noritake Dental Inc., Tokyo, Japan) (Fig. 2a).

Eight weeks after implant placement and sub-mucosal healing, reopening was performed with a minimally invasive roll-flap, and the individualized healing abutment with the digitally flipped emergence profile of the contra-lateral was immediately delivered (Fig. 2b). The supra-implant mucosa architecture was modulated after four days after placement of the CAD/CAM-healing abutment (Fig. 2c). Finally, the patient

was definitively restored with a one-piece screw-retained individualized Zirconium dioxide abutment plus hand-layered veneering (CARES abutment, CARES Digital Solutions, Institut Straumann AG, Basel, Switzerland). The shape of the final implant reconstruction was analogously to the individualized healing abutment (Fig. 2d).

## 3. Difference from conventional methods

The use of standardized healing abutments with a circular diameter results in a discrepancy to a patient-specific emergence profile – especially in the esthetic zone with a triangular tooth shape [7,8]. Clinicians have to choose between two treatment modalities for the finalization of the implant crown: (i) vague assumption of the emergence profile mostly defined by the dental technician, and subsequently insertion with potentially high pressure toward the fragile soft tissue; or (ii) a more predictable but time-consuming, and consequently more expensive procedure with step-wise conditioning of an implant-supported provisional combined after a customized impression transfer of the modulated mucosa architecture.

In contrast, the novel DFT allowed a predictable one-step formation of the supra-implant mucosa architecture. The virtual DICOM-segmentation of the digitally flipped contra-lateral tooth could be successfully transferred slice-wise for CAD/CAM-processing of an individualized healing abutment. The entire workflow was performed in a fully digital process without any physical models.

## 4. Effect

Digital dental processing opened the opportunity to fabricate CAD/CAM-generated implant components in combination with high-performance restoration materials [9,10]. The application of a healing abutment with an individualized shape, as a contour copy of the digitally flipped contra-lateral DICOM-segmented tooth, offered a simplified approach in esthetical demanding cases. A costly and time-intensive pre-conditioning of the mucosa with an implant-supported provisional was not needed. Besides the economic advantages of this streamlined workflow, biological compromises by means of repeating destruction of the epithelium attachment could be avoided. Moreover, poorly polished acrylic surfaces of the implant provisional due to the multiple chair-side adjustments was also no longer needed.

For future application of the DFT, an actual CBCT might not be compellingly necessary. Any existing DICOM-data of the patient could be used for radiographic tooth-segmentation and ‘copy & paste’ contouring for the formation of the final emergence profile. It might be even easier if the shape information of the tooth to be replaced would be accessible because mirroring would not be required. In addition, the gathered information of different tooth shapes could be implemented in a data bank of DICOM-segmented sample teeth, and then, case-sensitively chosen via a drop-down-menu in the specific CAD/CAM-program to produce the individualized healing abutment.

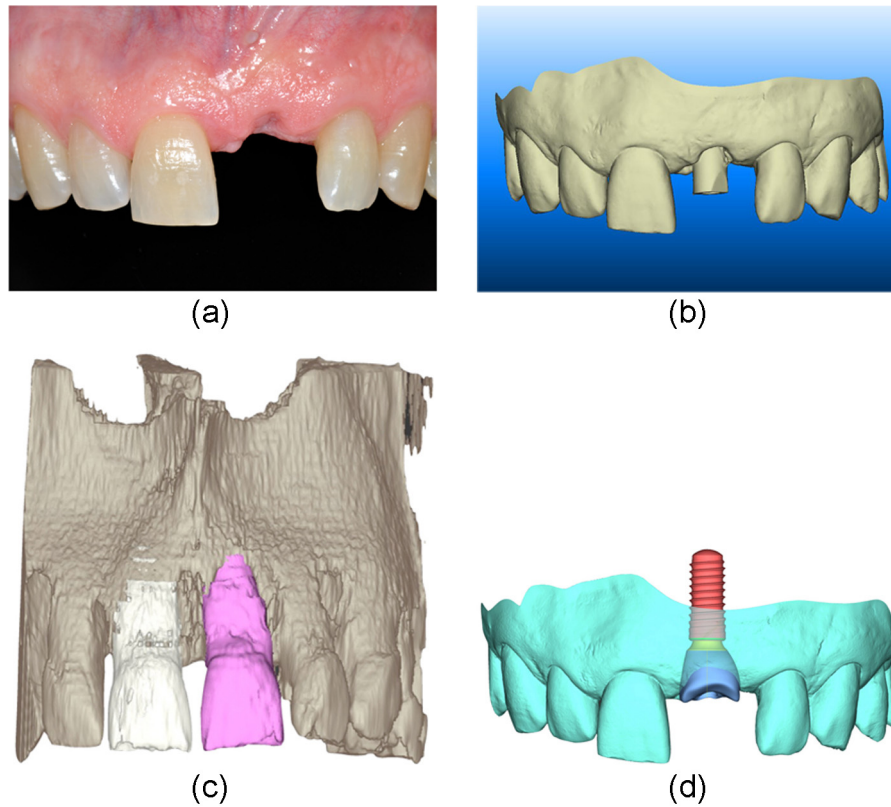


Fig. 1 – (a)–(d) Clinical situation with single tooth gap in position 21 (a), screenshot of the STL-file with inserted scanbody for detection of the final implant location (b), maxillary DICOM-data with segmented natural tooth 11 [white] and mirrored copy for visualization of the prospective emergence profile of the implant reconstruction in position 21 [pink] (c), and three-dimensional imaging of the individualized healing abutment on top of the virtual implant in position 21 (d).

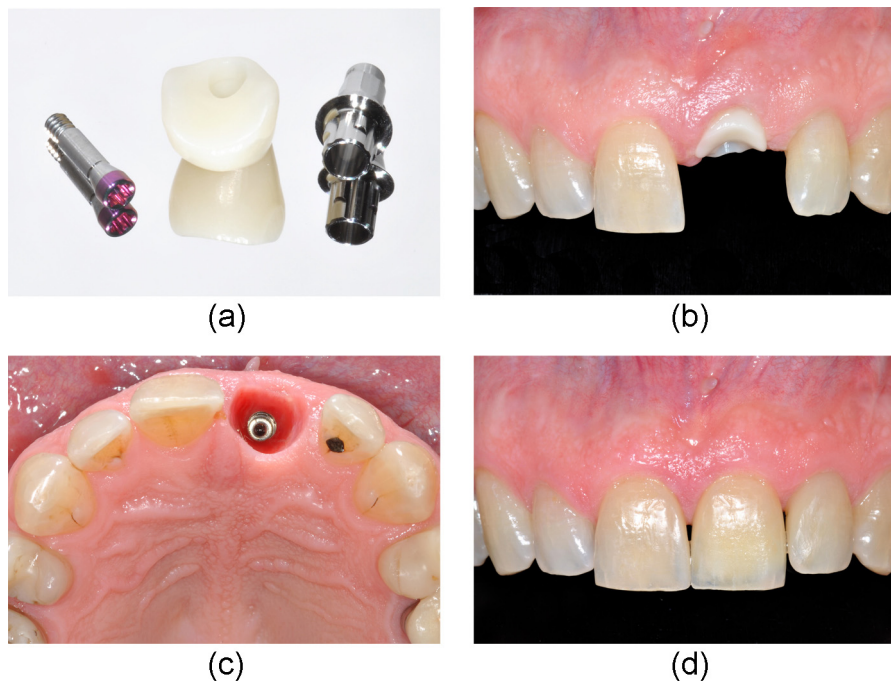


Fig. 2 – (a)–(d) Pre-fabricated bonding base plus CAD/CAM-abutment made of PMMA (a), individualized healing abutment in situ according to the digitally flipped DICOM-based contour of the contra-lateral tooth 11 (b), clinical situation of the modulated emergence profile 4 days after placement (c), and the final implant supported crown made of a manually veneered Zirconium dioxide abutment for screw-retention with an analogous shape compared to the individualized healing abutment as well as direct composite restorations each mesially on tooth 11 as well as 22 (d).

## 5. Conclusion

With the application of the DFT, the supra-implant mucosa architecture could be individually created within a single treatment step in order to mimic the morphological emergence profile of the contra-lateral tooth. Overall, there was no need for uncertain assumption of the prospective implant emergence profile, and furthermore, time-consuming supra-implant mucosa conditioning with repeatable changes of an implant provisional crown was superseded.

It has to be emphasized that the quality and the quantity of the supra-implant soft tissue as well as the vertical-horizontal positioning of the installed implant would have a major effect on the final result. Therefore, a prosthetically oriented three-dimensional placement of the implant is a key factor for a pleasant, harmonious, and predictable treatment outcome. In addition, it has to be mentioned in particular that the DFT is a novel application which has to be proven in following long-term follow-up investigations.

## Conflict of interest

The authors declare no conflict of interest.

## Acknowledgements

The authors thank Albrecht Schnapphauf (Computer Scientist, Dentalwings, Chemnitz, Germany) for the IT-support, MDT Marc Zettler (Head of Dental Laboratory, Institut Straumann AG, Basel, Switzerland) for the CAD/CAM-processing, and Dr. David Gfeller for the placement of the implant (Dentist, Department of Oral Surgery, University of Bern, Switzerland).

## REFERENCES

- [1] Buser D, Wittneben J, Bornstein MM, Grutter L, Chappuis V, Belser UC. Stability of contour augmentation and esthetic outcomes of implant-supported single crowns in the esthetic zone: 3-year results of a prospective study with early implant placement postextraction. *J Periodontol* 2011;82:342–9.
- [2] Neale D, Chee WW. Development of implant soft tissue emergence profile: a technique. *J Prosth Dent* 1994;71:364–8.
- [3] Buskin R, Salinas TJ. Transferring emergence profile created from the provisional to the definitive restoration. *Pract Perio Aesthet Dent* 1998;10:1171–9.
- [4] Wittneben J, Buser D, Belser UC, Braegger U. Peri-implant soft tissue conditioning with provisional restorations in the esthetic zone: the dynamic compression technique. *Int J Periodont Rest Dent* 2013;33:447–55.
- [5] Elian N, Tabourian G, Jalbout ZN, Classi A, Cho SC, Froum S, et al. Accurate transfer of peri-implant soft tissue emergence profile from the provisional crown to the final prosthesis using an emergence profile cast. *J Esthet Rest Dent* 2007;19:306–15.
- [6] Joda T, Wittneben JG, Braegger U. Digital implant impressions with the Individualized Scanbody Technique for emergence profile support. *Clin Oral Impl Res* 2014;25:395–7.
- [7] Chee WW. Treatment planning and soft-tissue management for optimal implant esthetics: a prosthodontic perspective. *J Cal Dent Assoc* 2003;31:559–63.
- [8] Priest G. Developing optimal tissue profiles implant-level provisional restorations. *Dent Today* 2005;24:96–100.
- [9] Joda T, Braegger U. Complete digital workflow for the production of implant-supported single-unit monolithic crowns. *Clin Oral Impl Res* 2014;25:1304–6.
- [10] Patel N. Integrating three-dimensional digital technologies for comprehensive implant dentistry. *J Am Dent Assoc* 2010;141(Suppl. 2):20–4.