



Origin and insertion of the medial patellofemoral ligament: a systematic review of anatomy

Arash Aframian^{1,2,3} · Toby O. Smith⁴ · T. Duncan Tennent^{1,2} · Justin Peter Cobb³ · Caroline Blanca Hing^{1,2}

Received: 4 March 2016 / Accepted: 3 August 2016

© The Author(s) 2016. This article is published with open access at Springerlink.com

Abstract

Purpose The medial patellofemoral ligament (MPFL) is the major medial soft-tissue stabiliser of the patella, originating from the medial femoral condyle and inserting onto the medial patella. The exact position reported in the literature varies. Understanding the true anatomical origin and insertion of the MPFL is critical to successful reconstruction. The purpose of this systematic review was to determine these locations.

Methods A systematic search of published (AMED, CINAHL, MEDLINE, EMBASE, PubMed and Cochrane Library) and unpublished literature databases was conducted from their inception to the 3 February 2016. All papers investigating the anatomy of the MPFL were eligible. Methodological quality was assessed using a modified CASP tool. A narrative analysis approach was adopted to synthesise the findings.

Results After screening and review of 2045 papers, a total of 67 studies investigating the relevant anatomy were included. From this, the origin appears to be from an area rather than (as previously reported) a single point on the medial femoral condyle. The weighted average length was 56 mm with an ‘hourglass’ shape, fanning out at both ligament ends.

Conclusion The MPFL is an hourglass-shaped structure running from a triangular space between the adductor tubercle, medial femoral epicondyle and gastrocnemius tubercle and inserts onto the superomedial aspect of the patella. Awareness of anatomy is critical for assessment, anatomical repair and successful surgical patellar stabilisation.

Level of evidence Systematic review of anatomical dissections and imaging studies, Level IV.

Keywords Medial patellofemoral ligament · Anatomy · Insertion · Origin · MPFL · Attachments · Reconstruction

Abbreviations

AA	Arash Aframian
AMT	Adductor magnus tendon
AT	Adductor tubercle
CASP	Critical appraisal skills programme
CH	Caroline Hing
CT	Computed tomography
DT	Duncan Tennent
MeSH	Medical subject headings
JC	Justin Cobb
LPD	Lateral patellar dislocation
LPFL	Lateral patellofemoral ligament
MCL	Medial collateral ligament
MFE	Medial femoral epicondyle
MPFL	The medial patellofemoral ligament
MRI	Magnetic resonance imaging
PRISMA	Preferred reporting items for systematic reviews and meta-analyses
USS	Ultrasound scan
SD	Standard deviation
TOS	Toby O Smith
VMO	Vastus magnus obliquus

✉ Arash Aframian
arash.aframian@gmail.com

¹ Trauma and Orthopaedics Department, 5th Floor St James' Wing, St George's University Hospitals NHS Foundation Trust, Blackshaw Road, London SW17 0QT, UK

² St George's, University of London, London SW17 0RE, UK

³ Imperial College, London W6 8RP, UK

⁴ Faculty of Medicine and Health Sciences, University of East Anglia, Norwich NR4 7TJ, UK

Introduction

Patellar dislocation is multi-factorial in aetiology and may involve abnormalities of the bone or soft tissues [82]. The medial patellofemoral ligament (MPFL) is a band of retinacular tissue within layer II of the medial side of knee and as the main medial soft tissue stabiliser of the patella (particularly in early flexion) is critical for tracking and stability in the trochlear groove [38, 66, 69, 81, 88, 101]. Acute lateral patellar dislocation (LPD) is associated with MPFL rupture in 87–100 %, and the significant number of different procedures to treat the problem highlights the limitations in understanding and management [5, 20, 54, 77].

Longer term, patellar instability and dislocation are associated with chondral injury and osteoarthritis [28, 54]. Non-operative management can leave 33 % with significant patient-reported symptoms, 44 % with at least one episode of further dislocation and 52 % of patients unable to return to vigorous sports at an average of 11.8-year follow-up [20]. Surgery can correct recurrent dislocation which untreated can occur in 42–49 % of patients [20, 55].

Reconstruction of the MPFL is now an accepted technique for the treatment of patellofemoral instability when soft tissues rather than bony morphology are the primary pathological feature [18, 29, 74, 88]. Performed non-anatomically, it can lead to non-physiological patellofemoral loads and kinematics which may lead to pain and increased chondral injury [7, 30, 79, 95].

Although Weber and Weber first described the anatomy of the knee in 1836, there remains no consensus on the anatomy of the MPFL or even its existence, which has been reported to be present in 35–100 % of cadaveric specimens [21, 63, 71, 76, 99]. Understanding of MPFL origin and insertion points is fundamental for functional reconstruction of the ligament thus reducing the risk of subsequent repeated instability, maltracking and osteoarthritis [45].

The aim of this study was to conduct a systematic review of the literature to define the anatomy of the MPFL.

An accurate definition of MPFL anatomy enables assessment of MPL injuries and planning anatomical reconstruction of the MPFL to restore tracking without overloading the patellofemoral joint.

Materials and methods

Search strategy

An electronic PRISMA compliant [59] search was conducted on the 3 February 2016 from database inception to the search date. Databases searched included Embase, AMED, Medline, PsycINFO, Cochrane, CINAHL, PubMed and NHS Evidence. Where available, medical subject headings (MeSH) terms were used. In addition, searches of grey literature were conducted using Google Scholar, Web of Science, OpenGrey, Ethos and the Zetoc engines. Search terms used for the MEDLINE search are presented in Table 1. This strategy was modified for the other database searches. The reference lists of all potentially eligible papers were also reviewed to identify any additional studies.

Eligibility criteria and identification

Inclusion eligibility was confirmed if publications investigated the anatomy of the MPFL, specifically origin or insertion points in human subjects. Where inclusion could not be determined from the title and subsequently abstract, the full paper was retrieved as shown in Fig. 1. Assessment of anatomy was permitted either surgically or radiologically. Papers were excluded if MPFL anatomy had been based on other data sources. Studies were eligible irrespective of language, age or country of origin.

The electronic searches were independently performed by two authors (AA, TOS). Based on the eligible criteria, the two reviewers (AA, TOS) independently screened the search results to identify potentially eligible papers. The

Table 1 Search strategy terms for the literature search of anatomy of the medial patellofemoral ligament using MEDLINE (via OVID)

1. Anatomy, Regional/or exp Anatomy/or Anatomy, Cross-Sectional/or Anatomy, Comparative/
2. Exp Knee Joint/or exp Patellofemoral Joint/
3. 1 or 2
4. Medial patellofemoral ligament.mp. [mp = title, abstract, original title, name of substance word, subject heading word, keyword heading word, protocol supplementary concept word, rare disease supplementary concept word, unique identifier]
5. 3 and 4
6. mpfl.mp. [mp = title, abstract, original title, name of substance word, subject heading word, keyword heading word, protocol supplementary concept word, rare disease supplementary concept word, unique identifier]
7. 3 and 6
8. 5 or 7

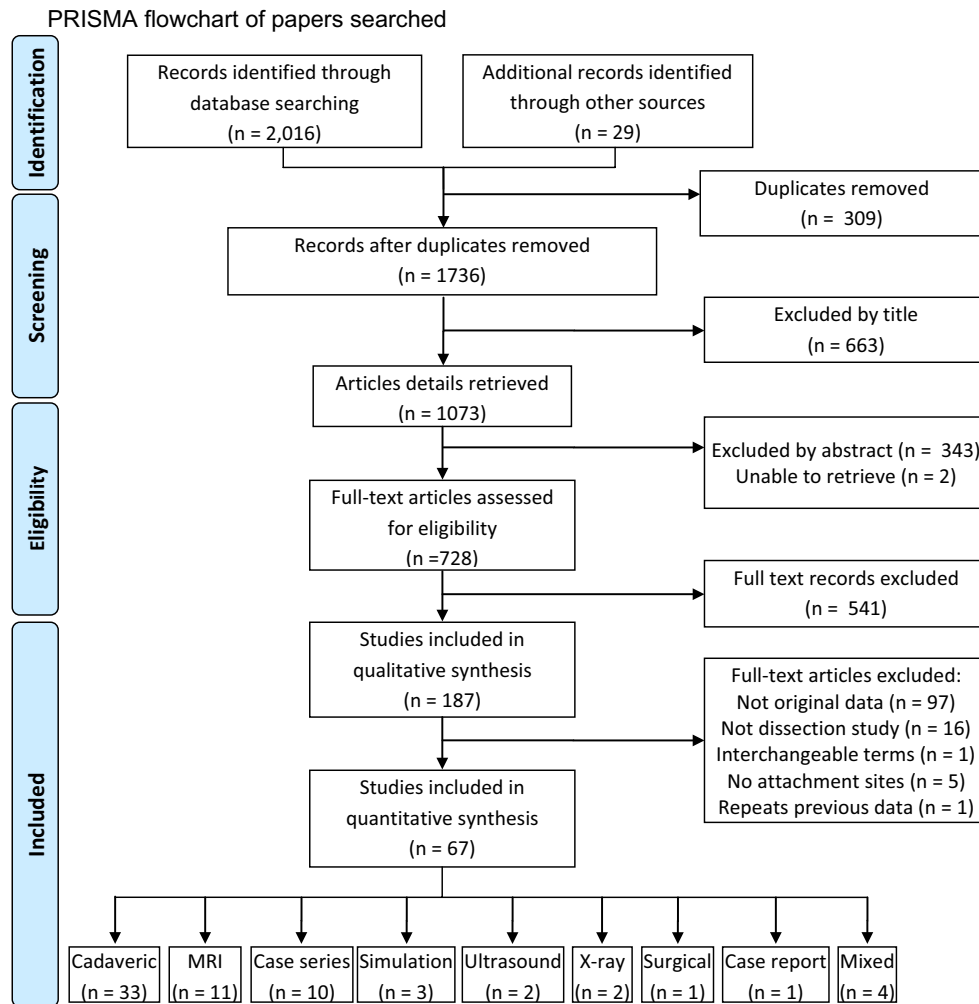


Fig. 1 PRISMA flowchart of papers searched

full-texts of all provisional papers were obtained, and a decision of final eligibility was made after reviewing these by the two reviewers (AA, TOS).

Data extraction and critical appraisal

Data extraction was made by one reviewer (AA) and repeated by a second reviewer (TOS) to check and verify the findings and accuracy of the results—there was 100 % agreement in data extracted (Fig. 1). All data were extracted into an electronic database. Data extracted included: country of origin, study type, whether the study was of normal or patellar dislocation knees and in cases following dislocation whether acute or recurrent, number of patients and knees, age, gender, preservation method (if cadaveric), MPFL identification rate and size, origin and insertion.

The quality of each included paper was evaluated using a modified critical appraisal skills programme (CASP) tool [89]. This was undertaken by one reviewer (AA) and verified by a second (TOS). Any disagreements in data extraction or quality assessment were resolved through discussion between the reviewers so that there was 100 % agreement in the assessments of cadaveric and radiological or clinical papers (Tables 2, 3).

Data analysis

Due to multiple methodologies used in the included studies, there was a high degree of study heterogeneity, and therefore, a meta-analysis was inappropriate. Accordingly, a narrative analysis was adopted to determine the consensus on MPFL identification rate, MPFL size, and origin and insertion of the MPFL from the study cohorts.

Table 2 Methodological assessment of cadaveric papers

References	Focussed question	Appropriate design	Population defined	[Ethical approval considered?]	Sample size defined by power	[Source of samples stated]	Outcome measures defined	Dissection method defined	Radiological assessment described	Observers defined	Observer reliability assessed	Multiple observations	Blinding of observer to pathology	Statistical methods described	Variance described	Inferential statistics employed	Appropriate interpretation	Generalisability	Relevance to present evidence base	Clinical relevance discussed	Total number of features met
Philippot et al. [68]	✓	✓	✓	✓	✓	✓	✓	✓	✓	✓	✓	✓	✓	✓	✓	✓	✓	✓	✓	✓	10
Panagiotopoulos et al. [65]	✓	✓	✓	✓	✓	✓	✓	✓	✓	✓	✓	✓	✓	✓	✓	✓	✓	✓	✓	✓	10
Lee et al. [49]	✓	✓	✓	✓	✓	✓	✓	✓	✓	✓	✓	✓	✓	✓	✓	✓	✓	✓	✓	✓	10
Warren and Marshall [101]	✓	✓	✓	✓	✓	✓	✓	✓	✓	✓	✓	✓	✓	✓	✓	✓	✓	✓	✓	✓	10
Reider et al. [76]	✓	✓	✓	✓	✓	✓	✓	✓	✓	✓	✓	✓	✓	✓	✓	✓	✓	✓	✓	✓	11
Tuxøe et al. [98]	✓	✓	✓	✓	✓	✓	✓	✓	✓	✓	✓	✓	✓	✓	✓	✓	✓	✓	✓	✓	11
Feller et al. [32]	✓	✓	✓	✓	✓	✓	✓	✓	✓	✓	✓	✓	✓	✓	✓	✓	✓	✓	✓	✓	11
Starok et al. [91]	✓	✓	✓	✓	✓	✓	✓	✓	✓	✓	✓	✓	✓	✓	✓	✓	✓	✓	✓	✓	11
Schöttle et al. [81]	✓	✓	✓	✓	✓	✓	✓	✓	✓	✓	✓	✓	✓	✓	✓	✓	✓	✓	✓	✓	11
Nomura et al. [62]	✓	✓	✓	✓	✓	✓	✓	✓	✓	✓	✓	✓	✓	✓	✓	✓	✓	✓	✓	✓	12
Triantafyllopoulos et al. [97]	✓	✓	✓	✓	✓	✓	✓	✓	✓	✓	✓	✓	✓	✓	✓	✓	✓	✓	✓	✓	12
Andrikoula et al. [3]	✓	✓	✓	✓	✓	✓	✓	✓	✓	✓	✓	✓	✓	✓	✓	✓	✓	✓	✓	✓	13

Table 2 continued

References	Focussed question	Appropriate design	Population defined	[Ethical approval considered?]	Sample size defined by power	[Source of samples stated]	Outcome measures defined	Dissection method defined	Radio-logical assessment described	Observers defined	Observer reliability assessed	Multiple observations	Blinding of observer to pathology	Statistical methods described	Variance described	Inferential statistics employed	Appropriate interpretation	Generalisability	Relevance to present evidence base	Clinical relevance discussed	Total number of features met
Mochizuki et al. [57]	✓	✓	✓	✓	✓	✓	✓	✓	✓	✓	✓	✓	✓	✓	✓	✓	✓	✓	✓	✓	13
Viste et al. [99]	✓	✓	✓	✓	✓	✓	✓	✓	✓	✓	✓	✓	✓	✓	✓	✓	✓	✓	✓	✓	13
Nomura et al. [60]	✓	✓	✓	✓	✓	✓	✓	✓	✓	✓	✓	✓	✓	✓	✓	✓	✓	✓	✓	✓	13
Shea et al. [83]	✓	✓	✓	✓	✓	✓	✓	✓	✓	✓	✓	✓	✓	✓	✓	✓	✓	✓	✓	✓	13
Waligora et al. [100]	✓	✓	✓	✓	✓	✓	✓	✓	✓	✓	✓	✓	✓	✓	✓	✓	✓	✓	✓	✓	13
Conlan et al. [21]	✓	✓	✓	✓	✓	✓	✓	✓	✓	✓	✓	✓	✓	✓	✓	✓	✓	✓	✓	✓	13
Jacobi et al. [44]	✓	✓	✓	✓	✓	✓	✓	✓	✓	✓	✓	✓	✓	✓	✓	✓	✓	✓	✓	✓	14
Philippot et al. [69]	✓	✓	✓	✓	✓	✓	✓	✓	✓	✓	✓	✓	✓	✓	✓	✓	✓	✓	✓	✓	14
Smirk and Morris [88]	✓	✓	✓	✓	✓	✓	✓	✓	✓	✓	✓	✓	✓	✓	✓	✓	✓	✓	✓	✓	14
Baldwin [11]	✓	✓	✓	✓	✓	✓	✓	✓	✓	✓	✓	✓	✓	✓	✓	✓	✓	✓	✓	✓	14
Desio et al. [23]	✓	✓	✓	✓	✓	✓	✓	✓	✓	✓	✓	✓	✓	✓	✓	✓	✓	✓	✓	✓	14
Fujino et al. [37]	✓	✓	✓	✓	✓	✓	✓	✓	✓	✓	✓	✓	✓	✓	✓	✓	✓	✓	✓	✓	14
Aragão et al. [4]	✓	✓	✓	✓	✓	✓	✓	✓	✓	✓	✓	✓	✓	✓	✓	✓	✓	✓	✓	✓	15
Piacella et al. [73]	✓	✓	✓	✓	✓	✓	✓	✓	✓	✓	✓	✓	✓	✓	✓	✓	✓	✓	✓	✓	15

Table 2 continued

References	Focussed question	Appropriate design	Population defined	[Ethical approval considered?]	Sample size defined by power	[Source of samples stated]	Outcome measures defined	Dissection method defined	Radio-logical assessment described	Observers defined	Observer reliability assessed	Multiple observations	Blinding of observer to pathology	Statistical methods described	Variance described	Inferential statistics employed	Appropriate interpretation	Generalisability	Relevance to present evidence base	Clinical relevance discussed	Total number of features met
Kang et al. [45]	✓	✓	✓	✓	✗	✓	✓	✓	✗	✗	✗	✗	✓	✓	✓	✓	✓	✓	✓	✓	15
Steensen et al. [92]	✓	✓	✓	✗	✗	✗	✓	✓	✓	✓	✗	✗	✓	✓	✓	✓	✓	✓	✓	✓	15
Redfern et al. [75]	✓	✓	✓	✗	✗	✗	✓	✓	✓	✗	✓	✗	✓	✓	✓	✓	✓	✓	✓	✓	15
Barnett et al. [13]	✓	✓	✓	✓	✗	✗	✓	✓	✓	✗	✗	✗	✓	✓	✓	✓	✓	✓	✓	✓	15
Shea et al. [84]	✓	✓	✓	✓	✗	✗	✓	✓	✓	✓	✗	✓	✓	✓	✗	✓	✓	✓	✓	✓	15
LaPrade et al. [48]	✓	✓	✓	✗	✗	✗	✓	✓	✓	✓	✓	✗	✓	✓	✗	✓	✓	✓	✓	✓	15
Farrow et al. [31]	✓	✓	✓	✓	✗	✗	✓	✓	✗	✗	✓	✓	✓	✓	✓	✓	✓	✓	✓	✓	16
Stephen et al. [93]	✓	✓	✓	✓	✗	✗	✓	✓	✓	✗	✓	✓	✓	✓	✓	✓	✓	✓	✓	✓	17

✓ = Satisfies criterion, ✗ = Does not meet criterion

Total score represents number of features met by paper, ascending order

Table 3 Methodological assessment of radiological and clinical papers

References	Study type	Study type	Focussed Qs	Appropriate design	Population defined	Recruitment methods described	Sample size defined by power	Study setting described	Outcome measures defined	Dissection method defined	Radiological assessment described	Observers defined	Observer reliability assessed	Multiple observations	Blinding of observer pathology	Statistical methods described	Variance described	Inferential statistics employed	Appropriate interpretation	Generalisability	Relevance to present evidence base	Clinical relevance discussed	Total number of features met
Camanho et al. [17]	Surgical		✓	✓	✓	✓	✓	✓	✓	✓	✓	✓	✓	✓	✓	✓	✓	✓	✓	✓	✓	✓	7
Lippacher and Nelitz [51]	X-ray		✓	✓	✓	✓	✓	✓	✓	✓	✓	✓	✓	✓	✓	✓	✓	✓	✓	✓	✓	✓	8
Matthews and Schranz [55]	Case series		✓	✓	✓	✓	✓	✓	✓	✓	✓	✓	✓	✓	✓	✓	✓	✓	✓	✓	✓	✓	11
Schottle et al. [81]	Mixed		✓	✓	✓	✓	✓	✓	✓	✓	✓	✓	✓	✓	✓	✓	✓	✓	✓	✓	✓	✓	11
Inoue et al. [41]	Case reports		✓	✓	✓	✓	✓	✓	✓	✓	✓	✓	✓	✓	✓	✓	✓	✓	✓	✓	✓	✓	12
Avikainen et al. [8]	Case series		✓	✓	✓	✓	✓	✓	✓	✓	✓	✓	✓	✓	✓	✓	✓	✓	✓	✓	✓	✓	12
Felus et al. [34]	USS		✓	✓	✓	✓	✓	✓	✓	✓	✓	✓	✓	✓	✓	✓	✓	✓	✓	✓	✓	✓	12
Ahmad et al. [1]	Case series		✓	✓	✓	✓	✓	✓	✓	✓	✓	✓	✓	✓	✓	✓	✓	✓	✓	✓	✓	✓	13
Deic et al. [22]	Case series		✓	✓	✓	✓	✓	✓	✓	✓	✓	✓	✓	✓	✓	✓	✓	✓	✓	✓	✓	✓	13
Nomura et al. [59]	Mixed		✓	✓	✓	✓	✓	✓	✓	✓	✓	✓	✓	✓	✓	✓	✓	✓	✓	✓	✓	✓	13
Dirim et al. [25]	Mixed		✓	✓	✓	✓	✓	✓	✓	✓	✓	✓	✓	✓	✓	✓	✓	✓	✓	✓	✓	✓	13
Phornphutkul et al. [70]	Mixed		✓	✓	✓	✓	✓	✓	✓	✓	✓	✓	✓	✓	✓	✓	✓	✓	✓	✓	✓	✓	13
Sallay et al. [77]	MRI		✓	✓	✓	✓	✓	✓	✓	✓	✓	✓	✓	✓	✓	✓	✓	✓	✓	✓	✓	✓	13

Table 3 continued

References	Study type	Study type	Focussed Qs	Appropriate design	Population defined	Recruitment methods described	Sample size defined by power	Study setting described	Outcome measures defined	Dissection method defined	Radiological assessment described	Observers defined	Observer reliability assessed	Multiple observations	Blinding of observer to pathology	Statistical methods described	Variance described	Inferential statistics employed	Appropriate interpretation	Generalisability	Reliance to present evidence base	Clinical relevance discussed	Total number of features met
Kang et al. [46]	MRI		✓	✓	✓	✓	✓	✓	✓	✓	✓	✓	✓	✓	✓	✓	✓	✓	✓	✓	✓	✓	13
Balcarek et al. [9]	MRI		✓	✓	✓	✓	✓	✓	✓	✓	✓	✓	✓	✓	✓	✓	✓	✓	✓	✓	✓	✓	13
Iwama et al. [42]	MRI		✓	✓	✓	✓	✓	✓	✓	✓	✓	✓	✓	✓	✓	✓	✓	✓	✓	✓	✓	✓	13
Nomura and Inoue [61]	Case series		✓	✓	✓	✓	✓	✓	✓	✓	✓	✓	✓	✓	✓	✓	✓	✓	✓	✓	✓	✓	14
Balcarek et al. [10]	MRI		✓	✓	✓	✓	✓	✓	✓	✓	✓	✓	✓	✓	✓	✓	✓	✓	✓	✓	✓	✓	14
Wissman et al. [103]	MRI		✓	✓	✓	✓	✓	✓	✓	✓	✓	✓	✓	✓	✓	✓	✓	✓	✓	✓	✓	✓	14
Oka et al. [63]	Simulation		✓	✓	✓	✓	✓	✓	✓	✓	✓	✓	✓	✓	✓	✓	✓	✓	✓	✓	✓	✓	14
Christiansen et al. [19]	Case series		✓	✓	✓	✓	✓	✓	✓	✓	✓	✓	✓	✓	✓	✓	✓	✓	✓	✓	✓	✓	15
Lim et al. [50]	Case series		✓	✓	✓	✓	✓	✓	✓	✓	✓	✓	✓	✓	✓	✓	✓	✓	✓	✓	✓	✓	15
Enderlein et al. [30]	Case series		✓	✓	✓	✓	✓	✓	✓	✓	✓	✓	✓	✓	✓	✓	✓	✓	✓	✓	✓	✓	15
Elias et al. [28]	MRI		✓	✓	✓	✓	✓	✓	✓	✓	✓	✓	✓	✓	✓	✓	✓	✓	✓	✓	✓	✓	15
Graf et al. [39]	Simulation		✓	✓	✓	✓	✓	✓	✓	✓	✓	✓	✓	✓	✓	✓	✓	✓	✓	✓	✓	✓	15
Bitar et al. [15]	Case series		✓	✓	✓	✓	✓	✓	✓	✓	✓	✓	✓	✓	✓	✓	✓	✓	✓	✓	✓	✓	16
Kepler et al. [47]	MRI		✓	✓	✓	✓	✓	✓	✓	✓	✓	✓	✓	✓	✓	✓	✓	✓	✓	✓	✓	✓	16

Table 3 continued

References	Study type	Study type	Focussed Qs	Appropriate design	Population defined	Recruitment methods described	Sample size defined by power	Study setting described	Outcome measures defined	Dissection method defined	Radiological assessment described	Observers defined	Observer reliability assessed	Multiple observations	Blinding of observer to pathology	Statistical methods described	Variance described	Inferential statistics employed	Appropriate interpretation	Generalizability	Relevance to present evidence base	Clinical relevance discussed	Total number of features met
De Oliveira et al. [64]	MRI		✓	✓	✓	✓	✗	✓	✓	✗	✓	✓	✓	✗	✗	✓	✓	✓	✓	✓	✓	✓	16
Yoo et al. [104]	Simulation		✓	✓	✓	✓	✗	✓	✓	✗	✓	✓	✗	✓	✗	✓	✓	✓	✓	✓	✓	✓	16
Zhang et al. [105]	USS		✓	✓	✓	✓	✗	✓	✓	✗	✓	✓	✓	✗	✗	✓	✓	✓	✓	✓	✓	✓	16
Tateishi et al. [94]	Case series		✓	✓	✓	✓	✗	✓	✓	✓	✓	✗	✓	✓	✗	✓	✓	✓	✓	✓	✓	✓	17
Sillanpää et al. [86]	MRI		✓	✓	✓	✓	✗	✓	✓	✗	✓	✓	✗	✓	✗	✓	✓	✓	✓	✓	✓	✓	17
Sillanpää et al. [87]	MRI		✓	✓	✓	✓	✗	✓	✓	✓	✓	✗	✓	✓	✓	✓	✓	✓	✓	✓	✓	✓	18
Wijdeks et al. [102]	X-ray		✓	✓	✓	✓	✗	✓	✓	✓	✓	✓	✓	✓	✗	✓	✓	✓	✓	✓	✓	✓	18

✓ = Satisfies criterion, ✗ = Does not meet criterion

Total score represents number of features met by paper, ascending order

Results

Search results

A summary of the search results is presented in Fig. 1. A total of 2045 papers were identified. Of the 187 potentially relevant papers, 67 satisfied the inclusion criteria.

Characteristics of included studies

The 67 studies included 1950 knees where the MPFL was investigated in over 1475 patients (some cadaveric studies did not state whether the knees were from the same body). Where both the average age and number of patients were given (35 studies), the weighted average age was 33 years. Gender was given in 44 publications with 613 males (48 %) and 658 females (52 %). The 67 studies were from several countries and included 764 (39 %) normal, 507 (26 %) acute dislocation, 381 (20 %) recurrent dislocation and 289 (15 %) mixed pathology knees. Investigation technique was heterogeneous (Tables 4, 5).

Characteristics by study design

Surgical studies

Surgical technique or case series reports usually describe an approach rather than study anatomy (Tables 4, 5). Five studies were of acute patellar dislocation, and seven referred to recurrent patellar dislocation. Amongst the ten papers which did specify gender, nine papers included 76 male and 77 female subjects and a single case series which reported 78 male and 162 female knees, but only 224 participants indicating that some must be from the same participants [32]. Four studies were in adults, six were mixed age groups and one did not give the age of subjects [17]. One study looked at MPFL reconstruction in children [24]. Eight papers provided the average age, giving a weighted average of 21 years for adults (9 years for children). Due to expectation bias of surgical studies, these were excluded from the final analysis.

Imaging studies

Amongst the imaging studies, there was also heterogeneity (Tables 4, 5). Eight studies were of anatomy in acute patellar dislocation, one with recurrent patellar dislocation, one in patients without any history or evidence of patellofemoral instability and five studies were a mixture of these types. There was a large variation in subjects, with an age range of 12–89 years, and average ages of 14–72 years even within imaging modalities with the two radiographic studies reporting a large variation in age range [53, 102].

Table 4 Patellar insertions of the MPFL reported

Site	References	Number of knees	
Medial patella	Panagiotopoulos et al. [65] ^a	8	
	Mochizuki et al. [57] ^a	16	
	Lee et al. [49] ^a	5	
	Starok et al. [91] ^a	5	
	Waligora et al. [100] ^a	18	
	Matthews and Schanz [55] ^e	21	
	Iwama et al. [42] ^c	25	
	Kang et al. [46] ^c	85	
	Sillanpää et al. [86] ^c	32	
	Sillanpää et al. [87] ^c	56	
Proximal	Viste et al. [99] ^a	12	
	Wissman et al. [103] ^c	10	
Proximal half	Jacobi et al. [44] ^a	20	
	Philipott et al. [69] ^a	23	
	Conlan et al. [21] ^a	25	
Proximal one third	Stephen et al. [93] ^a	8	
	Triantafillopoulos et al. [97] ^a	8	
	Placella et al. [73] ^a	20	
	Tateishi et al. [94] ^e	27	
Proximal one third to midline	Graf et al. [39] ^d	10	
	Nomura et al. [60] ^a	17	
Middle	Nomura et al. [59] ^b	27	
	Kang et al. [45] ^a	12	
	Shea et al. [84] ^a	9	
	Yoo et al. [104] ^d	10	
Proximal two thirds	Tuxøe et al. [98] ^a	39	
	Andrikoula et al. [3] ^a	10	
	Nomura et al. [62] ^a	20	
	Baldwin. [11] ^a	50	
	Inoue et al. [41] ^f	2	
	Christiansen et al. [19] ^c	42	
	Balcarek et al. [10] ^c	73	
	Balcarek et al. [9] ^c	43	
	Superomedial	LaPrade et al. [48] ^a	8
		Feller et al. [32] ^a	20
Desio et al. [23] ^a		9	
Barnett et al. [13] ^a		10	
Hautamaa et al. [40] ^a		17	
Phornphutkul et al. [70] ^b		5	
Dirim et al. [25] ^b		12	
De Oliveira et al. [64] ^c		125	
Zhang et al. [105] ^g	49		
Insertion fans out over patella and surrounding tissues	Steensen et al. [92] ^a	11	
	Fujino et al. [37] ^a	31	
	Smirk and Morris [88] ^a	25	
	Aragão et al. [4] ^a	10	

Study type: ^aCadaveric; ^bMixed; ^cMRI; ^dSimulation; ^eSeries; ^fCase report; ^gUSS

Table 5 Femoral origins of the MPFL reported

Site	Papers	Number of knees
Adductor tubercle (AT)	Starok et al. [91] ^a	5
Distal to AT	Smirk and Morris [88] ^a	25
	Viste et al. [99] ^a	12
	Jacobi et al. [44] ^a	20
	Nomura et al. [60] ^a	17
	Tuxøe et al. [98] ^a	39
	Nomura et al. [62] ^a	20
	Dirim et al. [25] ^b	12
	Lim et al. [50] ^b	27
	Medial femoral epicondyle (MFE)	Panagiotopoulos et al. [65] ^a
Mochizuki et al. [57] ^a		16
Andrikoula et al. [3] ^a		10
Steensen et al. [92] ^a		11
Reider et al. [76] ^a		48
Hautamaa et al. [40] ^a		17
Kang et al. [46] ^c		85
Philippot et al. [69] ^a		23
Placella et al. [73] ^a		20
Laprade et al. [48] ^a		8
Between MFE and AT	Fujino et al. [37] ^a	31
	Stephen et al. [93] ^a	8
	Baldwin [11] ^a	50
	Farrow et al. [31] ^a	16
	Lee et al. [49] ^a	5
	Waligora et al. [100] ^a	18
	Kang et al. [45] ^a	12
	Barnett et al. [13] ^a	10
	Schöttle et al. [81] ^a	8
	De Oliveira et al. [23] ^c	125
	Sillanpää et al. [86] ^c	32
	Balcarek et al. [10] ^c	73
	Balcarek et al. [9] ^c	43
	Yoo et al. [104] ^d	10
	Enderlein et al. [30] ^e	240
	Tateishi et al. [94] ^e	27
	Bitar et al. [15] ^e	41
	Wijdicks et al. [102] ^f	11
	Nomura et al. [59] ^b	27
	MFE and AT	Iwama et al. [42] ^c
Aragão et al. [4] ^a		17
Triantafillopoulos et al. [97] ^a		8
Anterior to MFE	Feller et al. [32] ^a	20
Adjacent to medial collateral (MCL) insertion	Deie et al. [22] ^e	6
AT with MCL	Phornphutkul et al. [70] ^b	5

Table 5 continued

Site	Papers	Number of knees
Between AT and MCL	Christiansen et al. [19] ^e	42
	Avikainen et al. [8] ^e	14
	Wissman et al. [103] ^c	10
With superficial MCL	Warren and Marshall [101] ^a	154
AT and MFE and superficial MCL	Desio et al. [23] ^a	9
Over MFE, distal to AT, partly to capsule	Inoue et al. [41] ^g	1
38 % of postero-anterior distance and 54 % of distal-proximal distance of condyle	Oka et al. [63] ^d	20
5 mm anterior to posterior cortex, 3 mm proximal to apex with Blumenfaat's line	Redfern et al. [75] ^a	8
Proximal to physis	Shea et al. [83] ^a	6
5-6 mm distal to physis	Kepler et al. [47] ^c	44
	Lippacher and Nelitz [51] ^f	27

Study type: ^aCadaveric; ^bMixed; ^cMRI; ^dSimulation; ^eSeries; ^fX-ray; ^gCase report

AT adductor tubercle, MFE medial femoral condyle, MCL medial collateral ligament

Another study which correlated magnetic resonance imaging (MRI) findings to histology reported that in two of five knees examined, the MPFL attached to the medial femoral epicondyle (MFE) with the medial collateral ligament (MCL) [27].

Cadaveric studies

The methodological assessment of the 33 cadaveric studies is shown in Table 2. Cadaveric studies were in knees which the authors believed to be normal, and different cadaveric preservation techniques were used, with eighteen fresh frozen, eight embalmed, two unpreserved and the remainder using more than one preservation method (five papers) or not describing the preservation technique used (four papers).

To determine possible variations in anatomy (particularly knee size and MPFL length) based on height of subjects or cadavers, the origin countries for papers were recorded, and particularly if they described the source of the cadavers for dissection studies. Only nine of the 33 cadaveric studies specifically stated where the knees were sourced from.

For the others, even if all authors were from the same country, then this was recorded separately as cadavers may be obtained and transported from a different country.

In total amongst the 33 studies, there were 705 cadaveric knees (range 5–154, median 16). These were mostly adult knees (29/33 papers) given that paediatric cadavers (3/33 papers) are not readily available [33]. One study did not specify the age range [51]. For the purposes of this review, skeletal maturity was defined as closure of the distal femoral physis. Amongst the adult cadaveric studies, the median of the average ages reported amongst the 18 papers that provided this information was 71 (range 19–100) years and when number of patients was also given (12 papers), the weighted average was 75 years in this subset. Cadaveric specimens do not accurately reflect the age of the patients typically seen with patellar dislocation or instability as demonstrated by the largest case series in this review of 224 patients with a median age of 23 years [32]. Likewise, of the three paediatric groups, one was of children aged 1 month–11 years [83].

There were also discrepancies with gender representation in cadaveric studies. Of the studies of adults, only 18/33 recorded the gender of subjects (158 male, 121 female), in contrast to the usual finding in patellofemoral instability of more female than male patients [37]. There was no significant difference in laterality of knees in the cadaveric papers.

Quality assessment

The results of the CASP assessment are presented in Tables 2, 3. The overall quality of the evidence was strong with several studies scoring highly in the quality analysis and overlap of results.

Recurrent weaknesses of the cadaveric literature were that none of the studies were based on a sample size calculation, the source of the cadaveric samples were only presented in 26 % of papers and the observer or assessor was only defined in 12 % of papers. Only two studies amongst the radiological and clinical based their sample size on a power calculation, the assessor was only defined in 29 % of papers, observer reliability was ascertained in 21 % of papers, and only 36 % of studies recorded measures from multiple observations (Table 3).

Anatomy of MPFL synthesis findings

MPFL identification rate

Data on MPFL identification rate were given in 28 studies. Earlier studies reported that the MPFL was not identified in all knees, raising a question about whether it was always present. In this systematic review, documented

identification of the MPFL varied from 35 to 92 % in four studies, 24 studies described 100 % identification of the MPFL and five did not specifically state the rate of identification, but did not report difficulty identifying the ligament.

MPFL size

Data on MPFL length were presented in 19 papers. There was no obvious relationship to country of origin, or method of study with both the shortest (45 mm) and the longest (74 mm) reported MPFL lengths being from Japan and China, respectively. A single USS review article had reported a length of 40 mm but did not state whether this value was actually measured and was therefore excluded [22]. The weighted MPFL mean length and the unweighted median of the averages were both 56 mm. The reliability of reported length is in part dependent on the difficulty in measuring it. More specifically, it has a broad insertion onto the patella 20–30 mm wide, being largely on the proximal medial border, with some fibres extending to the lower third in a minority of cases [65]. Similarly, the femoral origin of the ligament covers an area of around 10–22 mm width [65]. With such broad attachment points, it is difficult to know whether the different studies were measuring the same length.

An MRI study reported a 0.1 mm greater thickness of the MPFL in men than in women (1.0 and 0.9 mm, respectively), whilst another reported statistically significant ($p < 0.001$) increasing MPFL length when comparing normal, unstable and recurrently dislocating patellae at 49, 54 and 64 mm, respectively [23, 44]. In contrast, MPFL lengths from 47 to 72 mm were reported in normal knees so it is unclear whether there is a direct correlation between patellar stability and ligament length, particularly given differences in measurement methods [65, 72]. This difference was also not explained by source of specimens (both cadaveric) or preservation method (both fresh frozen).

Investigating normal and acute MPFL injury MRI scans, a Japanese study reported average lengths of 53 and 49 mm in normal men and women, whereas a Chinese publication reported average MPFL length of 59 mm in acute patellar dislocation [44, 48]. This would seem, then, to support the concept that MPFL length is increased in patellar dislocation. What is not known is whether these patients dislocate because they had longer MPFLs or whether they had longer MPFLs because they have dislocated and the injured MPFL heals longer than it was prior to injury. There was evidence that the MPFL ruptured once elongated beyond 12–18 mm and so even a first episode of patellar dislocation would result in injury [2]. Although the Chinese paper did not provide length separately by gender, the distribution of participants in papers was not dissimilar, being 4:6 and 32:53 males to females, respectively.

Origin and insertion of the MPFL from the study cohorts

There were only four paediatric studies and they were not easily comparable as one related to the patellar attachment alone and another publication by the same authors was related to the physis alone [83, 84]. Of the two remaining paediatric papers, one reported attachment next to the superficial MCL attachment and the other in the sulcus between the adductor tubercle (AT) and the medial femoral epicondyle (MFE), which covers a similar area [24, 33].

Fifteen of the studies were of acute patellar dislocation, forty in normal knees, nine in recurrent dislocation and three were a mixture of acute and recurrent. Again, there was no significant difference in attachment points reported, with a mixture of locations given in each group.

Data on MPFL femoral origin were given in 33 papers and MPFL patellar insertion in 29 papers (Tables 4, 5). There was excellent correlation on the insertion of the MPFL onto the medial patella but some discordance regarding which part precisely (Table 4; Fig. 2). There is evidence that the MPFL fans out and may have attachments distributed along the medial border, with 13 % upper third only, seven percent middle third only, 40 % upper and middle thirds, 13 % middle and lower thirds and 27 % along the whole length [4]. The patellar insertion measures

24 ± 5 (standard deviation, SD) mm, and given that the articular surface of the patella is 46 mm long, there was overlap in reports of the patellar insertion (the insertion is half the length of the articular surface) [12, 67].

The greatest variations in anatomy described were of the femoral origin of the MPFL, with several sites reported in the literature (Table 5; Fig. 2). The size of the femoral origin itself varied with the width reported as 9–17 mm [4, 65, 72]. Compared to the width of the MFE and length of the MPFL itself, this is relatively large with the femoral attachment covering an area rather than a discrete point. To compare normal cadaveric knees to those with recurrent dislocation, the literature relevant to surgery for recurrent dislocation was reviewed. Many were excluded through screening as they referred to the MPFL origin without stating where this was found, or citing other papers [40, 85]. Where given, the attachment was within similar boundaries and covered an area that was more posterior and proximal to the medial epicondyle [17].

Discussion

The most important finding of this review was that the MPFL originates between the medial femoral epicondyle, adductor tubercle and gastrocnemius tubercle and inserts on to the superomedial aspect of the patella with an average length of 56 mm.

Studies have shown that a non-anatomical surgical reconstruction can lead to aberrant restraining forces and patellofemoral contact pressures [14, 26, 30]. Mal-positioning of the femoral insertion in the distal or proximal plane has been shown to have the most significant effect on isometry [93]. However, authors investigating the isometric and non-isometric attachment sites at the medial femoral epicondyle and adductor tubercle, respectively, did not find a significant difference in the contact pressures [57] and this may be explained by the relatively large attachment points that we have found with our systematic review. Use of the attachment areas (Fig. 2) rather than a specific point may be a truer representation of the normal anatomy, and this may provide a safe working window for graft attachment during MPFL reconstruction.

The literature search revealed no prior systematic reviews specifically investigating MPFL anatomy, and we are aware of only one review of the anatomy in 2015 with several more studies published on the subject in the interim. Their review had a number of limitations. The papers reviewed were limited chronologically to the 20 years prior to the literature search with a more limited search of the grey literature performed. Although the authors describe the mean length and the approximate area of the femoral attachment, there was no consensus given

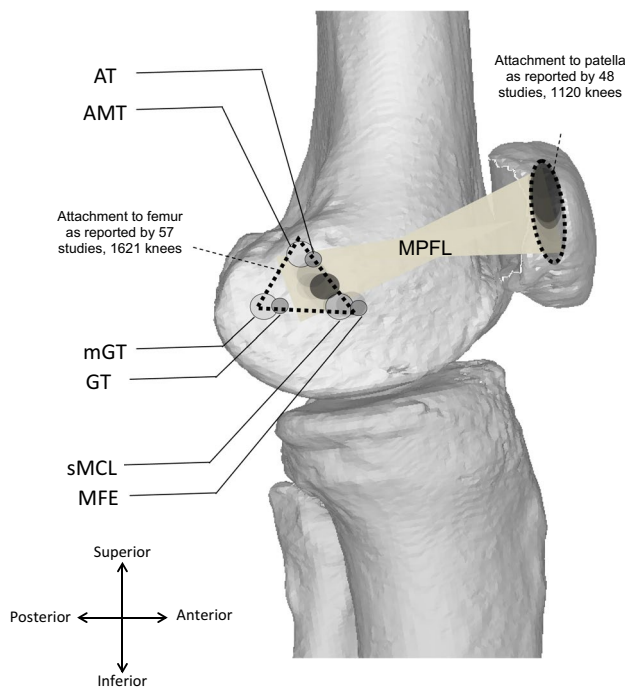


Fig. 2 Diagram summarising the MPFL attachment areas, darker shading represents study concordance. *AT* adductor tubercle, *AMT* adductor magnus tendon, *GT* gastrocnemius tubercle, *mGT* medial gastrocnemius tendon, *sMCL* superficial medial collateral ligament, *MFE* medial femoral condyle

and it was difficult to translate this conclusion into a meaningful surgical planning tool [73]. Further, they stated that the MPFL had a ‘sail type’ shape, but in our wider review of the literature above, we have shown that it not only fans out at the patellar insertion but also at the femoral insertion, with a narrow central portion and is therefore shaped like an hourglass (Fig. 2).

Some issues also arise from nomenclature as the terminal part of the medial ridge of the linea aspera of the femur becomes the adductor tubercle. Previous studies have reported that publications have described the attachments interchangeably [11, 65] (regarding [93, 98]) [80].

Many of the studies looked at normal knees, not knees with patellar instability, and this may not be a true reflection of knees where the MPFL has been injured. Previous epidemiological studies demonstrated that patellar dislocation typically occurs during adolescence yet all but a handful of specifically paediatric studies using cadavers were in elderly adults [37, 96]. There may be age-related changes in the ligament which should be considered given that some cases of recurrent instability are reported to improve without surgical intervention [6]. Within paediatric studies, there were differences in reporting (if measured proximal or distal to the physis) due to concavity of the growth plate [53]. Cadaveric studies do not reflect the gender bias with a 3:1 risk ratio for females to males aged 10–17 years for previous subluxation or dislocation, whereas cadaveric specimens were generally gender-balanced [37].

Imaging studies also have limitations, with both CT and MRI affected by partial volume loss between axial slices when the raw image data are obtained, and further losses within each slice from averaging algorithms. In addition, there was bias with more positive identification in patients with patellar dislocation or injury because the MPFL is more easily identified in patients with an effusion than in control patients [31]. In specialist studies, identification or exclusion of MPFL injuries using USS has been shown to have 100 % sensitivity, specificity, negative and positive predictive values compared to subsequent surgical findings, and has the added advantage of dynamic imaging to look at the integrity of the ligament with respect to function [35].

Whilst studies have shown that the femoral fixation point in MPFL reconstruction is more important than the patellar fixation point, a non-anatomical femoral fixation point is not in isolation predictive of graft failure. Sanchez-Alfonso et al. investigated the influence of femoral fixation site on ligament dynamic changes and clinical outcome in 24 patients with 3D CT reconstruction. They found that out of 24 patients with a non-anatomical femoral graft fixation site, only four were defined as failures. Out of these four failures, three had anterior knee pain and only one had recurrent instability. They concluded that whilst reproducing an anatomical femoral fixation

point was a reproducible way of achieving an optimal result, a non-anatomical femoral fixation site that reproduced graft isometry specifically during 0°–30° of flexion will still produce a satisfactory result [78]. This can also be explained by our study that has shown that the MPFL is hourglass in shape which may explain the satisfactory results obtained with previous studies investigating a ‘non-anatomic’ graft placement.

Warren and Marshall reported that the MPFL forms the inferior part of an anatomical space of triangular shape formed by the MPFL with the adductor magnus tendon (AMT) and the vastus medialis obliquus (VMO), with the femoral origin lying between MFE and AT [101], although the MPFL was not always easily identified.

One cadaveric dissection study included inspection for collateral knee structures in 20 cases, finding 13 had a lateral patellofemoral ligament (LPFL), and six of these also had a MPFL, whereas one specimen had a MPFL only [76]. They reported a finding of MPFL breadth of 5–12 mm in seven specimens. The MPFL superior border meets the oblique distal fibres of the vastus medialis obliquus, and there is wide variation in angle and differing origins and insertions, so there may be an underestimation of how often the MPFL is present. A 2008 study reported the ligament present in 15 of 17 cases (88 %) [4]. More recent studies have reported that the MPFL can be very thin, but is consistently seen at dissection [2, 16].

Knowledge of the anatomical origin and insertion points enables accurate assessment of potential injury and surgical repair or reconstruction, particularly in recurrent patellar dislocation. Understanding of key anatomical differences between normal and dislocation groups can guide surgical planning where lack of attention and understanding of attachment sites has been linked to a significant proportion of poor outcome in patients undergoing surgery [90].

Future studies with larger numbers of demographically linked (younger, proportionately more female) patients with and without patellar instability would be useful to confirm the findings of this systematic review. Whilst the instability group may be more easily available for surgical exploration, this will not represent the normal MPFL given the almost universal MPFL rupture rate from a single dislocation episode and the high rates of trochlear dysplasia.

Conclusion

The MPFL is hourglass in shape, originates from the medial femur and inserts onto the medial patellar border with an average length of 56 mm.

Acknowledgements This study was supported by a grant from Orthopaedic Research UK.

Authors' contributions AA, TOS, DT, CH: Study design, data analysis. AA, TOS, DT, CH, JC: Study write-up.

Compliance with ethical standards

Conflict of interests Mr Arash Aframian: None—MD(Res) student. Dr Smith: Grants in primary care research from South Norfolk Clinical Commissioning Group. Grants in patellofemoral instability research from Action Arthritis (Norfolk). Mr Tennent: Consultancy for and royalties from Arthrex. Miss Hing: ORUK (Orthopaedic Research UK) grants. AOUK (Arbeitsgemeinschaft für Osteosynthesefragen UK) grants. St George's Hospital Charity Grant. Editorial stipend Elsevier. Professor Cobb: Grants in hip surgery with DePuy. Advisory panel for hip preservation for Zimmer Biomet. Consultancy for hip arthroplasty for JRI. Consultancy for knee arthroplasty for Zimmer Biomet. Founder and shareholder for Embody. Founder and shareholder for Orthonika. Multi-centre grant for hip device with JRI. Royalties for knee arthroplasty with MatOrtho. Royalties for transcatheter limb salvage device with Stanmore Orthopaedics.

Open Access This article is distributed under the terms of the Creative Commons Attribution 4.0 International License (<http://creativecommons.org/licenses/by/4.0/>), which permits unrestricted use, distribution, and reproduction in any medium, provided you give appropriate credit to the original author(s) and the source, provide a link to the Creative Commons license, and indicate if changes were made.

References

- Ahmad CS, Shubin Stein BE, Matuz D, Henry JH (2000) Immediate surgical repair of the medial patellar stabilizers for acute patellar dislocation. A review of eight cases. *Am J Sports Med* 28:804–810
- Amis AA, Firer P, Mountney J, Senavongse W, Thomas NP (2003) Anatomy and biomechanics of the medial patellofemoral ligament. *Knee* 10:215–220
- Andrikoula S, Tokis A, Vasilidis HS, Georgoulis A (2006) The extensor mechanism of the knee joint: an anatomical study. *Knee Surg Sports Traumatol Arthrosc* 14:214–220
- Aragão JA, Reis FP, de Vasconcelos DP, Feitosa VLC, Nunes MAP (2008) Metric measurements and attachment levels of the medial patellofemoral ligament: an anatomical study in cadavers. *Clinics (Sao Paulo)* 63:541–544
- Arendt EA, Fithian DC, Cohen E (2002) Current concepts of lateral patella dislocation. *Clin Sports Med* 21:499–519
- Arnbjörnsson AH, Egund N, Rydning O, Stockerup R, Ryd L (1992) The natural history of recurrent dislocation of the patella. Long-term results of conservative and operative treatment. *J Bone Joint Surg Br* 74:140–142
- Arthrex (2010) Medial Patellofemoral Ligament: Surgical Technique. http://www.arthrex.com/resources/surgical-technique-guide/sjxx_kEEeCRTQBQVoRHOW/medialpatellofemoral-ligament-mpfl
- Avikainen VJ, Nikku RK, Seppänen-Lehmonen TK (1993) Adductor magnus tenodesis for patellar dislocation. Technique and preliminary results. *Clin Orthop Relat Res* 297:12–16
- Balcarek P, Ammon J, Frosch S, Walde TA, Schüttrumpf JP, Ferlemann KG, Lill H, Stürmer KM, Frosch K-H (2010) magnetic resonance imaging characteristics of the medial patellofemoral ligament lesion in acute lateral patellar dislocations considering trochlear dysplasia, patella alta, and tibial tuberosity–trochlear groove distance. *Arthroscopy* 26:926–935
- Balcarek P, Alexander T, Frosch S, Schüttrumpf JP, Wachowski MM, Stürmer KM, Frosch K-H (2011) Patellar dislocations in children, adolescents and adults: a comparative MRI study of medial patellofemoral ligament injury patterns and trochlear groove anatomy. *Eur J Radiol* 79:415–420
- Baldwin JL (2009) The anatomy of the medial patellofemoral ligament. *Am J Sports Med* 37:2355–2361
- Baldwin JL, House CK (2005) Anatomic dimensions of the patella measured during total knee arthroplasty. *J Arthroplasty* 20:250–257
- Barnett AJ, Howells NR, Burston BJ, Ansari A, Clark D, Eldridge JD (2012) Radiographic landmarks for tunnel placement in reconstruction of the medial patellofemoral ligament. *Knee Surg Sports Traumatol Arthrosc* 20:2380–2384
- Beck P, Brown NAT, Greis PE, Burks RT (2007) Patellofemoral contact pressures and lateral patellar translation after medial patellofemoral ligament reconstruction. *Am J Sports Med* 35:1557–1563
- Bitar AC, Demange MK, D'Elia CO, Camanho GL (2012) Traumatic patellar dislocation: nonoperative treatment compared with MPFL reconstruction using patellar tendon. *Am J Sports Med* 40:114–122
- Boden BP, Pearsall AW, Garrett W, Feagin J (1997) Patellofemoral instability: evaluation and management. *J Am Acad Orthop Surg* 5:47–57
- Camanho GL, Bitar AC, Hernandez AJ, Olivi R (2007) Medial patellofemoral ligament reconstruction: a novel technique using the patellar ligament. *Arthroscopy* 23:108.e1–108.e4
- Camanho GL, Ph D, Viegas ADC, Sc M, Bitar AC, Sc M, Demange MK, Sc M, Hernandez AJ, Ph D (2009) Conservative versus surgical treatment for repair of the medial patellofemoral ligament in acute dislocations of the patella. *Arthroscopy* 25:620–625
- Christiansen SE, Jakobsen BW, Lund B, Lind M (2008) Isolated repair of the medial patellofemoral ligament in primary dislocation of the patella: a prospective randomized study. *Arthroscopy* 24:881–887
- Cofield RH, Bryan RS (1977) Acute dislocation of the patella: results of conservative treatment. *J Trauma* 17:526–531
- Conlan T, Garth WP, Lemons JE (1993) Evaluation of the medial soft-tissue restraints of the extensor mechanism of the knee. *J Bone Joint Surg Am* 75:682–693
- De Maeseneer M, Marcellis S, Boulet C, Kichouh M, Shahabpour M, de Mey J, Cattrysse E (2014) Ultrasound of the knee with emphasis on the detailed anatomy of anterior, medial, and lateral structures. *Skeletal Radiol* 43:1025–1039
- De Oliveira V, De Souza V, Cury R, Camargo OP, Avanzi O, Severino N, Fucs P (2014) Medial patellofemoral ligament anatomy: is it a predisposing factor for lateral patellar dislocation? *Int Orthop* 38:1633–1639
- Deie M, Ochi M, Sumen Y, Yasumoto M, Kobayashi K, Kimura H (2003) Reconstruction of the medial patellofemoral ligament for the treatment of habitual or recurrent dislocation of the patella in children. *J Bone Joint Surg Br* 85:887–890
- Desio SM, Burks RT, Bachus KN (1998) Soft tissue restraints to lateral patellar translation in the human knee. *Am J Sports Med* 26:59–65
- DeVries Watson N, Duchman KR, Bollier MJ, Grosland NM (2015) A finite element analysis of medial patellofemoral ligament reconstruction. *Iowa Orthop J* 35:13–19
- Dirim B, Haghghi P, Trudell D, Portes G, Resnick D (2008) Medial patellofemoral ligament: cadaveric investigation of anatomy with MRI, MR arthrography, and histologic correlation. *Am J Roentgenol* 191:490–498
- Dirisamer F, Anderl C, Liebensteiner M, Hochreiter J (2014) Operative Therapie der isolierten patellofemorale Arthrose. *Orthopade* 43:432–439

29. Duchman KR, DeVries N, McCarthy M, Kuiper JJ, Grossland NM, Bollier MJ (2013) Biomechanical evaluation of medial patellofemoral ligament reconstruction. *Iowa Orthop J* 33:64–69
30. Elias JJ, Cosgarea AJ (2006) Technical errors during medial patellofemoral ligament reconstruction could overload medial patellofemoral cartilage: a computational analysis. *Am J Sports Med* 34:1478–1485
31. Elias DA, White LM, Fithian DC (2002) Acute lateral patellar dislocation at MR imaging: injury patterns of medial patellar soft-tissue restraints and osteochondral injuries of the inferomedial patella. *Radiology* 225:736–743
32. Enderlein D, Nielsen T, Christiansen SE, Faunø P, Lind M (2014) Clinical outcome after reconstruction of the medial patellofemoral ligament in patients with recurrent patella instability. *Knee Surg Sports Traumatol Arthrosc* 22:2458–2464
33. Farrow LD, Alentado VJ, Abdulnabi Z, Gilmore A, Liu RW (2014) The relationship of the medial patellofemoral ligament attachment to the distal femoral physis. *Am J Sports Med* 42:2214–2218
34. Feller MJ, Feagin JA Jr, Garrett WE Jr (1993) The medial patellofemoral ligament revisited: an anatomical study. *Knee Surg Sports Traumatol Arthrosc* 1:184–186
35. Felus J, Kowalczyk B (2012) Age-related differences in medial patellofemoral ligament injury patterns in traumatic patellar dislocation: case series of 50 surgically treated children and adolescents. *Am J Sports Med* 40:2357–2364
36. Felus J, Kowalczyk B, Lejman T (2008) Sonographic evaluation of the injuries after traumatic patellar dislocation in adolescents. *J Pediatr Orthop* 28:397–402
37. Fithian DC, Paxton EW, Lou Stone M, Silva P, Davis DK, Elias DA, White LM (2004) Epidemiology and natural history of acute patellar dislocation. *Am J Sports Med* 32:1114–1121
38. Frosch S, Balcarek P, Walde TA, Schüttrumpf JP, Wachowski MM, Ferleman K-G, Stürmer KM, Frosch K-H (2011) The treatment of patellar dislocation: a systematic review. *Z Orthop Unfall* 149:630–645
39. Fujino K, Tajima G, Yan J, Kamei Y, Maruyama M, Takeda S, Kikuchi S, Shimamura T (2015) Morphology of the femoral insertion site of the medial patellofemoral ligament. *Knee Surg Sports Traumatol Arthrosc* 23:998–1003
40. Goorens CK, Robijn H, Hendrickx B, Delpoort H, De Mulder K, Hens J (2010) Reconstruction of the medial patellofemoral ligament for patellar instability using an autologous gracilis tendon graft. *Acta Orthop Belg* 76:398–402
41. Graf M, Diether S, Vlachopoulos L, Fucentese S, Fürnstahl P (2014) Automatic string generation for estimating in vivo length changes of the medial patellofemoral ligament during knee flexion. *Med Biol Eng Comput* 52:511–520
42. Hautamaa PV, Fithian DC, Kaufman KR, Daniel DM, Pohlmeier AM (1998) Medial soft tissue restraints in lateral patellar instability and repair. *Clin Orthop Relat Res* 349:174–182
43. Inoue M, Nomura E, Sugiura H, Kobayashi S (2006) Histological findings of avulsion tear-type medial patellofemoral ligament injury in acute patellar dislocation. *J Clin Pathol* 60:1068–1069
44. Iwama Y, Fujii M, Shibamura H, Muratsu H, Kurosaka M, Kawamitsu H, Sugimura K (2006) High-resolution MRI using a microscopy coil for the diagnosis of recurrent lateral patellar dislocation. *Radiat Med Med Imaging Radiat Oncol* 24:327–334
45. Iwano T, Kurosawa H, Tokuyama H, Hoshikawa Y (1990) Roentgenographic and clinical findings of patellofemoral osteoarthritis. With special reference to its relationship to femorotibial osteoarthritis and etiologic factors. *Clin Orthop Relat Res* 252:190–197
46. Jacobi M, Reischl N, Bergmann M, Bouaicha S, Djonov V, Magnussen RA (2012) Reconstruction of the medial patellofemoral ligament using the adductor magnus tendon: an anatomic study. *Arthroscopy* 28:105–109
47. Kang HJ, Wang F, Chen BC, Su YL, Zhang ZC, Yan CB (2010) Functional bundles of the medial patellofemoral ligament. *Knee Surg Sports Traumatol Arthrosc* 18:1511–1516
48. Kang HJ, Wang F, Chen BC, Zhang YZ, Ma L (2013) Non-surgical treatment for acute patellar dislocation with special emphasis on the MPFL injury patterns. *Knee Surg Sports Traumatol Arthrosc* 21:325–331
49. Kepler CK, Bogner EA, Hammoud S, Malcolmson G, Potter HG, Green DW (2011) Zone of injury of the medial patellofemoral ligament after acute patellar dislocation in children and adolescents. *Am J Sports Med* 39:1444–1449
50. LaPrade RF, Engebretsen AH, Ly TV, Johansen S, Wentorf FA, Engebretsen L (2007) The anatomy of the medial part of the knee. *J Bone Joint Surg Am* 89:2000–2010
51. Lee HS, Choi JY, Ha JK, Lee YS, Yoo JH, Kim MK, Kim JG (2011) Anatomical reconstruction of the medial patellofemoral ligament: development of a novel procedure based on anatomical dissection. *J Korean Orthop Assoc* 46:443
52. Lim AKS, Chang HC, Hui JHP (2008) Recurrent patellar dislocation: reappraising our approach to surgery. *Ann Acad Med Singapore* 37:320–323
53. Lippacher S, Nelitz M (2012) Femorale Insertion des medialen patellofemorale Ligaments in Relation zur distalen femoralen Wachstumsfuge [The femoral insertion of the medial patellofemoral ligament in relation to the distal femoral growth plate]. *Arthroscopie* 25:275–279
54. Macnab I (1952) Recurrent dislocation of the patella. *J Bone Joint Surg Am* 34:957–967 (**passim**)
55. Mäenpää H, Huhtala H, Lehto MUK (1997) Recurrence after patellar dislocation. *Acta Orthop Scand* 68:424–426
56. Matthews JJ, Schranz P (2010) Reconstruction of the medial patellofemoral ligament using a longitudinal patellar tunnel technique. *Int Orthop* 34:1321–1325
57. Melegari TM, Parks BG, Matthews LS (2008) Patellofemoral contact area and pressure after medial patellofemoral ligament reconstruction. *Am J Sports Med* 36:747–752
58. Mochizuki T, Nimura A, Tateishi T, Yamaguchi K, Muneta T, Akita K (2013) Anatomic study of the attachment of the medial patellofemoral ligament and its characteristic relationships to the vastus intermedius. *Knee Surg Sports Traumatol Arthrosc* 21:305–310
59. Moher D, Liberati A, Tetzlaff J, Altman DG, The PRISMA Group (2009) Preferred reporting items for systematic reviews and meta-analyses: the PRISMA statement (Reprinted from *Annals of Internal Medicine*). *PLOS Med* 6(e1000097):1–6
60. Nomura E, Inoue M (2006) Hybrid medial patellofemoral ligament reconstruction using the semitendinous tendon for recurrent patellar dislocation: minimum 3 years' follow-up. *Arthroscopy* 22:787–793
61. Nomura E, Horiuchi Y, Kihara M (2000) Medial patellofemoral ligament restraint in lateral patellar translation and reconstruction. *Knee* 7:121–127
62. Nomura E, Horiuchi Y, Inoue M (2002) Correlation of MR imaging findings and open exploration of medial patellofemoral ligament injuries in acute patellar dislocations. *Knee* 9:139–143
63. Nomura E, Inoue M, Osada N (2005) Anatomical analysis of the medial patellofemoral ligament of the knee, especially the femoral attachment. *Knee Surg Sports Traumatol Arthrosc* 13:510–515

64. Oka S, Matsushita T, Kubo S, Matsumoto T, Tajimi H, Kurosaka M, Kuroda R (2014) Simulation of the optimal femoral insertion site in medial patellofemoral ligament reconstruction. *Knee Surg Sports Traumatol Arthrosc* 22:2364–2371
65. Panagiotopoulos E, Strzelczyk P, Herrmann M, Scuderi G (2006) Cadaveric study on static medial patellar stabilizers: the dynamizing role of the vastus medialis obliquus on medial patellofemoral ligament. *Knee Surg Sports Traumatol Arthrosc* 14:7–12
66. Panagopoulos A, van Niekerk L, Triantafillopoulos I (2008) MPFL reconstruction for recurrent patella dislocation: a new surgical technique and review of the literature. *Int J Sports Med* 29:359–365
67. Philippot R, Chouteau J, Wegrzyn J, Testa R, Fessy MH, Moyen B (2009) Medial patellofemoral ligament anatomy: implications for its surgical reconstruction. *Knee Surg Sports Traumatol Arthrosc* 17:475–479
68. Philippot R, Chouteau J, Farizon F, Moyen B (2011) Anatomy of the medial patellofemoral ligament and implications for its surgical reconstruction. *J Bone Joint Surgery Br* 93:507
69. Philippot R, Boyer B, Testa R, Farizon F, Moyen B (2012) Study of patellar kinematics after reconstruction of the medial patellofemoral ligament. *Clin Biomech* 27:22–26
70. Phornphutkul C, Sekiya JK, Wojtys EM, Jacobson JA (2007) Sonographic imaging of the patellofemoral medial joint stabilizing structures: findings in human cadavers. *Orthopedics* 30:472–478
71. Pinskerova V, Maquet P, Freeman M (2000) Writings on the knee between 1836 and 1917. *J Bone Joint Surg Br* 82:1100–1102
72. Placella G, Tei MM, Sebastiani E, Criscenti G, Speziali A, Mazzola C, Georgoulis A, Cerulli G (2014) Shape and size of the medial patellofemoral ligament for the best surgical reconstruction: a human cadaveric study. *Knee Surg Sports Traumatol Arthrosc* 22:2327–2333
73. Placella G, Tei M, Sebastiani E, Speziali A, Antinolfi P, Delcogliano M, Georgoulis A, Cerulli G (2015) Anatomy of the medial patello-femoral ligament: a systematic review of the last 20 years literature. *Musculoskelet Surg Milan* 99:93–103
74. Reagan J, Kullar R, Burks R (2015) MPFL reconstruction technique and results. *Orthop Clin North Am* 46:159–169
75. Redfern J, Kamath G, Burks R (2010) Anatomical confirmation of the use of radiographic landmarks in medial patellofemoral ligament reconstruction. *Am J Sports Med* 38:293–297
76. Reider B, Marshall JL, Koslin B, Ring B, Girgis FG (1981) The anterior aspect of the knee joint. *J Bone Joint Surg Am* 63:351–356
77. Sallay PI, Poggi J, Speer KP, Garrett WE (1995) Acute dislocation of the patella. A correlative pathoanatomic study. *Am J Sports Med* 24:52–60
78. Sanchis-Alfonso V, Ramirez-Fuentes C, Montesinos-Berry E, Domenech J, Martí-Bonmatí L (2015) Femoral insertion site of the graft used to replace the medial patellofemoral ligament influences the ligament dynamic changes during knee flexion and the clinical outcome. *Knee Surg Sports Traumatol Arthrosc* 1–9. doi:10.1007/s00167-015-3905-0
79. Schottle PB, Schmeling A, Rosenstiel N, Weiler A (2007) Radiographic landmarks for femoral tunnel placement in medial patellofemoral ligament reconstruction. *Am J Sports Med* 35:801–804
80. Schöttle PB, Fucetese SF, Romero J (2005) Clinical and radiological outcome of medial patellofemoral ligament reconstruction with a semitendinosus autograft for patella instability. *Knee Surg Sports Traumatol Arthrosc* 13:516–521
81. Schöttle PB, Hensler D, Imhoff AB (2010) Anatomical double-bundle MPFL reconstruction with an aperture fixation. *Knee Surg Sports Traumatol Arthrosc* 18:147–151
82. Senavongse W, Amis AA (2005) The effects of articular, retinacular, or muscular deficiencies on patellofemoral joint stability. *J Bone Joint Surg Br* 87:577–582
83. Shea KG, Polousky JD, Jacobs JC, Ganley TJ, Aoki SK, Grimm NL, Parikh SN (2014) The relationship of the femoral physis and the medial patellofemoral ligament in children: a cadaveric study. *J Pediatr Orthop* 34:808–813
84. Shea KG, Polousky JD, Jacobs JC, Ganley TJ, Aoki SK, Grimm NL, Parikh SN (2015) The patellar insertion of the medial patellofemoral ligament in children: a cadaveric study. *J Pediatr Orthop* 35:e31–e35
85. Siebold R, Borbon CAV (2012) Arthroscopic extraarticular reconstruction of the medial patellofemoral ligament with gracilis tendon autograft-surgical technique. *Knee Surg Sports Traumatol Arthrosc* 20:1245–1251
86. Sillanpää PJ, Peltola E, Mattila VM, Kiuru M, Visuri T, Pihlajamäki H (2009) Femoral avulsion of the medial patellofemoral ligament after primary traumatic patellar dislocation predicts subsequent instability in men: a mean 7-year nonoperative follow-up study. *Am J Sports Med* 37:1513–1521
87. Sillanpää PJ, Salonen E, Pihlajamäki H, Mäenpää HM (2014) Medial patellofemoral ligament avulsion injury at the patella: classification and clinical outcome. *Knee Surg Sports Traumatol Arthrosc* 22:2414–2418
88. Smirk C, Morris H (2003) The anatomy and reconstruction of the medial patellofemoral ligament. *Knee* 10:221–227
89. Smith TO, Nichols R, Harle D, Donell ST (2009) Do the vastus medialis obliquus and vastus medialis longus really exist? A systematic review. *Clin Anat* 22:183–199
90. Spritzer CE, Courneya DL, Burk DL, Garrett WE, Strong JA (1997) Medial retinacular complex injury in acute patellar dislocation: MR findings and surgical implications. *Am J Roentgenol* 168:117–122
91. Starok M, Lenchik L, Trudell D, Resnick D (1997) Normal patellar retinaculum: MR and sonographic imaging with cadaveric correlation. *Am J Roentgenol* 168:1493–1499
92. Steensen RN, Dopirak RM, McDonald WG (2004) The anatomy and isometry of the medial patellofemoral ligament: implications for reconstruction. *Am J Sports Med* 32:1509–1513
93. Stephen JM, Lumpaopong P, Deehan DJ, Kader D, Amis AA (2012) The medial patellofemoral ligament: location of femoral attachment and length change patterns resulting from anatomic and nonanatomic attachments. *Am J Sports Med* 40:1871–1879
94. Tateishi T, Tsuchiya M, Motosugi N, Asahina S, Ikeda H, Cho S, Muneta T (2011) Graft length change and radiographic assessment of femoral drill hole position for medial patellofemoral ligament reconstruction. *Knee Surg Sports Traumatol Arthrosc* 19:400–407
95. Thauinat M, Erasmus PJ (2009) Management of overtight medial patellofemoral ligament reconstruction. *Knee Surg Sports Traumatol Arthrosc* 17:480–483
96. Tompkins MA, Arendt EA (2015) Patellar instability factors in isolated medial patellofemoral ligament reconstructions-what does the literature tell us?: a systematic review. *Am J Sports Med* 43:2318–2327
97. Triantafillopoulos IK, Panagopoulos A, van Niekerk L (2007) Isometric behavior of the reconstructed medial patellofemoral ligament using two different femoral pulleys: a cadaveric study. *Med Sci Monit* 13:BR181–R187
98. Tuxøe JJ, Teir M, Winge S, Nielsen PL (2002) The medial patellofemoral ligament: a dissection study. *Knee Surg Sports Traumatol Arthrosc* 10:138–140
99. Viste A, Chatelet F, Desmarchelier R, Fessy M-H (2014) Anatomical study of the medial patello-femoral ligament: landmarks for its surgical reconstruction. *Surg Radiol Anat* 36:733–739

100. Waligora AC, Johanson NA, Hirsch BE (2009) Clinical anatomy of the quadriceps femoris and extensor apparatus of the knee. *Clin Orthop Relat Res* 467:3297–3306
101. Warren LF, Marshall JL (1979) The supporting structures and layers on the medial side of the knee: an anatomical analysis. *J Bone Joint Surg Am* 61:56–62
102. Wijdicks CA, Griffith CJ, LaPrade RF, Johansen S, Sunderland A, Arendt EA, Engebretsen L (2009) Radiographic identification of the primary medial knee structures. *J Bone Joint Surg Am* 91:521–529
103. Wissman RD, Verma S, Kreeger M, Robertson M (2009) Extensor mechanism injuries in tibiofemoral dislocations. *J Comput Assist Tomogr* 33:145–149
104. Yoo Y, Chang HG, Seo Y, Byun JC, Lee GK, Im H, Song SY (2012) Changes in the length of the medial patellofemoral ligament: an in vivo analysis using 3-dimensional computed tomography. *Am J Sports Med* 40:2142–2148
105. Zhang GY, Zheng L, Shi H, Qu SH, Ding HY (2013) Sonography on injury of the medial patellofemoral ligament after acute traumatic lateral patellar dislocation: injury patterns and correlation analysis with injury of articular cartilage of the inferomedial patella. *Injury* 44:1892–1898