



Swansea University  
Prifysgol Abertawe



## Cronfa - Swansea University Open Access Repository

---

This is an author produced version of a paper published in :

*Microsurgery*

Cronfa URL for this paper:

<http://cronfa.swan.ac.uk/Record/cronfa18860>

---

### Paper:

Enajat, M., Rozen, W., Whitaker, I., Smit, J., Van Der Hulst, R. & Acosta, R. (2010). The deep inferior epigastric artery perforator flap for autologous reconstruction of large partial mastectomy defects. *Microsurgery*, 31(1), 12-17.

<http://dx.doi.org/10.1002/micr.20829>

---

This article is brought to you by Swansea University. Any person downloading material is agreeing to abide by the terms of the repository licence. Authors are personally responsible for adhering to publisher restrictions or conditions. When uploading content they are required to comply with their publisher agreement and the SHERPA RoMEO database to judge whether or not it is copyright safe to add this version of the paper to this repository.

<http://www.swansea.ac.uk/iss/researchsupport/cronfa-support/>

# THE DEEP INFERIOR EPIGASTRIC ARTERY PERFORATOR FLAP FOR AUTOLOGOUS RECONSTRUCTION OF LARGE PARTIAL MASTECTOMY DEFECTS

MORTEZA ENAJAT, M.D., B.A.,<sup>1</sup> WARREN M. ROZEN, M.B.B.S., B.Med.Sc., P.G.Dip.Surg.Anat., Ph.D.,<sup>2\*</sup>  
IAIN S. WHITAKER, B.A. (Hons), M.A. Cantab., M.B.B.Chir., M.R.C.S., Ph.D.,<sup>1,2</sup> JEROEN M. SMIT, M.D.,<sup>1</sup>  
RENE R. W. J. VAN DER HULST, M.D., Ph.D.,<sup>1</sup> and RAFAEL ACOSTA, M.D., E.B.O.P.R.A.S.<sup>1</sup>

**Background:** Breast conservation surgery in the treatment of early stage breast cancer has become increasingly utilized as a means to avoiding mastectomy. While partial mastectomy defects (PMDs) may often be cosmetically acceptable, some cases warrant consideration of reconstructive options, and while several reconstructive options have been described in this role, a series of deep inferior epigastric perforator (DIEP) flaps has not been reported to date. **Methods:** A cohort of 18 patients undergoing PMD reconstruction with a DIEP flap were included. Patient-specific data, operation details, cosmetic results, and complication rates were assessed. Oncologic outcomes, in particular recurrence rates, were also evaluated. **Results:** In our series there were no cases of partial or total flap necrosis, and overall complications were low. There were two cases of wound infection (both had undergone radiotherapy), managed conservatively, and one case of reoperation due to hematoma. There were no cancer recurrences or effect on oncologic management. Cosmetic outcome was rated as high by both patients and surgeon. The results were thus comparable with other reconstructive options. **Conclusion:** Although autologous reconstruction has an established complication rate, our results suggest that the DIEP flap may be of considerable value for delayed reconstruction of selected larger partial mastectomy defects. © 2010 Wiley-Liss, Inc. *Microsurgery* 31:12–17, 2011.

**B**reast conservation surgery (BCS) is widely the treatment of choice for early stage breast cancer, with BCS shown to significantly reduce breast deformity and minimize the invasiveness of breast cancer treatment, without compromising oncologic outcomes.<sup>1–3</sup> Although BCS can preserve an adequate amount of breast tissue to avoid the use of reconstructive techniques, unacceptable disfigurement remains a problem in up to 30% of patients, many of whom will opt for reconstruction of their partial mastectomy defect (PMD).<sup>4,5</sup> In such cases, a variety of reconstructive options have been described, ranging from immediate reconstruction with local tissue advancement or rotation, or with prosthetic implants.<sup>6</sup> The use of distant autologous options have included latissimus dorsi flaps,<sup>7</sup> transverse rectus abdominis myocutaneous (TRAM) flaps,<sup>8</sup> and the superficial inferior epigastric artery (SIEA) flap,<sup>9</sup> all of which have been effective in this setting.

The deep inferior epigastric artery (DIEA) perforator (DIEP) flap has been popularized for postmastectomy reconstruction, and offers a range of advantages over the other reconstructive options described.<sup>10,11</sup> It has been

shown to have a consistent blood supply, versatility in volume and shape, and a donor site profile considerably superior to other myocutaneous flap options.<sup>10,11</sup> While free flaps based on the DIEA have been described in postmastectomy breast reconstruction and in augmentation mammoplasty, reports of their use in the reconstruction of PMDs are limited to case reports only.<sup>12,13</sup> The current study is the first to consider the DIEP flap in this role in a consecutive series of patients, providing a detailed assessment of outcomes and comparing this approach with other established reconstructive options.

## METHODS

The study comprised a cohort of 18 consecutive patients with PMDs after BCS for breast carcinoma. All patients were recruited through a single reconstructive surgeon at a single institution, with all referrals through a single oncologic surgeon at the same institution. BCS was planned based on a tumor size of 3 cm or less, lack of palpable axillary lymph nodes, and the absence of distant metastases. Adjuvant radiotherapy, chemotherapy, and endocrine therapies and all oncologic follow-up were dictated by the oncologic surgeon, and the decision for reconstruction was made between patient and oncologic surgeon. All patients were delayed reconstructions, with a minimum of 6 months following oncologic surgery before any of the referrals were made. While over 20% of patients in this series did not have adjuvant radiotherapy (see Table 1), delayed reconstruction was selected in all cases as a means to avoiding any delay in the administration of adjuvant therapy and to minimize the effects of radiotherapy (on both the skin paddle and subcutaneous

<sup>1</sup>Department of Plastic Surgery, Uppsala Clinic Hospital, Uppsala, 75185, Sweden

<sup>2</sup>Department of Anatomy and Cell Biology, Jack Brockhoff Reconstructive Plastic Surgery Research Unit, The University of Melbourne, Grattan St, Parkville, 3050, Victoria, Australia

\*Correspondence to: Warren M. Rozen, M.B.B.S., B.Med.Sc., P.G.Dip.Surg. Anat., Ph.D., Department of Anatomy and Cell Biology, Jack Brockhoff Reconstructive Plastic Surgery Research Unit, The University of Melbourne, Grattan St, Parkville, 3050, Victoria, Australia.  
E-mail: warrenrozen@hotmail.com

Received 11 June 2010; Accepted 20 July 2010

Published online 6 December 2010 in Wiley Online Library (wileyonlinelibrary.com). DOI 10.1002/micr.20829

**Table 1.** Patient Demographic and Oncologic Details

Demographic data		
Mean age (years)		53.5 (SD = 8.2); range: 34–66
Oncologic details		
Tumor size (maximal dimension) (mm)		mean 23 (SD = 8)
Tumor histology		
Ductal carcinoma in situ (%)		22%
Invasive ductal carcinoma (%)		56%
Invasive lobular carcinoma (%)		22%
Adjuvant radiotherapy		14/18 (78%)
Adjuvant chemotherapy		5/18 (28%)
Adjuvant endocrine therapy		9/18 (50%)
Axillary staging		
None		2/18 (11%)
Sentinel lymph node biopsy		1/18 (6%)
Axillary clearance		15/18 (83%)

SD = standard deviation.

tissues of the flap). However, in cases where it is known that radiotherapy is not going to be used, immediate reconstruction may certainly be considered. The reconstructive options were discussed in each case, with decision for DIEP flap partial breast reconstruction made between patient and reconstructive surgeon.

Demographic data was collected in each case, including age, associated risk factors, and oncologic data which included tumor specifics, the use of adjuvant therapies, and axillary staging (see Table 1). Operative outcomes and complications were assessed, with patients followed up every 6 months following reconstruction, and a minimum of 3 years follow-up in each case. Cosmetic outcome was evaluated qualitatively by both the surgeon and patients, with patients asked for their subjective opinion (poor, average, good) and surgeons asked to assess outcome based on shape, symmetry, and overall appearance (poor, average, good).

### Surgical Technique

Surgical approach to DIEP flap harvest was performed in a routine manner, as per full mastectomy reconstruction, with a full lower abdominal ellipse marked preoperatively, and DIEA perforators marked on the abdomen based on localization with imaging. This preoperative flap planning was achieved with the use of computed tomographic angiography (CTA) imaging in all cases, aiding perforator selection and the planning of flap harvest (see Table 2).

In all cases a two-surgeon team was used, with one team undertaking flap harvest and the other preparing recipient vessels. The DIEA and deep inferior epigastric vein (DIEV) comprised the donor vessels in all cases, and the recipient vessels were the internal mammary artery (IMA) and veins (IMVs) or the circumflex scapula artery and veins, and the cephalic vein used as a source of

**Table 2.** Operative Details

Operative details	
Timing	0 immediate/18 delayed
Sides	18 unilateral/0 bilateral
Defect	
Upper medial quadrant	1/18 (6%)
Upper lateral quadrant	10/18 (56%)
Lower medial quadrant	2/18 (11%)
Lower lateral quadrant	5/18 (28%)
Preoperative imaging (donor site)	18 Doppler ultrasound/18 computed tomographic angiography (CTA)
Imaging findings	18/18 cases suitable deep inferior epigastric artery (DIEA) perforators >1 mm
Imaging concordance	100% concordance Doppler ultrasound and CTA
Primary donor vessels	Deep inferior epigastric artery/vein (all cases)
Primary recipient vessels	Internal mammary artery/vein or circumflex scapula artery/vein
Secondary donor vein	Superficial inferior epigastric veins (all cases)
Secondary recipient vein	Cephalic vein (all cases)

secondary venous drainage (see Table 2). In all cases, the defect was extended to the chest wall, with selective undermining of the remaining breast tissue at the level of the pectoral fascia, and exposure of internal mammary perforators and the circumflex scapula vessels. Selection of the vascular pedicle was then made based on the ability for relative exposure of the vascular pedicle, proximity of the defect to the exposed pedicles, and the effect of radiotherapy changes on the exposed vascular pedicles. As such, there was no correlation between the location of the defect and the chosen recipient pedicle. Arterial anastomoses were sutured in all cases, while venous anastomoses were performed with a microvascular anastomotic coupling device (Microvascular Anastomotic Coupling System, Synovis Micro Companies Alliance, St Paul, MN).

After venous anastomosis has been completed, an implantable Doppler probe is placed around the veins to monitor anastomotic patency during inseting and in the postoperative period (Cook-Swartz implantable Doppler probe; Cook Medical<sup>®</sup>, Cook Ireland, Limerick, Ireland). Postoperative monitoring was achieved with a combination of the implantable Doppler probe and clinical assessment, and all cases were monitored for 7 postoperative days.

### Statistical Analysis

Data is presented as population means, with standard deviations and/or 95% confidence intervals of differences given. Statistical analysis was performed using statistical package for the social sciences (SPSS) for Windows (version 16.0, SPSS Incorporated, Chicago, IL).

## RESULTS

Eighteen patients underwent delayed, unilateral DIEP flap breast reconstruction of a PMD. Mean patient age was 53.5 years (range 34–66), patients had a range of body habitus (no patients were morbidly obese), and mean time interval between initial BCS and reconstruc-

**Table 3.** Operative Outcomes

Operative complications (n/%)	
Complete flap loss	0 (0%)
Partial flap loss	0 (0%)
Arterial thrombosis	0 (0%)
Venous thrombosis	0 (0%)
Venous congestion	1/18 (6%)
Hematoma	1/18 (6%)
Superficial wound infection	2/18 (11%)
Fat necrosis	1/18 (6%)
Seroma	0 (0%)
Reoperation	1/18 (6%)
Donor site morbidity	
Abdominal weakness (subjective or objective)	0 (0%)
Abdominal bulge	0 (0%)
Abdominal herniation	0 (0%)
Oncologic outcomes (n/%)	
Delays in administering adjuvant therapies	0 (0%)
Tumor recurrence	0 (0%)
Cosmetic outcomes	
Patient-rated score (mean)	high
Surgeon-rated score (mean)	high

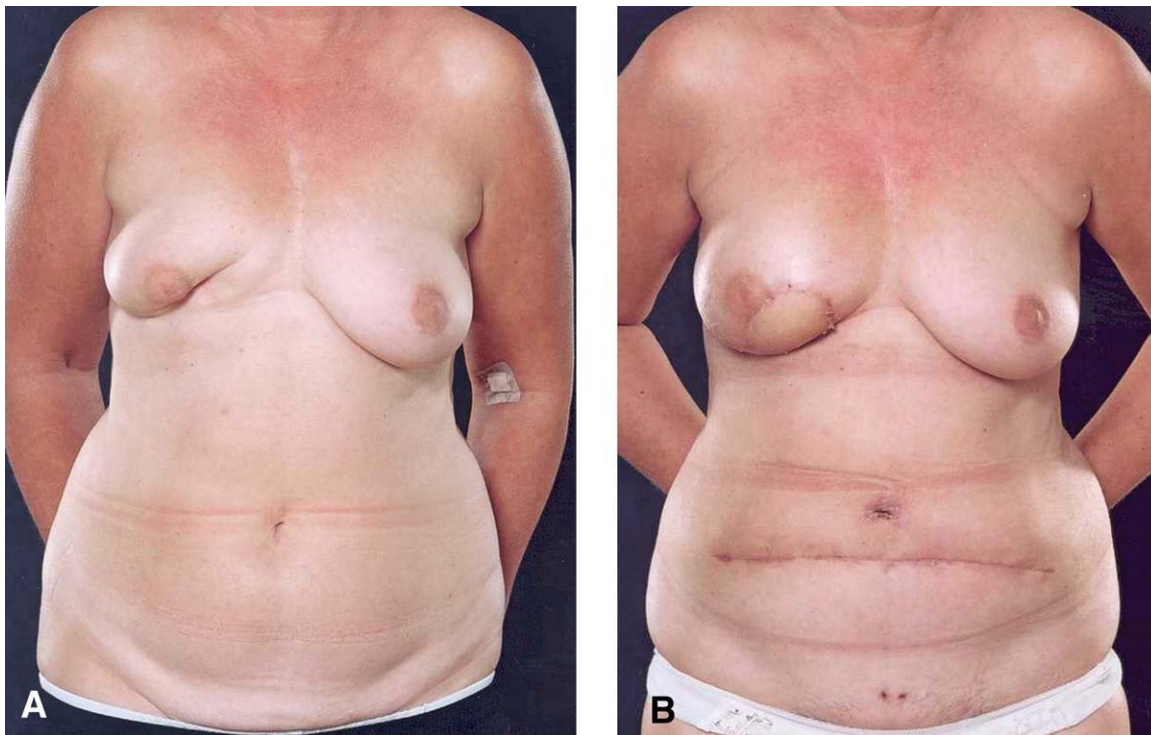
tion was 2.4 years. Patients had relatively large tumors (mean size 23 mm) and a range of tumor histology. Adjuvant therapies were used in the majority of cases (see Table 1), with 14 of the 18 patients having undergone adjuvant radiotherapy (mean dosage of 50 Gy).

All defects were considered deforming by the patient, and were all large defects in small to medium sized breasts. The majority of defects were in the lateral half of the breast (15/18 = 83% of cases).

There was only one major complication in the series, comprising a hematoma requiring return to theater (see Table 3). Otherwise, there were no cases of partial or total flap necrosis, no anastomotic revisions, and overall complications were low. There were two cases of wound infection (both had undergone radiotherapy), managed conservatively. There was no donor site morbidity on either subjective questioning or examination at any follow-up appointments. There were no cancer recurrences or effect on oncologic management. Cosmetic outcome was rated as high by both patients and surgeon in all cases (see Figs. 1A and 1B).

## DISCUSSION

BCS has become increasingly utilized in the management of breast cancer, and while cosmetic outcomes may be achieved in many cases, BCS can include a broad



**Figure 1.** **A:** Preoperative photograph of a patient with a right partial mastectomy defect (PMD). **B:** Postoperative photograph after deep inferior epigastric artery perforator (DIEP) flap reconstruction of the partial mastectomy defect (PMD). [Color figure can be viewed in the online issue, which is available at [wileyonlinelibrary.com](http://wileyonlinelibrary.com).]



spectrum of resection volumes, and thus preservation of an adequate amount of breast tissue for esthetically pleasing outcomes may not be uniform. Specific predictors of an unsatisfactory result after BCS included large tumor size relative to the size of the breast and the use of radiotherapy. Reconstructive options have thus been sought, including single-stage implant-based reconstruction, with or without the use of tissue expansion, autologous reconstruction using local tissue or free flaps, and reconstruction using a combination of autologous tissue and prosthetic implants.

Reconstruction with the use of prosthetic implants has been proposed as technically easier and less invasive compared to autologous reconstruction, and with quicker convalescence may require shorter hospitalization times.<sup>14-16</sup> However, there are notable disadvantages with the use of implants when compared to autologous reconstruction. Where tissue expansion is needed, the use of expansion can be associated with pain for the patient, and where irradiation has been performed (a majority of BCS cases) tissue expansion can be problematic and associated with increased pain and inadequate expansion. Implant-related complications are also of concern, with the risk of infection, capsular contracture, and implant extrusion markedly increased in the presence of irradiated tissue.<sup>14,15</sup>

Given these problems, autologous tissue reconstruction has been described as a preferred option.<sup>15,17</sup> While the effects of radiotherapy are certainly more marked for implant-based reconstruction, the effects on autologous tissues are certainly a concern, and our preference is to delay reconstruction in all cases. These effects can occur on both fat and skin, with the effects on subcutaneous fat most feared, with fat necrosis not uncommon after irradiation.<sup>18</sup> A recent review by Losken and Hamdi provided a comprehensive overview of reconstructive options after PMDs.<sup>19</sup> While reconstructive options with local tissue or flaps were clearly outlined and described as preferred options, the use of distant flaps in this setting were not extensively explored. Given the increasingly low complication rates described in the literature and in our experience, free tissue transfer is fast becoming a safe and potentially improved reconstructive option in this setting. In fact, Kronowitz et al. found free tissue transfer to PMDs to have significantly less complications compared to local tissue options.<sup>6</sup> One particular benefit of free tissue transfer is the ability to inset the flap into defects in all four quadrants of the breast with relative ease. Local tissue flaps require somewhat more planning in this regard. The thoracodorsal artery perforator flap is of particular benefit for lateral and central defects, similar to that of the latissimus dorsi myocutaneous flap.<sup>6,17,20</sup> Medial defects are more difficult to reconstruct with local options, and may be particularly suited to free flap recon-

struction. In addition, many patients do not have sufficient volume within local tissue for such an option.

Autologous options described in the setting of BCS include the use of local tissue,<sup>6</sup> free latissimus dorsi myocutaneous flaps,<sup>7</sup> muscle-sparing TRAM flaps,<sup>8</sup> SIEA flaps,<sup>9</sup> and thoracodorsal artery perforator (TDAP) flaps.<sup>17</sup> While we prefer the DIEP flap, with its known benefits in terms of versatility in shape and volume and its good donor site profile, other authors have offered other options, each with their own morbidity profiles. The latissimus dorsi flap has been described with rates of partial flap loss of 6%, total flap loss of 2%, and an overall complication rate of 33%,<sup>21</sup> and being a denervated musculocutaneous flap, volume changes with muscle atrophy can be problematic. Similarly, the pedicled and free muscle-sparing TRAM flaps described in this setting are associated with worse donor site outcomes than the DIEP flap.<sup>8,10,11,22,23</sup> The DIEP flap has a long pedicle for ease of reconstruction of all breast defects, is widely outside of the irradiated field, and has been associated with good donor- and flap-related outcomes in many reported series. The current series highlights that the complication rates of DIEP flaps in the repair of PMDs are similar to that in postmastectomy reconstruction, and to delayed reconstruction after BCS using other reconstructive options. The good cosmetic results universally reported add to these benefits. The additional esthetic benefit of the abdominoplasty was noted by many patients.

In the current series, a DIEP flap was used in all cases, with this decision made based on surgeon and patient preference after performing a preoperative CTA for vascular mapping. The CTA is used to define the dominant vascular supply to the lower abdominal wall, with all perforators over 1 mm identified, and the superficial inferior epigastric artery (SIEA) also identified. While we do consider the use of an SIEA flap, the SIEA itself is frequently absent altogether or too small for use in free tissue transfer, and thus the DIEP flap is preferred, as occurred in all cases of the current series.<sup>24</sup> In cases where a SIEA flap may be considered, the same lower abdominal ellipse would be designed, with flap design based on the course of the SIEA as demonstrated on CTA. An additional technical consideration is the use of a skin paddle as part of the flap. In all cases within this series, there was a skin defect included as part of the partial mastectomy specimen, and/or radiation changes that warranted excision. The skin paddle of the DIEP flap was thus useful for reconstruction of such a deficit, and also able to be used as a monitoring paddle for postoperative monitoring of the flap clinically. A de-epithelialized flap may be used where skin is not required, with the flap inset as a buried flap, and able to be monitored postoperatively with an implantable Doppler probe.<sup>25,26</sup>

While the argument exists for preservation of the abdominal donor site for the case of future need for post-mastectomy reconstruction, recurrence rates in patients having undergone BCS after breast cancer are low overall, with only 5–8% requiring salvage mastectomy.<sup>14,16</sup> In these few cases, other satisfactory reconstructive options (both prosthetic and autologous) still remain and thus preservation of this tissue in up to 95% of cases where it can be effectively used may not be warranted. Case selection is thus highly important in employing this reconstructive option, with clear margins, lack of regional spread, and time to reconstruction all important selection considerations. With no detriment to oncologic outcomes identified in the current series, it is pertinent that postreconstruction oncologic follow-up is essential, with timely administration of adjuvant therapies, ongoing clinical examination and mammography, and consideration of advanced imaging technologies all important. Magnetic resonance imaging (MRI) in particular has been shown to be useful in this setting.<sup>27,28</sup> The majority of local recurrences after BCS are known to occur within the first 2 years of presentation,<sup>1</sup> and while recurrence rates of 5–8% over a 5-year period are described,<sup>1,2</sup> delayed reconstruction minimizes the need for revision surgery. The longer the interval between BCS and reconstruction, the more likely it is that recurrence is detected prior to reconstruction, and we prefer delayed reconstruction for this reason.

## CONCLUSION

BCS has become a valuable option in the treatment of breast cancer, but does not rule out the need for breast reconstruction. There are many variables that can influence the choice of reconstruction in this setting, and thus many options have been described. We have described our experience with the use of the DIEP flap in delayed breast reconstruction after BCS. We have found the DIEP flap to be a safe, effective, and esthetic tool for reconstruction of larger partial mastectomy defects, particularly in small to medium sized breasts. The technique thus offers a useful alternative to other reconstructive options in this setting.

## REFERENCES

1. Fisher B, Anderson S, Redmond CK, Wolmark N, Wickerham DL, Cronin WM. Reanalysis and results after 12 years of follow-up in a randomized clinical trial comparing mastectomy with lumpectomy, with or without irradiation in the treatment of breast cancer. *N Engl J Med* 1995;333:1456–1461.
2. Jacobson JA, Danforth DN, Cowan KH, d'Angelo T, Steinberg SM, Pierce L, Lippman ME, Lichter AS, Glatstein E, Okunieff P. Ten-year results of a comparison of conservation with mastectomy in the treatment of stage I and II breast cancer. *N Engl J Med* 1995;332:907–911.
3. Fisher B, Redmond C, Fisher ER, Bauer M, Wolmark N, Wickerham DL, Deutsch M, Montague E, Margolese R, Foster R. Ten-year results of a randomized clinical trial comparing radical mastectomy and total mastectomy with or without radiation. *N Engl J Med* 1985;312:674–681.
4. Bajaj AK, Kon PS, Oberg KC, Miles DA. Aesthetic outcomes in patients undergoing breast conservation therapy for the treatment of localized breast cancer. *Plast Reconstr Surg* 2004;114:1442–1449.
5. Petit JY, Rietjens M, Garusi C, Greuze M, Perry C. Integration of plastic surgery in the course of breast conserving surgery for cancer to improve cosmetic results and radicality of tumour excision. *Recent Results Cancer Res* 1998;152:202–211.
6. Kronowitz SJ, Feledy JA, Hunt KK, Kuerer HM, Youssef A, Koutz CA, Robb GL. Determining the optimal approach to breast reconstruction after partial mastectomy. *Plast Reconstr Surg* 2006;117:1–11.
7. Monticciolo DL, Ross D, Bostwick J III, Eaves F, Styblo T. Autologous breast reconstruction with endoscopic latissimus dorsi musculocutaneous flaps in patients choosing breast-conserving therapy: Mammographic appearance. *Am J Roentgenol* 1996;167:385–389.
8. Moran SL, Serletti JM, Fox I. Immediate free TRAM reconstruction in lumpectomy and radiation failure patients. *Plast Reconstr Surg* 2000;106:1527–1531.
9. Rizzuto RP, Allen RJ. Reconstruction of a partial mastectomy defect with the superficial inferior epigastric artery (SIEA) flap. *J Reconstr Microsurg* 2004;20:441–445.
10. Allen RJ. DIEP versus TRAM for breast reconstruction. *Plast Reconstr Surg* 2003;111:2478.
11. Blondeel PN, Demuyneck M, Mete D, Monstrey SJ, Van Landuyt K, Matton G, Vanderstraeten GG. The donor site morbidity of free DIEP flaps and free TRAM flaps for breast reconstruction. *Br J Plast Surg* 1997;50:322–330.
12. Munhoz AM, Ishida LH, Duarte GG, Cunha MS, Montag E, Sturtz G, Gemperli R, Ferreira MC. Aesthetic refinements in breast augmentation with deep inferior epigastric perforator flap: A case report. *Aesthetic Plast Surg* 2003;27:107–111.
13. Allen RJ, Heitland AS. Autogenous augmentation mammoplasty with microsurgical tissue transfer. *Plast Reconstr Surg* 2003;112:91–100.
14. Forman DL, Chiu J, Restifo RJ, Ward BA, Haffty B, Ariyan S. Breast reconstruction in previously irradiated patients using tissue expanders and implants: A potentially unfavorable result. *Ann Plast Surg* 1998;40:360.
15. Bostwick J III, Paletta C, Hartrampf CR. Conservative treatment for breast cancer. *Ann Surg* 1986;203:481–490.
16. Kroll SS, Evans GR, Reece GP, Miller MJ, Robb GL, Baldwin BJ, Schusterman MA. Comparison of resource costs between implant-based and TRAM flap breast reconstruction. *Plast Reconstr Surg* 1996;97:364–372.
17. Hamdi M, Van Landuyt K, Monstrey S, Blondeel P. Pedicled perforator flaps in breast reconstruction: A new concept. *Br J Plast Surg* 2004;57:531–539.
18. Rozen WM, Ashton MW, Taylor GI. Defining the role for autologous breast reconstruction after mastectomy: Social and oncologic implications. *Clin Breast Cancer* 2008;8:134–142.
19. Losken A, Hamdi M. Partial breast reconstruction: Current perspectives. *Plast Reconstr Surg* 2009;124:722–736.
20. Rainsbury RM. Breast sparing reconstruction with latissimus dorsi miniflaps. *Eur J Surg Oncol* 2002;28:891–895.
21. Munhoz AM, Montag E, Fels KW, Arruda EG, Sturtz GP, Aldrighi C, Gemperli R, Ferreira MC. Outcome analysis of breast-conservation surgery and immediate latissimus dorsi flap reconstruction in patients with T1 to T2 breast cancer. *Plast Reconstr Surg* 2005;116:741–752.
22. Singletary SE, Hortobagyi GN, Kroll SS. Surgical and medical management of local-regional treatment failures in advanced primary breast cancer. *Surg Oncol Clin N Am* 1995;4:671–684.

23. Kroll SS, Schusterman MA, Reece GP, Miller MJ, Smith B. Breast reconstruction with myocutaneous flaps in previously irradiated patients. *Plast Reconstr Surg* 1994;93:460–469.
24. Rozen WM, Chubb D, Grinsell D, Ashton MW. The variability of the superficial inferior epigastric artery (SIEA) and its angiosome: A clinical anatomical study. *Microsurgery* 2010;30:386–391.
25. Rozen WM, Whitaker IS, Wagstaff MJ, Audolfsson T, Acosta R. Buried free flaps for breast reconstruction: A new technique using the Cook-Swartz implantable Doppler probe for postoperative monitoring. *Plast Reconstr Surg* 2010;125:171e–172e.
26. Rozen WM, Chubb D, Whitaker IS, Acosta R. The efficacy of post-operative monitoring: A single surgeon comparison of clinical monitoring and the implantable Doppler probe in 547 consecutive free flaps. *Microsurgery* 2010;30:105–110.
27. Drew PJ, Kerin MJ, Turnbull LW, Imrie M, Carleton PJ, Fox JN, Monson JR. Routine screening for local recurrence following breast conserving therapy for cancer with dynamic contrast-enhanced magnetic resonance imaging of the breast. *Ann Surg Oncol* 1998;5:265–270.
28. Weinreb JC, Newstead G. MR imaging of the breast. *Radiology* 1995;196:593–610.