



Swansea University
Prifysgol Abertawe



Cronfa - Swansea University Open Access Repository

This is an author produced version of a paper published in :
Journal of Reconstructive Microsurgery

Cronfa URL for this paper:

<http://cronfa.swan.ac.uk/Record/cronfa18855>

Paper:

Whitaker, I., Pratt, G., Rozen, W., Cairns, S., Barrett, M., Hiew, L., Cooper, M. & Leaper, D. (2011). Near Infrared Spectroscopy for Monitoring Flap Viability Following Breast Reconstruction. *Journal of Reconstructive Microsurgery*, 28(03), 149-154.

<http://dx.doi.org/10.1055/s-0031-1296030>

This article is brought to you by Swansea University. Any person downloading material is agreeing to abide by the terms of the repository licence. Authors are personally responsible for adhering to publisher restrictions or conditions. When uploading content they are required to comply with their publisher agreement and the SHERPA RoMEO database to judge whether or not it is copyright safe to add this version of the paper to this repository.

<http://www.swansea.ac.uk/iss/researchsupport/cronfa-support/>

Near Infrared Spectroscopy for Monitoring Flap Viability Following Breast Reconstruction

Iain S. Whitaker, B.A. (Hons), M.A. (Cantab), M.B.B.Chir., F.R.C.S., Ph.D.^{1, 2, 3}

George F. Pratt, M.B.B.S., P.G.DipSurgAnat.²

Warren Matthew Rozen, M.B.B.S., B.Med.Sc., P.G.DipSurgAnat., Ph.D.² Scott A. Cairns, B.M., M.R.C.S.^{1, 4}

Matthew David Barrett, M.B.B.Ch., M.R.C.S.¹ Leong Yoon Hiew, M.B.Ch.B., F.R.C.S.¹

Mark ACS Cooper, M.B.B.S., F.R.C.S.¹ David J. Leaper, M.D., Ch.M., F.R.C.S., F.A.C.S., F.L.S.⁴

¹Department of Plastic, Reconstructive, and Burns Surgery, Welsh Centre for Burns and Plastic Surgery, Morriston Hospital, Swansea, United Kingdom;

²Department of Anatomy, Jack Brockhoff Reconstructive Plastic Surgery Research Unit, University of Melbourne, Victoria, Australia;

³Swansea University College of Medicine, Swansea;

⁴Department of Wound Healing, Cardiff University, Heath Park, Cardiff, United Kingdom.

Address for correspondence and reprint requests Iain S. Whitaker, B.A. (Hons), M.A. (Cantab), M.B.B.Chir., F.R.C.S., Ph.D., Swansea University College of Medicine, Singleton Park, Swansea, 5A2 8PP, UK (e-mail: iainwhitaker@fastmail.fm).

J Reconstr Microsurg 2012;28:149–154.

Abstract

Free flap monitoring is essential to the early detection of compromise thereby increasing the chance of successful salvage surgery. Many alternatives to classical clinical monitoring have been proposed. This study seeks to investigate a relatively new monitoring technology: near infrared spectroscopy (NIRS). Patients were recruited prospectively to the study from a single center. During the research period, 10 patients underwent reconstruction with a free deep inferior epigastric perforator flap (DIEP). Measurements of flap perfusion were taken using NIRS in the preoperative and intraoperative phases and postoperatively for 72 hours. NIRS showed characteristic changes in all cases which returned to theater for pedicle compromise. In these cases, NIRS identified pedicle compromise prior to clinical identification. There were no false-positives. NIRS accurately identified all compromised flaps in our study. In most cases, there was an evidence of changes in oxygen saturation on NIRS prior to clinical observation. Further research, ideally double blind randomized control trials with large sample groups would be required to definitively establish NIRS as an ideal flap monitoring modality.

Keywords

- ▶ free flap
- ▶ perforator flap
- ▶ reconstructive surgery
- ▶ monitoring

Postmastectomy breast reconstruction using autologous free tissue transfer is a common procedure in the United Kingdom. In recent times, the trend has been toward technically challenging perforator-based reconstructions such as the deep inferior epigastric perforator flap (DIEP). These flaps provide the aesthetic advantage of autologous tissue while minimizing donor site morbidity. Increasing experience with these procedures and advances in preoperative planning have resulted in some specialized centers publishing flap loss rates

of lower than 2%^{1–3} however in some series, failure rates are as high as 5 to 20%.^{4,5}

Flap failures are usually due to pedicle compromise and require urgent re-exploration and re-establishment of inflow and outflow for salvage to occur. It is well established that early detection of compromise leads to a higher salvage rate. To date, the gold standard for detection of a compromised flap remains clinical examination by an experienced practitioner⁶ with the use of common bedside tests such as the handheld

received

March 22, 2011

accepted after revision

September 12, 2011

published online

November 30, 2011

Copyright © 2012 by Thieme Medical Publishers, Inc., 333 Seventh Avenue, New York, NY 10001, USA.
Tel: +1(212) 584-4662.

DOI <http://dx.doi.org/10.1055/s-0031-1296030>.
ISSN 0743-684X.

Doppler. However with this being subtle and subjective, especially in the case of muscle flaps, a reliable automated alternative has long been sought.

Near infrared spectroscopy (NIRS) employs a light source producing energy in the near infrared wavelengths, which is then collected by a detector, which measures the intensity at various wavelengths. Biological tissues are relatively transparent to light in these wavelengths and by measuring the amount of light absorbed by tissue chromophores (predominantly hemoglobin) it is able to infer the amount, and oxygen saturation of hemoglobin in tissues. Technological advances in recent years have resulted in miniaturization and reduction in cost making this technology increasingly feasible.

NIRS allows continuous, noninvasive monitoring of hemoglobin levels and oxygen saturations in a free flap. Typically, measurements of saturated and nonsaturated hemoglobin levels are taken at a depth of ~10 mm in the tissue. This data are fed back to a laptop computer, which displays graphic and numerical data. Based on the typical curves and values, abnormalities can be identified as arterial or venous in origin.⁷

Advantages of the NIRS system are that it is noninvasive and reliable. In addition, it can be used to monitor buried flaps provided the overlying skin is not more than 10 mm thick. Disadvantages include the cost of the unit and the fact that while current evidence suggests that it reliably detects circulatory failure prior to clinical signs, it may lag behind continuous monitoring devices such as the implantable Doppler as it measures indirect evidence of circulatory failure. While NIRS has been extensively investigated in animal models,⁸⁻¹¹ there is a relative paucity of reported uses in clinical practice.^{7,12-18}

Methods

A prospective observational study was undertaken, recruiting all women who were undergoing autologous breast reconstruction following mastectomy, aged between 18 and 65 years old at a single institution (the Regional Plastic Surgical Centre at the Morriston Hospital in Swansea, Wales). Those with a history of healing complications, bleeding disorders, and systemic skin disease or infection, which may have influenced healing, were excluded. Also excluded were those who were currently participating in another trial or those having done so within 3 months of the current study and those undergoing evaluation for an unrelated disease, which may have interfered with trial participation. All patients gave written consent following study approval by the institutional ethics committee.

Following preoperative marking by the operating surgeon, preoperative measurements were taken from the donor sites, from each of the four zones marked on the DIEP flap. Measurements were made of tissue oxygen saturation (StO₂) and total hemoglobin index (THI) using the Inspectra (Model 650, Hutchinson Technology Inc. [Hutchinson, MN]) StO₂ monitor and its single-use measurement probe.

Using this monitor StO₂ is the noninvasive, direct measurement of hemoglobin oxygen saturation in the microcirculation of a volume of tissue. StO₂ is a dynamic measurement that changes as oxygen supply and consumption change. THI

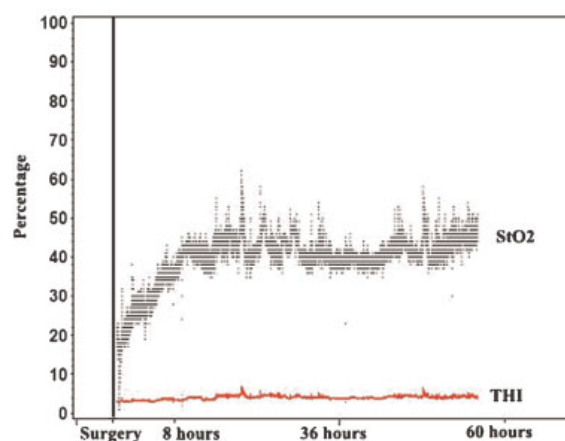


Figure 1 Typical outcome curves in an uncomplicated case. StO₂, tissue oxygen saturation; THI, total hemoglobin index.

is a relative index of the amount of hemoglobin in the volume of tissue illuminated by the sensor. Range is 1.0 to 99.0. It functions as a signal strength indicator. Preliminary data suggests that changes in THI may differentiate venous from arterial occlusions in breast reconstructions.⁷ A graph may then be displayed showing consecutive StO₂ (gray line) and THI (red line), so that a trend may be discerned (→**Fig. 1**).

Once the flap had been raised, and was dependent on one artery and vein, prior to being inset or the pedicle divided, intraoperative measurements were taken. At the end of the operation, the measurement probe was attached using adhesive to the visible skin paddle to provide 72 hours of continuous postoperative measurements in the monitoring recovery room area. In addition, clinical staff performed routine monitoring of the flap, using clinical markers of color, temperature, capillary refill time and flap texture. Traditional bedside tests such as handheld Doppler and capillary bleeding with a 25 gauge needle were also required. The monitors were set to alarm if the StO₂ or THI decreased to 50% or less of their starting values as in other studies.⁷ After 72 hours, the monitoring probe was removed and the patient transferred to the general plastic surgery ward.

Flap complications included vascular compromise; either arterial or venous, thrombosis, occlusion or excessive edema, wound infection, and wound separation. These were defined as “early” if intervention was required within 72 hours of surgery or “late” if after this time. Flap complications requiring surgical intervention, leech therapy, or intravenous antibiotics were recorded. Following discharge patients were given a patient diary to complete and were followed in clinic at approximately 2, 6, and 12 weeks.

Results

Eleven patients aged between 28 and 61, with a median age of 46, were enrolled into the study but one patient requested withdrawal from the study on the day of surgery. The length of postoperative stay ranged from 6 to 13 days. All 10 patients

Table 1 Statistical Comparisons for Primary Objective

	Immediately Postsurgery		p-Value
	No Intervention (Group A) N = 6	Intervention (Group B) N = 4	Group A versus Group B Postsurgery ^a
Average StO ₂	47.1 ± 20.4 (52.2) 0.0 – 78.2	26.9 ± 8.1 (28.2) 16.0 – 35.8	0.0169
Average THI	5.9 ± 2.8 (5.2) 2.2 – 10.3	6.7 ± 3.2 (7.3) 2.9 – 10.4	0.6734
Average HbO ₂	315 ± 237 (262) 0 – 789	198 ± 127 (206) 50 – 353	0.3736
Average StO ₂ per unit volume THI	8.5 ± 4.4 (8.1) 0.0 – 17.7	4.5 ± 1.4 (4.6) 2.8 – 6.6	0.0218

HbO₂, hemoglobin and oxygen saturation; StO₂, tissue oxygen saturation; THI, total hemoglobin index.
^aWilcoxon Rank Sum Test.

underwent reconstruction with a free DIEP flap ($n = 10$). Of these 10 patients, 4 required further intervention with evacuation of hematoma or revision of the anastomosis. One flap was lost despite re-exploration (free flap loss 10%, salvage rate 75%).

The four patients who required intervention went back to the theater within 24 hours of their index reconstructive surgery (13 to 23 hours). Three of these patients had revision of their anastomoses, and the fourth underwent evacuation of a hematoma. No patients had intervention for arterial problems. Patient number 5 had leeches placed on the flap following revision surgery, but ultimately lost her flap. Patients number 13 and 16 had some minor debridement performed between 3 and 5 days postindex surgery, and Patient number 17 required no further interventions.

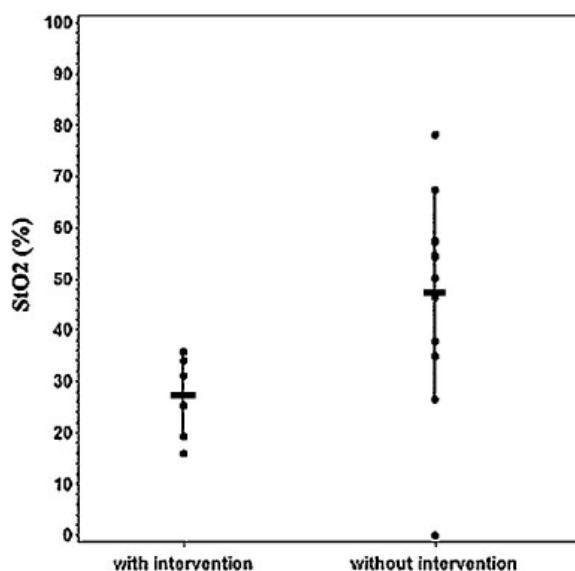


Figure 2 Tissue oxygen saturation (StO₂) measurements for all cases, comparing the intervention and no-intervention groups. Each data point is entered, with the horizontal marks signifying the mean values, and the vertical marks signifying all values within one standard deviation (SD) of the mean.

Comparing the StO₂ and THI in the intervention with the nonintervention groups immediately postoperatively, there is a significant difference in StO₂ ($p = 0.0169$) but not in THI (►Table 1, ►Fig. 2). In the cases of the venous congestion in the flaps, one flap (Patient number 5, ►Fig. 3) had virtually unrecordable readings in recovery before subsequently returning to theater when the flap deteriorated clinically. In patients number 16 (►Fig. 4) and 17, the changes in StO₂ and THI preceded the first recorded clinical observation. No false-positives were experienced specifically, the NIRS receiver did not alarm for any case which did not return to the operating theater.

Discussion

As yet no monitoring method, save perhaps the handheld Doppler has satisfied Creech and Miller's 1975 criteria for free flap monitoring.¹⁹ Broadly, these state should be noninvasive, reliable, repeatable and recordable, rapid, cheap, objective, and simple to use by even the most junior member of staff.

A vast range of technologies have been proposed for postoperative monitoring and discussed in the literature, but there is no consensus on the topic. This is reflected in the wide variety of techniques currently in use to monitor flaps including the use of clinical monitoring alone, pulse oximetry,^{20,21} perfusion photoplethysmography,^{22,23} surface temperature measurement,^{24,25} fluorometry,^{25,26} microdialysis,^{27,28} ultrasound,^{29,30} implanted (Cook-Swartz) Doppler probes,^{31,32} laser Doppler flowmetry,^{33,34} impedance plethysmography,^{35,36} confocal microscopy,³⁷ nuclear medicine,^{38,39} subcutaneous pH measurement,^{40,41} hydrogen clearance,^{42,43} externalization of part of a buried flap,⁴⁴ and white light spectrometry.⁴⁵ Surveys of plastic surgical units and oral and maxillofacial units in the UK have shown that there is a vast range in the methods, organization, and implementation of postoperative monitoring used following free tissue transfer.^{46,47}

Recent publications confirm that the survival of a compromised flap is dependent on ischemic time.^{48–50} Of the flaps which require intervention approximately half have a successful outcome. These complications typically occurs

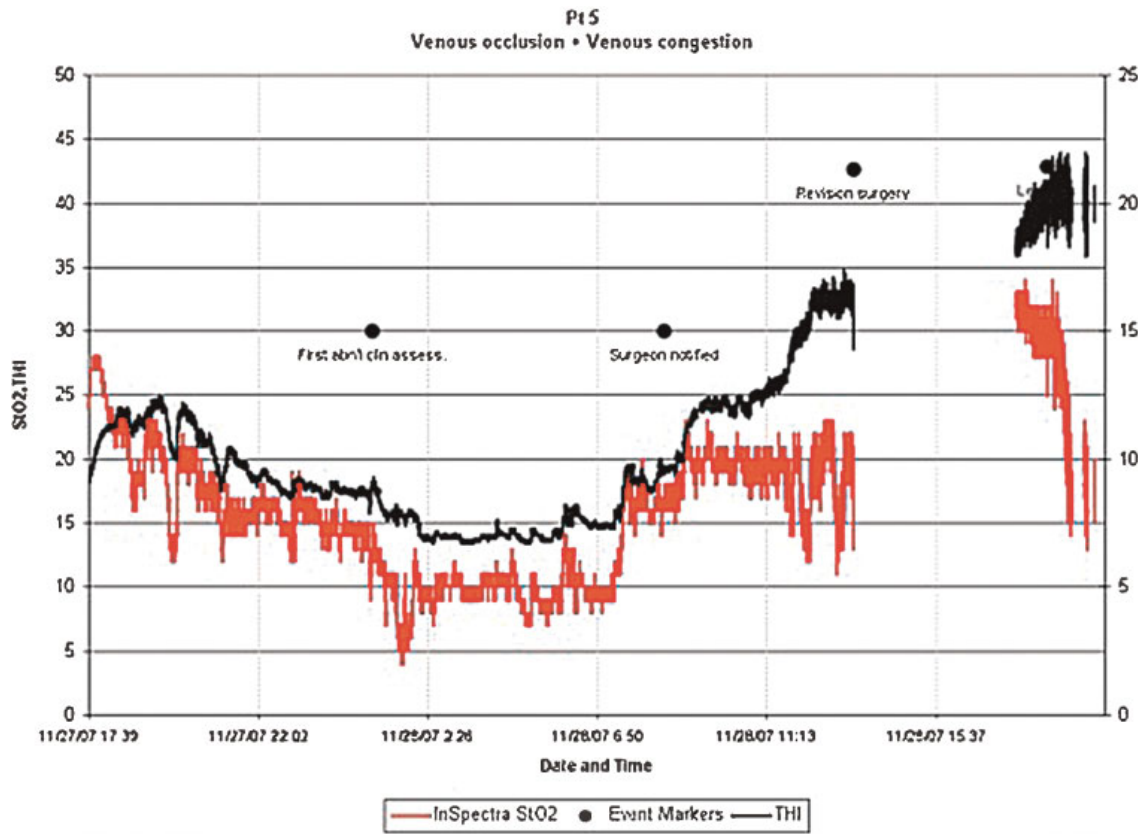


Figure 3 Abnormal NIRS, StO₂, and THI curves for patient number 5 with event points.

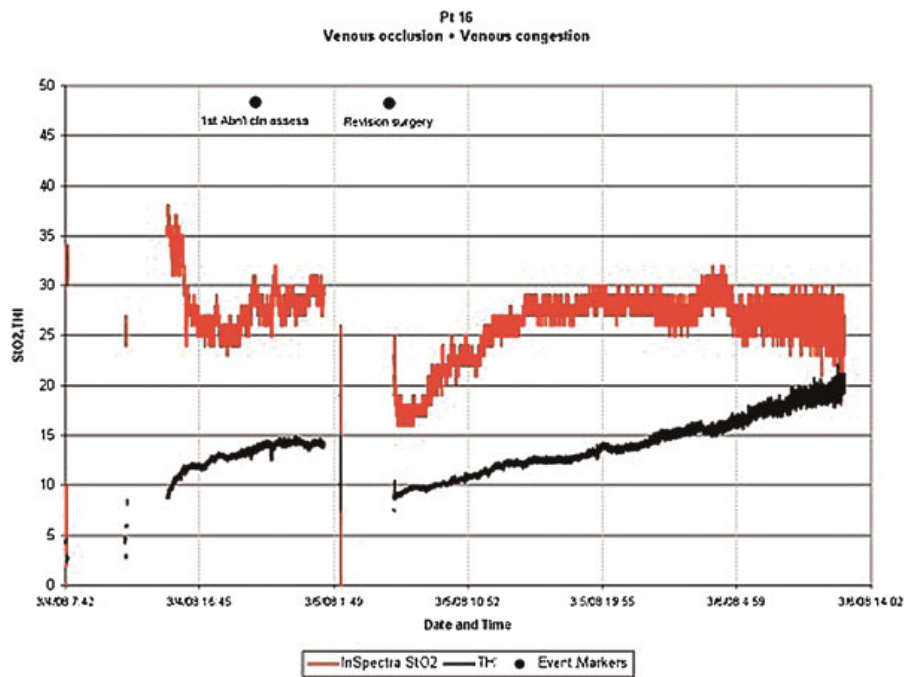


Figure 4 Abnormal NIRS, StO₂, and THI curves for patient number 15 with event points.

within the first 48 hours of the surgery and are irreversible if not corrected within 12 hours of onset.⁴

The use of a monitoring system to enable early identification and intervention in a failing flap would clearly have benefits in reducing patient morbidity. Additionally, a monitoring system which could differentiate between arterial or venous embarrassment would allow the surgical team to take a much more targeted approach to the salvage surgery. Many pre-existing monitoring techniques are able to identify arterial insufficiency but struggle in the identification of venous outflow problems, yet these are more injurious to the flaps, and having a greater effect on flap survival rates. NIRS is a noninvasive technique, which provides continuous perioperative and postoperative monitoring. It can be used with minimal training, and can also differentiate venous insufficiency.

There was a statistically significant difference in postoperative readings for the intervention group compared with the nonintervention group, and the monitor showed significant changes in StO₂ and THI which preceded clinical observations. This shows that the use of NIRS can be used to predict those flaps at an increased likelihood of failure and can pre-empt clinical findings.

In those flaps where NIRS accurately predicted impending flap problems, the patients were not returned to theater until the clinical signs became apparent. Early intervention in a struggling flap has been shown to improve flap survivability, and the use of NIRS to monitor patients, shown in this study, may result in a timely return to theater prior to the onset of clinical changes with a corresponding increase in flap survivability.

False-positive alerts have been raised as a potential concern for all monitoring modalities. In the case of NIRS, occasionally the sensor can become dislodged, particularly if there is a buildup of serosanguineous exudate in the context of muscle flaps. Appropriate application of the probe should be checked in the event of any alarm. This problem did not arise in our series.

Conclusion

NIRS appears to be a reliable and accurate monitoring method which is capable of consistently identifying pedicle compromise before clinical changes significant enough to trigger a return to theater. Other series have suggested that NIRS is also capable of differentiating between venous and arterial compromise in a flap. NIRS has also been investigated in buried flaps. Further research including large double blind randomized control trials would be required to definitively establish the reliability of this technology but in the event of the NIRS trace becoming a trusted trigger for return to theater there is a potential for increased flap salvage rates and better patient outcomes.

Notes

Declarations: Authorship: Full authorship and ownership of the manuscript is with the authors above. All authors contributed significantly, and are in agreement with the

content. Conflicts of Interest: The authors declare that there is no source of financial or other support, or any financial or professional relationships which may pose a competing interest. Ethical Approval: Institutional Ethical Approval was obtained prospectively, and conforms to the provisions of the Declaration of Helsinki in 1995.

Acknowledgments

The authors would like to acknowledge Dr. D. Boyce for his help in initiating the study.

References

- Ahn CY, Shaw WW, Berns S, Markowitz BL. Clinical experience with the 3M microvascular coupling anastomotic device in 100 free-tissue transfers. *Plast Reconstr Surg* 1994;93(7):1481-1484
- Spector JA, Draper LB, Levine JP, Ahn CY. Routine use of microvascular coupling device for arterial anastomosis in breast reconstruction. *Ann Plast Surg* 2006;56(4):365-368
- Jandali S, Wu LC, Vega SJ, Kovach SJ, Serletti JM. 1000 consecutive venous anastomoses using the microvascular anastomotic coupler in breast reconstruction. *Plast Reconstr Surg* 2010;125(3):792-798
- Bui DT, Cordeiro PG, Hu QY, Disa JJ, Pusic A, Mehrara BJ. Free flap reexploration: indications, treatment, and outcomes in 1193 free flaps. *Plast Reconstr Surg* 2007;119(7):2092-2100
- Disa JJ, Cordeiro PG, Hidalgo DA. Efficacy of conventional monitoring techniques in free tissue transfer: an 11-year experience in 750 consecutive cases. *Plast Reconstr Surg* 1999;104(1):97-101
- Pratt GF, Rozen WM, Chubb D, et al. Modern adjuncts and technologies in microsurgery: an historical and evidence-based review. *Microsurgery* 2010;30(8):657-666
- Repez A, Oroszy D, Arnez ZM. Continuous postoperative monitoring of cutaneous free flaps using near infrared spectroscopy. *J Plast Reconstr Aesthet Surg* 2008;61(1):71-77
- Stranc MF, Sowa MG, Abdulrauf B, Mantsch HH. Assessment of tissue viability using near-infrared spectroscopy. *Br J Plast Surg* 1998;51(3):210-217
- Thorniley MS, Sinclair JS, Barnett NJ, Shurey CB, Green CJ. The use of near-infrared spectroscopy for assessing flap viability during reconstructive surgery. *Br J Plast Surg* 1998;51(3):218-226
- Hayden RE, Tavill MA, Nioka S, Kitai T, Chance B. Oxygenation and blood volume changes in flaps according to near-infrared spectrophotometry. *Arch Otolaryngol Head Neck Surg* 1996;122(12):1347-1351
- Irwin MS, Thorniley MS, Doré CJ, Green CJ. Near infra-red spectroscopy: a non-invasive monitor of perfusion and oxygenation within the microcirculation of limbs and flaps. *Br J Plast Surg* 1995;48(1):14-22
- Cai ZG, Zhang J, Zhang JG, et al. Evaluation of near infrared spectroscopy in monitoring postoperative regional tissue oxygen saturation for fibular flaps. *J Plast Reconstr Aesthet Surg* 2008;61(3):289-296
- Colwell AS, Wright L, Karanas Y. Near-infrared spectroscopy measures tissue oxygenation in free flaps for breast reconstruction. *Plast Reconstr Surg* 2008;121(5):344e-345e
- Keller A. Noninvasive tissue oximetry for flap monitoring: an initial study. *J Reconstr Microsurg* 2007;23(4):189-197
- Keller A. A new diagnostic algorithm for early prediction of vascular compromise in 208 microsurgical flaps using tissue oxygen saturation measurements. *Ann Plast Surg* 2009;62(5):538-543

- 16 Shan XF, Cai ZG, Yu GY, Li Y, Ding HS. [Application of near infrared spectroscopy in monitoring blood oxygen saturation of fibula flaps]. *Zhonghua Kou Qiang Yi Xue Za Zhi* 2008;43(7):398–401
- 17 Scheufler O, Andresen R. Tissue oxygenation and perfusion in inferior pedicle reduction mammoplasty by near-infrared reflection spectroscopy and color-coded duplex sonography. *Plast Reconstr Surg* 2003;111(3):1131–1146
- 18 Scheufler O, Exner K, Andresen R. Investigation of TRAM flap oxygenation and perfusion by near-infrared reflection spectroscopy and color-coded duplex sonography. *Plast Reconstr Surg* 2004;113(1):141–152, discussion 153–155
- 19 Creech B, Miller S. Evaluation of circulation in skin flaps. In: Grabb WC, Myers MB, eds. *Skin Flaps*. 1975:21–38
- 20 Lindsey LA, Watson JD, Quaba AA. Pulse oximetry in postoperative monitoring of free muscle flaps. *Br J Plast Surg* 1991;44(1):27–29
- 21 Achauer BM, Black KS, Beran AV, Huxtable RF. Transcutaneous PO₂ monitoring of flap circulation following surgery. *Birth Defects Orig Artic Ser* 1979;15(4):517–522
- 22 Stack BC Jr, Futran ND, Shohet MJ, Scharf JE. Spectral analysis of photoplethysmograms from radial forearm free flaps. *Laryngoscope* 1998;108(9):1329–1333
- 23 Stack BC Jr, Futran ND, Zang B, Scharf JE. Initial experience with personal digital assistant-based reflectance photoplethysmograph for free tissue transfer monitoring. *Ann Plast Surg* 2003;51(2):136–140
- 24 Chiu ES, Altman A, Allen RJ Jr, Allen RJ Sr. Free flap monitoring using skin temperature strip indicators: adjunct to clinical examination. *Plast Reconstr Surg* 2008;122(5):144e–145e
- 25 Issing WJ, Naumann C. Evaluation of pedicled skin flap viability by pH, temperature and fluorescein: an experimental study. *J Craniomaxillofac Surg* 1996;24(5):305–309
- 26 Denny JC III, Weisman RA, Silverman DG. Monitoring free flap perfusion by serial fluorimetry. *Otolaryngol Head Neck Surg* 1983;91(4):372–376
- 27 Udesen A, Løntoft E, Kristensen SR. Monitoring of free TRAM flaps with microdialysis. *J Reconstr Microsurg* 2000;16(2):101–106
- 28 Mourouzis C, Anand R, Bowden JR, Brennan PA. Microdialysis: use in the assessment of a buried bone-only fibular free flap. *Plast Reconstr Surg* 2007;120(5):1363–1366
- 29 Rosenberg JJ, Fornage BD, Chevray PM. Monitoring buried free flaps: limitations of the implantable Doppler and use of color duplex sonography as a confirmatory test. *Plast Reconstr Surg* 2006;118(1):109–113, discussion 114–115
- 30 Prantl L, Pfister K, Kubale R, et al. Value of high resolution ultrasound and contrast enhanced US pulse inversion imaging for the evaluation of the vascular integrity of free-flap grafts. *Clin Hemorheol Microcirc* 2007;36(3):203–216
- 31 Whitaker IS, Smit JM, Acosta R. A simple method of implantable Doppler cuff attachment: experience in 150 DIEP breast reconstructions. *J Plast Reconstr Aesthet Surg* 2008;61(10):1251–1252
- 32 Swartz WM, Izquierdo R, Miller MJ. Implantable venous Doppler microvascular monitoring: laboratory investigation and clinical results. *Plast Reconstr Surg* 1994;93(1):152–163
- 33 Yuen JC, Feng Z. Monitoring free flaps using the laser Doppler flowmeter: five-year experience. *Plast Reconstr Surg* 2000;105(1):55–61
- 34 Svensson H, Pettersson H, Svedman P. Laser Doppler flowmetry and laser photometry for monitoring free flaps. *Scand J Plast Reconstr Surg* 1985;19(3):245–249
- 35 Concannon MJ, Stewart DH, Welsh CF, Puckett CL. Impedance plethysmography: a new method for continuous muscle perfusion monitoring. *Plast Reconstr Surg* 1991;88(2):292–298
- 36 Harrison DH, Mott G. Impedance monitoring for subcutaneous free flap transfers. *Br J Plast Surg* 1989;42(3):318–323
- 37 Altintas MA, Altintas AA, Guggenheim M, Knobloch K, Niederbichler AD, Vogt PM. Monitoring of microcirculation in free transferred musculocutaneous latissimus dorsi flaps by confocal laser scanning microscopy—a promising non-invasive methodical approach. *J Plast Reconstr Aesthet Surg* 2010;63(1):111–117
- 38 Top H, Sarikaya A, Aygit AC, Benlier E, Kiyak M. Review of monitoring free muscle flap transfers in reconstructive surgery: role of 99mTc sestamibi scintigraphy. *Nucl Med Commun* 2006;27(1):91–98
- 39 Aygit AC, Sarikaya A. Technetium 99m sestamibi scintigraphy for noninvasive assessment of muscle flap viability. *Ann Plast Surg* 1999;43(3):338–340
- 40 Raskin DJ, Erk Y, Spira M, Melissinos EG. Tissue pH monitoring in microsurgery: a preliminary evaluation of continuous tissue pH monitoring as an indicator of perfusion disturbances in microvascular free flaps. *Ann Plast Surg* 1983;11(4):331–339
- 41 Dickson MG, Sharpe DT. Continuous subcutaneous tissue pH measurement as a monitor of blood flow in skin flaps: an experimental study. *Br J Plast Surg* 1985;38(1):39–42
- 42 Machens HG, Mailaender P, Reimer R, Pallua N, Lei Y, Berger A. Postoperative blood flow monitoring after free-tissue transfer by means of the hydrogen clearance technique. *Plast Reconstr Surg* 1997;99(2):493–505
- 43 Thomson JG, Kerrigan CL. Hydrogen clearance: assessment of technique for measurement of skin-flap blood flow in pigs. *Plast Reconstr Surg* 1991;88(4):657–663
- 44 Hallock GG, Koch TJ. External monitoring of vascularized jejunum transfers using laser Doppler flowmetry. *Ann Plast Surg* 1990;24(3):213–215
- 45 Hölzle F, Loeffelbein DJ, Nolte D, Wolff K-D. Free flap monitoring using simultaneous non-invasive laser Doppler flowmetry and tissue spectrophotometry. *J Craniomaxillofac Surg* 2006;34(1):25–33
- 46 Whitaker IS, Oliver DW, Ganchi PA. Postoperative monitoring of microvascular tissue transfers: current practice in the United Kingdom and Ireland. *Plast Reconstr Surg* 2003;111(6):2118–2119
- 47 Whitaker IS, Gulati V, Ross GL, Menon A, Ong TK. Variations in the postoperative management of free tissue transfers to the head and neck in the United Kingdom. *Br J Oral Maxillofac Surg* 2007;45(1):16–18
- 48 Smit JM, Acosta R, Zeebregts CJ, Liss AG, Anniko M, Hartman EHM. Early reintervention of compromised free flaps improves success rate. *Microsurgery* 2007;27(7):612–616
- 49 Smit JM, Zeebregts CJ, Acosta R. Timing of presentation of the first signs of vascular compromise dictates the salvage outcome of free flap transfers. *Plast Reconstr Surg* 2008;122(3):991–992
- 50 Hofer SO, Damen TH, Mureau MA, Rakhorst HA, Roche NA. A critical review of perioperative complications in 175 free deep inferior epigastric perforator flap breast reconstructions. *Ann Plast Surg* 2007;59(2):137–142