

# PREVENTING INFECTIVE COMPLICATIONS FOLLOWING LEECH THERAPY: IS PRACTICE KEEPING PACE WITH CURRENT RESEARCH?

IAIN S. WHITAKER, B.A. (Hons), M.A. (Cantab), M.B.B.Chir., M.R.C.S.,<sup>1,2\*</sup> CYRIL KAMYA, M.B.Ch.B.,<sup>2</sup>  
ERNEST A. AZZOPARDI, M.D., M.R.C.S.,<sup>2</sup> JOERG GRAF, Ph.D.,<sup>1</sup> MOSHE KON, M.D., Ph.D.,<sup>3</sup>  
and WILLIAM C. LINEAWEAVER, M.D., F.A.C.S.<sup>4</sup>

**Background:** Despite several publications strongly advocating prophylactic antibiotics during leech therapy, and recent primary articles shedding new light on the microbiota of leeches, many units either do not use antibiotic prophylaxis, or are continuing to use ineffective agents. **Methods:** A 5-year follow-up of plastic surgery units in the United Kingdom and the Republic of Ireland was conducted in 2007 to ascertain current practice regarding the use of prophylactic antibiotics with leech therapy. A comprehensive literature search investigated primary research articles regarding the microbiota of leeches to update the reconstructive surgery community. **Results:** Despite published evidence to support the use of prophylactic antibiotics during leech therapy, 24% of units do not use antibiotic prophylaxis and 57% of those using antibiotics are using potentially ineffective agents. Advanced molecular genetic techniques, which allow accurate characterization of both culturable and nonculturable microbiota of the leech digestive tract, show a wider diversity than at first thought, with variable antibiotic resistance profiles. **Conclusions:** Despite infection due to leech therapy being a well known and relatively common complication, many units are not using appropriate antibiotic prophylaxis. © 2009 Wiley-Liss, Inc. *Microsurgery* 29:619–625, 2009.

**B**lood letting and the therapeutic use of medicinal leeches dates back to ancient Egypt.<sup>1</sup> Decades of reports of leech therapy in plastic and reconstructive surgery<sup>2</sup> and more recently the application of leeching for diverse medical problems such as chronic pain syndromes associated with degenerative diseases<sup>3–5</sup> have given leech therapy multiple roles in modern day medicine. Their popularity has indeed varied over the years, having been used by plastic,<sup>6–9</sup> maxillofacial,<sup>10</sup> and other reconstructive surgeons<sup>11,12</sup> to aid salvage of compromised pedicled flaps,<sup>2,13</sup> microvascular free-tissue transfers,<sup>6,14–16</sup> venously congested digits,<sup>8,17–24</sup> nipples,<sup>25,26</sup> ears,<sup>27–32</sup> lips,<sup>33,34</sup> nasal tips,<sup>11,35</sup> and even the penis.<sup>12</sup> Peer-reviewed evidence suggests that the survival of compromised, venous-congested tissues is improved by early application of a leech.<sup>36–38</sup> The leech simulates venous circulation until the congested tissue reestablishes venous capillary circulation. The benefits of leech therapy were only relatively recently acknowledged with The Food and

Drug Administration of the United States approving the use of *Hirudo medicinalis* as a medical device in 2004.<sup>39</sup> While most commercial suppliers sell medicinal leeches as *H. medicinalis*, a recent study revealed that the annelids sold were genetically distinct from *H. medicinalis* and were identified as *H. verbana* by Siddall et al.<sup>40</sup> Bely et al. encourage the increased use of “DNA Barcodes” such as COI gene sequences to reveal genetic variations in leeches,<sup>41</sup> while DeSalle et al. advocate a more cautious approach until the barcode reader is reliable and the taxonomic community is in agreement.<sup>42</sup> Whether clarification of these differences will have any medical or microbiological importance remains to be demonstrated. In this study, we refer to medicinal leeches as *H. medicinalis* unless the animals were specifically identified as *H. verbana*. An overview of the anatomy, physiology, and mechanisms of action of the medicinal leech relevant to the reconstructive surgeon is summarized elsewhere.<sup>43</sup>

A high incidence of infection during and after application of medicinal leeches has been widely reported despite external decontamination. The exact incidence of leech-associated infection associated with postoperative use is difficult to assess, with incidences ranging from 2.4% to 36.2% being reported in the literature<sup>8,36,44–46</sup> (see Table 1). At least one clinical study has demonstrated that limiting leech application to tissue with clear evidence of arterial circulation while giving patients antibiotics effective against leech enteric flora during leech therapy can eliminate leech-related soft-tissue infection.<sup>47</sup> Despite several publications advocating prophylactic antibiotics to combat leech-borne infections,<sup>7–9,44,48–52</sup> we were aware of many units either not using antibiotic prophylaxis at all, or continuing to use inappropriate agents.

<sup>1</sup>Department of Molecular and Cell Biology, University of Connecticut, CT

<sup>2</sup>Department of Plastic, Reconstructive and Burns Surgery, Welsh Centre for Burns and Plastic Surgery, Swansea, UK

<sup>3</sup>Plastic, Reconstructive and Hand Surgery, University Medical Center, Utrecht, The Netherlands

<sup>4</sup>Department of Plastic, Reconstructive and Aesthetic Surgery, Rankin Medical Center, MS

Conflict of interest: The authors confirm that none of them have any financial or other interest in any of the techniques or data described in this manuscript. Grant sponsor: U.S. National Science Foundation CAREER award; Grant number: MCB 0448052 (to J.G.).

\*Correspondence to: Iain S. Whitaker, B.A. (Hons), M.A. (Cantab), M.B.B.Chir., M.R.C.S., Department of Plastic, Reconstructive and Burns Surgery, Welsh Centre for Burns and Plastic Surgery, Morriston Hospital, Swansea SA6 6NL, UK. E-mail: iainwhitaker@fastmail.fm

Received 3 December 2008; Accepted 23 March 2009

Published online 27 April 2009 in Wiley InterScience (www.interscience.wiley.com). DOI 10.1002/micr.20666

**Table 1.** Chronological Table Summarizing the Published Infection Rates Following Leech Therapy in the Medical Literature

Number of patients	Period (years)	Infection rate (%)	Authors	Year
30	3	20	Mercer et al. <sup>45</sup>	1987
42	Not stated	7	Lineaweaver et al. <sup>8</sup>	1992
18	5	11	De Chalain et al. <sup>36</sup>	1996
122	5	4.1	Sartor et al. <sup>46</sup>	2002
47	2	36.2	Bauters et al. <sup>44</sup>	2007

With the knowledge of the microbiota of the leech digestive tract continuing to grow, the last decade has shown that the bacterial community is much more complex than previously documented. More accurate identification and antibiotic sensitivity testing has allowed an exponential increase in relevant data regarding leech microbiota. A limitation of the clinical articles that previously characterized the digestive tract microbiota of leeches was that these studies were purely culture based. It is now widely recognized that >99% of microbes are at present unculturable<sup>53</sup> and modern techniques must be used to identify these symbionts.

In this article we present the results of a 5-year follow-up national survey of antibiotic prophylaxis during leech therapy and draw on the combined wisdom of both the microbiological and plastic surgery community to discuss the implications of our findings including an up-to-date discussion concerning leech borne infections and appropriate evidence-based treatment.

## METHODS

A telephone survey of all 62 plastic surgery units in the United Kingdom and the Republic of Ireland was conducted in August 2007. The names, addresses, and phone numbers were obtained from the British Association of Plastic, Reconstructive and Esthetic Surgeons Website ([www.bapras.co.uk](http://www.bapras.co.uk)). Information was obtained from the senior sister on the Plastic and Microsurgery ward who had first hand experience of the use of leeches on the unit, and was responsible for the supervision of antibiotic administration and leech application.

Five simple questions were asked:

1. Are leeches used postoperatively by the plastic surgeons in your unit?
2. How many times per year on average are leeches used?
3. Do you use antibiotics routinely postoperatively when leeches are applied?
4. If yes: What antibiotics do you use?
5. Were there written protocols for the use of leeches?

This questionnaire was accompanied by an extensive literature search to investigate primary research papers regarding the microbiota of leeches and update the reconstructive surgery community.

## RESULTS

Accurate information was gained from 55 of the 62 units (89% response rate). Of these, 49 (90%) had used leeches postoperatively in the salvage of compromised free flaps or digital replants within the last 5 years. On average, 23 units used leeches one to five times per year, 15 units used leeches 6–10 times per year, four units used leeches 11–15 times per year, and seven units used leeches more than 16 times per year. Twelve units (24.5%) did not use any antibiotic prophylaxis before or during leech therapy. The remaining 37 units used a range of prophylactic antibiotics routinely during leech application including coamoxiclav, metronidazole, benzyl penicillin, ciprofloxacin, and flucloxacillin. Written protocols concerning the use of leeches were available in 39 units (80%) and 49 units (100%) routinely kept leeches in the hospital pharmacy overnight (see Figs. 1–4). In the figures, “other” antibiotics include metronidazole, cephalosporins, and trimethoprim.

## DISCUSSION

This study confirms that the majority of plastic surgery units in the United Kingdom and Ireland use medicinal leeches to improve drainage from venously congested tissues or extremity replants postoperatively, but despite strong supportive evidence, 24.5% of units fail to use any antibiotic prophylaxis. The total percentage of units using prophylactic antibiotics has decreased from 2002 to 2007 from 92.5% to 75.5%, although the number of units using reliably effective antibiotics such as fluoroquinolones has improved from 22% in 2002% to 43% in 2007<sup>9</sup> (see Fig. 4).

### Leech-Borne Infection: Clinical Aspects

The leech bite is created by three jaws, each containing 60–100 pairs of cutting teeth, forming the characteristic Y-shaped tri-radiate conformation 1 mm in diameter and up to 1.5 mm in depth.<sup>54,55</sup> These specially adapted jaws pierce the host tissues in order to feed on blood. The combination of local tissue damage, along with contact between the oral and digestive tract flora (including both the leech crop and intestine) and the patient means that a potential for infection exists. Although the use of leeches in the treatment of arthritis and other medical conditions seems to be associated with negligible risks of infection, the venous congestion in plastic surgery patients requiring treatment seems to lead to a localized

area of immunocompromise that is more susceptible to infection. The exact incidence of infection is difficult to assess, with incidences ranging from 2.4% to 36.2%<sup>8,36,44-46</sup> being reported in the literature.

Extensive studies have been carried out on the surface, mouth, and digestive tract microbiota of leeches, which show *Aeromonas* spp. to be prominent in the resident flora.<sup>36,47,48,53,56-60</sup> The most recent of these primary research articles was able to identify both culturable and unculturable isolates. The most common clinical presentation of *Aeromonas* infection in humans is of cellulitis,<sup>61,62</sup> often with a foul odor, complicated by subcutaneous abscess formation. In severe cases, extensive tissue loss and septicemia has been reported.<sup>63</sup> *Aeromonas* seems to have an affinity for muscle tissue, and is capable of producing extensive proteolytic enzymes lead-

ing to a picture resembling clostridial myonecrosis with gas production.<sup>64</sup> Of most concern to microsurgeons is the ability of *Aeromonas* to invade the walls of blood vessels with resultant vasculitis, thrombosis, and hemorrhagic necrosis.<sup>65</sup> In immunocompetent patients, surgical site infections (SSIs) due to leech application may result in additional antibiotic therapy, extended hospital stays, rehospitalization, or removal of nonviable tissues.<sup>46</sup> Chailain's meta-analysis reported on a total of 19 cases of aeromonas infection (nine replants, three free flaps, and seven pedicled flaps) with an overall salvage rate of the tissues in the presence of infection of 31.8%, compared with an expected salvage rate of 60-80% in noninfected tissues.<sup>36</sup> As one would expect, neutropenic and immunocompromised patients seem to be more at risk. Leechborne infections are by no means heterogenous in presentation; delayed presentations have been recently reported

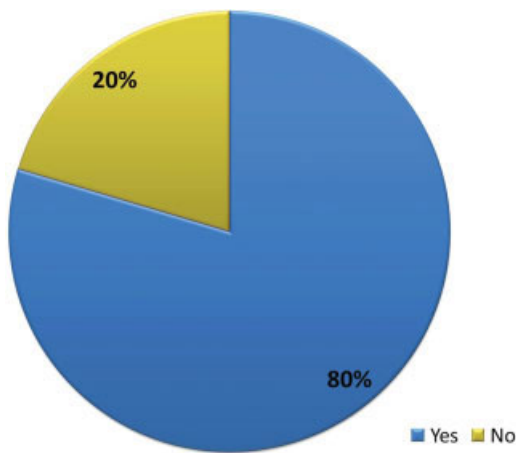


Figure 1. A pie chart showing the percentage of units in the United Kingdom with and without a written protocol for leech therapy. [Color figure can be viewed in the online issue, which is available at [www.interscience.wiley.com](http://www.interscience.wiley.com).]

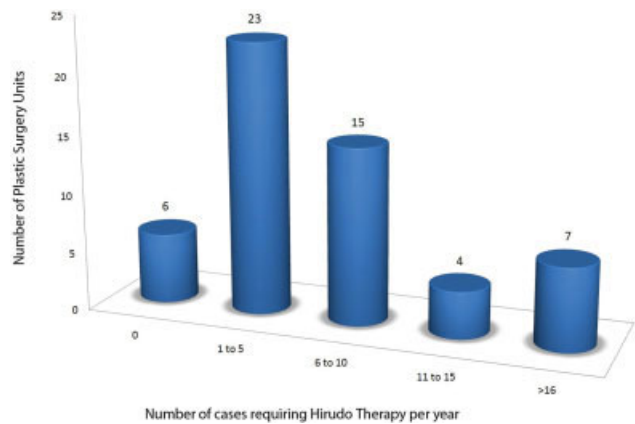


Figure 2. A bar chart showing the approximate number of cases per year requiring leech therapy in each unit in the United Kingdom. [Color figure can be viewed in the online issue, which is available at [www.interscience.wiley.com](http://www.interscience.wiley.com).]

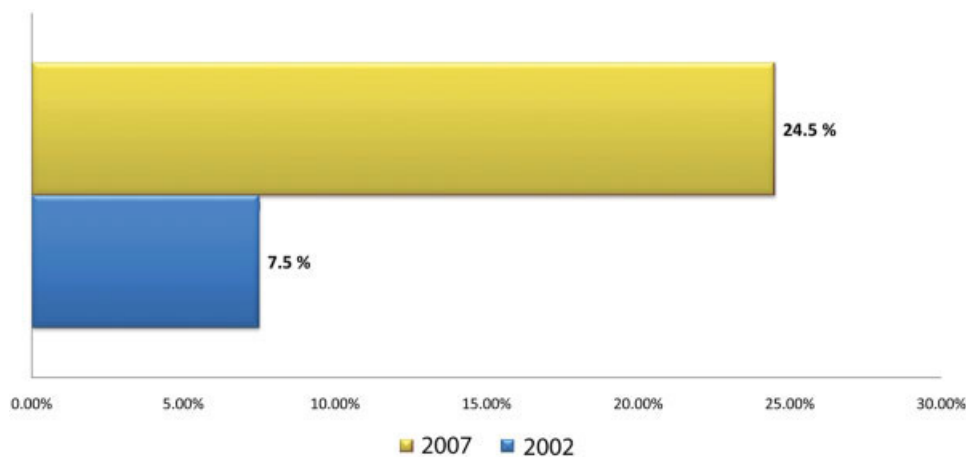


Figure 3. A bar chart showing the percentage of United Kingdom units not using any antibiotic prophylaxis during leech therapy in 2007 compared with 2002. [Color figure can be viewed in the online issue, which is available at [www.interscience.wiley.com](http://www.interscience.wiley.com).]

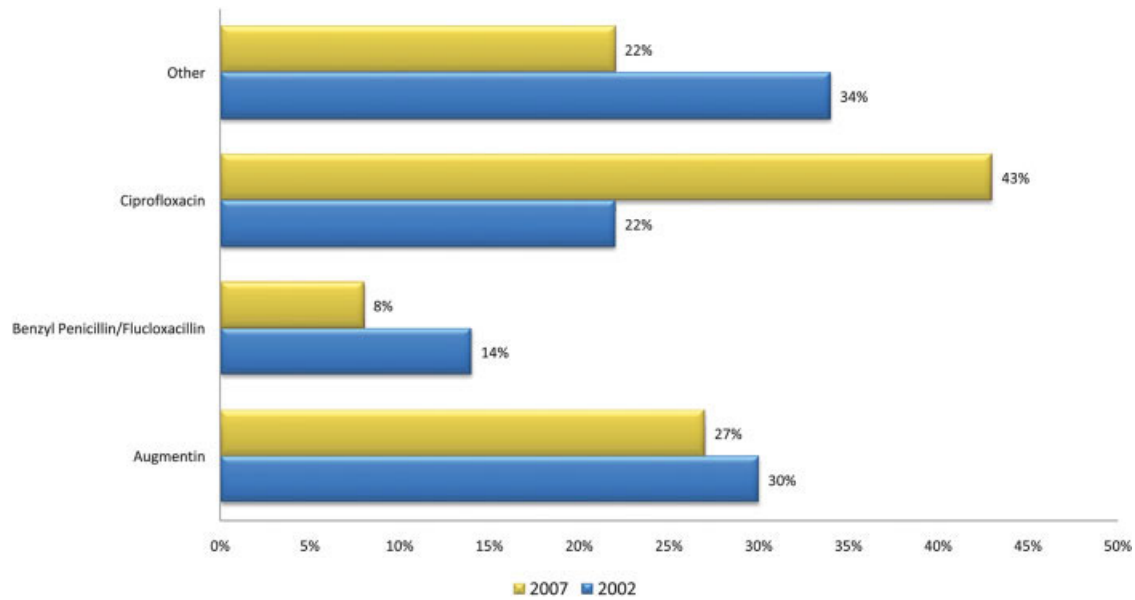


Figure 4. A bar chart showing the percentage of units using specific antibiotic prophylaxis in 2007 compared with 2002. [Color figure can be viewed in the online issue, which is available at [www.interscience.wiley.com](http://www.interscience.wiley.com).]

in escharotic flaps<sup>66</sup> and a case of meningitis due to leech-borne infection has previously been reported.<sup>67</sup>

### Leech-Borne Infection: Microbiology

Since 1976 three *Aeromonas* genospecies (*Aeromonas hydrophila*, *Aeromonas veronii*, and *Aeromonas caviae*) have been subdivided into 14 species.<sup>68</sup> A combination of molecular and biochemical studies has revealed the digestive tract of *H. verbana* contained *A. veronii*<sup>69,70</sup> and not *A. hydrophila*. Soft-tissue infections due to *A. hydrophila* have been widely reported as a complication of leech application but may well be due to *A. veronii*,<sup>58</sup> which has a similar clinical presentation. Apart from *A. hydrophila*, pathogens causing wound infection following Hirudo therapy reported in the literature include *Serratia marcescens*,<sup>71</sup> *Aeromonas sobria*,<sup>72</sup> and *Vibrio fluvialis*.<sup>73</sup> The accurate identification is challenging because commercial identification kits frequently misidentify the species and such kits could report *A. veronii* biovar *sobria* as *Aeromonas sobria*. The single report of *Vibrio fluvialis* associated infection may well have been misnamed, as the API20E method was used for identification purposes and the microbe was almost certainly an *Aeromonad*.<sup>74</sup> The API20E<sup>®</sup> test (bioMérieux) was used in the older studies to identify *Aeromonas* species. Although it is still used today, it is rather imprecise when compared with molecular genetic analysis. The test consists of a plastic strip of 20 individual, miniaturized tests tubes (cupules) each containing a different reagent used to determine the metabolic capabilities, and, ultimately, the genus and spe-

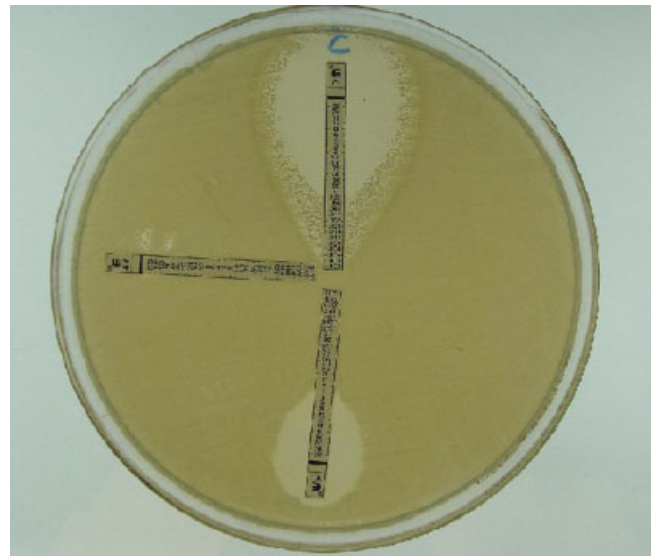

Figure 5. E test<sup>®</sup> results showing the susceptibility of *Aeromonas veronii* to ciprofloxacin (top center), the complete resistance to ampicillin (middle left), and intermediate resistance to augmentin (amoxycillin and clavulanic acid) (bottom middle). [Color figure can be viewed in the online issue, which is available at [www.interscience.wiley.com](http://www.interscience.wiley.com).]

cies of enteric bacteria in the family Enterobacteraceae. Interpretation of the 20 reactions plus a separate oxidase reaction is converted to a digital code which is compared with a known database of bacteria.

Knowledge of the diversity, virulence, and infections caused by *Aeromonas* spp. continues to increase rap-



idly.<sup>75</sup> Of potential clinical importance is the increasing incidence of multidrug resistance among *Aeromonas* spp. isolates that have been observed in aquaculture worldwide. This increasing incidence of resistance is due to the horizontal transfer of mobile genetic elements such as plasmids and class 1 integrons.<sup>76</sup> High levels of resistance to first-generation cephalosporins<sup>44</sup> and penicillins<sup>75–77</sup> (via  $\beta$ -lactamases), tetracyclines,<sup>76</sup> and augmentin<sup>76–79</sup> have been observed in studies, whereas fluoroquinolones seem to be consistently active.<sup>44,48,57,66,75–77</sup>

We performed a preliminary study to illustrate the antibiotic resistance profile of *A. veronii* to plastic surgeons considering using leeches in their practice. We identified a leech (*H. medicinalis*) by comparing with color charts<sup>80</sup> and isolated *A. veronii* in the laboratory from the leech crop using previously described techniques.<sup>81</sup> The identity of *Aeromonas* was confirmed using the API20E test and more accurate molecular genetic analysis. After plating a lawn of *A. veronii*, three Etest<sup>®</sup> strips comprising predefined gradients of antibiotic concentrations on strips of plastic were used to determine the on-scale minimum inhibitory concentration (MIC in  $\mu\text{g/ml}$ ) of ciprofloxacin, ampicillin, and augmentin. Following 48 hours of incubation, the Etest<sup>®</sup> results showed the susceptibility of *A. veronii* to ciprofloxacin (top center), the complete resistance to ampicillin (middle left), and intermediate resistance to augmentin (bottom middle) (see Fig. 5).

One of the limitations of this study is the lack of culture-based data from patients with infections following leech therapy. In an ideal world, a large prospective study would report on the clinical outcome and infection rate following leech therapy, along with an analysis of the microbiota and resistance profiles. The use of leeches is often a last resort, unplanned, and out of hours. Personal opinions and experience of their use varies from surgeon to surgeon. To coordinate the collection and analysis of this data would be incredibly difficult considering the diversity of units using leeches and the lack of a centralized database.

Considering the efficacy of leeches, it would be favorable to breed a germ-free leech. Unfortunately, *H. medicinalis*'s obligatory symbiotic relationship with *A. veronii* seems to preclude this.<sup>53,58,81–83</sup> Future research could potentially be targeted toward breeding less pathogenic genotypes which retain only the proteolytic determinants with the caveat that germ-free animals are susceptible to colonization by potentially more virulent bacteria.

## CONCLUSIONS

Infection due to leech therapy is a well-known complication with rates of up to 36.2% in recent studies.

Many units are not using appropriate antibiotic prophylaxis. There is known resistance of *Aeromonas* species to commonly used agents such as penicillins and augmentin. The recommended antibiotic at the present time is ciprofloxacin, which has favorable resistance profiles and good oral bioavailability.

## REFERENCES

- Whitaker IS, Rao J, Izadi D, Butler PE. Historical article: *Hirudo medicinalis*: Ancient origins of, and trends in the use of medicinal leeches throughout history. *Br J Oral Maxillofac Surg* 2004;42:133–137.
- Derganc M, Zdravic F. Venous congestion of flaps treated by application of leeches. *Br J Plast Surg* 1960;13:187–192.
- Michalsen A, Deuse U, Esch T, Dobos G, Moebus S. Effect of leeches therapy (*Hirudo medicinalis*) in painful osteoarthritis of the knee: A pilot study. *Ann Rheum Dis* 2001;60:986.
- Michalsen A, Moebus S, Spahn G, Esch T, Langhorst J, Dobos GJ. Leech therapy for symptomatic treatment of knee osteoarthritis: Results and implications of a pilot study. *Altern Ther Health Med* 2002;8:84–88.
- Michalsen A, Klotz S, Ludtke R, Moebus S, Spahn G, Dobos GJ. Effectiveness of leech therapy in osteoarthritis of the knee: A randomized, controlled trial. *Ann Intern Med* 2003;139:724–730.
- Batchelor AG, Davison P, Sully L. The salvage of congested skin flaps by the application of leeches. *Br J Plast Surg* 1984;37:358–360.
- Lineaweaver WC. *Aeromonas hydrophila* infections following clinical use of medicinal leeches: A review of published cases. *Blood Coagul Fibrinolysis* 1991;2:201–203.
- Lineaweaver WC, Hill MK, Buncke GM, Follansbee S, Buncke HJ, Wong RK, Manders EK, Grotting JC, Anthony J, Mathes SJ. *Aeromonas hydrophila* infections following use of medicinal leeches in replantation and flap surgery. *Ann Plast Surg* 1992;29:238–244.
- Whitaker IS, Izadi D, Oliver DW, Monteath G, Butler PE. *Hirudo medicinalis* and the plastic surgeon. *Br J Plast Surg* 2004;57:348–353.
- Rao J, Whitaker IS. Use of *Hirudo medicinalis* by maxillofacial surgical units in the United Kingdom: Current views and practice. *Br J Oral Maxillofac Surg* 2003;41:54–55.
- Frodel JL Jr, Barth P, Wagner J. Salvage of partial facial soft tissue avulsions with medicinal leeches. *Otolaryngol Head Neck Surg* 2004;131:934–939.
- Pantuck AJ, Lobis MR, Ciocca R, Weiss RE. Penile replantation using the leech *Hirudo medicinalis*. *Urology* 1996;48:953–956.
- Gideroglu K, Yildirim S, Akan M, Akoz T. Immediate use of medicinal leeches to salvage venous congested reverse pedicled neurocutaneous flaps. *Scand J Plast Reconstr Surg Hand Surg* 2003;37:277–282.
- Connor NP, Conforti ML, Heisey DM, Vanderby R, Kunz D, Hartig GK. Augmented blood removal after medicinal leech feeding in congested tissue flaps. *J Rehabil Res Dev* 2002;39:505–512.
- Dabb RW, Malone JM, Leverett LC. The use of medicinal leeches in the salvage of flaps with venous congestion. *Ann Plast Surg* 1992;29:250–256.
- Utlely DS, Koch RJ, Goode RL. The failing flap in facial plastic and reconstructive surgery: Role of the medicinal leech. *Laryngoscope* 1998;108:1129–1135.
- Brody GA, Maloney WJ, Hentz VR. Digit replantation applying the leech *Hirudo medicinalis*. *Clin Orthop Relat Res* 1989;245:133–137.
- Durrant C, Townley WA, Ramkumar S, Khoo CT. Forgotten digital tourniquet: Salvage of an ischaemic finger by application of medicinal leeches. *Ann R Coll Surg Engl* 2006;88:462–464.
- Gur E, Eldor A. Medicinal leeches for the salvage of a replanted digit. *Isr Med Assoc J* 1999;1:62.
- Lineaweaver WC, O'Hara M, Stridde B, Valauri FA, Buncke HJ. Clinical leech use in a microsurgical unit: The San Francisco experience. *Blood Coagul Fibrinolysis* 1991;2:189–192.

21. Shenfeld OZ. Successful use of the medicinal leech (*Hirudo medicinalis*) for the treatment of venous insufficiency in a replanted digit. *Isr Med Assoc J* 1999;1:221.
22. Soucacos PN, Beris AE, Malizos KN, Kabani CT, Pakos S. The use of medicinal leeches, *Hirudo medicinalis*, to restore venous circulation in trauma and reconstructive microsurgery *Int Angiol* 1994;13:251–258.
23. Tuncali D, Terzioglu A, Cigsar B, Aslan G. The value of medical leeches in the treatment of class IIC ring avulsion injuries: Report of 2 cases. *J Hand Surg [Am]* 2004;29:943–946.
24. Valauri FA. *Aeromonas hydrophilia* infection complicating digital replantation and revascularization. *J Hand Surg [Am]* 1991;16:181–182.
25. Gross MP, Apesos J. The use of leeches for treatment of venous congestion of the nipple following breast surgery. *Aesthetic Plast Surg* 1992;16:343–348.
26. Guneren E, Erolu L, Akba H, Uysal OA, Hokelek M, Erolu C. The use of *Hirudo medicinalis* in nipple-areolar congestion. *Ann Plast Surg* 2000;45:679–681.
27. Cho BH, Ahn HB. Microsurgical replantation of a partial ear, with leech therapy. *Ann Plast Surg* 1999;43:427–429.
28. de CT, Jones G. Replantation of the avulsed pinna: 100 percent survival with a single arterial anastomosis and substitution of leeches for a venous anastomosis. *Plast Reconstr Surg* 1995;95:1275–1279.
29. Funk GF, Bauman NM, Rinehart RJ, Mankarious LA. Microvascular replantation of a traumatically amputated ear. *Arch Otolaryngol Head Neck Surg* 1996;122:184–186.
30. Hullett JS, Spinnato GG, Ziccardi V. Treatment of an ear laceration with adjunctive leech therapy: A case report. *J Oral Maxillofac Surg* 2007;65:2112–2114.
31. Otto A, Schoeller T, Wechselberger G, Ohler K. [Successful ear replantation without venous anastomosis by using leeches]. *Handchir Mikrochir Plast Chir* 1999;31:98–101.
32. Talbi M, Stussi JD, Meley M. Microsurgical replantation of a totally amputated ear without venous repair. *J Reconstr Microsurg* 2001;17:417–420.
33. Holtje WJ. Successful replantation of an amputated upper lip. *Plast Reconstr Surg* 1984;73:664–670.
34. Walton RL, Beahm EK, Brown RE, Upton J, Reinke K, Fudem G, Banis J, Davidson J, Dabb R, Kalimuthu R, Kitzmiller WJ, Gottlieb LJ, Buncke HJ. Microsurgical replantation of the lip: A multi-institutional experience. *Plast Reconstr Surg* 1998;102:358–368.
35. Mortenson BW, Dawson KH, Murakami C. Medicinal leeches used to salvage a traumatic nasal flap. *Br J Oral Maxillofac Surg* 1998;36:462–464.
36. de Chalain TM. Exploring the use of the medicinal leech: A clinical risk-benefit analysis. *J Reconstr Microsurg* 1996;12:165–172.
37. Hayden RE, Phillips JG, McLearn PW. Leeches. Objective monitoring of altered perfusion in congested flaps. *Arch Otolaryngol Head Neck Surg* 1988;114:1395–1399.
38. Lee C, Mehran RJ, Lessard ML, Kerrigan CL. Leeches: Controlled trial in venous compromised rat epigastric flaps. *Br J Plast Surg* 1992;45:235–238.
39. Rados C. Beyond bloodletting: FDA gives leeches a medical makeover. *FDA Consum* 2004;38:9.
40. Siddall ME, Trontelj P, Utevsky SY, Nkamany M, Macdonald KS. Diverse molecular data demonstrate that commercially available medicinal leeches are not *Hirudo medicinalis*. *Proc Biol Sci* 2007;274:1481–1487.
41. Bely AE, Weisblat DA. Lessons from leeches: A call for DNA barcoding in the lab. *Evol Dev* 2006;8:491–501.
42. DeSalle R, Egan MG, Siddall M. The unholy trinity: Taxonomy, species delimitation and DNA barcoding. *Philos Trans R Soc Lond B Biol Sci* 2005;360:1905–1916.
43. Whitaker IS, Cheung CK, Chahal CA, Karoo RO, Gulati A, Foo IT. By what mechanism do leeches help to salvage ischaemic tissues? A review. *Br J Oral Maxillofac Surg* 2005;43:155–160.
44. Bauters TG, Buyle FM, Verschraegen G, et al. Infection risk related to the use of medicinal leeches. *Pharm World Sci* 2007;29:122–125.
45. Mercer NS, Beere DM, Bornemisza AJ, Thomas P. Medical leeches as sources of wound infection. *Br Med J (Clin Res Ed)* 1987;294:937.
46. Sartor C, Limouzin-Perotti F, Legré R, Casanova D, Bongrand MC, Sambuc R, Drancourt M. Nosocomial Infections with *Aeromonas hydrophila* from leeches. *Clin Infect Dis* 2002;35:E1–E5.
47. Lineaweaver WC, Furnas H, Follansbee S, Buncke GH, Whitney TM, Canales F, Bruneteau R, Buncke HJ. Postprandial *Aeromonas hydrophila* cultures and antibiotic levels of enteric aspirates from medicinal leeches applied to patients receiving antibiotics. *Ann Plast Surg* 1992;29:245–249.
48. Braga A, Lineaweaver WC, Whitney TM, Follansbee S, Buncke HJ. Sensitivities of *Aeromonas hydrophila* cultured from medicinal leeches to oral antibiotics. *J Reconstr Microsurg* 1990;6:135–137.
49. Hermansdorfer J, Lineaweaver W, Follansbee S, Valauri FA, Buncke HJ. Antibiotic sensitivities of *Aeromonas hydrophila* cultured from medicinal leeches. *Br J Plast Surg* 1988;41:649–651.
50. Kalbermatten DF, Rieger UM, Uike K, Erba P, Laifer G, Hintermann B, Pierer G. [Infection with *Aeromonas hydrophila* after use of leeches (*Hirudo medicinalis*) in a free microvascular osteo-(myo-) cutaneous flap—Suggestions for successful management]. *Handchir Mikrochir Plast Chir* 2007;39:108–111.
51. Snower DP, Ruef C, Kuritza AP, Edberg SC. *Aeromonas hydrophila* infection associated with the use of medicinal leeches. *J Clin Microbiol* 1989;27:1421–1422.
52. Whitaker IS, Elmihyeh B, Wright DJ. *Hirudo medicinalis*: The need for prophylactic antibiotics. *Plast Reconstr Surg* 2003;112:1185–1186.
53. Graf J, Kikuchi Y, Rio RV. Leeches and their microbiota: Naturally simple symbiosis models. *Trends Microbiol* 2006;14:365–371.
54. Sawyer RT. Feeding and digestive system. In: Sawyer RT, editor. *Leech Biology and Behaviour*. Oxford: Clarendon Press; 1986.
55. Kraemer BA, Korber KE, Aquino TI, Engleman A. Use of leeches in plastic and reconstructive surgery: A review. *J Reconstr Microsurg* 1988;4:381–386.
56. Bickel KD, Lineaweaver WC, Follansbee S, Feibel R, Jackson R, Buncke HJ. Intestinal flora of the medicinal leech *Hirudinaria manilensis*. *J Reconstr Microsurg* 1994;10:83–85.
57. Eroglu C, Hokelek M, Guneren E, Esen S, Pekbay A, Uysal OA. Bacterial flora of *Hirudo medicinalis* and their antibiotic sensitivities in the Middle Black Sea Region, Turkey *Ann Plast Surg* 2001;47:70–73.
58. Graf J. Symbiosis of *Aeromonas veronii* biovar *sobria* and *Hirudo medicinalis*, the medicinal leech: A novel model for digestive tract associations. *Infect Immun* 1999;67:1–7.
59. Graf J. Molecular requirements for the colonization of *Hirudo medicinalis* by *Aeromonas veronii*. *Prog Mol Subcell Biol* 2006;41:291–303.
60. Mackay DR, Manders EK, Saggars GC, Banducci DR, Prinsloo J, Klugman K. *Aeromonas* species isolated from medicinal leeches. *Ann Plast Surg* 1999;42:275–279.
61. de la Fuente AJ, Nodar GA, Touza RF, Crespo CM, Arnillas GE, Martinez VC. [Cellulitis caused by *Aeromonas hydrophila*]. *An Med Interna* 1999;16:635–636.
62. Fenollar F, Fourmier PE, Legre R. Unusual case of *Aeromonas sobria* cellulitis associated with the use of leeches. *Eur J Clin Microbiol Infect Dis* 1999;18:72–73.
63. Evans J, Lunnis PJ, Gaunt PN, Hanley DJ. A case of septicaemia due to *Aeromonas hydrophila*. *Br J Plast Surg* 1990;43:371–372.
64. Lowen RM, Rodgers CM, Ketch LL, Phelps DB. *Aeromonas hydrophila* infection complicating digital replantation and revascularization. *J Hand Surg [Am]* 1989;14:714–718.
65. Ketover BP, Young LS, Armstrong D. Septicemia due to *Aeromonas hydrophila*: Clinical and immunologic aspects. *J Infect Dis* 1973;127:284–290.
66. Ardehali B, Hand K, Nduka C, Holmes A, Wood S. Delayed leech-borne infection with *Aeromonas hydrophila* in escharotic flap wound. *J Plast Reconstr Aesthet Surg* 2006;59:94–95.
67. Ouder Kirk JP, Bekhor D, Turett GS, Murali R. *Aeromonas meningitis* complicating medicinal leech therapy. *Clin Infect Dis* 2004;38:e36–e37.
68. Janda JM, Abbott SL. Evolving concepts regarding the genus *Aeromonas*: An expanding panorama of species, disease presentations, and unanswered questions. *Clin Infect Dis* 1998;27:332–344.

69. Abbott SL, Cheung WK, Janda JM. The genus *Aeromonas*: Biochemical characteristics, atypical reactions, and phenotypic identification schemes. *J Clin Microbiol* 2003;41:2348–2357.
70. Ormen O, Granum PE, Lassen J, Figueras MJ. Lack of agreement between biochemical and genetic identification of *Aeromonas* spp. *APMIS* 2005;113:203–207.
71. Pereira JA, Greig JR, Liddy H, Ion L, Moss AL. Leech-borne *Serratia marcescens* infection following complex hand injury. *Br J Plast Surg* 1998;51:640–641.
72. Fenollar F, Fournier PE, Legre R. Unusual case of *Aeromonas sobria* cellulitis associated with the use of leeches. *Eur J Clin Microbiol Infect Dis* 1999;18:72–73.
73. Varghese MR, Farr RW, Wax MK, Chafin BJ, Owens RM. *Vibrio fluvialis* wound infection associated with medicinal leech therapy. *Clin Infect Dis* 1996;22:709–710.
74. Abbott SL, Seli LS, Catino M Jr, Hartley MA, Janda JM. Misidentification of unusual *Aeromonas* species as members of the genus *Vibrio*: A continuing problem. *J Clin Microbiol* 1998;36:1103–1104.
75. Jones BL, Wilcox MH. *Aeromonas* infections and their treatment. *J Antimicrob Chemother* 1995;35:453–461.
76. Jacobs L, Chenia HY. Characterization of integrons and tetracycline resistance determinants in *Aeromonas* spp. isolated from South African aquaculture systems. *Int J Food Microbiol* 2007;114:295–306.
77. Rolston KV, Ho DH, LeBlanc B, Bodey GP. Activity of newer antimicrobial agents against *Aeromonas hydrophila*. *Eur J Clin Microbiol* 1986;5:454–456.
78. Motyl MR, McKinley G, Janda JM. In vitro susceptibilities of *Aeromonas hydrophila*, *Aeromonas sobria*, and *Aeromonas caviae* to 22 antimicrobial agents. *Antimicrob Agents Chemother* 1985;28:151–153.
79. Vila J, Marco F, Soler L, Chacon M, Figueras MJ. In vitro antimicrobial susceptibility of clinical isolates of *Aeromonas caviae*, *Aeromonas hydrophila* and *Aeromonas veronii* biotype *sobria*. *J Antimicrob Chemother* 2002;49:701–702.
80. Trontelj P, Utevsky SY. Celebrity with a neglected taxonomy: Molecular systematics of the medicinal leech (genus *Hirudo*). *Mol Phylogenet Evol* 2005;34:616–624.
81. Worthen PL, Gode CJ, Graf J. Culture-independent characterization of the digestive-tract microbiota of the medicinal leech reveals a tripartite symbiosis. *Appl Environ Microbiol* 2006;72:4775–4781.
82. Busing KH, Doll W, Freytag K. [Bacterial flora of the medicinal leech.]. *Arch Mikrobiol* 1953;19:52–86.
83. Kikuchi Y, Graf J. Spatial and temporal population dynamics of a naturally occurring two-species microbial community inside the digestive tract of the medicinal leech. *Appl Environ Microbiol* 2007;73:1984–1991.