

THE EFFICACY OF POSTOPERATIVE MONITORING: A SINGLE SURGEON COMPARISON OF CLINICAL MONITORING AND THE IMPLANTABLE DOPPLER PROBE IN 547 CONSECUTIVE FREE FLAPS

WARREN M. ROZEN, M.B.B.S., B.Med.Sc., P.G. Dip. Surg. Anat., Ph.D.,^{1*} DANIEL CHUBB, M.B.B.S., B.Med.Sc.,¹ IAIN S. WHITAKER, B.A. (Hons), M.A. Cantab., M.B.B.Chir. M.R.C.S.,² and RAFAEL ACOSTA, M.D., E.B.O.P.R.A.S.³

Background: An important element in achieving high success rates with free flap surgery has been the use of different techniques for monitoring flaps postoperatively as a means to detecting vascular compromise. Successful monitoring of the vascular pedicle to a flap can potentiate rapid return to theater in the setting of compromise, with the potential to salvage the flap. There is little evidence that any technique offers any advantage over clinical monitoring alone. **Methods:** A consecutive series of 547 patients from a single plastic surgical unit who underwent a fasciocutaneous free flap operation for breast reconstruction [deep inferior epigastric artery perforator (DIEP) flap, superficial inferior epigastric artery (SIEA) flap, or superior gluteal artery perforator (SGAP) flap] were included. A comparison was made between the first 426 consecutive patients in whom flap monitoring was performed using clinical monitoring alone and the subsequent 121 patients in whom monitoring was achieved with the Cook-Swartz implantable Doppler probe. Outcome measures included flap salvage rate and false-positive rate. **Results:** There was a strong trend toward improved salvage rates with the implantable Doppler probe compared with clinical monitoring (80% vs. 66%, $P = 0.48$). When combined with the literature (meta-analysis), the data prove statistically significant ($P < 0.01$). There was no statistical difference between the groups for false-positive rates. **Conclusion:** Flap monitoring with the implantable Doppler probe can improve flap salvage rates without increasing the rate of false-positive takebacks. ©2009 Wiley-Liss, Inc. *Microsurgery* 30:105–110, 2010.

Success rates of free flap operations have steadily increased since their inception four decades ago. An important element in achieving these outcomes has been the use of different techniques for monitoring flaps postoperatively as a means to detecting vascular compromise. Successful monitoring of the vascular pedicle to a flap can potentiate rapid return to theater in the setting of compromise, with the potential to salvage the flap.

There is universal agreement that early intervention is key to the successful salvage of a flap that has become compromised by arterial or venous thrombosis, external compression, or kinking of the pedicle.^{1–6} Currently, the only method that is ubiquitous amongst microsurgical units is the use of clinical monitoring.^{7,8} Although some studies have demonstrated that adjunctive monitoring techniques may have benefit, and indeed that flap salvage rate may be increased,^{9–11} there are still no large-scale comparative trials supporting these studies. Without rea-

sonable evidence for new monitoring techniques, bedside monitoring has remained the norm, with some units using adjunctive techniques at the discretion of the surgeon.^{7,8}

The implantable Doppler probe manufactured by Cook[®] has been the subject of several recent articles in the plastic surgery literature.^{10,12–20} Despite these recent publications, only one previous study assessing the implanted Doppler probe has used clinically relevant endpoints as its primary outcome measure.¹⁰ This study was thus undertaken to assess the surgical outcomes associated with the Cook-Swartz probe on large scale, in a way that enables objective evaluation of its efficacy.

METHODS

A retrospective analysis of a consecutive series of patients from a single plastic surgical unit was undertaken. All patients who underwent a fasciocutaneous free flap operation for breast reconstruction [deep inferior epigastric artery perforator (DIEP) flap, superficial inferior epigastric artery (SIEA) flap, or superior gluteal artery perforator (SGAP) flap] were included. All the patients were monitored postoperatively with only one of clinical monitoring alone or with the Cook-Swartz implantable Doppler probe. The analysis was achieved by chart review.

Patient records were assessed to determine the postoperative course after their free flap operation. Several factors were identified for each patient, including whether they were taken back to theater for presumed pedicle compromise, reoperative findings, and final outcomes of their operations.

¹Jack Brockhoff Reconstructive Plastic Surgery Research Unit, Department of Anatomy, University of Melbourne, Parkville 3050, Victoria, Australia

²Department of Plastic, Reconstructive and Burns Surgery, The Welsh Centre for Burns and Plastic Surgery, Morriston Hospital, Swansea, UK

³Department of Plastic Surgery, Uppsala University Hospital, Uppsala 75185, Sweden

The first two authors contributed equally to this work.

*Correspondence to: Warren M. Rozen, M.B.B.S., B.Med.Sc., P.G. Dip. Surg. Anat., Ph.D., Jack Brockhoff Reconstructive Plastic Surgery Research Unit, Room E533, Department of Anatomy, University of Melbourne, Grattan St, Parkville, Victoria 3050, Australia.
E-mail: warrenrozen@hotmail.com

Received 14 July 2009; Accepted 10 August 2009

Published online 29 September 2009 in Wiley InterScience (www.interscience.wiley.com). DOI 10.1002/micr.20706

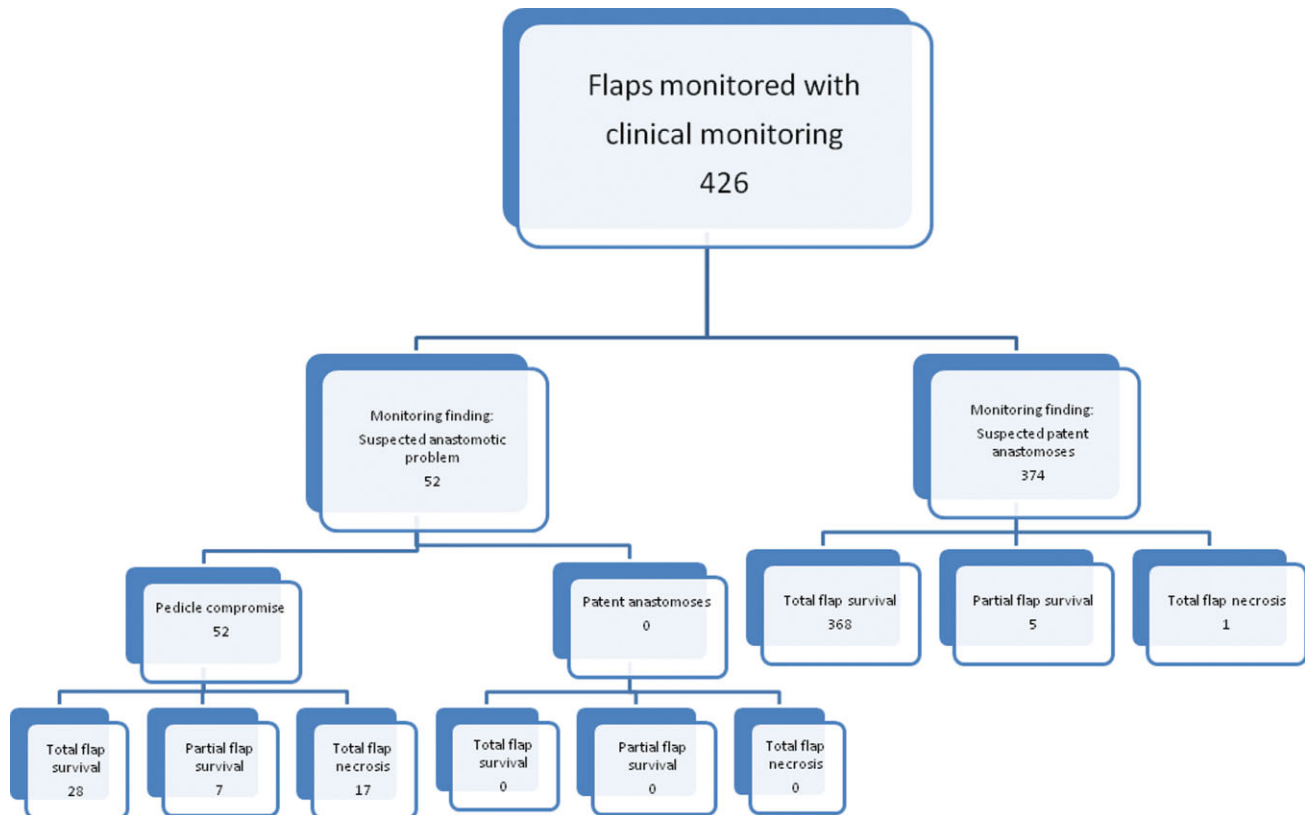


Figure 1. Flow chart for the recording of outcomes for each flap monitored with clinical monitoring alone. Each flap being monitored is recorded as either encountering a positive monitoring alarm or not encountering an alarm, with findings at theater noted, and ultimate outcomes recorded for each group. [Color figure can be viewed in the online issue, which is available at www.interscience.wiley.com.]

Application of Clinical Monitoring

Clinical monitoring was achieved through the assessment of the color, temperature, tactility, capillary refill, bleeding, and appearance of the flap. Assessment begins intraoperatively and is continued by both medical and nursing staff postoperatively. Suspicion of flap compromise by either nursing or more junior medical staff results in consultation with senior medical staff who bear the ultimate responsibility for decisions to reexplore the flap.

Application of the Cook-Swartz Implantable Doppler Probe

The Cook-Swartz probe (Cook Medical[®], Cook Ireland Ltd, Limerick, Ireland) comes with a specifically designed silicone cuff, which is wrapped carefully around the venous pedicle following successful venous anastomosis. Application is always distal to the anastomosis, and our surgeons prefer to use microclips rather than sutures or glue for attachment. The tension of the silicone cuff is important, as a tight cuff may cause venous outflow obstruction, while a loose cuff is prone to false-positive results. Multiple venous anastomoses can be monitored simultane-

ously with the Cook-Swartz system. Routine flap monitoring is performed without adjunctive clinical monitoring. As such, we use Cook-Swartz probe as a primary monitoring technique, with thorough clinical assessment following any detection of pedicle compromise by the probe.

The Cook-Swartz probe is first used intraoperatively, both to ensure proper application of the probe and to check anastomotic patency during flap inseting. Any problems detected intraoperatively can then be reexplored immediately. After completion of the operation, monitoring surveillance using the probe is carried out by both medical and nursing staff, who are instructed to report any change in the audible output to medical staff.

Algorithm and Outcome Analysis

Each flap was categorized into one of each of the two monitoring groups and were then stratified further into groups according to an algorithm based on monitoring findings (see Figs. 1 and 2). A monitored flap was first stratified according to whether there was a positive monitoring "alarm" (i.e., the monitoring test suggested that there was pedicle compromise requiring a return to theater for pedicle revision). Of the positive alarms, the find-

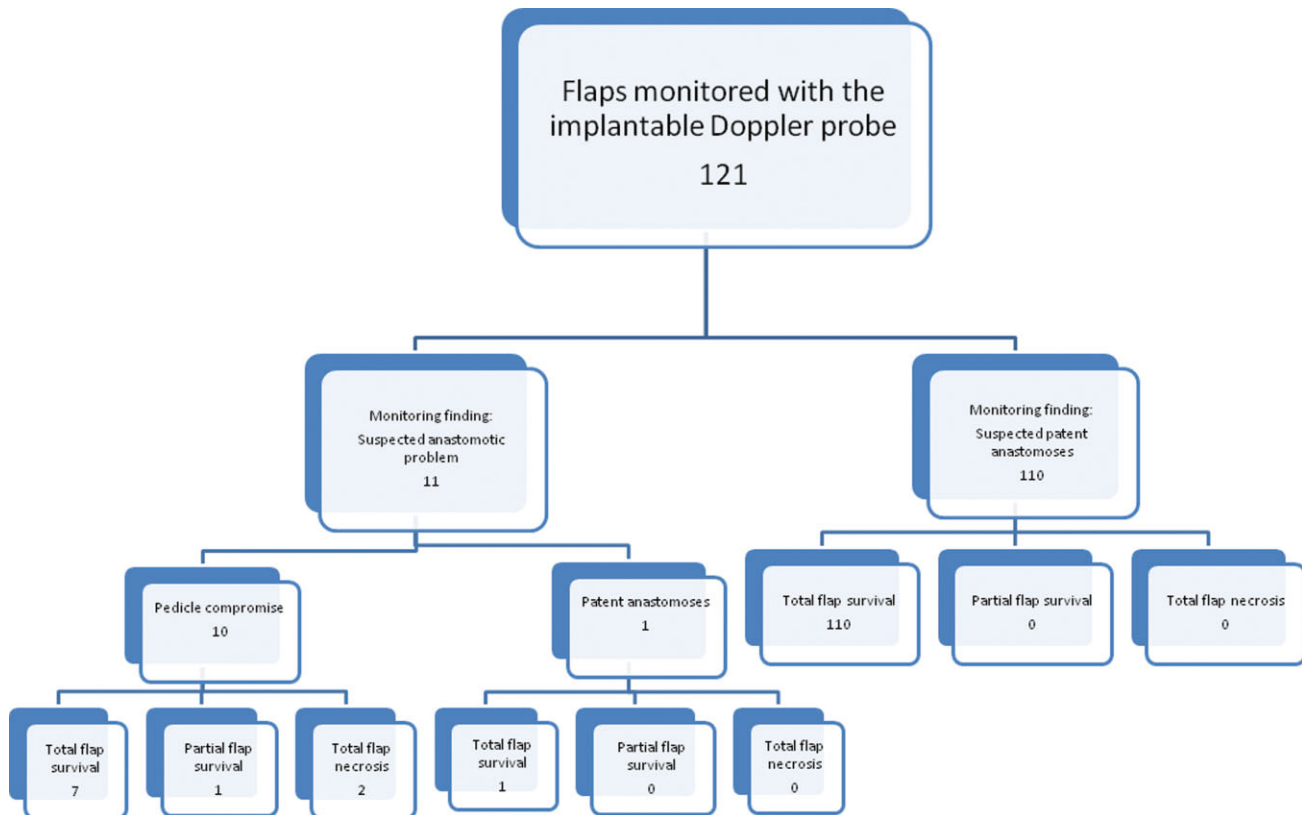


Figure 2. Flow chart for the recording of outcomes for each flap monitored with the Cook-Swartz implantable Doppler probe. Each flap being monitored is recorded as either encountering a positive monitoring alarm or not encountering an alarm, with findings at theater noted, and ultimate outcomes recorded for each group. [Color figure can be viewed in the online issue, which is available at www.interscience.wiley.com.]

ings at theater were then able to stratify these flaps into those cases with confirmed pedicle compromise and those without any pedicle compromise identified. In all the groups, the final flap outcomes were then documented.

Two primary outcome measures were assessed. The first was the flap salvage rate, calculated as all flaps with true pedicle compromise that ultimately survived divided by all flaps with true pedicle compromise (i.e., all true positives and all false negatives). The second was the false-positive rate, which was calculated as all flaps with positive monitoring alarms that were found to have no pedicle compromise (i.e., false positives) divided by all flaps with no pedicle compromise (i.e., all false positives and all true negatives). These have been described previously as true tests of the efficacy of each technique by Whitney et al.⁹ and Lineaweaver,²¹ with flap salvage rate showing the benefit of any monitoring technique in improving outcomes and the false-positive rate reporting the number of needless returns to theater. Both of these measures are aimed at demonstrating the effectiveness of the monitoring technique when compared with no monitoring at all (or a nonfunctioning monitor, a concept that is also of Lineaweaver's invention²¹). It is clear that a

reasonable monitoring technique can perform well when compared with a nonfunctioning monitor, but it is also important that the new method is better than the clinical standard. For this reason, it is important that any prospective monitoring technique is compared with clinical monitoring alone in the critical analysis of its effectiveness.

The false-negative rate was not included, as this calculation is dependent upon surgeon decision making; i.e., if a flap is ultimately failing due to pedicle compromise (and not salvaged), this case is recorded as reducing the flap salvage rate of the given monitoring technique, regardless of the decision to take a flap to theater for revision (which would result in a true positive) or to not take it back to theater (which would result in a false negative).

Data for each monitoring group was analyzed for statistical significance performed using Fisher's exact test. Statistical significance was considered at $P \leq 0.05$.

RESULTS

The study comprised 547 consecutive patients. Of these, a comparison was made between the first 426 consecutive patients in whom flap monitoring was performed

Table 1. Outcomes from the Use of Monitoring with Each of Clinical Monitoring Alone and the Implantable Doppler Probe

	Clinical assessment	Cook-Swartz implantable Doppler probe	<i>P</i> value
Raw data			
True positives	52/426 = 12.2%	10/121 = 8.3%	N/A
False positives	0/426 = 0%	1/121 = 0.8%	N/A
True negatives	373/426 = 87.6%	110/121 = 90.9%	N/A
False negatives	1/426 = 0.2%	0/121 = 0%	N/A
Outcomes			
Overall survival rate (<i>n</i> /%)	408/426 = 95.8%	119/121 = 98.3%	0.18
Flap salvage rate (salvaged flaps/compromised flaps) (<i>n</i> /%)	35/53 = 66%	8/10 = 80%	0.48
False-positive rate (false positives/uncompromised flaps) (<i>n</i> /%)	0/373 = 0%	1/111 = 0.9%	0.23

using clinical monitoring alone and the subsequent 121 patients in whom monitoring was achieved with the Cook-Swartz implantable Doppler probe. In terms of the overall findings, 63 were taken back to theater, with all but one flap demonstrating pedicle compromise (i.e., 62 true positives and 1 false positive). One flap not taken back to theater ultimately failed (a false negative). Of the 63 flaps that did have pedicle compromise (62 of which were true positives and 1 was a false negative), 43 were salvaged (an overall flap salvage rate of 68%). Overall, 408 flaps out of the 426 ultimately survived (an overall success rate of 96%).

Each flap was classified according to the algorithm described, with a comparison between clinical monitoring (Fig. 1) and the Cook-Swartz implantable Doppler probe (Fig. 2). Table 1 summarizes operative and reoperative outcomes. It can be seen that there were no differences between the groups in term of overall salvage rates (98% vs. 96%, $P = 0.18$) and no statistically significant differences between the techniques in terms of the primary outcome measures, flap salvage rate (80% vs. 66%, $P = 0.48$), and false-positive rate (1% vs. 0%, $P = 0.23$). However, this trend toward increase flap salvage rate in the implantable Doppler arm compared with clinical monitoring alone (80% vs. 66%) was notable.

The primary outcome measures of efficacy (flap salvage rate and false-positive rate) are calculated for each group.

The use of the implantable Doppler probe was thus able to potentiate the salvage of an additional 1.4 flaps over the calculated salvage rate of clinical monitoring in the same group.

DISCUSSION

There has been a substantial body of data presenting anecdotal evidence for the use of a multitude of monitoring techniques. However, there has been a relative paucity of trials that demonstrate the efficacy of any moni-

toring technique over clinical monitoring. To date, only three such trials have been published, supporting the use of quantitative fluorometry, laser Doppler flowmetry, and the implanted Doppler probe.⁹⁻¹¹

The first attempt to use an implantable Doppler probe for free flap monitoring was in 1984 by Parker et al.,¹⁹ and soon afterward, Cook Medical developed a probe specifically for use in free flap operations.²⁰ It was initially used on the arterial pedicle, but subsequent studies showed it to be more sensitive when placed on the venous anastomosis, particularly for the detection of venous thrombosis.¹³ There have been some other minor revisions in the technique used to apply the probe.

There is only one previous study that purports to show that the implanted Doppler probe can improve flap salvage rates.¹⁰ In this study, Kind et al. evaluated a series of 147 free flaps in 135 patients who were monitored by this method. They reported an outstanding 100% flap salvage rate, with a false-positive rate of 3.4%. Although it is clear that these results weigh heavily in favor of the implanted Doppler probe, the number of failing flaps in this study was small. As such, further publication is necessary for providing adequate evidence in support of the use of implanted Doppler devices. We have previously published a series of free flaps monitored with this method,¹⁵ but this series was not compared with clinical monitoring. By adding this comparative analysis to the published literature, we hope to improve the evidence supporting the use of the implanted Doppler probe.

Inclusive of the study by Kind et al., this is only the second study to provide an objective comparison of the implanted Doppler probe to clinical monitoring using clinically relevant outcome measures as primary endpoints. A clear trend of increased flap salvage was seen in our trial, but this trend was not statistically significant. The groups were highly comparable, although the numbers in the Doppler arm were not as pronounced, and with greater power to the study greater significance may be achievable. Although the study by Kind et al. showed

statistical significance, the number of compromised flaps involved with this study was still small ($n = 16$ compromised flaps). If the data from both studies are combined, a clinical flap salvage rate of 70% and implanted Doppler salvage rate of 92% is seen, with statistical significance ($P < 0.01$, Fisher's exact test). This is without a statistical increase in the false-positive rate, with Kind et al. showing a false-positive rate of 3% compared with our 0.9%. This combined result demonstrates a clear clinical benefit of the implanted Doppler probe, especially if the number needed to treat (NNT) before a single additional flap is salvaged at reexploration is calculated based on this combined data. With an absolute salvage rate increase of 22%, the NNT is 4.54, demonstrating that on average, for every five flaps reexplored for pedicle compromise, one additional flap will be salvaged.

The implanted Doppler probe has several other benefits over most other monitoring techniques. It can be used continuously, allowing for very early recognition of pedicle compromise. It is also a direct pedicle monitor rather than many other methods, which measure perfusion, oxygenation, or ischaemia within the flap itself which take time to manifest. This removes the possibility of the Doppler probe being confounded by problems affecting only part of the flap (territorial problems). Other advantages that the implanted Doppler has over clinical monitoring specifically are the monitoring of buried flaps, as well as improving patient comfort.

These benefits need to be evaluated in the context of the increased financial cost associated with the implantable Doppler probe. The Cook-Swartz implantable Doppler system itself costs US\$3000 (reusable) and the disposable probes cost US\$250 per patient. During the course of the current study (121 cases), this was a cost of US\$275 per patient to use the device. In our study, the overall survival rate was 96%, and thus despite an increase in flap salvage from 66 to 80%, the overall benefit needs to be assessed with some perspective. Using our results, the use of the implantable Doppler probe in the clinically monitored cohort would have potentiated the salvage of 7.4 additional flaps. The financial cost of monitoring in the implantable Doppler arm was thus US\$33,275 to potentiate the salvage of an additional 1.4 flaps (in the order of US\$20,000 to salvage one flap). The cost of the surgical management of a failed flap (both the early management and the repeat reconstruction) can be well over this amount.

The improved flap salvage rates associated with a monitoring technique need to be evaluated simultaneously with the detrimental effects associated with any monitoring technique, in particular, the false-positive takebacks to theater, the rate of which has been shown to be extremely low with clinical monitoring.²² Initial studies of the implanted Doppler probe demonstrated a high

false-positive rate, which in some cases was as high as 37%.²³ However, subsequent studies, including that of Kind et al. have shown rates of around 3%.^{10,13} It is thought that the false-positive rates shown in earlier studies were most likely due to the learning curve associated with using the device.^{13,19,20} In keeping with the theory that a learning curve was responsible for the initial problems with false-positive rates, our study has demonstrated the lowest false-positive rate in a case series to date, with only 1 case in our series of 121 flaps having a false-positive result. Other described complications with the Doppler probe include failure to apply the probe adequately and difficulty in probe removal, complications we did not encounter in any of our cases.

Another way to measure monitoring success would be to evaluate the performance of the monitor in terms of false-negative results. However, as discussed, false negatives may depend on an individual surgeon's decision making and is thus not a truly independent test of a specific monitor; i.e., if a flap is ultimately failing due to pedicle compromise (and not salvaged), the decision to take a flap back to theater for revision would classify the flap as a true positive, while not taking it back would register a false negative. Regardless, as can be seen from our results, clinical monitoring has been overwhelmingly successful in this regard, meaning that the false-negative rate can only be used as a measure of whether the prospective technique can be used as a stand-alone method or whether it is confined to use in an adjunctive role only.

In addition to the similar salvage rates as those attained through the use of clinical monitoring, this study demonstrates that the Doppler probe has extremely low false-positive and false-negative rates when used as a stand-alone device by experienced surgical units. This means that the use of the implanted Doppler probe can be accepted as a safe stand-alone monitoring technique once the initial learning curve of using this technique has been overcome. Even by the most pessimistic analysis, this implanted Doppler monitoring performs no worse than clinical monitoring alone and is likely to be able to improve flap salvage rates, a conclusion that becomes apparent when the results of this study are considered in the context of the previous study by Kind et al. Given the NNT described earlier, the beneficial effects of this monitoring technique will be apparent after only a small number flaps are reexplored due to vascular compromise.

CONCLUSION

The implanted Doppler probe is a safe and an effective monitoring technique that is able to be used as a stand-alone monitoring technique. Initial use of the

device can be associated with a learning curve that may result in a small number of false-positive results. Although this study did not show clinical significance, a trend of significant benefit was seen. Combined with the results of the previous study by Kind et al., a statistically significant benefit is in fact confirmed.

REFERENCES

- Bui DT, Cordeiro PG, Hu QY, Disa JJ, Pusic A, Mehrara BJ. Free flap reexploration: Indications, treatment, and outcomes in 1193 free flaps. *Plast Reconstr Surg* 2007;119:2092–2100.
- Chen KT, Mardini S, Chuang DC, Lin CH, Cheng MH, Lin YT, Huang WC, Tsao CK, Wei FC. Timing of presentation of the first signs of vascular compromise dictates the salvage outcome of free flap transfers. *Plast Reconstr Surg* 2007;120:187–195.
- Hofer SO, Damen TH, Mureau MA, Rakhorst HA, Roche NA. A critical review of perioperative complications in 175 free deep inferior epigastric perforator flap breast reconstructions. *Ann Plast Surg* 2007;59:137–142.
- May JW, Chait LA, O'Brien BM, Hurley JV. The no-reflow phenomenon in experimental free flaps. *Plast Reconstr Surg* 1978;61:256–267.
- Smit JM, Acosta R, Zeebregts CJ, Liss AG, Anniko M, Hartman EH. Early reintervention of compromised free flaps improves success rate. *Microsurgery* 2007;27:612–616.
- Smit JM, Zeebregts CJ, Acosta R. Timing of presentation of the first signs of vascular compromise dictates the salvage outcome of free flap transfers. *Plast Reconstr Surg* 2008;122:991–992.
- Whitaker IS, Gulati V, Ross GL, Menon A, Ong TK. Variations in the postoperative management of free tissue transfers to the head and neck in the United Kingdom. *Br J Oral Maxillofac Surg* 2007;45:16–18.
- Whitaker IS, Oliver DW, Ganchi PA. Postoperative monitoring of microvascular tissue transfers: Current practice in the United Kingdom and Ireland. *Plast Reconstr Surg* 2003;111:2118–2119.
- Whitney TM, Lineaweaver WC, Billys JB, Siko PP, Buncke GM, Alpert BS, Oliva A, Buncke HJ. Improved salvage of complicated microvascular transplants monitored with quantitative fluorometry. *Plast Reconstr Surg* 1992;90:105–111.
- Kind GM, Buntic RF, Buncke GM, Cooper TM, Siko PP, Buncke HJ. The effect of an implantable Doppler probe on the salvage of microvascular tissue transplants. *Plast Reconstr Surg* 1998;101:1268–1273; discussion 1274–1275.
- Goldberg J, Sepka RS, Perona BP, Pederson WC, Klitzman B. Laser Doppler blood flow measurements of common cutaneous donor sites for reconstructive surgery. *Plast Reconstr Surg* 1990;85:581–586.
- Whitaker IS, Smit JM, Acosta R. A simple method of implantable Doppler cuff attachment: Experience in 150 DIEP breast reconstructions. *J Plast Reconstr Aesthet Surg* 2008;61:1251–1252.
- Swartz WM, Izquierdo R, Miller MJ. Implantable venous Doppler microvascular monitoring: Laboratory investigation and clinical results. *Plast Reconstr Surg* 1994;93:152–163.
- Solomon GA, Yaremchuk MJ, Manson PN. Doppler ultrasound surface monitoring of both arterial and venous flow in clinical free tissue transfers. *J Reconstr Microsurg* 1986;3:39–41.
- Smit JM, Whitaker IS, Liss AG, Audolfsson T, Kildal M, Acosta R. Post operative monitoring of microvascular breast reconstructions using the implantable Cook-Swartz Doppler system: A study of 145 probes & technical discussion. *J Plast Reconstr Aesthet Surg* 2009 [Epub ahead of print].
- Pryor SG, Moore EJ, Kasperbauer JL. Implantable Doppler flow system: Experience with 24 microvascular free-flap operations. *Otolaryngol Head Neck Surg* 2006;135:714–718.
- De La Torre J, Hedden W, Grant JH, Gardner PM, Fix RJ, Vasconez LO. Retrospective review of the internal Doppler probe for intra- and postoperative microvascular surveillance. *J Reconstr Microsurg* 2003;19:287–290.
- Oliver DW, Whitaker IS, Giele H, Critchley P, Cassell O. The Cook-Swartz venous Doppler probe for the post-operative monitoring of free tissue transfers in the United Kingdom: A preliminary report. *Br J Plast Surg* 2005;58:366–370.
- Parker PM, Fischer JC, Shaw WW. Implantable pulsed Doppler cuff for long-term monitoring of free flaps: A preliminary study. *Microsurgery* 1984;5:130–135.
- Swartz WM, Jones NF, Cherup L, Klein A. Direct monitoring of microvascular anastomoses with the 20-MHz ultrasonic Doppler probe: An experimental and clinical study. *Plast Reconstr Surg* 1988;81:149–161.
- Lineaweaver WC. The implantable Doppler probe. *Plast Reconstr Surg* 1988;82:1099–1100.
- Disa JJ, Cordeiro PG, Hidalgo DA. Efficacy of conventional monitoring techniques in free tissue transfer: An 11-year experience in 750 consecutive cases. *Plast Reconstr Surg* 1999;104:97–101.
- Rosenberg JJ, Fornage BD, Chevray PM. Monitoring buried free flaps: Limitations of the implantable Doppler and use of color duplex sonography as a confirmatory test. *Plast Reconstr Surg* 2006;118:109–113; discussion 114–105.