

Department of Diagnostic Radiology  
Helsinki University Central Hospital  
University of Helsinki, Finland

**MULTIDETECTOR COMPUTED TOMOGRAPHY AND MAGNETIC  
RESONANCE IMAGING OF ACUTE KNEE TRAUMA**

**Erno Peltola**

Academic Dissertation

To be presented with the permission of  
The Faculty of Medicine of the University of Helsinki for public discussion in  
Auditorium I, Töölö Hospital  
On December 9th 2016 at 12 noon.

Helsinki 2016

**Supervisor:** Professor Seppo K. Koskinen, Division of Medical Imaging and Technology, Department of Clinical Science, Intervention and Technology, Karolinska Institute, Sweden

**Reviewed by:** Associate professor Mats Geijer, Department of Radiology, Lund University and Docent Jukka Ristiniemi, Department of Orthopedic and Trauma Surgery, University of Oulu

**Opponent:** Docent Jaakko Niinimäki, Department of Radiology, University of Oulu

ISBN 978-951-51-2680-1 (paperback)

ISBN 978-951-51-2681-8 (PDF)

Unigrafia Helsinki University Print

Helsinki 2016

To Marjaana, Viena and Kielo

## TABLE OF CONTENTS

ABSTRACT.....	1
LIST OF ORIGINAL PUBLICATIONS.....	3
ABBREVIATIONS.....	4
INTRODUCTION.....	5
REVIEW OF THE LITERATURE.....	8
Avulsion fractures in acute knee trauma.....	8
Tibial plateau fractures.....	12
Cruciate ligament injuries.....	13
Meniscal injuries.....	14
Overweight as a risk factor.....	14
Femorotibial dislocation.....	15
Neural injuries in acute knee trauma.....	17
Vascular injuries in acute knee trauma.....	18
Patellar dislocation.....	20
Imaging modalities.....	21
AIMS OF THE STUDY.....	26
MATERIALS AND METHODS.....	27
RESULTS.....	34
DISCUSSION.....	42
CONCLUSIONS.....	51
ACKNOWLEDGEMENTS.....	54
REFERENCES.....	56
ORIGINAL PUBLICATIONS.....	68

## **ABSTRACT**

**OBJECTIVE.** The main purpose of this thesis was to evaluate the incidence, injury patterns and MRI and MDCT findings of the acute trauma patients with knee dislocation, patellar dislocation, Segond fracture and reverse Segond fracture, and also to examine dual-energy computed tomography in evaluating cruciate ligament injuries.

**MATERIALS AND METHODS.** At a level 1 trauma center, emergency department acute trauma patients MDCT or MRI examinations were retrospectively evaluated for knee dislocation, patellar dislocation, reverse Segond fracture and Segond fracture. Pediatric population was not included in studies, except in the patellar dislocation material. Surgical findings served as the reference standard for intra-articular injuries. In the DECT publication, a level 1 trauma center DECT examinations for acute knee trauma was reviewed by two radiologists for presence of cruciate ligament injuries, and the subsequent MRI served as a reference standard.

**RESULTS.** A total of 24 patients with a knee dislocation, 71 patients with a patellar dislocation, 33 patients with a Segond fracture and 10 patients with a reverse Segond fracture were found. The annual incidence of knee dislocation due to low energy trauma in overweight patients was found to be significant, about 1.0 per million, and these patients had no injuries to the popliteal tendon and no irreversible peroneal nerve injuries, otherwise, the patients' injuries were in agreement with previous knee dislocation studies. Of the bony fragments that were seen on MDCT images in patellar dislocation patients 59% were not seen on AP and lateral views of the conventional radiographs. The location, size and donor site of the bony fragments was similar between first-time and recurrent patellar

dislocators. An average number of bony fragments were 2.1 and 1.0 in first-time and recurrent dislocators, respectively. Patients with a Segond fracture associated with a tibial plateau fracture had significantly fewer ACL ruptures and more avulsion fractures of the ACL than patients with isolated Segond fractures. In approximately one of every 32 tibial plateau fractures, a Segond fracture also coexists. In 0.64 % of the emergency room acute knee trauma MDCT examinations a reverse Segond fracture were found. Of the operated reverse Segond fracture patients 43% had an avulsion fracture of the ACL, and 14% had a PCL rupture. DECT's sensitivity and specificity to detect ACL rupture were 79 % and 100 %, respectively, and the intra- and interobserver proportions of agreement for ACL rupture were excellent and good.

CONCLUSION. The radiologist should be aware that even after a simple fall, overweight patients may have a knee dislocation. In patellar dislocation patients, the number of bony fragments seems to be higher in first-time dislocators than recurrent dislocators, otherwise MDCT findings between the two patient groups are similar. Patients with a Segond fracture combined with a tibial plateau fracture have a high risk of avulsion fracture of the ACL. Cruciate ligament injuries appear to be associated with a reverse Segond fracture, but every patient does not have PCL injury, as previously reported. DECT is a usable method to evaluate ACL in acute knee trauma patients with rather good sensitivity and high specificity.

## LIST OF ORIGINAL PUBLICATIONS

This thesis is based on the following articles, which are referred to by their Roman numerals I-V. Original publications are reproduced with permission from their copyright holders.

- I           **Peltola EK**, Lindahl J, Hietaranta H, Koskinen SK. Knee dislocation in overweight patients. *AJR Am J Roentgenol.* 2009 Jan;192(1):101-106.
  
- II           **Peltola EK**, Koskinen SK. Multidetector computed tomography evaluation of bony fragments and donor sites in acute patellar dislocation. *Acta radiol.* 2011 Feb 1;52(1):86-90.
  
- III           **Peltola EK**, Mustonen AO, Lindahl J, Koskinen SK. Segond fracture combined with tibial plateau fracture. *AJR Am J Roentgenol.* 2011 Dec;197(6):1101-1104.
  
- IV           **Peltola EK**, Lindahl J, Koskinen SK. The reverse Segond fracture: not associated with knee dislocation and rarely with posterior cruciate ligament tear. *Emerg Radiol.* 2014 Jun;21(3):245-249.
  
- V           **Peltola EK**, Koskinen SK. Dual-energy computed tomography of cruciate ligament injuries in acute knee trauma. *Skeletal Radiol.* 2015 Sep;44(9):1295-1301.

## **ABBREVIATIONS**

ACL	Anterior Cruciate Ligament
ALL	Anterolateral ligament
BMI	Body Mass Index
DECT	Dual-Energy Computed Tomography
DSA	Digital Subtraction Angiography
GSI	Gemstone Spectral Imaging
ICC	Intra-class Correlation Coefficient
MDCT	Multidetector Computed Tomography
MR	Magnetic Resonance
MRA	Magnetic Resonance Angiography
MRI	Magnetic Resonance Imaging
NPV	Negative Predictive Value
PACS	Picture Archiving and Communication System
PCL	Posterior Cruciate Ligament
PPV	Positive Predictive Value
SD	Standard Deviation



## INTRODUCTION

Acute knee injuries constitute a substantial patient subgroup in acute medicine. Of all injuries treated at an emergency department 6-8 % have been published to involve a knee joint [1, 2]. Incidence of knee injuries has been calculated to be 2-12 knee injuries per 1 000 person population per year [1-3]. The most common cause of injury category is reported to be a sports and recreation which contains almost half (49.3%) of the knee injury cases [3]. The injury rate is highest in 15 to 24 years of age group, and this is presumable related to the high proportion of sport and recreational injuries [2, 3]. Because these patients are typically at working age knee injuries are causing remarkable economical influence to society due to loss of workdays in addition to direct costs for the health care system [4].

Besides the immediate suffering and disability knee injuries also have a more subtle and long-term influence. Knee injuries have been recognized as a major risk factor for knee osteoarthritis. In the meta-analysis of 24 observational studies overall odds ratio between a prior history of acute knee trauma and knee osteoarthritis was found to be 4.2 [5].

Radiograph is still widely used as a front-line imaging technique in knee trauma patients. It provides valuable information of osseous injuries although there are limitations to what a radiograph can depict. Some fractures with minimal dislocation, such as a reverse Segond fracture, can easily be missed on radiographs. [6, 7] Information of soft tissue injuries can't be directly achieved from the radiographs but there are number of indirect sign that can raise suspicion of specific soft tissue injury. For example, if there is a linear lucency through the head of the fibula, representing a fracture, this can be recognized as an arcuate sign. This sign is known to be indicative of injury to the posterolateral corner of the knee. [8,

9] Therefore, radiologist is able to convey information of possible soft tissue injury to posterolateral corner structures, and further, it is also known that posterolateral injuries are associated with cruciate ligament injuries [10, 11]. One of the most important groups of subtle radiograph findings in trauma patient's knee radiographs is avulsion fractures. These small fractures near ligament or tendon cortical attachment site, has oftentimes a remarkable clinical significance. Avulsion fractures are associated with specific soft tissue injury patterns, and also treatment of avulsion fractures is different than treatment of corresponding ligament or tendon rupture. [12-14] It is very important, that radiologist actively seeks these subtle findings in radiographs.

Oftentimes radiographs are able to give sufficient osseous information to the clinician to treat the patient but if more detailed three-dimensional information of fracture is needed or more subtle fractures are suspected, multi-detector computed tomography (MDCT) is the imaging modality of choice. MDCT is nowadays well available in trauma centers. It's high spatial resolution, a good tissue contrast and ability to do multi-planar reconstructions make it a superior imaging modality to examine osseous injuries in the acute knee traumas. In addition to evaluating indirect signs of soft tissue injuries, a radiologist can try directly evaluate some soft tissue injuries in MDCT images. It has been published that MDCT can detect an intact ACL and PCL with good specificity and accuracy [15]. Dual-energy computed tomography (DECT) is a quite new imaging modality that is available in some trauma centers. Additional information gained by using two tube voltages, compared to single tube voltage in conventional MDCT images, can be used to reduce metal artefacts and also it may have potential advantages to evaluate soft tissue injuries [16-19].

In large number of publications MRI is demonstrated to have excellent performance in diagnosing soft tissue injuries in acute knee traumas [20]. In addition to soft tissue injury detection MRI can also be helpful diagnostic tool for detecting acute occult osseous injuries based on its' ability to detect bone marrow edema [21]. However, MRI is not always available in trauma centers during on call times. Also, MRI's long acquisition times and need to remove all ferromagnetic objects can cause practical problems to acute trauma patients, especially if they are multi injured.

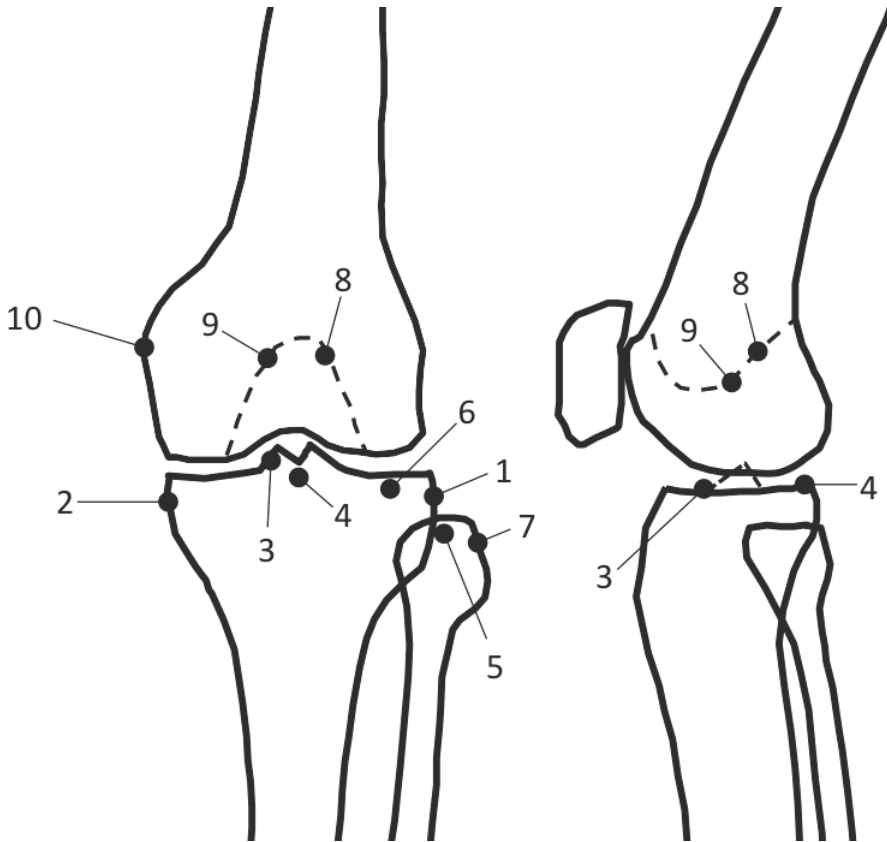
## **REVIEW OF THE LITERATURE**

### **Avulsion fractures in acute knee trauma**

Acute avulsion fractures are typically derived from forceful trauma or drastic muscular contraction, where traction forces are transmitted from a ligament or tendon to its cortical attachment site resulting in an avulsion fracture. Typical mechanism of injury is sport related and these injuries are common in adolescent population. Chronic avulsion injuries are caused by chronic overuse and are outside of scope of this thesis. [12, 13]

Avulsion fragments are usually clearly shown on conventional radiographs, however if displacement is minimal appearance of these fractures can also be subtle. (Figure 1) In these cases, MDCT tomography with multi-planar reconstructions can be helpful to better visualize these minimally displaced avulsion fragments. Also MR imaging can be used to demonstrate avulsion fragments and typical bone marrow edema patterns. [12, 13]

It is important that radiologists are able to differentiate an avulsion fracture from a ligament or tendon rupture because the operative treatment of these two entities is different. Surgical treatment options of avulsion fracture include arthroscopic reattachment of the avulsion fragment with fixation device without the use of tendon grafts [14].



**Fig. 1** – Avulsion fragment sites of the knee joint. 1 Segond fracture, 2 Reverse Segond fracture, 3 ACL avulsion fracture, 4 PCL avulsion fracture, 5 Arcuate complex avulsion fracture, 6 Iliotibial band avulsion fracture, 7 Biceps femoris avulsion fracture, 8 Femoral avulsion fracture of ACL, 9 Femoral avulsion fracture of PCL, 10 Femoral avulsion fracture of MCL ( Stieda fracture).

### Segond fracture

A Segond fracture is a small elliptic avulsion fracture of the proximal lateral tibia. When the French surgeon Segond described the Segond fracture, he also reported the existence of a fibrous band at the anterolateral aspect of the knee, which was attached to the Segond fractures avulsion fragment. [22] It was not until 2013 when

satisfactory anatomical description of this fibrous band was published [23] and name of this structure was stabilized to be anterolateral ligament (ALL). Prior to the above-mentioned Claes publication [23] nomenclature for this fibrous band has been confusing in the literature, such as: lateral capsular ligament, capsulo-osseous layer of the iliotibial band or anterolateral ligament. ALL has been described to be found in 97 % of knees as a well-defined ligamentous structure, clearly distinguishable from the anterolateral joint capsule. The origin of the ALL is situated at the lateral femoral epicondyle, from where it courses obliquely to the anterolateral aspect of the proximal tibia. ALL is firmly attached to the lateral meniscus. [24-26] Biomechanically ALL is related to internal tibial rotation, and thus its' injuries are potentially involved in the mechanism of the pivot shift phenomenon. However, it is still highly disputed, whether ALL injuries takes part in the development of anterolateral rotational instability of the knee. [27]

Segond fractures are usually seen on conventional radiographs on anteroposterior or tunnel-view projections as a thin curved bony fragment close to proximal lateral tibia [28]. MR images typically demonstrate a focal area of bone marrow edema in the lateral tibial rim [29].

A Segond fracture is associated with ACL rupture in 75–100% of cases and with meniscal injury in 42–67% of cases [29-31]. Therefore a Segond fracture is important indicator of increased risk of associated soft tissue injuries when found on images of acute knee trauma patient.

## Reverse Segond fracture

Reverse Segond fracture is one of the three medial tibial plateau rim fractures. It is an elliptical avulsion fracture of the medial proximal tibia. It represents an avulsion of the deep capsular component of the medial collateral ligament [32]. Two other medial tibial plateau rim fractures that have been described are anteromedial and posteromedial. Anteromedial tibial rim fracture has been associated with posterolateral corner injuries of the knee [33, 34], and posteromedial tibial rim fracture has been associated with medial meniscus tear and ACL rupture [35]. Reverse Segond fracture's mechanism of injury is presumed to be valgus stress, with probable external rotation [32, 36, 37].

Reverse Segond fracture has been strongly associated with injury of the PCL insertion complex. In all the published reverse Segond fracture cases, the fracture has coexisted with either a rupture of PCL or avulsion fracture of PCL. [32, 36, 37] Over half of the published reverse Segond fractures have been found on knee dislocation patients [32, 36, 37]. Some authors have even discussed that reverse Segond fracture might always be associated with a dislocated or highly unstable knee, and a reverse Segond fracture should alert the radiologist to a potentially unrecognized knee dislocation [37].

Incidence of the reverse Segond fracture is not known, but there are only a few published cases of reverse Segond fracture presented in the medical literature, and therefore it can be presumed that this finding is rather rare.

## **Tibial plateau fractures**

Tibial plateau fractures are commonly classified by using the Schatzker classification system. In this system tibial plateau fractures are divided into six types: lateral plateau fracture without depression (type I), lateral plateau fracture with depression (type II), compression fracture of the lateral (type IIIA) or central (type IIIB) plateau, medial plateau fracture (type IV), bicondylar plateau fracture (type V), and plateau fracture with diaphyseal discontinuity (type VI). [38] These fractures may occur as an isolated osseous injury or combined with ligament and meniscal injuries [39, 40]. For example a tibial plateau fracture is associated with disruption of the ACL in 18% of cases [41].

Tibial plateau fractures have similarities in mechanism of injuries with some avulsion fractures of the knee. Reverse Segond fracture's mechanism of injury is considered to be a valgus stress, with probable external rotation [32, 37] and the mechanism of injury in Schatzker type 1 and 2 tibial plateau fractures invariably involves valgus forces [39]. Anterior subluxation together with varus angulation is presumably the injury mechanism of the Segond fracture [13] and the mechanism of injury of Schatzker IV tibial plateau fracture is varus force with axial loading at the knee [42]. Therefore it is not surprising that tibial plateau fractures coexists with Segond and reverse Segond fractures, and as all of these injuries have been associated with cruciate ligament and meniscal injuries this causes a potential bias to scientific works concerning association of soft tissue injuries and one of these fractures. In this thesis we examined radiological and operative findings of Segond and reverse Segond fractures as an isolated osseous injuries and also as a combined injuries with tibial plateau fractures.



## **Cruciate ligament injuries**

Many knee injuries that are subject of this thesis are associated with cruciate ligament injuries. MRI is demonstrated to have excellent performance in diagnosing cruciate ligament lesions. It has been reported that MRI's sensitivity to detect ACL lesion is 92 to 96 % and specificity 92 to 99 % [43, 44]. The published accuracy of MRI for diagnosing PCL tears ranges from 86 to 100% [45-47]. It has been published that MDCT can detect an intact ACL and PCL with good specificity and accuracy but the assessment of torn ligaments is unreliable [15]. However, MRI is not oftentimes available to acute trauma patients and therefore knowledge of association of certain injury patterns and cruciate ligament ruptures is crucial to radiologist working in the trauma center to be able to suspect cruciate ligament injuries based on other imaging modalities than MRI.

Radiological diagnosis of cruciate ligament injury is important because presence of this injury affects on the decision of the operative or conservative primary treatment. For example, in a study involving 6576 active-duty army personnel showed that ACL reconstruction was protective against meniscal and cartilage injury. Of those treated conservatively 32.6% underwent meniscal or cartilage reoperations as compared to 12.7% reoperations in the ACL reconstruction group. [48]. In randomized study with long term follow up it was reported that ACL reconstruction significantly increases the likelihood of return to the preinjury activity [49]. Current data seems to advocate non-operative management of isolated PCL injuries but PCL reconstructions are common procedures in multi ligament injured knees to return the stability of the knee [50-53]. Treatment algorithms continue to evolve but nevertheless status of cruciate ligaments is particularly important to treatment of acute knee trauma patients.

## **Meniscal injuries**

MRI has shown high diagnostic accuracy for the diagnosis of meniscal injuries. A meta-analysis of 29 publications between 1991 and 2004 reported a pooled sensitivity and specificity of 93.3% and 88.4% for medial meniscal tear and 79.3% and 95.7% for lateral meniscal tear [54]. Based on MRI meniscal tears can be classified to longitudinal, vertical, horizontal, radial, vertical flap, horizontal flap, and complex tears. The MRI is important for surgeon for decision of operative or conservative treatment of meniscal injuries and in case of operative treatment, for choosing the surgical technique. [55, 56] Segond and reverse Segond fractures, as well as, knee dislocation are associated with meniscal injuries. If a conservative treatment is option to these patients, MRI should be considered to rule out the meniscal injuries.

## **Overweight as a risk factor**

Over the past few decades the prevalence of obesity has increased to significant level in Western Europe and in the United States [57-60]. Several studies have demonstrated that obesity has an effect on injury patterns in knee trauma patients. A study that included 168 patients showed that higher BMI in middle-aged patients with isolated medial meniscus tears predicts more advanced chondral lesions at arthroscopy [61]. It has been demonstrated that in adolescent patients with ACL rupture obesity is significant predictive factor of a concomitant injury that requires additional operative procedures [62]. In addition to influence on injury patterns, it has been shown that obesity also affects to treatment outcomes. A study including 126 patients with operated multi ligament injury knee showed that patient's obesity significantly increased the surgical complication rate [63]. The most consequential effect of obesity on knee injuries is that an obese patient can have a knee

dislocation with very low energy injury mechanism. Prior to publication of study I of this thesis only few single case reports of low energy knee dislocation in obese patients were published [64, 65].

### **Femorotibial dislocation**

Dislocation of the femorotibial knee joint is a severe injury that requires immediate emergency care. Neurovascular injuries that are potentially involved in knee dislocation can lead to a permanent disability of the lower limb or even to amputation in worst case [66, 67]. The incidence of knee dislocation is reported to be highest among males aged 18 years to 29 years (29 cases per million person per year) [68]. However, the incidence of knee dislocation is not unequivocal to assess, because of the spontaneous reduction tendency. Many of these patients are high-energy multi-trauma patients who are not able to give the anamnesis of the dislocation. In these cases suspicion of the knee dislocation arises from the multi-injury patterns found in clinical examination, operation or radiological imaging. There is a debate in medical literature which patients should be referred as a knee dislocation patient: some authors include traumatic patients with multidirectional instability and other authors only patients who have evidence of a complete disruption of a joint such that the articular surfaces are no longer in contact [69]. In this thesis, patients were considered to have knee dislocation only if they had dislocation on radiographs or they had clearly documented dislocation. Patients with a dislocatable knee at surgery but who had no evidence of previous true dislocation were not included. The reason for this more strict approach was to produce as valid scientific data as possible. However, in clinical practice it is important that radiologists are aware of injury patterns associated with a knee dislocation and therefore are able to suspect this limb-threatening injury in patients with a spontaneously reduced knee dislocation.

Knee dislocation is traditionally thought to be caused by a high energy trauma such as motor vehicle accident [70]. However, more recent studies have demonstrated that significant proportion of knee dislocations are caused by low energy traumas such as simple fall or sport related traumas. [68, 71]. In this thesis we study radiological findings in knee dislocation patients with special focus on low-energy traumas.

Knee dislocations are classified to anterior, posterior, medial, lateral and rotational luxation based on position of tibia respect to femur [72]. Knee dislocation is always associated with extensive soft tissue injuries. Usually both cruciate ligaments are ruptured but it has been published few knee dislocation cases where one of the cruciate ligaments has been intact [67, 72-75]. Usually the intact cruciate ligament is the PCL [74], but rare cases of knee dislocation without ACL disruption have been reported [75]. In addition to cruciate ligament injuries, ruptures of collateral ligaments, meniscal injuries and rupture of popliteal tendon are common in these patients [70, 73]. Treatment of these instable knees is almost always operative and it is important to surgeon to know the specific injuries included to be able to plan the operation beforehand [68, 71, 76]. MRI is good and well documented imaging modality to assess soft tissue injuries of the knee [43, 44]. These studies have been mostly included patients with less severe injuries than knee dislocation, and there are only few studies concerning MR imaging of the knee dislocation patients and patient materials in these studies have been relatively small [67, 70, 72, 73, 77-79]. Based on these studies MRI seems to be accurate imaging modality to assess soft tissue injuries also in case of multi ligament injured knees.

## **Neural injuries in acute knee trauma**

The peroneal nerve courses around the fibular neck, making it susceptible to injury in severe knee traumas, particularly in posterolateral knee dislocation [67]. Also a severe varus type of injury that result in a popliteal tendon rupture has been reported to increase the possibility of peroneal nerve injury in knee dislocation patients [67]. Of the knee dislocation patients 20-25% have injury to peroneal nerve [80, 81]. In two recent studies knee dislocation patients have been subdivided to two patient groups based on the injury mechanism. In these studies, patients with a low energy knee dislocation have been reported to have an increased risk of peroneal injuries (39-50%) compared to a high energy knee dislocation patients [82, 83].

Besides to nerve ruptures there could be traction injuries to peroneal nerve that impair nerve conduction while the nerve remains intact [84]. In addition to peroneal nerve injury also combined peroneal and tibial nerve injuries have been represented [85, 86]. In these cases the tibial nerve injury has almost always been incomplete.

Several MRI findings of the status of the peroneal nerve can be made from the images of the acute knee trauma patient. These findings include: surrounding edema, encasing hematoma, mild contusion, and disruption of fibers. However, there is limited information available how to correlate these findings to clinical outcome of the patient. In one study, including 21 patients, all patients with clinical nerve symptoms had an abnormal MRI, but on the other hand, some patients had no symptoms despite the presence of apparent hemorrhage or edema surrounding the nerve. In this same study all patients with the more severe imaging findings (encasing hematoma, contusion, partial disruption of fibers) all displayed some

degree of peroneal nerve palsy. [72] In the three patients case report, a location of peroneal nerve tear could be identified on MRI images in all three cases and the MRI finding correlated precisely with operative findings [77]. More recently there have been published a study where was 47 knee dislocation patient and 14 minor knee trauma without a dislocation. In this study they gave a severity score from 1 to 4 to peroneal nerve injury based on MRI findings and compared this scoring to a corresponding clinical score based on clinical examination, electromyography and nerve conduction studies. They found that the clinical injury score had a significantly strong correlation with the MRI injury score. [79]

A rupture of a muscular nerve causes increase of extracellular fluid in those muscles that it is serving, and this in turn causes increase of T1 and T2 relaxation times in MRI images. In addition to direct signs of nerve rupture, also these secondary findings could be searched in the MRI images. These changes in the MRI signal in the muscles could be detected after 24 hours from the nerve injury. [87, 88]

### **Vascular injuries in acute knee trauma**

High energy knee traumas can involve an injury to the popliteal artery. A popliteal artery injury, have been reported to be found in knee dislocation patients and in patients with several types of tibial or femoral fractures [89]. Acute occlusion of the popliteal artery leads to a severe ischemia of the lower leg because of the development of sufficient collateral circulation is too slow process. Early recognition of the vascular injury is crucial for the salvage of the extremity [90]. However, these injuries are easily missed [91], presumably because they occur typically in patients with multiple traumatic injuries, which make clinical examination and also interpretation of radiological images more difficult.

There is a wide range of reported incidence of popliteal artery injury in knee dislocation patients in different publications. Some authors report as high as 31% of knee dislocation patient to have a vascular injury [92] and some authors report that only 1.6% of knee dislocation patients have vascular injuries [68]. Some authors have explained a low rate of popliteal artery injuries with large proportion of low energy knee dislocation patients in their patient material [68]. However, other authors have reported that in their material low energy knee dislocation patients are more likely to have vascular injuries and are more likely to undergo vascular repair than high energy knee dislocation patients [83]. Further meta analysis of this subject is needed.

If there is a clear clinical sign of popliteal artery injury it is common procedure to directly proceed to the operation [78, 92] Alternatively MR angiography, CT angiography or DSA angiography could be made for characterization of the vascular lesion in order that vascular surgeon can beforehand plan the revascularization operation. In addition to acute occlusion of popliteal artery, acute knee trauma can also cause a more occult arterial injury that can lead to delayed complication. These more occult injuries include a dissection, a pseudoaneurysm or a intimal tear of the popliteal artery [93, 94]. Because of these more occult vascular injuries, a patient with a knee trauma, which is known to be associated with vascular injuries, without a sign of vascular injury, should be at least in adequate clinical surveillance for vascular complication or examined anyway with doppler ultrasound, DSA angiography, MR angiography or CT angiography [72, 78, 93, 94].

## **Patellar dislocation**

Acute patellar dislocation is the second most common cause of traumatic hemarthrosis and 2-3 % of all knee injuries are patellar dislocations [95, 96]. Patellar dislocation is frequently associated with bony fragments and the treatment options include arthroscopy for removal of a bony fragment or restoration of cartilage congruity by fixation of an osteochondral fragment [97]. Therefore radiologist should be able to give the surgeon data regarding the number, size, location and donor site location of bony fragments. However, these fractures are often difficult to see on radiographs. The incidence of bony fragments in radiograph-based studies is significantly lower than in operative or arthroscopic-based studies [98-102]. It has been published that up to 71% of osteochondral fragments are missed on conventional radiographs [101]. It has been shown that on radiographs a reduction in the standard number of projections from AP, lateral, and two oblique to just AP and lateral projections decreases sensitivity (from 0.85 to 0.79) and specificity (from 0.92 to 0.87) of detection of fractures in acute knee trauma [103]. Therefore, the use of four projections would presumably to some extent assist to detect also osteochondral fragments on radiographs in patellar dislocation patients. MDCT has an excellent bone/soft tissue contrast, a good spatial resolution and, in contrast to plain radiographs, it is possible to do high quality multiplanar reconstruction images. However, also MDCT has its' limits as purely chondral fragments are not visible on MDCT. It has been reported that 6% of all loose bodies are purely chondral in acute patellar dislocation patients [101]. To detect these chondral loose bodies CT or MR arthrography is required, and also the accuracy to detect osseous bodies is reported to be slightly higher with these arthrography modalities compared to MDCT or MRI without intra-articular contrast agent [104]. In this thesis we studied use of MDCT in detecting bony fragments in acute patellar dislocation patients.



## **Imaging modalities**

Radiograph is often the first radiological examination of knee trauma patients. However, a fracture is seen on only 5% of emergency department knee radiographs only [105]. Therefore, several clinical decision rules have been suggested that could considerably reduce the number of radiographs ordered without missing clinically significant fractures. In the ACR Appropriateness Criteria, which are American evidence-based guidelines for specific clinical conditions that are reviewed every three years by a multidisciplinary expert panel, is stated that twisting injuries in young patients who can walk and bear weight an emergent radiographs are not required. However, in patients with a fall or twisting injury who have focal tenderness, effusion, or inability to bear weight, radiographs should be the first imaging study obtained. [105] In addition to fractures of distal femur or proximal tibia and fibula, radiographs are reviewed for avulsion fractures and other more subtle signs of soft tissue injuries such as Arcuate sign, as already discussed more detailed above.

If major osseous knee injury is suspected radiograph is obvious first line imaging modality. Also, usually radiographs are able to give sufficient information to the clinician to treat osseous injuries. More detailed three-dimensional information of fracture can be gained by MDCT. For example it has been published that MDCT is useful in preoperative planning and execution of surgical strategies in tibial plateau fracture patients [106]. MDCT can also be used to rule-out more subtle fractures and also in some degree to evaluate soft tissue injuries [15].

Variety of ways of using ultra sound in acute knee trauma patients has been researched. Ultrasound is well suited for example in diagnosis and follow up of the vascular lesions in knee dislocation patients [107]. Also, it is suggested that

ultrasound could be used to evaluate neural injuries in knee dislocation patients. It has been reported that knee dislocation patients with clinical symptoms of peroneal nerve injury had increased peroneal nerve area with hypoechogenicity in ultrasound. In this study authors furthermore reported that the greater ultrasound peroneal nerve enlargement associated with the worse clinical recovery of neuronal symptoms. [108] The use of ultrasound in evaluation of soft tissue injuries in acute knee trauma has also been investigated. For example it has been published that ultrasound and MR have similar diagnostic performance in the evaluation of medial patellofemoral ligament tears after acute lateral patellar dislocation [109]. It has also been reported that preoperative ultrasound assessment of meniscal pathology in acute knee trauma patients had good sensitivity (91%) and specificity (84%) compared to arthroscopy findings [110]. However, the main flaw of the ultrasound is a high dependence of the ultrasound operator. Also, ultrasound is time-consuming, and hematoma and inability to freely move the patient can considerably decrease the possibilities to use ultrasound as a diagnostic tool in acute trauma setting.

Detecting injuries that lead to knee instability is important because knee instability has been identified as a risk factor for meniscal and chondral damage and furthermore, risk factor for early osteoarthritis [5, 111]. MRI is the most useful imaging modality to examine these soft tissue injuries that could cause the knee instability. In large number of publications MRI is demonstrated to have excellent performance in diagnosing soft tissue injuries in acute knee traumas. The most commonly injured ligament of the knee is ACL. It has been reported that MRI's sensitivity to detect complete rupture of ACL is 92 to 96 % and specificity 92 to 99 %. [43, 44] Of the all ACL tears 20-47% are reported to be partial, and these partial tears can progress to complete ACL deficiency [112-114]. Partial ACL tears are more difficult to diagnose in MRI than complete tears [113]. MRI's accuracy to

detect partial ACL tears has been reported to be 87% if in addition to standard orthogonal sequences, also oblique axial intermediate-weighted sequences has been applied [114]. MRI's accuracy to detect complete PCL tears has been reported to be 86-100% [45-47]. In addition to finding ligament injuries that lead to meniscal and chondral injuries in later phase, MRI can also be used to examine acute traumatic meniscal and chondral injuries. MRI's sensitivity and specificity for the diagnosis of meniscal injuries is reported to be 93.3% and 88.4% for medial meniscal tears and 79.3% and 95.7% for lateral meniscal tears [54]. Acute chondral lesions are much more difficult to detect than meniscal injuries. MRI's sensitivity to detect chondral lesions in preoperative non-acute setting was reported to be only 45% compared to arthroscopy findings [115]. In one study, authors reviewed MRI's of 44 acute multi-ligament injured knee patients and detected no chondral lesions in MRI images but arthroscopy revealed 11 chondral lesions [116].

A subtraction angiography is the golden standard in the diagnosis of the vascular lesions. However, this imaging method is not always available in trauma centers at on-call times. Also, it is an invasive and time-consuming method, which could be limitation in case of multi-injured trauma patients. Based on retrospective review of knee dislocation patients with vascular injuries, it has been suggested that a repeated clinical examination can reliably predict which patients have surgically significant popliteal artery injury and need further evaluation [78, 117]. The use MR angiography in examination of knee dislocation patients' vascular injuries has also been researched [118], and MRA has been shown to be as accurate and useful as angiography. Therefore, if knee dislocation patient is examined with MRI for characterization of soft tissue injuries, it seems reasonable to do simultaneously MRA to rule-out clinically occult vascular lesions. Also, CT angiography and duplex ultrasonography are sensitive and specific in screening for vascular injury [119], and these methods are well available in trauma centers, and are good options

to further evaluate the vascular status of acute knee trauma patient if clinical suspicion of vascular trauma is raised.

In Dual-energy computed tomography (DECT) two computed tomography image sets are applied by using a different tube voltage from the same anatomical region. This method has potential advantages to evaluate soft tissue injuries in acute knee trauma compared to a conventional MDCT, but there are only few published studies of utilization of DECT in evaluation of soft tissue injuries of the knee [16-18]. Potential advantages of DECT include a higher soft tissue resolution in monochromatic gemstone spectral imaging (GSI) images compared to conventional polychromatic MDCT images and ability to create material specific color mapping and dual-energy bone removal [120, 121].

It has been published a case control study of 16 ACL rupture patients where DECT was shown to have high accuracy and interobserver agreement for the detection of complete ACL tears [18]. The patient material in this study included chronic and subacute knee trauma patients. In the acute trauma setting there is usually an edema, which may obscure the ACL and thus these results do not necessarily correlate with the acute trauma patients. In an ex vivo experiment with 20 porcine hind legs, DECT sensitivity and specificity were found to be 75% and 68.8% in the case of completely discontinued ACLs compared with the defined arthrotomy [17]. There is a publication where 24 knee DECT images were reviewed and subjective visualization of ACL, PCL, fibular collateral ligament and patellar ligament were found to be good.

In previous studies tendon visualization in DECT GSI images and material-specific color maps has been investigated in hands tendons [120, 121]. It has been demonstrated that 65-keV monochromatic GSI images could increase the image quality and ability to display minor tendon lesions compared to conventional

polychromatic CT images [120]. There is a high concentration of collagen in tendons and ligaments, and collagen's specific dual-energy index values allow collagen to be theoretically decomposed from the surrounding tissue [121]. The collagen decomposition algorithm is performed on a DECT workstation where collagen-specific color mapping images are generated. Published data concerning the clinical application of this technique are few and partially controversial. In one study, authors reported that DECT with material decomposition for collagen can clearly differentiate the tendons of the wrist [121]. In other study, the DECT tendon-specific color map images did not perform as well as the mixed kV or DECT bone removal series in the identification of the ACL [18].

In summary, the scientific evidence of utilization of DECT in evaluation of soft tissue injuries of the knee is very modest, but there is some evidence that DECT can be used in evaluation of complete ACL rupture.

## **AIMS OF THE STUDY**

- (I) To evaluate the incidence, cause, injury patterns, and MRI findings in knee dislocation in patients.
- (II) To assess the use of MDCT for locating bony fragments and donor sites in patients with acute patellar dislocation, and to test whether sizes and quantity of bony fragments differ between first-time dislocations and recurrent dislocations.
- (III) To examine the coexistence of Segond fracture in tibial plateau fractures and to assess the prevalence of ACL rupture and meniscal tear when those fractures coexist.
- (IV) To assess the incidence of reverse Segond fracture, to examine the associated ligamentous injuries, and to examine how often reverse Segond fracture coexists with a knee dislocation.
- (V) To examine DECT in evaluating cruciate ligament injuries

## **MATERIALS AND METHODS**

### **Patients**

Patient materials to studies included in this thesis were received by retrospectively retrieving the Töölö hospital's Picture Archiving and Communication System (PACS). The Töölö hospital is the only hospital in an 8,929 km<sup>2</sup> area that takes care of major trauma patients with a basic population of about 1.4 million people. Also, if in case a patient with a severe injury, such as a knee dislocation, is initially taken to some other hospital, the patient is eventually transferred to Töölö hospital for final treatment. The entire population is entitled to a general health care system, and there are no private hospitals taking care of severe trauma patients in this area. No patients younger than 16 years are treated at Töölö hospital, and therefore this pediatric population was not included in studies I and III-V. In the study II also an other hospital's (Meilahti, Children's clinic), taking care of a pediatric population of patients under 16 years of age in the same area, PACS were used to include the pediatric patient material in the study. From those patients' that were included in the study age, gender, history, mechanism of injury, clinical findings and operation findings were retrieved from the patients' electronic files, or paper archive if necessary.

### **Knee dislocations (I)**

Patients with knee dislocations from April 2000 to the end of September 2007 were identified using the Töölö hospital's PACS by retrieving all of the hospital's knee MRI studies. In Töölö hospital, early preoperative MRI is routinely performed on patients with knee dislocation. A total of 24 patients who had sustained a knee dislocation were identified.

## Patellar dislocation (II)

Patellar dislocation patients were identified, from April 2000 to the end of July 2008, using two hospitals' PACS by retrieving all emergency room knee MDCT examinations. The inclusion criteria for the study were an acute dislocation of the patella and an MDCT examination of the knee in the acute phase. A total of 46 patients were included in the study.

## Segond fractures (III)

Using the Töölö hospital's PACS, we retrieved all of the hospital's emergency department knee MDCT examinations performed from August 2000 to the end of August 2009. During this 9-year period, a total of 1203 emergency department acute knee trauma MDCT examinations were retrieved, and a total of 33 patients with Segond fracture were included in the study.

## Reverse Segond fracture (IV)

All of the Töölö hospitals' emergency room knee MDCT examinations from August 2000 through the end of August 2011 were retrieved. During this 11-year period, a total of 1553 emergency room acute knee trauma MDCT examinations were retrieved. The inclusion criteria for the study were an acute reverse Segond fracture and a MDCT examination of the knee in the acute phase. A total of 10 patients were included in the study.



## Dual-energy CT of cruciate ligaments (V)

Using the Töölö hospital's PACS, we retrieved all of the hospitals' emergency room knee CT examinations from the beginning of January 2012 through the end of May 2014. During this 29-month period, a total of 132 emergency room acute knee trauma DECT examinations were retrieved. A routine protocol in Töölö hospital during the study period was to use the dual-energy CT technique if a CT was requested from an acute knee trauma patient. Inclusion criteria for the study were an acute knee trauma and a DECT and subsequent MRI examination in the acute or subacute phase. A total of 18 patients who met the inclusion criteria were found.

## Methods

### Scanners

The MR images of the knees in the studies I and V were obtained with a 1.5-T unit scanner (Signa MRI EchoSpeed, GE Healthcare). Two different dedicated knee coils were used: the quadrature lower extremity coil (Medical Advances; internal diameter, 18 cm) and an 8-channel HD knee array coil (MRI Devices Corporation; internal diameter, 19 cm). The standard sequences used were coronal T2-weighted fast spin-echo with fat saturation, sagittal proton-density spin-echo, sagittal T2-weighted fast spin-echo, and axial proton-density fast spin-echo with fat saturation sequences.

Adult populations' MDCT examinations in studies II-IV were done with two different scanners. The scanners were a four-slice MDCT scanner (LightSpeed QX/i; GE Healthcare, Milwaukee, WI, USA) and a 32-MDCT scanner (LightSpeed

VCT, GE Healthcare). The 4-MDCT unit was installed in 2000 and uninstalled in 2008 and was subsequently replaced with the 32-MDCT scanner.

Pediatric population's MDCT examinations in study II were done with a 16-slice MDCT scanner (Aquilion TSX-101A; Toshiba Medical Systems Corporation, Tochigi, Japan). The routine protocol was as follows: 4x1.25-mm collimation, reconstruction interval 0.625 mm, or 16x1.00-mm collimation, reconstruction interval 0.625 mm, or a 32 × 1.25 mm collimation and an interval of 0.625 mm. The axial slice thickness of images that were sent to PACS ranged from 1–1.25mm.

The DECT images in study V were acquired with a GE Discovery CT750 HD with a 0.516 pitch, 0.5-s rotation time, 32×0.625-mm detector collimation. Tube voltage varied between 80 kV and 140 kV in a single X-ray tube.

#### Image evaluation

The PACS system used was IMPAX, Agfa-Gevaert N. V., Mortsel, Belgium. In the studies I-IV two radiologists independently reviewed the MR and MDCT images and equivocal cases were decided by consensus.

In the study V DECT images were review with DECT's workstation (Advantage Windows, version 4.4, GE Healthcare with VolumeShare 2, version 4.4, GE Healthcare). DECT examinations were made anonymous and double reading in randomized order was separately made by two radiologists in two session with 4-week waiting period between the two readings.

### Knee dislocations (I)

The MRI studies of the knee dislocation patients' were evaluated for the presence of injury to the cruciate and collateral ligaments, popliteus tendon, biceps femoris tendon, quadriceps tendon, patellar ligament, and medial retinaculum. If present, injury was categorized as partial or complete. Associated injuries to the bone, menisci, cartilage, peroneal nerve, and popliteal artery were also analyzed. Surgical findings served as a reference standard for intra-articular injuries. BMI and mechanism of injury were retrieved from each patient's file.

### Patellar dislocation (II)

The MDCT examinations of patellar dislocation patients' were evaluated for the presence of sharp-edged and non-sclerotic new bony fragments. The volume of bony fragments was calculated, and for every bony fragment identified, we searched for a corresponding sized non-sclerotic and sharp-edged bony irregularity on the patellar facets and femoral condyles. If such an irregularity was found, we concluded that this irregularity represents a donor site of the fragment. Surgical correlation was available for 22 of 46 patients.

### Segond and reverse Segond fracture (III and IV)

Knee MDCT images were evaluated for the presence of Segond, reverse Segond and tibial plateau fractures. Tibial plateau fractures were classified according to the Schatzker system [38]. Soft tissue injuries were not evaluated from MDCT images but surgical findings of intra-articular injuries were retrieved from patient files.

## Dual-energy CT of cruciate ligaments (V)

Knee DECT images were evaluated for the presence of total ACL and PCL ruptures. The DECT images were analyzed with a DECT workstation in three different ways: GSI viewer (General GSI Protocol, GE Healthcare), dual-energy bone removal (AutoBone Xpress General, GE Healthcare) and with collagen-specific color mapping that was made by using four overlapping volumes [monochromatic 65 keV, Material Density Collagen (Bone), Material Density Bone (Collagen) and Effective-Z in the General GSI protocol, GE Healthcare]. For every case, readers judged what were subjectively the best, second best and least usable protocol to evaluate the cruciate ligaments and popliteus tendon. Readers also subjectively stated an optimal keV level in monochromatic GSI images for visualization of the ACL, PCL and popliteus tendon. MRI findings served as the reference standard for ligament and tendon injuries.

## Statistical analysis

The appropriate procedures in the IBM SPSS Statistics program, version 22.0.0.0 (IBM Corp., Armonk, NY, USA) (study V), or The SAS/STAT 8.02 (SAS Institute) (study I-III) were used for the statistical computations. In the studies I, II and V the differences in injuries between the patient groups were analyzed using the Mann-Whitney  $U$  test (nonparametric data) and with Fisher exact test (two-sided) in the study III. A  $p$  value of less than 0.05 was interpreted as statistically significant. In the study V the intra-class correlation coefficient (ICC) served to test the inter- and intraobserver repeatability of the optimal keV level evaluation. Statistical analysis of the differences in the usefulness ranking of three different evaluation protocols in study V was done with Friedman's test and post hoc analysis with the Wilcoxon signed-rank test, which was conducted with a

Bonferroni correction. In Friedman's test, a P value  $< 0.05$  was interpreted as statistically significant, and in post hoc analysis a P value  $< 0.017$  was interpreted as statistically significant.

## RESULTS

Main results of soft tissue injuries in knee dislocation (publication I), Second fracture (publication III) and reverse Second fracture (publication IV) are represented in Table 1.

### **Knee dislocation**

Annual incidence of knee dislocations in adult population was calculated to be 2.3 per million. Of the 24 patients included in the study, seven had knee dislocation caused by high energy trauma such as a motor vehicle or motorcycle accident. Eleven patients had a BMI greater than 25 (mean, 33; range, 27–42) and had knee dislocation due to low energy trauma (nine due to a simple fall, two due to downhill skiing). These patients were of special interest in this study and are referred to as group A. The other 13 patients—patients with dislocation due to high energy trauma ( $n = 7$ ) and normal weight patients with dislocation due to low energy trauma ( $n = 6$ ) were referred to as group B. The annual incidence of patients having a BMI greater than 25 and had knee dislocation due to low energy trauma is about 1.0 per million.

22 patients underwent surgery. Operative findings revealed that 21 of these 22 patients had complete ruptures of both cruciate ligaments. One patient in group B had a rupture of the ACL but an intact PCL. Complete tear of the MCL was present in seven and five patients in groups A and B, respectively. A complete tear of the LCL was found in five patients in both groups. Complete popliteal tendon tears occurred in five patients, all of whom were in group B. Difference of popliteal tendon tears between two patient groups was statistically significant ( $p = 0.0262$ ). Ten avulsion fractures and one tibial plateau fracture were seen in eight patients.

Patients in group A had eight meniscal tears; group B patients had four meniscal tears. No statistically significant differences in bone or meniscal injuries between the two groups were found. False positive and false negative MRI diagnoses of soft tissue injuries were equally divided between the two groups.

Three patients had signs of complete peroneal nerve injury after knee dislocation. None of these three patients has regained peroneal function after 1 year of follow-up. All three patients belonged to group B. Four patients had signs of partial peroneal injury. After 1 year of follow-up, three of these patients regained function with rehabilitation. Two patients were in group A and two in group B.

On MR images, seven patients had edema or hematoma surrounding the peroneal nerve. Two of these patients had clinical signs of a partial peroneal injury. Of the three patients with complete irreversible peroneal paresis, only one had an MRI examination before surgery. In this patient, the peroneal nerve was not identified on the MR images.

Two patients in group A and one patient in group B had popliteal artery injuries that were imaged with DSA angiography and treated surgically.

**Table 1.** A summary of surgical findings of soft tissue injuries of the knee in publications I, III and IV.

	<b>Knee dislocation, all patients</b>	<b>Knee dislocation, subgroup: obese patients with low energy trauma</b>	<b>Isolated Second fracture</b>	<b>Second fracture combined with tibial plateau fracture</b>	<b>Reverse Second fracture combined with tibial plateau fracture</b>
Incidence	2,3 per million	1,0 per million			
ACL, rupture	100%	100%	71%	20%	0%
ACL, avulsion	0%	0%	0%	50%	43%
PCL, rupture	95%	100%	0%	0%	0%
PCL, avulsion	0%	0%	0%	0%	14%
MCL, rupture	55%	70%	14%	20%	29%
LCL, rupture	45%	50%	0%	5%	0%
Popliteal tendon	23%	0%			
Medial meniscal tear	18%	30%	14%	10%	
Lateral meniscal tear	36%	50%	57%	15%	29%
Peroneal injury, complete	13%	0%			
Peroneal injury, partial	17%	18%			
Popliteal artery injury	13%	18%			

ACL=anterior cruciate ligament, PCL=posterior cruciate ligament, MCL=medial collateral ligament, LCL=lateral collateral ligament.



## **Patellar dislocation**

We identified 22 patients with first time patellar dislocation and 24 patients with recurrent patellar dislocation. In these patients' MDCT images there were 71 sharp-edged and non-sclerotic new bony fragments that were analyzed in this study. The most common site (48% of all bony fragments) was medial facet of the patella. On the basis of MDCT images we were able to identify the likely donor site of the bony fragment in 87% of cases. The bony irregularity representing the donor site was found in 94% of cases at the medial patellar facet, and in the remaining 6% of cases at the lateral femoral condyle. Of the bony fragments 61% were found adjacent to the donor site. The location and donor site of bony fragments was similar between patients who had first-time or recurrent dislocation of the patella.

Every patient who had first-time patellar dislocation had at least one bony fragment and the average number of fragments was 2.1. 42% of recurrent patellar dislocation patients did not have any new bony fragments. The average number of bony fragments in recurrent dislocation patients was 1.0. The size of bony fragments ranged from 4 mm<sup>3</sup> to 1630 mm<sup>3</sup> and the average size was 198 mm<sup>3</sup>. There was no statistically significant difference in the size of bony fragments between first-time and recurrent dislocators (p=0.77).

On AP and lateral views of the conventional radiographs, 41% of bony fragments that were seen on the MDCT images were identified. If trans-axial radiographic views were also obtained 81% of bony fragments were seen. There was no significant difference in number of missed bony fragments on conventional radiographs between first-time and recurrent dislocators. These missed bony fragments were located in the lateral femoral recess or medial facet of the patella.

The size of the missed bony fragments was relatively small (mean size 29 mm<sup>3</sup>, range 4–105 mm<sup>3</sup>, SD 35 mm<sup>3</sup>).

### **Segond fracture**

A total of 10 patients with a Segond fracture without a tibial plateau fracture were identified. Of these 10 patients, seven were treated surgically. Of these patients, five had a complete rupture of the ACL. No avulsion fractures of the ACL existed. Five meniscal tears, one medial meniscal tear, and four lateral meniscal tears were found in four of these patients.

There were 23 patients who had a Segond fracture associated with a tibial plateau fracture. There were 2 Schatzker type I fractures, 1 type III fracture, 7 type IV fractures, 6 type V fractures, and 3 type VI fractures. Of these patients, 20 underwent surgery. Of the operated patients 14 had injury of the ACL. 10 patients had a distal avulsion of ACL, and 4 patients had a complete rupture of the ACL. There were no significant differences in distribution of Schatzker classes between patients with an ACL avulsion fracture and those with an ACL rupture. Of these 20 patients five had a meniscal tear. We estimated that one of every 32 tibial plateau fractures coexists with a Segond fracture.

Patients who had a Segond fracture combined with a tibial plateau fracture had significantly fewer ACL ruptures ( $p=0.023$ ) and had more avulsion fractures of the ACL ( $p=0.026$ ) than patients with an isolated Segond fracture. These patients may also have fewer meniscal injuries, but this difference was not statistically significant ( $p = 0.175$ ).

## **Reverse Segond fracture**

A total of 10 reverse Segond fracture were include in the study. Incidence of Reverse Segond fracture was 0.64 % of emergency room acute knee trauma MDCT examinations at a level 1 trauma center. The ratio of reverse Segond fractures to Segond fractures was 1:4.

We were able to retrospectively observe a bony avulsion fragment of the reverse Segond fracture in 8 of the 10 the primary radiographs. In two cases, reverse Segond fracture was seen only in the MDCT images.

Of the 10 reverse Segond fracture patients, 8 patients had a reverse Segond fracture combined with tibial plateau fracture. There were one Schatzker type I fracture, four type II fractures, and one type VI fracture. Two patients had an isolated tibial eminence fracture without depression. Two patients had a reverse Segond fracture as an isolated osseous injury.

Seven patients were treated surgically and all these patients had a reverse Segond fracture combined with a tibial plateau fracture. Of seven surgically treated patients, three (43 %) had an associated avulsion fracture of the ACL. An avulsion fracture of the PCL was found in only one (14 %) patient. No rupture of either ACL or PCL existed. A total of two (29 %) lateral meniscal injuries were evident. A complete rupture of the medial collateral ligament was found in two (29 %) patients. There were no complete ruptures of lateral collateral ligament.

Only one patient in both groups had an MRI of the knee in acute phase. Based on MRI, there were intact cruciate ligaments and no signs of meniscal injury or injury to the lateral collateral ligament in the patient who had an isolated reverse Segond fracture. The other patient had a reverse Segond fracture combined with a tibial

eminence fracture without depression. In this case, avulsion fractures of both cruciate ligaments were found in MR images. No signs of meniscal injuries were detected, and the lateral collateral ligament was found to be intact.

From the same study period all the knee dislocation patients in our institution were reviewed and none of these patients had a reverse Segment fracture.

### **DECT of cruciate ligaments**

Of the 18 patients included in the study, 6 had a total ACL rupture based on MR images. DECT's sensitivity to detect rupture of the ACL was 79 % and the specificity was 100 %. The accuracy, PPV and NPV were 93 %, 100 % and 91 %, respectively. The interobserver proportion of agreement for ACL rupture was excellent (kappa value 0.85) in the first reading, and in the second reading there were no disagreements between the two readers. The intraobserver proportion of agreement for ACL ruptures were excellent and good (kappa values 0.85 and 0.72) for the first and second reader, respectively. The proportion of agreement for ACL rupture at DECT versus MRI was excellent (kappa values 0.80 and 0.87) in the first and second reading, respectively.

Only one total rupture of the PCL was observed in MR images. Both readers detected this rupture in DECT images in the first reading, but both missed it during the second reading.

The overall optimal mean keV level for visualization of ACL, PCL and popliteus tendon was 63 (range 40–93, SD 10.6). However, a statistical analysis of these subjectively assessed optimal keV levels revealed that the evaluations were of low repeatability. The intra- and interobserver ICC were poor. We also tested if optimal keV levels differed between a ruptured ACL and intact ACL groups, but there was

no statistically significant difference in keV levels between the two groups ( $P = 0.302$ ).

From the three different evaluation protocols the first reader subjectively assessed the GSI protocol to be the most useful in 92%, 95% and 86% of cases in the evaluation of the ACL, PCL and popliteus tendon, respectively. The bone removal protocol was assessed by the first reader to be the best protocol in 8%, 5% and 14% of cases in the evaluation of the ACL, PCL and popliteus tendon. The second reader assessed the GSI protocol to be the most useful in 89%, 89% and 71% of cases and the bone removal protocol in 11 %, 11 % and 29 % of cases in the evaluation of the ACL, PCL and popliteus tendon, respectively. Both readers did grade the collagen-specific color mapping protocol to be the least usable evaluating protocol in every case and ligament structure that was reviewed. There was a statistically significant difference in usefulness of the evaluation protocols,  $p < 0.001$ . In post hoc analysis, there was a statistically significant ( $p < 0.001$ ) difference in every reading between the GSI and color mapping groups as well as the bone removal and color mapping groups. Between the GSI and bone removal groups, the difference was statistically significant in 9 of 12 readings ( $p=0.012$  or lower).

## **DISCUSSION**

### **Knee dislocation (I)**

The former understanding of injury mechanism of the knee dislocation was high energy trauma or contact-sport related trauma [67, 70, 73, 78, 81]. Prior to publication of knee dislocation cases of this thesis (study I) only few single case reports of low energy knee dislocation in obese patients were published [64, 65]. Almost half (46%) of the knee dislocation patients in this thesis were overweight and had suffered low energy trauma. We included in the study only the patients with dislocation on radiographs or patients with clearly documented dislocation, and this could have increased the portion of low energy trauma patients because we have missed some spontaneously reduced high energy dislocations because a patient could not recall the knee dislocation because of a high energy multitrauma. Prevalence of obesity has increased [58, 60] and this could have increased the portion of low-energy knee dislocations because there seems to be correlation of obesity and low-energy knee dislocation, as we have demonstrated in this thesis. Our study was one the first ones to show that the annual incidence of knee dislocation due to low energy trauma in obese patients is not insignificant at a level 1 trauma center. After our study, similar results have been published in other single center studies [82, 83, 122] and also in one nation wide study [68].

After we had recognized the obese low-energy knee dislocation patients as a novel and significant subgroup of the knee dislocation patients, the natural next question was if these patients had some special soft tissue injury patterns. Especially we were interested if these patients had less or more neurovascular injuries. Our findings of soft tissue injuries, however, were mainly in agreement with former studies. In the knee dislocation patients in this thesis every patient had an ACL

rupture, and one patient had an intact PCL. Also previous studies had reported few cases where one of the cruciate ligaments has been intact [74, 75]. Knee dislocation had been associated with meniscal tears [67, 70, 72] In our study, 18% of patients had a medial meniscal tear and 36% had a lateral meniscal tear, and these numbers are in agreement with previous studies. When we statistically compared ligament, tendon and meniscal injuries of overweight patients with a low energy knee dislocation to other knee dislocation patients, the only statistically significant difference between the two groups was that overweight patients with low energy knee dislocation had fewer popliteal tendon ruptures. In other knee dislocation publications this finding has not recurred [82, 83].

In previous studies, where patients have not been divided into high energy and low energy knee dislocation groups, the prevalence of severe peroneal nerve injury has been reported to be 20–25% [80, 81]. In our series, 13% of patients had complete peroneal palsy, and all of these patients had a high energy injury mechanism. Overweight patients with low energy injury mechanism did not have complete peroneal injuries. Patients who had signs of partial peroneal injury were equally divided between two groups. In two recent studies low energy knee dislocation patients have been reported to have an increased risk of peroneal injuries (39-50%) and vascular injuries (28-33%) compared to high energy knee dislocation patients [82, 83]. Our results do not support the hypothesis of an increased risk of peroneal injuries in low energy knee dislocation patients. In our material two overweight patients with a low energy knee dislocation and one patient with a high energy knee dislocation had a popliteal artery injury. However, the number of vascular injuries in our material is so few that reasonable statistical conclusions can't be made. Patient materials in all these studies have been relatively small and further meta-analysis is needed to fully answer the question of prevalence of neurovascular injuries in low energy knee dislocation patients.

I have made a hypothesis that knee dislocation also causes intimal injuries to popliteal artery that does not progress to acute or subacute occlusion or stenosis of the vessel, and therefore these asymptomatic injuries are not recognized. It is well known that intimal injuries in arteries can lead to intimal hyperplasia. Intimal hyperplasia is caused by vascular smooth muscle cell proliferation and migration through the internal elastic lamina, and deposition of extracellular matrix in the vessel wall. In long term, this pathology results in local stenosis of the injured vessel and also serves as an increased risk site for thrombosis and atherosclerotic lesions. [123-126] I am not aware of any study that had focused to these hypothetical subtle long-term effects of vascular injuries in knee dislocation patients, and this could be interesting subject for further research.

MRI has been used to evaluate peroneal nerve status in knee injury patients in few previous studies [72, 77, 79]. In our series, we found a good correlation between patients who had normal peroneal nerve findings on MRI and patients with no clinical signs or symptoms of peroneal nerve injury. Significance of finding of a hematoma surrounding an intact peroneal nerve remained unclear.

The subjective image quality of all MR images was evaluated to be diagnostic. Statistical analysis of false-positive or false-negative MRI findings between overweight low energy knee dislocation patients and other knee dislocation patients revealed no statistically significant differences. Based on these findings we concluded that obesity does not interfere knee MRI imaging.

## **Patellar dislocation (II)**

In current practice, the only radiological modality that is usually used in acute patellar dislocation patients is conventional radiography. However, MDCT is a more accurate method to detect bony fragments than plain radiographs or MRI



[104]. In this thesis we demonstrated that 19% bony fragments that were seen on MDCT images were not visualized on AP, lateral or trans-axial view of conventional radiographs. Also, significance of trans-axial view was demonstrated as if only AP lateral views were obtained 59% of bony fragments were missed. Also previous studies have shown that a significant number of osteochondral fragments are missed on conventional radiographs [98, 99, 101, 102]. Based on findings in this thesis and previous studies, it should be considered to increase the usage of MDCT for evaluating the presence of bony fragments.

If we propose to increase the use of MDCT for patellar dislocation we should also consider what is the clinical significance of these bony fragments that are missed on plain radiographs. If a patient has a large bony fragment visible on plain radiograph, the more detailed knowledge of possible small fragments, gained by using MDCT, is not necessarily helpful to the surgeon. However, if there are only small bony fragments that are not visible on plain radiographs, use of MDCT could give valuable information that could effect the treatment of the patient. For example, chondral injuries could be suspected and these patients could be sent to MRI. Recurrent patellar dislocation patients oftentimes have old bony fragments from former patellar dislocations and with MDCT it is usually possible to see the difference between new and old bony fragments. In this thesis we also demonstrated that MDCT can be used for detecting the location of the donor site of the bony fragment. It is also possible to detect a donor site of the bony fragment on plain radiographs [127], however, the donor site visualization on plain radiographs was not examined in this thesis.

If we increase the use of MDCT, in addition to plain radiographs, we also increase the radiation dose of these patients. This aspect is particularly important because patellar dislocation is common among the pediatric population. However, the employment of the modern pediatric dose reduction technology has decreased the

radiation dose [128-130]. Also, in modern CT scanners the penumbra zone is relatively smaller than in older CT scanners, and thus these scanners are significantly more dose-efficient [131, 132] Most importantly, as we are imaging the knee joint the effective doses are small because of the minimal presence of radio-sensitive tissues.

### **Segond fracture and reverse Segond fracture (III and IV)**

In this study we had a novel approach to evaluate Segond fracture and reverse Segond fracture patients radiological and surgical findings. In contrast to previous studies we examined separately patients with a Segond or reverse Segond fracture as an isolated osseous injury and patients with Segond or reverse Segond fracture combined with a tibial plateau fracture. We showed that there are not only similarities but also differences in soft-tissue injury patterns between these two groups.

#### **Segond fracture**

In previous studies a tibial plateau fracture is associated with disruption of the ACL in 18% of cases [41]. However, in this thesis we demonstrated that, if a tibial plateau fracture coexists with a Segond fracture, 70 % of patients had an ACL injury. Majority of these ACL injuries were avulsion fractures. In previous studies Segond fracture is associated with ACL injuries but these injuries has mostly been ACL ruptures not avulsion fractures. Also in this thesis patients with isolated Segond fractures had no avulsion fracture of the ACL.

If we don't handle ACL avulsion and ruptures separately, our results are in agreement with previous studies. A Segond fracture is associated with ACL injury

in 75–100% of cases [29-31]. In this thesis we found that prevalence of ACL injury was 71% and 70 % in patients with an isolated Segond fractures and a Segond fracture combined with a tibial plateau fracture, respectively.

We found a significant difference in prevalence of meniscal injuries between the two groups. Only 25% of patients with a Segond fracture combined with a tibial plateau fracture had a meniscal injury and 57% of patients with isolated Segond fracture had a meniscal injury. In previous studies it has been published that 42-67 % of Segond fracture patients had meniscal injuries [29-31]. If we do not separate the two patient groups, 33% of our patients had a meniscal injury. This is little less than in previous studies but could be explained by the fact that in our material there was significant proportion of patients with a Segond fracture combined with tibial fracture and it seems that these patients have less meniscal injuries.

Based on our results in this thesis we propose that a Segond fracture is clinically significant finding on radiographs of patients with plateau fracture. Tibial plateau fracture patients are commonly imaged with conventional radiography and MDCT but not with MRI, and soft tissue injuries of the knee could be missed. Therefore it is clinically significant knowledge that if a tibial plateau fracture coexists with a Segond fracture, there is a high risk of avulsion fracture of the ACL. All the tibial fractures are not treated with operation and when conservative treatment is considered to patients with tibial plateau fracture combined with Segond fracture, we suggest that MRI should be performed to rule out the ACL injury.

### Reverse Segond fracture

Our findings of soft tissue injuries of Reverse Segond patients, differs significantly from previous reports. In this study Reverse Segond fracture patients had no PCL ruptures and only 14 % of these patients had an avulsion fracture of the PCL. In

previous publications all reverse Segond fracture patients have had an injury of the PCL [32, 36, 37]. Based on soft tissue injury patterns of the reverse Segond fracture posterior subluxation of the tibia, external rotation and valgus angulation of the knee are thought to be the injury mechanism of the reverse Segond fracture [32]. Our results suggest that external rotation and posterior subluxation are not necessary in the reverse Segond fracture's mechanism of the injury, because majority of our reverse Segond fracture patients had intact PCL. Therefore we suggest that valgus angulation is the most essential mechanism of injury. Most of the previously published reverse Segond fracture cases have been knee dislocation patients [32, 36, 37] and this seems to explain the high incidence of the PCL rupture among the previously published cases, as almost every knee dislocation patient has ruptures of both cruciate ligaments [133]. In this thesis we report 10 reverse Segond fracture cases without a knee dislocation. We also reviewed knee dislocation patients in our hospital from 11 years' period of time, and we did not find a single reverse Segond fracture in these patients. Therefore, our results do not support the association of knee dislocation and reverse Segond fracture.

In previous publications, there has been no discussion of association of a reverse Segond fracture and an ACL injury [32, 36, 37]. However, in our material 43 % of reverse Segond fracture patients had an avulsion fracture of the ACL. We think that this difference is explained by the high prevalence of tibial condyle fracture patients in our material. Over half of our patients had an Schatzker type 2 tibial condyle fracture. Schatzker type 2 fractures have been strongly associated with ACL injuries. It has been reported that 42 % of patients with Schatzker type 2 fractures had an avulsion fracture of the ACL and 15 % of patients have an ACL rupture [40]. Therefore, we do not suggest association of the ACL injury and a reverse Segond fracture.

## **DECT of cruciate ligaments (V)**

DECT is a relatively new technology. It has many well-known implementations such as metal artifact reduction, gout crystal and kidney stone differentiation and the differentiation of iodine and calcium from angiographic datasets. In this thesis we studied DECT possibilities to evaluate soft tissue injuries of the knee. This is relatively unknown subject, and there are only a few previously published studies. [16-18] There is a small 16 patients study where authors showed DECT to have high accuracy and interobserver agreement for the detection of complete ACL tears [18]. In addition there is an ex vivo experiment with 20 porcine hind legs where DECT's sensitivity and specificity to detect ACL rupture was 75 % and 68.8 %. In this thesis we reported that DECT has 93 % accuracy to detect a total ACL rupture, and DECT versus MRI, inter- and intraobserver proportions of agreement were excellent or good in the acute and subacute knee trauma patients. Therefore, our results are in agreement with previously published data and in addition, our study complements previous findings by demonstrating that DECT can be used for evaluating ACL injuries also in the acute trauma setting.

There was only one PCL rupture in our patient material. Therefore, we could not properly assess the utilization of DECT in PCL injuries.

There are few studies that concern DECT ability to visualize soft tissue structures and injuries of hand tendons. In these studies authors reported that 65-keV monochromatic GSI images had better image quality and ability to display minor tendon lesions compared to conventional polychromatic CT images [120, 121]. In this thesis, we evaluated what was the subjectively best keV level for visualization of the ACL, PCL and popliteus tendon. Our result with knee ligament and tendon was close to previously published study with hand tendons. The overall optimal mean keV level for visualization of ligaments was 63 keV. However, statistical

analysis revealed that the repeatability was poor. We also tested whether an intact ACL would be optimally visualized in a different keV level than a ruptured ACL, but no statistically significant difference between the two groups was found. This kind of comparison between an intact and an injured structure has not been reported in previous publications.

Published data concerning the clinical application of collagen specific color mapping are few and controversial. In our study, two radiologists graded the collagen-specific color mapping protocol to be the least usable of evaluating protocols in each case and structure that was reviewed compared to GSI and dual-energy bone removal protocols.

When proposing a new clinical use of a CT technique potential effect on radiation doses has to be discussed. In our material, an estimate of the mean effective dose for DECT knee examinations was 0.24 mSv. It has been reported that the mean radiation exposure for non-DECT examinations of the knee is 0.16 mSv [134].

Therefore, it seems that increase of effective dose is only slight, if DECT technique is used instead of conventional MDCT.

## **CONCLUSIONS**

### **Knee dislocation (I)**

The annual incidence of knee dislocation due to low-energy trauma in obese patients is not insignificant at a level 1 trauma center. The radiologist should be aware that, even after a simple fall, obese patients may have a knee dislocation. Obesity did not interfere with the performance or subjective image quality of knee MRI examinations. In our material, these patients seemed to have fewer neurovascular injuries than high energy knee dislocation patients. However, a question of associated neurovascular injuries needs further studies to be satisfyingly answered.

### **Patellar dislocation (II)**

MDCT is a useful imaging method to locate bony fragments and donor sites in patients with acute dislocation of the patella. There is no significant difference in the size, location or donor site of bony fragments between patients who have first-time or recurrent patellar dislocation. The number of bony fragments in first-time dislocators seems to be twice as high as in recurrent dislocators. Based on our results, it should be considered to increase the usage of MDCT for evaluating the presence of bony fragments and donor sites in acute patellar dislocation patients.

### **Segond fracture (III)**

Radiologists in emergency departments should be aware that a tibial plateau fracture combined with a Segond fracture is associated with avulsion fracture of the ACL. One of every 32 tibial plateau fractures coexists with a Segond fracture.

Of these patients, 70% have an ACL injury and 71% of these injuries are avulsion fractures. Previously reported isolated Segond fractures have mostly been associated with ruptures of the ACL with an intact bony insertion site. Patients with Segond fracture combined with a tibial plateau fracture may also have fewer meniscal injuries (25%) than patients with isolated Segond fractures.

#### **Reverse Segond fracture (IV)**

A reverse Segond fracture is found in 0.64 % of emergency room acute knee trauma MDCT examinations in a level 1 trauma center. Our results suggest that external rotation and posterior subluxation are not necessary in the reverse Segond fracture's mechanism of the injury as only 14 % of patients in our material had an injury of the PCL. We did not find association of knee dislocation and reverse Segond fracture. Based on our results, radiologists should not consider reverse Segond fracture as a sign of potential unrecognized spontaneously reduced knee dislocation, and also radiologists should not consider reverse Segond fracture to be indicator of the PCL injury, as former studies had suggested.

#### **DECT of cruciate ligaments (V)**

DECT is a usable method to evaluate a total rupture of the ACL in acute knee trauma patients. DECT have 79% sensitivity and 100 % specificity to detect a total rupture of ACL. This method is also repeatable based on excellent inter- and intraobserver proportions of agreement values. The collagen-specific color mapping protocol seems not to be useful for evaluating the ACL, PCL or popliteus tendon. Monochromatic GSI of 40–140 keV is generally a better protocol to evaluate ACL, PCL or popliteus tendon injuries than dual-energy bone removal. In monochromatic GSI images, the optimal keV level for visualization of the ACL, PCL and popliteus tendon is 63 keV. Our results indicates that if a dual energy CT



technique is available in a trauma center it should also be used in the case of acute knee trauma patient to improve diagnostic accuracy of the ACL rupture.

## ACKNOWLEDGEMENTS

Foremost I want to acknowledge my supervisor professor Seppo Koskinen for the excellent guidance throughout the 10-year-long process that finally resulted to this dissertation. I am very grateful for many discussions, where Koskinen always incredible promptly had a vision where the scientific project should aim and how the difficult problems should be handled. Also I want to express my gratitude for the patience and motivation in times my first priorities were temporarily wandered out of the academic work.

I am deeply grateful to docents Jukka Ristiniemi and Mats Geijer for the pre-examination. They did throughout and an adept evaluation of this thesis and gave valuable comments and suggestions which significantly improved the thesis.

I want to express my gratitude to docent Antti Paakkala and docent Roberto Blanco who formed an advisory committee for this thesis.

Furthermore, I want to offer my most sincere thankfulness to my coauthors Jan Lindahl and Harri Hietaranta. They as experts of trauma surgery had a different point of view than radiologist, and this kind of co-operation is essential to traumaradiological research. Especially Jan Lindahls comments significantly improved original publications of this dissertation. I owe profound gratitude to my radiology colleague Antti Mustonen, who served as a coauthor in original publication III, and helped in patient material search and gave highly valuable comments on my manuscripts.

Above all, I express my gratitude and love to my wife Marjaana. Thank you for all practical helps with this thesis, and especially, for your incredibly adamant love.

Our family is the ultimate base of my life, where I have drawn all the strength to finish this dissertation. Viena and Kielo you are the main reason for the snail's pace of this thesis, but also the main reason for everything else. I want also thank to my parents Jukka and Ria for the supportive childhood home and parenting which enabled my career.

This study was in part funded by the state subsidy for University Hospitals.

## REFERENCES

1. Nielsen AB, Yde J. Epidemiology of acute knee injuries: a prospective hospital investigation. *J Trauma* 1991; 31:1644-1648
2. Ferry T, Bergstrom U, Hedstrom EM, Lorentzon R, Zeisig E. Epidemiology of acute knee injuries seen at the Emergency Department at Umea University Hospital, Sweden, during 15 years. *Knee Surg Sports Traumatol Arthrosc* 2014; 22:1149-1155
3. Gage BE, McIlvain NM, Collins CL, Fields SK, Comstock RD. Epidemiology of 6.6 million knee injuries presenting to United States emergency departments from 1999 through 2008. *Acad Emerg Med* 2012; 19:378-385
4. Gianotti SM, Marshall SW, Hume PA, Bunt L. Incidence of anterior cruciate ligament injury and other knee ligament injuries: a national population-based study. *J Sci Med Sport* 2009; 12:622-627
5. Muthuri SG, McWilliams DF, Doherty M, Zhang W. History of knee injuries and knee osteoarthritis: a meta-analysis of observational studies. *Osteoarthritis Cartilage* 2011; 19:1286-1293
6. Yu JS. Easily Missed Fractures in the Lower Extremity. *Radiol Clin North Am* 2015; 53:737-55, viii
7. Gottsegen CJ, Eyer BA, White EA, Learch TJ, Forrester D. Avulsion fractures of the knee: imaging findings and clinical significance. *Radiographics* 2008; 28:1755-1770
8. Lee J, Papakonstantinou O, Brookenthal KR, Trudell D, Resnick DL. Arcuate sign of posterolateral knee injuries: anatomic, radiographic, and MR imaging data related to patterns of injury. *Skeletal Radiol* 2003; 32:619-627
9. Shindell R, Walsh WM, Connolly JF. Avulsion fracture of the fibula: the 'arcuate sign' of posterolateral knee instability. *Nebr Med J* 1984; 69:369-371
10. Ross G, Chapman AW, Newberg AR, Scheller AD, Jr. Magnetic resonance imaging for the evaluation of acute posterolateral complex injuries of the knee. *Am J Sports Med* 1997; 25:444-448
11. Strub WM. The arcuate sign. *Radiology* 2007; 244:620-621

12. Mellado JM, Ramos A, Salvado E, Camins A, Calmet J, Sauri A. Avulsion fractures and chronic avulsion injuries of the knee: role of MR imaging. *Eur Radiol* 2002; 12:2463-2473
13. Stevens MA, El-Khoury GY, Kathol MH, Brandser EA, Chow S. Imaging features of avulsion injuries. *Radiographics* 1999; 19:655-672
14. White EA, Patel DB, Matcuk GR, et al. Cruciate ligament avulsion fractures: anatomy, biomechanics, injury patterns, and approach to management. *Emerg Radiol* 2013; 20:429-440
15. Mustonen AO, Koivikko MP, Haapamaki VV, Kiuru MJ, Lamminen AE, Koskinen SK. Multidetector computed tomography in acute knee injuries: assessment of cruciate ligaments with magnetic resonance imaging correlation. *Acta Radiol* 2007; 48:104-111
16. Sun C, Miao F, Wang XM, et al. An initial qualitative study of dual-energy CT in the knee ligaments. *Surg Radiol Anat* 2008; 30:443-447
17. Fickert S, Nix M, Dinter DJ, et al. Assessment of the diagnostic value of dual-energy CT and MRI in the detection of iatrogenically induced injuries of anterior cruciate ligament in a porcine model. *Skeletal Radiol* 2013; 42:411-417
18. Glazebrook KN, Brewerton LJ, Leng S, et al. Case-control study to estimate the performance of dual-energy computed tomography for anterior cruciate ligament tears in patients with history of knee trauma. *Skeletal Radiol* 2014; 43:297-305
19. Takroui HS, Alnassar MM, Amirabadi A, et al. Metal Artifact Reduction: Added Value of Rapid-Kilovoltage-Switching Dual-Energy CT in Relation to Single-Energy CT in a Piglet Animal Model. *AJR Am J Roentgenol* 2015; 205:W352-9
20. Farshad-Amacker NA, Potter HG. MRI of knee ligament injury and reconstruction. *J Magn Reson Imaging* 2013; 38:757-773
21. Mutlu S, Mutlu H, Komur B, Guler O, Yucel B, Parmaksizoglu A. Magnetic resonance imaging-based diagnosis of occult osseous injuries in traumatic knees. *Open Orthop J* 2015; 9:84-88
22. Segond P. Recherches cliniques et experimentales sur les epanchements sanguins du genou par entorse. 1879; 7:297-299,319, 340, 379, 400, 419.

23. Claes S, Vereecke E, Maes M, Victor J, Verdonk P, Bellemans J. Anatomy of the anterolateral ligament of the knee. *J Anat* 2013; 223:321-328
24. Campos JC, Chung CB, Lektrakul N, et al. Pathogenesis of the Segond fracture: anatomic and MR imaging evidence of an iliotibial tract or anterior oblique band avulsion. *Radiology* 2001; 219:381-386
25. Caterine S, Litchfield R, Johnson M, Chronik B, Getgood A. A cadaveric study of the anterolateral ligament: re-introducing the lateral capsular ligament. *Knee Surg Sports Traumatol Arthrosc* 2015; 23:3186-3195
26. Dodds AL, Halewood C, Gupte CM, Williams A, Amis AA. The anterolateral ligament: Anatomy, length changes and association with the Segond fracture. *Bone Joint J* 2014; 96-B:325-331
27. Roessler PP, Schuttler KF, Heyse TJ, Wirtz DC, Efe T. The anterolateral ligament (ALL) and its role in rotational extra-articular stability of the knee joint: a review of anatomy and surgical concepts. *Arch Orthop Trauma Surg* 2016; 136:305-313
28. Capps GW, Hayes CW. Easily missed injuries around the knee. *Radiographics* 1994; 14:1191-1210
29. Goldman AB, Pavlov H, Rubenstein D. The Segond fracture of the proximal tibia: a small avulsion that reflects major ligamentous damage. *AJR Am J Roentgenol* 1988; 151:1163-1167
30. Dietz GW, Wilcox DM, Montgomery JB. Segond tibial condyle fracture: lateral capsular ligament avulsion. *Radiology* 1986; 159:467-469
31. Weber WN, Neumann CH, Barakos JA, Petersen SA, Steinbach LS, Genant HK. Lateral tibial rim (Segond) fractures: MR imaging characteristics. *Radiology* 1991; 180:731-734
32. Hall FM, Hochman MG. Medial Segond-type fracture: cortical avulsion off the medial tibial plateau associated with tears of the posterior cruciate ligament and medial meniscus. *Skeletal Radiol* 1997; 26:553-555
33. Bennett DL, George MJ, El-Khoury GY, Stanley MD, Sundaram M. Anterior rim tibial plateau fractures and posterolateral corner knee injury. *Emerg Radiol* 2003; 10:76-83
34. Bennett DL, George MJ, El-Khoury GY, Stanley MD, Sundaram M. Anterior

- rim tibial plateau fractures and posterolateral corner knee injury. *Emerg Radiol* 2003; 10:76-83
35. Vanek J. Posteromedial fracture of the tibial plateau is not an avulsion injury. A case report and experimental study. *J Bone Joint Surg Br* 1994; 76:290-292
  36. Engelsohn E, Umans H, Difelice GS. Marginal fractures of the medial tibial plateau: possible association with medial meniscal root tear. *Skeletal Radiol* 2007; 36:73-76
  37. Escobedo EM, Mills WJ, Hunter JC. The "reverse Segond" fracture: association with a tear of the posterior cruciate ligament and medial meniscus. *AJR Am J Roentgenol* 2002; 178:979-983
  38. Schatzker J, McBroom R, Bruce D. The tibial plateau fracture. The Toronto experience 1968--1975. *Clin Orthop Relat Res* 1979; (138):94-104
  39. Markhardt BK, Gross JM, Monu JU. Schatzker classification of tibial plateau fractures: use of CT and MR imaging improves assessment. *Radiographics* 2009; 29:585-597
  40. Gardner MJ, Yacoubian S, Geller D, et al. The incidence of soft tissue injury in operative tibial plateau fractures: a magnetic resonance imaging analysis of 103 patients. *J Orthop Trauma* 2005; 19:79-84
  41. Delamarter RB, Hohl M, Hopp E, Jr. Ligament injuries associated with tibial plateau fractures. *Clin Orthop Relat Res* 1990; (250):226-233
  42. Schatzker J. Compression in the surgical treatment of fractures of the tibia. *Clin Orthop Relat Res* 1974; (105):220-239
  43. Moore SL. Imaging the anterior cruciate ligament. *Orthop Clin North Am* 2002; 33:663-674
  44. Klass D, Toms AP, Greenwood R, Hopgood P. MR imaging of acute anterior cruciate ligament injuries. *Knee* 2007; 14:339-347
  45. Theodorou DJ, Theodorou SJ, Fithian DC, Paxton L, Garelick DH, Resnick D. Posterolateral complex knee injuries: magnetic resonance imaging with surgical correlation. *Acta Radiol* 2005; 46:297-305
  46. Fischer SP, Fox JM, Del Pizzo W, Friedman MJ, Snyder SJ, Ferkel RD. Accuracy of diagnoses from magnetic resonance imaging of the knee. A multi-center analysis of one thousand and fourteen patients. *J Bone Joint Surg Am*

1991; 73:2-10

47. Grover JS, Bassett LW, Gross ML, Seeger LL, Finerman GA. Posterior cruciate ligament: MR imaging. *Radiology* 1990; 174:527-530
48. Dunn WR, Lyman S, Lincoln AE, Amoroso PJ, Wickiewicz T, Marx RG. The effect of anterior cruciate ligament reconstruction on the risk of knee reinjury. *Am J Sports Med* 2004; 32:1906-1914
49. Andersson C, Odensten M, Good L, Gillquist J. Surgical or non-surgical treatment of acute rupture of the anterior cruciate ligament. A randomized study with long-term follow-up. *J Bone Joint Surg Am* 1989; 71:965-974
50. Morelli V, Bright C, Fields A. Ligamentous injuries of the knee: anterior cruciate, medial collateral, posterior cruciate, and posterolateral corner injuries. *Prim Care* 2013; 40:335-356
51. Shelbourne KD, Clark M, Gray T. Minimum 10-year follow-up of patients after an acute, isolated posterior cruciate ligament injury treated nonoperatively. *Am J Sports Med* 2013; 41:1526-1533
52. Wang D, Berger N, Cohen JR, Lord EL, Wang JC, Hame SL. Surgical treatment of posterior cruciate ligament insufficiency in the United States. *Orthopedics* 2015; 38:e281-6
53. Geeslin AG, Moulton SG, LaPrade RF. A Systematic Review of the Outcomes of Posterolateral Corner Knee Injuries, Part 1: Surgical Treatment of Acute Injuries. *Am J Sports Med* 2015;
54. Oei EH, Nikken JJ, Verstijnen AC, Ginai AZ, Myriam Hunink MG. MR imaging of the menisci and cruciate ligaments: a systematic review. *Radiology* 2003; 226:837-848
55. Anderson AF, Irrgang JJ, Dunn W, et al. Interobserver reliability of the International Society of Arthroscopy, Knee Surgery and Orthopaedic Sports Medicine (ISAKOS) classification of meniscal tears. *Am J Sports Med* 2011; 39:926-932
56. Rosas HG. Magnetic resonance imaging of the meniscus. *Magn Reson Imaging Clin N Am* 2014; 22:493-516
57. Flegal KM, Carroll MD, Ogden CL, Curtin LR. Prevalence and trends in obesity among US adults, 1999-2008. *JAMA* 2010; 303:235-241



58. Lissau I, Overpeck MD, Ruan WJ, et al. Body mass index and overweight in adolescents in 13 European countries, Israel, and the United States. *Arch Pediatr Adolesc Med* 2004; 158:27-33
59. Ogden CL, Carroll MD, Curtin LR, Lamb MM, Flegal KM. Prevalence of high body mass index in US children and adolescents, 2007-2008. *JAMA* 2010; 303:242-249
60. Stamatakis E, Primatesta P, Chinn S, Rona R, Falaschetti E. Overweight and obesity trends from 1974 to 2003 in English children: what is the role of socioeconomic factors? *Arch Dis Child* 2005; 90:999-1004
61. Haviv B, Bronak S, Thein R. Correlation between body mass index and chondral lesions in isolated medial meniscus tears. *Indian J Orthop* 2015; 49:176-180
62. Newman JT, Carry PM, Terhune EB, et al. Factors predictive of concomitant injuries among children and adolescents undergoing anterior cruciate ligament surgery. *Am J Sports Med* 2015; 43:282-288
63. Ridley TJ, Cook S, Bollier M, et al. Effect of body mass index on patients with multiligamentous knee injuries. *Arthroscopy* 2014; 30:1447-1452
64. Shetty RR, Mostofi SB, Housden PL. Knee dislocation of a morbidly obese patient: a case report. *J Orthop Surg (Hong Kong)* 2005; 13:76-78
65. Pace A, Fergusson C. Spontaneous non-traumatic dislocation of the knee. *Acta Orthop Belg* 2004; 70:498-501
66. Reckling FW, Peltier LF. Acute knee dislocations and their complications. 1969. *Clin Orthop Relat Res* 2004; (422):135-141
67. Yu JS, Goodwin D, Salonen D, et al. Complete dislocation of the knee: spectrum of associated soft-tissue injuries depicted by MR imaging. *AJR Am J Roentgenol* 1995; 164:135-139
68. Sillanpaa PJ, Kannus P, Niemi ST, Rolf C, Fellander-Tsai L, Mattila VM. Incidence of knee dislocation and concomitant vascular injury requiring surgery: a nationwide study. *J Trauma Acute Care Surg* 2014; 76:715-719
69. Brautigam B, Johnson DL. The epidemiology of knee dislocations. *Clin Sports Med* 2000; 19:387-397
70. Twaddle BC, Hunter JC, Chapman JR, Simonian PT, Escobedo EM. MRI in

- acute knee dislocation. A prospective study of clinical, MRI, and surgical findings. *J Bone Joint Surg Br* 1996; 78:573-579
71. Henrichs A. A review of knee dislocations. *J Athl Train* 2004; 39:365-369
  72. Potter HG, Weinstein M, Allen AA, Wickiewicz TL, Helfet DL. Magnetic resonance imaging of the multiple-ligament injured knee. *J Orthop Trauma* 2002; 16:330-339
  73. Twaddle BC, Bidwell TA, Chapman JR. Knee dislocations: where are the lesions? A prospective evaluation of surgical findings in 63 cases. *J Orthop Trauma* 2003; 17:198-202
  74. Cooper DE, Speer KP, Wickiewicz TL, Warren RF. Complete knee dislocation without posterior cruciate ligament disruption. A report of four cases and review of the literature. *Clin Orthop Relat Res* 1992; (284):228-233
  75. Flowers A, Copley LA. High-energy knee dislocation without anterior cruciate ligament disruption in a skeletally immature adolescent. *Arthroscopy* 2003; 19:782-786
  76. Bohndorf K, Kilcoyne RF. Traumatic injuries: imaging of peripheral musculoskeletal injuries. *Eur Radiol* 2002; 12:1605-1616
  77. Trappeniers L, De Maeseneer M, Van Roy P, Chaskis C, Osteaux M. Peroneal nerve injury in three patients with knee trauma: MR imaging and correlation with anatomic findings in volunteers and anatomic specimens. *Eur Radiol* 2003; 13:1722-1727
  78. Hollis JD, Daley BJ. 10-Year Review of Knee Dislocations: is Arteriography always Necessary? *J Trauma* 2005; 59:672-5; discussion 675-6
  79. Reddy CG, Amrami KK, Howe BM, Spinner RJ. Combined common peroneal and tibial nerve injury after knee dislocation: one injury or two? An MRI-clinical correlation. *Neurosurg Focus* 2015; 39:E8
  80. Niall DM, Nutton RW, Keating JF. Palsy of the common peroneal nerve after traumatic dislocation of the knee. *J Bone Joint Surg Br* 2005; 87:664-667
  81. Robertson A, Nutton RW, Keating JF. Dislocation of the knee. *J Bone Joint Surg Br* 2006; 88:706-711
  82. Werner BC, Gwathmey FW, Jr, Higgins ST, Hart JM, Miller MD. Ultra-low velocity knee dislocations: patient characteristics, complications, and

- outcomes. *Am J Sports Med* 2014; 42:358-363
83. Georgiadis AG, Mohammad FH, Mizerik KT, Nypaver TJ, Shepard AD. Changing presentation of knee dislocation and vascular injury from high-energy trauma to low-energy falls in the morbidly obese. *J Vasc Surg* 2013; 57:1196-1203
  84. Kim DH, Kline DG. Management and results of peroneal nerve lesions. *Neurosurgery* 1996; 39:312-9; discussion 319-20
  85. Terzis JK, Kostopoulos VK. Vascularized nerve grafts for lower extremity nerve reconstruction. *Ann Plast Surg* 2010; 64:169-176
  86. Johnson ME, Foster L, DeLee JC. Neurologic and vascular injuries associated with knee ligament injuries. *Am J Sports Med* 2008; 36:2448-2462
  87. McDonald CM, Carter GT, Fritz RC, Anderson MW, Abresch RT, Kilmer DD. Magnetic resonance imaging of denervated muscle: comparison to electromyography. *Muscle Nerve* 2000; 23:1431-1434
  88. Bendszus M, Wessig C, Reiners K, Bartsch AJ, Solymosi L, Koltzenberg M. MR imaging in the differential diagnosis of neurogenic foot drop. *AJNR Am J Neuroradiol* 2003; 24:1283-1289
  89. Xu YQ, Li Q, Shen TG, Su PH, Zhu YZ. Early diagnosis and treatment of trauma in knee joints accompanied with popliteal vascular injury. *Int J Clin Exp Med* 2015; 8:9421-9429
  90. Jones SA, Roberts DC, Clarke NM. Popliteal vasculature injuries in paediatric trauma patients. *Injury* 2012; 43:1709-1711
  91. Mahadeva D, Costa ML, Gaffey A. Open reduction and internal fixation versus hybrid fixation for bicondylar/severe tibial plateau fractures: a systematic review of the literature. *Arch Orthop Trauma Surg* 2008; 128:1169-1175
  92. Perron AD, Brady WJ, Sing RF. Orthopedic pitfalls in the ED: vascular injury associated with knee dislocation. *Am J Emerg Med* 2001; 19:583-588
  93. Gable DR, Allen JW, Richardson JD. Blunt popliteal artery injury: is physical examination alone enough for evaluation? *J Trauma* 1997; 43:541-544
  94. Martinez D, Sweatman K, Thompson EC. Popliteal artery injury associated with knee dislocations. *Am Surg* 2001; 67:165-167

95. Harilainen A, Myllynen P, Antila H, Seitsalo S. The significance of arthroscopy and examination under anaesthesia in the diagnosis of fresh injury haemarthrosis of the knee joint. *Injury* 1988; 19:21-24
96. Stefancin JJ, Parker RD. First-time traumatic patellar dislocation: a systematic review. *Clin Orthop Relat Res* 2007; 455:93-101
97. Metzler AV, Lattermann C, Johnson DL. Cartilage lesions of the patella: management after acute patellar dislocation. *Orthopedics* 2015; 38:310-314
98. Nomura E, Inoue M, Kurimura M. Chondral and osteochondral injuries associated with acute patellar dislocation. *Arthroscopy* 2003; 19:717-721
99. Luhmann SJ, Schoenecker PL, Dobbs MB, Gordon JE. Arthroscopic findings at the time of patellar realignment surgery in adolescents. *J Pediatr Orthop* 2007; 27:493-498
100. Virolainen H, Visuri T, Kuusela T. Acute dislocation of the patella: MR findings. *Radiology* 1993; 189:243-246
101. Stanitski CL, Paletta GA, Jr. Articular cartilage injury with acute patellar dislocation in adolescents. Arthroscopic and radiographic correlation. *Am J Sports Med* 1998; 26:52-55
102. Elias DA, White LM. Imaging of patellofemoral disorders. *Clin Radiol* 2004; 59:543-557
103. Gray SD, Kaplan PA, Dussault RG, et al. Acute knee trauma: how many plain film views are necessary for the initial examination? *Skeletal Radiol* 1997; 26:298-302
104. Brossmann J, Preidler KW, Daenen B, et al. Imaging of osseous and cartilaginous intraarticular bodies in the knee: comparison of MR imaging and MR arthrography with CT and CT arthrography in cadavers. *Radiology* 1996; 200:509-517
105. Tuite MJ, Kransdorf MJ, Beaman FD, et al. ACR Appropriateness Criteria Acute Trauma to the Knee. *J Am Coll Radiol* 2015; 12:1164-1172
106. Molenaars RJ, Mellema JJ, Doornberg JN, Kloen P. Tibial Plateau Fracture Characteristics: Computed Tomography Mapping of Lateral, Medial, and Bicondylar Fractures. *J Bone Joint Surg Am* 2015; 97:1512-1520
107. Medina O, Arom GA, Yeranoshian MG, Petrigliano FA, McAllister DR.

- Vascular and nerve injury after knee dislocation: a systematic review. *Clin Orthop Relat Res* 2014; 472:2621-2629
108. Coraci D, Tsukamoto H, Granata G, Briani C, Santilli V, Padua L. Fibular nerve damage in knee dislocation: Spectrum of ultrasound patterns. *Muscle Nerve* 2015; 51:859-863
  109. Zhang GY, Zheng L, Ding HY, Li EM, Sun BS, Shi H. Evaluation of medial patellofemoral ligament tears after acute lateral patellar dislocation: comparison of high-frequency ultrasound and MR. *Eur Radiol* 2015; 25:274-281
  110. Cook JL, Cook CR, Stannard JP, et al. MRI versus ultrasonography to assess meniscal abnormalities in acute knees. *J Knee Surg* 2014; 27:319-324
  111. Lee JJ, Choi YJ, Shin KY, Choi CH. Medial meniscal tears in anterior cruciate ligament-deficient knees: effects of posterior tibial slope on medial meniscal tear. *Knee Surg Relat Res* 2011; 23:227-230
  112. Siebold R, Fu FH. Assessment and augmentation of symptomatic anteromedial or posterolateral bundle tears of the anterior cruciate ligament. *Arthroscopy* 2008; 24:1289-1298
  113. Van Dyck P, De Smet E, Veryser J, et al. Partial tear of the anterior cruciate ligament of the knee: injury patterns on MR imaging. *Knee Surg Sports Traumatol Arthrosc* 2012; 20:256-261
  114. Ng AW, Griffith JF, Hung EH, Law KY, Yung PS. MRI diagnosis of ACL bundle tears: value of oblique axial imaging. *Skeletal Radiol* 2013; 42:209-217
  115. Figueroa D, Calvo R, Vaisman A, Carrasco MA, Moraga C, Delgado I. Knee chondral lesions: incidence and correlation between arthroscopic and magnetic resonance findings. *Arthroscopy* 2007; 23:312-315
  116. Halinen J, Koivikko M, Lindahl J, Hirvensalo E. The efficacy of magnetic resonance imaging in acute multi-ligament injuries. *Int Orthop* 2009; 33:1733-1738
  117. Abou-Sayed H, Berger DL. Blunt lower-extremity trauma and popliteal artery injuries: revisiting the case for selective arteriography. *Arch Surg* 2002; 137:585-589
  118. Tocci SL, Heard WM, Fadale PD, Brody JM, Born C. Magnetic resonance

- angiography for the evaluation of vascular injury in knee dislocations. *J Knee Surg* 2010; 23:201-207
119. Halvorson JJ, Anz A, Langfitt M, et al. Vascular injury associated with extremity trauma: initial diagnosis and management. *J Am Acad Orthop Surg* 2011; 19:495-504
  120. Deng K, Li W, Wang JJ, Wang GL, Shi H, Zhang CQ. The pilot study of dual-energy CT gemstone spectral imaging on the image quality of hand tendons. *Clin Imaging* 2013; 37:930-933
  121. Johnson TR, Krauss B, Sedlmair M, et al. Material differentiation by dual energy CT: initial experience. *Eur Radiol* 2007; 17:1510-1517
  122. Engebretsen L, Risberg MA, Robertson B, Ludvigsen TC, Johansen S. Outcome after knee dislocations: a 2-9 years follow-up of 85 consecutive patients. *Knee Surg Sports Traumatol Arthrosc* 2009; 17:1013-1026
  123. Mills B, Robb T, Larson DF. Intimal hyperplasia: slow but deadly. *Perfusion* 2012; 27:520-528
  124. Chen D, Shrivastava S, Ma L, et al. Inhibition of thrombin receptor signaling on alpha-smooth muscle actin(+) CD34(+) progenitors leads to repair after murine immune vascular injury. *Arterioscler Thromb Vasc Biol* 2012; 32:42-49
  125. Allaire E, Clowes AW. Endothelial cell injury in cardiovascular surgery: the intimal hyperplastic response. *Ann Thorac Surg* 1997; 63:582-591
  126. Sterpetti AV, Cucina A, Lepidi S, et al. Progression and regression of myointimal hyperplasia in experimental vein grafts depends on platelet-derived growth factor and basic fibroblastic growth factor production. *J Vasc Surg* 1996; 23:568-575
  127. Bohndorf K. Imaging of acute injuries of the articular surfaces (chondral, osteochondral and subchondral fractures). *Skeletal Radiol* 1999; 28:545-560
  128. Frush DP. Pediatric dose reduction in computed tomography. *Health Phys* 2008; 95:518-527
  129. Santos J, Foley S, Paulo G, McEntee MF, Rainford L. The impact of pediatric-specific dose modulation curves on radiation dose and image quality in head computed tomography. *Pediatr Radiol* 2015; 45:1814-1822

130. Young C, Owens CM. Pediatric computed tomography imaging guideline. *Acta Radiol* 2013; 54:998-1006
131. Geijer M, El-Khoury GY. MDCT in the evaluation of skeletal trauma: principles, protocols, and clinical applications. *Emerg Radiol* 2006; 13:7-18
132. Dalrymple NC, Prasad SR, Freckleton MW, Chintapalli KN. Informatics in radiology (infoRAD): introduction to the language of three-dimensional imaging with multidetector CT. *Radiographics* 2005; 25:1409-1428
133. Robertson A, Nutton RW, Keating JF. Dislocation of the knee. *J Bone Joint Surg Br* 2006; 88:706-711
134. Biswas D, Bible JE, Bohan M, Simpson AK, Whang PG, Grauer JN. Radiation exposure from musculoskeletal computerized tomographic scans. *J Bone Joint Surg Am* 2009; 91:1882-1889

