

Acta Med. Okayama, 2017  
Vol. 71, No. 1, pp. 85-89

Copyright©2017 by Okayama University Medical School.

Acta Medica  
Okayama

<http://escholarship.lib.okayama-u.ac.jp/amo/>

Case Report

## Syndrome of Inappropriate Antidiuretic Hormone Secretion Following Liver Transplantation

Kosei Takagi, Takahito Yagi\*, Susumu Shinoura, Yuzo Umeda,  
Ryuichi Yoshida, Daisuke Nobuoka, Nobuyuki Watanabe, Takashi Kuise,  
Tomokazu Fuji, Hiroyuki Araki, and Toshiyoshi Fujiwara

*Department of Gastroenterological Surgery, Okayama University Graduate School of Medicine,  
Dentistry and Pharmaceutical Sciences, Okayama 700-8558, Japan*

Syndrome of inappropriate antidiuretic hormone secretion (SIADH) is an extremely rare cause of hyponatremia post-liver transplantation. A 15-year-old Japanese girl with recurrent cholangitis after Kasai surgery for biliary atresia underwent successful living donor liver transplantation. Peritonitis due to gastrointestinal perforation occurred. Hyponatremia gradually developed but improved after hypertonic sodium treatment. One month later, severe hyponatremia rapidly recurred. We considered the hyponatremia's cause as SIADH. We suspected that tacrolimus was the disease's cause, so we used cyclosporine instead, plus hypertonic sodium plus water intake restriction, which improved the hyponatremia. Symptomatic hyponatremia manifested by SIADH is a rare, serious complication post-liver transplantation.

**Key words:** syndrome of inappropriate antidiuretic hormone secretion, SIADH, hyponatremia, liver transplantation, tacrolimus

The mechanism of hyponatremia is complex, as it presents as a generalized hemodynamic derangement [1]. Severe hyponatremia (serum sodium level  $< 125$  mEq/L) is associated with serious sequelae, especially when the condition develops rapidly (within 48 h) (e.g., confusion, hallucinations, seizures, coma, and respiratory arrest, leading to death) [2]. The syndrome of inappropriate antidiuretic hormone secretion (SIADH) is the most frequent cause of hyponatremia [3]. The criteria for diagnosing SIADH are as follows: euvolemic hyponatremia (serum sodium level  $< 135$  mEq/L), low serum osmolality ( $< 275$  mOsm/kg), urinary osmolality ( $> 100$  mOsm/kg), natriuresis (urinary sodium level  $> 40$  mEq/L), normal thyroid, pituitary, and adrenal function; and no recent use of

diuretic agents [2, 4, 5].

The causes of SIADH include malignant diseases, pulmonary diseases, disorders of the central nervous system, and drugs such as chemotherapeutic and antiepileptic agents [2, 6]. Symptomatic hyponatremia secondary to SIADH is extremely rare in recipients of liver transplantation; indeed, only one previous case has been reported, and hyponatremia developed as the initial presentation of cryptococcal meningitis after liver transplantation [7].

Here we describe the first reported case of a patient who developed drug-induced SIADH after undergoing a living donor liver transplantation (LDLT).

Received August 1, 2016; accepted September 14, 2016.

\*Corresponding author. Phone: +81-86-223-7151; Fax: +81-86-221-8775  
E-mail: twin1957yagi2000@yahoo.co.jp (T. Yagi)

Conflict of Interest Disclosures: No potential conflict of interest relevant to this article was reported.

## Case Report

A 15-year-old Japanese girl who had undergone Kasai surgery [8] for biliary atresia was referred to our facility for liver transplantation because of recurrent cholangitis. Her laboratory data are shown in Table 1. The model for end-stage liver disease score was 12 points, and the Child-Pugh classification was B.

The patient underwent the LDLT at our facility with an extended left lobe graft donated by her mother. The operative time was 7 h 36 min, and the intraoperative blood loss was 1,090 mL without blood transfusion. The post-transplant immunosuppression treatment consisted of tacrolimus (TCL) and prednisolone. She did not have any vascular complications or cellular rejection, but she underwent surgical drainage for peritonitis due to gastrointestinal perforation on days 13

and 17 after the transplantation.

After a reoperation for the peritonitis, she had diarrhea and clinical signs of excessive extracellular fluid retention, including a weight gain of 7 kg compared to her preoperative weight and edema of the entire body. Subsequently, her serum sodium concentration gradually decreased to 113 mEq/L (Table 1). Her postoperative clinical course is presented in Fig. 1. An endocrinological examination showed a low serum osmolality level (226 mOsm/kg) and high urinary osmolality and sodium levels (507 mOsm/kg and 114 mEq/L, respectively). The renal, thyroid, and adrenal findings were normal, and the results of imaging studies including chest and abdominal computed tomography and brain magnetic resonance imaging showed no abnormality.

We considered that the overflow of fluids, decrease in the sodium level due to diarrhea, and use of diuretic

**Table 1** Laboratory values before liver transplantation and during the two episodes of hyponatremia

	Reference value	Before transplantation	First episode of hyponatremia	Second episode of hyponatremia
WBC, / $\mu$ L	3,300–8,600	4,130	5,920	3,150
Hb, g/dL	11.6–14.8	13.6	7.4	10.4
T-bil, mg/dL	0.40–1.50	4.3	0.88	1.15
D-bil, mg/dL	0.08–0.28	3.2	0.42	0.35
AST, U/L	13–30	95	35	16
T-Cho, mg/dL	142–248	166	93	188
TP, g/dL	6.6–8.1	7.2	4.5	5.1
Alb, g/dL	4.1–5.1	4.3	3.1	3.2
CRTN, mg/dL	0.46–0.79	0.7	0.26	0.33
BUN, mg/dL	8.0–20.0	9.4	4.4	1.1
UA, mg/dL	2.6–5.5	3.0	0.9	0.6
Na, mEq/L	138–145	139	113	109
K, mEq/L	3.6–4.8	4.5	4.0	3.1
CL, mEq/L	101–108	104	85	77
CRP, mg/dL	<0.15	1.8	1.86	0.57
OSM, mOsm/kg	276–292	–	226	223
U-OSM, mOsm/kg	–	–	507	521
U-Na, mEq/L	130–260	–	114	80
AVP, pg/mL	0.0–4.2	–	1.8	2.8
ACTH, pg/mL	7.2–63.3	–	6.1	2.6
COR, $\mu$ g/dL	8.0–25.0	–	7.1	8.3
ALD, ng/dL	3.6–24.0	–	–	4.6
Renin activity, ng/mL/h	–	–	–	0.4
TSH, $\mu$ U/L	0.33–4.05	1.9	1.4	–
FT3, pg/mL	2.3–4.0	2.6	2.5	–

–, No data. ACTH, adrenocorticotropic hormone; Alb, albumin; ALD, aldosterone; AST, aspartate transaminase; AVP, arginine vasopressin; BUN, blood urea nitrogen; CL, chloride; COR, cortisol; CRP, C-reactive protein; CRTN, creatinine; D-bil, direct bilirubin; FT3, free triiodothyronine; Hb, hemoglobin; K, potassium; LDH, lactate dehydrogenase; Na, sodium; OSM, serum osmolality; T-bil, total bilirubin; T-Cho, total cholesterol; TP, total protein; TSH, thyroid stimulating hormone; UA, uric acid; U-Na, urinary sodium; U-OSM, urinary osmolality; WBC, white blood cell.

agents significantly affected the hyponatremia, and we therefore could not make a definitive diagnosis of SIADH. The hyponatremia gradually improved within 2 weeks after the administration of hypertonic sodium. She was discharged with a serum sodium concentration of 135 mEq/L on day 50 after the LDLT.

On day 78 after the LDLT, the patient was readmitted due to cholangitis with a serum sodium concentration of 140 mEq/L. Fasting and the administration of an antimicrobial drug promptly resolved the cholangitis; however, severe hyponatremia (serum sodium level=109 mEq/L) accompanied by malaise, loss of appetite, and headaches rapidly recurred on day 5 after readmission. The endocrinological examination showed a low serum osmolality level with increased vasopressin suppression, and high urinary osmolality and sodium levels (Table 1). The levels of blood sugar and total cholesterol were normal, which denied the possibility of pseudohyponatremia.

She had no clinical signs of excessive volume of extracellular fluid retention; thus, we considered the cause of hyponatremia as SIADH. Drugs were considered as possible factors in the etiology of SIADH,

because the patient did not have ordinary causes of SIADH such as malignant disease, pulmonary disease, and disorders of the central nervous system. We suspected that the TCL was the cause of the hyponatremia, so we used cyclosporine A (CyA) instead of TCL in addition to hypertonic sodium and a restriction of her water intake, which improved the hyponatremia within 2 weeks.

The patient has been followed up for 3 months without a recurrence of hyponatremia due to SIADH after CyA was used instead of TCL.

### Discussion

To our knowledge, this is the first detailed description of a patient with hyponatremia due to drug-induced SIADH following liver transplantation. This case highlights the potential association between the administration of TCL and drug-induced SIADH and the importance of perioperative management, including the diagnosis and treatment of SIADH.

Symptomatic hyponatremia secondary to SIADH is an extremely rare but occasionally life-threatening com-

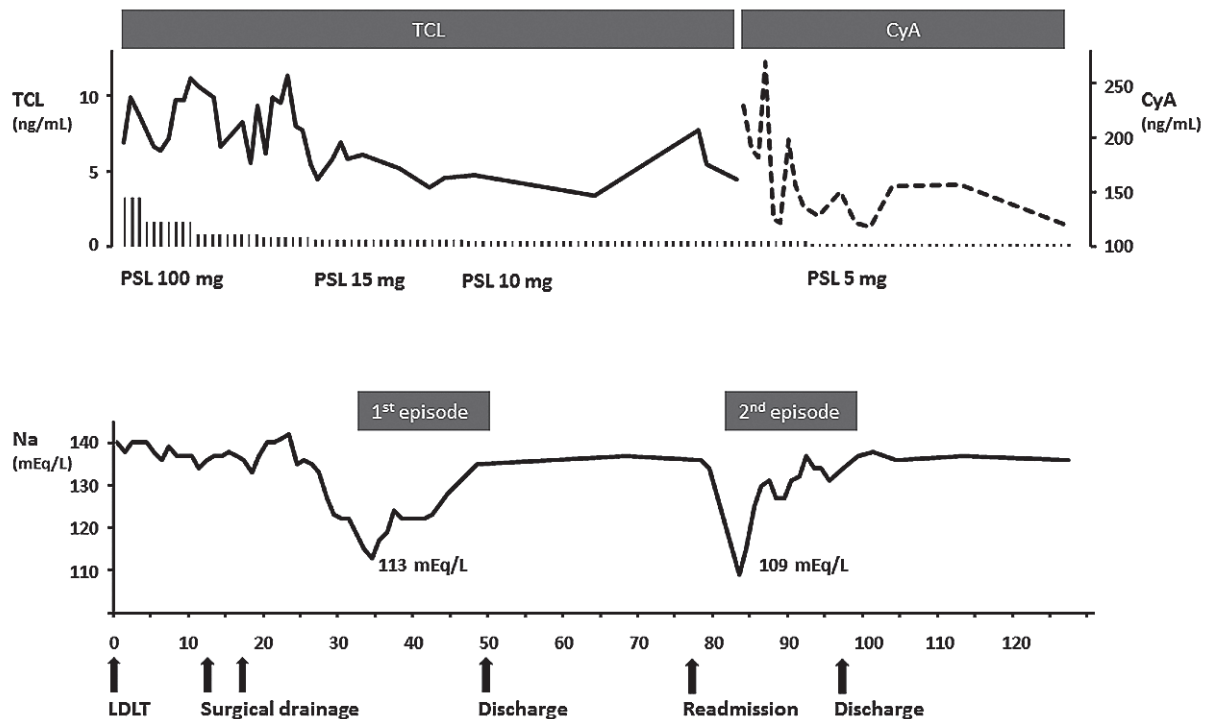


Fig. 1 Patient's clinical course after living donor liver transplantation (LDLT). CyA, cyclosporine A; Na, serum sodium; PSL, prednisolone; TCL, tacrolimus.

plication in patients who have undergone liver transplantation [7]. Our patient had two episodes of severe hyponatremia (Fig. 1). Although data from the endocrinological examination met the criteria for SIADH during the first episode, the presence of SIADH was masked by the clinical signs of an excessive volume of extracellular fluid, including weight gain, edema, pleural effusion, and abdominal effusion, and loss of sodium due to diarrhea and the administration of diuretic agents. We considered the cause of hyponatremia as the overflow of fluids and loss of sodium rather than SIADH. During the second episode, severe hyponatremia with symptoms rapidly developed despite the absence of the overflow of fluids, and the criteria for SIADH were met. Infections might be a trigger of SIADH, but our patient's cholangitis was not so severe and it was promptly resolved when the second episode of hyponatremia recurred. The possibility of relative adrenal insufficiency might not be completely excluded, but it was not main pathophysiology in this case. The immunosuppression management consisted of TCL and prednisolone (10 mg), and we did not change the amount of prednisolone during the second episode (Table 1). We checked the levels of cortisol and adrenocorticotropic hormone at the fastigium of the hyponatremia and the level of urinary free cortisol was also normal, which denied relative adrenal insufficiency.

The etiology of SIADH varies and includes malignant diseases, pulmonary diseases, disorders of the central nervous system, and drugs [2,6]. Drug-induced SIADH was considered the most plausible factor in the present case, because the patient had no malignant diseases, pulmonary diseases, or disorders of the central nervous system.

Regarding drug-induced SIADH, a variety of drugs can stimulate the release of arginine vasopressin or potentiate its action [2]. The hypothalamic production of vasopressin is increased by antiepileptic, antipsychotic, and chemotherapeutic agents such as Vinca alkaloids, platinum compounds, and alkylating agents [2,6]. Drugs that cause SIADH change the normal osmoreceptor control of vasopressin secretion by direct toxic effects on the neurohypophysis and hypothalamic system [2,9]. TCL is a rare cause of drug-induced SIADH; indeed, only three other cases have been reported [9-11]. In those three cases, TCL was used as treatment for acute graft-versus-host disease [10], systemic lupus erythematosus [11], and cord blood trans-

plantation [9], and the TCL was stopped or decreased when the patient's symptoms were suggestive of SIADH, which contributed to the improvement of hyponatremia.

Although the definitive pathophysiology of TCL-induced SIADH has not been examined, we suspect that toxic effects on the neurohypophysis and hypothalamus occur [6,9]. In addition, TCL can sensitize the kidneys to the antidiuretic hormone and stimulate the release of the antidiuretic hormone [10]. There were potential causative drugs of SIADH other than TCL in our patient's case, such as prednisolone, fluconazole, and valacyclovir. However, the effects of these drugs were likely to be negligible, because their administration was either decreased or stable at the onset of the SIADH. There appear to be no previous reports evaluating the relationship between SIADH and these drugs. We considered that TCL was the causative drug in our patient, because there was a strong association between the occurrence of SIADH and the increase in blood concentrations of TCL.

The only definitive treatment of hyponatremia associated with SIADH is the elimination of its causal lesions and the cessation of causative drugs [2,12]. For symptomatic patients with severe hyponatremia, rapid treatment is warranted [5,13]. The goal is to increase the serum sodium level by 1 to 2 mEq/L/h by infusing 3% saline. During the first 24 h of treatment, the correction should be no more than 8-10 mEq/L, and during the first 48 h, the correction should be no more than 18-25 mEq/L to avoid osmotic demyelination syndrome [2,5,14]. Avoiding overcorrection is particularly important. For asymptomatic patients, hyponatremia should be corrected gradually by fluid restriction, the intake of solute, or the intake of salt. For our patient, we used CyA instead of TCL and began sodium correction immediately by administering a 3% saline infusion. During the first 24 and 48 h of treatment, the sodium level was corrected to 6 mEq/L and 16 mEq/L, respectively. When a patient with SIADH is hospitalized, physicians should avoid excessive infusion, closely monitor the sodium concentration in the serum and urine, and prevent the occurrence of acute hyponatremia.

Despite our important findings, there are a few limitations to the present case report. First, the pathophysiology of TCL-induced SIADH has not been identified in detail. Second, we diagnosed drug-induced

SIADH by elimination and considered that TCL was the most likely causative drug. There were other potential causative drugs of SIADH, but the patient's hyponatremia improved and has not recurred after CyA was used instead of TCL.

In conclusion, our patient's case may indicate that SIADH is a potentially important complication of hyponatremia following liver transplantation, and this complication should be kept in mind whenever TCL administration is performed, irrespective of the dosage and TCL blood concentrations.

**Acknowledgments.** We thank the staff of the Departments of Anesthesiology, Gastroenterology and Hepatology, and Endocrinology and Metabolism at Okayama University Graduate School of Medicine, Dentistry and Pharmaceutical Sciences for providing perioperative patient management and helpful suggestions.

## References

1. Cimen S, Guler S, Ayloo S and Molinari M: Implications of hyponatremia in liver transplantation. *J Clin Med* (2014) 4: 66–74.
2. Ellison DH and Berl T: Clinical practice. The syndrome of inappropriate antidiuresis. *N Engl J Med* (2007) 356: 2064–2072.
3. Berghmans T, Paesmans M and Body JJ: A prospective study on hyponatraemia in medical cancer patients: epidemiology, aetiology and differential diagnosis. *Support Care Cancer* (2000) 8: 192–197.
4. Janicic N and Verbalis JG: Evaluation and management of hypo-osmolality in hospitalized patients. *Endocrinol Metab Clin North Am* (2003) 32: 459–481, vii.
5. Runkle I, Villabona C, Navarro A, Pose A, Formiga F, Tejedor A and Poch E: Treatment of hyponatremia induced by the syndrome of inappropriate antidiuretic hormone secretion: a multidisciplinary Spanish algorithm. *Nefrologia* (2014) 34: 439–450.
6. Liamis G, Milionis H and Elisaf M: A review of drug-induced hyponatremia. *Am J Kidney Dis* (2008) 52: 144–153.
7. Mansoor S, Juhardeen H, Alnajjar A, Al-Kattan W, Alsebayel M, Al Hamoudi W and Elsiey H: Hyponatremia as the initial presentation of cryptococcal meningitis after liver transplantation. *Hepat Mon* (2015) 15: e29902.
8. Kasai M and Suzuki S: A new operation for noncorrectable biliary atresia-hepatic portoenterostomy. *Shujutsu* (1959) 13: 733–739.
9. Arai Y, Kondo T, Kitano T, Yamashita K, Kadowaki N and Takaori-Kondo A: Syndrome of inappropriate antidiuretic hormone secretion induced by tacrolimus following allogeneic cord blood transplantation. *Intern Med* (2013) 52: 1223–1226.
10. Azuma T, Narumi H, Kojima K, Nawa Y and Hara M: Hyponatremia during administration of tacrolimus in an allogeneic bone marrow transplant recipient. *Int J Hematol* (2003) 78: 268–269.
11. Suemori K, Hasegawa H, Nanba C, Kohno M, Matsumoto T, Kawamoto Y, Murakami S, Sada E, Hashimoto K and Yasukawa M: Syndrome of inappropriate secretion of antidiuretic hormone induced by tacrolimus in a patient with systemic lupus erythematosus. *Mod Rheumatol* (2011) 21: 97–100.
12. Esposito P, Piotti G, Bianzina S, Malul Y and Dal Canton A: The syndrome of inappropriate antidiuresis: pathophysiology, clinical management and new therapeutic options. *Nephron Clin Pract* (2011) 119: c62–c73; discussion c73.
13. Ayus JC, Krothapalli RK and Arief Al: Treatment of symptomatic hyponatremia and its relation to brain damage. A prospective study. *N Engl J Med* (1987) 317: 1190–1195.
14. Adrogué HJ and Madias NE: Hyponatremia. *N Engl J Med* (2000) 342: 1581–1589.