

Original Article

Shortening Oblique Osteotomy with Screw Fixation for Correction of the Lesser Metatarsophalangeal Joints of Rheumatoid Forefoot

Keiichiro Nishida^{a,b*}, Takahiro Machida^b, Masahiro Horita^b, Kenzo Hashizume^c,
Ryuichi Nakahara^d, Yoshihisa Nasu^e, Hideki Ohashi^b, Kenta Saiga^b, and Toshifumi Ozaki^b

Departments of ^aHuman Morphology, ^bOrthopaedic Surgery, ^dMusculoskeletal Traumatology,
and ^eMedical Materials for Musculoskeletal Reconstruction, Okayama University Graduate School of Medicine,
Dentistry and Pharmaceutical Sciences, Okayama 700-8558, Japan, ^cDepartment of Rehabilitation,
Japan Labour Health and Welfare Organization, Okayama Rosai Hospital, Okayama 702-8055, Japan

The metatarsophalangeal (MTP) joints are often and predominantly affected in rheumatoid arthritis. The aim of the current study was to describe surgical techniques of shortening oblique osteotomy for lesser metatarsal bone with screw fixation at the osteotomy site, and to investigate the short-term clinical outcomes of our procedure. Twenty-seven feet (78 toes) of 24 RA patients underwent the shortening oblique osteotomy for the correction of deformity at the lesser MTP joints. The average Japanese Society of Surgery of the Foot (JSSF) standard rating system for the RA foot and ankle scale improved significantly from 59.6 points preoperatively to 88.3 points postoperatively ($p < 0.001$). Twenty-four feet (89%) were free from metatarsalgia and symptomatic callosities at the lesser MTP joint after surgery. Our present findings showed satisfactory early clinical outcomes of the shortening oblique osteotomy of the metatarsal bone with screw fixation for RA forefoot.

Key words: shortening oblique osteotomy, rheumatoid arthritis, forefoot, screw fixation

In rheumatoid arthritis (RA), 16–19% of patients initially present foot and ankle symptoms [1], with a lifetime prevalence of up to 90% [2]. The metatarsophalangeal (MTP) joints are often and predominantly affected with resultant hallux valgus of the big toe, and subluxation or luxation of the lesser toe dorsally over the metatarsal head, leading to claw toe deformities with painful callosity at plantar of MTP joints or at the dorsal aspect of the interphalangeal joints.

Although recent advances in pharmacologic therapy against RA have achieved better disease control,

ongoing progressive joint destruction may still occur in a subgroup of RA patients. Van der Leeden reported that among 848 patients who fulfilled the remission criteria during the first 8 years of RA, 29% had at least one painful MTP joint and 31% had at least one swollen MTP joint [3]. There is another subgroup of RA patients with long-standing disease who exhibit pain and functional impairment due to joint destruction and deformity. These patients may require joint surgery for improvement of the physical function and quality of life, in part based on increased expectation levels of the patients [2].

An investigation of the recent trends in orthopae-

dic surgery in a Japanese cohort reported a gradual increase in the number of foot arthroplasties [4]. Among the surgical procedures currently used for the correction of rheumatoid forefoot deformities, resection arthroplasty and its modifications have been the gold standard to improve patients' pain and ambulation, providing a satisfactory alignment of the toe [2,5]. However, stability of the forefoot can be lost by the resection of metatarsal head, and the deformity and metatarsalgia may recur gradually with time. Moreover, resection arthroplasty is not acceptable for feet with isolated or scattered dorsal dislocations of the MTP joints.

Given the recent advancement of improved disease-modifying antirheumatic drugs (DMARDs), preservation of the metatarsal heads has gained renewed interest as an alternative to resection arthroplasty when the joint destruction is mild to moderate [6]. To date, several metatarsal shortening osteotomies at the metatarsal neck or midshaft [7-9], the metatarsal head and neck [10-12], or a proximal metatarsal [13] have been reported as MTP joint-preserving methods.

We have modified the shortening oblique osteotomy described by Hanyu *et al.* [8], in a procedure in which metatarsal bones are fixed by screws instead of longitudinal Kirschner wire (K-wire) fixation from the distal phalanx to the metatarsal shaft. Here we describe the surgical techniques that we use for the screw fixation and the preliminary clinical results of our procedure for RA forefoot.

Patients and Methods

This retrospective study has been approved by the Ethics Committee of our institute (No. 2194). Twenty-seven feet (78 toes) of 24 RA patients who underwent a shortening oblique osteotomy on the lesser metatarsal bones at our institute between 2009 and 2014 with a minimum 6-months' follow-up were included in the study. All patients met the American Rheumatism Association 1987 revised criteria for RA [14]. They were 23 women and 1 man, and their average age was 63.0 (40-79) years at the surgery. The average disease duration was 18.5 (4-47) years, and the average postoperative follow-up period was 18.3 (6-49) months. Eleven patients (46%) were under being treated with biologic DMARDs (b-DMARDs).

For fixation of the osteotomy site, cortex screws

were used in 24 feet, and cannulated cancellous screws were used in 3 feet. The clinical condition of each foot before and after surgery was assessed according to the Japanese Society of Surgery of the Foot (JSSF) standard rating system for the RA foot and ankle scale for pain (0-30 points), deformity (0-25 points), range of motion (ROM, 0-15 points), walking ability (0-20 points), and activity of daily living (0-10 points) [15]. The radiographic assessment included the presence or absence of preoperative dislocation of an MTP joint, the extent of dislocation of MTP joint(s) evaluated by the distance between the distal end of the metatarsal head and the proximal end of the basal phalanx, and the amount of shortening of the metatarsal bone at the final follow-up.

Surgical techniques. For a single osteotomy, a 3-cm longitudinal dorsal skin incision is made over the metatarsal. For a multiple osteotomy, a 4- to 5-cm longitudinal dorsal skin incision is made between the second and the third, and the fourth and fifth metatarsals. Blunt dissection of the soft tissue is made, and the extensor digitorum brevis tendon is routinely sectioned. The extensor digitorum longus tendon is preserved or separated using Z-lengthening if there is a severe MTP joint dislocation. The MTP joint is then opened with a capsulo-synovectomy, and the medial and lateral collateral ligaments and the associated lumbricals are completely released. After the distal third of metatarsal bones is exposed subperiosteally, a drill hole is made on the dorsal cortex at the level of the metatarsal neck sloping at 45 degrees from the distal dorsal to the proximal planter (Fig. 1A).

Next, an osteotomy is done with an oscillating saw at 1.0 cm proximally from the neck of the metatarsal bone, sloping at 45 degrees from the proximal dorsal to the distal planter (Fig. 1B). After the division of the metatarsal bone and resection of the plantar tip of the proximal stump, the distal fragment is slide up at the osteotomy site with planterflexion and reduction of the MTP joint (Fig. 1C).

When joint reduction is difficult, a slice of the proximal stump is resected by 1-2 mm at a time parallel to the original plane of the osteotomy until smooth reduction of the MTP joint is achieved. Under C-arm fluoroscopy, the amount of shortening is adjusted, making the second metatarsal bone the longest, followed by the third, fourth, and fifth metatarsal bones

in order to form a smooth arc toward the lateral side. While holding the distal fragment, the drilling is conducted further to penetrate the plantar cortex of the proximal shaft (Fig. 1D).

After the appropriate length of the screw is sized, a cortex screw (Modular Hand System, DePuy Synthes, Switzerland) with the dia. of 2.0 or 2.4 mm is inserted to fix the fragment (Fig. 1E). When the cannulated screw is used, the osteotomy is done first (Fig. 2A), and the distal fragment is slide up at the osteotomy site (Fig. 2B). With reduction of the MTP joint, a guide wire is inserted from the center of the distal fragment at the level of the metatarsal neck sloping at 45 degrees from the distal dorsal to the proximal planter (Fig. 2C).

After the length of the appropriate screw is measured (Fig. 2D), a drill hole for a 2.0- or 2.5-mm-dia. screw is made along with the guide wire (Fig. 2E), and the bones are fixed by a selected length of cannulated cancellous screw (DARTFIRE[®], Wright Medical Technology, Memphis, TN, USA) (Fig. 2F). The hammertoe or claw toe deformity is carefully corrected manually, and dermadesis or extensor tendon plication is added at the dorsal aspect of the proximal interphalangeal (PIP) joint if necessary. If the ham-

mer toe deformity is not correctable, a proximal phalangeal head excision and temporary wire fixation, or arthrodesis of the PIP joint is indicated.

Postoperative management. A bulky compressive bandage is applied with the toe held in planarflexion for 7–10 days. Passive and active ROM exercise is started at 5–7 days. Bandages are removed 10–14 days postoperatively. Heel gait is permitted at 7 days if possible, and partial weight bearing with a custom-made arch support is permitted at 14 days. Full weight bearing with a custom-made arch support is permitted 3 weeks after surgery. Patients are able to return to normal footwear 6–8 weeks after surgery.

Statistical analysis. We used the free statistical package R for Windows (www.r-project.org) for the statistical analyses. The pre- and post-operative JSSF scales and radiographic variables were analyzed using the Wilcoxon signed-rank sum test and the Mann-Whitney *U*-test, respectively. For the analysis of the correlation between the extent of the dislocation of the MTP joint and the amount of shortening of the metatarsal bone, we used the Spearman rank correlation coefficient. *P*-values < 0.05 were considered significant.

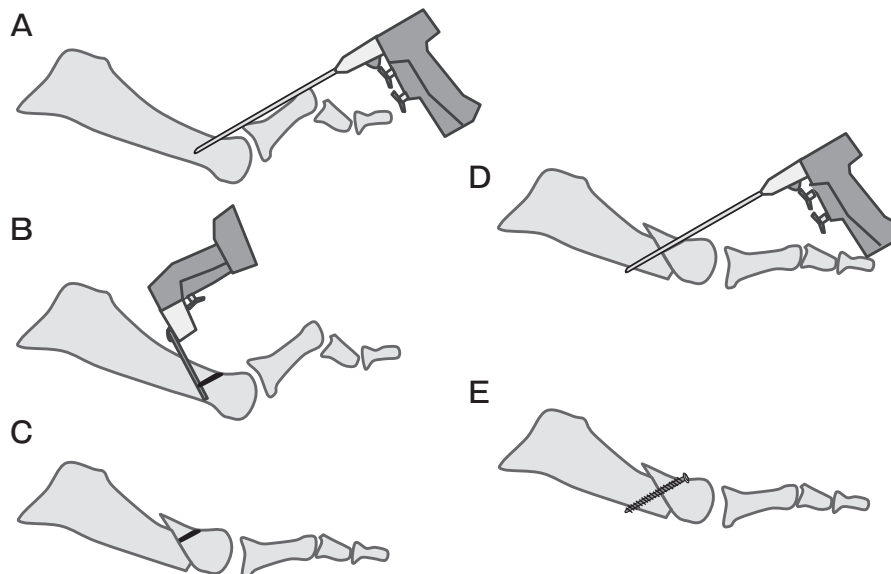


Fig. 1 Surgical procedure for shortening oblique osteotomy for lesser metatarsal bone with cortex screw fixation. A drill hole is made on the dorsal cortex at the level of the metatarsal neck (A), osteotomy is done with the oscillating saw (B), and distal fragment is slide up at the osteotomy site with the reduction of MTP joint (C). Then the drilling is further proceeded to penetrate the plantar cortex of the proximal shaft (D), and cortex screw with the diameter of 2.0 or 2.4 mm is inserted to fix the fragment after sizing the appropriate length of the screw (E).

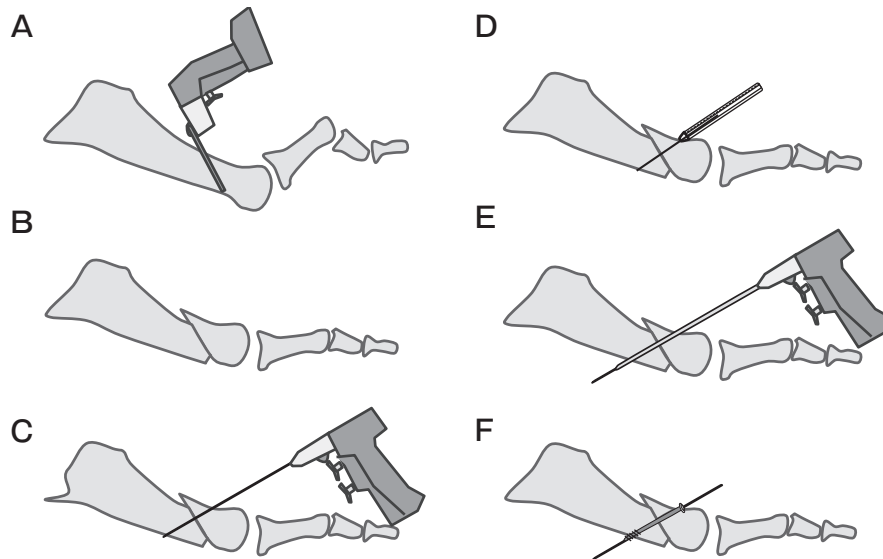


Fig. 2 Surgical procedure for shortening oblique osteotomy for lesser metatarsal bone with cannulated cancellous screw fixation. An osteotomy is done first (A), distal fragment is slide up at the osteotomy site (B), and a guide wire is inserted from the center of distal fragment at the level of the metatarsal neck (C). After measuring the length of appropriate screw (D), drill hole for 2.0 or 2.5mm diameter screw is made along with the guide wire (E), and bones are fixed by selected length of cannulated cancellous screw (F).

Results

For the big toe, a modified Mann method with plate fixation was done in 6 feet (Fig. 3), and MTP joint arthrodesis was done in 9 feet combined with shortening osteotomy of the lesser toes. The remaining 12 feet underwent lesser toe surgery without big toe procedures. The average JSSF scale improved significantly from 59.6 points (range, 28–81 points) preoperatively to 88.3 points (range, 56–98 points) postoperatively ($p < 0.001$) (Table 1). In the sub-analysis of activity of daily life, “standing on toe” was Easy in 13 feet (48%) and Difficult in 6 feet (22%). Eight feet (30%) were unable to stand on the toe, and of these, 5 feet (63%) had undergone MTP joint arthrodesis of the big toe.

Radiographic assessment. The average amount of shortening of the metatarsal bone after the surgery was 4.1 ± 1.9 mm. Preoperative dislocation of the MTP joint was noted in 39 toes of 20 feet. In these toes, the average preoperative extent of dislocation of the MTP joint was 6.1 ± 2.3 mm, and the average amount of shortening of the metatarsal bone after the surgery was 4.6 ± 2.0 mm. In the 39 toes without MTP joint dislocation, the amount of shortening of the metatarsal bone after the surgery was 3.6 ± 1.7 mm,

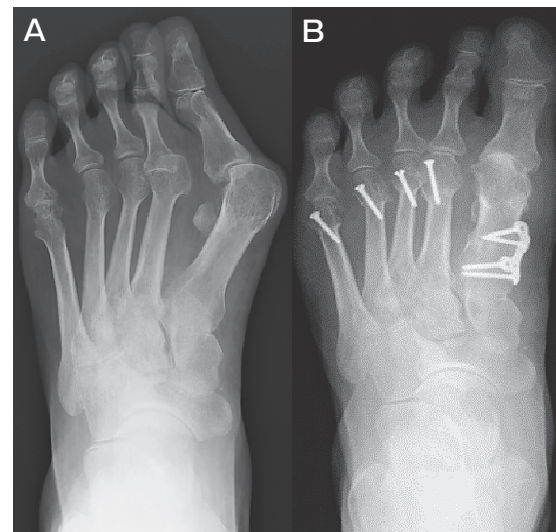

Fig. 3 Radiographs showing before (A) and after shortening oblique osteotomy for lesser metatarsal bone with screw fixation (B). For the 1st metatarsal bone, correction osteotomy and plate fixation was done.

which was significantly lower than that of the toes with MTP joint dislocation ($p < 0.01$). There was no significant correlation between the extent of dislocation of the MTP joint and the amount of shortening of the metatarsal bone ($R = 0.17$, $p = 0.31$).

Table 1 Clinical outcome of shortening oblique osteotomy assessed by JSSF-RA scale

Items	Preoperative	Postoperative	P value
General pain (30 points)	20.7 (20–30)	30.0	<0.0001*
Deformity (25 points)	13.8 (3–21)	21.1 (11–25)	<0.0001*
Motion (15 points)	9.4 (0–15)	11.6 (0–15)	0.0081*
Walking ability (20 points)	11.5 (5–20)	18.9 (10–20)	0.0002*
Activities of daily living (10 points)	4.2 (0–9)	6.6 (0–10)	0.0004*
Total	59.6 (28–81)	88.3 (56–98)	<0.0001*

all values are expressed as mean (range). *Statistically significant ($p < 0.05$)

IP, interphalangeal; MTP, metatarsophalangeal

JSSF-RA scale, Japanese Society of Surgery of the Foot standard rating system for the RA foot and ankle scale.

Postoperative complications. Superficial infection was noted in 2 cases, and treated by antibiotics. In one case with a deep infection, a screw was removed and antibiotics were prescribed. None of the cases presented nonunion, screw breakage, delayed wound healing, or a digital nerve injury. The recurrence of callosity at the plantar aspect of the MTP joint was noted in 4 toes of 4 patients, and 2 of the toes presented mild pain. Three toes of 2 patients showed recurrence of hammer toe deformity after manipulation, and 2 toes of one patient were symptomatic. Twenty patients (89%) were symptom-free at the lesser MTP joint after surgery.

Discussion

Any joint-preserving procedure for the correction of RA forefoot theoretically has several merits; it contributes to the reconstruction of the transverse metatarsal arch, corrects the metatarsus latus, preserves the joint function (especially of the fulcrum of flexor tendon), and preserves the weight-bearing area of the metatarsal head. Fukushi *et al.* retrospectively investigated 17 patients with rheumatoid forefoot deformities who underwent surgery, and they reported that the joint-preserving procedures for rheumatoid forefoot deformities resulted in better clinical outcomes than resection arthroplasty with regard to the function of the hallux and the alignment of the lesser toes [16]. However, severe destruction of the metatarsal head is not a good indication for a joint-preserving procedure; rather, resection arthroplasty is indicated especially for the fifth MTP joint.

The distal shortening oblique osteotomy of the lesser metatarsals occasionally causes delayed union

at the osteotomy site. In their comparison of the results of the Weil and Helal osteotomies for lesser MTP joints of 30 RA patients, Trnka *et al.* reported that there was also no malunion or pseudoarthrosis in the Weil osteotomy group, whereas there were five malunions and 3 pseudoarthroses in the Helal osteotomy group. A possible reason for this difference in the rate of complications might be that no fixation was used after Helal osteotomy.

The shortening oblique osteotomy surgical method reported by Hanyu modified the original Helal method, and fixed the osteotomy sites temporary by 1.2 mm of K-wire from the distal phalanx to the metatarsal shaft; the K-wires are removed 3 weeks after surgery. Using this method, Yano *et al.* reported that delayed union occurred in 21 of 127 metatarsals (16.5%) of patients who underwent a shortening oblique osteotomy [17]. In our procedure, the osteotomy site is secured with a single screw, similarly to a Weil's osteotomy. It is not necessary to remove the screws, and thus the fixing force at the osteotomy site would not be lost before bone union.

In the present study, nonunion was not observed in any of the cases. However, firm screw fixation at the osteotomy site can be a disadvantage in that it may not permit the further slide of the distal fragment postoperatively. With weight bearing, the distal metatarsal would rise to a "natural" level in Helal's method [18] and would be "automatically reduced" by intramedullary fixation by a thin K-wire in Hanyu's method [8]. Surgeons should carefully determine the length of the metatarsal to reproduce a smooth arc with the adjacent metatarsal bones, as well as to preserve the transverse metatarsal arch.

There are several other advantages of screw fixa-

tion over K-wire fixation. Our procedure does not fix the MTP joint, and is not invasive for phalangeal bones. Early postoperative exercise for MTP-joint ROM can be started, thus contributing to improved postoperative ROM and function of the feet. In the present study, 46% of the patients were using a b-DMARD. The cannulated screw system also enabled us to re-start the b-DMARD after the surgical wounds healed. Further, the use of the cannulated screw system simplified the surgery, and drilling through the guide wire secured the distal fragment from the bone fracture by direct drilling. This system also made the operative time shorter and may have contributed to the prevention of delayed wound healing, as Yano *et al.* described [19].

The post-operative length of the metatarsal bone is important for stable weight bearing and powerful toe-off, and thus a minimum amount of shortening is preferred. In the oblique osteotomy procedure reported by Hanyu, the osteotomy is performed twice according to the extent of dislocation, and the resulting shortening was an average of 7 mm; however, 80% of the ray shortenings were <10 mm [8]. Niki *et al.* described a technique in which, after a proximal oblique shortening osteotomy, the head of each metatarsal is repositioned to the level of the proximal part of each dislocated proximal phalanx [13]. Trnka *et al.* described shortening ranging from 3 to 8 mm according to the length of the involved and adjacent metatarsal bones and the severity of the dislocation in the Weil osteotomy [18].

In our procedure, the sliding up of the distal fragment at the osteotomy site is done with the smooth reduction of the MTP joint after an intensive capsulo-synovectomy and soft tissue release within the MTP joint. The sliding up of the distal fragment was enough for MTP joint reduction in the toes without dislocation. When joint reduction is difficult, shortening of the proximal stump is performed 1–2 mm at a time until smooth reduction of MTP joint is achieved. As a result, the average amount of shortening of the metatarsal bone after the surgery was 4.1 ± 1.9 mm (range 1.3–10.9 mm).

In addition to the minimum shortening of the metatarsal bone, the release of the extensor digitorum brevis tendon and the Z-lengthening of the extensor digitorum longus tendon, soft tissue release, and synovectomy at the MTP joint are important for the joint

reduction. Our present findings revealed that there was no correlation between the extent of the dislocation of the MTP joint before the surgery and the amount of shortening of the metatarsal bone. As the severity of contracture at the MTP joint differs among patients, it would be difficult to completely predict the amount of shortening from the preoperative radiograph.

In conclusion, the results of the present study showed that the early clinical outcome of the shortening oblique osteotomy of the metatarsal bone with screw fixation for RA forefoot was satisfactory and comparable to those reported previously. The surgical procedure was relatively easy when a cannulated screw system was used. Further investigations with longer follow-up periods and comparisons with other surgical procedures are needed to test our findings.

References

1. Jaakkola JI and Mann RA: A review of rheumatoid arthritis affecting the foot and ankle. *Foot Ankle Int* (2004) 25: 866–874.
2. Matricali GA, Boonen A, Verduyck J, Taelman V, Verschueren P, Sileghem A, Corluy L and Westhovens R: The presence of forefoot problems and the role of surgery in patients with rheumatoid arthritis. *Ann Rheum Dis* (2006) 65: 1254–1255.
3. van der Leeden M, Steultjens MP, van Schaardenburg D and Dekker J: Forefoot disease activity in rheumatoid arthritis patients in remission: results of a cohort study. *Arthritis Res Ther* (2010) 12: R3.
4. Momohara S, Inoue E, Ikari K, Ochi K, Ishida O, Yano K, Sakuma Y, Yoshida S, Koyama T, Koenuma N, Taniguchi A and Yamanaka H: Recent trends in orthopedic surgery aiming to improve quality of life for those with rheumatoid arthritis: data from a large observational cohort. *J Rheumatol* (2014) 41: 862–866.
5. Reize P, Leichtle CI, Leichtle UG and Schanbacher J: Long-term results after metatarsal head resection in the treatment of rheumatoid arthritis. *Foot Ankle Int* (2006) 27: 586–590.
6. Krause FG, Fehlbaum O, Huebschle LM and Weber M: Preservation of lesser metatarsophalangeal joints in rheumatoid forefoot reconstruction. *Foot Ankle Int* (2011) 32: 131–140.
7. Helal B: Metatarsal osteotomy for metatarsalgia. *J Bone Joint Surg Br* (1975) 57: 187–192.
8. Hanyu T, Yamazaki H, Murasawa A and Tohyama C: Arthroplasty for rheumatoid forefoot deformities by a shortening oblique osteotomy. *Clin Orthop Relat Res* (1997): 131–138.
9. Takakubo Y, Takagi M, Tamaki Y, Sasaki A, Nakano H, Orui H and Ogino T: Mid-term results of joint-preserving procedures by a modified Mann method for big toe deformities in rheumatoid patients undergoing forefoot surgeries. *Mod Rheumatol* (2010) 20: 147–153.
10. Trieb K, Hofstaetter SG, Panotopoulos J and Wanivenhaus A: The Weil osteotomy for correction of the severe rheumatoid forefoot. *Int Orthop* (2013) 37: 1795–1798.
11. Barouk LS and Barouk P: Joint-preserving surgery in rheumatoid forefoot: preliminary study with more-than-two-year follow-up. *Foot*

- Ankle Clin (2007) 12: 435–454, vi.
12. Bhavikatti M, Sewell MD, Al-Hadithy N, Awan S and Bawarish MA: Joint preserving surgery for rheumatoid forefoot deformities improves pain and corrects deformity at midterm follow-up. *Foot (Edinb)* (2012) 22: 81–84.
 13. Niki H, Hirano T, Akiyama Y, Mitsui H and Fujiya H: Long-term outcome of joint-preserving surgery by combination metatarsal osteotomies for shortening for forefoot deformity in patients with rheumatoid arthritis. *Mod Rheumatol* (2015) 25: 683–688.
 14. Arnett FC, Edworthy SM, Bloch DA, McShane DJ, Fries JF, Cooper NS, Healey LA, Kaplan SR, Liang MH, Luthra HS, et al.: The American Rheumatism Association 1987 revised criteria for the classification of rheumatoid arthritis. *Arthritis Rheum* (1988) 31: 315–324.
 15. Niki H, Aoki H, Inokuchi S, Ozeki S, Kinoshita M, Kura H, Tanaka Y, Noguchi M, Nomura S, Hatori M and Tatsunami S: Development and reliability of a standard rating system for outcome measurement of foot and ankle disorders I: development of standard rating system. *J Orthop Sci* (2005) 10: 457–465.
 16. Fukushi J, Nakashima Y, Okazaki K, Yamada H, Mawatari T, Ohishi M, Oyamada A, Akasaki Y and Iwamoto Y: Outcome of Joint-Preserving Arthroplasty for Rheumatoid Forefoot Deformities. *Foot Ankle Int* (2016) 37: 262–268.
 17. Yano K, Ikari K, Ishibashi M and Momohara S: Preventing delayed union after distal shortening oblique osteotomy of metatarsals in the rheumatoid forefoot. *Mod Rheumatol* (2015): 1–5.
 18. Trnka HJ, Muhlbauer M, Zettl R, Myerson MS and Ritschl P: Comparison of the results of the Weil and Helal osteotomies for the treatment of metatarsalgia secondary to dislocation of the lesser metatarsophalangeal joints. *Foot Ankle Int* (1999) 20: 72–79.
 19. Yano K, Ikari K, Takatsuki Y, Taniguchi A, Yamanaka H and Momohara S: Longer operative time is the risk for delayed wound healing after forefoot surgery in patients with rheumatoid arthritis. *Mod Rheumatol* (2016) 26: 211–215.