

Acta Med. Okayama, 2016
Vol. 70, No. 5, pp. 389–392

Copyright©2016 by Okayama University Medical School.

Acta Medica
Okayama

<http://escholarship.lib.okayama-u.ac.jp/amo/>

Case Report

Case of 24-week Fetus Delivered from Mother on Life Support with Brain-death from Suicide Attempt: Ethical Issues Associated with Severe Complications

Takeshi Nishimura^a, Keisuke Kohama^b, Takaaki Osako^a, Taihei Yamada^a,
Hiroyuki Tanaka^c, Atsunori Nakao^{a*}, and Joji Kotani^a

^aDepartments of Emergency, Disaster and Critical Care Medicine, and
^cObstetrics and Gynecology, Hyogo College of Medicine, Nishinomiya, Hyogo 663-8501, Japan,
^bSenri Critical Care Medical Center, Suita City, Osaka 565-0862, Japan

Advances in critical care medicine have made it possible to sustain vital organ systems in brain-dead patients. One clinical scenario besides donor organ retrieval in which a benefit may be gained from continuing life support is pregnancy. A pregnant woman in her late 30's at 23 weeks gestation exhibiting worsening depression was referred to the Department of Psychiatry. One day after admission she attempted suicide by hanging and suffered a cardiopulmonary arrest. A fetal heart beat and fetal motion was confirmed immediately after resuscitation. Three days after admission, an emergency Cesarean section (CS) was performed because of her unstable hemodynamic situation. The baby was born and the mother died after delivery. The baby presented neurological complications. Such a case should be managed collaboratively among professional experts in several medical teams. Consensus and recommendations for the management of similar scenarios may also be adjusted.

Key words: brain-dead mother, suicide, somatic support

Advances in critical care medicine and life support devices have made it possible to sustain the vital organs and systems of brain-dead patients. For many years, the only benefit of prolonging life support for brain-dead patients was the preservation of donor organs until needed. However, in last few decades, other clinical scenarios in which prolonged life support for brain-dead patients is advantageous have been reported. The case of a brain-dead pregnant woman is extraordinary and noteworthy, as such a case involves at least three lives; the mother, the fetus, and potential donor organ recipients(s).

Although previous publications on brain-dead preg-

nant women have reported that gestational age is the most important factor in determining when to deliver a fetus, somatic life support can help the fetus continue to develop.

We describe a delivery from a brain-dead pregnant woman at 24 weeks and one day gestation who had attempted suicide by hanging 2 days prior and suffered a cardiopulmonary arrest. After resuscitation, her blood pressure deteriorated, and an emergency Cesarean section was required. Unfortunately, her fetus was born with severe neurological disorders.

Our case involves a lot of issues for obstetric intensive care and ethical management. We believe our case report can help clinicians decide whether to

Received November 19, 2015; accepted March 31, 2016.

*Corresponding author. Phone: +81-86-235-7426; Fax: +81-86-235-7427
E-mail: qq-nakao@okayama-u.ac.jp (A. Nakao)

Conflict of Interest Disclosures: No potential conflict of interest relevant to this article was reported.

maintain life support for pregnant brain-dead women.

Case Presentation

A pregnant woman in her late 30's at in her 23rd week of gestational, gravida 1 para 1, was admitted to our hospital due to depression associated with pregnancy. At four month' gestation, she had experienced suicidal thoughts and fell into an unhealthy psychiatric state. She was referred to the hospital's psychosomatic department complaining of a sleeping disorder, and was diagnosed with peripartum depression. She was admitted to the psychiatric unit, and psychiatric and obstetric clinicians collaborated regarding her care at 23 weeks and 5 days. Selective serotonin reuptake inhibitors and a sleeping drug were administered.

One day after admission, at 23 weeks and 6 days gestation age, she attempted suicide by hanging and suffered a cardiopulmonary arrest. CPR was performed to try to save her. Her spontaneous circulation returned with CPR and epinephrine administration after 21 minutes of pulseless electrical activity. After resuscitation, her laboratory blood test appeared as follows: pH, 6.983; base excess, -19.3 mmol/L; serum lactate, 17.6 mmol/L. She was referred to the intensive care unit (ICU) because she needed respiratory and circulatory support such as a ventilator and catecholamine infusion. She experienced a refractory seizure and aspiration pneumonia was recognized by chest radiography. Although the fetus's heartbeat and movements were confirmed by ultrasonography, the mother's coma (Glasgow Coma Scale: E1VTM1) had continued after resuscitation. Computed tomography (CT) revealed hypoxic brain damage, which has a severe prognosis. During the patient's stay in the ICU, the psychiatrist, obstetrician, ethical nurse team, emergency clinicians, and patient's husband and sister discussed their concerns about the mother and fetus. Her husband wanted aggressive life support for the mother to increase the likelihood of fetal survival for as long as possible. During the discussion, ventilator and somatic life support were administered, and consent to emergency Cesarean section was obtained when the patient's condition worsened. No more concrete criteria for Cesarean section or treatment policy for this patient were available. While the mother had received by somatic support in ICU, the fetus's condition and heartbeat were confirmed by intermittent

trans-abdominal ultrasonography rather than cardiocography.

Three days after ICU admission (at 24 weeks and 1 day gestational age), the mother's condition deteriorated suddenly (Fig. 1). Pupillary reflex and spontaneous respiration disappeared, and pupils became dilated and fixed. Blood pressure fell to 80 mmHg even with rapid crystalloid infusion. Emergency CT revealed lethal edematous brain injury. Since catecholamine and ventilator support could not prevent the worsening vital signs, an emergency Cesarean section was performed to rescue the fetus's life (Fig. 2). A live 690-g male was delivered, with Apgar scores of 4 and 6 at 1 min and 10 min, respectively.

The mother died 45 days after the baby was delivered. Unfortunately, the baby presented serious neurological disorders.

Discussion

The meaning of the term "brain-death" has changed both clinically and ethically since it was first defined in 1959 [1]. Advances in critical care medicine and somatic life support have made it possible to maintain

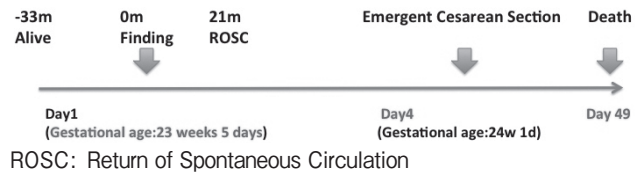


Fig. 1 Clinical course of mother

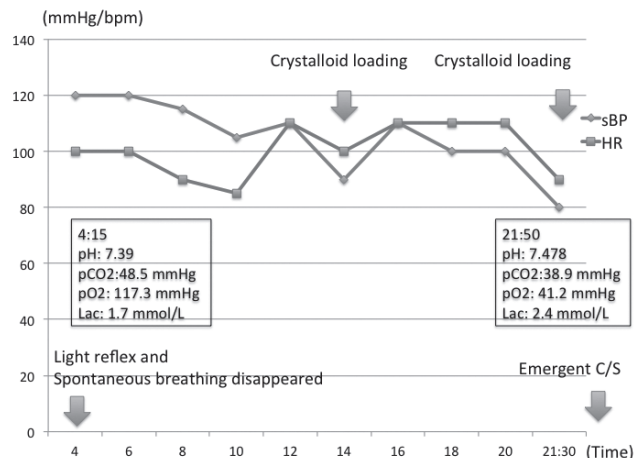


Fig. 2 The course at the day of emergent C/S (cesarean section).

not only a brain-dead maternal patient, but also her neonatal infant's life. As far as we know, more than 30 cases of pregnant brain-dead women, whose non-neurological somatic function was successfully maintained to facilitate further fetal development in the uterus, have been published between 1982 and 2015 [2]. Brain death in these cases was caused by traumatic severe injury, intracranial hemorrhage, meningitis, and other reasons.

Suddaby *et al.* investigated 5 cases of 252 brain-dead patients (2.8%) in pregnant woman ages 15 to 45 years [3]. The first case of extended somatic support leading to a successful birth was in 1982, with 3 weeks of treatment [4]. The longest somatic support period reported by Abhasna *et al.* was 110 days, which had started at a gestational age of 16 weeks and had a successful outcome [5]. Bernstein *et al.* reported a neonatal case in which somatic support started at 15 weeks of gestation [6]. Wood *et al.* and Slattery *et al.* reported that fetuses delivered at 22, 23, 24, and 25 weeks gestation have about a 1%, 11%, 26%, and 44% respective chance of survival and a 0.7%, 5%, 12%, and 23% respective likelihood of survival without handicaps at 30 months [7,8]. In our case, the neonate was born at 24 weeks and 1 day gestational age with a low Apgar score. Furthermore, the prematurely-delivered infant had a severe neurological disorder. Lack of blood flow from the placenta due to cardiac arrest in the mother's body, as well as prematurity, were assumed to be the relevant factors. The infant did not leave the hospital and did not know the outside world.

Cardiac arrest occurs in approximately 1 per 30,000 pregnancies [9]. The basic and advanced cardiac life support resuscitation algorithm is similar for pregnant patients, with a few important differences [10]. Although Advanced Life Support in Obstetrics recommends that clinicians decide to perform an emergency Cesarean section within 4 min when resuscitating pregnant women, it is hard to make this decision. This rule is usually adapted to a situation in which pregnant victims suffer cardiac arrest during vaginal delivery or in-hospital. Most pregnant patients who have no signs of life are treated by emergency clinicians before arriving at the hospital. This guideline has no meaning in the many cases of emergency medicine in which the time until arrival at the hospital exceeds 4 min.

In the ICU, prolonging life support is an important issue in order for the neonate to mature and grow in the uterus for as long as possible. A review of papers comparing pregnant patients in a persistent vegetable state and those with brain death focusing on neurological severity was published [11]. Hill reported a case of a pregnant woman with cardiac arrest, who gave birth to a neurologically normal neonate [12]. However, the criteria for termination of somatic support are not clear when the mother's vital signs suddenly become unstable. In our case, the obstetrician and emergency clinicians decided to perform a Cesarean section because catecholamine support could not stabilize her somatic organ dysfunction caused by worsening brain injury.

As a result, the fetus was delivered at 24 weeks and one day, and had a serious neurological disability with severe sequelae. Majid recommended a protocol for the management of maternal brain death [2]. He divided maternal brain-dead patients into 3 groups, high risk (gestational age ≤ 24 weeks), intermediate risk ($24 < \text{gestational age} < 28$ weeks), and low risk (gestational age ≥ 28 weeks). In high-risk patients, maternal serum screening, sonography to rule out congenital fetal abnormalities, amniocentesis, and administration of glucocorticoid after 24 weeks gestation should be considered, with emergency delivery performed as soon as possible when maternal vital signs deteriorate.

Organ donations from pregnant brain-dead women are justifiable if the mother expressed in writing prior to brain-death her intent to donate her organs. Extended somatic support and stabilization of a patient's vital signs with catecholamine and ventilator support is reasonable to preserve organs. According to a report by Esmailzadeh *et al.*, organs donated from 10 brain-dead mothers had superior rates of graft survival [2]. In their retrospective analysis of pregnant brain-dead organ donors, Suddaby *et al.* reported that out of 25 donated organs, (5 hearts, 5 livers, 10 kidneys, 5 pancreases), only one liver and one pancreas graft had poor outcomes [3].

Powner *et al.* reviewed cases of pregnant women who received extended somatic support after brain death until successful delivery of their infants [13]. In this article, special considerations for brain-dead patients focus on medication use, nutrition, hormone replacement, fetal monitoring, cardiovascular, respi-

ratory, and endocrine therapy, and ethical concerns. The authors concluded that preserving placental and uterine blood flow is the most critical priority during somatic support for fetal maturity.

In conclusion, according to previous case reports, gestational age is one of the most important factors in the decision-making process regarding management of a brain-dead pregnant woman. However, as the field of critical medicine and somatic support progresses, the gestational age when maternal brain death occurs is no longer the sole consideration in deciding whether to provide the woman somatic support. This development requires the next of kin, particularly the fetus's father, to be clearly informed of the risks of a severely premature infant, and the associated economic, physical and emotional costs of such a birth.

Although the number of brain-dead patients, including pregnant women, is increasing with developments in critical care medicine, difficult ethical issues with economic and medical dimensions have arisen. Establishment of an algorithm to address the medical and ethical issues associated with brain-dead patients, particularly those who are pregnant, is very much needed.

References

1. Mollaret P and Goulon M: Le coma depasse. *Rev Neurol (Paris)* (1959) 101: 3–15.
2. Esmaeilzadeh M, Dictus C, Kayvanpour E, Sedaghat-Hamedani F, Eichbaum M, Hofer S, Engelmann G, Fonouni H, Golriz M, Schmidt J, Unterberg A, Mehrabi A and Ahmadi R: One life ends, another begins: Management of a brain-dead pregnant mother—A systemic review—*BMC medicine* (2010) 8: 74.
3. Suddaby EC, Schaeffer MJ, Brigham LE and Shaver TR: Analysis of organ donors in the peripartum period. *J Transpl Coord* (1998) 8: 35–39.
4. Dillon WP, Lee RV, Tronolone MJ, Buckwald S and Foote RJ: Life support and maternal brain death during pregnancy. *JAMA* (1982) 248: 1089–1091.
5. Said A, Amer AJ, Masood UR, Dirar A and Faris C: A brain-dead pregnant woman with prolonged somatic support and successful neonatal outcome. *Int J Crit Illn Inj Sci* (2013) 3: 220–224.
6. Bernstein IM, Watson M, Simmons GM, Catalano PM, Davis G and Collins R: Maternal brain death and prolonged fetal survival. *Obstet Gynecol* (1989) 74: 434–437.
7. Wood NS, Marlow N, Costeloe K, Gibson AT and Wilkinson AR: Neurological and development disability after extremely preterm birth. EPI Cure Study Group. *N Engl J Med* (2000) 343: 278–284.
8. Slattery MM and Morison JJ: Preterm delivery. *Lancet* (2002) 360: 1489–1497.
9. Murphy N, Reed S, et al.; Maternal resuscitation and trauma; in *Advanced Life Support in Obstetrics (ALSO) Provider Course Syllabus*. Damos JR, Eisinger SH eds. Leawood, KS, American Academy of Family Physicians (2000) pp 1–25.
10. Dildy GA and Clark SL: Cardiac arrest during pregnancy. *Obstet Gynecol Clin North Am* (1995) 22: 303–314.
11. Bush MC, Nagy S, Berkowitz RL and Gaddipati: Pregnancy in a Persistent Vegetative State: Case Report, Comparison to Brain Death, and Review of the Literature. *Obstet Gynecol Surv* (2003) 58: 738–748.
12. Hill LM: Management of maternal vegetative state during pregnancy. *Mayo Clin Proc* (1985) 60: 469–472.
13. Powner DJ and Bernstein IM: Extended somatic support for pregnant women after brain death. *Crit Care Med* (2003) 31 1241–1249.