

Case Report

A Case of *Streptobacillus moniliformis* Infection with Cutaneous Leukocytoclastic Vasculitis

Yoshio Kawakami^{a*}, Takashi Katayama^b, Masayuki Kishida^b,
Wakako Oda^c, and Yasuro Inoue^d

Departments of ^aDermatology, ^bGeneral Medicine, ^cPathology and ^dClinical Laboratory,
Okayama City Hospital, Okayama 700-8557, Japan

A 71-year-old man presented with a high fever, polyarthralgia, petechiae and palpable purpura accompanied by livedoid change on his legs and feet. Histopathological findings of the purpura revealed perivascular infiltration of neutrophils, mononuclear cells, and nuclear debris, and extravasation of red cells mainly in the upper dermis: all signs consistent with leukocytoclastic vasculitis. Small vessel thrombi, which are characteristic features of septic vasculopathy, were also observed. Direct immunofluorescence showed negative results. Blood culture revealed the growth of gram-negative bacilli. Subsequently, 16S rRNA sequencing of DNA confirmed the organism as *Streptobacillus moniliformis*, which is the causative pathogen of rat-bite fever. He had frequently encountered wild rats in his house although there was no evidence of rat bite on his body. Empiric therapy with intravenous administration of ceftriaxone in combination with azithromycin hydrate led to a prompt resolution of the symptoms. Precise history-taking related to contact with rats and detection of skin eruptions suggestive of leukocytoclastic vasculitis on the extremities, especially on the feet, can be clues to *Streptobacillus moniliformis* infection. Familiarity with its cutaneous features is important for early diagnosis; the evidence herein may also help in understanding its underlying pathogenesis.

Key words: livedo, vasculitis, rat bite fever, polyarteritis nodosa, septic vasculopathy

Streptobacillus moniliformis is a pleomorphic gram-negative bacillus that colonizes the commensal flora of the upper respiratory tract of rats including pet rats [1,2]. *S. moniliformis* infection, commonly called “rat-bite fever”, is characterized by fever, rash and polyarthralgia. Despite its name, nearly 30% of patients with *S. moniliformis* infection report no recognizable rat bite [1]. In such situations, cutaneous manifestations may be the most important clues to its diagnosis. However, cutaneous and dermato-histopathological findings of *S. moniliformis* infection

are not well-characterized. Herein, we report a case of *S. moniliformis* infection without a history of rat bite. Cutaneous findings of the legs demonstrated livedoid change, petechiae and palpable purpura, histopathologically confirmed as leukocytoclastic vasculitis. There were also small vessel thrombi that were characteristic for septic vasculopathy. We discuss the importance of considering this bacterial infection in cutaneous vasculitis with systemic symptoms.

Case Report

A 71-year-old Japanese man was admitted to our hospital with a 6-day history of high fever and arthralgia. His medical history was unremarkable except for deafness since childhood. He had no pets and no evident history of rat bite although he had frequently encountered wild rats in his house. Clinical examination revealed a high fever of 39.9 °C, elevated heart rate of 133 beats/min, elevated respiratory rate of 30 breaths/min, and polyarthralgia involving sternoclavicular joints, right wrist joint, and metacarpophalangeal joints of his right index and middle fingers. Cutaneous findings showed palpable purpura and petechiae on the lower legs including the dorsum of the feet, accompanied by livedoid change on the lower legs and thighs (Fig. 1A,B). There was no obvious skin lesion suggestive of rat bite. Laboratory investigations revealed elevated levels of white blood cells (WBC), 16,480/ μ l (segmented neutrophils, 86.5%; banded neutrophils, 5.5%; eosinophils, 0%; basophils, 0%; monocytes, 4.5%; lymphocytes, 3.0%); C-reactive protein (CRP), 30.04 mg/dl; erythrocyte sedimentation rate (ESR), 41 mm/h; soluble interleukin-2 receptor (sIL-2R), 2,590 U/ml; procalcitonin, 7.45 ng/ml; fibrinogen, 642 mg/dl, d-dimer, 5.7 μ g/ml and fibrin degradation products, 9.4 μ g/ml. He had slightly elevated serum levels of blood urea nitrogen (BUN) and creatine, at 40 mg/dl and 1.16 mg/dl, respectively, as well as proteinuria and

hematuria. Measurements of arterial blood gases while the patient was breathing ambient air showed a decreased arterial carbon dioxide tension [PaCO₂] of 28.8 mmHg and increased arterial oxygen tension [PaO₂] of 122.0 mmHg. Prothrombin time (PT), activated partial thromboplastin time (aPTT), and platelet count were all within normal ranges. Serological findings regarding autoimmune disorders including antinuclear antibodies (ANA), anti-double-stranded DNA, perinuclear anti-neutrophil cytoplasmic antibodies (pANCA), cytoplasmic ANCA (cANCA), anti-ribonucleoprotein antibodies, rheumatoid factor, Immunoglobulin (Ig) G, IgA, IgM, C3 and C4 were all within normal limits. Hepatitis B virus antigen and hepatitis C virus antibody were negative. A computed tomography scan of the chest, abdomen, and pelvis showed no evidence of infectious origin and there was no evidence of infective endocarditis by echocardiography.

Histopathological findings of a biopsied specimen from a purpuric lesion on the lower leg demonstrated perivascular infiltration of neutrophils, mononuclear cells and nuclear debris, and extravasation of red cells mainly in the upper dermis, all signs consistent with leukocytoclastic vasculitis, as well as occlusion of small dermal vessels by fibrin thrombi (Fig. 2), which stained blue with phosphotungstic acid hematoxylin (PTAH) (Fig. 3). Gram staining showed no organisms and direct immunofluorescence showed no deposits of IgG, A, or M, or of C3.

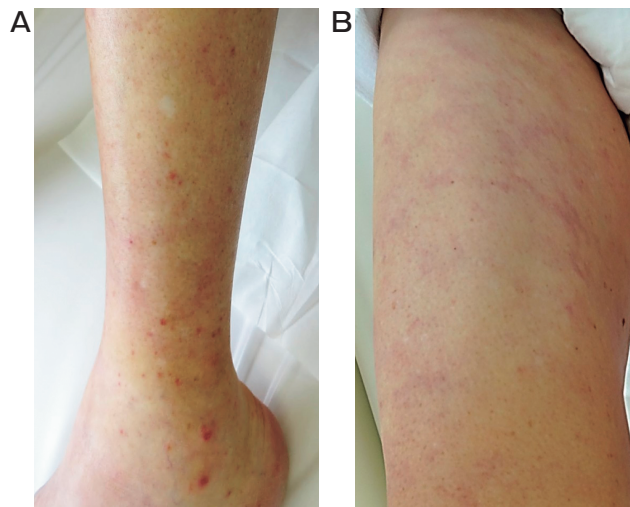


Fig. 1 (A) Petechiae, palpable purpura, and livedoid change on the left lower leg; (B) Livedoid change on the right thigh.

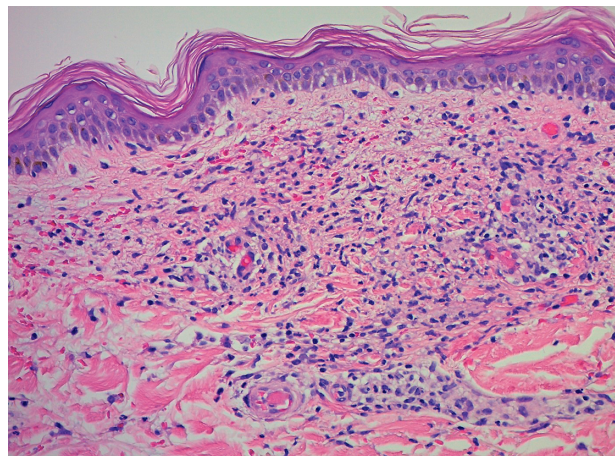


Fig. 2 Inflamed perivascular tissue on the upper and middle dermis contained neutrophils, nuclear debris and mononuclear cells, and showed extravasation of red blood cells and small vessel thrombi (hematoxylin-eosin)

According to a tentative diagnosis of bacterial infection based on acute onset of fever and elevated levels of WBC, CRP, and ESR, empiric therapy with intravenous administrations of ceftriaxone (2 g/day for 7 days) and azithromycin hydrate (500 mg/day for 5 days) was started. Within one week, the fever, polyarthralgia and skin lesions disappeared and the renal function tests normalized. Oral administration of levofloxacin (500 mg/day for 10 days) was subsequently administered. After discharge, oral cefcapene pivoxil hydrochloride hydrate (300 mg/day) was administered for 2 weeks, during which time no relapse occurred. Therapy was then discontinued while the patient was watched closely.

Blood culture taken in the first day of his admission revealed a growth of gram-negative bacilli. Four weeks after the initial therapy with ceftriaxone and azithromycin hydrate, the diagnosis of *Streptobacillus moniliformis* infection was confirmed by 16S rRNA PCR assays [3], which was tested by BML general laboratory in Japan. Briefly, primers F27 (AGAGTTTGATCMTGGCTCAG) and 1392R (ACGGGCGGTGTGTRC) were used to amplify a 16S PCR product of approximately 1.3 kb. Comparison with sequences deposited in the EMBL-GenBank database showed that a 1,288-bp sequence shared 100% homology with the 16S rRNA sequence of the *S. moniliformis* type strain (DSM12112T; EMBL-GenBank accession no. NR_074449). Although the patient's clinical symptoms were completely resolved

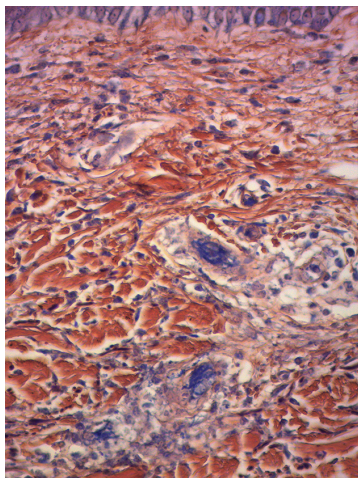


Fig. 3 Occlusion of small dermal vessels by fibrin thrombi, which stained blue with a fibrillar pattern by phosphotungstic acid hematoxylin (PTAH) staining.

when the diagnosis of *S. moniliformis* infection was made, we finally administered amoxicillin hydrate (750 mg/day for 5 days) as an extra precaution. We instructed him to rid his house of wild rats. Twelve months after his initial presentation, there has been no recurrence of the symptoms.

Discussion

S. moniliformis infection is more common in North America than Asia [1], but its geographic distribution is worldwide including Japan [4]. *S. moniliformis* infection is characterized by fever, polyarthralgia, and skin eruption with an incubation period ranging from 3 days to 3 weeks. It carries a mortality rate of 10%, and has complications, such as endocarditis, myocarditis, meningitis, nephritis, amnionitis, and pneumonia [1]. Therefore, early recognition of the disease is important.

Cutaneous findings of *S. moniliformis* infection are various, such as infiltrated erythema on the legs and soles of the feet [4], hemorrhagic pustule on the hands, elbows and heels [5], and petechial and purpuric lesions on the foot [1].

There have been 4 case reports, including our case, describing leukocytoclastic vasculitis associated with *S. moniliformis* infection (Table 1) [6–8]. The bacteria were isolated from the blood in 3 cases, and from a pustule in one case. Although all of the subjects had possible contact with rats, only one had a history of rat bite. Our case might have been unknowingly exposed to excreta or saliva containing *S. moniliformis* in his house, or he might have ingested food contaminated with *S. moniliformis* because he had encountered wild rats in his house. Notably, all cases had fever, polyarthralgia and skin eruptions on the feet. All were cured without complication under appropriate antimicrobial therapies, suggesting that cutaneous lesions are an early event. Whether leukocytoclastic vasculitis associated with *S. moniliformis* infection is caused by direct infection or indirect immune-mediated mechanisms remains unknown. One case had positive ANA and transient cryoglobulinemia [8], whereas our case showed negative results with regard to autoimmune disorders including direct immunofluorescence. To our knowledge, this is the first report investigating direct immunofluorescence of a skin lesion in *S. moniliformis* infection.

Table 1 Characteristics of patients with leukocytoclastic vasculitis associated with *S. moniliformis* infection

Case/[reference]	1[6]	2[7]	3[8]	4[our case]
Age/gender	39/ male	14/ male	26/ female	71/ male
Rat bite/possible exposure	Right thumb by pet gerbil /	None / Pet rats	None / Pet rats	None / Wild rats
Isolation of the bacteria	Blood	Pustule	Blood	Blood
Clinical symptoms and laboratory abnormalities	Fever (39 °C), polyarthralgia	Fever, polyarthralgia	Fever (38.8 °C), headache, polyarthralgia, ANA positive, cryoglobulinemia	Fever (39.9 °C), polyarthralgia, impaired renal function tests
Distribution of the exanthema	Limbs including palms and soles	Lower limbs including soles	Hands and feet	Legs and dorsum of feet
Characteristics of the skin rash	Maculopapules, petechiae, and pustules	Petechial-purpuric rash and pustules	Erythematous to dusky purple purple papules and pustules	Petechiae, palpable pupura, and livedoid changes
Treatment	Penicillin	Penicillin	Penicillin	Mainly ceftriaxone and azithromycin hydrate
Outcome	Cured	Cured	Cured	Cured

The dermato-histopathological findings of our case also revealed small vessel thrombi that were characteristic for septic vasculopathy. Delgado-Jiménez *et al.* [9] investigated 32 patients with septic vasculopathy, which is defined by the presence of (i) bacterial sepsis (systemic inflammatory response syndrome presenting two or more of the following symptoms: body temperature $>38\text{ }^{\circ}\text{C}$ or $<36\text{ }^{\circ}\text{C}$, heart rate of >90 beats/min, respiratory rate of >20 breaths/min or arterial carbon dioxide tension [PaCO₂] of <32 mmHg, leukocytes $>12,000/\text{l}$ or $<4,000/\text{l}$, or $>10\%$ left shift and positive blood cultures); (ii) skin lesions consistent with vasculitis; and (iii) biopsy-proven vascular changes associated with sepsis (defined as the presence of thrombi and/or fibrinoid necrosis). *Neisseria meningitidis* was the most common causable agent although several microorganisms were identified. The most common cutaneous manifestations were purpuric lesions and petechiae. Skin biopsies showed intravascular thrombi in 100% of cases and bacteria within the vascular wall in 21.9% of cases. Cutaneous lesions were disseminated in 62.5% of cases and localized in 37.5% of cases. Interestingly, clinical presentations did not depend on the microorganism. Our case fulfilled the criteria of septic vasculopathy,

and characteristic intravascular thrombi were also present. There has been no clinical report describing septic vasculopathy as associated with *S. moniliformis* infection. The presence of intravascular thrombi has not been mentioned in previous case reports of leukocytoclastic vasculitis associated with *S. moniliformis* infection. Although the skin changes of our case might be nonspecific septic vasculopathy, its distribution on the legs and dorsum of the feet seems to be a rather characteristic feature of *S. moniliformis* infection.

Because of the lack of recognizable history of rat bite in our case, initial evaluation was difficult. The differential diagnosis included vasculitis associated with autoimmune diseases, such as polyarteritis nodosa. One case report described a 9-year-old male who suffered from fatal infection with *S. moniliformis* displaying polyarteritis nodosa involving all organs except the skin, lung, and spleen [10]. However, it is important to consider that the first step to the clinical approach of cutaneous vasculitis is to rule out infection-induced vasculitis because 22% of all cases of cutaneous vasculitis have been reported to be associated with infection, such as gonococci, meningococci, pseudomonads, staphylococci, streptococci and certain rickettsial infections [11,12]. High fever, arthritis,

elevated ESR (> 40 mm/h), abnormal blood count, and tissue neutrophilia are helpful clues to infections associated with cutaneous vasculitis [11]. In addition, our case displayed elevated serum level of sIL-2R, suggesting the activation of T-cells and/or B-cells by *S. moniliformis*. An elevated serum level of sIL-2R associated with *S. moniliformis* infection has never been reported. Since serum sIL-2R is elevated in various kinds of diseases including hematological diseases, autoimmune diseases, infectious diseases, and non-hematological tumors [13], it might merely reflect strong, non-specific inflammation.

Penicillin is commonly used to treat *S. moniliformis* infection [1]; however, ceftriaxone, which has a broader spectrum of activity, has also shown sensitivity [1] and clinical efficacy [5] against this bacterium. Therefore, ceftriaxone might be used as empiric therapy, especially when the exact pathogen cannot be deduced from clinical symptoms.

In conclusion, we report a case of *S. moniliformis* infection associated with leukocytoclastic vasculitis without a history of rat bite. Precise history-taking related to contact with rats and detection of skin eruptions suspicious of leukocytoclastic vasculitis on the extremities, especially on the feet, can be clues to diagnosis of this infection. It is important to characterize its cutaneous features not only for diagnosis but also for better understanding of its underlying pathogenesis.

References

1. Elliott SP: Rat bite fever and *Streptobacillus moniliformis*. *Clin Microbiol Rev* (2007) 20: 13–22.
2. Hayashimoto N, Yoshida H, Goto K and Takamura A: Isolation of *Streptobacillus moniliformis* from a pet rat. *J Vet Med Sci* (2008) 70: 493–495.
3. Addidle M, Pynn J, Grimwade K and Giola M: Epidural abscess caused by *Streptobacillus moniliformis*. *J Clin Microbiol* (2012) 50: 3122–3124.
4. Nakagomi D, Deguchi N, Yagasaki A, Harada K, Shibagaki N, Kimura M, Imaoka K and Shimada S: Rat-bite fever identified by polymerase chain reaction detection of *Streptobacillus moniliformis* DNA. *J Dermatol* (2008) 35: 667–670.
5. Cunningham BB, Paller AS and Katz BZ: Rat bite fever in a pet lover. *J Am Acad Dermatol* (1998) 38: 330–332.
6. Wilkins EG, Millar JG, Cockcroft PM and Okubadejo OA: Rat-bite fever in a gerbil breeder. *J Infect* (1988) 16: 177–180.
7. Albedwawi S, LeBlanc C, Shaw A and Slinger RW: A teenager with fever, rash and arthritis. *CMAJ* (2006) 175: 354.
8. Tandon R, Lee M, Curran E, Demierre MF and Sulis CA: A 26-year-old woman with a rash on her extremities. *Clin Infect Dis* (2006) 43: 1585–1586.
9. Delgado-Jiménez Y, Fraga J, Requena C, Requena L, Aragües M, Fernandez Herrera J and Garcia Diez A: Acute bacterial septic vasculopathy. *Int J Dermatol* (2013) 52: 1071–1080.
10. Prouty M and Schafer EL: Periarthritis nodosa associated with rat-bite fever due to *streptobacillus moniliformis* (erythema arthriticum epidemicum). *J Pediatr* (1950) 36: 605–613.
11. Chen KR and Carlson JA: Clinical approach to cutaneous vasculitis. *Am J Clin Dermatol* (2008) 9: 71–92.
12. Fiorentino DF: Cutaneous vasculitis. *J Am Acad Dermatol* (2003) 48: 311–340.
13. Tsujioka T, Kishimoto M, Kondo T, Matsuoka A, Tasaka T, Sugihara T, Wada H and Tohyama K: The impact of serum soluble interleukin-2 receptor levels on the diagnosis of malignant lymphoma. *Kawasaki Medical Journal* (2011) 37: 19–27.