

OBJECTIVES

The aim of this work is to collect all the information that is known about inflammatory bowel disease, or IBD, based on the available literature, emphasizing the importance of vomiting as an indicator of this disease in cats, analyzing the obscure points and propose them as starting points for future studies.

INTRODUCTION

Feline Inflammatory bowel disease, or IBD, is a chronic enteropathy that occurs in adult cats. It is a disease characterized nonspecific gastrointestinal signs such as vomiting, diarrhea, anorexia and weight loss, which can be permanent or recurrent. This disease is immunologically regulated. Feline IBD is compared to canine IBD and Crohn's disease in humans (Zoran, 2010, Jergens, 2012).

HAIRBALLS ARE VOMIT

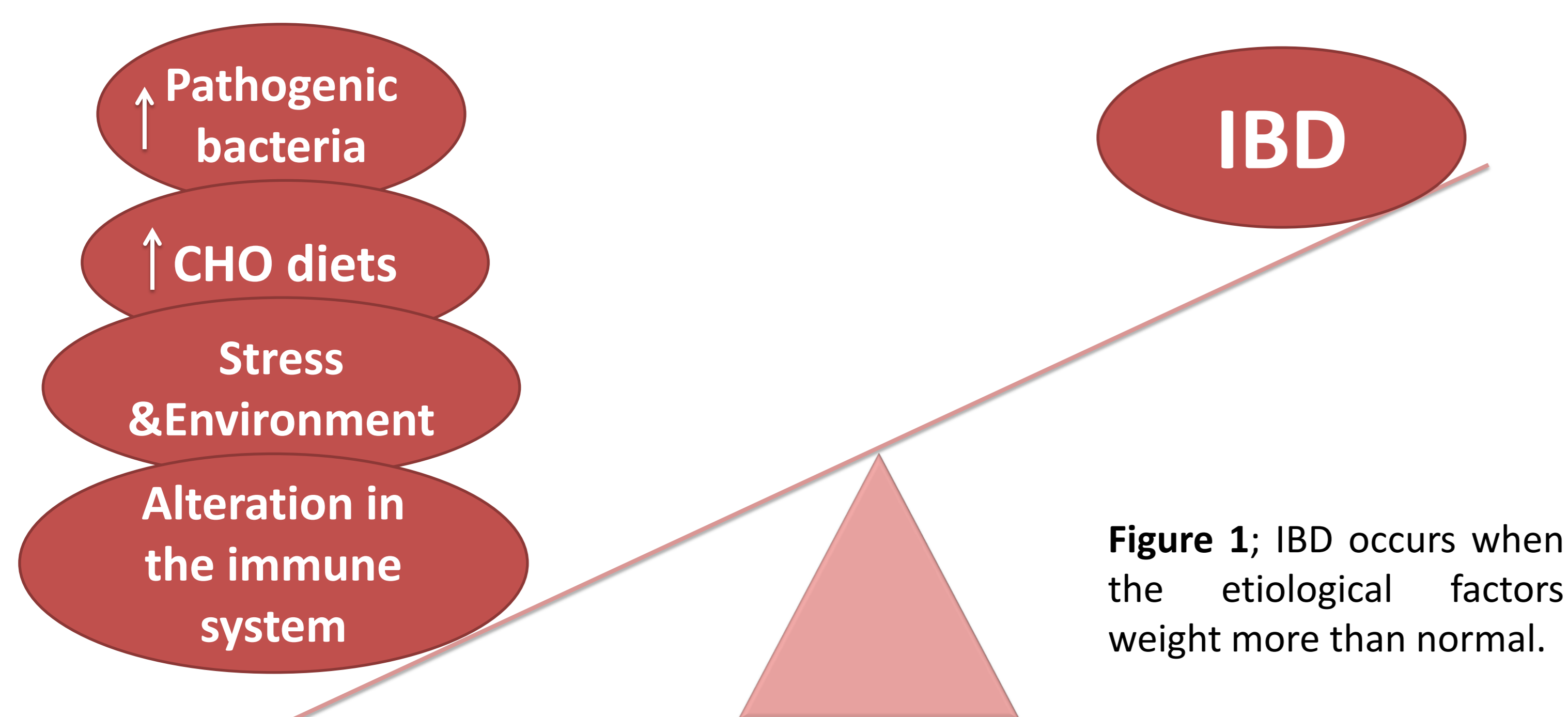
It is time to change owner's mind. Cats are prepared to ingest the equivalent of all their hair every month, so hairballs wouldn't be part of their lives (St. Denis, 2016).

VOMITING MORE THAN TWICE A MONTH IS NOT NORMAL

In a study made by Norsworthy et al. (2013) based on 100 cats with signs of diarrhea, loss of weight, vomiting and showing ecocardiographic signs of thickened muscularis propria, they only got normal results in one biopsy of the intestinal wall. The other cats were diagnosed of IBD or lymphoma, so these results showed the importance of investigating the underlying cause of vomiting, because these two diseases are very frequent and harmful in cats.

ETIOLOGY

IBD is thought to be due to a loss of the dynamic balance between factors that activate the immune system that is associated with the intestinal mucosa, such as food antigens, enteric flora and host defenses, that keep mucosal integrity and modulate inflammation in the intestines (Jergens, 2012).



DIAGNOSIS

In the process to get the diagnosis of this enteropathy it is important to exclude among the diseases that mimic IBD signs. To get the definitive diagnosis of IBD is essential to perform mucosal biopsies from various parts of the gastrointestinal tract, in order to rule out lymphoma, classify the type of IBD based on the predominant infiltrating cell population and indicate the degree of severity of the disease (Janeczko et al., 2008; Jergens, 2012).

TREATMENT

Therapy for IBD is tailored to each case and it is important to take into account the severity of the disease. Depending on whether it is more or less severe, the treatment will begin more or less aggressively (Trepanier, 2009, Jergens, 2012).

Elimination diet during 4-6 weeks

- New protein source
- Hydrolyzed diet

Metronidazole (or Metronidazole Benzoate):

15mg/kg PO every 24hours, for 14days.

Prednisolone:

2mg/kg PO every 24 hours, for 2 weeks. After this time, reduce the dose 25% every 2 weeks.

Chlorambucil:

2mg/cat PO every 72 hours

Cyclosporine:

5mg/kg PO every 24 hours during 21 days.

Supplement with Cobalamin:

- 250mg/week SC for 6 weeks
- 250mg/month SC long-term

Probiotics & Prebiotic

CONCLUSION

Feline IBD is a very unknown and misunderstood disease. It is important to pay attention to cats that use to vomit frequently, provided that vomits can be a sign of IBD or other diseases.

This review has reported the hypothesis that have been confirmed but there are some hypothesis, about the causes of IBD mainly, that still remain to be further studied as:

1. Whether there is a genetic origin in the alteration of the immune system associated with the intestinal mucosa.
2. Whether the diet can have an important role to prevent feline IBD, as it has to rule out some mimic diseases.
3. Whether the stress and the environment can be a cause of IBD on their own.
4. Whether IBD can progress to a lymphoma as it has been seen in other organs and tissues.
5. Which are the cytokines and other molecules that are involved in the process, and if some of them are exclusive of IBD, so that it would allow to look for more focused drugs and more precise and objective diagnosis.

BIBLIOGRAPHY

- Jergens, A. E. (2012). Feline idiopathic inflammatory bowel disease: what we know and what remains to be unraveled. *J Feline Med Surg*, 14(7), 445-458.
- Trepanier, L. (2009). Idiopathic inflammatory bowel disease in cats. Rational treatment selection. *J Feline Med Surg*, 11(1), 32-38.
- St. Denis, K. (2016). The Vomiting Cat: From Diet to Dexamethasone - Making Therapeutic Decisions. Consulted on April 26th 2016, available from: <http://www.vin.com/members/cms/project/defaultadv1.aspx?pld=14827>
- Zoran, D. L. (2010). Feline IBD: The Good (Diets), the Bad (Bacteria), and the Ugly (Diagnosis). In *Western Vet Conference*. Las Vegas, Nevada.