

Electronic Letters on Computer Vision and Image Analysis 15(2):7-9, 2016

Automated Analysis of Orthopaedic X-ray Images based on Digital-Geometric Techniques

Oishila Bandyopadhyay

Advanced Computing and Microelectronics Unit, Indian Statistical Institute, 203, B. T. Road, Kolkata, India

Advisor/s: Bhargab B. Bhattacharya and Arindam Biswas

*Date and location of PhD thesis defense: 15 June 2016, Department of Information Technology
Indian Institute of Engineering Science and Technology*

Received 31st July 2016; accepted 1st August 2016

Abstract

This thesis reports several methods for automated analysis and interpretation of bone X-ray images. Automatic segmentation of the bone part in a digital X-ray image is a challenging problem because of its low contrast against the surrounding flesh. In this thesis, we propose a fully automated X-ray image segmentation technique, which is based on a variant of entropy measure of the image. We have also analyzed the geometric information embedded in the long-bone contour image to identify the presence of abnormalities in the bone and perform fracture detection, fracture classification, and bone cancer diagnosis.

Key Words: X-ray image, Segmentation, Entropy, Digital Straight line segment, Concavity index, Runs-test, Support vector machine

1 Introduction

X-ray imaging is used as the basic diagnostic tool for the low-cost initial assessment of orthopaedic problems in developing countries. The manual analysis of X-ray images and diagnosis of the underlying orthopaedic problem may not be always possible due to non-availability of specialist doctors and trained para-medical personnel in remote areas. In such scenarios, development of an efficient computer-aided diagnostic system (CAD) will be useful for the analysis and interpretation of X-ray images [5], [6]. This work focuses on several issues that arise in automated X-ray image analysis, and proposes solutions that lead to the development of an efficient computer-aided diagnostic system.

2 Automated X-ray Image Analysis

An automated X-ray image analysis tool needs an efficient segmentation technique to separate the bone region from surrounding tissues and muscles [10]. The segmented bone image can then be used for the analysis and subsequent identification of orthopaedic disorders such as bone fracture and bone diseases (Fig. 1).

Correspondence to: oishila@gmail.com

Recommended for acceptance by David Vázquez Bértudez

DOI <http://dx.doi.org/10.5565/rev/elcvia.970>

ELCVIA ISSN:1577-5097

Published by Computer Vision Center / Universitat Autònoma de Barcelona, Barcelona, Spain

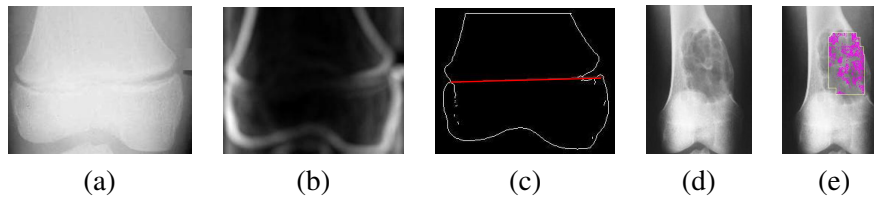


Figure 1: (a) Input *X*-ray, (b) Segmented bone, (c) Bone contour with fracture line (classification: region - distal, type - simple, sub-type- extra-articular), (d) Input *X*-ray, (e) Cancer affected region marked (diagnosis: stage - 2A, grade - 2, pattern - geographic)

2.1 Bone-Image Segmentation

In *X*-ray images, the bone boundary, which separates the bone region from flesh, is found to be diffused and fragmented, resulting in poor image contrast and ill-defined contours. In our work, we have proposed a segmentation approach based on entropy measure [2] to segment the bone region from its surrounding flesh. Main advantage of this generalized method is that it can be used to segment *X*-ray images from different regions of human body.

2.2 Bone Contour Generation

In this work, we have proposed a new technique of bone-contour generation by integrating an entropy-based segmentation method with adaptive thresholding-based contour tracing. The novelty of the technique lies in the fact that it rectifies the false discontinuities of bone contour while retaining the real (uneven) discontinuities caused by fractures or other abnormalities [2].

2.3 Long-Bone Fracture Detection

Automated fracture detection is an essential part of a computer-aided tele-medicine system. In this thesis, we have proposed a unified technique for the detection and evaluation of orthopaedic fractures in long-bone digital *X*-ray image. Several concepts from digital geometry such as relaxed digital straight line segments (RDSS) and concavity index are utilized to correct contour imperfections, and to detect fracture locations and type [1].

2.4 Long-Bone Fracture Classification

This thesis proposes a novel approach to automated classification of long-bone fractures based on the analysis of an input *X*-ray image. The method identifies the fracture-points by analysing the input *X*-ray image, determine an equivalent set of geometric features in tune with the Müller-AO clinical classification of fractures [7], and identify the fracture-type. The decision procedure makes use of certain geometric properties of digital curves such as RDSS, arcs, discrete curvature, and concavity index [3].

2.5 Bone Cancer Diagnosis and Stage Detection

In this thesis, we propose a novel technique of automated bone cancer detection in long-bones based on *X*-ray image analysis. We use certain statistical analysis (runs-test) of bone intensity variation to localize the cancer affected region and apply support vector machine (SVM) to classify the healthy and cancer-affected bones and stage and grade of the disease on the basis of some selected features [4].

3 Conclusion

This thesis presents studies on various components of automated *X*-ray image analysis. The techniques proposed in different chapters successfully integrate conventional image analysis algorithms with some novel digital-geometric concepts such as RDSS, relative concavity, and discrete curvature are also proposed to address the problems that arise during automated *X*-ray image analysis for diagnostic purposes. The work reported in this thesis (<https://drive.google.com/open?id=0B5M6Y0ylgFnSNUVKV05zVl82dHM>) suggests that digital-geometric concepts can be efficiently utilized to automate medical image analysis and subsequent diagnosis.

References

- [1] O. Bandyopadhyay, A. Biswas, B. B. Bhattacharya, "Long-bone Fracture Detection in Digital X-ray Images Based on Digital-Geometric Techniques", *Computer Methods and Programs in Biomedicine* 123:2-14, 2016. doi:10.1016/j.cmpb.2015.09.013.
- [2] O. Bandyopadhyay, B. Chanda, B. B. Bhattacharya, "Automatic Segmentation of Bones in X-ray Images based on Entropy Measure", *International Journal of Image and Graphics* 16(1):165000-1-165000-32, 2016. doi:10.1142/s0219467816500017.
- [3] O. Bandyopadhyay, A. Biswas, B. B. Bhattacharya, "Classification of Long-Bone Fractures based on Digital-Geometric Analysis of X-ray images", *Pattern Recognition and Image Analysis: Advances in Mathematical Theory and Applications* (accepted in June 2016).
- [4] O. Bandyopadhyay, A. Biswas, B. B. Bhattacharya, "Automated Diagnosis of Bone Cancer and Assessment of Severity Based on X-ray Image Analysis", *Technical Report Published by Indian Institute of Engineering Science and Technology, Shibpur, West Bengal, India*, June 2016.
- [5] M. L. Giger, M. Karssemeijer, S. G. Armato, "Computer-Aided Diagnosis in Medical Imaging", *IEEE Transactions on Medical Imaging* 20(12):1205-1208, 2001.
- [6] Q. Li, R. M. Nishikawa, "Computer Aided Detection and Diagnosis in Medical Imaging", *CRC Press* 2015. doi:10.1201/b18191.
- [7] M. E. Muller, P. Koch, S. Nazarian, J. Schatzker, "The Comprehensive Classification of Fractures of Long Bones", *Springer-Verlag* 1990. doi:10.1007/978-3-642-61261-9.
- [8] R. Klette and A. Rosenfeld, "Digital Geometry: Geometric Methods for Digital Picture Analysis", *Elsevier* 2007.
- [9] S. Pal, R. Dutta, P. Bhowmick, "Circular Arc Segmentation by Curvature Estimation and Geometric Validation", *International Journal of Image and Graphics* 12(4):1250024-1-1250024-24, 2012. doi:10.1142/s0219467812500246.
- [10] Z. Ma, J. M. Tavares, R. N. Jorge, T. Mascarenhas, "A review of algorithms for medical image segmentation and their applications to the female pelvic cavity", *Computer Methods in Biomedicine and Biomedical Engineering*, 13(2):235-246, 2010. doi:10.1080/10255840903131878.
- [11] J. Hao, Y. Shen, H. Xu, J. Zou, "A region entropy based objective evaluation method for image segmentation", *IEEE Proc. of International Conference on Instrumentation and Measurement Technology*, Singapore, 1:373-377, 2009. doi:10.1109/imtc.2009.5168478.
- [12] A. Gaidel and A. Khramov, "Application of texture analysis for automated osteoporosis diagnostics by plain hip radiography", *Pattern Recognition and Image Analysis*, 25(2):301-305, 2015. doi:10.1134/s1054661815020108.
- [13] D. Sen and S. K. Pal, "Gradient histogram thresholding in a region of interest for edge detection", *Image and Vision Computing*, 28:677-695, 2010. doi:10.1016/j.imavis.2009.10.010.
- [14] J. Canny, "A computational approach to edge detection", *IEEE Transactions on Pattern Analysis and Machine Intelligence*, 8(6):679-698, 1986. doi:10.1109/tpami.1986.4767851.