

EFFECT OF THE ACIDOSIS ON THE DEGENERATING MESONEPHRIC VASCULAR SYSTEM OF THE CHICK EMBRYOS

Marc NAVARRO, Ana CARRETERO, Francisco Javier PEREZ-APARICIO, Margarita ARBOIX*, Jesús RUBERTE

*Department of Anatomy and Embryology. * Department of Pharmacology. Veterinary Faculty. Autonomous University of Barcelona. 08193-Bellaterra, Barcelona. SPAIN*

The mesonephros of the chick embryo is a temporary organ that offers the possibility to study both vascular growth and degeneration in the same model under physiological conditions. We know from previous studies that the mesonephros at the stage 41 H-H (Hamburger and Hamilton, 1951) presents a severe degeneration (Carretero et al., 1993; 1995; 1996). The aim of this work is to study the effect of the acidosis on the degenerating mesonephric vascular system of the chick embryos.

Thirty embryos of commercially bred chicken (*Gallus domesticus*; White Leghorn) were used in this study. Eggs were divided into two groups: 15 embryos were injected into the primitive intestine with 10 ml of HCl 0.1 N, using a Hamilton microliter syringe through a window in the shell, at 56-60 hours of incubation (stage 16-17 H-H); and 15 embryos were used as controls. The windows were sealed and the eggs were reincubated until 15.5 days (stage 41 H-H), when the mesonephric degeneration is severe.

Embryos were removed from the egg-shell and injected manually through the umbilical vessels with Mercocox® diluted with methyl methacrylate (Carretero et al., 1993). Subsequently, the mesonephros were removed and corroded with KOH. The resulting casts were mounted in stubs, sputtered with gold and observed in a Hitachi S570 scanning electron microscopy.

Observation of the casts showed that the main effects of the acidosis on the mesonephric vascular system were the loss of the normal venous pattern and an increased angiogenesis.

In some cases, the changes even consisted of loss of the topography and normal disposition of great vessels such as the subcardinal veins or the cava vein. Figure 1 shows the normal vascular pattern of a control embryo, in which several subcardinal veins of each mesonephros drain into the cava vein. On the other hand, the anomalous venous pattern of a mesonephros treated with HCl 0.1 N (Fig. 2), showed different disposition and diameters of the subcardinal veins and loss of the topography of the cava vein.

A high vascular density of certain areas of the mesonephric plexus of treated embryos could be observed (Fig. 3), when compared with that of control embryos (Fig. 4), demonstrating an increased angiogenesis induced by the acidosis. These areas showed enlarged vessels similar to vascular lacunae, where many angiogenic structures, such as angiogenic holes, could be noticed (Fig. 5). The aspect of these vascular lacunae demonstrated that they were not extravasations of the injected resin, since they showed blood cell imprints on their surface (Fig. 6).


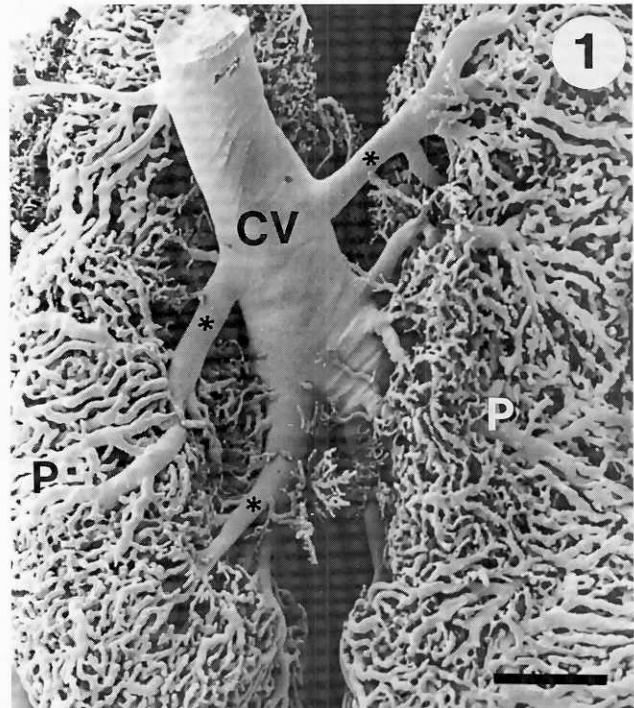


Figure 1. Corrosion cast of the mesonephros of a control chick embryo. Ventral view. CV: Cava vein. P: Mesonephric plexus. (*) Subcardinal veins. Bar = 0.7 mm.

Figure 2. Corrosion cast of the mesonephros of a HCl treated chick embryo. Ventral view. Notice the anomalous pattern of the subcardinal veins (*) and cava vein (CV), as well as the high density vascular areas in the mesonephric plexus (arrow). Bar = 0.6 mm.

New interest about vasculogenesis and angiogenesis has arisen due to their close relation to tumoral neovascularization. It is well known that both hypoxia and anemia are potent "in vivo" and "in vitro" inducers of several angiogenic factors, such as the vascular endothelial growth factor (VEGF) (Plate et al., 1992). These factors are inducible in human glioma cells, mouse fibroblast L cells, rat cardiac cells, human mammary fibroblast, etc. Moreover, these factors are expressed during vasculogenesis and vascular differentiation in the quail embryo (Flamme et al., 1995). These authors have observed an increase in vascular density of the avian limb bud, similar to that observed by us in the mesonephros.

In our study, we hypothesized that the increased angiogenesis could be due to the low pH produced by the HCl injection, inducing a similar mechanism as that produced by the pH decrease in hypoxia or anemia.

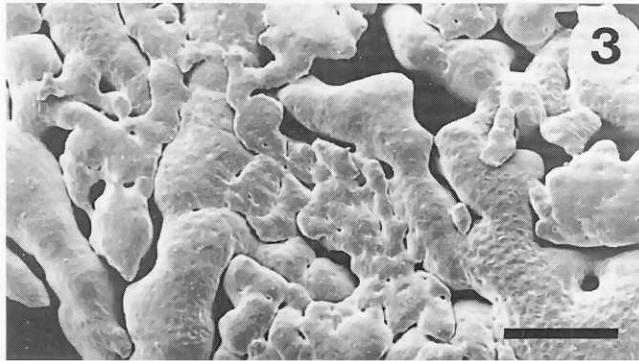


Figure 3. Overview of the mesonephric plexus of a HCl treated chick embryo. Note the enlarged vessels that determine an increase of the vascular density. Bar = 64 μ m.

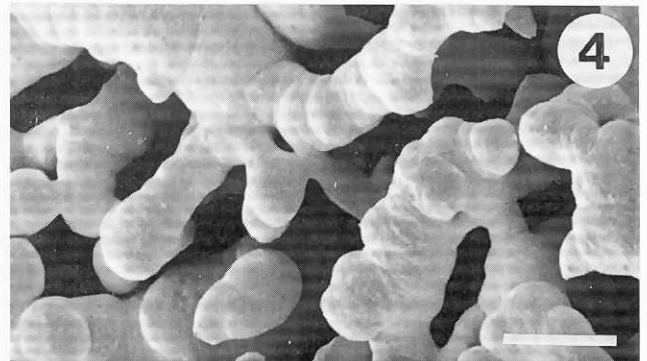


Figure 4. Overview of the mesonephric plexus of a control chick embryo. Bar = 64 μ m.

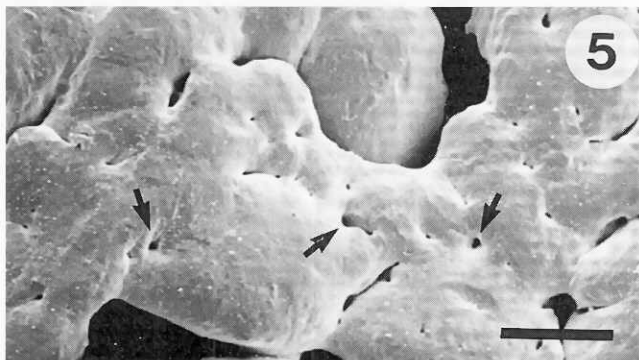

Figure 5. Detail of the plexus of figure 3, showing many angiogenic holes (arrows). Bar = 19 μ m.

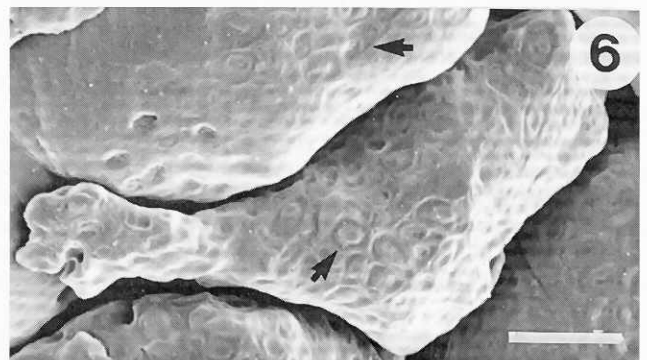


Figure 6. Detail of the plexus of figure 3. Note the blood cell imprints on the surface of the cast (arrows) that demonstrate the lack of extravasation of the injected resin. Bar = 16.5 μ m.

References

- Carretero, A., Ditrich, H., Navarro, M., Splechna, H. and Ruberte, J. (1993) Technical improvements in corrosion casting of small specimens: A study on mesonephric tubules and vessels of chicken embryos. *Scanning Microsc.* 7: 1333-1338.
- Carretero, A., Ditrich, H., Pérez-Aparicio, F.J., Splechna, H. and Ruberte, J. (1995) Development and degeneration of the arterial system in the mesonephros and metanephros of chicken embryos. *Anat. Rec.* 243: 120-128.
- Carretero, A., Ditrich, H., Navarro, M. and Ruberte, J. (1996) The afferent portal venous system in the mesonephros and metanephros of chick embryos: Development and degeneration. *Anat. Rec.* 246: ??
- Flamme, I., von Reutern, M., Drexler, H.C.A., Syed-Ali, S. and Risau, W. (1995) Overexpression of Vascular Endothelial Growth Factor in the avian embryo induces hypervascularization and increased vascular permeability without alterations of embryonic pattern formation. *Dev. Biol.* 171: 399-414.
- Plate, K.H., Breier, G., Weich, H.A. and Risau, W. (1992) Vascular endothelial growth factor is a potential tumour angiogenesis factor in human gliomas in vivo. *Nature* 359: 845-848.