

A Specific Treatment for Global Aphasia

Michael P. Alexander and Felice Loverso

Global aphasia profoundly impairs all aspects of language—oral and written production as well as auditory and written comprehension. The syndrome is usually due to a large lesion of the left perisylvian cortex (Kertesz, Lesk, McCabe, 1977). When persistent for more than a few days after onset, global aphasia has a grim prognosis for recovery of communication. The recent literature on the natural outcome of global aphasia follows one of two views: simple evolution over time or outcome as correlated with specific lesion's profiles. Brust, Shafer, Richter, and Bruun (1976) followed 850 cases of acute stroke admitted to an urban hospital; 177 (21%) demonstrated aphasia. The most common aphasia diagnosis was global (72; 41%). At 4 to 12 weeks post onset, of the 72 global aphasic subjects, 28 (33%) were dead. Thirty-three of the surviving individuals with aphasia (22%) were still global, and 11 (22%) had milder aphasias. The measure of comprehension was unspecified.

Sarno and co-workers, in a series of reports, further defined the natural course. In the first three months, all cases improved, and all aspects of language improved (Sarno, Silverman, & Sands, 1970). Improvement was not proportional to early aphasia severity. Over the next 3 months improvement slowed, but even from 6 to 12 months post onset, considerable recovery of comprehension was observed (Sarno & Levita, 1979). All patients, however, were still diagnosed with global aphasia. The comprehension measure was the Functional Communication Profile (Sarno, 1969).

Kertesz and McCabe (1977) reported similar results. Patients with global aphasia at 1 month post onset had less recovery than any other diagnostic group. Most improvement occurred in the first 3 months. By 1 year post-onset, only 17% had improved enough to be considered severe Broca's aphasics and even they had minimal language output. When the profile of recovery was analyzed (Lomas & Kertesz, 1978), the global cases showed better improvement of comprehension than expression. Prins, Snow, and Wagenaar (1978) demonstrated the same results in a group followed from 3 months

post onset. They reported poor group improvement over 1 year, relatively greater improvement of comprehension, and only a minority (20%) actually improving enough to be considered severe Broca's at 1 year post onset.

The overall implication of these studies is that for patients diagnosed as global aphasia at 1 month post onset, the prognosis is bleak. There will be modest improvement over the entire year. Comprehension may preferentially improve, but the best outcome (reached in less than 20% of cases) is severe Broca's aphasia.

In the past 10 years, the investigation of global aphasia's evolution has turned toward identification of neurobiological factors that might predict or constrain recovery. Most studies have explored relationships between the brain lesion and severity or recovery of global aphasia. The usual lesion configuration associated with global aphasia is a large confluent left perisylvian lesion including subcortical structures (Kertesz & McCabe, 1977; Mazzocchi & Vignolo, 1979; Poeck, de Bleser, & von Keyserlingk, 1984). When investigated, no correlation between the clinical and CT subtypes has been observed (Poeck et al., 1984; Vignolo, Boccardi, & Caverni, 1986). In one report (Poeck et al., 1984) a subtype of global aphasia was defined by the presence of well-inflected, pseudofluent stereotypes, and it was noted that these cases were particularly refractory to speech therapy.

Global aphasia has been reported after purely subcortical lesions (Alexander, Naeser, & Palumbo, 1987; Naeser, Palumbo, Helm-Estabrooks, Stiassney-Eder, & Albert, 1989). In these cases, comprehension deficits have been attributed to a temporal isthmus lesion. Outcome was often poor, even with just subcortical lesions. Recovery of single-word comprehension may, however, be better in cases with temporal isthmus lesion than in those with superior temporal gyrus lesion (Naeser, Gaddie, Palumbo, & Stiassney-Eder, 1990).

There is a group of patients with acute global aphasia (usually without hemiparesis) who may have rapid recovery. Not surprisingly, they have smaller lesions, either discrete separate frontal and temporal lesions or large frontal lesions (Legatt, Rubin, Kaplan, Healton, & Brust, 1987; Tranel, Biller, Damasio, Adams, & Cornell, 1987). Many of these cases rapidly recover in the first 1 to 2 months post onset. They would not, of course, ever qualify for entry into the bulk of the lesion outcome studies, as those studies usually consider only cases that are persistently global at 1 month post onset.

Patients with global aphasia may have different lesions, but they also have different brains. The most accessible differences in brains are the subject's gender and pattern of cerebral asymmetries. At least three studies (Mazzocchi & Vignolo, 1979; Poeck et al., 1984; Vignolo et al., 1986) have found a high percentage of globally aphasic women without cortical temporal lesions. All of the cases of Naeser and colleagues (1990) without cortical temporal lesions, however, were men. Pieniadz and associates

(Pieniadz, Naeser, Koff, & Levine, 1983) demonstrated that globally aphasic patients with posterior asymmetries that are reversed from the most typical patterns (i.e., having larger right temporal lobes than left) have better recovery. The better recovery is limited to single-word tasks—comprehension, repetition and naming.

Although recovery is limited, it follows predictable dimensions, and even patients with severe global aphasia develop some communication capacities. They are able to discriminate between their native language and foreign languages (Boller & Green, 1972); recognize the pragmatic intent of utterances addressed to them (i.e., declarative vs. interrogative, and if interrogative, whether a yes/no or lengthy response is expected [Boller & Green, 1972]); recognize the emotional intent of an utterance (Heilman, Scholes, & Watson, 1975); follow commands that involve moving the whole body (Alexander, Baker, Naeser, & Kaplan, *in press*); comprehend gestures, at least customary representational ones (Daniloff, Noll, Fristoe, & Lloyd, 1982; Duffy & Duffy, 1981); learn substituted iconic language schemes (Gardner, Zurif, Berry & Baker, 1976); Johannsen-Horbach, Cegla, Mager, Schempp, Wallesch, 1985; Steele, Weinrich, Wertz, & Carlson, 1989); and manipulate symbols in syntactically acceptable manners to construct phrases and sentences (Weinrich et al., 1989).

In a particularly illuminating experiment (Wapner & Gardner, 1979), patients with global aphasia could recognize place names and common objects' names (again, single words) while rejecting pseudo-words and real but incorrect names. The probability of word recognition increased with higher-frequency words, with names for objects or places that were highly canonical—predictable in their place or location, and to a lesser extent with their operativity.

The final observations come from analysis of the nature of preservation of semantic relationships in aphasia. Patients with severe comprehension deficits are still able to demonstrate preferential sparing of supra-ordinate semantic relationships (a chair is furniture) over associational semantic relationships (Goodglass & Baker, 1976). Furthermore, even in cases with global aphasia semantic priming in lexical decision tasks can be demonstrated, supporting the preservation of some semantic relationships (Blumstein, Milberg, & Shrier, 1982).

Some authorities have suggested that global aphasia is fundamentally untreatable (Schuell, 1955). In the past 20 years, a small number of specific treatments have been suggested (Helm-Estabrooks & Barresi, 1980; Helm-Estabrooks, Fitzpatrick, & Barresi, 1982; Steele et al., 1989), but the current literature does not reveal a consistent theory of management. Beyond the scientific merits of identification of a specific theory of treatment, there are the practical issues that global aphasia is the most common acute and persisting aphasic disorder (Brust et al., 1976) and that language rehabilitation interventions for global aphasia are costly and of uncertain value.

Practical experience over a 2-year period with speech-language treatment of 22 globally aphasic patients in our in-patient aphasia program led us to develop a specific treatment for global aphasia. During those 2 years, we followed all patients referred for speech-language treatment whose aphasia was due to a CT-confirmed unilateral left hemisphere infarction and who were right-handed, native English speakers, 40 and 75 years of age. Initial evaluations were performed at 2-5 weeks post-stroke. The Western Aphasia Battery (WAB) (Kertesz, 1982) was the diagnostic tool used at the onset and termination of therapy. Treatment consisted of the individual clinician's decision about the relative necessity for individual, programmed (technician-monitored computer programs predominantly), group or family therapy. The patients received therapy 6 days per week. Treatment lasted 4-10 weeks and ran more than 8 weeks in more than 90% of the cases. The responsible clinicians prescribed therapy along the following proportions: 1) individual sessions (including evaluation) 53%; 2) programmed therapy sessions (various simple computer tasks) 25%; 3) group sessions (mostly small pragmatic groups) 19%; 4) family teaching sessions, 3%. The average bill for speech-language pathology services was \$7,272.

At the end of in-patient treatment period, by WAB criteria, all patients still had global aphasia. By clinician criteria, 14 cases were diagnosed as global aphasia; 8 were considered severe Broca's aphasia. No patient had useful propositional speech. There were no apparent correlations between any descriptive variable (e.g. age, lesion size) and recovery in this relatively early follow-up period.

METHODS

Based on our institutional experience and the literature, we attempted to construct a specific treatment program for global aphasia that fulfilled two purposes: 1) support capacities likely to improve with natural recovery, primarily the capacity to make categorical and associational semantic discriminations; 2) be sufficiently easy that most severe, acute global aphasic adults could comprehend the nature and the purpose of the task. The long-term expectation was that patients treated in this manner would be able to approach iconic/substitutional language (Steele et al., 1989) successfully at an earlier point post-onset.

Subjects

Five patients with global aphasia and one with Wernicke's aphasia served as subjects for this preliminary investigation. The patient criteria were objective aphasia diagnosis (Kertesz, 1979), right-handedness, high moti-

TABLE 1. SAMPLE CASES

Patient #	Age/Sex	Post Onset (months)	Lesion*	Diagnosis (Aud. Comp.**)	# of Treatment Sessions
1	65/M	2	FPT (STG, SMG, MTG)	Global (2.8; 4.15)	14
2	29/M	3	FPT (STG, SMG)	Global (3.05; 6.1)	9
3	50/M	2	FPT (STG, SMG)	Global (1.65; 2.5)	3
6	71/M	1	TP (STG, SMG, MTG)	Wernicke's (2.5; 4.2)	17

*Lesion: FPT—Frontal, parietal, and temporal lesions

TP—Temporal and parietal lesions

including—STG—superior temporal gyrus

SMG—supramarginal gyrus

MTG—middle temporal gyrus

Aud. Comp.**—Overall auditory comprehension at admission and discharge on the Western Aphasia Battery.

vation, and a single left hemisphere infarction by CT scan (See Table 1). Treatment was begun between 1 and 2 months post onset.

Procedures

Treatment stimuli were 24 common, everyday objects, realistic pictures of those objects, and realistic pictures of the locations in which those objects would unambiguously be found. These representational stimuli are similar to those commonly adopted for simple communication boards. The C-VIC program devised by Steele et al. (1989) utilizes many unambiguous iconic stimuli in addition to more abstract icons. A C-VIC-type system may offer the best prospects for independent communication in patients with chronic global aphasia, but it is not apparent from the reports thus far with these substituted language systems that *acutely* aphasic patients can learn any substituted representational system. We studied whether acute patients could learn a simpler system.

There were eight hierarchically arranged treatment levels:

IA: Object to object match, field of 1 (modeling expected response).

IB: Object to object match, field of 2.

IC: Object to object match, field of 4.

ID: Object to realistic picture match, field of 4.

- IIA: Picture to semantically related picture match, field of 2, (e.g., spoon should match to picture of frying pan.)
- IIB: Picture to semantically related picture match, field of 4.
- III: Object picture to locatively coordinate picture match, field of 4, (e.g., spoon should match to picture of a kitchen.)
- IV: Picture sorting into locatively related groups.

A multiple baseline design was used. The stability of performance was tested across all treatment tasks. Baseline data were established across three test sessions. Treatment was initiated at the level of performance breakdown. Patients were to be advanced through the treatment levels, moving up when 90% accuracy was achieved. The therapist would use any object at any given level, attempting to model a correct match with encouragement, hand-over-hand direction, or blocking incorrect choices. Failure was defined as five sessions completed with less than 60% accuracy. During treatment at any given level, probing continued on all untreated levels. Following completion of the overall treatment program, standardized testing was repeated.

RESULTS

During baseline phase, patient 1 performed at criterion for levels IA through IIA; thus, treatment began at IIB. He reached overall treatment criterion in 14 sessions, but little generalization to untrained levels was noted (Figure 1). Patient 2 was also able to begin treatment at level IIB. He required nine sessions to reach overall criterion success, but again little generalization to untrained stimuli was noted (Figure 2). Patient 3 represents the other remaining three globally aphasic patients. They were able to perform successfully at level ID but completely unable to match a picture to a semantically related picture at the treatment success criterion (Figure 3). Some, like patient 3, found the task so confusing that they refused to attempt the task again after the first session. All five cases still had auditory comprehension quotients in the range for global aphasia on standardized testing (WAB), and three had no improvement at all.

Patient 6 with Wernicke's aphasia also began at level ID after baseline evaluation. He quickly reached criterion on all subsequent levels. Unlike the cases with global aphasia, this patient demonstrated considerable generalization to levels III and IV while being trained at level IIA (Figure 4).

CONCLUSIONS

Patients with acute global aphasia may show rapid recovery, but most will remain aphasic patients. Patients with global aphasia 1 month post onset have a low probability of substantial improvement. If improvement occurs,

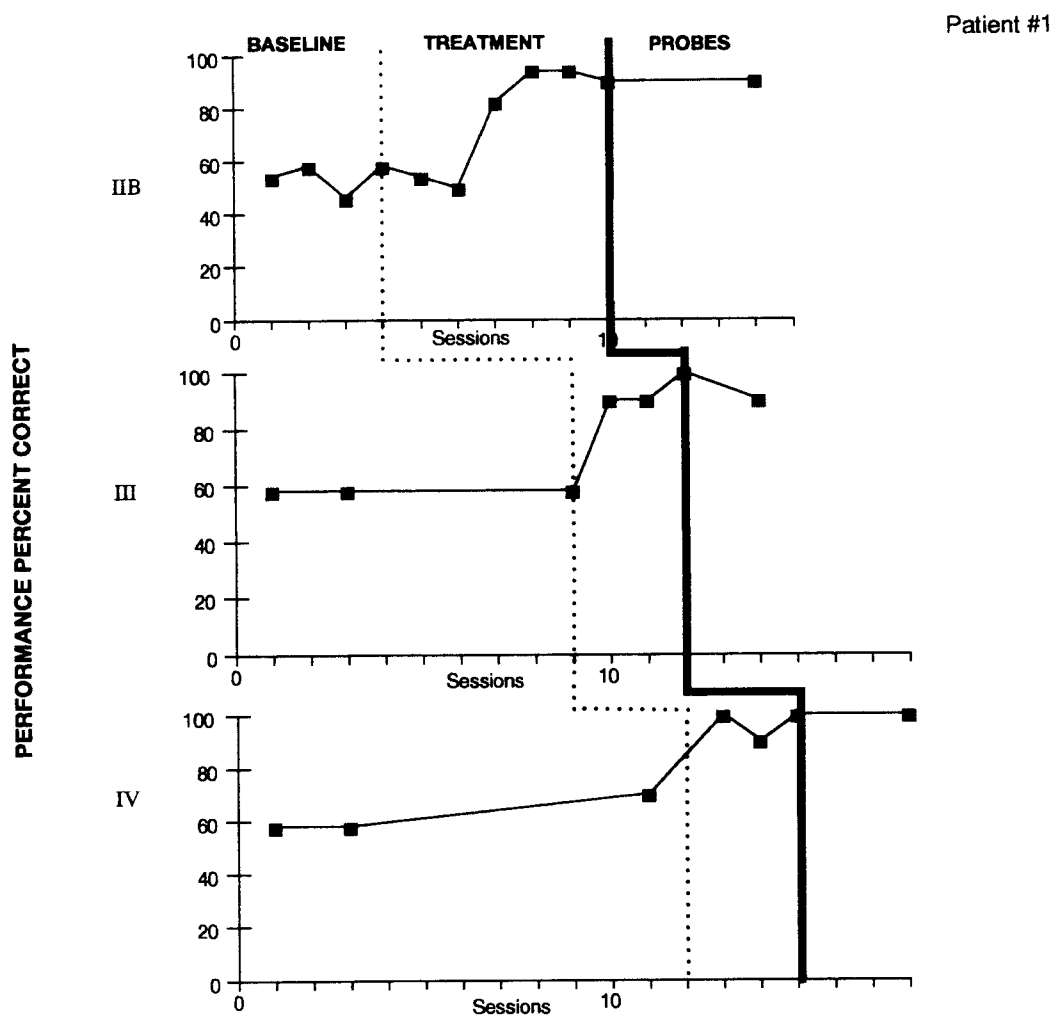


Figure 1. Global patient 1 performed at the success criterion for steps IA to IIA and began treatment at Level IIB—semantically related picture match, field of four. Training was successful for all levels but without generalization.

it may be more likely in patients with reversed cerebral asymmetries and in women. When improvement occurs, it will primarily be at the single-word discrimination level and will be determined by frequency, predictability, and perhaps semantic category.

Traditional treatment programs in the post-acute epoch may be of no value, although quite expensive. Initial efforts might be better placed in family teaching; programs designed to stimulate the recovery path are needed.

The treatment strategy we devised for global aphasia was partly successful. Two of the five global aphasia cases reached the proposed goal of treatment—demonstration of semantic capacity across categorical and

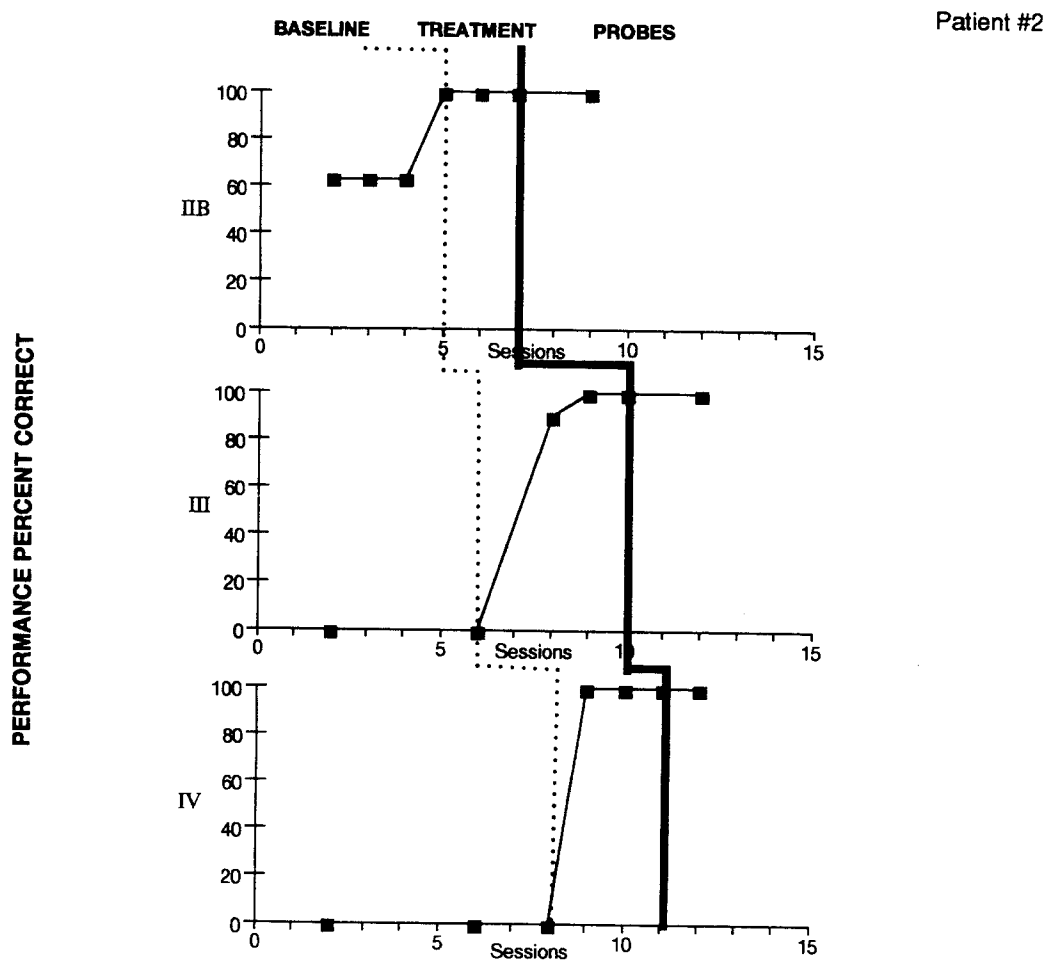


Figure 2. Global patient 2 performed at the criterion for success for steps IA to IIA and began treatment at Level IIB—semantically related picture match, field of four. Training was successful for all levels but without generalization.

associational boundaries. We propose that this precondition is necessary to the use of feasible communication boards or a substituted iconic language. The other three global patients were unable to recognize the nature of the response required at the more complex levels (i.e. above the object to realistic picture match, field of 4). Additional attempts to structure responses and guide the patients might have succeeded. Additionally, the same approach later in recovery might be more successful and might still be necessary to advance broader comprehension.

We plan to continue stimulating categorical and associational relationships in post-acute cases of global aphasia in an attempt to establish the neurobiologic factors that might predict early response and possibly earlier recovery. Even if only 40% of the post-acute cases can respond to the

Patient 3

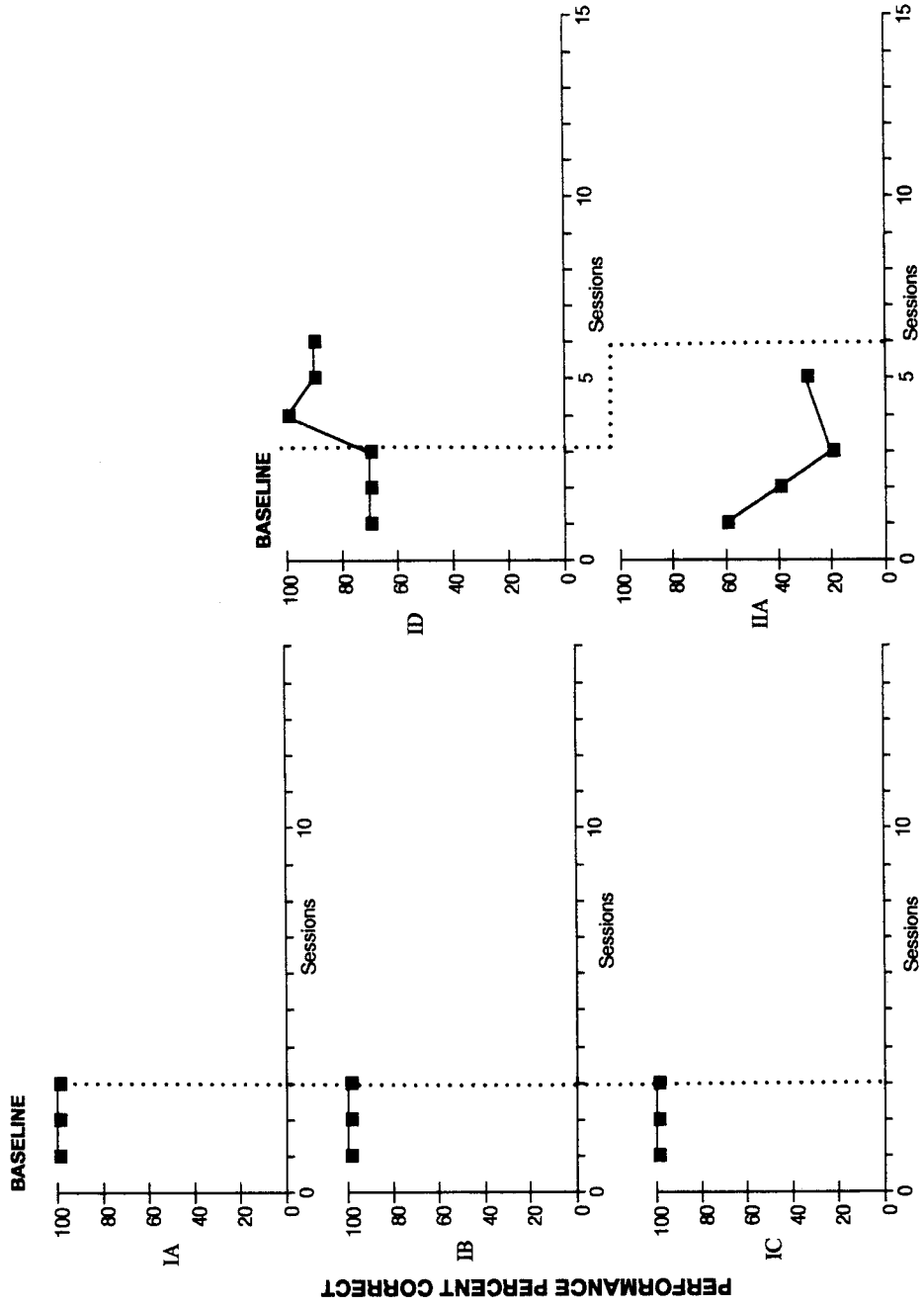


Figure 3. Global patient 3 is representative of all three global patients who were unable to do the task. At Level IIA—the semantically related picture match, field of two—he could not grasp the matching principle. This patient refused further attempts.

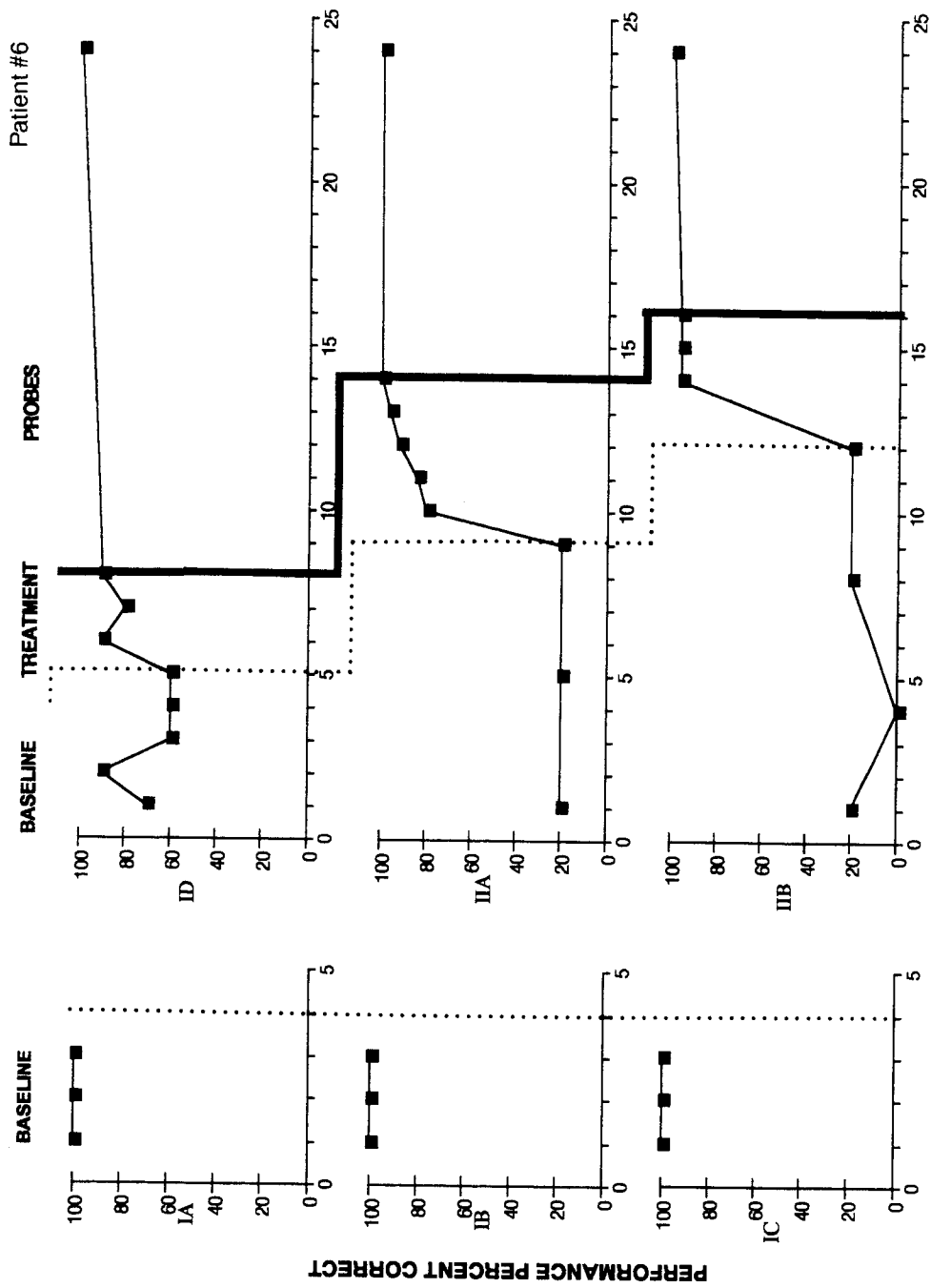


Figure 4a.

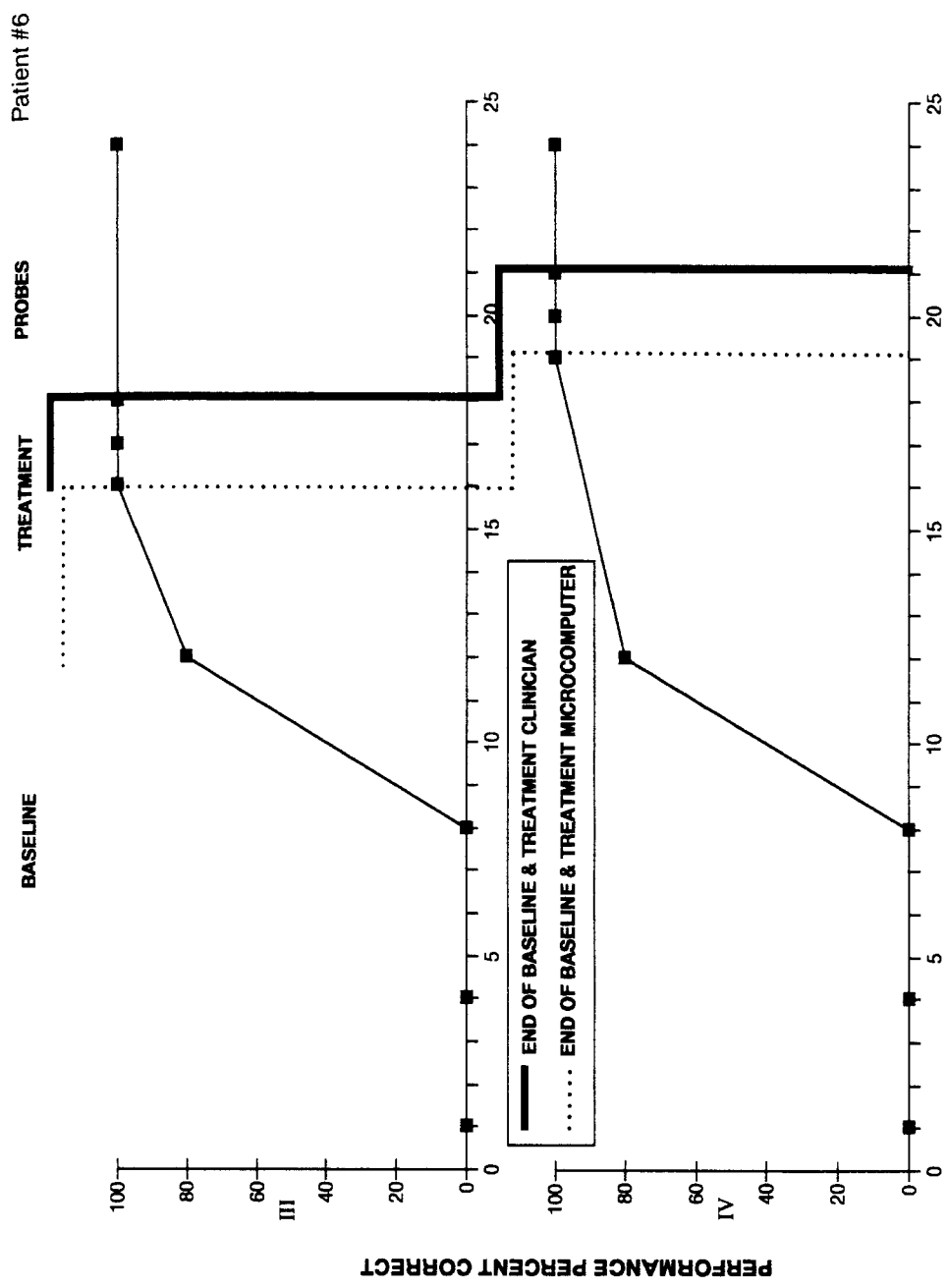


Figure 4b.

Figures 4a-b. Patient 6 had Wernicke's aphasia. Treatment began at Level ID, object to realistic picture match, and training was successful at all levels. Unlike the two successful cases with global aphasia (Figures 1 & 2), this patient showed considerable generalization to later levels of treatment (4b, Levels III & IV).

program, in that group we will attempt a substituted language system. Given our preliminary data on one subject it is also possible that this approach will be equally appropriate, or even more effective, in patients with severe Wernicke's aphasia.

REFERENCES

- Alexander, M. P., Baker, E., Naeser, M. A., & Kaplan, E. (in press), Neuropsychological and neuroanatomical dimensions of ideomotor apraxia, *Brain*.
- Alexander, M. P., Naeser, M. A., & Palumbo, C. L. (1987) Correlations of subcortical CT lesion sites and aphasia profiles. *Brain* 110, 961-991.
- Blumstein, S. E., Milberg, W., & Shrier, R. (1982). Semantic processing in aphasia. *Brain and Language*, 17, 301-315.
- Boller, F., & Green, E. (1972). Comprehension in severe aphasics. *Cortex*, 8, 382-394.
- Brust, J. C. M., Shafer, S. Q., Richter, R. W., & Bruun, B. (1976). Aphasia in acute stroke. *Stroke*, 7, 167-174.
- Daniloff, J. K., Noll, J. D., Fristoe, M., & Lloyd, L. L. (1982). Gesture recognition in patients with aphasia. *Journal of Speech and Hearing Diseases*, 47, 43-49.
- Duffy, R., & Duffy, J. (1981). Three studies of deficits in pantomimic expression and recognition in aphasia. *Journal of Speech and Hearing Research*, 46, 70-84.
- Gardner, H., Zurif, E., Berry, T., & Baker, E. (1976). Visual communication in aphasia. *Neuropsychologia*, 14, 275-292.
- Goodglass, H. & Baker, E. (1976). Semantic field naming and auditory comprehension in aphasia. *Brain and Language*, 3, 359-374.
- Helm-Estabrooks, N., & Barresi, B. (1980). Voluntary control of involuntary utterances. In R. H. Brookshire (Ed.), *Clinical Aphasiology Conference* (Vol. 10, pp. 308-316). Minneapolis MN: BRK Publishers.
- Helm-Estabrooks, N., Fitzpatrick, P. M., & Barresi, B. (1982). Visual action therapy for global aphasia. *Journal of Speech and Hearing Research*, 47, 385-389.
- Heilman, K. M., Scholes, R., & Watson, R. T. (1975). Auditory affective agnosia. *Journal of Neurology, Neurosurgery and Psychiatry*, 38, 69-72.
- Johannsen-Horbach, H., Cegla, B., Mager, U., Schempp, B., & Wallesch, C. W. (1985). Treatment of chronic global aphasia with a nonverbal communication system. *Brain and Language*, 24, 74-82.
- Kertesz, A. (1979) *Aphasia and Related Disorders*. New York: Grune and Stratton.
- Kertesz, A. (1982). *Western Aphasia Battery*. New York: Grune and Stratton.
- Kertesz, A., Lesk, D., & McCabe, P. (1977). Isotope localization of infarcts in aphasia. *Archives of Neurology*, 34, 590-601.
- Kertesz, A., McCabe, P. (1977). Recovery Patterns and Prognosis in Aphasia. *Brain*, 100, 1-18.
- Legatt, A. D., Rubin, A. J., Kaplan, L. R., Heaton, E. B., & Brust, J. C. M. (1987). Global aphasia without hemiparesis. *Neurology*, 37, 201-205.
- Lomas, J., & Kertesz, A. (1978). Patterns of spontaneous recovery in aphasic groups: A study of adult stroke patients. *Brain and Language*, 6, 388-401.
- Mazzocchi, F., & Vignolo, L. A. (1979). Localization of lesions in aphasia. *Cortex*, 15, 627-654.
- Naeser, M. A., Gaddie, A., Palumbo, C. L., & Stiassney-Eder, D. (1990). Late recovery of auditory comprehension in global aphasia. *Archives of Neurology*, 47, 425-432.

- Naeser, M. A., Palumbo, C. L., Helm-Estabrooks, N., Stiassney-Eder, D., & Albert, M. L. (1989). Severe nonfluency in aphasia. *Brain*, *112*, 1-38.
- Pieniadz, J., Naeser, M. A., Koff, E., & Levine, H. L. (1983). CT scan cerebral asymmetry measurements in stroke cases with global aphasia. *Cortex*, *19*, 371-391.
- Poeck, K., de Bleser, R., & von Keyserlingk, D. G. (1984). Neurolinguistic status and localization of lesions in aphasic patients with exclusively consonant-vowel recurring utterances. *Brain*, *107*, 199-217.
- Prins, R. S., Snow, E., & Wagenaar, E. (1978). Recovery from aphasia: spontaneous speech versus language comprehension. *Brain and Language*, *6*, 192-211.
- Sarno, M. T. (1969). The functional communication profile: manual of directions. *Monographs of the Institute of Rehabilitation Medicine, New York University Medical Center*, 42.
- Sarno, M. T., & Levita, E. (1979). Recovery in treated aphasia in the first year post-stroke. *Stroke*, *10*, 663-670.
- Sarno, M. T., Silverman, M., & Sands, E. (1970). Speech therapy and language recovery in severe aphasia. *Journal of Speech and Hearing Research*, *13*, 607-623.
- Schuell, H. (1955). Diagnosis and prognosis in aphasia. *Archives of Neurology and Psychiatry*, *74*, 308-315.
- Steele, R. D., Weinrich, M., Wertz, R. T., & Carlson, G. S. (1989). Computer-based visual communication in aphasia. *Neuropsychologia*, *27*, 409-426.
- Tranel, D., Biller, J., Damasio, H., Adams, H. P., & Cornell, S. H. (1987). Global aphasia without hemiparesis. *Archives of Neurology*, *44*, 304-308.
- Vignolo, L. A., Boccardi, E., & Caverni, L. (1986). Unexpected CT-scan findings in global aphasia. *Cortex*, *22*, 55-69.
- Wapner, W., & Gardner, H. (1979). A note on patterns of comprehension and recovery in global aphasia. *Journal of Speech and Hearing Research*, *22*, 765-772.
- Weinrich, M., Steele, R. D., Carlson, G. S., Kleczewska, M., Wertz, R. T., & Baker, E. (1989). Processing of visual syntax in a globally aphasic patient. *Brain and Language*, *36*, 391-405.