

CT Scan Correlates of Recovery of Auditory Comprehension

Ola A. Selnes, Nancy E. Niccum, Alan B. Rubens
Hennepin County Medical Center, Minneapolis, Minnesota

INTRODUCTION

We owe much of our understanding of the anatomical correlates of auditory comprehension to the remarkable work of Carl Wernicke (1874). He was the first to demonstrate that lesions affecting the posterior superior aspect of the left temporal lobe, and its posterior extension, would result in a comprehension disturbance. Since the time of Wernicke, however, only limited progress has been made in further delineating the anatomy of auditory comprehension.

In the context of a large aphasia recovery study, we became interested in exploring in some detail the relationships between lesion location and both the initial severity of auditory comprehension deficits and the prognosis for their recovery. Specifically, we sought to determine whether or not temporal lobe lesions, in fact, were associated with more severe initial deficits and/or less favorable prognoses than non-temporal lobe lesions.

SUBJECTS AND METHODS

A series of 31 patients who had suffered a single left-hemisphere stroke were studied. The patients were all right-handed speakers of English with no history of previous CNS disease. They were tested at approximately 30 days post-onset and then retested at monthly intervals for 5 subsequent months as part of an aphasia recovery study. This report, however, will focus mainly on data from Months 1 and 6. Auditory comprehension was assessed with a slightly modified version of the Token Test included in the Neurosensory Center Comprehensive Examination for Aphasia (NCCEA).¹ The performance scale of the Wechsler Adult Intelligence Scale (WAIS) was used as a measure of nonverbal cognitive performance. A CT scan was obtained for each patient at approximately 5 months post-onset. The scans were rated by two experienced neurologists according to the degree of involvement (0-100%) of 40 predefined anatomical regions. A computer-generated estimate of lesion volume, based on tracings of the lesion on relevant cuts, was also obtained for each patient.

RESULTS

Patients were divided into four groups based on their performance on the Token Test on Month 1 and Month 6. Patients in the first three groups

¹The maximum obtainable score on items 28, 31, 37, and 38 was reduced to 4, which prevents patients who miss more than one part of those commands from receiving more credit than those patients who miss only 1 part. The maximum obtainable correct on item 35 was adjusted to 8, and the total correct score on the test was thus 157, 6 points lower than the 163 maximum score on the Spreen-Benton version.

were similar in that they all had scores below 50% correct on the Token Test on Month 1, but were distinguished on the basis of their Month 6 scores. The seven patients in Group 1, characterized by poor recovery, all had Month 6 scores below 25% correct. The six patients in Group 2 showed moderate recovery (scores below 75% correct). Group 3 consisted of six patients who all demonstrated good recovery, with scores above 75% correct on Month 6. The 12 patients in Group 4 were distinguished on the basis of Month 1 performance. They all scored above 50% correct on Month 1, and their Month 6 scores exceeded 75% correct. There were no significant differences between the four groups in terms of age, level of education, or gender.

Table 1 presents more detailed information on patients in each of the groups. The seven patients in Group 1 were, on the average, the most severely impaired on Month 1, and they all showed no appreciable recovery, thus remaining severely impaired at 6 months post-onset. Their Month 6 scores on the Token Test ranged from 0-18% correct, with a mean of 5%. Their nonverbal Performance IQ scores were also somewhat depressed, with a mean of only 87. Damage of the posterior superior aspect of the temporal lobe (PST) was present in all seven of these patients, and six also had some extension of their lesions into the infrasyllvian portion of the supramarginal gyrus (SMG).

Table 1. Anatomical correlates (PST involvement, SMG involvement, and lesion volume) and nonverbal performance for patients grouped according to Token Test performance.

Group	Token Test Month 6	WAIS PIQ Month 5	PST lesion ^a	SMG lesion ^b	lesion volume (cm ³)
1 (N=7)	0-18% (\bar{x} =5%)	65-100 (\bar{x} =87)	7	6	60-183 (\bar{x} =116)
2 (N=6)	29-64% (\bar{x} =52%)	92-125 (\bar{x} =103)	5	6	30-103 (\bar{x} =61)
3 (N=6)	76-94% (\bar{x} =86%)	89-116 (\bar{x} =106)	1	0	13-115 (\bar{x} =46)
4 (N=12)	83-100% (\bar{x} =94%)	85-130 (\bar{x} =108)	1	1	4-47 (\bar{x} =22)

^a PST = Posterior Superior Temporal Lobe

^b SMG = Supramarginal Gyrus

All of these patients had very extensive lesions, with volume estimates ranging from 60-183 cm³, with a mean of 116 cm³. Figure 1 shows lateral drawings of the lesions in two of the patients in this group. One is an example of an extensive posterior lesion, destroying most of the parietal lobe in addition to the PST, and the other is an example of a very large frontal lobe lesion.

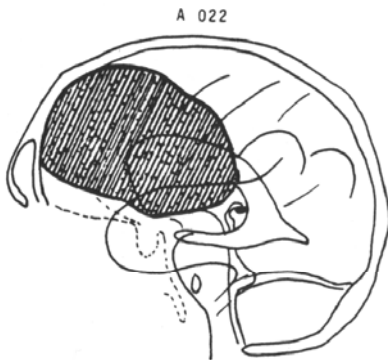
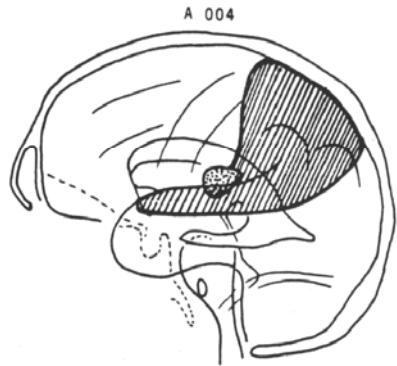


Figure 1. Approximate lateral projection of lesions in two patients in Group 1. Lesion volume is 106 cm^3 for Patient A004 and 102 cm^3 for Patient A030.

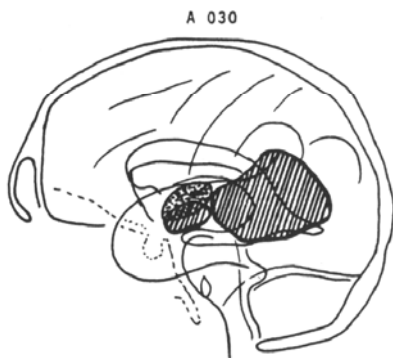
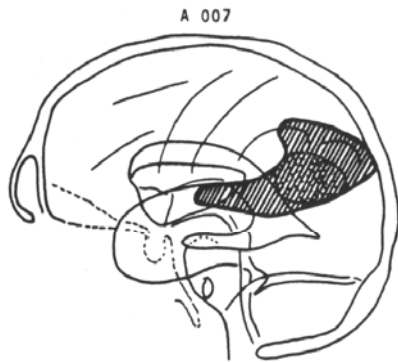


Figure 2. Approximate lateral projection of lesions in two patients in Group 2. Lesion volume is 37 cm^3 for Patient A007 and 30 cm^3 for Patient A030.

Six patients in Group 2 achieved a moderate degree of recovery with Month 6 Token Test scores ranging from 29-64% correct ($\bar{x} = 52\%$, s.d. = 15%). Nonverbal Performance IQ scores were in the normal range for this group ($\bar{x} = 103$, s.d. = 13). With one exception, all of these patients had a lesion which included the posterior superior aspect of the temporal lobe, with some extension into the supramarginal gyrus. The one patient in whom the posterior temporal lobe apparently was spared did have, in addition to extensive frontal gyrus and supramarginal damage, significant involvement of callosal pathways deep to the temporal lobe. This patient also failed to recover any spontaneous speech. Lesion volume was on the average smaller in this group, ranging from 30-103 cm³ ($\bar{x} = 61.3$ cm³, s.d. = 27.5 cm³). Figure 2 shows lateral drawings of the lesion in two representative patients for this group.

The six patients in Group 3 all showed good recovery on the Token Test. Although their Month 1 scores on the Token Test were comparable to the Month 1 scores of patients in Group 2, their Month 6 scores were much higher, ranging from 76-94% correct ($\bar{x} = 86\%$, s.d. = 7%). This group was similar to the patients in Group 2 in nonverbal performance, with scores ranging from 89 to 116 ($\bar{x} = 106$, s.d. = 9). In contrast to the findings from Group 2, however, only one of these patients had involvement of the posterior superior temporal lobe. Furthermore, the lesion in that patient appeared to involve mainly the primary auditory cortex (Heschl's gyrus), rather than any of the surrounding association areas (Wernicke's area). None of the patients in this group had a lesion involving the infrasyllvian portion of the SMG. The lesion volume was slightly smaller in this group than in Group 2, ranging from 13-115 cm³ ($\bar{x} = 46.2$ cm³, s.d. = 38.4 cm³), but the difference was not significant.

The 12 patients in Group 4 had scores above 50% correct on the Token Test when tested on Month 1. Their performance had improved to nearly normal by Month 6, with scores ranging from 83% to 100% correct ($\bar{x} = 94\%$). Nonverbal performance was also quite high for this group, with scores ranging from 85 to 130 ($\bar{x} = 108$, s.d. = 12). Only one of the patients in this group had some involvement of the PST. However, the major portion of the lesion in this patient was in the anterior portion of the temporal lobe, sparing the presumably more critical posterior aspect of the PST and the supramarginal extension. One of the other patients in this group, in whom PST was spared, did have some involvement of the SMG. Lesion volume for these patients ranged from 4 to 47 cm³ ($\bar{x} = 22.2$ cm³, s.d. = 12.9).

DISCUSSION

A principal finding of this study is that a striking relationship exists between auditory comprehension scores at 6 months post-onset and lesion location (see Table 1). All the patients in Group 1 who demonstrated little or no recovery of auditory comprehension had lesions involving the PST and most of these patients also had posterior extension into the infrasyllvian SMG. However, the lesions were also very large for these patients. Thus, their failure to recover might be because of the large volume of the lesion rather than the specific involvement of structures in the posterior superior aspect of the left temporal lobe.

The comparison of most interest, therefore, centers on Groups 2 and 3, who both started out with severe auditory comprehension impairments, but who

differed in degree of recovery by Month 6. Both of these groups had, on the average, lesions of comparable volume, so that any difference in degree of recovery cannot be explained on the basis of a lesion volume effect. Rather, the critical variable determining degree of recovery appears to be lesion location.

Patients with lesions involving the posterior superior aspect of the left temporal lobe showed only a moderate degree of recovery of auditory comprehension by Month 6 (performing less than 75% correct on the Token Test). The one patient who had good recovery of auditory comprehension despite the presence of a temporal lobe lesion had damage primarily involving Heschl's gyrus rather than the surrounding association areas which constitute the major part of the posterior superior temporal lobe. By contrast, patients with a lesion that spared the critical PST area showed good recovery, with scores above 75% on the Token Test at Month 6. The one exception was a patient who had only moderate recovery of auditory comprehension in the absence of a temporal lobe lesion. This patient had considerable frontal and deep callosal involvement in addition to possible involvement of the supramarginal gyrus which forms the posterior extension of the PST region. It is important to emphasize that the two groups were comparable in terms of initial degree of impairment on the Token Test.

The fact that in the acute period auditory comprehension may be impaired to a similar degree whether or not the posterior superior aspect of the temporal lobe is involved represents another important finding of this study. Thus, the severity of auditory comprehension deficits in the acute period is not predictive of lesion location or of prognosis for recovery of patients in these two groups. Furthermore, it should be reemphasized that lesion volume alone cannot explain the difference in degree of recovery because it does not differ significantly between Groups 2 and 3. A relatively small lesion of the PST may carry a much worse prognosis for recovery of auditory comprehension than a lesion three times as big, provided that the larger lesion spares the posterior superior aspect of the temporal lobe.

One additional finding of importance concerns the description of the shape of recovery curves for auditory comprehension in aphasia. Groups 2 and 3 differed not only in terms of level of performance at Month 6, but the shape of their recovery curves was also quite different as can be seen in Figure 3.

Group 3 showed a very rapid change during the first 3 months post-onset, and had achieved approximately 80% of their recovery by Month 3. The patients in Group 2, on the other hand--most of whom had PST lesions--had a much more gradual rate of recovery, as suggested by the shape of their recovery curve. They, in fact, had no significant difference between the amount of change that occurred before and after Month 3. Therefore, lesion location is also an important variable to consider when predicting the rate at which auditory comprehension is likely to return. Most studies of recovery of auditory comprehension have averaged across patients with and without PST lesions, and this may be obscuring important differences in the shape of the recovery curve for individual patients. The difference in the rate of recovery may also suggest that the processes underlying recovery of auditory comprehension in the two groups may be quite different. However, at this point, we can only offer speculations as to what the specifics of those differences may be.

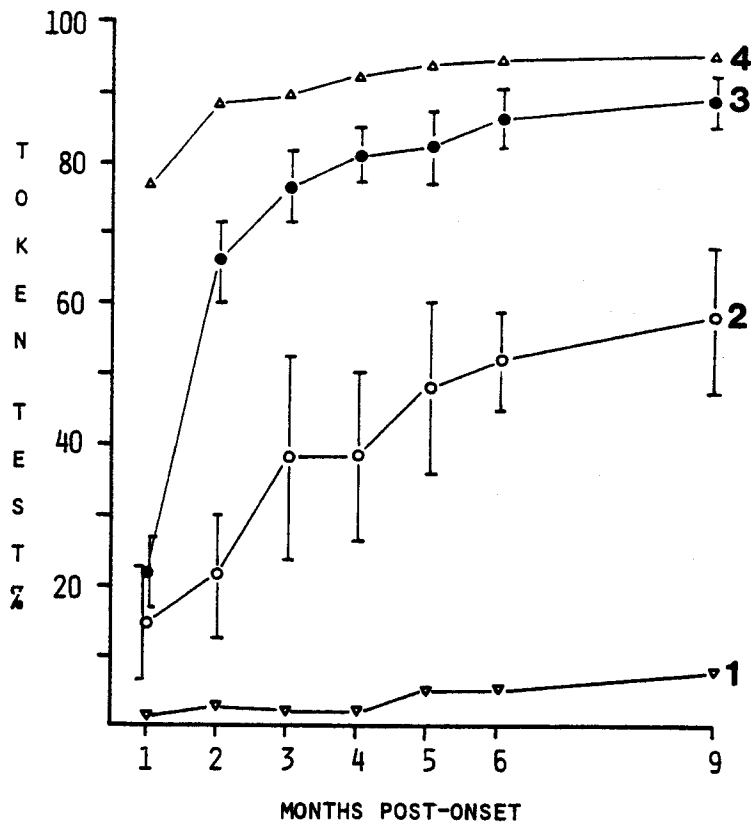


Figure 3. Recovery curves on the Token Test (percent correct) for the four groups. Patients in Group 3 showed a rapid degree of improvement during the first few months post-onset, accomplishing about 80% of their recovery by Month 3. Patients in Group 2 showed a more gradual rate of improvement.

SUMMARY

1. Degree of auditory comprehension impairment at one month post-onset is not predictive of lesion location (i.e., lesions outside the PST may cause as severe impairments as those directly affecting the PST).
2. The presence of a PST lesion is associated with poor prognosis for auditory comprehension; conversely, the absence of a PST lesion is associated with good prognosis—even in cases with severe initial deficits.
3. Patients without PST lesions show very rapid improvement such that the largest part of their recovery occurs prior to three months post-onset. Patients with PST involvement show a much more gradual rate of recovery.

REFERENCES

Wernicke, C. Der Aphasische Symptomencomplex. Breslau, 1874.

DISCUSSION

- Q: How many of the patients were treated?
- A: All of the patients in Groups 2 and 3 were treated. I'm not sure about the patients in Groups 1 and 4.
- Q: What was the proportion of your patients, especially Groups 1 and 2, that had anterior lesions? I'm wondering about the possibility that with the kind of motor response required by the Token Test whether some of the performance of these patients might have been due to motor deficits?
- A: That is not very likely. Many of our patients did have frontal lobe damage, but despite very large frontal lesions, many of them did well on the Token Test.
- Q: Who read your scans, and how much did they know about the patients?
- A: Two neurologists. One of them knew a fair amount about the patients; the other knew very little. We are, however, planning to have the scans read independently by two radiologists.

ACKNOWLEDGMENT

This research was supported by NINCDS Contract N01-NS-2378.