


Role of the copepod parasite *Tracheliastes maculatus* Kollar, 1836 (Lernaeopodidae) in the common bream (*Abramis brama*) infestation occurring in Lake Balaton, Hungary

View metadata, citation and similar papers at core.ac.uk

brought to you by  CORE

provided by Repository of the

Cs. Székely^{1*}, M. Láng² and K. Molnár¹

¹Veterinary Medical Research Institute, Hungarian Academy of Sciences, H-1143 Budapest, Hungária krt. 21, Hungary; ²Central Agricultural Office, Veterinary Diagnostic Directorate, H-1149 Budapest, Tábornok u. 2, Hungary

Abstract

Tracheliastes maculatus is a copepod crustacean parasite belonging to the family Lernaeopodidae. In the late spring months, around the time of spawning, large numbers of the imago stages of that parasite can be found attached to the scales of common bream in Lake Balaton every year. Due to their bright red colour, the small ulcers formed at the site of parasite attachment are highly conspicuous even to non-specialists, calling attention to the presence of infestation. In 2008, *T. maculatus* infestation affecting the bream stock of Lake Balaton proved to be more intensive than usual. The intensity of infestation of the 3- to 5-year-old bream specimens markedly exceeded the usual level of 7–12 parasites per bream, and infestation could be detected also on the 2-year-old bream specimens 12 to 14 cm in length. On the 2-year-old bream specimens, the inflammatory zone of bacterial origin, which was mostly limited to a single scale on breams of bigger body size, involved a larger area, resulting in scaleless areas and extensive superficial erosions developing in the place of the parasitic focus that had become detached together with the attacked scale. When samples from the haemorrhagic areas, from the serum accumulating in the scale pouches and from the kidney were inoculated onto blood agar, colonies of the facultative pathogenic bacterium *Aeromonas hydrophila* grew out. In addition to the sporadic mortality regularly occurring among older fish specimens in the late spring period simultaneously with parasite infestation, this year mortality could be observed also in the younger age groups of bream.

Introduction

The copepod crustacean *Tracheliastes maculatus* Kollar, 1836 belonging to the Lernaeopodidae family and parasitic on the scales of common bream (*Abramis brama*) calls attention to itself with the interesting clinical signs it causes, rather than with its common occurrence. These greenish, transparent arthropods about

1–1.5 cm in length attach to the scales of fish with the bulla of their specially elongated second maxilla, thus securing their permanent adherence to the host. All of the parasite specimens attached in this way and visible also with the unaided eye are females, and the male specimen of very small size, pressed

* Corresponding author's email: szekely@vmri.hu

close against the female's body, can be detected only on closer inspection. During infestation with *T. maculatus* specimens, which occurs primarily in common bream and less often in white bream and roach, a haemorrhage due to bacterial superinfection develops around the site of parasite attachment, under the scales, in an area involving either a single scale or 3–5 scales, resulting in the development of highly conspicuous red spots on the body of the fish. Females of these parasitic copepods colonising the body surface of common bream by adhering to the scales can be observed in Lake Balaton every year. These crustaceans cause a parasitosis resembling *Lernaea cyprinacea* infestation well known from fish farms. This disease regularly occurs in Lake Balaton in late May or early June, simultaneously with the spawning of common bream, but the severity of the losses caused by it vary from year to year. The appearance of *T. maculatus* infestation in Lake Balaton regularly coincides with a low-level mortality among common bream. The adjective 'maculatus' in the name of the parasitic copepod *T. maculatus* obviously refers to the haemorrhages caused by the bacterial complications of parasitic infestation. The occurrence of the parasite in Lake Balaton and the clinical signs produced by it were first described by Geyer (1939). According to Gussev et al. (1987) this parasite is common in the former Soviet Union, but it occurs in Great Britain and in the Netherlands as well (Boxhall and Frear, 1990; Walker et al., 2006). This copepod, which is primarily specialized for the common bream, is a frequent cause of mortality in lakes where the common bream has substantial dominance within the fish population. Such cases were reported by Grabda and Grabda (1958) as

well as Piasecki (1989; cited by Piasecki and Avenant-Oldewage, 2008). The damage done by *T. maculatus* in Lake Balaton was reported by Molnár (1965). Another species, *T. polycolpus* Nordmann, 1832 commonly occurs on fluvial fish species in Hungary; however, this latter species adheres to the base of the fins rather than to the scales (Molnár, 1966).

Material and methods

During a multiple-year survey aimed at the regular monitoring of parasitic infections of Lake Balaton fishes, a few dead common bream specimens were noted in the northern region of the lake, around Tihany, in mid-May 2008. One week later, on the southern shore of the lake, in Balatonszemes higher numbers of dead common bream specimens were recorded. Some moribund 2-year-old common bream, on the body surface of which the red spots and the scaleless areas could already be seen while they were still in the water, were collected with a hand net from the water close to the surface. A higher number of bream specimens showing the clinical signs of the disease were caught with a dragnet. The fish were placed into plastic bags and transported to the laboratory, where the parasites and the lesions caused by them were examined by microscopy and the secondary bacterial infections were studied by inoculation of samples onto blood agar media. Tissue samples from the damaged parts of the skin were fixed in Bouin's solution, embedded in paraffin wax, cut to 4–5 µm sections, and stained with haematoxylin and eosin.

Results and Discussion

During regular fish health monitoring surveys conducted in Lake Balaton in 2008,

in May and June as in the previous years. *T. maculatus* infestations were observed on the scales of common bream accompanied by the appearance of red spots, and simultaneously a low-level common bream mortality was noted, which is known to occur regularly at that time. A unique feature of this infestation was that, unlike the previous years, in 2008 an intensive *T. maculatus* infestation was detected not only in the several years old bream specimens but also in the younger age groups of common bream, and at the same time the mortality rate also exceeded the usual level recorded in the previous years.

A further interesting feature of the infestation observed in 2008 was that, in addition to the usual inflammation mostly restricted to a single scale or extending only to the immediate surroundings of the attachment site, in the younger bream specimens an erosion extending to large areas of the body surface developed. In the 3- to 5-year-old age group the usual clinical signs, characterised by a ring of inflammation surrounding the attached copepods, were diagnosed. In these areas, at the centre of the haemorrhagic ring *T. maculatus* females, less conspicuous because of their greenish colour, protruded from the affected scale. In these fish groups, as many as 5 to 30 spots indicative of infestation were found on the bream specimens that were infested by the copepods but did not show signs of disease. In the infested 2-year-old common bream specimens 12–14 cm in length, a few copepods attached to the scales were still visible in the areas showing less pronounced inflammation, while on the majority of the body surface only the pathological consequences of infestation could be observed. As a result of

the damage done by the parasite, scaleless areas of varying size and the appearance of haemorrhagic-inflammatory foci were seen. In addition to the direct damage done to the scales, the bacterial infection developing in the disintegrated tissues was also a major factor in the pathogenesis of the disease. The bright-coloured ulcers were well visible even with the unaided eye on the body of fish swimming close to the water surface, often floating apathetically on their sides or with their belly up (Figure 1). On the moribund or dead fish drifted to the shore, there were confluent haemorrhages and scaleless areas of substantial size on the sides of the body. The remaining scales surrounding the erosions had a ruffled appearance and a serosanguineous exudate had accumulated under them.

When samples from the haemorrhagic areas, from the serum accumulating in the scale pouches and from the kidney were inoculated onto blood agar, colonies of the facultative pathogenic bacterium *Aeromonas hydrophila* grew out. In histological sections accumulation of serum in the scale pouches was found (Figure 2), the multilayered connective tissue of the dermis became disintegrated, and necrotic cells and tissue debris could be seen in the serum. As a sign of regeneration, in the scaleless areas a relatively intact epithelium developed, which obscured the injured epithelial cells and the haemorrhagic areas (Figure 3). In this granulation tissue, red blood cells, necrotic epithelial cells and occasionally flint algae could also be observed.

When receiving news of the low-level common bream mortalities regularly occurring in May, members of the Fish Pathology Research



Figure 1. Unlike the previous years, in 2008 we detected intensive *T. maculatus* infestation not only in the several years old common bream age groups but also on the younger, 2- to 3-year-old bream specimens (arrows).

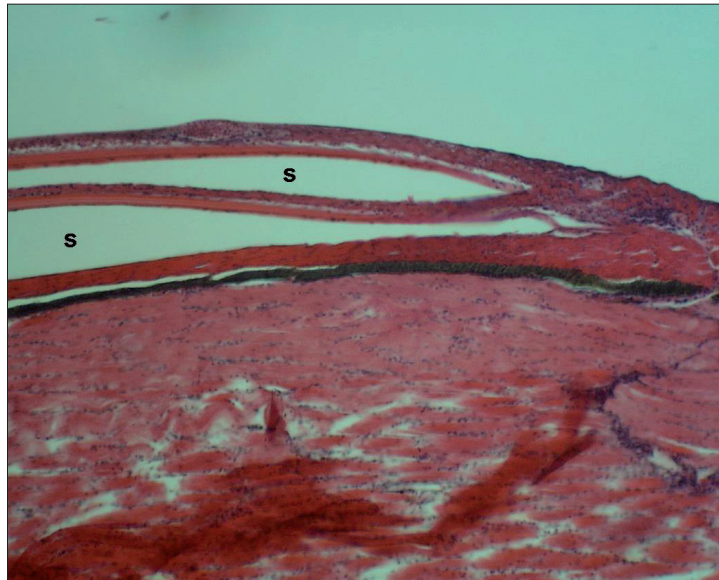


Figure 2. As a result of infection, serum (s) accumulates in the scale pouches and the scales assume a “ruffled” appearance.

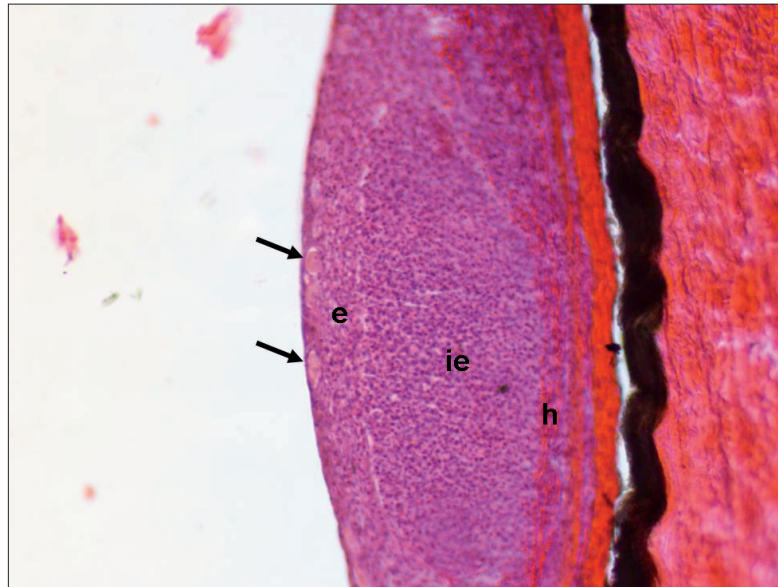


Figure 3. As a sign of regeneration, in the scaleless areas a relatively intact epithelium (e) containing also sensory cells (arrows) appears, which obscures the injured epithelial cells (ie) and the haemorrhagic areas (h).

Team of the Hungarian Academy of Sciences acknowledge this as an unalterable event indicating that the parasitic copepod *T. maculatus* has again exerted its harmful activity. The time of occurrence is also natural, since – as established by Piasecki (1989) – the Cyclops-like larval stages of *T. maculatus* are free-living constituents of the plankton, and its imagos colonise the scales of fish only in the late spring period. Having adhered to the scales, the females undergo substantial transformation. Staying on the scales for about one month, they produce eggs and then die. It is interesting that Gussev et al. (1987) mentions the occurrence of *T. maculatus* infestation in the white bream and less often also in other cyprinids, while during this survey the parasite was not detected either on the white bream or on other cyprinid fishes.

As regards the mortality caused by *T. maculatus* infestation, it was unusual that the mortality was observed among young common bream, as until then the mortality caused by this parasite in younger age groups of common bream had not been a typical finding prior to 2008. The sporadic mortalities reported earlier had mostly been restricted to the older age groups of common bream. On the older common bream specimens caught in 2008 the presence of the usual number of *T. maculatus* copepods was noted; however, in addition to the local punctiform haemorrhages involving single scales, the occurrence of confluent haemorrhages extending to larger scaly areas was more frequently seen also on these fish. The number of deaths in these age groups of common bream roughly corresponded to that observed in the previous years. However, the non-negligible mortality rate observed

among the younger, 2- to 3-year-old common bream specimens was a novel feature. By laboratory examination, the accumulation of a serosanguineous exudate under the scales was detectable also in the affected areas still covered with scales. On some scales traces of attachment of copepods that had adhered to the scales but subsequently fallen off was noted; however, the copepods presumably fell off the body surface of these smaller-sized fish together with the scale serving as their site of attachment. All the affected fish transported to the laboratory died in the aquarium within a few days. Both the clinically affected fish and those free from clinical signs were pathologically emaciated. Although the bream is a less fleshy fish even under normal conditions, the body condition of the specimens caught during this survey was poorer than that typical of the Lake Balaton bream. It was also striking that younger bream specimens could be caught using a dragnet near the shoreline as previously it was only possible to catch young bream specimens only from the open waters or from the deep waters of harbours in the autumn or early spring. During a survey conducted in 2009, mortality of the younger bream age groups was not observed, and even among the older age groups only the periodic bream mortality typically found in the earlier years was recorded.

It follows from the biology of this crustacean parasite that its attachment to the body surface of fish requires strong scales. As opposed to *L. cyprinacea*, which fixes its anchors deep in the muscles beneath the pierced scale, the attachment of *T. maculatus* is limited to a single scale. It is presumed that in the year 2008, because of their presence in increased

numbers, *T. maculatus* parasites attacked also the smaller bream specimens but could not permanently establish themselves on them and, in the majority of cases, became detached from the fish together with the attacked scale. The scale injury caused by the parasite increased the chances of bacterial invasion. The limited common bream mortality, typically occurring in Lake Balaton in the period of warming up every year, is partly attributable to the damage done by *T. maculatus* and to secondary *A. hydrophila* infection through the wounds created by the female copepods attached to the scales. The direct cause of death is clearly the septicæmia caused by the facultative pathogenic bacterium *A. hydrophila*, but *T. maculatus* infestation opening the gate for this bacterial infection definitely plays a primary role in the pathogenesis of the disease.

In addition to the pathogen and the environment, the development of the disease greatly depends on the natural resistance of the fish as well. While the continuous improvement of the water quality of Lake Balaton is very pleasing, it is expected to be accompanied by a decrease in the abundance of food organisms available for fish. It was known already from studies conducted in previous years that the growth rate of common bream in Lake Balaton was substantially inferior to that of common bream specimens living in the Kis-Balaton water reservoir, in Lake Velence and in the river Danube more abundant in natural food (Pénzes, 1966; Specziár et al., 1997; Specziár and Tölg, 2000; Specziár and Rezsü, 2009). The feeding opportunities of the common bream stock in Lake Balaton cannot be considered optimal even at present. The increased intensity of *T. maculatus* infestation

in 2008 may be due to the conditions favouring the growth of the parasite and to the different reaction of younger common bream age groups to the infestation.

Acknowledgements

This work was supported by the Hungarian Scientific Research Fund (OTKA), project No. K 71837. We thank Györgyi Ostoros for preparing the histological sections. The help of our colleagues Gábor Cech and Olga Kelemen (Veterinary Medical Research Institute, Hungarian Academy of Sciences), as well as András Specziár and Géza Dobos (Balaton Limnological Research Institute of the Hungarian Academy of Sciences) in the fish collections is gratefully acknowledged.

References

- Boxhall GA and Frear PA (1990). *Tracheliastes maculatus* (Kollar, 1936) (Crustacea, Lernaepodidae), a new species for Britain. *Journal of Fish Biology* **37**, 489–491.
- Geyer F (1939). Über parasitische Lernaepodiden von Balaton Fischen (Ungarn). *Zoologische Anzeiger* **127**, 145–159.
- Grabda E and Grabda J (1958). Tracheliastosis in the common bream, *Abramis brama* L. in Lake Jamno. *Zoologica Poloniae* **8**, 325–334.
- Gussev AV, Poddubnaya AV and Avdeyeva VV (1987). Arthropoda Knidosporidii (Cnidosporidia). In: **“Key to the Parasites of Freshwater Fishes of the USSR”** (O. N. Bauer, Ed.). pp. 378–532. Nauka, Leningrad (in Russian).
- Molnár K (1965). On a parasitic copepod from Lake Balaton. *Halászat* **11**, 151 (in Hungarian).
- Molnár K (1966). Cohabitation of a parasitic copepod and ciliates. *Halászat* **12**, 111 (in Hungarian).
- Pénzes B (1966). Data on the growth of bream in Lake Balaton. In: **“Annals of the Balaton Limnological Research Institute of the Hungarian Academy of Sciences (Tihany)”**, 1966, Volume **33**, pp. 173–176. ISSN 1215-0584. (in Hungarian)
- Piasecki W (1989). Life cycle of *Tracheliastes maculatus* Kollar, 1835 (Copepoda, Siphonostomatoida, Lernaepodidae). *Wiadomosci Parasitologiczne* **35**, 187–245.
- Piasecki W and Avenant-Oldewage A (2008). Diseases caused by Crustacea. In: **“Fish diseases 2”** (Eiras, J. C. et al., Eds). Science Publishers Enfield (NH) **18**, 1115–1200.
- Specziár A and Rezsű ET (2009). Feeding guides and food resource partitioning in a lake fish assemblage: an ontogenetic approach. *Journal of Fish Biology* **75**, 247–267.
- Specziár A and Tölg L (2000). Investigations of the bream stock of Lake Balaton. *Halászat* **93** (3), 135–144. (in Hungarian)
- Specziár A, Tölg L and Bíró P (1997). Feeding strategy and growth of cyprinids in the littoral zone of Lake Balaton. *Journal of Fish Biology* **51**, 1109–1124.
- Walker PD, Abbink W, Van der Velde G and Bonga SEW (2006). A new record of *Tracheliastes maculatus* Kollar, 1835 (Copepoda, Siphonostomatoida, Lernaepodidae) on common bream (*Abramis brama* (L., 1758)) in the Netherlands. *Crustaceana* **79**, 1015–1019.