

## ***Plasmodium Vivax*–Associated Myopericarditis**

Ajinkya A. Sonambekar, Nikhil Gupta, Mukul P. Agarwal, Surendra Rajpal, Amitesh Aggarwal  
Department of Medicine, University College of Medical Sciences & GTB Hospital, Delhi, India

### **Abstract:**

*Plasmodium* infection in human beings is often associated with complications. Complications such as cerebral malaria, acute respiratory distress syndrome, acute kidney injury and cardiac complications including myocarditis, pericarditis and hypoglycaemia may be seen in infection by *Plasmodium falciparum*. However, these complications have rarely been reported with *Plasmodium vivax* infections. Myopericarditis complicating *P. vivax* malaria is particularly rare and only a few cases have been reported so far. We report on a case of myopericarditis due to *P. vivax* malaria to add to the literature

**Keywords:** Plasmodium vivax, malaria, myocarditis

**Received:** 23/12/2013

**Accepted:** 18/02/2014

**Published:** 28/04/2014

**How to cite this article:** Sonambekar AA, Gupta N, Agarwal MP, Rajpal S, Aggarwal A. Plasmodium vivax–Associated Myopericarditis, *EJCRIM* 2014;**1**:doi: 10.12890/2014\_000039

**Conflicts of Interests:** The authors declare that they have no conflicts of interest in this research.

### **Introduction**

Malarial fever continues to be an important public health problem in India. India contributes about 70% of the total reported cases of malaria in Southeast Asia. More than two-thirds of the Indian population live in zones where malaria is endemic. *Plasmodium vivax* accounts for nearly 50% of all malarial cases. *Plasmodium falciparum* infections are occasionally associated with complications like cerebral malaria, acute kidney injury, acute respiratory distress syndrome, severe anaemia, lactic acidosis, jaundice and hypoglycaemia. Myocarditis has also been reported. However, cardiac involvement in *P. vivax* infections is very rare<sup>1–3</sup>. We hereby report the case of a young female, 7 months pregnant, who developed myopericarditis along with acute kidney injury due to *P. vivax* infection.

## Case report

A 27-year-old woman, 3 months pregnant, presented to us with a history of high-grade fever associated with rigors for 10–12 days previously. There was a history of fever spike every third day with response to antipyretics. She gave a history of yellowish discoloration of the eyes and high coloured urine for the last 7–8 days, generalised body swelling for the last 4–5 days, and decreased urine output and cola-coloured urine for the last 2 days. There was no history of altered mentation, convulsions, bleeding from any site or decreased foetal movements. The patient had no history of any similar illness, hypertension, diabetes or cardiac disease in the past. Two previous pregnancies had been uneventful. On examination, the patient was conscious, oriented and febrile (temperature 39.2°C) with BP 110/74 mmHg and pulse rate 92 beats/min. She was pale and icteric with facial puffiness and bilateral pedal oedema. Jugular venous pressure was 11 cm H<sub>2</sub>O.

On systemic examination, cardiac examination revealed a pericardial rub with holosystolic murmurs in mitral and tricuspid areas, suggestive of mitral regurgitation (MR) and tricuspid regurgitation (TR), respectively. Abdominal examination revealed congestive hepatomegaly and a splenomegaly of 4 cm below the right costal margin, and uterus 26–28 weeks, relaxed with normal foetal heart sounds. The rest of the systemic examination was unremarkable.

On workup, her haemoglobin was 81 g/l, total leukocyte count 4,300 cells/cm<sup>3</sup>, platelet count 64,000 cells/cm<sup>3</sup>, blood urea nitrogen 19.7 mmol/l, serum creatinine 468.5 µmol/l, sodium 138 mmol/l, potassium 3.9 mmol/l and serum bilirubin 159 µmol/l with a direct fraction of 122.4. Serum glutamic-pyruvic transaminase was 5.16 µkat/l and serum glutamic oxaloacetic transaminase 0.96 µkat/l. Peripheral smear showed ring and schizont stages of *P. vivax* malaria. Blood and urine cultures were sterile. A Widal test and *Leptospira* slide macroagglutination test (MAT) were also negative. Viral serology for adenovirus, cytomegalovirus, coxsackievirus and echovirus was negative. Urinalysis revealed 12–15 red blood cells per high power field (HPF) and 2–3 pus cells/HPF with granular casts. Serum lactate dehydrogenase was raised, being 15.8 µkat/l. Arterial blood gas analysis was normal. A chest X-ray done with an abdominal shield suggested cardiomegaly.

Electrocardiography (ECG) revealed sinus tachycardia with ST depression and T-wave inversion in V2–6. (*Fig. 1*) Echocardiography showed mildly dilated left and right ventricles, left ventricular ejection fraction of 45%, with minimal pericardial effusion, and moderate MR and TR suggestive of myopericarditis. Cardiac enzymes were sought after echocardiography and were negative (CK-MB and Trop-T).

Artesunate-based antimalarial treatment was initiated. Fever responded and the patient improved clinically. Laboratory parameters gradually returned to normal.

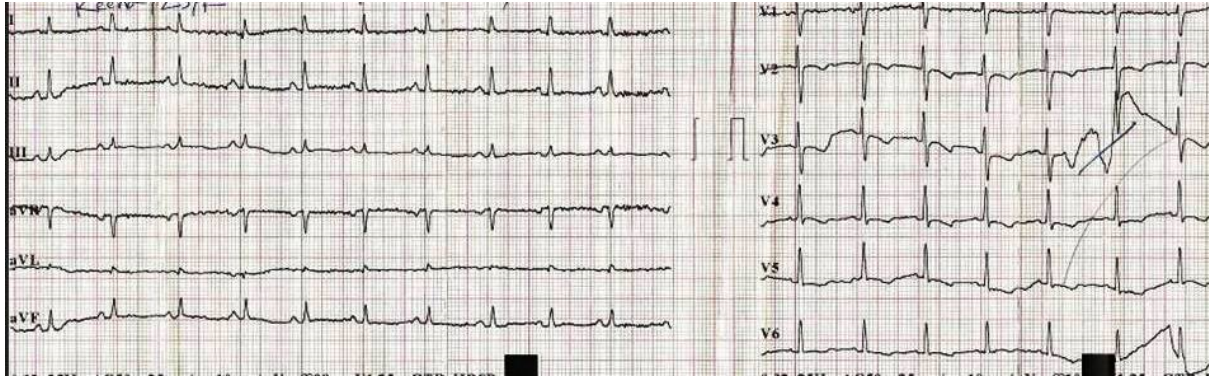


Figure 1: ECG showing sinus tachycardia with ST depression and T-wave inversion in V2–6.

A repeat echocardiography done after 7 days showed normal cardiac chambers with ejection fraction of 55% and no pericardial effusion. A repeat ECG done on the same day showed mild residual T-wave changes in V2–3 (Fig. 2).

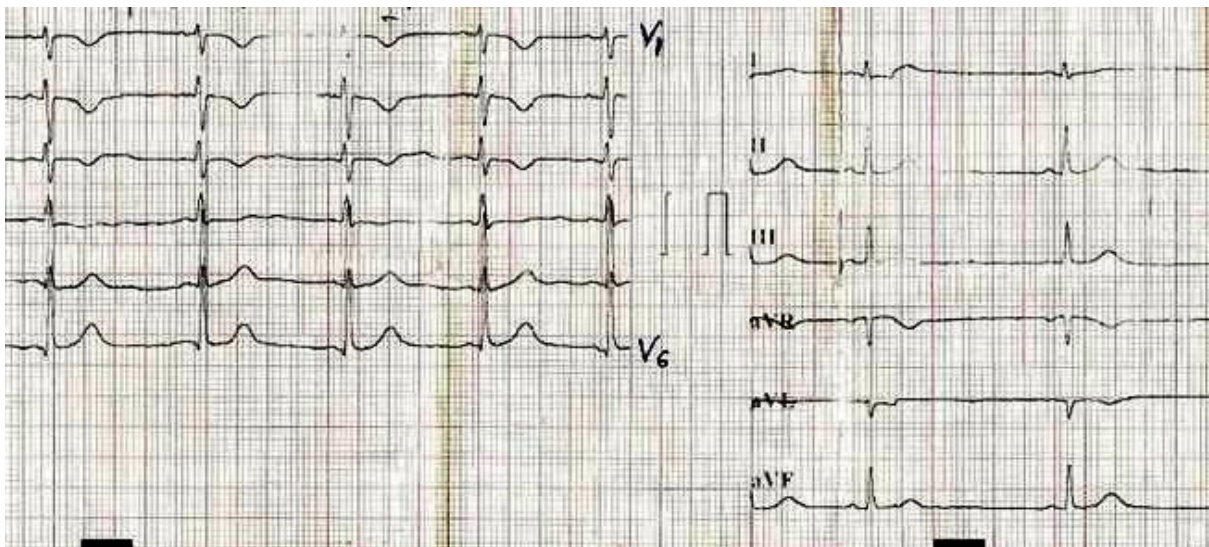


Figure 2: A repeat ECG done on the 7th day showing mild residual T-wave changes in V2–3.

## Discussion

The mechanism of cardiac involvement in malaria is not yet fully understood, but some theories have been proposed. It could be due to mechanical clogging of capillaries by parasitized red blood cells (PRBCs); severe acidosis may impair cardiac function. Polypeptides like tumour necrosis factor (TNF) are also implicated in the pathophysiological process<sup>4</sup>. TNF-like polypeptides enhance the secretion of thrombospondin, which causes sequestration of knob-bearing PRBCs. *P. vivax* has been demonstrated to cause both sequestration-related as well as non-sequestration-related complications of severe malaria<sup>5</sup>.

In our case, infection by *P. vivax* was confirmed by a peripheral smear, which is considered the gold standard for diagnosis of malaria and by clinical response to the treatment. The patient developed severe complications including hepatitis, acute kidney injury and severe anaemia within 4–5 days of

initiation of fever. In view of pericardial rub and holosystolic murmurs in the mitral and tricuspid areas, echocardiography was performed and was suggestive of myocardial involvement, along with evidence of pericarditis. Since myocarditis was not thought of earlier, cardiac enzymes were done only after the echocardiography and this could be the reason for the results being within normal limits. Repeat echocardiography after treatment showed reversal of the changes observed earlier.

In a gravid female, peripartum cardiomyopathy could be thought of as a differential diagnosis. However, this rare condition more commonly occurs in the last month of pregnancy and up to five months postpartum; it is associated with multiple pregnancies in women aged >30 years. In a 7-month gravid female with a single pregnancy in the setting of uneventful previous pregnancies, with improvement in cardiac functions after antimalarial treatment, the possibility of peripartum cardiomyopathy appears highly unlikely.

Keeping in mind the clinical presentation, other complications of *Plasmodium* infection and reversal of the cardiac involvement, a diagnosis of *P. vivax*-induced myopericarditis was made. This case report emphasizes the need to consider the possibility of myopericarditis in cases of *P. vivax*-induced sepsis, since timely detection can improve prognosis.

### Learning Points

1. Complications like myopericarditis do occur in *P. vivax* infections, though they are very rare. Only a few cases of myopericarditis due to *P. vivax* are reported in literature till date.
2. In a relevant clinical setting, prompt diagnosis and management of this life-threatening complication can be life-saving.
3. Myopericarditis due to *P. Vivax* infection is reversible with no long term sequel.

### References

1. Kim SA, Kim ES, Rhee MY et al. A case of myocarditis associated with *Plasmodium vivax* malaria, *J Travel Med* 2009;**16**:138–140.
2. Maheshwari M, Soni T. *Plasmodium vivax* malaria complicated by pericardial effusion, *Ind Med Gaz* 2012;**5**:199–201.
3. Gupta N, Sahoo SK. *Plasmodium vivax* induced myocarditis: a rare case report, *Indian J Med Microbiol* 2013;**31**:180–181.
4. Clarke A, Chaudhri G, Cowden WB. Roles of tumor necrosis factor in the illness and pathology of malaria, *Trans R Soc Trop Med Hyg* 1989;**83**:436–440.
5. Kochar DK, Saxena V, Singh N et al. A *Plasmodium vivax* malaria, *Emerg Infect Dis* 2005;**11**:132–134.