

Sternal wound dehiscence from intense coughing in a cardiac surgery patient: could it be prevented?

G. SANTARPINO, S. PFEIFFER, G. CONCISTRÉ, T. FISCHLEIN

SUMMARY: Sternal wound dehiscence from intense coughing in a cardiac surgery patient: could it be prevented?

G. SANTARPINO, S. PFEIFFER, G. CONCISTRÉ, T. FISCHLEIN

This case report is on a obese patient who underwent a coronary artery bypass. The immediate postoperative phase, on the 8th day, was

characterized by sternal dehiscence with diastasis, from intense coughing. At present, for obese patients there are not any guidelines aimed to prevent the sternal diastasis. The use of a sternum support vest after median sternotomy could be a valuable tool in the postoperative care of our patients, in order to avoid chest wall hyperexpansion and to prevent sternal wound dehiscence and diastasis.

KEY WORDS: Chest wall - Wound closure - Healing - Dehiscence - Outcomes.

A 67-year-old male hypertensive patient, height 160 cm and body weight 95 kg (body mass index 37.1 kg/m², second degree of abdominal obesity), underwent coronary artery bypass grafting under cardiopulmonary bypass. The intraoperative course was uncomplicated, and sternal closure was performed using four stainless steel wires in a figure-of-eight configuration. Intensive care unit stay was uneventful, and the patient was transferred to the recovery ward on the second postoperative day. Inspections of the surgical wound showed nothing noteworthy, with no evidence of sternal instability up to postoperative day 8 (one day prior to planned hospital discharge). After the medical visits in the morning, the patient began complaining of pressing anterior chest pain in the immediate post-prandial period as a result of violent coughing after inadvertent aspiration of food particles into the trachea.

On clinical evaluation, the patient showed sternal instability on palpation, and there was serosanguineous discharge from the wound. After a control computed tomography scan with color-coded three-dimensional reconstruction (anterior view, Figure 1), it was decided

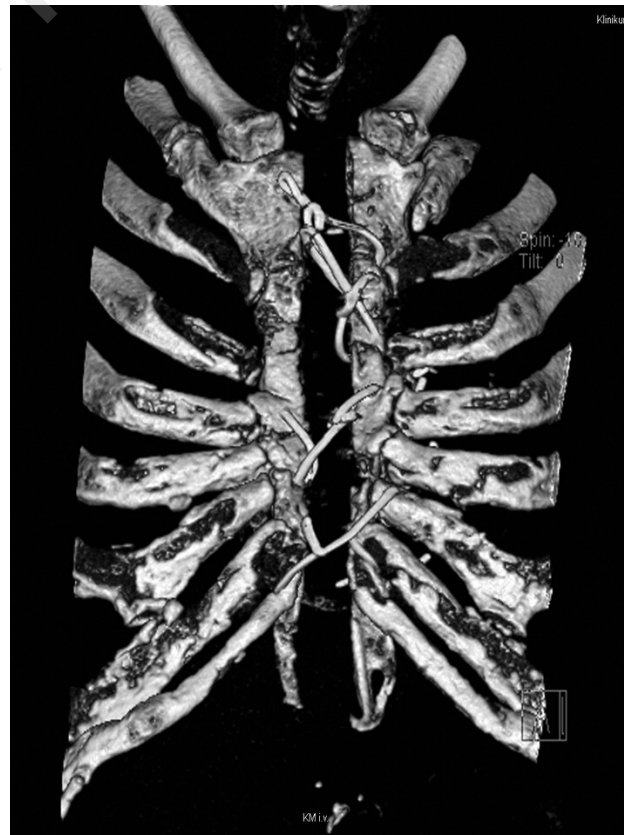


Fig. 1 - Chest computed tomography scan with color-coded three-dimensional reconstruction (anterior view) after the episode of intense coughing.

to perform surgical revision of the wound after placement of a vacuum-assisted closure system.

Discussion

This case aims at contributing to the contemporary debate regarding the ideal sternal closure technique, in particular in obese patients: is the use of four figure-of-eight stainless steel wires appropriate in patients with high body mass index? (1,2). This study does not allow us to establish whether the Robicsek's lateral support technique, and subsequent modifications (3), would have been more appropriate in our patient, or whether it should be considered as the first-line method for obese patients. At present, the optimal sternal closure technique still remains controversial. However, the increasing prevalence of obe-

sity both in the general population and the cardiac surgery setting makes the search for the best technique ever more important (4). The use of the new sternum support vest after median sternotomy (5) could be a valuable tool in the postoperative care of our patient, avoiding chest wall hyperexpansion during intense coughing fits and allowing adequate respiratory excursions. Chest expansion may occur not only after immediate postoperative orotracheal extubation but also later when the patient undergoes motor and respiratory rehabilitation. This should prompt us to get informed about the available sternum support devices and their use, especially in the in-hospital cardiological or rehabilitation clinic settings in order to prevent the occurrence of sternal wound complications as the one described here, which was successfully and rapidly treated also because the patient was still in the cardiac surgery environment.

References

1. Aykut K, Celik B, Acikel U. Figure-of-eight versus prophylactic sternal weave closure of median sternotomy in diabetic obese patients undergoing coronary artery bypass grafting. *Ann Thorac Surg* 2011;92:638-41.
2. Tekümit H, Cenal AR, Tataroğlu C, Uzun K, Akinci E. Comparison of figure-of-eight and simple wire sternal closure techniques in patients with non-microbial sternal dehiscence. *Anadolu Kardiyol Derg* 2009;9:411-6.
3. Tavilla G, van Son JA, Verhagen AF, Lacquet LK. Modified Robicsek technique for complicated sternal closure. *Ann Thorac Surg* 1991;52:1179-80.
4. Schimmer C, Reents W, Elert O. Primary closure of median sternotomy: a survey of all German surgical heart centers and a review of the literature concerning sternal closure technique. *Thorac Cardiovasc Surg* 2006;54:408-13.
5. Gortlitz M, Wagner F, Pfeiffer S, et al. A prospective randomized multicenter trial shows improvement of sternum related complications in cardiac surgery with the Posthorax support vest. *Interact Cardiovasc Thorac Surg* 2010;10:714-8.