

*G Chir Vol. 34 - n. 1/2 - pp. 27-31  
January-February 2013*

clinical practice

## Diagnosis of intra-abdominal injuries can be challenging in multitrauma patients with associated injuries. Our experience and review of the literature

N. KONTOPODIS, A. KOURAKI, G. PANAGIOTAKIS, O. MILIADIS, J. VOLAKAKIS, K. SPIRIDAKIS

**SUMMARY:** Diagnosis of intra-abdominal injuries can be challenging in multitrauma patients with associated injuries. Our experience and review of the literature.

N. KONTOPODIS, A. KOURAKI, G. PANAGIOTAKIS, O. MILIADIS, J. VOLAKAKIS, K. SPIRIDAKIS

**Introduction.** Trauma is the most common cause of death and disability among patients during the first four decades of life. Abdominal trauma is reported to be the 3rd most common injured region. Clinical examination may be unreliable in the evaluation of these patients especially in the presence of associated injuries. Therefore the use of diagnostic tools is essential in the management of the injured patient with abdominal trauma and additional injuries.

**Patients and Methods.** During 1 year period from December 2010 to November 2011 we recorded the patients that presented to the emergency department of our hospital and were found to suffer from intra-abdominal injuries. These patients were divided in two groups depending on whether they had additional comorbid injuries or not. Several parameters were recorded and compared between the two groups, such as mechanism of injury, general status and hemodynamic stability of the patient on presentation, physical examination, use of imaging

modalities and concomitant findings, need for surgical intervention and mortality rates. Furthermore the discrepancy between physical findings and final diagnosis after the use of diagnostic adjuncts is reported.

**Results.** We recorded 31 patients with abdominal trauma. 13 (42%) patients were found to suffer from abdominal trauma and associated injuries (Group I), whereas 18 (58%) presented with abdominal trauma alone (Group II). The patients of the first group presented hemodynamic instability in 38% of cases while the patients of the second in 22% of cases. Reduced consciousness was present in 38% in group I versus 17% in group II. Signs of abdominal injury during clinical examination were present in only 15% in group I versus 72% in group II that represented a remarkable difference between the two groups. Conservative treatment was possible in 15% of patients with additional injuries and in 22% of patients with abdominal injury alone. In group I there were two deaths whereas in group II all patients survived.

**Conclusion.** In patients with abdominal trauma, associated injuries seem to add to the severity of injury and indicate a worse prognosis. Clinical examination is unreliable and misleading in the majority of these patients and the use of diagnostic tools cannot be overemphasized.

KEY WORDS: Abdominal trauma - Associated injuries - Diagnostic tools - Imaging.

### Introduction

Trauma is the fifth most common cause of morbidity and mortality in the population whereas it is the most common cause of death and disability among patients during the first four decades of life (1,2). Abdomen seems to be the 3<sup>rd</sup> most common site of injury and surgical intervention is required in approximately 25% of the-

se patients (3). Missed intra-abdominal injuries are a frequent cause of morbidity and late mortality in injured patients with concealed hemorrhage being the 2<sup>nd</sup> most common cause of death after trauma (4).

The diagnosis of abdominal injuries abdominal trauma by clinical examination alone is unreliable because the symptoms and clinical signs can be mild even in serious injuries, especially in patients with associated injuries (5-7). Serious and complex mechanisms of injury often result in multiple injuries that may divert the physician's attention from potentially life-threatening intra-abdominal injuries. Therefore confirmation of the presence or absence of abdominal injury relies largely on the use of diagnostic tools. Late diagnosis and missed injuries are associated with a poor outcome (8). A recent study of patterns of abdominal injuries in trauma patients re-

port a 66,1% overall rate of additional comorbid injuries in patients with abdominal injuries which is even higher reaching 76,2% when referring to blunt abdominal trauma (9).

During the last year, in our department we came across 31 cases of abdominal injuries 13 of which were accompanied by associated injuries that made clinical evaluation challenging and required the use of imaging modalities to set the diagnosis. We report the patterns of injury, additional injuries, findings on physical examination and imaging techniques as well as injured intra-abdominal organs and need for surgical repair in both groups, to underline the importance of diagnostic tools when evaluating trauma patients with complex mechanism of injury resulting in multiple injuries.

## Patients and methods

During one year period from December /2010 to November 2011 we recorded the patients that presented to the emergency department of our hospital for intra-abdominal injuries. We came across 31 such patients that were divided in two groups depending on whether they had additional comorbid injuries (Group I) or not (Group II).

Several parameters were recorded, such as mechanism of injury, general status and hemodynamic stability of the patient, findings during physical examination, use of imaging modalities and concomitant findings. Also, need for surgical intervention as well as mortality rate were documented. The findings were compared between the two groups. Furthermore the findings of physical examination were compared to those of imaging techniques to determine the reliability of physical examination when evaluating patients with complex mechanisms of injury and multiple injuries. Ultrasound (Focused Assessment Sonography for Trauma, FAST), CT scan and Diagnostic Peritoneal Lavage (DPL) were used as diagnostic tools.

## Results

During the study period we recorded 31 patients with abdominal trauma that needed hospitalization and

either surgical or conservative management. These patients were divided in those with concurrent associated injuries and those that suffered from abdominal injuries only. The Group I included 13 (42%) patients that were diagnosed with various additional injuries whereas the Group II included 18 (58%) patients. Regarding the first group, 12 patients suffered from blunt abdominal trauma whereas 1 patient presented with penetrating trauma. The majority of the patients were involved in car and motor accidents (7 out of 13 patients) that included high speed accidents, overthrows, falls of cliffs etc, whereas less patients were injured after a fall usually from height >3m (5 out of 13 patients) and 1 patient suffered from a stab wound during an attempt for theft.

The additional coexisting injuries were in 5 cases head injuries, in 4 cases pelvic fractures, in 2 instances lower limb fractures, in one upper limb fractures and in one hemothorax. Figure 1 displays the relative presence of additional injuries in patients with abdominal trauma. Eight of these patients presented to the emergency department hemodynamically stable with a heart rate <100 bpm and systolic blood pressure >90mmHg; 5 patients had signs of hemodynamic instability (38% hemodynamically compromised patients). Eight patients presented in good mental status with GCS>13 (Glasgow Coma Score) whereas 5 patients had reduced consciousness meaning GCS <13 (38% reduced consciousness). With respect to patients with altered mental status the latter was attributed to head injuries in combination to secondary hypoxia due to hypoperfusion.

The physical findings from examination of the abdomen were poor in all 13 patients. With regard to the patients with reduced consciousness, signs of abdominal tenderness, rigidity and rebound tenderness were absent in all 5 patients. These patients had altered mental status, and were not complaining for any specific symptom. Clinical examination was considered unreliable and they all underwent imaging modalities to set the final dia-

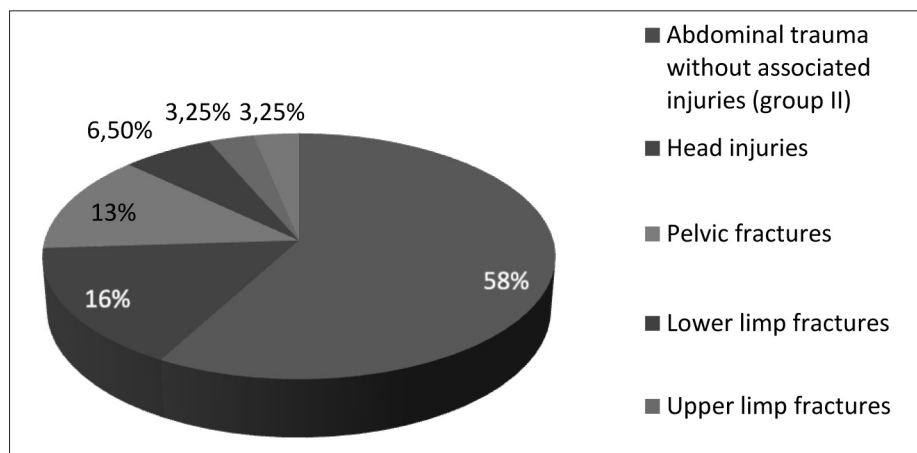


Fig. 1 - Relative presence of additional injuries in patients with abdominal trauma.

*Diagnosis of intra-abdominal injuries can be challenging in multitrauma patients with associated injuries. Our experience and review of the literature*

gnosis. With regard to conscious patients, signs of peritoneal irritation were present in only 2 out of 8 patients despite the fact that all of them were later proven to have suffered from serious intra-abdominal injuries. They were mostly complaining about pain in the anatomic sites that fractures had occurred as was pelvis, lower limbs and upper limbs in the same time that physical examination of the abdomen in most cases indicated no signs of injury. These patients underwent imaging procedures to determine whether there were abdominal injuries or not because of the complex and significant mechanisms of injury. In total, signs of intra-abdominal injury were present in 2 out of 13 patients of Group I meaning only in 15%.

The appropriate diagnostic techniques for all of these patients were determined from their hemodynamic condition. CT scan is considered more sensitive and specific in detecting abdominal injuries so a pan scan was performed in the 8 hemodynamically stable patients. In the remaining hemodynamically compromised 5 patients FAST was performed in three cases and DPL in the other two.

The intra-abdominal injuries as diagnosed from imaging techniques and intraoperative findings, when a laparotomy was performed, involved solid organs. In 7 cases there was a splenic injury and in 6 cases a liver injury. Out of 13 patients, a total of 11 patients underwent surgery, whereas 2 patients were managed conservatively. About laparotomies performed, 7 regarded splenectomy for splenic injuries and 4 liver packing or sutures for liver injuries. In the 2 cases managed by surveillance, liver was the injured intra-abdominal organ. Two out of 13 patients finally died during operation.

The group of patients that suffered from abdominal injuries alone included 18 (58%) of all patients (Group

II): of these, 13 patients presented with blunt, whereas 5 patients with penetrating abdominal trauma. A total of 14 patients were hemodynamic stable in the time of presentation and only 4 patients were hemodynamically compromised, a significantly lower rate when compared to the group of patients with concurrent injuries (38% hemodynamic instability in Group I vs 22% in Group II). Reduced consciousness was observed in 3 patients, 2 of which were intoxicated (38% in Group I vs 17% in Group II).

During physical examination signs of intra-abdominal injuries, meaning tenderness during palpation, abdominal rigidity and rebound tenderness, were found in 1 out of 3 patients with altered mental status and 12 out of 14 patients awake. Thus physical examination of the abdomen was indicative of abdominal injury in 13 of 18 patients (15% physical findings on clinical examination in Group I vs 72% in Group II). Comparison of the presence of physical signs during clinical examination for patients with abdominal trauma and associated injuries (Group I) and patients with abdominal injuries alone (Group II) is displayed in Figure 2.

Injured abdominal organs were spleen in 6 cases, liver in 5 cases, large bowel in 3 cases, urinary bladder in 2 cases, small bowel in 1 case and mesentery in one case. Four out of 18 patients were managed non-operatively all 3 with liver injuries and 1 with splenic trauma (15% of conservative treatment in Group I vs 22% in Group II). Comparison of hemodynamic instability, reduced consciousness and need for surgical intervention between patients with abdominal trauma and associated injuries (Group I) and in patients with abdominal injuries alone (Group II) are summarized in Figure 3. All patients in this group survived and were discharged from hospital.

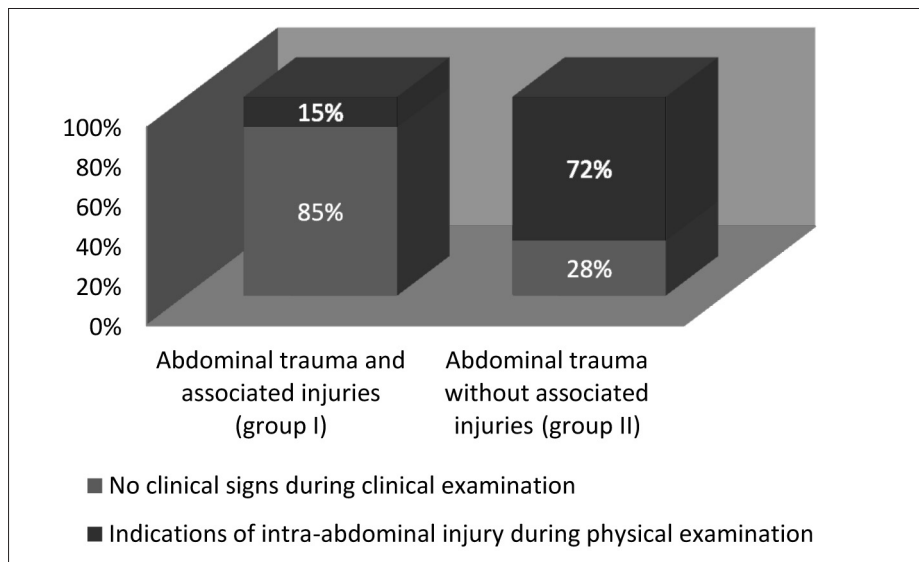


Fig. 2 - Comparison of the presence of physical signs of abdominal injury during clinical examination for patients with abdominal trauma and associated injuries (Group I) and patients with abdominal injuries alone (Group II).

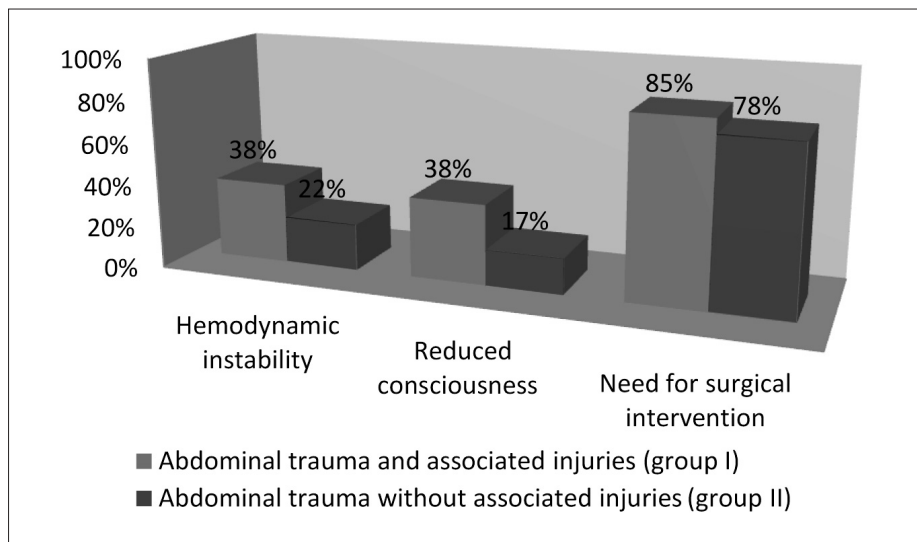


Fig. 3 - Comparison of hemodynamic instability, reduced consciousness and need for surgical intervention between patients with abdominal trauma and associated injuries (Group I) and in patients with abdominal injuries alone (Group II).

## Discussion

Trauma is a significant public health problem being the first cause of morbidity and mortality during the four first decades of life (1,2). Abdomen is reported to be the 3<sup>rd</sup> most commonly injured site (3). Evaluating a patient with abdominal trauma can be challenging as the diagnosis of abdominal injury by clinical examination alone can be unreliable. Therefore there is an important role for imaging techniques when evaluating such patients. This seems to be even more essential in patients with abdominal trauma and associated injuries. In our study physical examination of the abdomen was abnormal in 72% of patients with abdominal trauma alone (Group II) but only in 15% of patients with abdominal trauma and associated injuries (Group I). Therefore, in the same time that physical examination may miss a significant amount of injuries in patients of Group II, it has an impressively low sensitivity that makes it completely unreliable when evaluating patients of Group I. This underlines the important role of imaging modalities in the diagnosis and management of these patients. Furthermore the highest rate of reduced consciousness among patients with abdominal trauma and associated injuries when compared to abdominal trauma alone (38% vs 17%) makes the diagnosis of intra-abdominal injury in this group more hazardous and the use of appropriate diagnostics even more important. Finally it should be mentioned that a greater amount of patients with associated injuries presented with hemodynamic instability, required surgical intervention and finally died compared to patients with abdominal injury alone so that associated injuries seem to add to the severity of trauma being a marker of worse prognosis.

Other studies report similar findings, highlighting the role of imaging studies in the evaluation of trauma patients.

A large prospective observational study of one thousand patients with blunt polytrauma but no clinical signs of abdominal injury that underwent a pan scan found radiological evidence of injury in about 8.3% of these patients. This rate was even higher among patients with decreased consciousness due to head injuries or other reasons, reaching 10%. Treatment changes, meaning prompt hospital discharge or release to other services, admission for serial examination, change of a general admission to further evaluation of injuries (e.g., angiography, diagnostic peritoneal aspiration), and immediate operative intervention, occurred in 189 patients (18.9%) either because of findings on an abnormal scan or because of a normal scan (10).

The high rate of associated injuries in the same time with abdominal trauma makes the role of diagnostic tools even more important in the management of these patients. In our study this rate was 42% while others report even higher rates of 66,1% for both blunt and penetrating abdominal trauma and which reaches 76,2% for blunt abdominal trauma (9). Additional injuries have been found to be markers of worse prognosis in our study. Similar findings are reported by other groups that found the presence of a pelvic fracture to add to the severity of the injured patient with abdominal trauma (11). In the literature, DPL, ultrasound and CT scan are reported as the main diagnostic tools widely used for trauma patients. DPL has been proved to be a highly accurate (sensitivity 95%, specificity 99%) test for detection of intraperitoneal blood or gastrointestinal context (12). It can be used in the resuscitation area so it could add in the diagnosis of the hemodynamically compromised patient. On the other hand DPL can not specify the site of injury, has a high rate of false positive results in the presence of pelvic fractures and does not exclude retroperitoneal injury (13). Furthermore it is an invasive procedure that carries



*Diagnosis of intra-abdominal injuries can be challenging in multitrauma patients with associated injuries. Our experience and review of the literature*

a small risk of visceral injury (0, 6%) (12). On the other hand ultrasound is non-invasive, is repeatable, and similarly to DPL can be performed in the emergency department, concurrently with other aspects of resuscitation. A recent review reports a sensitivity of 74% for organ injury (14). The resulting consensus guideline concluded that ultrasound is not a satisfactory imaging modality for hemodynamically stable patients, because up to a quarter of hepatic and splenic injuries, most renal injuries, and almost all pancreatic, mesenteric, bladder, and gut injuries may be missed (14). A negative ultrasound does not rule out injury, and if ultrasound is used as the sole imaging modality, patients should be admitted for observation and possibly to repeat examination (14,15). Computed tomography is the imaging modality of choice for evaluating hemodynamically stable patients being both sensitive (92-97.6%) and specific (98.7%) (14,16). It can detect contrast extravasation and also evaluate the retroperitoneal space (17). Furthermore several high quality prospective and retrospective studies have shown non-operative management of solid organ injury to be safe and effective, and evaluation of the injuries with CT scan plays an important role in such therapeutic decisions (8,18). Additionally, a large prospective multicenter study

showed that a normal abdominal computed tomography scan has a high negative predictive value (99.63%), and that admission for observation may not be necessary in the presence of a normal abdominal CT scan, but this needs to be further investigated (5). On the other hand besides ionizing radiation CT's main disadvantage is that usually, requires the patient to move away from the resuscitation area, thus being useful only in hemodynamically stable patients.

## Conclusion

In the evaluation of patients with abdominal trauma and additional comorbid injuries physical examination can be unreliable and misleading. The use of diagnostic tools in the evaluation and management of these patients cannot be overemphasized. Ultrasound is the investigation of choice in the presence of hemodynamic instability. A negative result does not rule out injury and the patient should be admitted for observation and possible repeat examination. CT scan is superior in hemodynamic stable patients contributing to both diagnosis and decision making in the management of these patients.

## References

1. Pre Hospital Trauma Life Support, 6th edition p. 1-11.
2. Advanced Trauma Life Support, Course Manual, 7th edition 2002, p.1-12.
3. Hemmila MR, Wahl WL. Management of the injured patient. Doherty GM, Current Surgical Diagnosis and Treatment, McGraw-Hill Medical;2008, p.227-8.
4. Gilroy D. Deaths from blunt trauma, after arrival at hospital: plus ça change, plus c'est la même chose. *Injury* 2005;36:47-50.
5. Livingston DH, Lavery RF, Passannante MR, Skurnick JH, Fabian TC, Fry DE, et al. Admission or observation is not necessary after a negative abdominal computed tomographic scan in patients with suspected blunt abdominal trauma: results of a prospective, multiinstitutional trial. *J Trauma* 1998;44:273-80.
6. Isenhour JL, Marx J. Advances in abdominal trauma. *Emerg Med Clin North Am* 2007;25:713-33.
7. National Confidential Enquiry into Perioperative Deaths (NCEPOD). Trauma: who Cares? London: NCEPOD, 2007.
8. Jansen JO, Yule SR, Loudon MA. Investigation of blunt abdominal trauma. *Clinical Review. BMJ* 2008;336:938-42.
9. Mohamad A Gad, Ali Saber, Sheirif Harag, Mohamed E Shams, Goda M Ellaban. Incidence, patterns and factors predicting Mortality of Abdominal Injuries in Trauma Patients. *N Am J Med Sci* 2012;4(3):129-34.
10. Ali Salim, Burapat Sangthong, Matthew Martin, Carlos Brown, David Plurad, Demetrios Demetriades. Whole Body Imaging in Blunt Multisystem Trauma Patients Without Obvious Signs of Injury Results of a Prospective Study. *Arch Surg* 2006;141.
11. Roberto De Moraes Cordts Filho, José Gustavo Parreira, Jaqueline A. Giannini Perlingeiro, Silvia C. Solda, Tercio De Campos, José Cesar Asséf. Pelvic fractures as a marker of injury severity in trauma patients. *Rev. Col. Bras. Cir.* 2011;38(5):310-315.
12. Nagy KK, Roberts RR, Joseph KT, Smith RF, An GC, Bokhari F, et al. Experience with over 2500 diagnostic peritoneal lavages. *Injury* 2000;31:479-82.
13. Bain IM, Kirby RM, Tiwari P, McCraig J, Cook AL, Oakley PA, et al. Survey of abdominal ultrasound and diagnostic peritoneal lavage for suspected intra-abdominal injury following blunt trauma. *Injury* 1998;29:65-71.
14. Shuman WP, Holtzman SR, Bree RL, Bettman MA, Cascani T, Foley WD, et al. American College of Radiology appropriateness criteria. Blunt abdominal trauma. 2005. [www.acr.org/SecondaryMainMenuCategories/quality\\_safety/app\\_criteria/pdf/ExpertPanelonGastrointestinalImaging.aspx](http://www.acr.org/SecondaryMainMenuCategories/quality_safety/app_criteria/pdf/ExpertPanelonGastrointestinalImaging.aspx).
15. Myers J. Focused assessment with sonography for trauma (FAST): the truth about ultrasound in blunt trauma. *J Trauma* 2007;62:S28.
16. Hoff WS, Holevar M, Nagy KK, Patterson L, Young JS, Arrillaga A, et al; Eastern Association for the Surgery of Trauma. Practice management guidelines for the evaluation of blunt abdominal trauma: the EAST practice management guidelines work group. *J Trauma* 2002;53:602-15.
17. Yao DC, Jeffrey RB, Mirvis SE, Weekes A, Federle MP, Kim C, et al. Using contrast-enhanced helical CT to visualize arterial extravasation after blunt abdominal trauma: incidence and organ distribution. *AJR Am J Roentgenol* 2002;178:17-20.
18. Velmahos GC, Toutouzas KG, Radin R, Chan L, Demetriades D. Nonoperative management of blunt injury to solid abdominal organs: a prospective study. *Arch Surg* 2003;138:844-51.