



Year: 2017

Noninvasive epicardial and endocardial mapping of premature ventricular contractions

Wissner, Erik; Revishvili, Amiran; Metzner, Andreas; Tsyganov, Alexey; Kalinin, Vitaly; Lemes, Christine; Saguner, Ardan M; Maurer, Tilman; Deiss, Sebastian; Sopov, Oleg; Labarkava, Eugene; Chmelevsky, Mikhail; Kuck, Karl-Heinz

Abstract: AIMS: The aim of the present study was to estimate the accuracy of a novel non-invasive epicardial and endocardial electrophysiology system (NEEES) for mapping ectopic ventricular depolarizations. **METHODS AND RESULTS:** The study enrolled 20 patients with monomorphic premature ventricular contractions (PVCs) or ventricular tachycardia (VT). All patients underwent pre-procedural computed tomography or magnetic resonance imaging of the heart and torso. Radiographic data were semi-automatically processed by the NEEES to reconstruct a realistic 3D model of the heart and torso. In the electrophysiology laboratory, body-surface electrodes were connected to the NEEES followed by unipolar EKG recordings during episodes of PVC/VT. The body-surface EKG data were processed by the NEEES using its inverse-problem solution software in combination with anatomical data from the heart and torso. The earliest site of activation as denoted on the NEEES 3D heart model was compared with the PVC/VT origin using a 3D electroanatomical mapping system. The site of successful catheter ablation served as final confirmation. A total of 21 PVC/VT morphologies were analysed and ablated. The chamber of interest was correctly diagnosed non-invasively in 20 of 21 (95%) PVC/VT cases. In 18 of the 21 (86%) cases, the correct ventricular segment was diagnosed. Catheter ablation resulted in acute success in 19 of the 20 (95%) patients, whereas 1 patient underwent successful surgical ablation. During 6 months of follow-up, 19 of the 20 (95%) patients were free from recurrence off antiarrhythmic drugs. **CONCLUSION:** The NEEES accurately identified the site of PVC/VT origin. Knowledge of the potential site of the PVC/VT origin may aid the physician in planning a successful ablation strategy.

DOI: <https://doi.org/10.1093/europace/euw103>

Posted at the Zurich Open Repository and Archive, University of Zurich

ZORA URL: <https://doi.org/10.5167/uzh-135292>

Published Version



Originally published at:

Wissner, Erik; Revishvili, Amiran; Metzner, Andreas; Tsyganov, Alexey; Kalinin, Vitaly; Lemes, Christine; Saguner, Ardan M; Maurer, Tilman; Deiss, Sebastian; Sopov, Oleg; Labarkava, Eugene; Chmelevsky, Mikhail; Kuck, Karl-Heinz (2017). Noninvasive epicardial and endocardial mapping of premature ventricular contractions. *Europace*, 19(5):843-849.

DOI: <https://doi.org/10.1093/europace/euw103>

Noninvasive epicardial and endocardial mapping of premature ventricular contractions

Erik Wissner^{1*}, Amiran Revishvili², Andreas Metzner¹, Alexey Tsyganov³, Vitaly Kalinin³, Christine Lemes¹, Ardan M. Saguner¹, Tilman Maurer¹, Sebastian Deiss¹, Oleg Sopov², Eugene Labarkava², Mikhail Chmelevsky³, and Karl-Heinz Kuck¹

¹Asklepios Klinik St Georg, Hamburg, Germany; ²Bakoulev Scientific Centre for Cardiovascular Surgery, Moscow, Russia; and ³EP Solutions SA, Yverdon-les-Bains, Switzerland

Received 5 December 2015; accepted after revision 15 March 2016

Aims

The aim of the present study was to estimate the accuracy of a novel non-invasive epicardial and endocardial electrophysiology system (NEEES) for mapping ectopic ventricular depolarizations.

Methods and results

The study enrolled 20 patients with monomorphic premature ventricular contractions (PVCs) or ventricular tachycardia (VT). All patients underwent pre-procedural computed tomography or magnetic resonance imaging of the heart and torso. Radiographic data were semi-automatically processed by the NEEES to reconstruct a realistic 3D model of the heart and torso. In the electrophysiology laboratory, body-surface electrodes were connected to the NEEES followed by unipolar EKG recordings during episodes of PVC/VT. The body-surface EKG data were processed by the NEEES using its inverse-problem solution software in combination with anatomical data from the heart and torso. The earliest site of activation as denoted on the NEEES 3D heart model was compared with the PVC/VT origin using a 3D electroanatomical mapping system. The site of successful catheter ablation served as final confirmation. A total of 21 PVC/VT morphologies were analysed and ablated. The chamber of interest was correctly diagnosed non-invasively in 20 of 21 (95%) PVC/VT cases. In 18 of the 21 (86%) cases, the correct ventricular segment was diagnosed. Catheter ablation resulted in acute success in 19 of the 20 (95%) patients, whereas 1 patient underwent successful surgical ablation. During 6 months of follow-up, 19 of the 20 (95%) patients were free from recurrence off antiarrhythmic drugs.

Conclusion

The NEEES accurately identified the site of PVC/VT origin. Knowledge of the potential site of the PVC/VT origin may aid the physician in planning a successful ablation strategy.

Keywords

Non-invasive imaging • Non-invasive epicardial and endocardial electrophysiology system • Premature ventricular contraction • Ventricular tachycardia • Ventricular arrhythmias

Introduction

To understand the underlying mechanism and treatment of cardiac rhythm disorders, it is essential to correctly localize regional cardiac electrical activity and to delineate its activation and recovery sequence. The standard 12-lead surface EKG is commonly used, though it provides insufficient information about the accurate localization of the site of origin (SOO) of PVC or focal VT. In clinical practice, the SOO of cardiac arrhythmias and the sequence of

cardiac excitation are commonly determined using invasive 3D electroanatomical mapping systems. However, these mapping systems may face significant limitations in addition to their invasive nature, in particular in patients presenting with non-sustained or haemodynamically intolerant arrhythmias. In recent years, great progress has been made to develop a method that provides extensive information on cardiac electrical activity on the basis of potentials observed from the body surface. Simultaneous acquisition of 3D anatomical and EKG data obtained by computed tomography

* Corresponding author. Erik Wissner, MD, Consultants in Cardiology and Electrophysiology, 5151 W 95th St, Floor 2, Oak Lawn, IL 60453, USA. Tel: +1 312 945 1177; E-mail address: ewissner@yahoo.com

© The Author 2016. Published by Oxford University Press on behalf of the European Society of Cardiology.

This is an Open Access article distributed under the terms of the Creative Commons Attribution Non-Commercial License (<http://creativecommons.org/licenses/by-nc/4.0/>), which permits non-commercial re-use, distribution, and reproduction in any medium, provided the original work is properly cited. For commercial re-use, please contact journals.permissions@oup.com

What's new?

- A novel non-invasive epicardial and endocardial electrophysiology system accurately identified the site of PVC/VT origin
- Use of the novel non-invasive epicardial and endocardial electrophysiology system before invasive mapping may aid in identifying the optimal ablation strategy

(CT) or magnetic resonance imaging (MRI) and multi-channel body-surface EGG recordings, the latter processed by mathematical algorithms in order to solve the inverse problem of electrocardiography, allows for non-invasive imaging of human cardiac electrical activity. Recently, non-invasive mapping of both epicardial and endocardial surfaces,^{1,2} applying novel numerical algorithms,^{3,4} has been introduced into clinical practice.

The aim of the present study was to evaluate the feasibility of a novel non-invasive epicardial and endocardial electrophysiology system (NEEES, EP Solutions SA, Yverdon-les-Bains, Switzerland) for the diagnosis of focal ventricular arrhythmias.

Methods

Patient selection

A total of 20 symptomatic patients with ectopic ventricular arrhythmias were enrolled. Pre-procedural examination included a baseline 12-lead surface EKG, a 24-h Holter monitor, and transthoracic echocardiography. Nineteen patients presented with monomorphic PVCs ($n = 16$) or VT ($n = 3$). One patient presented with two different PVC morphologies. In one patient, a left ventricular diverticulum was present. The remaining patients had no underlying structural heart disease.

The study was approved by the institutional review board. Written informed consent was obtained from all patients.

Non-invasive epicardial and endocardial electrophysiology system

The methodology of non-invasive imaging using the NEEES has been previously described in detail.² Briefly, up to 28 custom-made vertical arrays incorporating 8 unipolar EKG electrodes each (for a maximum

of 224 MRI or CT compatible electrodes) were placed onto the patient's torso, followed by same-day contrast MRI (Magnetom Avanto, 1.5 T, Siemens, Germany) or EKG-gated CT (Somatom Definition Flash 128, Siemens, Germany) scanning of the heart and thorax.

Computed tomography or MRI data imported in the DICOM format were automatically processed by the NEEES to render a realistic 3D reconstruction of the torso geometry and surface electrodes' positions. The 3D heart model was plotted semi-automatically, and segmentation was performed using custom 3D editor software as part of the NEEES. Following heart and torso segmentation and volume reconstruction, the surfaces of the torso and cardiac chambers were triangulated and polygonal meshes were built.

Non-invasive mapping was completed at the patient's bedside before the invasive procedure. The electrode arrays were connected to the NEEES multi-channel EKG amplifier, and ≥ 4 PVC/VT beats were recorded using a bandwidth of 0.05–500 Hz, a sampling rate of 1000 samples/s, and an optional notch filter of 50 Hz. Electrocardiogram recording was performed during unrestricted breathing because some patients had only rare PVCs. Data from the body-surface EKG were processed by the NEEES using its inverse problem solution software in combination with anatomical data derived from MRI or CT of the heart and torso (Figure 1). A brief description of the numerical algorithms applied is provided as Supplementary material online, File S1.

The resulting epicardial and endocardial isopotential maps were reconstructed on the 3D volume and polygonal cardiac model and displayed as individual frames or activation movies. Isopotential maps of a minimum of four PVC/VT beats of identical morphology were analysed to determine the earliest zone of electrical activation. The centre of the zone of negative potentials spreading in a centrifugal fashion during early depolarization was considered the SOO. In some patients, electric potentials varied from -1 to -2 mV, a range comparable with the expected level of noise of the reconstructed electrograms. Conversely, a negative potential level exceeding 8 mV corresponded to a later stage of myocardial activation. Therefore, electric potentials from -3 to -8 mV were considered as the window of interest to localize the SOO. To enhance visualization of the activation sequence, isochronal and propagation maps were built using the maximum $-dU/dt$ approach.

Invasive 3D mapping and catheter ablation

The procedure was performed under conscious sedation using continuous infusion of 1% propofol. All patients underwent invasive mapping using a 3D electroanatomical mapping system (CARTO 3, Biosense Webster, Diamond Bar, CA, USA). Activation maps were reconstructed

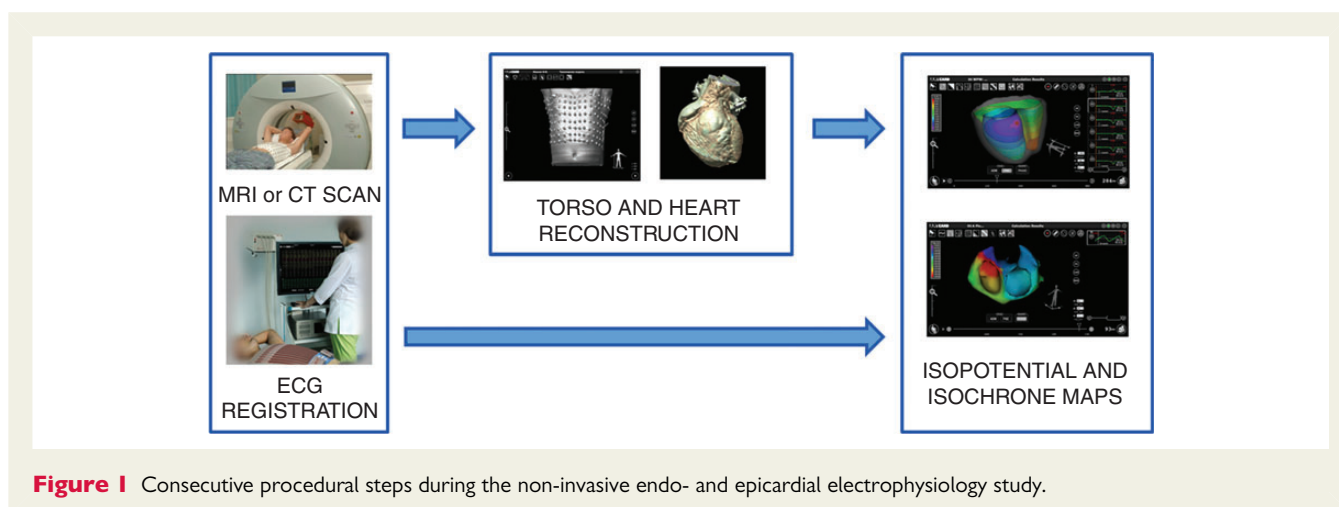


Figure 1 Consecutive procedural steps during the non-invasive endo- and epicardial electrophysiology study.

during episodes of clinical PVC or stable VT. Catheter ablation was performed using an irrigated-tip catheter (ThermoCool Navistar, Biosense Webster) applying a power of 30–50 W. If ablation was performed at the coronary cusps, energy delivery was limited to a maximum of 30 W. Acute procedural success was defined as freedom from recurrent clinical PVC/VT either occurring spontaneously or provoked by intravenous isoproterenol infusion during a 30-min waiting period that followed the last energy application.

A 12-lead surface EKG and 24-h Holter monitor the day before, the day after, and 6 months following the ablation procedure was completed in each patient. Late recurrence was defined as ≥ 1000 monomorphic PVCs on 24-h Holter monitoring or documentation of sustained monomorphic VT.

Detection of premature ventricular contraction/ventricular tachycardia origin comparing the non-invasive and invasive mapping systems

During the initial step, consecutive ectopic beats were analysed to reproducibly define the focal SOO. Foci were displayed on separate non-invasive isopotential maps, the latter of which were based on anatomical data derived from CT or MRI. In a second step, all non-invasively determined foci were marked on the same cardiac model and the distance between each was measured using the ‘ruler’ tool of the NEEES software.

Next, the NEEES data were compared with the results of the invasive procedure. The left ventricle (LV) was divided into 16 segments: right coronary cusp (RCC), left coronary cusp (LCC), aorto-mitral continuity (AMC), anterior mitral valve (MV), septal MV, posterior MV, lateral MV, basal anterior LV, basal septal LV, basal posterior LV, basal lateral LV, mid-anterior LV, mid-septal LV, mid-posterior LV, mid-lateral LV, and apical LV. The right ventricle (RV) was divided into 18 segments: anterior RV outflow tract (RVOT), lateral RVOT, posterior RVOT, septal RVOT, anterior tricuspid valve (TV), lateral TV, posterior TV, septal TV, parahisian (PH) RV, basal anterior RV, basal lateral RV, basal posterior RV, basal septal RV, mid-anterior RV, mid-lateral RV, mid-posterior RV, mid-septal RV, and apical RV (Figure 2).

Preceding the invasive electrophysiology study, the NEEES data were analysed and the PVC/VT was categorized as RV or LV in origin and then subcategorized according to the RV/LV segment. During invasive mapping, the SOO was localized using the CARTO 3 system and compared with the SOO predicted by the NEEES. The SOO was considered identical if localized within the same heart segment. Final confirmation of the SOO was made by successful catheter ablation.

Results

A total of 21 different types of PVC/VT in 20 patients were targeted for ablation. Catheter ablation was successful in 19 of the 20 (95%) patients. At 6-month follow-up off AAD, 19 of the 20 (95%) patients were free from recurrent PVC/VT.

Reproducibility of premature ventricular contraction/ventricular tachycardia localization using the non-invasive epicardial and endocardial electrophysiology system

In all patients, the non-invasively predicted SOO for consecutive PVC/VT beats was localized within the same cardiac segment. The distance between any two foci during consecutive PVC/VT beats was ≤ 6 mm.

Premature ventricular contraction/ventricular tachycardia site of origin

The PVC/VT SOO for all patients are summarized in Table 1. In 12 of the 21 (57%) patients, the PVC/VT emanated from the RV; 6 of the 21 (29%) patients PVC/VT originated from the RVOT; and 6 of the 21 (29%) patients PVC/VT arose from other RV sites. One patient had two ectopic foci originating from the posterolateral wall of the RVOT and the mid-lateral RV wall. This latter case is illustrated in Figures 3–6 and in Supplementary material online, Videos S1–S4.

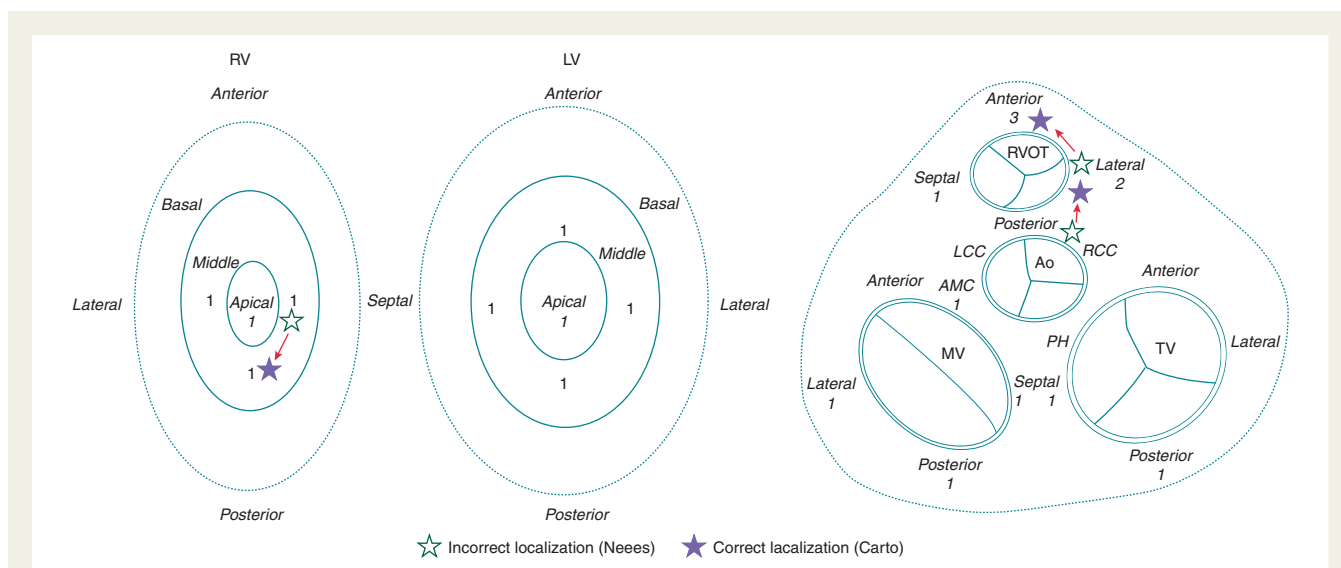


Figure 2 Diagram of segmentation of the ventricles. Detailed are the numbers of PVC/VT foci within the respective ventricular segment. Cases incorrectly identified by non-invasive mapping are marked within the diagram.

Table 1 Patient characteristics, origin of ventricular arrhythmias, correlation between NEEES/S and invasive Carto 3 mapping system, and acute catheter ablation outcome

No.	Sex	Age	Diagnosis	Type of tachycardia	Imaging modality	Location (Carto 3)		Location (NEEES)		Results (Carto 3 vs. NEEES)		Acute procedural outcome
						Ventricle	Site	Ventricle	Site	Ventricle	Site	
1	Male	67	Idiopathic	PVC	MRI	LV	Lateral MV	LV	Lateral MV	Identical	Identical	Successful
2	Male	65	Idiopathic	PVC	MRI	RV	Posterolateral RVOT	RV	Posterolateral RVOT	Identical	Identical	Successful
						RV	Mid-lateral RV	RV	Lateral RV apex	Identical	Identical	Successful
3	Male	79	Idiopathic	VT	CT	LV	Posterior MV	LV	Posterior MV	Identical	Identical	Successful
4	Female	36	Idiopathic	PVC	MRI	RV	Lateral RVOT	LV	Right coronary cusp	Error	Error	Successful
5	Male	54	Idiopathic	PVC	MRI	LV	Aortomitral continuity	LV	Aortomitral continuity	Identical	Identical	Successful
6	Male	18	Idiopathic	PVC	CT	LV	Mid-septal	LV	Mid-septal	Identical	Identical	Failed
7	Female	53	Idiopathic	PVC	CT	RV	Anterior RVOT	RV	Lateral RVOT	Identical	Error	Successful
8	Male	31	Idiopathic	PVC	CT	RV	Anterior RVOT	RV	Anterior RVOT	Identical	Identical	Successful
9	Male	31	Idiopathic	PVC	CT	RV	Anterior RVOT	RV	Anterior RVOT	Identical	Identical	Successful
10	Female	39	Idiopathic	PVC	CT	RV	Posterior TV	RV	Posterior TV	Identical	Identical	Successful
11	Female	60	Idiopathic	PVC	CT	LV	Mid-posterior	LV	Mid-posterior	Identical	Identical	Successful
12	Male	32	Idiopathic	PVC	CT	LV	Mid-lateral	LV	Mid-lateral	Identical	Identical	Successful
13	Female	27	Idiopathic	PVC	CT	RV	Apical	RV	Apical	Identical	Identical	Successful
14	Female	53	Idiopathic	PVC	CT	LV	Septal MV	LV	Septal MV	Identical	Identical	Successful
15	Male	32	Idiopathic	PVC	CT	LV	Mid-anterior	LV	Mid-anterior	Identical	Identical	Successful
16	Male	47	Idiopathic	PVC	CT	RV	Mid-septal	RV	Mid-posterior	Identical	Error	Successful ^a
17	Male	62	Idiopathic	PVC	CT	RV	Septal TV	RV	Septal TV	Identical	Identical	Successful
18	Female	33	Idiopathic	PVC	CT	RV	Mid-septal	RV	Mid-septal	Identical	Identical	Successful
19	Male	46	Diverticulum	VT	CT	LV	Apical	LV	Apical	Identical	Identical	Failed; surgical ablation successful
20	Female	23	Idiopathic	VT	CT	RV	Septal RVOT	RV	Septal RVOT	Identical	Identical	Successful

PVC, premature ventricular contraction; VT, ventricular tachycardia; LV, left ventricle, RV, right ventricle; RVOT, right ventricular outflow tract; TV, tricuspid valve; MV, mitral valve; RFA, radiofrequency ablation; CT, computed tomography; MRI, magnetic resonance imaging.

^aPVC recurrence at 3-month follow-up.

Left ventricular PVC/VT originated from the AMC in one, the mid-septal LV in one, the mid-posterior LV in one, the mid-anterior LV in one, the lateral MA in one, the septal MV in one, the posterior MV in one, and the lateral LV in one patient, respectively. In one patient, VT originated from a diverticulum located at the LV apex.

Correlation between non-invasive and invasive mapping

The NEEES correctly identified the chamber of interest in 20 of the 21 (95%) PVC/MTs and the respective ventricular segment in 18 of the 21 (86%) PVC/MTs. In 3 of the 21 (14%) PVC/MTs, the NEEES

failed to provide the correct SOO. In the first case, the NEEES predicted the SOO at the RCC, but successful ablation was performed within the RVOT. In the second case, the predicted origin of PVC was from the lateral wall of the RVOT, while successful ablation was achieved targeting the anterior aspect of the RVOT. In the third case, the predicted PVC SOO was from the mid-lateral segment of the RV, but ablation was successful at the mid-posterior segment of the RV. In the latter case, acute procedural success was followed by PVC recurrence at 3-month follow-up.

In one patient, an LV diverticulum was found on cardiac MRI. The NEEES and CARTO 3 mapping system indicated that the VT originated from the diverticulum at the LV apex, but catheter ablation was unsuccessful. The patient underwent successful surgical cryoablation.

Table 1 compares the results of the NEEES and invasive mapping and details the outcome of catheter ablation. Those cases incorrectly diagnosed by the NEEES are summarized in Figure 2.

Discussion

A variety of non-invasive imaging systems to display electrical cardiac activity have been used as diagnostic tools in clinical cardiac electrophysiology.^{5–8} The method of non-invasive electrocardiographic imaging (ECGI) has demonstrated significant clinical relevance, allowing non-invasive reconstruction of local unipolar electrograms (EG) on the epicardial surface of the heart.⁵ Advanced processing of reconstructed EG provides information on the cardiac activation sequence, the SOO of abnormal cardiac excitation and details about the arrhythmogenic substrate.^{9–11} The use of ECGI may facilitate rapid diagnosis of ventricular arrhythmias. Data from a randomized trial¹² demonstrated that the SOO of focal PVC could be detected in 95% of cases. Cakulev *et al.*¹³ reported that in 8 of the 10 (80%) patients with PVCs, the ECGI correctly identified the ventricular SOO, as confirmed by successful ablation at these sites.

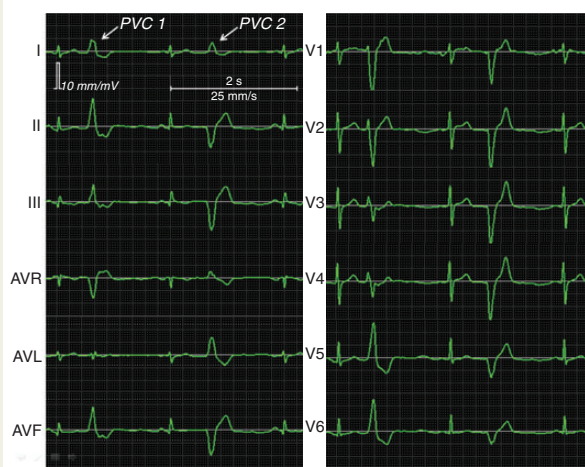


Figure 3 12-Lead surface EKG demonstrating two different PVC morphologies.

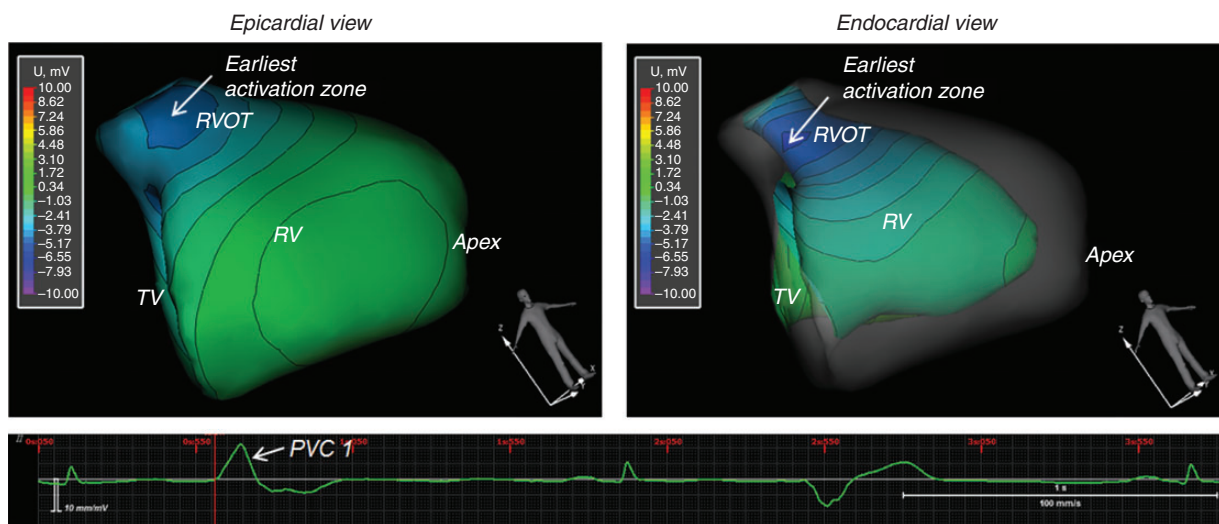


Figure 4 Non-invasive reconstruction of epicardial and endocardial isopotential maps superimposed on the polygonal models of the ventricles at the beginning of the QRS complex of PVC #1. The earliest activation originates from the posterolateral wall of the RVOT.

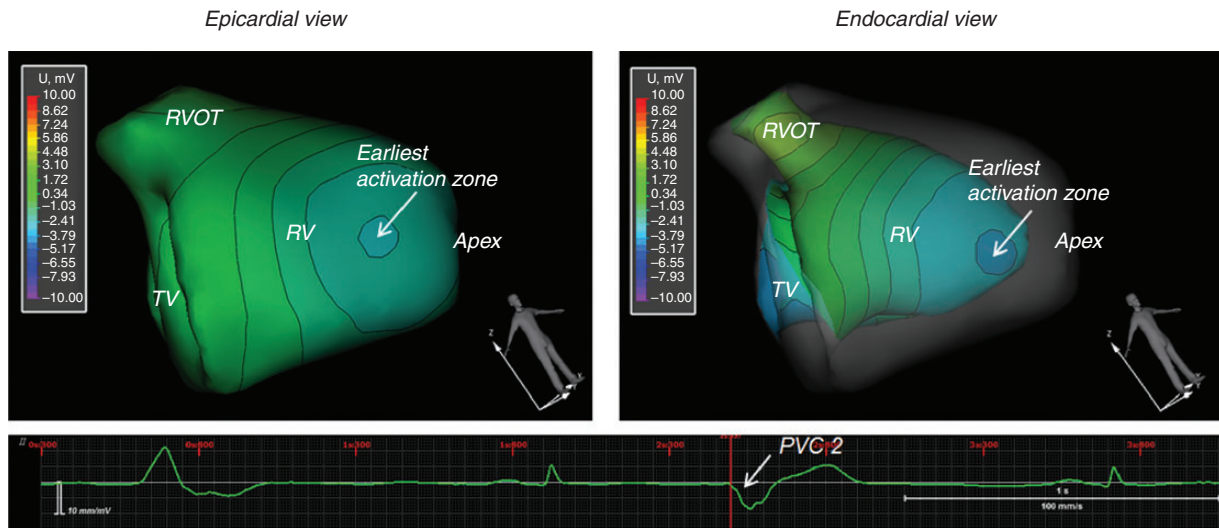


Figure 5 Non-invasive reconstruction of epicardial and endocardial isopotential maps superimposed on the polygonal models of the ventricles at the beginning of the QRS complex of PVC #2. The earliest activation originates from the mid-lateral wall of the RV.

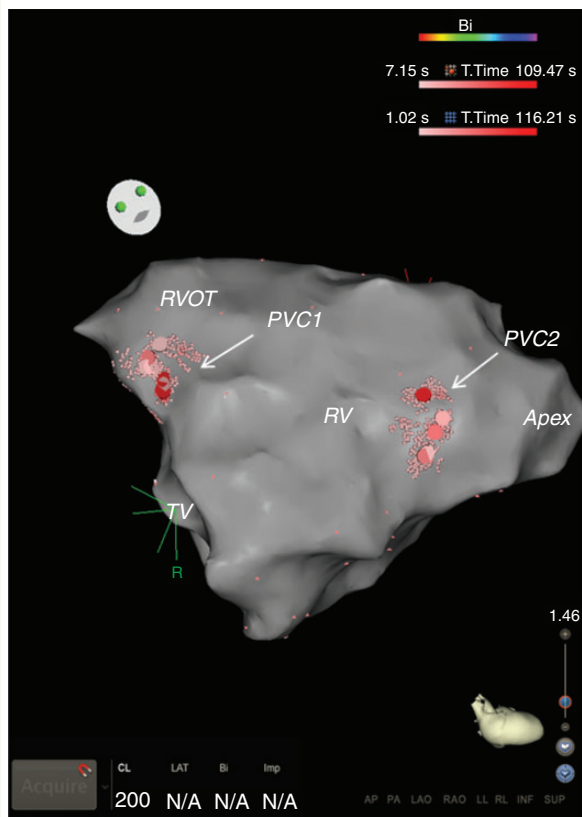


Figure 6 Invasive 3D CARTO 3 model of the RV. Shown are the location of successful RF ablation (red dots) for PVC #1 at the posterolateral wall of the RVOT and PVC#2 at the mid-lateral wall of the RV.

Wang *et al.*⁹ were able to predict the SOO of focal ventricular arrhythmias in 10 of the 11 (91%) RV and 11 of the 12 (92%) LV sites. Jamil-Copley *et al.*¹⁴ reported an accuracy of 96% in predicting non-invasively the focal SOO of ventricular arrhythmias. However, none of the aforementioned studies utilized an ECGI capable of mapping both the endocardial and the epicardial surfaces of the heart.

In a validation study,² the NEEES was able to identify with sufficient (<10 mm) accuracy the site of RV and LV pacing from various endocardial as well as epicardial sites.

In the present study, the NEEES was able to reproducibly localize the SOO over a series of consecutive recorded ectopic beats. The NEEES correctly diagnosed the respective ventricular segment in 86% of PVC/VT cases, thus establishing its value as an accurate diagnostic tool to identify the SOO of ventricular arrhythmias.

Knowledge of the location of the earliest site of activation before an invasive procedure, particularly in patients presenting with an ambiguous 12-lead surface EKG where the area of interest may be difficult to verify, should be of great value to the treating physician. The additional information provided by the NEEES may facilitate the planning of an appropriate invasive ablative strategy. Furthermore, from a single ectopic beat the complete activation sequence can be processed by the NEEES, facilitating successful mapping even in patients with haemodynamically intolerant or non-sustained arrhythmias. One major limitation of the standard 12-lead surface EKG is its low resolution in terms of localizing the SOO of ventricular ectopics. Multiple existing algorithms, often complex and difficult to apply, attempt to predict the earliest site of activation in ventricular arrhythmias, but many are hampered by their low specificity.^{15,16} Therefore, definitive diagnosis currently requires an invasive approach. The NEEES may overcome many of these limitations. Its use as a non-invasive diagnostic tool relies on the anatomical data derived from MRI or CT resulting in a highly accurate delineation of

the true cardiac activation sequence. In addition, the NEEES can provide important information regarding the underlying mechanism of arrhythmia using a single ectopic beat, even if recording rare clinical PVCs would require pre-procedural monitoring at the patient's bedside over an extended period of time. Finally, the use of CT scanning, as part of the non-invasive electrocardiographic imaging procedure, will expose patients to radiation. The NEEES allows data processing from cardiac MRI to complete heart and torso reconstruction, which eliminates the need for radiation.

Limitations

The present study provides no comparison between the NEEES and alternative methods to localize the SOO of PVC/VT, such as diagnostic algorithms based on information from the 12-lead surface EKG or invasive pace mapping.

Since patients included in the current study had no clinical indication for invasive epicardial mapping or ablation, epicardial breakthrough patterns could not be assessed.

In addition, no quantitative measures are given regarding the accuracy in localizing the ectopic foci. The current study compared ventricular segments to define successful catheter ablation, which as a reference has limited precision. The results of the present study underscore the need for further research on the accuracy of the NEEES. One area of improvement involves the complex anatomical region surrounding the left and right ventricular outflow tract. Differentiating PVC origin from the aortic sinus cusps and the RVOT is critical for the successful ablation outcome. On two occasions, the NEEES incorrectly identified the SOO in this complex region.

Conclusions

The novel non-invasive epicardial and endocardial electrophysiology mapping system accurately defines the site of focal PVC/VT origin and may facilitate planning of a successful ablation strategy. Combining anatomical data from MRI with information from the body-surface EKG eliminates the need for radiation exposure during the non-invasive diagnostic procedure.

Supplementary material

Supplementary material is available at *Europace* online.

Funding

This study was in part funded by a grant from the German Federal Ministry for Education and Research – International Bureau; and by the Russian Foundation for Assistance to Small Innovative Enterprises

(BMBF/IB - FASIE award # 14-1-H2.15-0001-7-P). Funding to pay the Open Access publication charges for this article was provided by EP Solutions SA, Yverdon-les-Bains, Switzerland.

Conflict of interest: E.W., A.T., and M.C. are consultants of EP Solutions SA. A.R. and V.K. are cofounders of EP Solutions SA.

References

1. Bokeriya LA, Revishvili AS, Kalinin AV, Kalinin VV, Lyadzhina OA, Fetisova EA. Hardware-software system for noninvasive electrocardiographic heart examination based on inverse problem of electrocardiography. *Biomed Eng* 2008;**42**: 273–9.
2. Revishvili AS, Wissner E, Lebedev DS, Lemes C, Deiss S, Metzner A *et al*. Validation of the mapping accuracy of a novel non-invasive epicardial and endocardial electrophysiology system. *Europace* 2015;**17**:1282–8.
3. Denisov AM, Zakharov EV, Kalinin AV, Kalinin VV, Trieb T *et al*. Single-beat non-invasive imaging of cardiac electrophysiology of ventricular pre-excitation. *J Am Coll Cardiol* 2006;**48**:2045–52.
4. Kalinin AV. Iterative algorithm for the inverse problem of electrocardiography in a medium with piecewise-constant electrical conductivity. *Comput Math Math Phys* 2011;**22**:30–4.
5. Ramanathan C, Ghanem RN, Jia P, Ryu K, Rudy Y. Noninvasive electrocardiographic imaging for cardiac electrophysiology and arrhythmia. *Nat Med* 2004;**10**:422–8.
6. Berger T, Fischer G, Pfeifer B, Modre R, Hanser F, Trieb T *et al*. Single-beat non-invasive imaging of cardiac electrophysiology of ventricular pre-excitation. *J Am Coll Cardiol* 2006;**48**:2045–52.
7. Van Dam PM, Oostendorp TF, Linnenbank AC, van Oosterom A. Noninvasive imaging of cardiac activation and recovery. *Ann Biomed Eng* 2009;**37**:1739–56.
8. Seger M, Hanser F, Dichtl W, Stuehlinger M, Hintringer F, Trieb T *et al*. Noninvasive imaging of cardiac electrophysiology in a cardiac resynchronization therapy defibrillator patient with a quadripolar left ventricular lead. *Europace* 2014;**16**:743–9.
9. Wang Y, Cuculich PS, Zhang J, Desouza KA, Vijayakumar R, Chen J *et al*. Noninvasive electroanatomic mapping of human ventricular arrhythmias with electrocardiographic imaging. *Sci Transl Med* 2011;**3**:98ra84.
10. Ramanathan C, Jia P, Ghanem R, Ryu K, Rudy Y. Activation and repolarization of the normal human heart under complete physiological conditions. *Proc Natl Acad Sci USA* 2006;**103**:6309–14.
11. Cuculich PS, Zhang J, Wang Y, Desouza KA, Vijayakumar R, Woodard PK *et al*. The electrophysiological cardiac ventricular substrate in patients after myocardial infarction: noninvasive characterization with electrocardiographic imaging. *J Am Coll Cardiol* 2011;**58**:1893–902.
12. Erkapic D, Greiss H, Pajitnev D, Zaltsberg S, Deubner N, Berkowitsch A *et al*. Clinical impact of a novel three-dimensional electrocardiographic imaging for non-invasive mapping of ventricular arrhythmias: a prospective randomized trial. *Europace* 2015;**17**:591–7.
13. Cakulev I, Sahadevan J, Arruda M, Goldstein RN, Hong M, Intini A *et al*. Confirmation of novel noninvasive high-density electrocardiographic mapping with electrophysiology study: implications for therapy. *Circ Arrhythm Electrophysiol* 2013;**6**: 68–75.
14. Jamil-Copley S, Bokan R, Kojodjojo P, Qureshi N, Koa-Wing M, Hayat S *et al*. Non-invasive electrocardiographic mapping to guide ablation of outflow tract ventricular arrhythmias. *Heart Rhythm* 2014;**11**:587–94.
15. Park KM, Kim YH, Marchlinski FE. Using the surface electrocardiogram to localize the origin of idiopathic ventricular tachycardia. *Pacing Clin Electrophysiol* 2012;**35**: 1516–27.
16. Zhang F, Chen M, Yang B, Ju W, Chen H, Yu J *et al*. Electrocardiographic algorithm to identify the optimal target ablation site for idiopathic right ventricular outflow tract ventricular premature contraction. *Europace* 2009;**11**: 1214–20.