



Year: 2016

Root canal morphology and configuration of 118 mandibular first molars by means of micro-computed tomography: an ex vivo study

Wolf, Thomas Gerhard; Paqué, Frank; Zeller, Maximilian; Willershausen, Brita; Briseño-Marroquín, Benjamín

Abstract: **INTRODUCTION** The aim of this study was to investigate the root canal system morphology of the mandibular first molar by means of micro-computed tomography. **METHODS** The root canal configuration, foramina, and accessory canals frequency of 118 mandibular first molars were investigated by means of micro-computed tomography and 3-dimensional software imaging. A 4-digit system describes the root canal configuration from the coronal to apical thirds and the main foramina number. **RESULTS** The most frequent root canal configurations in mesial root were 2-2-2/2 (31.4%), 2-2-1/1 (15.3%), and 2-2-2/3 (11.9%); another 24 different root canal configurations were observed in this root. A 1-1-1/1 (58.5%), 1-1-1/2 (10.2%), and 16 other root canal configurations were observed in the distal root. The mesiobuccal root canal showed 1-4 foramina in 24.6%, and the mesiolingual showed 1-3 foramina in 28.0%. One connecting canal between the mesial root canals was observed in 30.5% and 2 in 3.4%. The distolingual root canal showed 1-4 foramina in 23.7%, whereas a foramen in the distobuccal root canal was rarely detected (3.4%). The mesiobuccal, mesiolingual, and distolingual root canals showed at least 1 accessory canal (14.3, 10.2, and 4.2%, respectively), but the distobuccal had none. **CONCLUSIONS** The root canal configuration of mandibular first molars varies strongly. According to our expectations, both the mesial and distal roots showed a high number of morphologic diversifications. The root canal system of the mesial root showed more root canal configuration variations, connecting and accessory canals than the distal root.

DOI: <https://doi.org/10.1016/j.joen.2016.01.004>

Posted at the Zurich Open Repository and Archive, University of Zurich

ZORA URL: <https://doi.org/10.5167/uzh-133762>

Accepted Version



Originally published at:

Wolf, Thomas Gerhard; Paqué, Frank; Zeller, Maximilian; Willershausen, Brita; Briseño-Marroquín, Benjamín (2016). Root canal morphology and configuration of 118 mandibular first molars by means of micro-computed tomography: an ex vivo study. *Journal of Endodontics*, 42(4):610-614.

DOI: <https://doi.org/10.1016/j.joen.2016.01.004>

Root Canal Morphology and Configuration of 118 Mandibular First Molars by Means of Micro-computed tomography. An Ex Vivo-Study

Thomas Gerhard Wolf DDS, PhD*
Frank Paqué DDS, PhD**
Maximilian Zeller DDS*
Brita Willershausen DDS, PhD, Prof.*
Benjamín Briseño-Marroquín DDS, MDS, PhD, Prof.*

*Department of Operative Dentistry
Johannes Gutenberg University Medical Center
Mainz, Germany

**Division of Preventive Dentistry, Periodontology, and Cariology
University of Zürich Center of Dental Medicine
Zürich, Switzerland

Corresponding author:
Thomas Gerhard Wolf
Poliklinik für Zahnerhaltung
Augustusplatz 2
55131 Mainz
Germany
e-mail: thomaswolf@uni-mainz.de
Tel: +496131173501 (office)
Fax +496131173406 (office)

Keywords

Mandibular first molar; root canal configuration; internal tooth morphology; micro-computed tomography

Acknowledgments

“The authors deny any conflicts of interest

Abstract

Introduction

The aim of this study was to investigate the root canal system morphology of the mandibular first molar by means of micro-computed tomography (μ CT).

Materials and methods

The root canal configuration, foramina and accessory canals frequency of 118 mandibular first molars were investigated by means of micro-computed tomography and a 3D software imaging. A four digit system describes the root canal configuration from the coronal to apical thirds and the main foramina number.

Results

The most frequent root canal configurations in mesial root were 2-2-2/2 (31.4%), 2-2-1/1 (15.3%) and 2-2-2/3 (11.9%); another 24 different root canal configurations were observed in this root. A 1-1-1/1 (58.5%), 1-1-1/2 (10.2%) and 16 other root canal configurations were observed in the distal root. The mesiobuccal root canal showed in 24.6% one to four and the mesiolingual in 28.0% one to three foramina. One connecting canal between the mesial root canals was observed in 30.5% and two in 3.4%. The distolingual root canal showed in 23.7% one to four foramina; whereas a foramen in the distobuccal root canal was rarely detected (3.4%). The mesiobuccal, mesiolingual and distolingual root canals showed at least one accessory canal (14.3, 10.2 and 4.2%, respectively); yet the distobuccal had none.

Conclusions

The root canal configuration of mandibular first molars varies strongly. According to our expectations, both, the mesial and distal roots showed a high number of morphological diversifications. The root canal system of the mesial root showed more root canal configuration variations, connecting and accessory canals than the distal root.

Introduction

Success in endodontic surgical and non-surgical procedures requires an accurate knowledge of the internal tooth morphology (1, 2). Shaping, cleaning and filling of the root canal system can result in positive outcome only with a thorough understanding of the three-dimensional complexity of the root canal system (3, 4, 5). The morphology of the root canal system of mandibular first molars, known as the most frequently treated tooth (6, 7), has been described and discussed controversially in literature (8). Micro-computed tomography is a non-invasive, non-destructive and reproducible method and is nowadays considered the most accurate method for the investigation of the morphology of root canal systems combined with 3D software imaging (9-12). It provides a high resolution tooth morphology structure displaying and turns out to be a valuable information tool for the practitioner (6). The root canal configuration classification systems proposed by Weine et al. (1) and Vertucci (2), offer an overview of possible root canal system variations and allow its description. However, the morphological complexity of some root canals cannot be accurately classified with these systems (1, 2). The present study is aimed to investigate 118 mandibular first molars by means of micro-computed tomography and to describe their root canal configuration with a previously proposed classification system (13) employing a four digit code system to describe the root canal configuration at different root levels and foramina.

Materials and Methods

Tooth selection

118 extracted human permanent mandibular first molars were obtained for reasons unrelated to the present study from dental clinics and dental practitioners and stored in 5.25% sodium hypochlorite. Out of a greater sample number of teeth obtained from an Egyptian population (14) only teeth that could be strictly identified as mandibular first molars, with a coronal (mesiodistal crown diameter of 11 mm [± 0.2]) and radicular (two clear distinct roots) morphological dimensions that consistently adhere with the morphological description of Jordan et al. (15) were included in the study; otherwise they were discarded. Further selection criteria (10x) were complete root development, no signs of root fracture, coronal or radicular resorption and caries and the fact that they had no previous endodontic treatment. The teeth were cleansed from any attached hard and soft tissues as well as calculus by means of an ultrasonic scaler, placed for one hour in a 3% hydrogen peroxide ultrasonic bath and then stored in 70% alcohol. Endodontic access cavities were prepared with a high-speed hand piece and a diamond round bur (801-014 / Komet, Lemgo, Germany) for a research in which the pulp chamber floor and root canal accesses morphology was investigated; yet, these results are not reported in this investigation. When required, ultrasonic tips were used to remove pulp stones in the pulp chamber exclusively. The pulp chambers were rinsed with 1% sodium hypochlorite (60 sec) and dried through suction.

Micro computed tomography morphological analysis

The teeth were scanned at an isotropic resolution of 20 μm in a desktop micro-computed tomography unit (μCT 40; Scanco Medical, Brüttisellen, Switzerland) by means of a previ-

ously established method (16-18) at settings of 70 kV and 114 μ A resulting in 800 to 1200 slices per tooth.

To be able to differentiate the tooth structures, the obtained images were visualized through depiction with dummy colors and 3D reconstructions of the micro-computed tomography scans by means of a rendering software (VGStudio Max 2.2; Volumegraphics, Heidelberg, Germany). The pulp chamber and the root canal system were color coded with red, the coronal enamel with white and the dentin with transparent grey (Figs. 1 and 2).

The root canal configuration is described with four digits. The first three digits describe the root canal number, at the respective coronal limit of the coronal, middle and apical thirds. The fourth digit (separated with a slash) indicates the number of pertaining main foramina (13). Main foramina were defined as those pertaining to the same canal that had a diameter of no less than 0.2 mm. Furthermore, the number of accessory and connecting root canals, as well as the number of apical accessory foramina observed under micro-computed tomography, were also determined. The results are expressed through absolute and relative values according to the sample number.

Results

The described root canal configuration of the mesial and distal roots is shown in Tab 1. The most frequently observed root canal configuration in mesial root was 2-2-2/2 (31.4%) followed by 2-2-1/1 (15.3%), 2-2-2/3 (11.9%) and 2-2-1/2 (7.6%). Yet, 24 different root canal configurations could be observed with an incidence of less than 5% each. In the distal root the most commonly observed root canal configurations were 1-1-1/1 (58.5%) and 1-1-1/2 (10.2%). In the distal root, 16 other root canal configurations were observed.

The number of accessory and connecting canals observed in coronal and middle third of the mesial and distal roots are shown in Tabs. 2 and 3. The interconnection between two root canals by means of one connecting canal in the coronal third was observed in 20.3% and two connecting canals in 4.2%. While the mesiobuccal, mesiolingual and distolingual root canals presented in 14.3%, 10.2% and 4.2%, respectively at least one accessory canal, the distobuccal showed none. In the mesial root, connecting canals were observed in 19.4% in the middle third of the root. One (26.3%), two (5.1%) and three (2.5%) accessory canals were detected in the mesiolingual root. The mesiobuccal had in 14.4% cases one and 4.2% two accessory canals, whereas the distolingual and distobuccal root canals showed only in 4.2% at least one accessory canal.

The number of main and accessory apical foramina and connecting canals observed are shown in Tab. 4. The mesiobuccal had in 24.6% one to four and the mesiolingual root in 28.0% one to three foramina. A connecting canal was determined in 30.5% once and 3.4% twice in the apical third of the mesial root. While the distolingual root showed in 23.7% one to four foramina, in the distobuccal root one foramen was observed in only 3.4%.

Discussion

The aim of this study was to investigate the morphology of the mandibular first molar by means of 3D-image rendering after micro-computed tomography reconstruction and to sustain a reliable statistical analysis through a large number of samples. In vivo and in vitro investigations have examined the mandibular first molar reporting different results (8). Morphological three dimensional in vitro investigations are considered, when considering the internal tooth morphology, to be superior to in vivo methods (12). Although, micro-computed tomography is not suitable for clinical use it provides a more precise information than cone beam computed tomography (12). The intrinsic ability of micro-computed tomography to analyze the obtained information is less burdensome to evaluate in comparison to other techniques such as tooth clearing or cone beam computer tomography. As a noninvasive reproducible and relative simple technique, it can be used for quantitative and qualitative analysis in dental unfortunately only ex vivo research (19).

The results of this study showed that the root canal configuration of the mesial root had a relatively high variability. Our results showed an incidence of 2-2-2/2 in 31.4% and are lower compared to the results (ranging between 41.0 to 45.0%) of other authors (2, 20, 21). De Pablo et al. (8) reported in a systematic review including 4535 mandibular first molars from 17 studies that two root canals were observed in 94.4% and three in 2.3% in the mesial root. The root canal configuration most frequently reported in this root was 2-2-2/2 (52.3%), 2-2-1/1 (35.0%) and 2-1-1/1 (35%) (8). Yet, no micro-computed tomography studies were included in this systematic review. These observations are in contrast to our results when compared (2-2-2/2 in 31.4%; 2-2-1/1 and 2-1-1/1 in 17.0%). The reasons for these discrepancies could be explained by samples of the different ethnical origin, the investigation methods employed or the interpretation methodology implemented for the different root canal configurations in the systematic review.

In the present study the root canal configuration variation incidence in the distal root was quite different when compared with the mesial root. The most frequently observed root canal configurations in the distal root were 1-1-1/1 in 58.5% cases, followed by 1-1-1/2 in 10.2%. Similar results were found by Caliskan (20) and Sert & Bayirli (21) in a Turkish population (60.46; 53.0 male and 54.0% female, respectively). Vertucci (2) and Pineda and Kuttler (22) reported a higher incidence of this configuration (70.0 and 72.4%, respectively). To date to the best of our knowledge, only Harris et al. (7), Gu et al. (23) and Filpo-Pérez et al. (24) have investigated the root canal morphology of the mandibular first molar by means of micro-computed tomography. All of them report a higher 1-1-1/1 configuration incidence than the one of the present study ranging from 72.0 to 81.8%. These differences could be explained by the fewer teeth number examined by Gu et al. (n=25) (23) and Harris et al. (n=22) (7) or due to the the different population sample examined by Filpo-Perez et al. (n=100, Brazilian population) (24) when compared to our study (n=113, Egyptian population). Although, in the present investigation gender could not be considered as a parameter, morphological differences between both genders seem to be in literature in same ethnical origin samples not statistically significant (21). Our findings showed that distal root had a 1-1-1/2 configuration in 10.2%; thus, confirming the

results obtained by Harris et al. (7) who reports a 9.1% incidence. Gu et al. (23) and Filpo-Perez et al. (24) report a slightly lower 1-1-1/1 incidence (4.0 and 7.0%, respectively). The results of a systematic review of 22 studies including 3378 teeth (8) showed a similar 1-1-1/1 configuration frequency (62.7%) compared to our results. The configuration types 2-2-1/1 (14.5%) and 2-2-2/2 (12.4%) could not be confirmed in the present study. The results of this investigation as well as those obtained by Harris et al. (7) showed that although the mesial and distal roots have a high root canal configuration variability, the mesial root has a more complicated morphology due to the even higher number of morphological variations when compared with the distal root. A consistent morphological pattern could not be observed in mesial root such as the one reported by Villas-Boas et al. (25). According to all these morphological reports and transferring them to a clinical point of view, it seems to be that the endodontic treatment of the mesial root of mandibular first molar appears to be more demanding than the mesiobuccal root of the maxillary first molar.

In the present study accessory canals occurred in all thirds of the mesial root. Connecting canals between the two mesial root canals were observed more often in coronal the third (24.5%) than in middle third (19.4%). Accessory foramina in apical third of the mesial roots were detected in 33.9%. These results are in accordance with those obtained by Gu et al. (23), in which they report an extensive presence of accessory canals in the mesial root at various levels and rarely in the distal root. In contrast, Harris et al. (7), describe an "isthmus" between two or more canals in the mesial root in 100% of cases, and in the distal root in only 9.1% with a distance between 3 to 6mm from the apex. However, Gu et al. (23) observed a higher number of "isthmuses" with an incidence of 49.5 to 66.1% in the mesial and 17.3 to 17.8% in the distal roots appearing more frequently 4-6mm from the apex. This results are consistent with those obtained in this study. Due to the great anatomical variations, in both mesial and distal roots, and a high frequency of accessory canals, we are also (5) of the opinion that endodontic instruments and treatment techniques should be carefully selected in order to avoid mishaps; thus, compromising success during endodontic treatment (5). With the morphology knowledge reported in this and other micro-computer tomography investigations (5, 7, 11, 13, 16-18, 23-25), the importance of appropriate root canal preparation systems and irrigating solution selection becomes evident when considering the three dimensionality of the root canal system.

Conclusions

- The most frequent root canal configurations in the mesial root of mandibular first molars were 2-2-2/2 (31.4%), 2-2-1/1 (15.3%) and 2-2-2/3 (11.9%)
- The most frequently observed root canal configurations in the distal root of mandibular first molars were 1-1-1/1 (58.5%) and 1-1-1/2 (10.2%)
- One connecting canal was observed in the coronal (20.3%) and middle (14.4%) thirds between the mesiobuccal and mesiolingual root canals

- The mesiobuccal, mesiolingual and distolingual root canals showed in 14.3%, 10.2% and 4.2%, respectively, at least one accessory canal in the coronal third; whereas the distobuccal showed no accessory canals in the coronal third.
- The mesiobuccal, mesiolingual and distolingual root canals showed accessory canals in 18.6% and 33.9% in the middle third; whereas the distobuccal and distolingual showed only 4.2% and 4.2% accessory canals in this third.
- The mesiobuccal root canal had in 24.6% one to four, the mesiolingual in 28.0% one to three accessory apical foramina. The distolingual root canal showed in 23.7% one to four accessory apical foramina and in the distobuccal root canal only one foramen (3.4%) was rarely observed.

References

1. Weine FS, Healey HJ, Gerstein H, Evanson L. Canal configuration in the mesiobuccal root of the maxillary first molar and its endodontic significance. *Oral Surg Oral Med Oral Pathol* 1969;28:419–25.
2. Vertucci FJ. Root canal anatomy of the human permanent teeth. *Oral Surg Oral Med Oral Pathol* 1984;58:589–99.
3. Schilder H. Filling root canals in three dimensions. *Dent Clin North Am* 1967;17:723–44.
4. Schilder H. Cleaning and shaping the root canal. *Dent Clin North Am* 1974;18:269–96.
5. Lee JK, Yoo YJ, Perinpanayagam H, Ha BH, Lim SM, Oh SR, Gu Y, Chang SW, Zhu Q, Kum KY. Three-dimensional modelling and concurrent measurements of root anatomy in mandibular first molar mesial roots using micro-computed tomography. *Int Endod J* 2015;48:380–9.
6. Hull TE, Robertson PB, Steiner JC, del Aguila MA. Patterns of endodontic care for a Washington state population *J Endod* 2003;29:553–6.
7. Harris SP, Bowles WR, Fok A, McClanahan SB. An anatomic investigation of the mandibular first molar using micro-computed tomography. *J Endod* 2013;39:1374–8.
8. de Pablo OV, Estevez R, Péix Sánchez M, Heilborn C, Cohenca N. Root anatomy and canal configuration of the permanent mandibular first molar: a systematic review. *J Endod* 2010;36:1919–31.
9. Rhodes JS, Ford TR, Lynch JA, Liepins PJ, Curtis RV. Micro-computed tomography: a new tool for experimental endodontology. *Int Endod J* 1999;32:165–70.
10. Plotino G, Grande NM, Pecci R, Bedini R, Pameijer CH, Somma F. Three-dimensional imaging using microcomputed tomography for studying tooth macromorphology. *J Am Dent Assoc* 2006;137:1555–61.
11. Domark JD, Hatton JF, Benison RP, Hildebolt CF. An ex vivo comparison of digital radiography and cone-beam and micro computed tomography in the detection of the number of canals in the mesiobuccal roots of maxillary molars. *J Endod* 2013;39:901–5.
12. Acar B, Kamburoğlu K, Tatar İ, Arıkan V, Çelik HH, Yüksel S, Özen T. Comparison of micro-computerized tomography and cone-beam computerized tomography in the detection of accessory canals in primary molars. *Imaging Sci Dent* 2015;45:205-211.
13. Briseño-Marroquín B, Paqué F, Willershausen B, Wolf TG. Root Canal Morphology and Configuration of 179 Maxillary First Molars by Means of Micro-Computed Tomography. An Ex Vivo-Study. *J Endod*, 2015;41:2008-13.
14. Marroquín BB, El-Sayed MAA, Willershausen-Zönnchen B. Morphology of the physiological foramen: I. Maxillary and mandibular molars. *J Endod* 2004;30:321–8.
15. Jordan RE, Abrams L, Kraus BS. *Kraus' Dental Anatomy and Occlusion*. St. Louis: Mosby Year Book;1992.
16. Paqué F, Ganahl D, Peters OA. Effects of root canal preparation on apical geometry assessed by micro-computed tomography. *J Endod* 2009;35:1056–9.
17. Paqué F, Peters OA. Micro-computed tomography evaluation of the preparation of long oval root canals in mandibular molars with the self-adjusting file. *J Endod* 2011;37:517–21.
18. Paqué F, Al-Jadaa A, Kfir A. Hard-tissue debris accumulation created by conventional rotary versus self-adjusting file instrumentation in mesial root canal systems of mandibular molars. *Int Endod J* 2012;45:413–8.
19. Grande NM, Plotino G, Gambarini G, Testarelli L, D'ambrosio F, Pecci R, Bedini, R. Present and future in the use of micro-CT scanner 3D analysis for the study of dental and root canal morphology. *Ann Ist Super Sanita* 2012;48:26–34.
20. Calişkan MK, Pehlivan Y, Sepetçioğlu F, Türkün M, Tuncer SS. Root canal morphology of

human permanent teeth in a Turkish population J Endod 1995;21:200–4.

21. Sert S, Bayirli GS. Evaluation of the root canal configurations of the mandibular and maxillary permanent teeth by gender in the Turkish population J Endod 2004;30:391–8.
22. Pineda F, Kuttler Y. Mesiodistal and buccolingual roentgenographic investigation of 7,275 root canals. Oral Surg Oral Med Oral Pathol 1972;33:101–10.
23. Gu Y, Lu Q, Wang H, Ding Y, Wang P, Ni L. Root canal morphology of permanent three-rooted mandibular first molars—Part I: pulp floor and root canal system. J Endod 2010;36:990–4.
24. Filpo-Perez C, Bramante CM, Villas-Boas MH, Húngaro Duarte MA, Versiani MA, Ordinola-Zapata R. Micro-computed tomographic analysis of the root canal morphology of the distal root of mandibular first molar. J Endod 2015;41:231–6.
25. Villas-Boas MH, Bernardineli N, Cavenago BC, Marciano M, Del Carpio-Perochena A, de Moraes IG, Duarte HM, Bramante CM, Ordinola-Zapata R. Micro-computed tomography study of the internal anatomy of mesial root canals of mandibular molars. J Endod 2011;37:1682–6.

Mandibular first molar / Root canal configuration frequency					
Mesial root			Distal root		
Configuration	Absolute	Mean	Configuration	Absolute	Mean
2-2-2/2	37	31.4	1-1-1/1	69	58.5
2-2-1/1	18	15.3	1-1-1/2	12	10.2
2-2-2/3	14	11.9	1-1-2/2	5	4.2
2-2-1/2	9	7.6	1-1-1/3	4	3.4
2-2-2/4	5	4.2	1-1-2/3	4	3.4
1-1-1/1	3	2.5	2-2-1/1	4	3.4
1-1-1/2	3	2.5	2-2-2/2	4	3.4
2-1-1/2	3	2.5	1-1-1/4	3	2.5
2-1-1/1	2	1.7	1-2-2/2	2	1.7
2-2-1/3	2	1.7	2-1-1/1	2	1.7
2-2-2/5	2	1.7	2-2-2/3	2	1.7
2-2-3/3	2	1.7	1-2-1/1	1	0.8
2-2-3/4	2	1.7	1-2-1/2	1	0.8
2-3-3/3	2	1.7	1-2-2/3	1	0.8
1-1-2/2	1	0.8	1-2-3/3	1	0.8
1-1-4/4	1	0.8	2-1-1/2	1	0.8
1-2-1/1	1	0.8	2-2-1/2	1	0.8
1-2-1/2	1	0.8	2-2-3/3	1	0.8
1-2-2/2	1	0.8			
1-2-2/3	1	0.8			
1-4-1/3	1	0.8			
2-1-1/3	1	0.8			
2-1-2/2	1	0.8			
2-2-2/1	1	0.8			
2-2-4/3	1	0.8			
2-3-1/2	1	0.8			
2-3-2/2	1	0.8			
3-3-1/1	1	0.8			

Tab. 1. Root canal configuration observed under μ CT in the mesial and distal roots of the mandibular first molar (n = 118). The configuration numbers from left to right describe the root canal path of

the coronal, middle and apical thirds, respectively. The last digit, separated with a slash, shows the number of main foramina observed.

	MB		ML		Connecting (MB-ML)		DL		DB	
	n	%	n	%	n	%	n	%	n	%
0	101	85.6	106	89.8	89	75.4	113	95.8	118	100.0
1	13	11.0	8	6.8	24	20.3	4	3.4		
2	3	2.5	3	2.5	5	4.2	1	0.8		
3	1	0.8	1	0.8						

Tab. 2. Number (n) and mean (%) of accessory and connecting canals observed in the coronal third under μ CT of the mandibular first molar (n =118).

	MB		ML		Connecting (MB-ML)		DL		DB	
	n	%	n	%	n	%	n	%	n	%
0	96	81.4	78	66.1	95	80.5	113	95.8	113	95.8
1	17	14.4	31	26.3	17	14.4	5	4.2	4	3.4
2	5	4.2	6	5.1	5	4.2			1	0.8
3			3	2.5	1	0.8				

Tab. 3. Number (n) and mean (%) of accessory and connecting canals observed in the middle third under μ CT of the mandibular first molar (n =118).

	MB		ML		Connecting (MB-ML)		DL		DB	
	n	%	n	%	n	%	n	%	n	%
0	89	75.4	85	72.0	78	66.1	90	76.3	114	96.6
1	23	19.5	25	21.2	36	30.5	16	13.6	4	3.4
2	4	3.4	6	5.1	4	3.4	9	7.6		
3	1	0.8	2	1.7			2	1.7		
4	1	0.8					1	0.8		

Tab. 4. Number (n) and mean (%) of main and accessory apical foramina (F) and connecting canals observed under μ CT of the mandibular first molar (n =118).

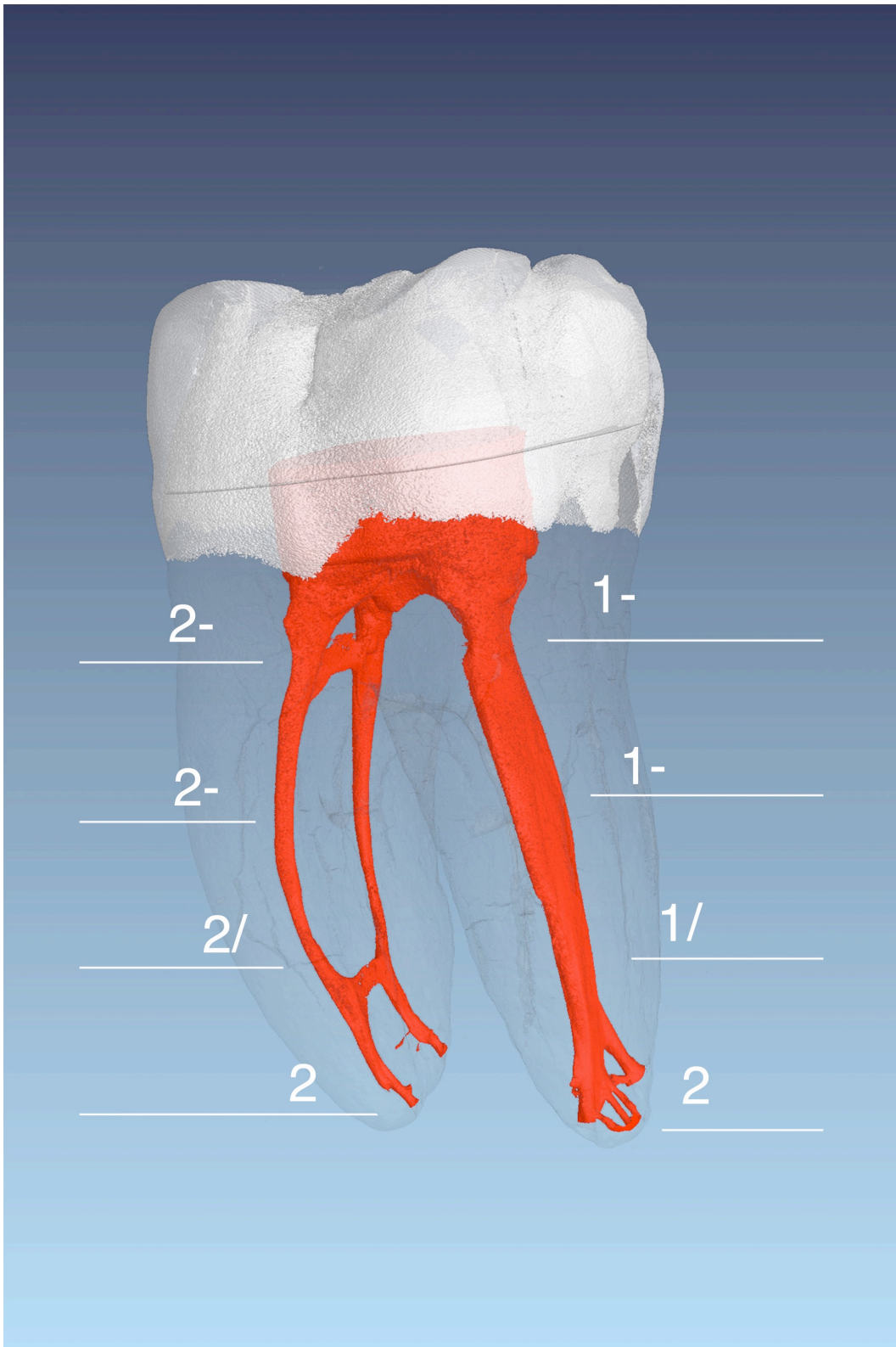


Fig. 1. Mandibular first molar with a root canal configuration 2-2-2/2 in the mesial root and 1-1-1/2 in the distal root. In the mesial root two communicating canals, one in the coronal and the other in the apical third, can be appreciated. Accessory canals can also be recognized in the mesial root. The distal root depicts a simple (oval) root canal configuration until it arrives at the apical third; it divides into two canals with multiple foramina and connecting canals.

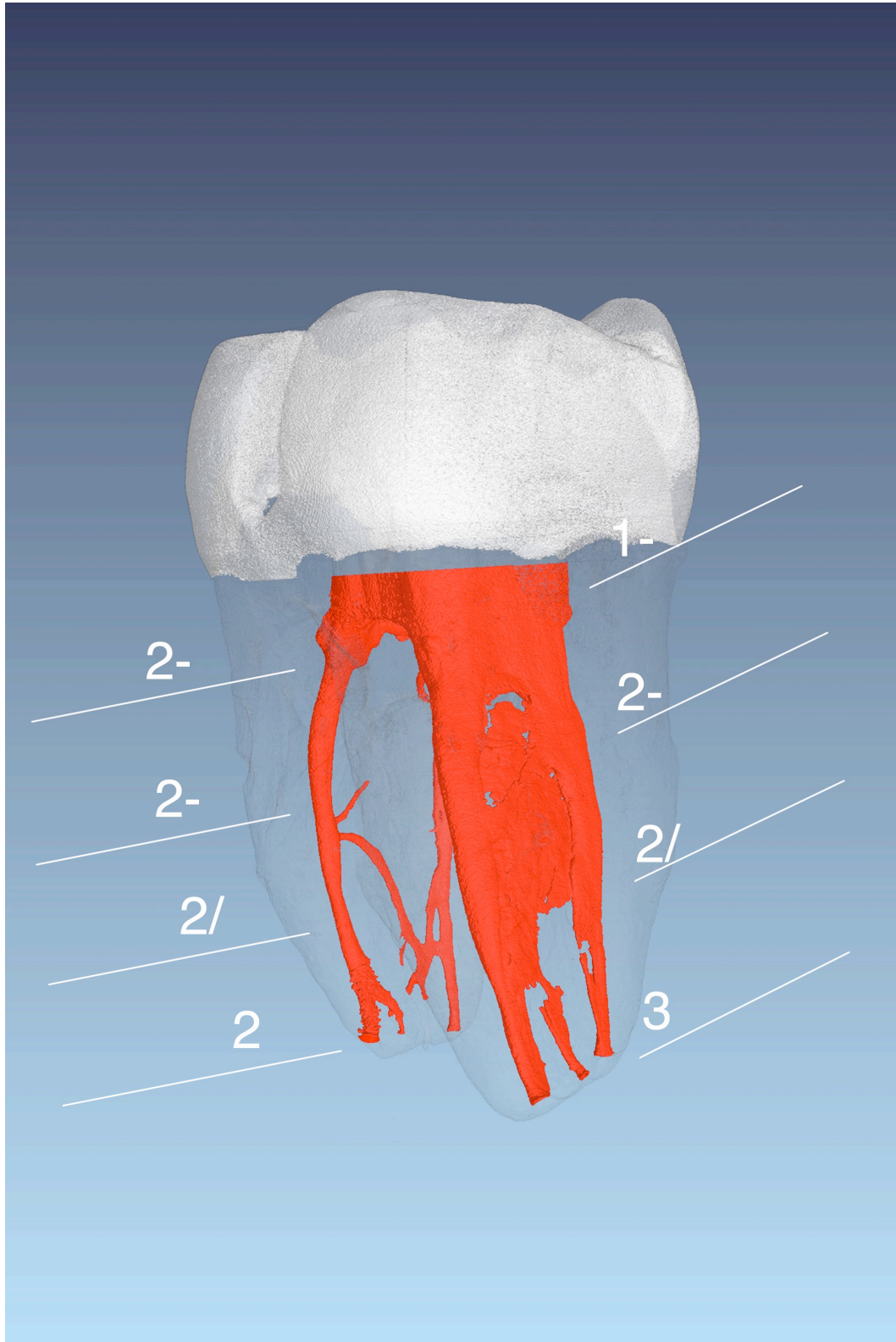


Fig. 2. Root canal morphology of a mandibular first molar. The mesial root has a 2-2-2/2 configuration. An accessory and communicating canal can be seen in the middle third. The configuration of the mesiobuccal canal cannot be completely depicted in this view; yet, an apical complicated root canal configuration can be perceived. The distobuccal and lingual root canals are anastomosed. However, in the apical third they divide into two canals and further apically the distolingual canal divides into two canals; thus, originating three root canals that could probably, when aware of them, be treated not only through the irrigating solution but also mechanically.

Legends

Tab. 1. Root canal configuration observed under μ CT in the mesial and distal roots of the mandibular first molar (n = 118). The configuration numbers from left to right describe the root canal path of the coronal, middle and apical thirds, respectively. The last digit, separated with a slash, shows the number of main foramina observed.

Tab. 2. Number (n) and mean (%) of accessory and connecting canals observed in the coronal third under μ CT of the mandibular first molar (n =118).

Tab. 3. Number (n) and mean (%) of accessory and connecting canals observed in the middle third under μ CT of the mandibular first molar (n =118).

Tab. 4. Number (n) and mean (%) of main and accessory apical foramina (F) and connecting canals observed under μ CT of the mandibular first molar (n =118).

Fig. 1. Mandibular first molar with a root canal configuration 2-2-2/2 in the mesial root and 1-1-1/2 in the distal root. In the mesial root two communicating canals, one in the coronal and the other in the apical third, can be appreciated. Accessory canals can also be recognized in the mesial root. The distal root depicts a simple (oval) root canal configuration until it arrives at the apical third; it divides into two canals with multiple foramina and connecting canals.

Fig. 2. Root canal morphology of a mandibular first molar. The mesial root has a 2-2-2/2 configuration. An accessory and communicating canal can be seen in the middle third. The configuration of the mesiobuccal canal cannot be completely depicted in this view; yet, an apical complicated root canal configuration can be perceived. The distobuccal and lingual root canals are anastomosed. However, in the apical third they divide into two canals and further apically the distolingual canal divides into two canals; thus, originating three root canals that could probably, when aware of them, be treated not only through the irrigating solution but also mechanically.