



University of  
Zurich<sup>UZH</sup>

Zurich Open Repository and  
Archive

University of Zurich  
Main Library  
Strickhofstrasse 39  
CH-8057 Zurich  
www.zora.uzh.ch

---

Year: 2016

---

## Apremilast is effective in lichen planus mucosae-associated stenotic esophagitis

Hafner, Jürg; Gubler, Christoph; Kaufmann, Karin; Nobbe, Stephan; Navarini, Alexander A; French, Lars E

**Abstract:** A 74-year-old woman with extensive lichen planus mucosae (LPM) developed stenotic esophagitis that was refractory to intravenous glucocorticosteroids. Esophageal dilatations to 14 mm width were repeatedly performed without any lasting effect. After introducing oral apremilast, she experienced complete clinical remission within the first 4 weeks of treatment. Control esophagoscopy confirmed a marked recovery of the esophageal mucosa with no recurrence of the former stenosis. Our observation is in line with the case series of Paul et al. [J Am Acad Dermatol 2013;68: 255–261] who first reported on the benefit of apremilast in patients with extensive LPM. Ideally, the effectiveness of apremilast in LPM should be studied in a randomized controlled trial.

DOI: 10.1159/000447051

Posted at the Zurich Open Repository and Archive, University of Zurich  
ZORA URL: <http://doi.org/10.5167/uzh-130523>  
Published Version



Originally published at:

Hafner, Jürg; Gubler, Christoph; Kaufmann, Karin; Nobbe, Stephan; Navarini, Alexander A; French, Lars E (2016). Apremilast is effective in lichen planus mucosae-associated stenotic esophagitis. Case Reports in Dermatology, 8(2):224-226. DOI: 10.1159/000447051

Single Case

# Apremilast Is Effective in Lichen Planus Mucosae-Associated Stenotic Esophagitis

Jürg Hafner Christoph Gubler Karin Kaufmann Stephan Nobbe  
Alexander A. Navarini Lars E. French

Department of Dermatology, University Hospital of Zurich, Zurich, Switzerland

## Keywords

Lichen planus · Lichen planus mucosae · Esophagitis · Apremilast

## Abstract

A 74-year-old woman with extensive lichen planus mucosae (LPM) developed stenotic esophagitis that was refractory to intravenous glucocorticosteroids. Esophageal dilatations to 14 mm width were repeatedly performed without any lasting effect. After introducing oral apremilast, she experienced complete clinical remission within the first 4 weeks of treatment. Control esophagoscopy confirmed a marked recovery of the esophageal mucosa with no recurrence of the former stenosis. Our observation is in line with the case series of Paul et al. [J Am Acad Dermatol 2013;68:255–261] who first reported on the benefit of apremilast in patients with extensive LPM. Ideally, the effectiveness of apremilast in LPM should be studied in a randomized controlled trial.

© 2016 The Author(s)  
Published by S. Karger AG, Basel

## Introduction

Erosive lichen planus mucosae (LPM) is a severe skin and mucosal disease which can seriously hamper nutrition if complications of the pharynx and esophagus are involved, eventually leading to deficiency symptoms. Paul et al. [1] reported on a series of 10 patients with biopsy-proven LPM who were treated with apremilast 20 mg twice daily. Three patients

(30%) showed an improvement of two grades on the Physician Global Assessment scale, but all participants experienced significant clinical improvement.

### Case Report

We are currently treating a 74-year-old woman with extensive LPM. She started developing genital skin changes at the age of 67 years, which were initially diagnosed as lichen sclerosus et atrophicus. Three years later, erosive stomatitis developed, and a mucosal biopsy showed the distinct histologic pattern of lichen planus. She has reported difficulties in swallowing for the last year. Gastroduodenoscopy confirmed erosive esophagitis and a long stenosis starting 20 cm ab ore (fig. 1).

Immunosuppressive treatment with pulsed intravenous methylprednisolone (125 methylprednisolone on 3 consecutive days, repeated 4 weeks later) did not show any beneficial effect, and azathioprine had to be ceased due to raised transaminases. Meanwhile, she developed a candida superinfection. Esophageal dilatations to 14 mm width were repeatedly performed without any lasting effect.

Having noted the publication of Paul et al. [1], we started treatment with apremilast. Only 4 weeks later, the patient was clinically free of dysphagia, and the erosive stomatitis had gone into complete remission (fig. 2). Control esophagoscopy confirmed a marked recovery of the esophageal mucosa with no recurrence of the former stenosis but some remaining enanthema and increased sensitivity to the mechanical stress caused by the endoscope.

Our case supports the observation of Paul et al. [1] that apremilast may represent a valuable immunomodulatory treatment for LPM. To our knowledge, this is the first report of successful application of apremilast in LPM-associated esophagitis, a rare but serious mucosal disease. The future will show whether more physicians can confirm our observation. Ideally, the effectiveness of apremilast in LPM should be studied in a randomized controlled trial.

### Statement of Ethics

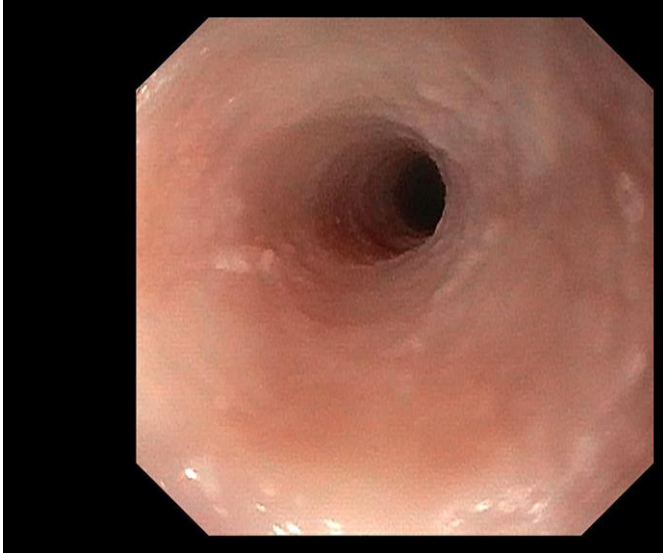The reported off-label use of apremilast in lichen planus mucosae-associated stenotic esophagitis has been conducted according to the recommendations of the Swiss Academy of Medical Sciences (www.samw.ch – Ethik – Archiv 2014, 11/06/2014). The patient has given her written informed consent.

### Disclosure Statement

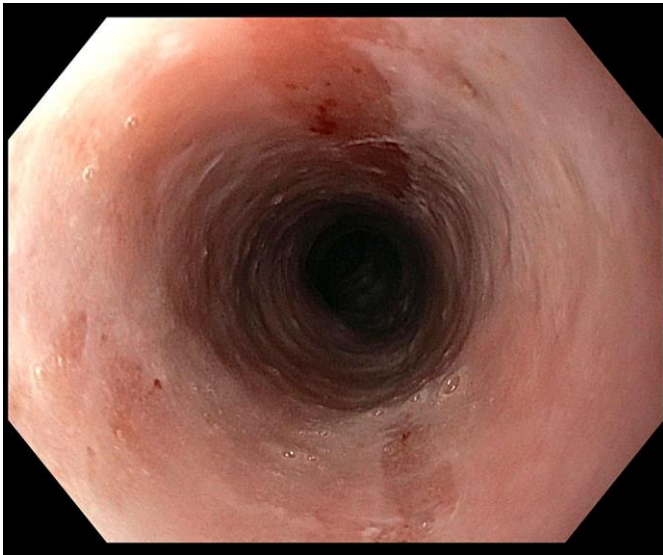
The authors declare that they have no conflicts of interest.

### References

- 1 Paul J, Foss CE, Hirano SA, Cunningham TD, Pariser DM: An open-label pilot study of apremilast for the treatment of moderate to severe lichen planus: a case series. *J Am Acad Dermatol* 2013;68:255–261.



**Fig. 1.** Esophagogastroscopy before the onset of apremilast treatment shows LPM esophagitis with esophageal stenosis 20 cm ab ore.



**Fig. 2.** Control esophagogastroscopy at 4 weeks of apremilast treatment shows no recurrence of the former stenosis.