



SHL ITEM BARCODE



19 1716809 4

REFERENCE ONLY

## UNIVERSITY OF LONDON THESIS

Degree MO

Year 2006

Name of Author VISVANATHAN  
S. D. K.

## COPYRIGHT

This is a thesis accepted for a Higher Degree of the University of London. It is an unpublished typescript and the copyright is held by the author. All persons consulting the thesis must read and abide by the Copyright Declaration below.

## COPYRIGHT DECLARATION

I recognise that the copyright of the above-described thesis rests with the author and that no quotation from it or information derived from it may be published without the prior written consent of the author.

## LOANS

Theses may not be lent to individuals, but the Senate House Library may lend a copy to approved libraries within the United Kingdom, for consultation solely on the premises of those libraries. Application should be made to: Inter-Library Loans, Senate House Library, Senate House, Malet Street, London WC1E 7HU.

## REPRODUCTION

University of London theses may not be reproduced without explicit written permission from the Senate House Library. Enquiries should be addressed to the Theses Section of the Library. Regulations concerning reproduction vary according to the date of acceptance of the thesis and are listed below as guidelines.

- A. Before 1962. Permission granted only upon the prior written consent of the author. (The Senate House Library will provide addresses where possible).
- B. 1962 - 1974. In many cases the author has agreed to permit copying upon completion of a Copyright Declaration.
- C. 1975 - 1988. Most theses may be copied upon completion of a Copyright Declaration.
- D. 1989 onwards. Most theses may be copied.

***This thesis comes within category D.***

This copy has been deposited in the Library of \_\_\_\_\_

This copy has been deposited in the Senate House Library, Senate House, Malet Street, London WC1E 7HU.



# **LOW POWER LASERS IN THE TREATMENT OF HEAVY MENSTRUAL PERIODS**

**Thesis submitted to the University of London**

**for the degree of**

**Doctor of Medicine (MD)**

**By**

**Dilip Visvanathan**

**MBBS MRCOG**

**2005**

**National Medical Laser Centre**

**Department of Surgery**

**University College London**

**and**

**Department of Obstetrics and Gynaecology**

**University College London Hospitals**

**London**

UMI Number: U592519

All rights reserved

INFORMATION TO ALL USERS

The quality of this reproduction is dependent upon the quality of the copy submitted.

In the unlikely event that the author did not send a complete manuscript and there are missing pages, these will be noted. Also, if material had to be removed, a note will indicate the deletion.



UMI U592519

Published by ProQuest LLC 2013. Copyright in the Dissertation held by the Author.  
Microform Edition © ProQuest LLC.

All rights reserved. This work is protected against  
unauthorized copying under Title 17, United States Code.



ProQuest LLC  
789 East Eisenhower Parkway  
P.O. Box 1346  
Ann Arbor, MI 48106-1346

## TABLE OF CONTENTS

TITLE PAGE.....	1
TABLE OF CONTENTS.....	2
LIST OF FIGURES.....	6
LIST OF TABLES.....	12
LIST OF ABBREVIATIONS.....	13
DEDICATION.....	14
ACKNOWLEDGEMENTS .....	15
STATEMENT OF ORIGINALITY.....	17
ABSTRACT.....	18
SECTION 1 INTRODUCTION AND BACKGROUND.....	20
<b>1.1 INTRODUCTION.....</b>	<b>20</b>
<b>1.2 THE NORMAL MENSTRUAL CYCLE.....</b>	<b>21</b>
<b>1.3 EXCESSIVE MENSTRUAL BLEEDING – DEFINITIONS AND TERMINOLOGY .....</b>	<b>25</b>
<b>1.4 MEDICAL TREATMENT OF DUB .....</b>	<b>29</b>
<b>1.5 MEDICAL MANAGEMENT OF UTERINE FIBROIDS.....</b>	<b>39</b>
<b>1.6 SUMMARY AND CONCLUSIONS.....</b>	<b>40</b>
<b>[2] SURGICAL ALTERNATIVES TO HYSTERECTOMY FOR HEAVY PERIODS.....</b>	<b>42</b>
<b>2.1 HYSTERECTOMY .....</b>	<b>42</b>
<b>2.2 ALTERNATIVE SURGICAL TREATMENT OF DUB .....</b>	<b>44</b>
<b>2.3 ALTERNATIVE SURGICAL TREATMENT OF UTERINE FIBROIDS.....</b>	<b>57</b>
<b>2.4 SUMMARY AND CONCLUSIONS.....</b>	<b>66</b>

<b>[3] LOW POWER LASER TREATMENTS FOR HEAVY PERIODS .....</b>	<b>71</b>
<b>3.1 LASER –TISSUE INTERACTION.....</b>	<b>71</b>
<b>3.2 LASERS IN CLINICAL USE.....</b>	<b>75</b>
<b>3.3 PHOTODYNAMIC THERAPY (PDT).....</b>	<b>77</b>
<b>3.4 INTERSTITIAL LASER PHOTOCOAGULATION (ILP).....</b>	<b>87</b>
<b>3.5 CONCLUSIONS .....</b>	<b>92</b>
<b>[4] AIMS OF THE THESIS .....</b>	<b>93</b>
<b>4.1 INTERSTITIAL LASER PHOTOCOAGULATION OF UTERINE FIBROIDS.....</b>	<b>93</b>
<b>4.2 PHOTODYNAMIC THERAPY OF THE ENDOMETRIUM IN WOMEN WITH DYSFUNCTIONAL UTERINE BLEEDING.....</b>	<b>94</b>
<b>SECTION 2 EXPERIMENTAL WORK.....</b>	<b>96</b>
<b>[5] DISTRIBUTION OF ALUMINIUM DISULPHONATED PHTHALOCYANINE IN THE RABBIT UTERUS AFTER TOPICAL INSTILLATION.....</b>	<b>97</b>
<b>5.1 INTRODUCTION .....</b>	<b>97</b>
<b>5.2 CHOICE OF AN ANIMAL MODEL .....</b>	<b>98</b>
<b>5.3 CHOICE OF PHOTOSENSITISER.....</b>	<b>101</b>
<b>5.4 AIM OF THIS STUDY .....</b>	<b>103</b>
<b>5.5 METHODS.....</b>	<b>103</b>
<b>5.6 RESULTS.....</b>	<b>108</b>
<b>5.7 DISCUSSION.....</b>	<b>115</b>
<b>5.8 CONCLUSION.....</b>	<b>122</b>

<b>[6] MORPHOLOGICAL CHANGES IN THE NORMAL RABBIT UTERUS FOLLOWING PDT WITH ALUMINIUM DISULPHONATED PHTHALOCYANINE.....</b>	<b>123</b>
6.1 INTRODUCTION .....	123
6.2 AIM OF THIS STUDY .....	124
6.3 EXPERIMENT 1 .....	125
A) TO COMPARE THE SHORT AND INTERMEDIATE TERM PDT EFFECT OF TOPICAL ALS2PC ON RABBIT ENDOMETRIUM USING DRUG LIGHT INTERVALS OF 1, 3 AND 6 HOURS.....	125
B) TO COMPARE THE PDT EFFECT OF TOPICAL ALS2PC ON RABBIT ENDOMETRIUM WHEN THE LIGHT INTENSITY IS INCREASED FROM 50 TO 100 JOULES/ CM.....	125
C) TO COMPARE THE EFFECT OF TOPICAL ALS2PC WITH THAT IN PREVIOUS WORK USING SYSTEMIC ALS2PC .....	125
6.4 EXPERIMENT 2 - TO STUDY THE LONG TERM EFFECT OF PDT OF THE RABBIT ENDOMETRIUM AFTER TOPICAL APPLICATION OF ALS2PC.....	152
6.5 CONCLUSION.....	156
<b>[7] INTRAUTERINE LIGHT DELIVERY FOR PHOTODYNAMIC THERAPY OF THE ENDOMETRIUM .....</b>	<b>158</b>
7.1 INTRODUCTION .....	158
7.2 AIM OF THE STUDY .....	160
7.3 EXPERIMENT 1 - COMPARISON OF THE MEDLIGHT BALLOON WITH THE UCL SMALL BALLOON, UCL LARGE BALLOON AND THE TRIFURCATOR DEVICE .....	161
7.4 EXPERIMENT 2 .....	175
A) THE EFFECT OF ADDING ANOTHER LIGHT DIFFUSER INTO A BALLOON DEVICE ON THE INTRAUTERINE LIGHT DELIVERY OF THE BALLOON DEVICES.....	175
B) COMPARISON OF THE BALLOON DEVICES WITH A CUSTOM MADE BIFURCATOR DEVICE FOR INTRAUTERINE LIGHT DELIVERY.....	175

<b>7.5</b>	<b>EXPERIMENT 3 - TO INVESTIGATE THE EFFECT OF INTRAUTERINE PATHOLOGY ON LIGHT DISTRIBUTION IN THE UTERUS.....</b>	<b>182</b>
<b>7.6</b>	<b>DISCUSSION.....</b>	<b>186</b>
<b>7.7</b>	<b>CONCLUSIONS.....</b>	<b>187</b>
<b>[8]</b>	<b>INTERSTITIAL LASER PHOTOCOAGULATION OF UTERINE FIBROIDS .....</b>	<b>189</b>
<b>8.1</b>	<b>METHODS.....</b>	<b>190</b>
<b>8.2</b>	<b>RESULTS.....</b>	<b>194</b>
<b>8.3</b>	<b>DISCUSSION.....</b>	<b>202</b>
<b>8.4</b>	<b>CONCLUSIONS .....</b>	<b>209</b>
<b>[9]</b>	<b>CONCLUSIONS .....</b>	<b>211</b>
<b>9.1</b>	<b>INTRODUCTION .....</b>	<b>211</b>
<b>9.2</b>	<b>SUMMARY OF THE OUTCOMES OF THE LITERATURE REVIEW .....</b>	<b>211</b>
<b>9.3</b>	<b>OBJECTIVES OF THE THESIS .....</b>	<b>214</b>
<b>9.4</b>	<b>MAJOR FINDINGS OF THE THESIS AND INTEGRATION WITH PREVIOUS WORK.....</b>	<b>214</b>
<b>9.5</b>	<b>STRENGTHS AND LIMITATIONS OF THIS THESIS .....</b>	<b>219</b>
<b>9.6</b>	<b>FUTURE AVENUES OF RESEARCH.....</b>	<b>220</b>
	<b>LIST OF REFERENCES.....</b>	<b>223</b>
	<b>LIST OF PUBLICATIONS.....</b>	<b>236</b>



## LIST OF FIGURES

Figure 1 Victor Bonney.....	44
Figure 2 Picture showing the loop resectoscope being used. At the bottom of the picture two sections of the uterine endometrium have been resected with the loop. The distension medium is 1.5% glycine.....	46
Figure 3 Diagrammatic representation of roller ball ablation of the endometrium. The thermal burns to the endometrium are illustrated. This procedure does not produce any tissue for histological evaluation .....	47
Figure 4 Figure showing the cryoprobe with gas delivery unit.....	48
Figure 5 Diagrammatic representation of the activated radiofrequency tip probe .....	49
Figure 6 Figure showing the waveguide with the sheath (graduated in cms) which is used for microwave endometrial ablation .....	50
Figure 7 The Cavaterm balloon .....	51
Figure 8 Figure showing the diagrammatic representation of the placing of the inflated Thermachoice balloon in the uterine cavity. The optical fibre is placed in the centre of the balloon.....	53
Figure 9 Diagrammatic representation of the activated ELLITT device inside the uterus. This shows optimal placement of the device .....	54
Figure 10 Diagrammatic representation of the double lumen sheath hysteroscope circulating heated saline in the uterine cavity. ....	56
Figure 11 Figures showing a uterus with an 8 cm intramural fibroid with subserosal extension before and after laparoscopic myomectomy.....	58
Figure 12 Diagrammatic representation of the technique described in removing anterior and posterior wall fibroids through a vaginal route .....	60
Figure 13 showing a uterus with a Type 0 large submucous fibroid almost filling the uterine cavity before and after removal with transcervical resection. The best results are obtained with Type 0 fibroids .....	62
Figure 14 Diagrammatic representation of uterine artery embolisation. The catheter is in the uterine artery and polyvinyl particles have been injected to cause obstruction to the distal branches of the uterine artery .....	63
Figure 15 Biological response of the target tissue to the energy density absorbed.....	74
Figure 16 showing a schematic diagram of the urogenital system of the female rabbit .....	99
Figure 17 showing a transverse section of the rabbit uterus. The superficial glands, deep glands, stroma and myometrium where fluorescence intensity measurements were taken are shown (magnification x10) .....	99
Figure 18 Picture showing the rabbit positioned for laparotomy with the Boyles apparatus and pulse oximetry showing monitoring used during surgery.....	105
Figure 19 showing the fluorescence imaging system and the cooled charged coupled device. The second diagram illustrates how the image is obtained. DM = Dichroic mirror and IF= interference filter .....	107

Figure 20 Fluorescence image of normal rabbit uterus 30 minutes after topical administration of 0.5 ml (1mg/ml) AIS<sub>2</sub>Pc with the same section subsequently stained with Haematoxylin and Eosin (H&E). The fluorescence image shows very high fluorescence in the lumen and the endometrium with significant fluorescence in the underlying layers. The upper colour bar indicates fluorescence intensity. (magnification x10) ..... 110

Figure 21 Fluorescence image of normal rabbit uterus 3 hours after topical administration of 0.5 ml (1mg/ml) AIS<sub>2</sub>Pc with the same section subsequently stained with Haematoxylin and Eosin (H&E). The fluorescence image shows fluorescence in the endometrium without significant fluorescence in the underlying layers. The upper colour bar indicates fluorescence intensity. (magnification x10)..... 111

Figure 22 A graph showing the comparison of the fluorescence intensity (arbitrary units) of the superficial glands and myometrium as a function of time (hours) when the uterine horn had been treated with a topical instillation of 1 mg/ml in a 0.5 ml volume of AIS<sub>2</sub>Pc. Each point represents the mean (with the standard error of the mean) from a minimum of two separate uterine horns. .... 112

Figure 23 A comparisons of the fluorescence intensity (arbitrary units) layers of the uterine horn as a function of time (hours) when the uterine horn had been treated with a topical instillation of 1 mg/ml in a 0.5 ml volume of AIS<sub>2</sub>Pc. Each point represents the mean (with the standard error of the mean) from a minimum of two separate uterine horns..... 113

Figure 24 Graph showing the comparison of the fluorescence intensity (arbitrary units) of the different layers in the uterus as a function of time (hours) when the uterine horn had been treated with a topical instillation of 1 mg/ml in a 0.5 ml volume of AIS<sub>2</sub>Pc. Each point represents the mean (with the standard deviation of the mean) from a minimum of two separate uterine horns..... 114

Figure 25 Fluorescence kinetics of the microscopic distribution of AIS<sub>2</sub>Pc in the normal uterine wall. Each point represents the mean of separate measurements corrected for auto fluorescence. (reproduced by permission from M Judd) ..... 118

Figure 26 A comparison of the fluorescence intensity (arbitrary units) of the uterine horn as a function of time (hours) when the uterine horn had been treated with a topical instillation of 1 mg/ml in a 0.5 ml volume of AIS<sub>2</sub>Pc and when it has been systemically administered at a concentration of 1mg/kg ..... 120

Figure 27 A graph showing the comparison of the fluorescence intensity (arbitrary units) of the superficial glands and myometrium as a function of time (hours) when the uterine horn has been treated with a topical instillation of 1 mg/ml in a 0.5 ml volume of AIS<sub>2</sub>Pc and when it has been treated systemically with a concentration of 1mg/kg..... 121

Figure 28 Photograph showing the rabbit uterus exteriorised from the anterior abdominal wall and surrounded by moist towels. The light diffuser fibre has been inserted through a 0.5 cm incision in the anti mesenteric border of the left uterine horn and is activated by light of 670nm wavelength produced by a diode laser at a power of 100 mwatts/cm<sup>2</sup>. ..... 126

Figure 29 Figure showing the set up of the diode laser and the light delivery system used for PDT of the rabbit uterus..... 127

Figure 30 – Grade 0 damage – the glandular architecture of the rabbit endometrium is the same as that of normal histology. There are no signs of PDT damage. .... 129

Figure 31 – Grade 1 damage – Many of the glands are destroyed by PDT. However a significant proportion of the deeper glands have not been affected. .... 129

Figure 32 – Grade 2 damage – Most of the glands in the endometrium have been damaged but there are a few scattered glands that have avoided PDT damage. 130

Figure 33 – Grade 3 damage – There is complete PDT destruction of the endometrium with no surviving glands. .... 130

Figure 34 – Grade 0 – untreated myometrium..... 131

Figure 35 – Grade 1 – Haemorrhage and cellular infiltration of the myometrium.... 131

Figure 36 Macroscopic appearance of uterus and vagina 3 days after PDT using 0.5 ml of 1mg/ml of AIS2 Pc with a light dose of 100 Joules/ cm<sup>2</sup> at a drug-light interval of 3 hours (both uterine horns have been treated). No serosal reaction was seen following PDT..... 133

Figure 37 Rabbit uterine horn cut open to show macroscopic appearance of uterine mucosa. Normal mucosal pattern on the left (control) and appearance after PDT using 0.5 ml of 1mg/ml of AIS2 Pc with a light dose of 100 Joules/ cm<sup>2</sup> at a drug-light interval of 3 hours..... 133

Figure 38 Transverse section of the rabbit uterus on day 3 following topical application of 0.5 ml of 1mg/ml of AIS2Pc. There was no light illumination following drug application. (Magnification x10) ..... 134

Figure 39 Transverse section of the rabbit uterus on day 3 following PDT using 0.5 ml of 1mg/ml of AIS2Pc with a drug light interval of 1 hour and a light intensity of 50 Joules/ cm<sup>2</sup>. (Magnification x10)..... 135

Figure 40 Transverse section of the rabbit uterus on day 3 following PDT using 0.5 ml of 1mg/ml of AIS2Pc with a drug light interval of 3 hours and a light dose of 100 Joules/ cm<sup>2</sup> (magnification x10)..... 136

Figure 41 Transverse section of the rabbit uterus on day 3 following PDT using 0.5 ml of 1mg/ml of AIS2Pc with a drug light interval of 6 hours and a light dose of 100 Joules/ cm<sup>2</sup> (magnification x10) ..... 137

Figure 42 Figure showing endometrial regeneration 13 days after using topical AIS2Pc PDT with a drug light interval of 1 hour and a light dose of 100 Joules/ cm<sup>2</sup> (Magnification x10) ..... 141

Figure 43 Figure showing endometrial regeneration 13 days after using topical AIS2Pc PDT with a drug light interval of 3 hours and a light dose of 100 Joules/ cm<sup>2</sup> (Magnification x10) ..... 143

Figure 44 Figure showing endometrial regeneration 13 days after using topical AIS2Pc PDT with a drug light interval of 6 hours and a light dose of 100 Joules/ cm<sup>2</sup> (Magnification x4) ..... 145

Figure 45 Percentage of uterine horn with grade 3 damage at 3 days with AIS2 Pc PDT with light intensities of 50 J/ cm<sup>2</sup> and 100 J/ cm<sup>2</sup> at different drug light intervals ..... 147

Figure 46 Figure comparing the PDT damage to rabbit endometrium at 3 days using light intensities of 50 J/cm<sup>2</sup> (left) and 100 J/cm<sup>2</sup> (right). Topical application of 0.5 ml of 1mg / ml of AIS2 Pc and a drug light interval of 1 hour were used. (Magnification x4) ..... 147

Figure 47 Figure comparing the PDT damage to rabbit endometrium at 3 days using light intensities of 50 Joules/ cm<sup>2</sup> (left) and 100 Joules/ cm<sup>2</sup> (right). Topical application of 0.5 ml of 1mg / ml of AIS2 Pc and a drug light interval of 3 hours were used. (Magnification x4)..... 148

Figure 48 Figure comparing the PDT damage to rabbit endometrium at 3 days using light intensities of 50 Joules/ cm<sup>2</sup> (left) and 100 Joules/ cm<sup>2</sup> (right). Topical application of 0.5 ml of 1mg / ml of AIS2 Pc and a drug light interval of 6 hours were used. (Magnification x4)..... 148

Figure 49 Figure showing the rabbit uterus 29 days after PDT exteriorised from the abdominal cavity. PDT was done using 0.5ml of 1mg/ml of AIS2Pc, a drug light interval of 3 hours and a light dose of 100 Joules/cm<sup>2</sup>. Both uterine horns do not show any serosal reaction and there are no adhesions or damage to the bladder ..... 153

Figure 50 Transverse section of rabbit uterine horn showing PDT damage at 29 days using 0.5 ml of 1mg/ml of AIS2 Pc topically with a light dose of 100 Joules/cm<sup>2</sup> at a drug light interval of 3 hours..... 154

Figure 51 Percentage of uterine horn with grades 0/1 and 2/3 damage at 29 days with AIS2 Pc PDT at a 3 hour drug light interval with light intensities of 100 J..... 154

Figure 52 Comparison of existing photodynamic light delivery device systems (from Dwyer et al) ..... 160

Figure 53 Photograph showing the plaster of paris mould used for the pouring of the molten paraffin wax and the uterine cavity cast with the metal rod cervical end. .... 161

Figure 54 Photograph showing the ready made uterine model which has been bisected. The dental wax which is poured into the uterine cavity when molten is also showed. The uterus is kept together with the O bands. .... 162

Figure 55 showing ingredients for the making of the silicone mixture ..... 162

Figure 56 showing the first and third coated uterine models ..... 163

Figure 57 the inflated small UCL balloon with the green nylon tube attached to it.. 164

Figure 58 the inflated large UCL balloon with the red nylon tube attached to it..... 164

Figure 59 The Medlight S.A. uterus balloon light diffuser model UB ..... 165

Figure 60 Simulation showing the insertion of the Medlight balloon into the uterine cavity..... 165

Figure 61 the Trifurcator ..... 166

Figure 62 simulation showing the ELITT procedure handset insertion..... 166

Figure 63 Pictures showing the locations of the spherical isotropically diffusing fibres in the uterus and the hysteroscopic guided placement of the cannulae. The fibres are flagged and passed through the cannulae. .... 168

Figure 64 showing the intrauterine balloon illuminated with the laser light at 635 nm. The light at the endometrial surface at 5 fixed points were measured with each of the devices. ....	169
Figure 65 Diagrammatic representation of the set up used for testing intrauterine light illumination of the different devices. ....	170
Figure 66 showing the mean light distribution in the anterior, posterior, right and left cornual positions of the uterus with the Medlight balloon, UCL small balloon, UCL large balloon and the trifurcator device. ....	171
Figure 67 showing box plots of the light intensities of the Medlight balloon, UCL small balloon, UCL large balloon and the trifurcator at each of the uterine positions. The length of each box shows the range within which the central 50% of the values fall, with the box edges (called hinges) at the first and third quartiles. The centre horizontal line marks the median of the sample.....	172
Figure 68 showing the average intrauterine light intensity of the Medlight balloon, UCL small balloon, UCL large balloon and the trifurcator device. ....	173
Figure 69 showing the design of the bifurcator device. The light fibre was inserted into each tube at different times for the purposes of the experiment. If a 2 way beam splitter was used then the two fibres could be inserted at the same time..	176
Figure 70 the bifurcator in the UCL small balloon.....	176
Figure 71 showing the mean light distribution in the anterior, posterior, right and left cornual positions of the uterus with the Medlight balloon, UCL small balloon, UCL large balloon, bifurcator in UCL small balloon and bifurcator device without a balloon.....	178
Figure 72 showing box plots of the light intensities of Medlight balloon, UCL small balloon, UCL large balloon, bifurcator in UCL small balloon and bifurcator device without a balloon at each of the uterine positions. The length of each box shows the range within which the central 50% of the values fall, with the box edges (called hinges) at the first and third quartiles. The centre horizontal line marks the median of the sample. ....	179
Figure 73 showing the average intrauterine light intensity of the Medlight balloon, UCL small balloon, UCL large balloon, bifurcator in UCL small balloon and bifurcator device without a balloon. ....	180
Figure 74 showing the light intensity at the level of the cervix with each of the devices tested .....	181
Figure 75 showing the light distribution with each of the devices (vertical line) in a uterus with a previous transcervical resection of the endometrium.....	184
Figure 76 showing the 5cm type 2 submucosal fundal fibroid. Note the narrowing of the cornual regions of the uterus.....	184
Figure 77 showing the light distribution with each of the devices (vertical line) in a uterus with a 5cm Type 2 submucosal fundal fibroid.....	185
Figure 78 showing the light distribution with each of the devices (vertical line) in a uterus with an intrauterine septum.....	186

Figure 79 showing how the bifurcator overcomes the midline uterine septum to deliver light to the uterine cornua. The balloon devices were not able to reach the fundus of the uterus..... 186

Figure 80 Semiconductor 805 nm Diode Laser Diomed 25W, Diomed Ltd Cambridge UK)..... 192

Figure 81 – A 4-way beam splitter allows 4 freshly cleaved optical fibres (400µm) to be used simultaneously for ILP treatment..... 192

Figure 82 Picture showing 10 mm laparoscope in umbilical port and grasper in the right flank (used for retracting bowel from the pouch of Douglas) and the Tuohey needles with the fibres inserted through them. Four fibres were used with a beam splitter. The flags on the fibres are also shown. .... 193

Figure 83 Picture showing the Tuohey needles inserted into the fibroid being treated. The 1cm graduations are visible. The aim is to keep a distance of 2 cms between each needle point..... 193

Figure 84 MRI showing subserous posterior wall fibroid with 2 diameters being measured..... 194

Figure 85 MRI of patient with fibroid no. 25. MRI showing (A) Before ILP 28cm<sup>3</sup> (B) 6 weeks after ILP 40cm<sup>3</sup> and (C) 1 year after ILP 11 cm<sup>3</sup>. In this patient there was a 40% reduction in fibroid volume..... 197

Figure 86 Graph showing the volume changes of fibroids (pre treatment volume less than 60 cm<sup>3</sup>) up to 12 months after laparoscopic ILP ..... 198

Figure 87 Graph showing the volume changes of fibroids (pre treatment volume greater than that 60 cm<sup>3</sup>) up to 12 months after laparoscopic ILP ..... 198

Figure 88 Graphical representation of volume changes of laparoscopic ILP .....202

Figure 89 Diagrammatic representation of the trifurcator ideally situated in the uterine cavity. ....216

Figure 90 Photograph of ends of Tuohey needle (above) and MRI needle (below). This illustrates the curved end of the Tuohey needle which encourages breakage of the charred tip when the fibre is withdrawn following ILP. The advantage of the needle however is the cm graduations which facilitate accurate needle placement.....217

## LIST OF TABLES

Table 1 Comparison of drug treatment of heavy periods.....	41
Table 2 Frequency of complication following hysterectomy. ....	43
Table 3 Comparison of first generation endometrial ablative techniques.....	67
Table 4 Comparison of second generation endometrial techniques. ....	68
Table 5 Comparison of the different routes used for fibroid removal .....	69
Table 6 Comparison of the conservative surgical treatments for uterine fibroids.....	70
Table 7 Continuous wave (CW) lasers in clinical use .....	76
Table 8 Pulsed lasers in clinical use.....	76
Table 9 Interstitial laser photocoagulation and photodynamic therapy .....	77
Table 10 Second generation photosensitisers.....	80
Table 11 Box showing the characteristics of the ideal minimal access technique .....	84
Table 12 Regeneration of rabbit endometrium afer curettage and cryosurgery .....	100
Table 13 Anaesthetic and analgesic regime used for rabbit experiments .....	104
Table 14 Comparison of fluorescence in uterine layers after topical AIS2Pc.....	114
Table 15 Comparison of fluorescence in uterine layers after intravenous AIS2Pc ...	119
Table 16 Comparison of topical and sytemic AIS2Pc in the rabbit uterus .....	121
Table 17 PDT damage in rabbit uterus 3 days after PDT with topical AIS2Pc using a drug light interval of 1hour and a light dose of 50 and 100 Joules/ cm2. ....	138
Table 18 PDT damage in rabbit uterus 3 days after PDT with topical AIS2Pc using a drug light interval of 3 hours and a light dose of 50 and 100 Joules/ cm2 .....	139
Table 19 PDT damage in rabbit uterus 3 days after PDT with topical AIS2Pc using a drug light interval of 6 hours and a light dose of 50 and 100 Joules/ cm2. ....	140
Table 20 PDT damage in rabbit uterus 13 days after PDT with topical AIS2Pc using a drug light interval of 1hour and a light dose of 50 and 100 Joules/ cm2.....	142
Table 21 PDT damage in rabbit uterus 13 days after PDT with topical AIS2Pc using a drug light interval of 3 hours and a light dose of 50 and 100 Joules/ cm2 .....	144
Table 22 PDT damage in rabbit uterus 13 days after PDT with topical AIS2Pc using a drug light interval of 6 hours and a light dose of 50 and 100 Joules/ cm2 .....	146
Table 23 Comparison of methodology used for topical and systemic administration of AIS2Pc for PDT of the normal rabbit uterus. ....	151
Table 24 Comparison of sytemic and topical AIS2Pc PDT at 29 days.....	156
Table 26 Volume changes in fibroids following laparoscopic ILP – Series 1. ....	195
Table 27 Volume changes in fibroids following laparoscopic ILP – Series 2 .....	196
Table 28 Volume changes in fibroids following laparoscopic ILP – Failures.....	197
Table 29 Table showing the effect of doubling the energy / cm3 of fibroid treated	199

## LIST OF ABBREVIATIONS

ALA	5-amino laevulinic acid
ALS2Pc	Aluminium disulphonated phthalocyanine
COCP	Combined oral contraceptive pill
DUB	Dysfunctional uterine bleeding
H&E	Haematoxylin and Eosi
ILP	Interstitial laser photocoagulation
LNG-IUS	Levonorgestrel intra uterine system
MRI	Magnetic Resonance Imaging
NET	Norethisterone
PDT	Photodynamic therapy
PPIX	Protoporphyrin IX
RCOG	Royal College of Obstetricians and Gynaecologists



## **DEDICATION**

*To Sharmistha,  
Avinash and Amrit*

## ACKNOWLEDGEMENTS

The work for this thesis was carried out at the National Medical Laser Centre, University College London and the Department of Obstetrics and Gynaecology, Elizabeth Garrett Anderson Hospital for Women London. My supervisors were Professor S G Bown and Mr A S Cutner. I am greatly indebted to them both for the support and encouragement that they gave me throughout this project. Professor Bown has been a continual source of education, inspiration and direction. Mr Cutner's enthusiasm and high standards for minimal access surgery has ensured optimal development of the ILP procedure. He has always been available for discussing the projects and I am grateful to him for all the advice given to ensure successful completion of the project.

I am especially grateful to Dr Sandy Mosse whose expert knowledge in medical physics has been invaluable throughout this project. He has helped set up, maintain and develop the techniques used for the making and testing of the intrauterine light devices and the development of the laser techniques for the ILP project. I am also grateful to Dr Josephine Woodhams who made up the AIS2Pc solutions and assisted me with the pharmacokinetics and PDT work ensuring that the results were not subject to observer bias.

Several other people have contributed significant time and effort towards this research project: Sandy McRobert for his advice with the use of the fluorescence microscope; Sangita Naranbhai for helping with MRI appointments; Dr Rowan Connell for validating the MRI measurements of the uterine fibroids; Mr Anthony Weekes and Harold Wood Hospital for allowing me to do the light distribution experiments on site; Noreen Farooqui for patiently teaching me to cut cryosections; Nick of Biological services UCL for advise and help with providing the facilities necessary for PDT work; Shayami Thanabalasunderam for her suggestions regarding graphical representation of data and Ramesh Kuppusamy for suggestions with formatting and proof reading.

I would also like to acknowledge Andrew Lee, Mahesh Pai, David Pickhard, Neil Jamieson, Kathryn Dempsey, Sally Thorpe and Liz Read who were always available for support when things were not going well.

Finally and most importantly I wish to thank my wife Sharmistha, who has endured the writing of this thesis with grace and constant support, and my two sons Avinash and Amrit, who taught me how to use word art to generate two of the diagrams in this thesis.

Financial support during this thesis came from the Peacock Trust.

## **STATEMENT OF ORIGINALITY**

The work presented in this thesis is original. The topical application of this particular photosensitiser (AlS2Pc) for photodynamic therapy of the endometrium has not been studied before. There have been previous studies comparing devices for intra uterine light distribution but not with the latest devices as described in this thesis. Laparoscopic interstitial laser photocoagulation of uterine fibroids has not been evaluated before with systematic follow up using magnetic resonance imaging. The concepts for these projects arose after joint consultations with my supervisors Professor S G Bown and Mr A S Cutner. I personally conducted all the experiments described and all help has been acknowledged.

## ABSTRACT

Two of the most frequent causes of excessive menstrual blood loss are dysfunctional uterine bleeding (DUB) and fibroids. Both can be cured by hysterectomy, but no non-surgical treatment for either is entirely satisfactory. This thesis looks at the potential of minimally invasive, low power laser techniques for treating these conditions: photodynamic therapy (PDT) for endometrial ablation for DUB and interstitial laser photocoagulation (ILP) for fibroids.

PDT is the local destruction of tissue with light after prior administration of a photosensitising drug. No heat is involved. In pharmacokinetic studies, I instilled the photosensitiser aluminium disulphonated phthalocyanine (AlS2Pc) into the horns of normal rabbit uteri, using fluorescence microscopy of uterine sections to document the drug distribution. The most appropriate drug levels in endometrium and myometrium were seen at 3 hours, at which time a diffuser fibre delivered laser light (670nm) to the endometrium.. Histological examination 3-28 days later showed that under optimal conditions, there was close to complete endometrial ablation with minimal myometrial damage. Studies on human hysterectomy specimens compared a range of light delivery devices for PDT. The bifurcator gave the most uniform light distribution.

ILP involves inserting one or more thin needles into fibroids at laparoscopy. Laser fibres are passed through the needles to gently heat the target lesion (typically 3W for 10 minutes per fibre site). 21 symptomatic patients with 32 fibroids were treated. At 6 weeks, most lesions were oedematous, but there was a mean shrinkage of 25% at 6 months and 50% at 12 months, with corresponding symptomatic relief.

These studies have shown that in the rabbit, PDT with AlS2Pc can produce endometrial ablation safely. The technique is ready for consideration for pilot clinical studies. ILP has been shown to be a safe and relatively simple treatment for moderate sized fibroids, which could be incorporated into gynaecological practice now.

# **SECTION 1 - BACKGROUND AND INTRODUCTION**

- Chapter 1 Medical management of heavy periods
- Chapter 2 Surgical alternatives to hysterectomy for heavy periods
- Chapter 3 Low power laser treatments for heavy periods
- Chapter 4 Aims of the thesis

# [1] Medical management of heavy periods

## **1.1 Introduction**

Excessive menstrual bleeding is a significant health care problem worldwide. In the United Kingdom alone 1 in 20 women aged 30-49 years consult their general practitioner each year with this problem (Vessey et al. 402-07). In 1995, the estimated cost of primary care prescriptions was around £7 million (Coulter, Kelland, and Long). It remains one of the commonest causes of primary care referral to a gynaecologist. Sixty per cent of women seen by a gynaecologist will have a hysterectomy within 5 years (Coulter et al. 789-96). In 1997-1998 there were 63,345 hysterectomies carried out in England (National Health Service Executive). Two thirds of these were performed for menorrhagia (Coulter et al. 218-26). of which the two most common causes are Dysfunctional Uterine Bleeding (DUB) (46%) and uterine fibroids (17% causal; 35% associated) (Maresh et al. 302-12).

The treatment options for DUB and uterine fibroids include medical management, conservative surgical management and hysterectomy. Although hysterectomy is an effective treatment it is associated with significant morbidity and even mortality. This

has led to the development of medical and conservative surgical techniques to avoid hysterectomy.

Medical treatment of menorrhagia relies on the manipulation of the endocrine and paracrine changes that occur in the menstrual cycle. Conservative surgical therapy for DUB relies on the destruction of the endometrial lining to a sufficient depth to prevent regeneration. Removal of the fibroids is a good alternative to hysterectomy but is associated with significant recurrence rates. Interference with the blood flow to the uterus, to the uterine fibroid and damage to the collagen within the uterine fibroid are being investigated to an attempt to reduce the size of the fibroid thereby causing symptomatic relief. This thesis investigates two procedures, photodynamic therapy of the endometrium for DUB and interstitial laser photocoagulation of uterine fibroids, which utilises lower power laser energy for its therapeutic effect. Development of both procedures will provide an exciting alternative to hysterectomy.

This chapter aims to review our understanding of the menstrual cycle and how this can be exploited for the medical treatment of women with DUB and uterine fibroids. Chapter 2 will review the existing methods of conservative surgical management of DUB and uterine fibroids. Chapter 3 will review the rationale for the use of low power lasers in the treatment of both these conditions.

## **1.2 *The normal menstrual cycle***

### **1.2.1 The endometrial cycle**

The endometrium undergoes a cycle of endometrial growth and regression, which is repeated some 300-400 times during reproductive life. Endometrial changes involve both the endometrial glands and the stroma. For descriptive purposes these changes will be described in the following phases; proliferative, early secretory, pre implantation, endometrial breakdown and menstrual endometrium.

#### **1.2.1.1 *The proliferative phase***

The ovarian follicle grows and increases the production of oestrogen. In response to this there is reconstruction and growth of glands, which show increased mitotic activity and pseudostratification. The ends of the glands link up together forming a continuous layer of glandular epithelium that faces the endometrial cavity. The number of ciliated and microvillous cells keep increasing and this is thought to be



important in the mobilisation of secretions in the secretory phase. The stroma “inflates” from the dense cellular layer at the end of menstruation to a loose syncytium through which the spiral vessels travel to the epithelium where they end in a dense capillary network. Macrophages and lymphocytes derived from the bone marrow are diffusely distributed in the stroma. During the proliferative phase the thickness of the endometrium increases from 0.5 mm to 3.5 – 5.0 mm.

#### *1.2.1.2 The secretory phase*

Both oestrogen and progesterone are secreted in increasing amounts after ovulation. Further increase in endometrial thickness is not seen despite the high levels of oestrogen as progesterone inhibits its action. Growth continues in a fixed thickness and hence the endometrial glands become progressively tortuous and the spiral vessels in the stroma become intensely coiled. The first sign of ovulation is the formation of sub nuclear intracytoplasmic vacuoles in the epithelium which migrates around the nucleus and then discharges into the endometrial cavity leaving a saw toothed appearance on the surface of the cells. The glands actively secrete glycoproteins and peptides into the endometrial cavity. There is also a transudation of plasma with carrier-mediated transport of important immunoglobulins into the endometrial cavity. This activity reaches a peak 7 days after the mid cycle gonadotrophin surge. This corresponds to the time at which a blastocyst implants if fertilisation has occurred in that cycle.

#### *1.2.1.3 The implantation (late secretory) phase*

There is differentiation of the endometrium into 3 zones. The lower zone comprises of the stratum basalis with is mainly unchanged and is fed by straight vessels running through a spindle shaped stroma. In this layer the glands are tubular. The intermediate zone is called the stratum spongiosum and has the loose oedematous stroma with tightly coiled spiral vessels and dilated glandular ribbons. The upper zone is called the stratum compactum, which contains large polyhedral stromal cells abutting one another forming a compact sturdy layer. Here the spiral vessels form a rich engorged capillary plexus. The upper 2 layers are also referred to as the functional layer as it prepares for the implantation of the blastocyst and goes through the changes of proliferation, secretion and regeneration. The function of the stratum

basale is to provide the regenerative endometrium following the menstrual loss of the functional layer.

#### ***1.2.1.4 The phase of endometrial breakdown***

In the absence of fertilisation, the corpus luteum in the ovary ceases to function and the oestrogen and progesterone levels start to decline. This causes three endometrial events namely vasomotor reactions, tissue loss and menstruation. There is shrinkage of the height of the endometrium and marked coiling and spasm of the spiral vessels. This occurs in waves of rhythmic contractions and relaxation, which progressively increase in duration causing endometrial blanching and finally ischaemic necrosis. The increased vascular permeability and stasis as a result of the ischaemia causes diapedesis of the white cells and movement of the red cells into the interstitial spaces. Cellular necrosis and liberation of the lysosomal enzymes causes digestion of the cells and collapse of the tissue. Once the plane of cleavage between the stratum basalis and the functional layer is breached the functional layer desquamates. Menstrual fluid is therefore composed of the autolysed functional layer, inflammatory exudates, red blood cells and proteolytic enzymes.

#### ***1.2.1.5 Menstrual endometrium***

This is composed of the stratum basalis and a small and variable component of the stratum spongiosum. The epithelium over the tubal ostia and the isthmus of the cervix are not lost during menstruation. Following desquamation of the functional layer, the stroma forms a compact mass over which the epithelium from the stumps of the endometrial glands in the basalis and from the region of the tubal ostia and cervical isthmus can grow. This epithelium covers the entire uterine cavity usually by day 5-6 of the menstrual cycle.

### **1.2.2 Local biochemical changes**

Prostaglandin F<sub>2α</sub> and the prostaglandin E<sub>2</sub> reach their highest concentrations in secretory endometrium during the time of menstruation and are thought to be the mediators of vasoconstriction and myometrial contractility. The late secretory and menstrual endometrium has a high concentration of fibrinolytic agents. Bleeding is limited by the formation of thrombin - platelet plugs both at the stumps of the

denuded blood vessels and upstream. The slowly rising levels of oestrogen enhance this effect.

### 1.2.3 Regulation of the menstrual cycle

Regulation of the menstrual cycle is by the integration of hormonal signals, autocrine and paracrine factors and target cell receptor function in the uterus, ovary, pituitary, hypothalamus and other central nervous system sources. Gonadotrophic releasing hormones (GnRH) are produced in the basal hypothalamus and are carried in the blood via the hypothalamo- hypophyseal portal to the anterior pituitary gland. The GnRH is released in pulses – the amplitude and frequency of which should be within a critical range for normal gonadotrophin production. In response to the release of GnRH, the gonadotrophins – Follicle Stimulating Hormone (FSH) and Luteinising Hormone (LH) are secreted in a pulsatile manner from the gonadotrophes, which are situated in the lateral aspect of the anterior pituitary. GnRH also primes the gonadotrophes so that at a later stage of the cycle there is a much bigger response and this self priming action is thought to be important for the induction of ovulation.

FSH is mainly responsible for the early development of the Graafian follicle with the production of oestrogen. LH may contribute to follicular growth and oestrogen production but its principal action is to induce ovulation and to convert the ruptured Graafian follicle into a corpus luteum which occurs through 4 feed back cycles.

### 1.2.4 Cycle length and ovulation

The studies of Vollman (Vollman 1-193) of more than 30,000 cycles recorded by 650 women and the study of Treloar (Treloar et al. 77-126) of more than 25,000 woman-years in a little over 2,700 women provide us with information on the normal variation in menstrual cycles.

Menstrual cycle length ranges from 21 days to 35 days (0.5% women have shorter cycles and 0.9% of women have longer cycles). The longest cycles are seen 5 years after the menarche and again after the age of 40 years. This coincides with the highest incidence of anovulatory cycles. The perfect 28 day cycle is indeed the most common length but occurs in only 12.4% of the cycles studies by Vollmans. Overall, approximately 15% of reproductive age cycles are 28 days in length with 20% of women experiencing irregular cycles.

### 1.2.5 Normal MBL

The most reproducible menstrual pattern in terms of quantity and duration occurs with the post ovular oestrogen and progesterone withdrawal MBL. In normal menstrual periods 79% of the blood is lost during the first two days and at least 92% in the first three days (Rybo Suppl-45). In a study by Hallberg in 1966 of 476 randomly selected Swedish women who considered their periods to be normal and who were not anaemic, the average blood loss measured quantitatively was 43ml. The 95<sup>th</sup> centile was 76.4 mls. The upper range of normal MBL was considered to be 60-80 mls and this occurred in 10-25% of women (Hallberg et al. 320-51).

### 1.2.6 Significance of an increased MBL

The haemoglobin and serum iron concentrations were decreased among women having an MBL exceeding 60ml per cycle and their incidence of iron deficiency anaemia was up to five times increased when compared to women with lighter MBL. Women losing 80 ml of blood per cycle without dietary iron supplementation had a 67% incidence of anaemia (Hallberg et al. 320-51).

Consequently a MBL of 80 mls or more in a woman with regular periods is generally regarded as the definition of menorrhagia. This is reflected initially by a reduced serum ferritin followed by iron deficiency anaemia.

## **1.3 Excessive menstrual bleeding – Definitions and terminology**

### 1.3.1 Menorrhagia

It can be appreciated that in clinical practice measurement of 80 mls of MBL is not practical. The Royal College of Obstetricians and Gynaecologists suggested that menorrhagia be defined as a complaint of “heavy cyclical menstrual bleeding over several consecutive cycles without any intermenstrual or postcoital bleeding”(The Royal College of Obstetrics and Gynaecology). If it is certain that the MBL is greater than 80 mls then the term “objective menorrhagia” is used. If the woman perceives her MBL to be heavy but it is not found to be so then the term subjective menorrhagia is used. This is a clinically difficult problem as up to 50% of women presenting with heavy MBL have subjective menorrhagia.

### 1.3.2 Dysfunctional uterine bleeding (DUB)

DUB is the term given to menorrhagia in the absence of any organic pathology.

Factors that affect MBL

### 1.3.3 Non organic causes

#### 1.3.3.1 *Stress and anxiety*

The complex interrelationships that are required for regulation of the menstrual cycle have been described (see section 1.2.3). It has been shown that norepinephrine stimulates GnRH production while Dopamine inhibits it. Endogenous opiate production causes a reduction in the pulse frequency of GnRH, which may explain the basis by which stress interferes with menstrual function as Corticotropin Releasing Hormone (CRH) is increased and the resulting increase in serum cortisol augments endogenous opiate production.

#### 1.3.3.2 *Disorders of the thyroid gland*

Goldsmith et al showed that 70 % of menstrual cycles in women with clinical and laboratory evidence of hypothyroidism were anovular resulting in menorrhagia. Thyroid replacement therapy restores ovulation. A return to normal menstrual function is presumed though none of the studies in the past documented MBL (Goldsmith et al. 846-55). A recent case report (Higham and Shaw 695-96) used the pictorial blood assessment chart (PBAC) to document a MBL of almost 500 ml in a woman with hypothyroidism which reduced to less than 80 mls with thyroxine.

There is however a lack of evidence that some women who present with menorrhagia may have subclinical hypothyroidism, which may be corrected by thyroxine replacement. Consequently, the routine screening of asymptomatic women who present with menorrhagia is not recommended (The Royal College of Obstetrics and Gynaecology).

#### 1.3.3.3 *Clotting abnormalities*

Menorrhagia is known to be associated with platelet abnormalities, afibrinogenaemia, Von Willebrand's disease, and macroglobulinaemia, factors II, V, VII X and XI deficiency. Inherited bleeding disorders would tend to present in adolescence and

were found in 29% of adolescents who were admitted with acute menorrhagia with no genital tract pathology (Claessens and Cowell 369-78). Menorrhagia in the older woman can result from the use of anticoagulants as shown by a small study of women using oral anticoagulants where 50% of women had a measured blood loss of greater than 80 mls of blood (Van Eijkeren et al. 1261-63). Universal screening for coagulation defects however is not sensitive and hence not cost effective.

#### **1.3.4 Organic causes of excessive MBL**

Conditions that are known to cause excessive MBL include adenomyosis, uterine fibroids, endometrial polyps and the use of the intra uterine contraceptive device.

##### **1.3.4.1 Uterine Fibroids**

Uterine fibroids are benign monoclonal tumours that arise from the smooth muscle cells of the uterus and are peculiar to humans. They are clinically detected in 20% of women under the age of 50 years (Graves WP). With increasing sensitivity and expertise with imaging techniques fibroids are found more frequently. Careful pathological examination of uterine specimens have revealed a prevalence in the order of 77% (Cramer and Patel 435-38). The incidence of fibroids is related to uninterrupted menstruation and age. With more women choosing to postpone the age of conception, an increase in the incidence of fibroids is expected.

In most instances, uterine fibroids do not cause symptoms but when they do they can impair the quality of life. Symptoms that are attributed to fibroids include menorrhagia, pressure effects and occasionally pelvic pain and infertility. Symptoms are usually dependent on the position, location and the size of the fibroids. Due to their high prevalence, fibroids may not be the cause of symptoms and women must be counselled accordingly. While most women with fibroids can be managed expectantly, some require treatment.

Uterine fibroids are the commonest pathology associated with menorrhagia (see section 1.1). Submucous fibroids and to some extent intramural fibroids are known to cause increased MBL. It is uncertain as to whether subserous fibroids have similar effects.

#### 1.3.4.2 Adenomyosis

Adenomyosis is a condition where endometrial glands with stroma are found surrounded by smooth muscle cells in the myometrium of the uterus. It is thought that the endometrial glands penetrate the myometrium by lymphatic and vascular channels. This is possibly due to the breakdown of the endometrial-myometrial border after trauma although the aetiology still remains unclear.

Adenomyosis is identified in 20 – 30% of all uteri and is much less common in uteri weighing greater than 280 g and above 12 weeks gestation size (Bird, McElin, and Manalo-Estrella 583-93; Molitor 275-84). This may be due to pressure atrophy caused by co existing uterine fibroids or that extensive adenomyosis causes such severe symptoms that a hysterectomy is performed before they reach a large size.

Due to its high prevalence there is considerable debate regarding the minimum distance of penetration of the myometrium to make a diagnosis of significant adenomyosis. Suggestions include a) a minimum distance of penetration ranging from 2-4 mm from one to two low-power fields and b) the involvement of at least 25% of the myometrial thickness with adenomyotic foci (Hendrickson MR and Kempson RL 452-67). Histopathological features used to assess the degree of the severity of the disease are depth and number of foci, number of glands, and number of glands per adenomyotic focus and the ratio of the depth of foci to muscle thickness.

Symptoms that have been attributed to adenomyosis are menorrhagia (40-50%) and dysmenorrhoea (15-30%). One third of women are asymptomatic (BENSON and SNEEDEN 1044-57). The depth of adenomyotic foci have been shown to be related to the severity of menorrhagia. There is no correlation shown with the number of foci and the number of glands per focus although all these factors correlate well with the severity of dysmenorrhoea (Nishida 229-31; Nishida 229-31). Diagnosis with hysteroscopy and ultrasonography are disappointing but the adenomyotic foci may be visualised by Magnetic Resonance Imaging (MRI), which because of its cost precludes its use in routine practice. More commonly adenomyosis is discovered in extirpated uteri from women with what was presumed to be DUB where all medical treatments and endometrial ablative treatments have failed.

## **1.4 Medical treatment of DUB**

The medical treatment of menorrhagia depends on whether the woman is trying to conceive or not. In the woman who is trying to conceive, a non hormonal preparation taken during menstruation will help reduce MBL without interfering with ovulation and conception. In the woman who does not wish to conceive, hormonal manipulation is usually given during the cycle. Although in most cases ovulation is inhibited, it is important to counsel women that alternative methods of contraception would be required unless the method used is also contraceptive.

### **1.4.1 Drugs used in the treatment of menorrhagia that does not interfere with fertility**

#### **1.4.1.1 Antifibrinolytic agents**

Epsilon aminocaproic acid was discovered in 1959 and 5 years later tranexamic acid and para amino methyl benzoic acid were synthesized. These substances were found to inhibit the activation of plasmin from its precursor plasminogen in the fibrinolytic pathway. In women with DUB there appears to be an increase in the normal fibrinolytic activity seen in the late proliferative and menstrual endometrium as described in section 1.2.2

In a meta analysis of seven trials where women with both objective and subjective menorrhagia were treated by tranexamic acid, Coulter et al (Coulter et al. 456-71) found a reduction in pre treatment MBL by an average of 46.7% (range = 35-56%). The dose varied from 0.5g – 3g a day during menstruation. Therapy lasted from two to six months. Limitations of the studies were that a placebo effect could not be excluded as some of the trials did not have a placebo arm.

In other studies that have compared tranexamic acid to placebo and NSAIDs, tranexamic acid was shown to cause the biggest reduction in MBL and improvement of QOL. It does not however appear to have any effect on the duration of MBL or menstrual pain.

Side effects that have been reported in up to 60% of women taking tranexamic acid include nausea, vomiting, diarrhoea, headache, dizziness, weight gain and leg cramps. A report of intra cranial thrombosis as a rare but serious side effect (Rydin and Lundberg 49) delayed the introduction of this drug in the United Kingdom until large



scale studies in Scandinavia showed that the incidence of thromboembolism with the use of tranexamic acid was no higher than the background incidence. However a history of thromboembolism is a contraindication to treatment. Another rare adverse effect is transient colour vision disturbance, which requires the withdrawal of the drug.

The RCOG recommend Tranexamic acid at a dose of 1 g three times a day. Treatment should be started on the first day of the period for the days of the heavy flow. This is now the recommended first line of treatment in women who do not require contraception or who prefer non hormonal contraception (The Royal College of Obstetrics and Gynaecology).

#### *1.4.1.2 Prostaglandin inhibitors*

In 1971, Vane demonstrated that a wide range of substances that were non steroidal, anti inflammatory and acidic in nature were potent inhibitors of prostaglandin synthetase, which promoted the conversion of unsaturated fatty acids into prostaglandins (Vane 232-35). This group of substances are referred to as Non Steroidal Anti Inflammatory Drugs (NSAIDS). The fenamates were also found to inhibit the action of prostaglandin on the uterine smooth muscle. DUB especially associated with dysmenorrhoea appears to be due in part to the high concentrations of prostaglandins that are normally found in the implantation and menstrual endometrium as described in section 1.2.2

In the meta analysis already referred to , Coulter examined ten studies which showed that mefenamic acid reduced the pre treatment MBL by a mean of 29% (range = 19-47%). Dosage was 1.5 g each day and was given during menstruation for two months. Mefenamic is effective in controlling symptoms of dysmenorrhoea, menstrual migraine and diarrhoea. No effect on the duration of the menstrual period is seen.

Side effects occur in 50 – 80 % of women and include nausea, indigestion, abdominal discomfort, depression, tiredness, light-headedness, headaches and skin irritation. Skin rashes are only occasionally seen but require withdrawal of treatment. There are more contraindications to treatment than tranexamic acid. These are a history of gastro intestinal ulceration or bleeding, inflammatory bowel disease, a history of

hypersensitivity (e.g. asthma, angioedema, urticaria or rhinitis) precipitated by aspirin or other NSAIDs and hepatic or renal impairment.

The RCOG guidelines recommend mefenamic acid as an alternative to tranexamic acid as a first line treatment for menorrhagia. Even though mefenamic acid is not as efficacious as tranexamic acid, its anti prostaglandin properties makes it desirable in women with additional menstrual symptoms like dysmenorrhoea, menstrual migraine and menstrual diarrhoea.

Mefenamic acid and Tranexamic acid are now the recommended first line therapeutic agents in the treatment of menorrhagia. Knowledge of their mechanisms of action suggests that when used in combination their actions should be synergistic. However there is no evidence from clinical trials to support this.

#### 1.4.2 Drugs used in the treatment of menorrhagia that affect fertility

##### 1.4.2.1 *Combined oral contraceptive pills (COCP)*

COCP's are useful in regulating MBL probably by inducing an element of endometrial atrophy. The proliferation of the endometrium and the final height of the endometrium are reduced and as a result so is the blood loss when menstrual endometrial shedding occurs.

##### Effect of the COCP on objective menorrhagia

Nilsson and Rybo studied 164 women with objective menorrhagia who were given the COCP in the usual 21 day cycles for a total of 284 cycles (Nilsson and Rybo 713-20). The COCP preparations used were: 5mg lynestrenol and 0.15mg mestranol in 131 cycles; 3 or 4 mg norethisterone acetate and 0.05 mg of ethinylestradiol in 86 cycles; 1 mg norgestrel and 0.05 mg of ethinylestradiol in 54 cycles and another COCP in 12 cycles. There was a 52% reduction in MBL in the whole series: Eighty eight percent of women with a pre treatment MBL of 80 – 100 ml; 69% of women with a pre treatment MBL of 100 – 200 ml and 44.5% of women with a MBL of greater than 200 ml benefited from therapy. There was no significant difference in the reduction in MBL between the treatments.

### Effect of the COCP on subjective menorrhagia

Nilsson and Slovell studied the effect of the COCP in women with subjectively normal MBL with no detectable pelvic pathology (Nilsson and Solvell Suppl-31). COCP preparations that were used contained either 50 µg of ethinylestradiol or 0.075 – 0.1 mg of mestranol. Pre and post treatment MBL were compared in 19 women over a total of 187 periods. A 54% reduction in MBL was seen with there being no statistically significant differences between the preparations used.

### Effect of COCP on the development of iron deficiency anaemia

A large prospective observational study in 1969 published through the auspices of the Royal College of General Practitioners (Royal College of General Practitioners) compared the prevalence of iron deficiency anaemia between COCP users and non users. 23,611 COCP users were compared with 22,766 non users who were matched for age and social class. COCP users were found to be less likely to develop menorrhagia (relative risk of 0.52) and iron deficiency anaemia than non users.

It appears that the COCP improves both subjective and objective menorrhagia and thereby iron deficiency anaemia. However, the trials quoted used the 50-µg ethinylestradiol preparations, which are seldom used today because of risks of thromboembolism. Furthermore it is not known whether the nature of the progestagen used influences the amount of MBL. Whilst tranexamic acid does not seem to increase the therapeutic effect of the COCP, it is not known whether mefenamic acid would affect it. Further research is required to answer these questions. The justification for using the current COCP preparations (30 µg ethinylestradiol) is from the extrapolation of the data from the high dose formulations.

#### *1.4.2.2 Progestogens*

##### *Low dose luteal phase treatment*

Low dose luteal phase administration of progestogens has been used for the treatment of menorrhagia in the belief that menorrhagia is due to lack of progesterone support in the luteal phase of the menstrual cycle. It was hypothesised that treatment with progestogens would rectify this and result in normal endometrial shedding and therefore normal MBL. Luteal phase norethisterone acetate (NET) was the commonest drug prescribed by general practitioners for menorrhagia.

There are four randomised controlled trials that compared the effect of luteal phase progestogens with other drugs used in the treatment of menorrhagia (Cameron et al. 99-110; Cameron et al. 85-88; Higham and Shaw 1134-39; Preston et al. 401-06). Two studies which recruited women with objective measurements of MBL > 80 mls showed an increase in the MBL of 12% and 20%. The other two studies which also entered women with objective menorrhagia (MBL >80 mls & MBL > 50mls) showed a reduction in MBL of 20% and 4% respectively.

A meta analysis of these studies showed that NET actually caused an increase in MBL by 3.6% (Coulter et al. 456-71). The RCOG publication states that “in the dosages and timings currently recommended in data sheets and in the British National Formulary norethisterone cannot be recommended as an effective treatment for menorrhagia”.

#### *Increased dose and long course progestogens treatment*

NET at a dose of 5mg tds from day 5 to day 26 of the menstrual cycle to 22 women with objective menorrhagia caused a significant reduction in median MBL of 85% at 1 month and 94% at 3 months (Irvine et al. 592-98). Nearly half the women “liked the treatment well or very well” with about a quarter indicating that they would “wish to continue with the treatment”.

#### *Long acting depot preparations of progestogens*

Depot preparations of progestogens may be administered either by a depot injection or as a subdermal implant. Medroxyprogesterone acetate is used for contraception at a dose of 150mg every 3 months. One of the common side effects is unpredictable irregular spotting that may last up to 6 months. However with repeated use endometrial gland atrophy and stromal decidualisation occur and after 1 year 40 – 50% of women have amenorrhea. Subdermal implants that release levonorgestrel have similar effects.

Consequently depot preparations of progestogens may be used to treat women with menorrhagia. However it has not been investigated in this context. The unpredictable and sometimes very heavy irregular bleeding that it can induce together with recent concerns of osteoporosis does not make it a desirable alternative to other medications in current use.

### *Levonorgestrel loaded intra uterine system (LNG-IUS)*

The LNG-IUS (Mirena intrauterine system – Schering Health Care Ltd, Burgess Hill) is a medicated intra uterine system that was developed in Finland in the mid 1970's to release 20 µg of levonorgestrel every 24 hours directly into the endometrium. This is taken up mainly by the basal layer of the endometrium with only slight increases in plasma progestagen levels when compared to other hormonal contraceptives. The hormone causes suppression of endometrial growth and within three months of insertion the endometrial glands are inactive with stromal decidualisation. There are also changes in the cervical mucus but the concentration of the progestagen in the blood is too low for inhibition of ovulation. These changes reverse to normal with removal of the device.

The LNG-IUS was initially developed in order to reduce the heavy periods associated with the use of the copper IUCDs that resulted in women discontinuing it. Review of results after five years of use showed that the incidence of pregnancies was very low, expulsion rates were no different from other IUCDs and the incidence of ectopic pregnancies was very low. It was also noted that there was a significant reduction in MBL with a high incidence of oligo - amenorrhea. The LNG-IUS was initially licensed in 1995 for contraceptive use for a period of 3 years. The period of use was extended to 5 years in 1998.

The initial findings of its effect on MBL prompted some studies that investigated its effect on women with menorrhagia. A systematic review of 5 case studies and 5 case controlled studies was done by Stewart et al in 2001(Stewart et al. 74-86).

#### *Case studies*

These were observational studies on women with menorrhagia who were prescribed the LNG-IUS system. One study used the system in menorrhagia associated with adenomyosis while others used it in women with presumed DUB (n=91). Mean MBL reduction at 3 months (75-87%) and 12 months of use (79-97%) were found to be significant. This was associated with an increase in haemoglobin (8-19%) and serum ferritin (36-47%) with relatively few side effects (0-15%). Barrington and Bowen-Simpkins recruited 50 women who had menorrhagia that had failed medical treatment and were on the waiting list for a TCRE or a hysterectomy(Barrington and Bowen-

Simpkins 614-16). Following insertion of the LNG-IUS, 41 women (85%) were removed from the waiting list because of a reduction in the mean MBL score.

*Case Controlled studies (Comparison of the LNG-IUS with other managements)*

Comparison of LNG-IUS with Norethisterone acetate (NET)

In 1998, Irvine et al (Irvine et al. 592-98) randomised 44 women with DUB into either taking NET 5mg three times daily for 21 days (n=22) or the LNG-IUS (n=22). Reduction in median MBL was significantly greater in the LNG-IUS group when compared to the NET group (85% vs. 62% at 1 month; 94% vs. 83% at 3 months). More women “liked treatment well” or “very well” in the LNG-IUS group (64% vs. 44%) and were prepared to continue with the treatment when compared to the NET group (77% vs. 22%).

Comparison of LNG-IUS with NSAIDs and Antifibrinolytic drugs

Milsom et al (Milsom et al. 879-83) compared the LNG-IUS with the NSAID Flurbiprofen (100mg twice daily for 5 days) and the anti fibrinolytic Tranexamic acid (1.5g three times daily for days 1-3 and 1g bd for days 4-5 of the menstrual cycle) in women with DUB. The first 20 women were given the LNG-IUS and the next 15 women were randomised to the drugs in a cross over design. Reduction in mean MBL was significantly higher in the LNG-IUS group (96% at 1 year) when compared with the Flurbiprofen group (22%) and the Tranexamic acid group (44%). However side effects were most significant in the LNG-IUS group with a 20% discontinuation rate. None of the women in the other two groups discontinued treatment.

Comparison of LNG-IUS with TransCervical Resection of the Endometrium (TCRE)

Crosignani et al (Crosignani et al. 257-63) compared the effects of the LNG-IUS with TCRE in women with DUB in a randomised trial. MBL was measured by the PBAC and the effect of treatments on the QOL of these women by using Short Form 36 (SF 36) questionnaires. The mean reduction in MBL was higher in the women who underwent TCRE (89% at 12 months) compared with the LNG-IUS group (78% at 12 months). Side effects were more commonly reported in the LNG-IUS group (15) and the discontinuation rate was 15%. There was no significant difference in the SF 36 scores between the two groups.

## Comparison of LNG-IUS with Hysterectomy

Hurskainen (Hurskainen et al. 273-77) compared the effect of the LNG-IUS with hysterectomy on the QOL of women with menorrhagia and the cost effectiveness of each procedure. 236 women with menorrhagia were randomised to treatment with the LNG-IUS (n=119) or hysterectomy (n=117). The amount of MBL was objectively measured and a QOL assessment was repeated at 12 months follow up. In the group assigned to LNG-IUS, 24 (20%) women had a hysterectomy and 81 (68%) continued to use the system at 12 months. Of the women assigned to the hysterectomy group, 107 underwent the operation. Health-related QOL improved significantly in both the IUS and hysterectomy groups, as did other indices of psychological well being. There were no significant differences between the treatment groups except that women with hysterectomy suffered less pain. Overall costs for hysterectomy group were three times higher compared to the IUS group.

The LNG-IUS has been studied mainly in the context of contraception. The studies reported above are the ones that investigated the use of the LNG-IUS in women with DUB. These are few with small numbers of women recruited, and the maximum follow up has been only up to one year in a device that has been licensed for 5 years. Nevertheless all studies report a substantial reduction in MBL and a reduction in the request for a surgical procedure. It has also been shown to improve the QOL of women with DUB and be a cost effective alternative to a hysterectomy. The data on the comparison of the efficacy of the LNG-IUS with other medical treatments are sparse. This medical treatment is however being increasingly utilised in women with DUB and it has now been licensed for use in menorrhagia. Problems that remain are a discontinuation rate of up to 25%. Furthermore, the side effect of unscheduled vaginal bleeding that may last up to 6 months may not be acceptable to certain women because of religious or other reasons.

### *1.4.2.3 Danazol*

Danazol is a derivative of testosterone. It acts centrally by inhibiting the mid cycle surge and pulsatile secretions of gonadotrophins. It also directly inhibits ovarian steroidogenesis and competitively blocks androgen, progesterone and oestrogen receptors in the endometrium. Free testosterone is increased by the inhibition of hepatic synthesis of sex hormone binding globulin.

Danazol has been extensively studied for the treatment of menorrhagia. Dosages that have been used vary from 50 – 400mg daily for variable time periods. A 200mg dose reduces MBL by 85% after 3 months (Chimbira et al. 1152-58). The main disadvantages of this treatment however are the side effects, which were reported by up to 75% of women who were on the medication with up to 40% of women finding them unacceptable leading to discontinuation of therapy.

The commonest complaint was the anabolic side effect of the drug causing an average weight gain of 2-4 Kg within 3 months of use. Other side effects are related to the androgenic nature of the drug and include acne, seborrhoea, hirsutism and voice changes. Hypo-oestrogenic side effects are rare and include hot flushes and breast atrophy. Voice changes in some women are irreversible and hence a matter of concern. Treatment with Danazol is not contraceptive and carries the risk of virilisation of a female fetus if a woman became pregnant while on treatment. Hence barrier contraception is required throughout therapy.

Danazol is currently licensed in the treatment of menorrhagia. The RCOG guidelines state the “while Danazol is effective in reducing menstrual blood flow, its daily regime and its side effects mean that it is not a suitable or acceptable treatment for all women and should not be used as a first line of treatment.”

#### **1.4.2.4 Gestrinone**

Gestrinone is a derivative of testosterone and has an action similar to Danazol. It has been shown to cause a significant reduction in MBL. Following cessation of treatment MBL returns to pre treatment levels in 3 months. The commonest side effect is weight gain (average 2 Kg) (Turnbull and Rees 713-15). Other side effects are acne, seborrhoea, hirsutism and muscle cramps, which are reversible on stopping treatment.

Gestrinone does appear to be an effective short term medical treatment for the treatment of menorrhagia. It however has an undesirable side effect profile, which may be unacceptable to some women. It is currently not licensed for menorrhagia and requires larger studies to confirm its efficacy and safety.



#### *1.4.2.5 Gonadotrophin Releasing Hormone analogues (GnRHa)*

Modifying the native gonadotrophin releasing hormone molecule with substitutions of amino acids in position 6 and 10 causes a prolongation of its therapeutic half life. Continued occupation of receptors leads to pituitary down-regulation with a state of hypogonadotrophic hypogonadism resulting in endometrial atrophy. Even though it is unlikely for pregnancies to occur while on treatment, contraception is not guaranteed and as such barrier contraception is required.

GnRHa are not licensed for the management of menorrhagia. The evidence for its effect on DUB comes from 3 studies. In a study on women with objectively proven MBL of > 80mls, intranasal buserelin reduced MBL from 95-198 mls to 4-30mls after 3 months of treatment in the four women studied (Shaw and Fraser 913-16). Goserelin by a subcutaneous injection monthly for 3 months had similar effects. Five out of six women studied had amenorrhea and the remaining woman had a MBL of 2 mls (Gardner RL and Shaw 149-59). The effect of Goserelin was also studied in 22 women with anovular DUB causing an iron deficiency anaemia of <9 g% (Vercellini et al. 127-29). All the women became amenorrhoeic with a significant increase in serum ferritin, serum iron, Hb and haematocrit. Stopping treatment with GnRHa caused the MBL to return to pre treatment levels in 16-27 days when intranasal buserelin was used and 7-10 weeks when Goserelin was used.

The most troublesome side effect was hot flushes as a consequence of the hypo oestrogenic state and this was experienced by up to 91% of women. Over a six month period there was a 3-5% loss in vertebral trabecular bone density of the lumbar spine. This has not been shown to be associated with an increase in fracture risk and said to be equivalent to the osteoporotic effect of 6 months of breast feeding. Because of the risk of irreversible osteoporosis with long term use, GnRHa have been licensed only for 6 months use. Add back therapy with hormone replacement therapy to counteract the vasomotor symptoms and decrease osteoporosis has been used and appears not to reduce the therapeutic effect (Hornstein et al. 16-24).

The RCOG guidelines state that “GnRH analogue treatment is effective in reducing MBL but can only be considered as a temporary treatment, perhaps while awaiting surgery or the natural menopause”.

## **1.5 Medical management of uterine fibroids**

### **1.5.1 Antifibrinolytic drugs and NSAIDs**

There is no conclusive evidence that shows the effect of Antifibrinolytics and NSAIDs on the treatment of menorrhagia secondary to uterine fibroids.

### **1.5.2 Combined Oral Contraceptive Pills**

A reduction in MBL of 25% was seen in women with menorrhagia and uterine fibroids (Nilsson and Rybo 713-20). However, details of the fibroids were not included and high dose formulations were used making it difficult to interpret the significance of these results.

### **1.5.3 Danazol and Gestrinone**

Danazol can be used to induce amenorrhea and thereby correct iron deficiency anaemia in women with fibroid induced menorrhagia. Reduction in uterine volumes in 100 women who had uterine fibroids were seen when Gestrinone was administered in 3 regimes: 2.5 mg oral capsules three times weekly; 5.0 mg oral capsules twice weekly; 5 mg vaginal tablets three times weekly (Coutinho and Goncalves 939-46). Volume reduction was greatest in the vaginal route group. Interestingly 89% of treated women maintained the reduction 18 months after stopping treatment.

### **1.5.4 Gonadotrophin Releasing Hormone analogues (GnRHa)**

Studies have shown that GnRHa reduce uterine size from 35% to 65% with a large number of women having amenorrhea (Shaw 859-64;Stovall et al. 65-71;Friedman et al. 251-56;Schlaff et al. 856-62). However with cessation of treatment rapid regrowth occurs with a return to pre treatment size in 3 to 6 months.

GnRh agonist therapy before surgery causes a reduction in the uterine volume, improved pre operative packed cell volume, decreases in the intraoperative estimated blood loss and vertical incisions at surgery. The significance of this is not known as the incidence of blood transfusion is not reduced and there are claims that myomectomy is more difficult due to a loss of a plane of cleavage between the fibroid and normal myometrium.

There have been attempts to extend the use of GnRHa with additional medications that would reduce its side effects. The earliest medication that was introduced was medroxyprogesterone acetate. This was chosen in the belief that it would not interfere with the degree of hypoestrogenism induced by GnRHa. Results however showed a reduction in the effect when compared to using GnRHa alone. (Carr et al. 1217-23) However, if GnRHa are used alone for the first three months before a progestagen add back regime is commenced, some of the reduction in uterine volume and symptoms are maintained.

Since then, oestrogen and progestogens add back therapy has also been studied. Fifty one women with uterine fibroids were given GnRHa for 3 months. A 40% reduction in uterine volume and 2.6% reduction in bone mineral density were noted. They were then randomised into 2 groups of add back therapy for 2 years – oestrogen and progestogens add back and progestogens only add back (Carr et al. 1217-23; Friedman et al. 1618-25). Women who received the combined add back maintained the uterine volume reduction with no further reduction in bone density. In the progestogens add back group, the uterine size returned to pre treatment size by month 24.

## **1.6 Summary and conclusions**

An increasing understanding of the menstrual cycle has enabled the development of many medical interventions to reduce MBL as shown in Table 1. Until recently, this has been used in a non systematic way with the most ineffective treatment (low dose luteal phase progestogens) being the most common prescription used in primary care. Consequently, the RCOG has published national guidelines for managing women with menorrhagia. It is presumed that if these were to be fully supplemented it would significantly reduce the need for surgery. The limitations with medical therapy are the resumption of symptoms once treatment is stopped. In addition, side effects can further reduce the QOL in these women. Comparisons of the mode of action, dosage, side effects, efficacy and recommendations for use of each of the group of medications discussed in this chapter are shown in Table 1. The LNG-IUS was thought to revolutionise treatment but is limited by the almost constant blood stained vaginal discharge for 6 months which precludes it from use from certain religious minorities and causes discontinuation of treatment in up to 25% of women.

Drug	Mode of action	Dose	Main side effects	MBL reduc'n	Contraceptive effect	Use
Tranexamic Acid	Antifibrinolytic	1g tds	Mainly thrombosis	50%	None	1st line – retain fertility
Mefenamic Acid	Prostaglandin inhibitor	500mg tds	GI effects	30%	None	2nd line – retain fertility
COCP	Endometrial atrophy	Depends on preparation	Thrombosis	50%	Contraceptive	Effective method
Luteal phase Progestogens Day 16-25	Endometrial atrophy	NET 5mg tds MPA 10mg tds	Acne weight gain	- 4%	Barrier method required	Not to be used
Long cycle Progestogens Day 5 - 25	Pseudo decidual change	NET 5mg tds MPA 10mg tds	Acne weight gain	90%	Barrier method required	Effective method
Danazol	Anti Gn, Anti E2 Anti P; Androgenic	200 mg daily	Weight gain androgenic	85%	Barrier method required	Side effects prohibit use
Gestrinone	Similar to Danazol	2.5 mg twice weekly	Weight gain androgenic	85%	Barrier method required	Evidence too scanty
GnRh analogues	Pituitary downregulation	3.75 / 3.60 mg SCT	Vasomotor osteoporosis	100%	Barrier method required	Short term use
LNG-IUS MIRENA	Endometrial atrophy	20µg daily release	Nuisance bleeding	85%	Contraceptive	Must be offered before surgery

Table 1 Table comparing the dosage, mode of action, side effects, efficacy, contraceptive effect and recommendations for use of medications available for treatment of heavy periods

GnRHa are limited to short term therapy because of the side effects of vasomotor symptoms and loss of vertebral mineral bone density.

Evidence for the medical treatment of uterine fibroids is surprisingly scarce in what is a very common condition. The evidence reviewed shows that there is no long term effective medical treatment for uterine fibroids.

If hysterectomy for the treatment of women with DUB and symptomatic fibroids is to be reduced by medical treatment alone, further research and development is required.

# [2] Surgical alternatives to hysterectomy for heavy periods

Hysterectomy is associated with a 100% primary success rate and high patient satisfaction scores but it is a major surgical procedure with significant physical and emotional complications, social and economic costs (see section 2.1.1). As dysfunctional uterine bleeding and uterine fibroids contribute to 63% of hysterectomies that are performed for the complaint of menorrhagia, the last twenty years have seen a rapid increase in the development of alternative surgical techniques to treat these conditions in an attempt to reduce the need for hysterectomy.

The aim of this chapter is to discuss the need, history of development and current alternative techniques used for the treatment of DUB and uterine fibroids.

## **2.1 Hysterectomy**

Hysterectomy used to be considered the treatment of choice for menorrhagia in women who had completed their family. It is associated with a high patient satisfaction rate and sense of mental well being after surgery(Carlson, Miller, and

Fowler, Jr. 556-65; Kjerulff et al. 1440-47). It is also the only modality of treatment which guarantees a 100% cure for both heavy MBL and uterine fibroids.

### 2.1.1 Problems with hysterectomy

Hysterectomy is a major operation with attendant morbidity and mortality (1:2000 under the age of 50). The average hospital stay is five days with a further four to eight weeks required to return to normal activity (Dicker et al. 841-48).

The complications associated with hysterectomy are shown in Table 2.

Complication	Frequency of occurrence
Haemorrhage	1-3%
Infection	Up to 9%*
Injury to bladder, bowel and ureter	1-2%, 0.4% and 0.2%
Thromboembolic disease	Low risk 0.25, high risk 2.4%
Wound dehiscence	0.3 – 0.7%
Return to the operating theatre	4%
Preponement of the menopause	Not known

Table 2 Table showing the frequency of intraoperative and postoperative complications of a hysterectomy. Long term sequels are also shown. \*Infection rates are currently lower as prophylactic antibiotics at the time of surgery have become routine practice.

### 2.1.2 History of uterine conserving surgery

In 1949, vigorous curettage of the uterus in the puerperium or after a miscarriage was observed to be associated with obliteration of the uterine cavity from fibrosis resulting in reduced or absent menstrual periods.(Ashermann JG 892-96) This has led gynaecologists to find a way of inducing this situation as a treatment for DUB. The first report of destruction of the endometrial lining by the thermal energy from a laser for the treatment of DUB as an alternative to a hysterectomy was in 1981(Goldrath, Fuller, and Segal 14-19).

The first uterine conserving procedure for uterine fibroids was performed by Amussat in 1840 when he did a myomectomy under the misconception that it was an ovarian tumour because it was on a pedicle. Atlee was the next surgeon to perform it. In 1889, Alexander of Liverpool reported a technique by which he was able to remove

25 such tumours from a single uterus. It was however only 24 years later that Victor Bonney developed this technique as an alternative to a hysterectomy(O'Dowd MJ and Phillip EE 411-12). The ethos for doing so can be summarised by his following remark;

*“Apart from its physical value, the womb has for most women a sentimental value which however illogical cannot be discounted.”*




Figure 1 Victor Bonney

This may have been from his personal observations on the change in his wife Annie who had to undergo an emergency hysterectomy at the Middlesex Hospital for severe anaemia from menorrhagia. It is said that after the hysterectomy, she retired from active life and lived away from children.

Alternative routes to myomectomy have been developed to avoid laparotomy. Recently techniques that reduce the blood supply to the fibroid and damage the collagen within the fibroid are being investigated.

## **2.2 Alternative surgical treatment of DUB**

### **2.2.1 First generation endometrial ablation techniques**

#### **2.2.1.1 Laser ablation**

Transcervical endometrial ablation was first described by Goldrath in 1981. (Goldrath, Fuller, and Segal 14-19) The procedure involves destroying the endometrium including the basal layer by coagulation or charring using an Nd:YAG

laser. This is done via an optical fibre that is passed through a channel in the operating hysteroscope.

The procedure is done under general anaesthesia. The resectoscope sheath has a diameter of 9 mm and as a result the cervix needs to be dilated to Hegar 10. The hysteroscope is inserted, the optical fibre introduced and the fibre is then drawn along the fundus and the walls of the uterus till the whole uterus is treated. The power used is usually 50 Watts at continuous wave.

The procedure is not very popular due to the expense of the laser and the availability of cheaper alternatives. In addition, personnel are required to have been specifically trained in operating the laser. Health and safety regulations today also need the appointment of a laser safety officer to ensure that all precautions are taken to reduce the risk of inadvertent laser injury to the patient, operator and other staff. Another disadvantage of this procedure is that there is no tissue available for histopathological examination. Adequate biopsies of the endometrium must therefore be taken prior to the procedure.

### *2.2.1.2 Loop resection*

The technique used for loop resection of the endometrium was borrowed from the urologists from the procedure transurethral resection of the prostate. The procedure was developed in North America in 1987 by Alan DeCherney (DeCherney et al. 668-70). Adam Magos's group published the first case series (Magos, Baumann, and Turnbull 1209-12). This is the commonest method (80%) practised in the United Kingdom (Overton, Hargreaves, and Maresh 1351-59).

Transcervical resection of the endometrium is carried out usually under a general anaesthetic. The cervix is dilated as described in section 2.2.1.1. The procedure is started at the fundus and then the sidewalls of the uterus before proceeding to the anterior and posterior walls. The uterus is distended with a non electrolyte solution (commonly 1.5% glycine) which is continuously irrigated through the double lumen sheath enabling the clearing of blood and debris and the maintenance of an optimal view. The operating hysteroscope is attached to a monitor so that the operation is performed visualising the monitor. The hysteroscope is a 4mm diameter scope with a 30 degree or 12 degree angle. The loop electrode is 24 F through which is delivered a 100-150 W cutting or blended current.



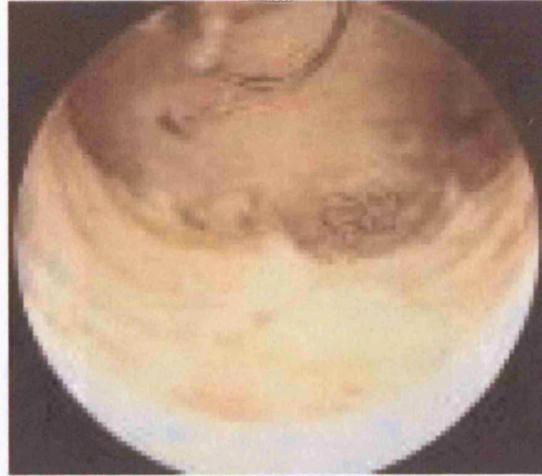


Figure 2 Picture showing the loop resectoscope being used. At the bottom of the picture two sections of the uterine endometrium have been resected with the loop. The distension medium is 1.5% glycine

The activated loop is moved towards the operator under vision taking 3-4 mm depth of endometrium as a chip exposing the muscle fibres of the underlying myometrium. The chips are then sent for histopathological evaluation. Rollerball diathermy may be used after the procedure to control bleeding points.

#### **2.2.1.3 Roller ball ablation**

This was first described by Vancaille in 1989 (Vancaillie 425-27). It is a simpler technique than loop resection and may be employed by an operator who is in the early learning curve of operative hysteroscopic surgery. The rollerball electrode has a larger contact with the endometrium (a 3 mm ball is usually used though a 5 mm ball is also available but tends to obscure the operators view). It is easier to maintain as it rotates around its own axis, thereby distributing the electrical energy over a larger surface area reducing the likelihood of damage to the deeper layers of the myometrium and serosa. It also fits better into the cornua of the uterus making it easier to treat this area, which is difficult to resect with the loop electrode. However, there are no strips of endometrium produced, which not only obscure the operators view but also increase the procedure time. As the procedure time is reduced and the depth of penetration is controlled the chances of fluid overload with dilutional hyponatraemia is reduced. After introduction of the resectoscope the ball is placed firmly onto the endometrium and current is then applied to check the extent of surrounding blanching in order to gauge the amount of current needed.

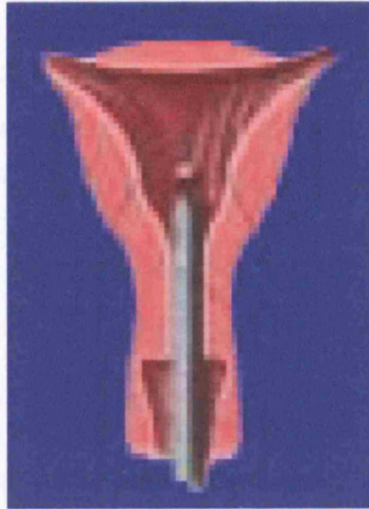


Figure 3 Diagrammatic representation of roller ball ablation of the endometrium. The thermal burns to the endometrium are illustrated. This procedure does not produce any tissue for histological evaluation

The usual recommendation is 40 – 60 W on a coagulation setting moving the ball through a distance of 1 cm per second. Under direct vision, the entire endometrium can be ablated. Adequate biopsies must be obtained prior to treatment as there is no histological specimen.

#### **2.2.1.4 Combined loop resection and roller ball ablation**

Many surgeons today use a combination of both techniques. The roller ball is used to thermally destroy the endometrium in the cornua and the fundus. The loop resectoscope is then used to finish the treatment. This is following a national audit that showed lower risk of perforation with roller ball treatment of the ostia (Overton, Hargreaves, and Maresh 1351-59).

#### **2.2.1.5 Outcome of hysteroscopic surgery**

The success rate at one year for TCRE and ELA is approximately 75% (amenorrhea rates of 42% and oligomenorrhea of 33%) with 9% requiring repeat treatment, and 16% needing a hysterectomy. (A Scottish audit of hysteroscopic surgery for menorrhagia: complications and follow up. Scottish Hysteroscopy Audit Group 249-54;Dwyer, Hutton, and Stirrat 237-43) Patient satisfaction is about 84% with median hospital stay being one day. There is no significant difference in these outcome measures between TCRE and ELA. 5 year follow up studies have shown that 76% - 80% of women would avoid a hysterectomy. (O'Connor and Magos 151-56) Failure was found to be more common in women under the age of 40 years, if the surgeon

had performed less than 10 procedures, if intramural fibroids were present or if the operation was done in the luteal phase of the menstrual cycle. Endometrial thinning was thought to be a significant factor but this was shown to make no difference to the outcome in the MISTLETOE study (Overton, Hargreaves, and Maresh 1351-59).

## 2.2.2 Second generation endometrial ablation techniques

### 2.2.2.1 Cryotherapy

In this procedure, the cervix is dilated with a cryoprobe (similar to a Hegar dilator) as shown in Figure 4, which enables its introduction to the uterine cavity. 3-5ml of saline is introduced into the device via a syringe. Using nitrous oxide or carbon dioxide, the probe is cooled by the rapid gas expansion to  $-45^{\circ}\text{C}$ . Two freeze thaw cycles, each taking about 5 minutes are required to complete treatment. Initial results from this procedure were disappointing. In a more recent study 279 women with menstrual bleeding due to benign causes were prospectively randomised to undergoing endometrial cryoablation or roller ball electroablation. MBL reduction was similar in both groups (92% vs. 94%), as was improvements in pain, mood and QOL. (Duleba et al. 17-26)



Figure 4 Figure showing the cryoprobe with gas delivery unit

### 2.2.2.2 Radio frequency

This method consists of thermal ablation of the endometrium induced by the rapid oscillation of charged particles in the tissue directly around an intrauterine radiofrequency probe. 550 watts of power is applied for 20 minutes to raise the

temperature of the stratum basalis to approximately 50 – 55 ° C whilst the rest of the pelvic contents remain at normal body temperature.




Figure 5 Diagrammatic representation of the activated radiofrequency tip probe

Early experience included complications of anterior vaginal wall fistulae in 2 women (Phipps et al. 374-76). Since then the probe has been considerably modified. A more recent study involving thirty two women with DUB reported a success rate of 84% with 31% of women becoming amenorrhoeic and 53% showing significant reduction in MBL (Prior et al. 213-20).

### 2.2.2.3 Microwave endometrial ablation (MEA)

This surgical device was developed in 1992 at the University of Bath in conjunction with the Royal University Hospital. (Microsulis plc, Waterlooville, Hampshire, UK) It consists of a microwave “waveguide” (a metal tube along which microwave energy propagates and is then released at the tip or distal opening) filled with dielectric material (that focuses the beam as it passes through so that a smaller diameter of waveguide may be used). The dielectric propagates microwaves at a frequency of 9.2GHz which was shown in experiments (both in vitro and in vivo) to produce tissue destruction to a depth of 6 mm. The diameter of the waveguide is 8 mm requiring the cervix to be dilated to 9 mm. The microwaves that are released from the tip are distributed in a spherical fashion which helps the heating effect to be evenly distributed. The waveguide is coated with a fluoroplastic sheath, which allows for chemical and autoclave cleaning. It is graduated in cms.

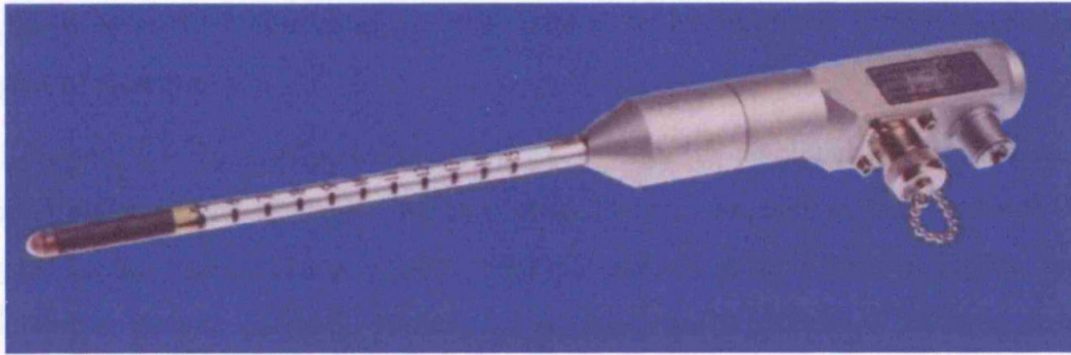


Figure 6 Figure showing the waveguide with the sheath (graduated in cms) which is used for microwave endometrial ablation

The device is attached to a system that generates the microwaves (magnetron) and monitors temperature. This is viewed by the surgeon as a computer display with an allocated treatment band. A hard copy can be obtained at the end of the procedure. Under a general anaesthetic (more recently MEA is being performed under a local anaesthetic) the cervix is dilated to Hegar 9. The uterus is sounded and the applicator is inserted to that depth. The power is switched on with a foot switch and heating occurs rapidly and temperatures enter the treatment band within a few seconds. The applicator is then moved from side to side until the whole fundal area is treated. The applicator is withdrawn with the same side to side movements for treatment of the walls of the uterus. As the applicator approaches the internal os a safety zone becomes visible at the internal os as indicated on the applicator. This has been set at 4 cms from the tip.

The initial study included a 6 month follow up of 23 women with a total of 26 treatments (Sharp et al. 1003-04). The average procedure time was 2 minutes and 12 seconds. The success rate of the procedure was 83% with 13 (57%) patients becoming amenorrhoeic, and six (26%) experiencing light menstruation. Three initial failures were successfully retreated.

In a randomised controlled trial comparing MEA (n=129) with TCRE (n=134) (Hodgson et al. 684-94), participants were asked to complete a baseline clinical and SF-36 questionnaire, to grade severity of bleeding and pain and to document bladder and bowel symptoms. This was repeated at 4 and 12 months. MEA achieved a 77% satisfaction rate and TCRE a 75% satisfaction rate. Both techniques were highly acceptable and improved QOL after 1 year. There was one case of uterine perforation

reported in each treatment group, the woman undergoing the TCRE requiring an urgent hysterectomy.

MEA appears to be as effective as TCRE but most of the outcomes measured were not significantly different between the two procedures. The odds of haemorrhage were higher in the TCRE group but the odds of equipment failure were higher in the microwave group. In both studies, MEA was mainly performed under a general anaesthetic even though one of the advantages cited are its use in the outpatient setting. There are scarce data in this setting and it would be interesting to see if the patient satisfaction results are the same.

#### 2.2.2.4 Fluid Balloon

##### Cavaterm endometrial ablation system

The system consists of a disposable catheter and a battery operated central unit. The central unit has a self-regulating electrical element that generates heat at 80 °C. The oscillatory pump maintains a continuous flow of heated fluid around the system. The balloon is made of silicone and its length can be adjusted to fit the uterine cavity. The end of the catheter at the lower end of the balloon is insulated to prevent thermal injury to the cervix. The outer diameter of the catheter is 8 mm requiring cervical dilatation to 9 mm for insertion.

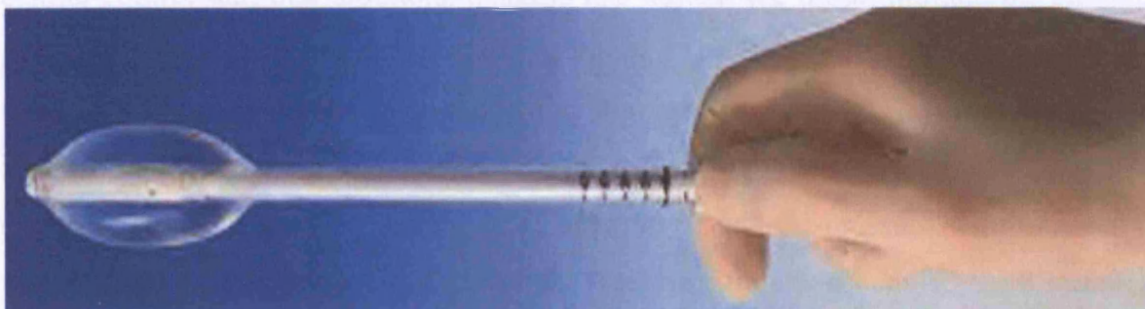


Figure 7 The Cavaterm balloon

The catheter is inserted till the fundus is reached and the balloon is inflated with glycine until a target pressure of 180 mm is reached. The pressure is maintained at 140-200 mm of Hg (20 mm above systolic blood pressure). The thermal unit is activated and balloon surface temperature rapidly reaches 75 C, which is maintained for a total treatment time of 15 minutes.

Published case studies have reported amenorrhoea rates of 22-68%, combined amenorrhoea and hypomenorrhoea rates of 56-82% and overall success rates of 92-98% (Hawe et al. 1143-48; Friberg et al. 330-35).

In a randomised controlled trial comparing the Cavaterm endometrial ablation system (n=37) and endometrial laser ablation (n=35) there was no significant difference in the amenorrhoea rates (29% vs. 39%) or combined amenorrhoea and hypomenorrhoea rates (73% vs. 69%) (Hawe et al. 350-57). There was a high patient satisfaction rate and improvement in QOL with both procedures.

The Cavaterm endometrial ablation system has been shown to be as effective and acceptable as laser ablation of the endometrium. However long term follow up will be required to assess long term outcome with this method.

#### Thermachoice endometrial thermal balloon therapy

This device consists of a plastic catheter of 16cm length and 5 mm width with a latex balloon that when inflated is designed to conform to the uterine cavity. The catheter is inserted into the uterine cavity and the balloon is inflated with a non electrolyte sterile aqueous liquid. An intraluminal pressure of 160-170 mm Hg is required for the balloon to be dilated by 10 mls. The distal end of the catheter contains a heating element and a temperature recording device (thermistor) which is connected to the central control unit that monitors, displays and adjusts the preset intrauterine balloon pressure, temperature and duration of treatment. The temperature is programmed to rise to 87 °C with a cut off when the temperature exceeds 92 °C. The pressure feature is set so that when the pressure is outside the range of 45-165 mm Hg the heating unit shuts down. When the temperature falls below 90 °C and the pressure stabilises in the preset range the heating coil switches on. Treatment time is scheduled for 8 minutes and starts when the temperature monitored is 85 °C. After treatment another 4-5 minutes is added for the system to cool down before the balloon is deflated and withdrawn. This treatment aims to cause a uniform coagulation of 3-5 mm of endometrium by the transfer of heat through the balloon.

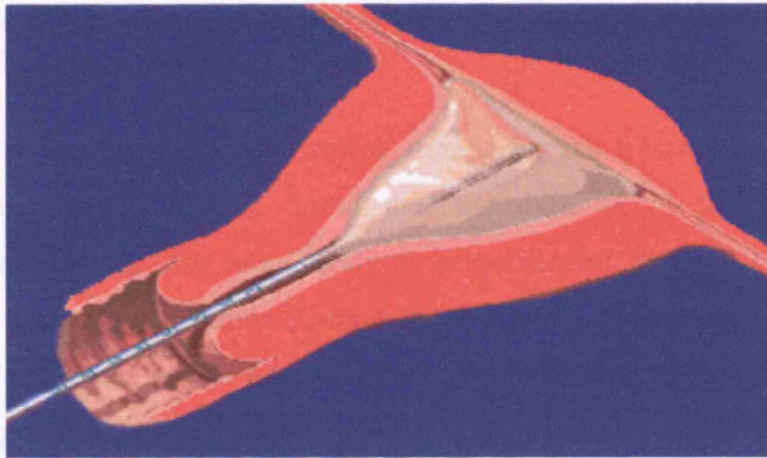


Figure 8 Figure showing the diagrammatic representation of the placing of the inflated Thermachoice balloon in the uterine cavity. The optical fibre is placed in the centre of the balloon

In a prospective observational study involving 296 women with DUB, Thermachoice balloon ablation was shown to have a success rate of 88-91% at 1 year. Pre treatment with GnRHa (5% of women in trial) increased the amenorrhea rates (Amso et al. 517-23).

In a long term multicentre follow up study of 188 women who replied to a questionnaire, (72% response rate) 47% had amenorrhoea, 30% had hypomenorrhoea and 86% of women had avoided a hysterectomy four to six years after the procedure (Amso et al. 1082-87).

#### 2.2.2.5 VestaBlate electrode balloon

The VestaBlate consists of a disposable single use multi electrode balloon. It contains six foil electrodes each of which has a thermistor on each side of the balloon connected to a controller. The balloon is placed in the uterine cavity through an 8 mm diameter inserter. When inflated by 10 mls of room air, the balloon distends to fit the uterine cavity and compresses the endometrium. The electrodes are then in contact with the endometrium and are connected through the controller to a standard electrosurgical generator. The thermistor is preset to a temperature between 65 °C and 75 °C. When one electrode is warmed up to that level the energy to that electrode is blocked and diverted to another electrode where the temperature is below the range. After an initial warm up period of 1-3 minutes the treatment phase starts and lasts for 4 minutes after which the system shuts off and the device may be removed. The aim



is to provide a uniform depth of desiccation by the uniform distribution of heat on the surface of the balloon.

In a multicentre randomised study (n=276) comparing the VestaBlate to endometrial resection and rollerball it was found that the duration of the procedure was significantly shorter and was more likely to be performed under a local anaesthetic than the first generation methods (Corson et al. 45-49). There were no significant differences in the amenorrhoea rate, complication rate, PBAC score after 12 months, additional surgery and success rates.

### 2.2.2.6 Interstitial lasers

The ELITT (endometrial laser interstitial thermotherapy) consists of a disposable handset containing three optical light diffusers (which can be manipulated individually on each side) and a compact tabletop diode laser (20W, 830 nm). The cross section of the folded handset is 6 mm requiring the cervix to be dilated to Hegar 7-8 for insertion. The portion of the handset that is inserted into the uterus is coated with Teflon, which does not adhere to the tissue while still transmitting light. The aim of the treatment is that the 830 nm laser light penetrates the endometrium and is absorbed by haemoglobin, warming the endometrium and causing coagulation.

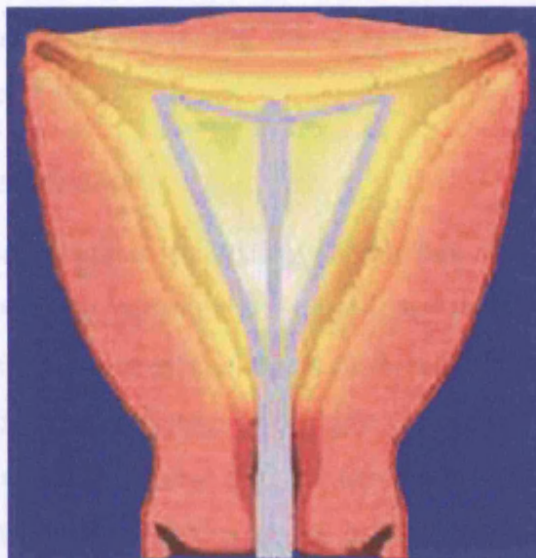


Figure 9 Diagrammatic representation of the activated ELITT device inside the uterus. This shows optimal placement of the device

The endocervical canal is dilated to Hegar 7 and the light diffuser handpiece is inserted into the uterus. The distal end of the handpiece is advanced and the side

diffusers are adjusted forming a butterfly wing contour that conforms to the uterine cavity. The laser is then activated for a 7 minute program (20W for the first 90 seconds; 18W during the next 90 seconds and 16 W during the final 240 seconds), which automatically shuts down allowing folding of the side diffusers and removal of the handpiece.

Donnez group pioneered this method and in a recent update it has now been performed on 100 women with DUB (Donnez et al. 791-96). At 12 months the rate of amenorrhoea was 71% and the combined rate of amenorrhoea and hypomenorrhoea (defined as less than 1 pad a day) was 91%. 87% of women said that they were most satisfied while another 12% were satisfied with the procedure. One woman was not satisfied, despite having a Higham score that was 88 % lower than her pre-treatment score. Sixty percent of the procedures were carried out under a general anaesthetic, 21% under paracervical block and epidural analgesia and 2% under conscious sedation only. There were no cases of perforation of the uterus or intraoperative complications reported. In a study by a British group the results were reproduced (n=40) with an amenorrhoea rate of 70% and a satisfaction rate of 88%. However the rate of hysterectomy in this series was 12.5%, four operations being the result of recurrent menorrhagia and one due to pelvic pain.

There is no randomised trial comparing this method to any of the first generation endometrial ablation techniques.

#### ***2.2.2.7 Hydrothermal ablation***

This consists of a double lumen insulating sheath that fits over the hysteroscope. Heated saline at 80-90 C is recirculated through the sheath distending the uterine cavity and causing destruction to all the layers of the endometrium and about 1-3 mm of the myometrium. The HTA system is designed as a closed circuit system, which will automatically shut down if more than 10 ml leakage is detected in the system. The intra uterine pressure achieved during the HTA procedure is 50 mm of Hg and this is achieved by the saline chamber being kept at a designed pole height above the procedure table. This is less than the opening pressure of the tubal ostia (70 mm of Hg) thereby minimising the passage of heated saline into the fallopian tubes.

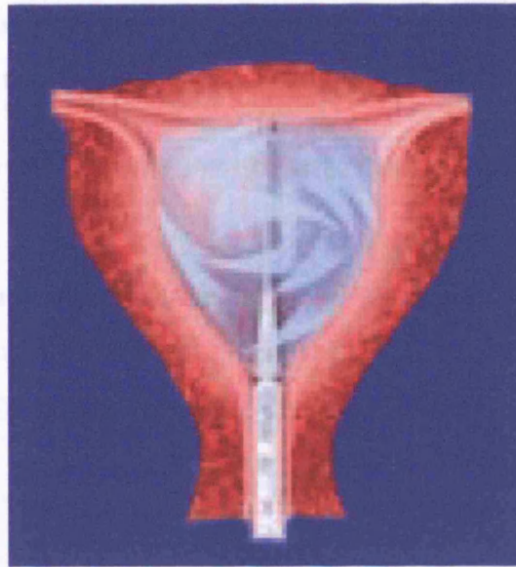


Figure 10 Diagrammatic representation of the double lumen sheath hysteroscope circulating heated saline in the uterine cavity.

The leakage of up to 10 ml of heated saline into the fallopian tube has been shown not to be harmful as the fallopian tubes are very vascular and act as a heat sink with temperatures at the cornual ends during HTA ablation been measured to be 42 °C and further rapid cooling occurs once the fluid enters the peritoneal cavity due to the large peritoneal surface area.

The cervix is dilated to 8.5 mm. This allows for a tight fit of the insulating sheath at the level of the cervix so that no leakage of fluid occurs. The ablation phase includes heating saline up to 90 C and then recirculating it for 10 minutes. This can be done under continuous visualisation. After the ablation phase is over the uterus is cooled with saline at room temperature before the instruments are removed from the uterus.

In 1995, Goldrath (Goldrath, Barrionuevo, and Husain 235-40) performed animal studies to show that instillation of hot saline into the endometrial cavity can cause ablation of the endometrium. This idea has been developed into the only second generation technique that is performed under hysteroscopic vision.

In a multicentre study 276 women with DUB were randomised into having HTA ablation or balloon ablation. There was no significant difference in the success of treatment, amenorrhoea rate, need for further surgery or operative adverse events. Women in the HTA group however were more likely to experience nausea, vomiting and abdominal pain after surgery. Women in the balloon ablation group were more

likely to have haematometra after the procedure. There were seven women in the HTA group who could not proceed with treatment because of equipment failure.

### **2.3 Alternative surgical treatment of uterine fibroids**

Surgical alternatives to hysterectomy for uterine fibroids are possible because uterine fibroids are benign tumours and the frequency of sarcomatous change is low (2-3 per thousand) (Parker, Fu, and Berek 414-18). Conservative surgery involves myomectomy or fibroid shrinkage either by embolisation, clipping of both uterine arteries and myolysis.

#### **2.3.1 Removal of fibroids**

##### **2.3.1.1 Myomectomy by laparotomy**

Myomectomy by laparotomy was described as far back as 1840 when Amussat removed a tumour thought to be an ovary because it had a pedicle (O'Dowd, Michael J, and Phillip Elliot 411). In a recent technology assessment and evidence report on the management of uterine fibroids (File Inventory and AHRQ Publication No.01-E052) where selected published series were analysed, there was an 80 –100 % relief of menorrhagia and a 50 –90% relief of pressure and pain symptoms after myomectomy. Fifty per cent of women with fibroids and otherwise unexplained infertility conceived after a myomectomy and the risk of uterine rupture in a subsequent pregnancy was low (0.002%) compared with that after a previous caesarean section (0.1%). Intraoperative blood transfusion rates of up to 18% and an increased febrile morbidity compared to hysterectomy were reported. Clinically significant recurrence rates were quoted as 10% at 5 years with post operative adhesions (often involving bowel) being long term complications.

There were significant difficulties encountered in the synthesis of the data. There were variations in patient selection, inadequate reporting correlating the number and location of the fibroids to the presenting symptoms and outcome, differences in practice in terms of measures taken to reduce intra operative blood loss, surgical techniques, indications for blood transfusion and the methods used to measure symptom improvement. The effect of myomectomy on infertility was also compounded by not accounting for the effect of assisted reproductive techniques after surgery. Furthermore, groups which performed large numbers of myomectomies have

reported no increase in short term complications like blood transfusion rates and febrile morbidity when compared to hysterectomy. This may reflect an evaluation of the practice of the particular group rather than the procedure itself in general use.

### 2.3.1.2 Laparoscopic Myomectomy

Laparoscopic myomectomy (LM) was first performed in 1977 (Semm and Mettler 121-27). Since this report it has been developed for subserous and intramural fibroids because of the possibilities of reduced postoperative pain, shorter hospitalisation, and earlier return to normal activity and reduced adhesions. Initially the procedure was associated with prolonged operating times, significant blood loss and a high risk of conversion to a laparotomy. Two specific issues were tissue retrieval from the peritoneal cavity and the repair of the uterine wall defect especially after the removal of a deep intramural fibroid. Case reports of spontaneous rupture of the uterus at 33 – 36 weeks of a subsequent pregnancy have been reported between 1992 and 1997 making the technique questionable in women desiring future pregnancies. (Dubuisson et al. 1475-77; Harris 545-46)

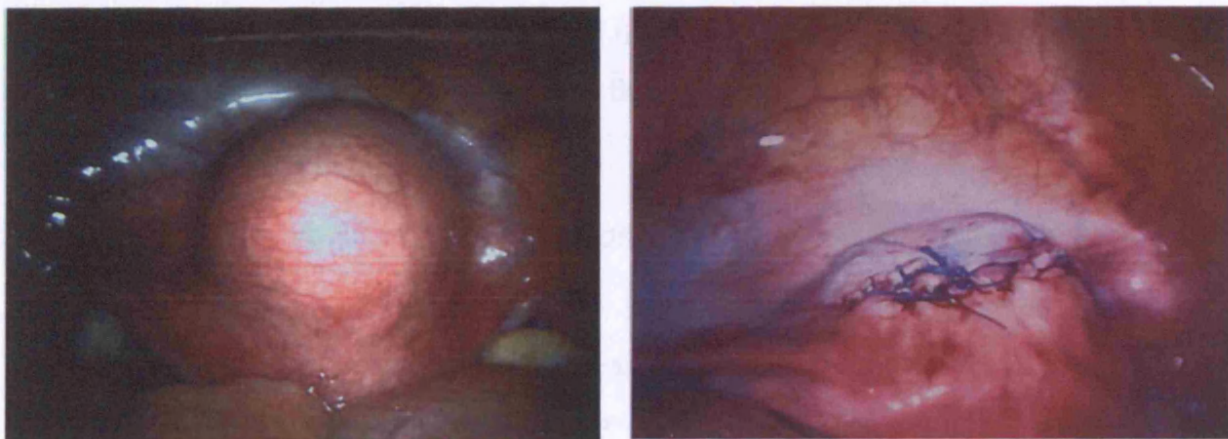


Figure 11 Figures showing a uterus with an 8 cm intramural fibroid with subserosal extension before and after laparoscopic myomectomy

With improving patient selection, laparoscopic skills in suturing, the adoption of microsurgical techniques and the development of more efficient electric morcellators considerable advances have been made in the efficacy of the procedure. Recent studies have shown comparable operating times and pregnancy rates to open myomectomy with reduced febrile morbidity, haemoglobin drop postoperatively,

transfusion rates and hospital stay. There is also a suggestion of reduced postoperative adhesions including periadnexal adhesions but the evidence is not conclusive. Rates for conversion to laparotomy range from 0 – 2.9% but this is not taking into account mini laparotomy to complete uterine closure.

There is still considerable debate as to whether the integrity of endoscopic sutures is equivalent to that at laparotomy. It is difficult to calculate an incidence of uterine rupture from isolated case reports as the total number of pregnancies following LM is not known. Recurrence of fibroids after LM is significantly higher and occurs earlier than after open myomectomy. The cumulative risk is 50% at 5 years (Tavmergan E, Tavmergan EN, and Turker S 68;Stringer, Walker, and Meyer 457-64). This is due to the lack of tactile sensation at laparoscopy resulting in an inability to detect small fibroids at the time of surgery. Meticulous preoperative investigation and careful patient selection reduces this risk.

LM is therefore recommended in women with a maximum of 3 fibroids, the largest not being greater than 8 cms in size and the overall uterine size being not greater than 16 weeks gestation. It should be performed by surgeons with sufficient skill especially in laparoscopic suturing to allow for proper closure of the uterine defect after deep intramural fibroids are removed thereby minimising the risks of uterine rupture in a subsequent pregnancy.

### ***2.3.1.3 Laparoscopic Assisted Myomectomy (LAM)***

LAM was first reported in 1994 (Nezhat et al. 39-44). The procedure involved the use of a 5 cm suprapubic minilaparotomy, which aided in morcellation and removal of the fibroid and repair of the uterus in layers. Convalescence and symptom relief is similar to that of LM. The technique was proposed to reduce operating time and improve uterine closure thereby reducing the risk of uterine dehiscence in a subsequent pregnancy. Recommended indications are fibroids which are deep intramural in type, are greater than 5 cms in diameter and require uterine closure in layers with the indication being primarily for infertility. However a recent case report on uterine rupture after LAM (Friedmann et al. 683-84) does not help in the creation of clear guidelines on the indications of this procedure in women undergoing LM.

#### 2.3.1.4 Vaginal Myomectomy

The first report of a vaginal approach to myomectomy was in 1988 and was used for the removal of prolapsed submucosal fibroids. (Ben Baruch et al. 858-61) Subsequently an anterior hysterotomy was described for the removal of large submucous fibroids. More recently vaginal myomectomy has been described as an alternative approach to myomectomy by laparotomy (Davies, Hart, and Magos 961-64). In this procedure, an anterior or posterior colpotomy is made depending on the position of the bulk of the fibroids. The uterus is manipulated till the fibroid is presented to the colpotomy and a vertical incision is made over the fibroid and the fibroid removed intact or piece meal by morcellation. As many fibroids as possible are removed in this manner and when the uterus is sufficiently debulked it is delivered into the colpotomy enabling closure of the uterine defect as at laparotomy.

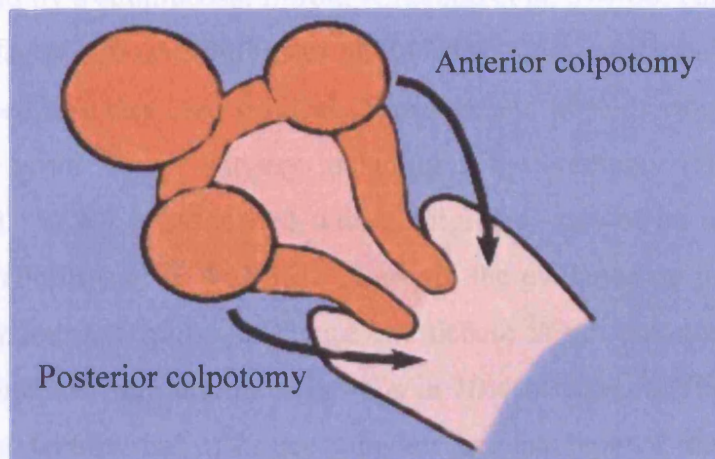


Figure 12 Diagrammatic representation of the technique described in removing anterior and posterior wall fibroids through a vaginal route

Removal of the fibroid has been found to be associated with minimal blood loss and this has been thought to be due to the tourniquet effect on uterine blood supply that is achieved by anteflexing or retroflexing the uterus to deliver it to the colpotomy. Other advantages quoted are the low morbidity associated with the avoidance of an abdominal incision. Advantages over LM are that vaginal myomectomy can be used for women with more than 3 fibroids, the operating time is far less, closure of the uterine defect is similar to that at laparotomy and the recurrence risk of fibroids should be less due to presence of tactile sensation.

However vaginal myomectomy is not suitable for all fibroids especially when situated in the fundal and lateral walls of the uterus. The risk of conversion to laparotomy is about 9 % and it is associated with an 11.4% risk of vault haematoma. To date there are no studies on long term complications. This procedure requires a high degree of specialised skill in vaginal surgery and therefore precludes it from widespread use.

### *2.3.1.5 Hysteroscopic resection of a fibroid*

Transcervical hysteroscopic resection of submucous fibroid (TCRF) was first described for the treatment of submucous fibroids in 1976 (Neuwirth and Amin 95-99). Submucous fibroids are classified into three types. Type 0 is when the fibroid is entirely submucous, Type I is when < 50% is intramural and Type II is when > 50% is intramural. TCRF has been shown to be effective in reducing menstrual blood loss (63-90%) caused by a submucosal fibroid (Cravello et al. 374-80; Hallez 703-08; Hart, Molnar, and Magos 700-05; Phillips et al. 147-53). It is particularly attractive as it can be performed as a day case surgical procedure and 80% of women who undergo this procedure avoid further surgery including a hysterectomy (Hart, Molnar, and Magos 700-05). TCRF is associated with a pregnancy rate of up to 73% in women with infertility (Phillips et al. 147-53). However the evidence on infertility does not include any randomised trials and hence the debate is not conclusive. Long term complications include intra uterine adhesions in 10% of women (Hallez 703-08) The most significant factors that influence outcome are the type of the fibroid (Type 0 giving the best results) and the overall size of the uterus (less than a six week gestation size). Factors such as the age of the woman and the number and size of the individual fibroids are only secondary to these in affecting outcome. TCRF is however associated with short term complications which include haemorrhage requiring transfusions (1-4%), (Derman, Rehnstrom, and Neuwirth 591-94) uterine perforation (1-4%), (Cravello et al. 374-80; Emanuel et al. 743-48; Hallez 703-08) emergency hysterectomy (up to 1%) and pulmonary oedema (0.3%) (Emanuel et al. 743-48) from dilutional hyponatraemia. Long term complications include an Ashermanns syndrome of up to 10%, (Hallez 703-08) and a 11% uterine rupture rate in a subsequent pregnancy (Hart, Molnar, and Magos 700-05).



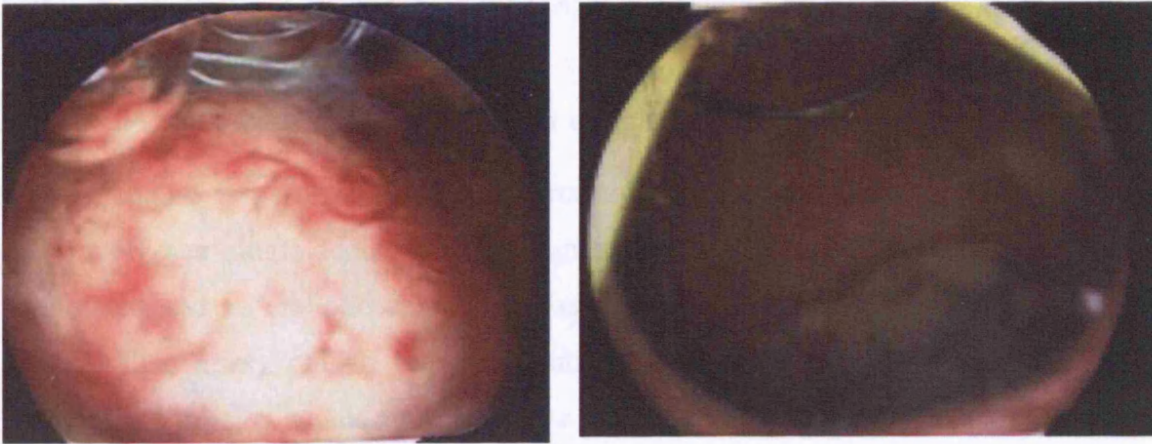


Figure 13 showing a uterus with a Type 0 large submucous fibroid almost filling the uterine cavity before and after removal with transcervical resection. The best results are obtained with Type 0 fibroids

Developments with instrumentation have enabled the use of miniature bipolar resectoscopes, which can be passed into the uterus without dilating the cervix. It can be used in the outpatient setting and employs physiological saline as a distending medium thereby reducing the risks of electrolyte disturbances with fluid overload. Because of the high energy intensity a vaporising effect is produced at the electrode tip and therefore there are no resection chips produced making the procedure easier and hence promises to be of more widespread use. After initial concerns with reports of non fatal air embolism for which the product was taken out of the market it has been reinstated without any modifications as investigators found that the complication was associated with any electro surgical procedure and not with the instrument itself. Results using this system seem to be comparable to the conventional operative hysteroscopes with an improvement in bleeding being reported by 78% of women at 6 months and a patient satisfaction rate of 92% (Clark et al. 237-42).

### 2.3.2 Reduction in the size of fibroids

#### 2.3.2.1 Uterine artery embolisation (UAE)

In 1995, Ravina's group performed prophylactic UAE on women prior to myomectomy and hysterectomy with the aim of reducing complications of intraoperative bleeding, blood transfusion and the conversion of a myomectomy to a hysterectomy (Ravina et al. 671-72). Surprisingly 14 out of 16 women in this series

had resolution of symptoms with a 20-60% reduction in uterine volume at 20 months and therefore did not require surgery. Since Ravina's work, other groups have evaluated UAE as a primary treatment for uterine fibroids.

The procedure is performed under fluoroscopic guidance under conscious sedation and involves a single femoral artery puncture through which the uterine artery is cannulated and an embolic agent introduced. The catheter is withdrawn across the internal iliac artery guided into the contralateral uterine artery and the procedure repeated. Embolic agents reported have been polyvinyl alcohol beads ranging in diameter size from 355-500 to 500-700 micrometers. Other agents used are gelatin sponge and trisacryl plastic spheres of 500-900 micrometer diameter.

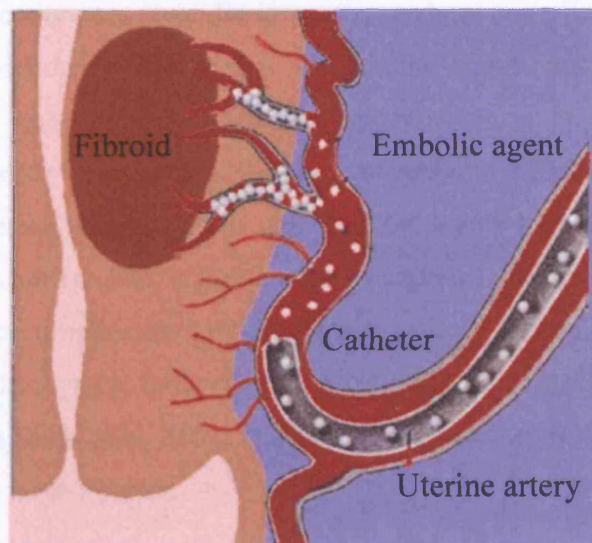


Figure 14 Diagrammatic representation of uterine artery embolisation. The catheter is in the uterine artery and polyvinyl particles have been injected to cause obstruction to the distal branches of the uterine artery

The use of platinum coils in addition to PVA particles to prolong the duration of fibroid ischaemia has also been used. The procedure takes between 35 – 135 minutes to perform and in most series the women are admitted overnight for analgesia though the procedure can be done on a day case basis. Women receive a radiation dose of approximately 20cGy which is about ten times that of a CT of the pelvis or equivalent to a Barium enema examination. Revascularisation of the myometrium and endometrium occurs by an effective collateral circulation developing which does not seem to extend to the fibroids. Fibroid necrosis and regression in size are therefore maintained.

In the hands of an experienced interventional radiologist, UAE is technically feasible in 96-100% of cases (Ravina et al. 272-75; Walker and Pelage 1262-72). Its efficacy is similar to that of the use of GnRH analogues. Fibroid volume shrinkage of 30-50% at 6 months in 85% of treated women have been reported (Goodwin et al. 1159-65; Spies et al. 1149-57; Brunereau et al. 1267-72). It is associated with a smaller reduction in the uterine volume of 29-48% (Spies et al. 1149-57; Walker and Pelage 1262-72). The shrinkage is however maintained at 6 months post treatment. UAE is associated with improvements in menstrual blood loss (80-96%), (Ravina et al. 233-43; Bradley et al. 235-40; Worthington-Kirsch, Popky, and Hutchins, Jr. 625-29; Hutchins, Jr., Worthington-Kirsch, and Berkowitz 279-84) pressure effects (84%), and dysmenorrhoea (77%) (Walker and Pelage 1262-72). Complications while performing the procedure are rare. Early post procedural complications include pain, post embolisation syndrome and sepsis. Pain is the commonest problem requiring narcotic analgesia, non-steroidal anti-inflammatory agents, anti emetics and patient controlled intravenous analgesia requiring admission. Unfortunately there is difficulty in predicting which women will develop severe pain with there being no relationship to the initial size, number and location of the fibroids. Attempts at reducing ischaemic complications by performing a more selective embolisation has been recently reported with reduced post procedural pain and a return to normal activity in 2.3 days, (Zupi et al. 107-11), This technique however is applicable only to women with single large fibroids.

Late complications include vaginal fibroid expulsion. This occurs in 10% and is often associated with a persistent vaginal discharge (Goodwin et al. 1159-65; Spies et al. 1149-57; Bradley et al. 235-40; Berkowitz, Hutchins, Jr., and Worthington-Kirsch 373-76). Amenorrhea with or without ovarian compromise can occur. This has been reported in 3% in women less than 40 years of age and 47% in women over the age of 45 (Goodwin et al. 1159-65; Spies et al. 1149-57; Bradley et al. 235-40). Transcervical resection of the fibroid for the incomplete vaginal expulsion of a fibroid or a hysterectomy for uterine sepsis may be required. Laparotomy and bowel resection for sepsis from a subserous fibroid is an occasional complication. There have been 3 reported cases of mortality from UAE, 2 from sepsis and 1 from a pulmonary embolism (Vashisht et al. 307-08; Lancoita R et al.; McLucas et al. 1730).

All series report pregnancies following the procedure but there are no detailed reports of outcome.

From the evidence available it does appear that UAE is a useful modality of treatment for women with symptomatic uterine fibroids. Further investigation is required to the applicability of the procedure to women desiring fertility, adapting methodology to reduce the dose of radiation, determining the ideal embolic agent, assessing whether the treatment can be repeated and more long term follow up data of the procedure. The Royal College of Radiologists and the Royal College of Obstetricians and Gynaecologists had a joint working party that issued clinical recommendations on the use of UAE in the management of uterine fibroids in November 2000. This recommends that all cases of UAE must be part of a primary research programme and be registered with the Safety and Efficacy Register for New Interventional Procedures (SERNIP), Class C procedure and that all cases be subject to prospective audit. It is not recommended in women wanting fertility (RCOG/RCR Report).

#### *2.3.2.2 Laparoscopic bipolar coagulation of the uterine blood vessels*

This procedure has recently been reported as an alternative to bilateral uterine artery embolisation (UAE). The uterine artery is isolated from the ureter and the internal iliac artery and desiccated using bipolar electrosurgery. Bipolar coagulation of the anastomotic sites of the uterine and ovarian arteries, after isolation of the ovary to prevent thermal damage, is also performed.

Liu et al (Liu et al. 417-22), reported this procedure and found that it was feasible in 98% of women with no intra operative complications. Postoperative pain occurring immediately postoperatively and lasting for 2 weeks was seen in 28% of women with one woman having an infection, which resolved with antibiotics for 7 days. Symptom relief was obtained for menorrhagia in 93% of women and pelvic pressure in 87%. Three women (3%) aged 46, 48 and 53 years became menopausal following surgery. Mean fibroid volume reduction was 76% (range = 38 – 100%).

This report is encouraging as the benefits are equivalent to that obtained at UAE and postoperative sepsis seems to be markedly reduced. However the study is a preliminary one and a high degree of laparoscopic skill is required to isolate the uterine artery without causing ureteric or vascular injury.

### **2.3.2.3 Laparoscopic Myolysis**

Myolysis consists of causing coagulation necrosis in the substance of the fibroid resulting in denaturation of collagen and vascular damage thereby causing shrinkage of the fibroid and reducing the chances of regrowth. Sources of energy that have been employed have been lasers, electrosurgery and cryotherapy.

The initial report (Nisolle, Smets M, and Gillerot S et al 95-99), laparoscopic myolysis used a laser at a power of 80 watts. The laser fibre was introduced in to the centre of the fibroid, activated and then withdrawn to the serosal surface. This was repeated at distances of 5-7 mm. In the 48 women who underwent the procedure there were no intraoperative complications or conversions to laparotomy with all patients being discharged home after an overnight stay in hospital. There was no significant postoperative pain or sepsis. A 41% mean decrease in fibroid diameter was seen after 6 months that persisted to one year. The main disadvantage however of this procedure was the operating time and a 10-50% incidence of postoperative adhesions to the serosal scars many of them being dense and involving bowel. Electro surgical bipolar needles have also been developed for myolysis with similar results (Goldfarb 636-38). This has the advantage of reducing the procedure time however 2 out of the 150 women (1.5%) developed postoperative sepsis.

### **2.3.2.4 Cryomyolysis**

Cryomyolysis consists of inserting a cryoprobe into the substance of the fibroid and freezing it to  $-180^{\circ}\text{C}$  creating an ice ball in the substance of the fibroid. Several freeze/thaw cycles were repeated. Results were disappointing with reduction in fibroid volume being only 6% but it has been shown to maintain the reduction of size achieved by pituitary downregulation in 14 women who underwent the procedure (Zreik et al. 33-38). Postoperative adhesions were a significant long-term complication.

## **2.4 Summary and conclusions**

### **2.4.1 Uterine conserving surgery for DUB**

The results of the first generation endometrial ablative techniques suggest that 80% of women would avoid a hysterectomy for DUB. It is associated with a reduced post operative morbidity (overall complication rate of 0.6%) with an earlier return to

normal activity. Ovarian function was not affected at 2 years when compared to hysterectomy. Patient satisfaction rates were only slightly less than that with hysterectomy. Hysteroscopic surgery is also proved to be more cost effective.

The efficacy of the three techniques is similar. Significant differences are illustrated in Table 3. The drawbacks of the first generation techniques are that a considerable skill is required on the part of the operator. There is a slow learning curve for proficiency in the procedure and the complications include perforation, visceral damage, fluid overload and haemorrhage. Furthermore a general anaesthetic is required in most cases

Procedure	Equipment	Advantages	Disadvantages
ELA	Complex	View not obscured	No histology, Cost
TCRE	Standard	Histology available	Higher risk of perforation
RBAE	Standard	View not obscured	No histology

Table 3 Table comparing the first generation endometrial ablative techniques. Specific differences between the techniques have been illustrated. ELA=Endometrial laser ablation, TCRE = transcervical resection of the endometrium and RBAE= roller ball ablation of the endometrium

The second generation endometrial ablative techniques have been developed to address these issues. They are non hysteroscopic techniques (other than for HTA) requiring minimal operator skill with a steep learning curve. These techniques were thought to eliminate the risks associated with hysteroscopic surgery and could be performed more commonly under a local anaesthetic.

They do not require any special skills or a distension medium. Due to financial considerations owing to the scope of the problem, industry has invested in a number of techniques of second generation endometrial ablation. These have been described in section 2.2.2. The main differences between these techniques and the evidence quoted in the section have been summarised in Table 4.

Device	Reduction in MBL	Anaesthetic used	Complications	Quality of studies
Cryotherapy	92%	50% GA	None reported	Observational
Radiofrequency	84%	Mostly GA	Vaginal fistula	Observational
Microwave	83%	Mostly GA	Uterine perforation	RCT vs TCRE
Interstitial laser	91%	Mostly GA	None reported	Observational
Fluid balloon	73 -88%	70-75% GA	Cramping pain; Haematometron	RCT vs ELA
Electrode balloon	84%	10% GA	Haematometron	RCT vs TCRE
Hydrothermal	75%	55% GA	Nausea vomiting abdominal pain	RCT vs roller ball ablation

Table 4 Table comparing the efficacy, ease of use, complications, cost and quality of evidence available for the second generation endometrial techniques described in section 2.2.2.

Most of the evidence for the efficacy of second generation ablative techniques comes from small case studies and a single randomised controlled trial comparing them to another first generation method. Overall it does appear that the efficacy of these methods are only slightly less than that of the first generation methods. However they are not free from complications and most procedures are still being performed under a general anaesthetic. A significant factor is the incidence of equipment failure reported.

#### 2.4.2 Uterine conserving surgery for uterine fibroids

The different routes that have been employed for removing fibroids have been described in section 2.3.1 These have been developed in an attempt to reduce hospital stay and enable an earlier return to normal activity. The clinical situation in which these techniques are best used have been summarised in Table 5. With increasing skill in laparoscopic suturing methods this technique is increasingly being employed in women requiring fertility.

Route of myomectomy	Suitable type of fibroid	Suitable location of fibroid	Unsuitable type/location of fibroid	Suitable for women requiring fertility	Advantages	Uses
Laparotomy	All types	All locations	Type 0 SM fibroid	Yes	Technically feasible in almost all cases	Large fibroids , difficult access to fibroid
Laparoscopy	SS and IM fibroids	Fundal and upper posterior wall	Very large fibroids and difficult access	Anterior and fundal	Earlier return to normal activity	Ideally women not requiring fertility
Laparoscopic assisted	SS and IM fibroids	Fundal and upper posterior wall	Very large fibroids and difficult access	Anterior and fundal	Earlier return to normal activity	Ideally women not requiring fertility
Vaginal	Small SS fibroids	Anterior and posterior wall	Fundal and large fibroids	Yes	Earlier return to normal activity	Limited to specialist centres only
Hysteroscopic	Type 0 and some Type 1	Any location	Cervical fibroids	Yes	Day care surgery	First line treatment for SM Type 0

Table 5 Table comparing the efficacy, ease of use, complications, cost and quality of evidence available for the different routes used for fibroid removal as described in section 2.3.1.

Myomectomy (by whatever route) is seen to be associated with a high degree of recurrence and post operative adhesions. The perioperative complications of haemorrhage and pyrexia are now much less with improvements in surgical techniques and pre operative pituitary down regulation.

Comparison of the treatments used to reduce the size of fibroids have been summarised in Table 6. UAE is a promising technique but is associated with significant morbidity. It requires a multidisciplinary team comprising both interventional radiologists and gynaecologists as most of the complications would require treatment by gynaecologists. Laparoscopic myolysis (using high power lasers) has largely been abandoned due to the high incidence of post operative bowel adhesions. Cryomyolysis requires further investigation. In conclusion, the gold



standard second generation technique for the treatment of DUB has not yet been found.

Device	Fibroid Shrinkage	Effect on Symptoms	Complications	Uses	Quality of studies
UAE	30-50% at 5 years	Reduction in MBL (80-96%) pressure effects (84%), dysmenorrhoea (77%)	Pain, post embolisation syndrome, sepsis, fibroid expulsion, early menopause, bowel perforation, hysterectomy, mortality	Specialist interventional radiology centres , not in infertility	Case reports
Laparoscopic UA clipping	76%	Reduction in MBL (93%) pelvic pressure (87%)	Pain, sepsis, early menopause	Highly specialist surgery	Case reports
Laparoscopic Myolysis	41%	Not known	Post operative adhesions , sepsis	Relatively easy to perform	Case reports
Cryomyolysis	6%	Not known	Dense post op adhesions, sepsis	Specialist centres	Case reports

Table 6 Table comparing the efficacy, ease of use, complications, cost and quality of evidence available for the uterine conserving surgical treatments for uterine fibroids as described in section 2.3.2.

In conclusion, there is still a need for a second generation endometrial ablative technique that does not require complex equipment, can be used in an outpatient setting with minimal anaesthetic while still having a steep learning curve. Uterine conserving surgery for uterine fibroids is far from ideal. There is a need for the development of a treatment which can be applied to general clinical use without the complications that are associated with the current methods.

# [3] Low power laser treatments for heavy periods

The two conservative surgical techniques that utilise lasers for the treatment of DUB and uterine fibroids are the ELLITT procedure and laser myolysis as described in Chapter 2. These treatments however utilise lasers at high power settings. Both procedures rely on a thermal effect for treatment. The aim of this chapter is to review our understanding of tissue effects of lasers and how low power lasers may be exploited for photodynamic therapy of the endometrium and interstitial laser photocoagulation of uterine fibroids. The lack of success of PDT of the endometrium in current clinical practice and the lack of data for ILP of uterine fibroids will also be presented and discussed.

## **3.1 LASER –Tissue interaction**

A LASER (Light Amplification by the Stimulated Emission of Radiation) is a device that produces a coherent monochromatic and highly collimated beam of light. This beam can be transmitted by thin flexible optical fibres, which can be delivered into body cavities with the aid of endoscopes or through needles to produce a precise controlled effect at a desired target area. The tissue effect of lasers depends on the properties of the incident laser beam, (wavelength, power, exposure time and beam

dimensions), the optical properties of the target tissue (reflection, transmission, scattering and absorption) and the biological response of the target tissue to the energy absorbed.

### 3.1.1 Effect of wave length of the laser beam on tissue effects

Tissue penetration depends on the wavelength of the laser beam used. Ultraviolet light (193-400nm) is very strongly absorbed by the pigment in tissue and by water (wavelength less than 300nm). Visible light (400-700nm) becomes more weakly absorbed as its colour changes from blue to red. Tissue becomes relatively transparent in the infrared range (700-1000nm) with absorption increasing again as the wavelength increases above 1300 nm as absorption in water increases.

### 3.1.2 Effect of the optical properties of the target tissue on the tissue effect

When laser light strikes a living tissue surface, it can be reflected, transmitted, scattered or absorbed depending on the optical properties of the target tissue. It is only the absorbed light energy that produces the biological effect, but reflection, transmission and scattering determine where the light goes and as a result the volume of the tissue which finally absorbs the light. In addition the thermal property of the target tissue will affect the final biological effect and this includes the water content, concentration of chromophores (haemoglobin, oxyhaemoglobin and melanin,) and the blood supply to the tissue.

### 3.1.3 Terminology with light delivery

The fluence rate is the amount of photons per second that passes through a particular area ( $\text{mW}\cdot\text{cm}^{-2}$ ). The optical dose is a product of the incident fluence rate and the exposure time. The effective penetration depth of light is the distance (in mm) corresponding to a decrease in the fluence rate by a constant factor ( $1/e$ ). The average light penetration depth is about 1-3mm at 630nm and 2-6mm at 700-850nm of light.

### 3.1.4 Biological response of the target tissue to the energy density of the incident laser beam

#### 3.1.4.1 *Non-linear effects*

##### 3.1.4.1.1 Photodisruption

This principle is used in the laser fragmentation of renal calculi which is usually done with flash pumped dye lasers. This is possible with Q switched Nd:YAG pulses. Effective fragmentation is possible with microsecond pulses which work under water. In addition to the shock wave created by the short laser pulse, boiling of a tiny drop of water at the tip of the fibre where it makes contact with the stone creates a mini explosion leading to the disruption of the calculus.

##### 3.1.4.1.2 Photoablation

Photoablation occurs when using light of very short wave length (ultraviolet) because the photon energy may be great enough to directly disrupt bonds within tissue. The excimer laser is said to exert its effect by means of photoablation and is used in ophthalmology for reshaping the cornea to correct refraction errors.

#### 3.1.4.2 *Linear - thermal effects*

##### 3.1.4.2.1 Tissue Hyperthermia

At a low energy density, lasers can cause an increase in tissue temperature to 41-45 °C. This tissue warming causes localised oedema and inflammation only which is reversible. If this relatively small temperature rise is maintained for a long time (e.g. 1 hour @ 44°C, 30 minutes at 45°C and 15 minutes at 46°C) cell death occurs over the remaining cell cycle over several days. This principle is utilised for the treatment of superficial cancers.

##### 3.1.4.2.2 Tissue coagulation

When the increase in the tissue temperature is between 45 – 99 °C, there is irreversible denaturation of proteins and coagulation occurs. This is dependent on the length of time that a particular temperature is maintained. Tissue necrosis occurs and healing is by scarring or regeneration depending on the tissue being treated.

Typical power (Watts)

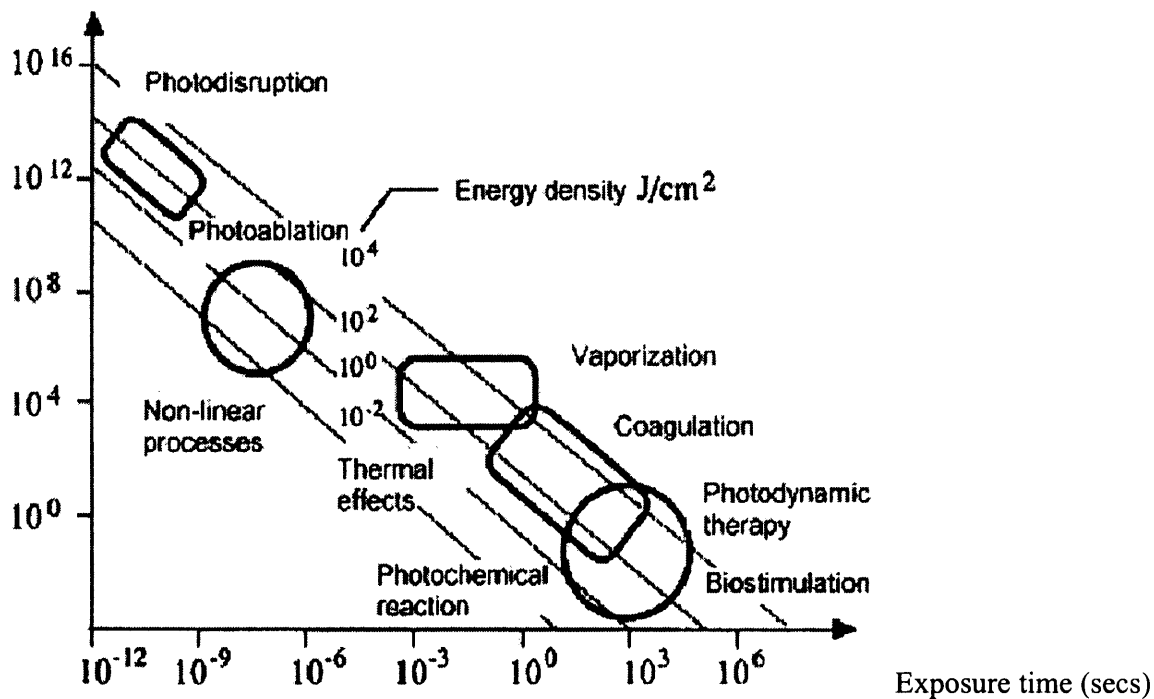


Figure 15 Biological response of the target tissue to the energy density absorbed

### 3.1.4.2.3 Tissue vaporisation

At temperatures that are greater than  $100\text{ }^\circ\text{C}$  tissue water boils. The conversion of water to steam causes a one thousand fold rapid rise in the cellular volume, which causes the cell wall to burst releasing steam and cellular debris. Once the water around the laser tip has vaporised the temperatures rapidly increase to  $300\text{-}400\text{ }^\circ\text{C}$ . Tissue blackens due to carbonisation and there is smoke production. With vaporisation there is total tissue destruction with underlying necrosis and later sloughing. If the energy applied is continued then the laser will bore a hole in the tissue.

### 3.1.4.3 Linear – non thermal (photochemical)

These tissue interactions produce biological effects at power and energy levels that do not cause significant tissue heating. The most promising technique employs tissue sensitising agents and forms the basis of photodynamic therapy.

### 3.1.5 Biomodulation

It has been shown that small doses of ruby laser radiation (e.g.  $1 \text{ J / cm}^2$ ) can stimulate cell division that can accelerate wound healing. However the effect is sensitive to the total energy and after 10 such doses of energy, inhibition occurs, with suppression of cell growth. This principle has been used with some beneficial effect in the healing of long standing ulcers but has not found widespread acceptance in clinical practice.

## 3.2 *Lasers in clinical use*

### 3.2.1 Conventional lasers

The common lasers that are used in clinical practice are shown in Table 7 and Table 8. The wavelengths at which soft tissue absorb light energy vary enormously. The  $\text{CO}_2$  laser which has a wavelength in the far infra red range is absorbed mainly by cellular water. The Nd: YAG laser (wavelength in the near infra red range) and the Argon ion laser (wavelength in the blue-green range) is absorbed mainly by pigments such as haemoglobin, oxyhaemoglobin and melanin.

#### 3.2.1.1 *Type of laser vs. depth of damage*

The depth of tissue damage varies with the laser used. For example at a power of 40-50 watts for a few seconds the  $\text{CO}_2$  laser produces tissue damage to a depth of 0.1mm, the Argon ion laser produces damage to 1mm whereas the Nd: YAG laser produces damage to a depth of 5 mm.

#### 3.2.1.2 *Volume of tissue treated*

The volume of tissue treated depends on the dissipation of energy. With the  $\text{CO}_2$  laser, the volume of tissue heated outside the vaporised tissue is minimal and hence it may only cause coagulation of capillary oozing. The Nd: YAG laser (at 50-80 W) causes a thermal effect of a greater volume of tissue and can seal vessels up to 1mm in diameter in suitably supporting tissue by thermal contraction of the surrounding tissue.

### 3.2.2 Semiconductor Diode lasers

The conventional lasers described have many disadvantages that have resulted in them not being widely used in clinical practice. An important consideration is the cost. In

addition to being expensive they are cumbersome to move and sensitive to misalignment with the minimum of trauma.

Laser	Wavelength (nm)	Power (W)	Fibre transmission
CO <sub>2</sub>	10,600	5-50	No
Nd:YAG	1,064	5-100	Yes
Argon	488; 514	1-10	Yes
Dye	Tunable (visible region)	0.05-5	Yes
Semiconductor Diode laser	Selected wavelengths (mainly in the red and near infra red region)	1-25	Yes

Table 7 Continuous wave (CW) lasers in clinical use

Laser	Wavelength (nm)	Pulse duration	Pulse energy (Joules)	Fibre transmission
Nd:YAG Q switched	1,064	nanoseconds	0.1-1	Yes
Nd:YAG	1,064	microseconds	0.1-1	Yes
Dye	Tunable visible region	nanoseconds	0.01-0.1	Yes
Excimer	Ultraviolet	nanoseconds	0.01-0.1	No

Table 8 Pulsed lasers in clinical use

The diode lasers rely on the activation of n-p junctions in semiconductor materials to produce a laser effect. They may be tuned over a very short range by altering the temperature of the semiconductor used. The early diode lasers emitted in the infra red part of the spectrum (e.g. GaAlAs -805 nm) but they are now being adapted to emit in the visible red regions of the spectra as well. They are much cheaper, portable, and are highly robust and may be plugged into a standard plug socket. They are more reliable than conventional lasers and as the cost reduces with the increase in demand, they may be more readily used in clinical practice in all hospitals and not be confined to specialist centres.

### 3.2.2.1 Low power laser therapy

Conventionally, most clinical applications of laser therapy utilise a thermal effect requiring a power of 50 –100 watts which causes damage to surrounding tissue in addition to the tissue being treated. The optimal aim however of laser therapy is to harness the properties of lasers to match the tissue damage produced with the disease being treated. This minimises alteration to the structure and function of the tissue.

Consequently there is a growing interest in using low power thermal treatments like interstitial laser photocoagulation and non thermal treatments like photodynamic therapy. There is the potential to treat the disease with minimal disruption to the structural and functional integrity of the organ being treated. Characteristics of these two modalities of treatment are summarised in the table shown below.

	Interstitial laser photocoagulation	Photodynamic therapy
Laser wavelength	Near infrared (805-1064nm)	Red (630-730nm)
Laser type	Nd;YAG, Diode	Dye, Diode
Nature of biological damage	Thermal	Photochemical
Effect on collagen and elastin	Destroyed	Largely unaffected
Inherent selectivity of necrosis between tumour and surrounding healthy tissue	None	Minimal (some selectivity between different layers of normal tissue)
Healing	Resorption and scarring	Regeneration, sometimes with scarring
Cumulative toxicity	None	None

Table 9 Characteristics of interstitial laser photocoagulation and photodynamic therapy

### 3.3 Photodynamic therapy (PDT)

This is a low power laser treatment that is not associated with a rise in tissue temperature. PDT treated connective tissues like elastin and collagen are largely unaffected. There is therefore much less risk of altering the mechanical integrity of a hollow organ. Healing takes place more by regeneration than scarring. These properties are in contrast to thermal damage and are therefore particularly appealing. Like ILP there is no cumulative toxicity and the treatment may be repeated.



### 3.3.1 Terminology

#### 3.3.1.1 *Phototherapy*

Phototherapy refers to the use of light in the treatment of disease. The light involved is in the 250-900 nm regions. The processes involved being photochemical ones.

#### 3.3.1.2 *Photochemotherapy*

Photochemotherapy is a subdivision of phototherapy where the treatment involves the administration of a drug and the administration of light.

#### 3.3.1.3 *Photodynamic therapy*

Photodynamic therapy is a part of photochemical therapy. In addition to light and the administered drug, oxygen is also required.

### 3.3.2 History of PDT

In 1900 a German medical student called Oscar Raab studied the behaviour of paramecia in the presence of minute concentrations of acridine (Bonnett R 1-17). His findings were erratic until he realised that daylight was affecting his results. Controlling for light he showed that acridine killed the paramecia in the presence of light but not in the dark. He also demonstrated that light alone did not kill the paramecia.

The first clinical report in modern literature of PDT describes the treatment of a woman with a large ulcerating breast tumour (Lipson, Gray MJ, and Baldes 393). She received multiple injections of Haematoporphyrin Derivative (HpD) injections followed by exposure to filtered light from a Xenon arc lamp. It was observed that the tumour responded to this treatment. Interest was rekindled only in the early 1970's when two American groups further investigated PDT.

In 1972, Diamond and colleagues transplanted gliomas into the subcutaneous tissue of rats (Diamond et al. 1175-77). Haematoporphyrin was administered which was found to localise in these tumours. The application of light caused massive destruction of these porphyrin containing tumours. This report brought the term "photodynamic therapy" in to general use. In 1974, Dougherty demonstrated the eradication of a

transplanted mouse mammary tumour using HpD activated by red light from a filtered xenon arc lamp (Diamond et al. 1175-77; Dougherty 1333-36).

### 3.3.3 Principle of PDT

The three fundamental elements of PDT are oxygen, a photosensitiser and visible light. The photosensitiser is activated by light and interacts with molecular oxygen to produce a reactive singlet oxygen moiety which has a short lifetime and a short radius of action. It is possible that other highly reactive intermediaries like free radicals are also produced. The result is an irreversible oxidation of essential cellular components leading to the destruction of crucial cell membranes, organelles and vasculature and ultimately cell death.

### 3.3.4 Photosensitisers

#### 3.3.4.1 *First generation photosensitisers*

The original photosensitiser was a preparation obtained from haematoporphyrin (Hp). Since its structure was not known it was termed haematoporphyrin Derivative (HpD). It is a mixture of products based on the porphyrin structure – monomers, protoporphyrin and intermediate products. The commercial product is Photofrin where the concentrations of the monomers and unstable products have been greatly reduced. Many institutions involved in PDT need to prepare their own product, each having different PDT efficacy. This made comparison of clinical results difficult. The wavelength of light required to activate HpD (628-630 nm) penetrates tissue to a maximum depth of only 1 cm limiting treatment to superficial lesions. Furthermore HpD causes severe skin photosensitivity lasting several weeks which has limited its acceptance. ~~Second generation photosensitisers~~

In order to avoid the side effects of Photofrin – newer photosensitisers have been synthesised as shown in Table 10.

#### 3.3.4.2 *Choosing a photosensitiser for PDT*

The choice of the photosensitiser depends on the nature of the lesion treated. PDT was first used for the treatment of malignant conditions. Today however it is also being investigated for the treatment of benign disease. Selectivity for hyperproliferating tissues varies between photosensitisers. Some such as Photofrin are

distributed to connective tissue and blood vessels whereas others such as ALA have a mucosal predilection.

Structure	Photosensitisers
Chlorins and chlorin-type Sensitisers	NPe6 Meta-tetrahydroxyphenyl chlorin MTHPc
Purpurins	Tin etiopurpurin (SnET2)
Benzoporphyrins	Benzoporphyrin Derivative (BpD)
Phthalocyanines	Disulphonated zinc Phthalocyanine (ZnPcS2) Disulphonated aluminium Phthalocyanine (AlS2Pc)
Texaphyrins	Lutetium texaphyrin
5-Aminolaevulinic acid	Amino laevulinic acid (ALA)

Table 10 Second generation photosensitisers

It is important to choose a route of delivery of the photosensitiser that would reduce skin photosensitivity. This can be achieved by topical application or administering the photosensitiser directly into the tumour. It must be ensured that adequate target tissue levels of the photosensitiser are achieved so that the optimum PDT effect is achieved.

The wavelength of light at which the photosensitiser is activated is also important as discussed in section 3.3.5

### 3.3.5 Light delivery for PDT

#### 3.3.5.1 Effect of wavelength on PDT

Each photosensitiser has its own absorption spectrum. Light of the appropriate wavelength must be applied for maximum absorption. For clinically used photosensitisers this ranges from 420 nm (blue light) to 780 nm (near infra red light). As the wavelength increases the depth of tissue penetration increases. Blue light penetrates about 0.3 mm while red light about 5 mm. As the wavelength shortens more light gets absorbed by chromophores like melanin and haemoglobin (see section 3.1.1). The haemoglobin absorption spectrum falls off rapidly above a wavelength of 600 nm in the red spectrum. Longer wavelengths are therefore chosen for PDT even though some photosensitisers absorb less well at these levels.

### *3.3.5.2 Light sources and delivery*

Initially only large complex laser systems were capable of delivering the power at appropriate wavelengths for effective treatment. The development of semi conductor diode lasers has however changed this (see section 3.2.2). Non laser light sources have also been investigated for PDT. However at present these cannot be directed into suitable optical fibres. The major attraction with lasers is that the light fibres can be passed through endoscopes, needles or customised light delivery devices allowing effective light delivery to the target area.

### *3.3.5.3 Effect of light fractionation on PDT*

During PDT the treated tissue is rendered ischaemic and oxygen concentrations begin to fall reducing the efficacy of the treatment. With some photosensitisers switching off the light temporarily during treatment allows the tissue to revascularise increasing oxygen concentrations. Studies fractionating the light delivery have shown an enhanced PDT effect. This however increases the treatment time and is inconvenient for the patient (Messmann et al. 589-94).

### *3.3.5.4 Drug light interval*

This is the time period from the administration of the drug until the delivery of light. It is important that sufficient data are available on the time at which the concentration of the photosensitiser is the highest in the tissue that is to be treated. It is convenient if the drug light interval is short so that both the administration and the delivery of light would occur on the same time. Long drug-light intervals (several days) are inconvenient to the patient and may not be acceptable.

## **3.3.6 Limitations of PDT**

PDT has many limitations. It is an ablative treatment that yields no biopsy material so a histological diagnosis must be made before treatment is carried out. It is more complex than other modalities of treatment as it involves a multi-disciplinary team comprising scientists (photo chemists and physicists) and clinicians.

## **3.3.7 Clinical applications of PDT**

Most of the clinical applications of PDT are for malignant or premalignant conditions. There was much optimism as it was initially thought that photosensitisers were

selectively taken up by tumour tissue with the possibility of subsequent selective tumour destruction with PDT. This is not the case. There does however appear some selectivity between the endothelium and other tissue layers and this may be exploited for PDT.

#### *3.3.7.1 PDT for the treatment of malignancy*

PDT has a limited depth of destruction of 5 mm or more. It is therefore best suited for the treatment of early invasive cancers in which the patient is not suitable for conventional surgery. PDT has been extensively investigated for the treatment of oral cancers. It has been shown to produce a depth of necrosis of 5 mm or more and heals with a very good cosmetic and functional result. Encouraging results have also been reported for cancers of the oesophagus, stomach and colon but it cannot treat tumours that have spread beyond the wall of the organ of origin (Sibille et al. 337-44).

PDT with the use of the photosensitiser 5-amino laevulinic acid shows some affinity for the epithelium or mucosa of hollow organs compared to the underlying submucosa and muscle. As mentioned before, this can be exploited for the treatment of dysplasias of the oesophagus (Barrett's disease), major bronchi and the vulva. PDT in this situation carries the advantage of causing epithelial destruction with minimal damage to the underlying muscle thereby maintaining the structural integrity of these organs.

More recently PDT has been investigated for the treatment of solid tumours of the pancreas, prostate, and lung. Here the light is delivered by fibres inserted percutaneously under radiological surveillance like that described for ILP. Interstitial PDT has been used to treat inoperable cancers of the pancreas. Results showing large areas of tumour necrosis which resolve spontaneously have been encouraging. (Bown et al. 549-57) Similarly in the studies done in patients with localised recurrence of prostatic cancer after radiotherapy, interstitial PDT has been shown to cause necrosis of these tumours with marked lowering of PSA levels (Nathan et al. 1427-32). Interstitial PDT has a place where the situation of the tumour causes technical difficulties with surgical resection like in the lungs and also where complete resection is not possible. PDT has been used as an adjuvant therapy to treat residual disease after surgical resection as in tumours of the brain (Muller and Wilson 346-54).

### *3.3.7.2 PDT for the treatment of skin conditions*

One of the original indications for PDT was for the treatment of skin conditions like basal cell carcinoma. This has been further investigated for the treatment of actinic keratosis, refractory acne vulgaris and psoriasis with varying results (Coulter 149-50; Itoh et al. 575-79). The advantage is healing with minimal fibrosis and scar formation resulting in remarkably good cosmetic results.

### *3.3.7.3 PDT for the treatment of vascular disease*

PDT with ALA has been shown to inhibit smooth muscle proliferation from the tunica media of blood vessel walls. This proliferation is one of the main reasons why restenosis occurs following balloon angioplasty or the insertion of vascular stents in patients with obstructive vascular disease. PDT to the procedure site to suppress this proliferation is being investigated as an alternative to brachytherapy and coated stents to reduce the incidence of restenosis. Minimal damage to the elastin and collagen of the blood vessel walls appears to minimise complications such as aneurysms (Jenkins et al. 1258-63).

One of the success stories of PDT is the treatment of patients with age related macular degeneration which is a leading cause of blindness in the UK (Bressler 1425-27). Conventional therapy which consists of laser photocoagulation of the neovasculature causes adjacent thermal damage to the retina. PDT with BpD can be done under local anaesthetic with the light delivered by a slit lamp for duration of less than one minute. Unlike laser treatment, selectivity is possible because at the time of the treatment the photosensitiser is still in the neovasculature.

### *3.3.7.4 PDT for the treatment of infections*

PDT was coined by the serendipitous discovery of the effect of acridine on paramecia (see section 3.3.2) in the presence of light and oxygen. Many bacteria and fungi like *Candida* take up photosensitisers which can be activated by light thereby destroying the organisms. Clinical applications would include the treatment of superficial ulcers on the skin and the mouth which are easily accessible to the administration of both the photosensitiser and light. This would be useful especially in Methicillin Resistant *Staphylococcus aureus* (MRSA) infection. Another potential application would be the treatment of *Helicobacter pylori*. PDT has also been used in the treatment of viral

infections particularly with Human Papilloma Virus when it forms condylomata accuminata of the vulva with two thirds of women showing a complete response (Frank and Bos 70-71). The attraction is that scarring is minimal with a good cosmetic result. As this condition tends to recur PDT is an ideal treatment as it can be repeated without any toxicity. The drawback is the pain during illumination.

### 3.3.8 PDT for the treatment of DUB

There are a number of methods currently in use to destroy the endometrium in an attempt to reduce menstrual blood loss in the absence of any pathology (see section 2.2). None of these methods guarantee complete global destruction of the endometrium. Furthermore the methods use a thermal effect for tissue destruction which carries with it a risk of uterine perforation and transmission of heat to the serosal surface of the uterus with subsequent damage to intraperitoneal organs. Post treatment intra uterine adhesions occurs which makes future biopsy to exclude endometrial cancer, where indicated, difficult.

#### 3.3.8.1 *Characteristics of the ideal minimal access technique for endometrial ablation in women with DUB*

The ideal characteristics of a minimal access technique is summarised in Table 11

Ideal characteristic
Requires no endometrial preparation
Requires only a local anaesthetic or no anaesthetic
No risk of uterine perforation
No risk of damage to other intraperitoneal organs
Does not cause intra uterine adhesions
Easy to perform
Acceptable to women
100 % success rates

Table 11 Box showing the characteristics of the ideal minimal access technique

### *3.3.8.2 Suitability of PDT as an alternative minimal access technique for endometrial ablation in women with DUB*

PDT is a non thermal technique of endometrial ablation and hence does not carry the risk of thermal damage to intra peritoneal organs. It has a maximum depth of destruction of 5-7 mm and hence the possibility of uterine perforation is minimal. As there is minimal PDT destruction of the myometrium it is thought that intrauterine adhesions and synechiae would be minimal. PDT could be performed as an out patient procedure but would preferably need conscious sedation. It is non operator dependant on its effect and hence would have a very sharp learning curve and would therefore be easy to perform. With these advantages it is not difficult to see that women would have no difficulty in making this their choice of treatment. The problems however with PDT is to obtain total or global destruction of the endometrium. As described in section 1.2.1.5, even if a small area of endometrium is left that is viable – complete endometrial regeneration would occur resulting in a treatment failure.

### *3.3.8.3 Results of PDT of the endometrium*

Our understanding of the pharmacokinetics of photosensitisers investigated for PDT of the endometrium comes from animal studies. This enables refinements to be made before clinical trials are commenced.

#### *3.3.8.3.1 Route of administration*

Rats were randomised to receive intravenous, intraperitoneal and intrauterine Photofrin II (Chapman et al. 685-92). Intra uterine administration provided the best uptake and distribution within the uterus with the lowest drug dosage. When clinically applied this would be the ideal route of administration as skin photosensitivity would be minimised.

#### *3.3.8.3.2 Endometrial selectivity of photosensitiser*

Wyss et al (Wyss et al. 409-14), conducted a study on the intrauterine instillation of BpD in female rabbits. They showed that there was a much higher concentration of BpD in the endometrium compared to the myometrium and the stroma. PDT at 1 and 4 weeks showed destruction of the endometrium and not the myometrium.



Intrauterine instillation of PHP (similar to BpD) in volunteers prior to hysterectomy showed similar results.

Yang et al (Yang et al. 995-1001) studied ALA in rats. Exposure of the sensitised uteri to light produced endometrial ablation. There was however some preservation of glandular elements but no regrowth at 10 days. Pregnancy implantation in the treated uterine horn was significantly less than that of the untreated horn indicating a functional effect. ALA PDT in the rabbit uterus did not show such consistent results with patchy areas of regrowth of the endometrium at 10 days. This was attributed to the larger uterine horns and asymmetrical placing of the light diffuser fibre.

#### 3.3.8.3.3 Pharmacokinetics of ALA

Wyss et al (Wyss et al. 1176-83), used rats and rabbits as animal models to study the pharmacokinetics of the intrauterine instillation of ALA. Peak concentrations of PPIX (the active metabolite of ALA) in the endometrium were observed at 3 hours. ALA concentrations in the endometrium were much higher than the myometrium. Increasing the concentrations from 100 mg/ml or buffering the ALA solution to a pH of 5.5 did not alter the findings. PDT caused destruction of the endometrial glandular epithelium with minimal stromal scarring which was maintained at 7 days. Studies using monkeys showed peak concentrations at 4-5 hours with similar PDT results. Intravenous administration of ALA at doses of 250 g/kg did not have any adverse effects other than for increased serum aspartate aminotransferase levels which were transient.

One of the steps that render PPIX inactive is iron dependant. Connell et al (unpublished data) investigated the addition of CP94 (an iron chelator) to the pharmacokinetics of ALA. They were able to demonstrate that the peak concentrations of ALA were higher in the rabbit uterine horn where CP94 was added. This translated to a better PDT effect which was maintained at 10 days. Patchy regeneration of the endometrium was however seen at 28 days.

#### 3.3.8.3.4 Clinical studies

Gannon et al performed the first clinical studies with ALA PDT of the endometrium. He did 2 series of experiments with different doses of ALA. (Gannon) In the first series, twenty five women were administered 2 capsules of ALA (250 mg/capsule)

inserted through the cervix into the uterine cavity with the aid of an endotracheal tube as an introducer. Light was delivered by a copper vapour laser (wavelength 630 nm) through a light diffuser fibre which was passed centrally into a custom made soft latex balloon distended by Intralipid solution. The drug-light interval was 3-4 hours. All women had oestrogen priming of the endometrium. Unfortunately there was no effect of the treatment on menstrual blood loss with two thirds of women proceeding to surgery.

In a further study comprising of 4 women the dosage of ALA was doubled to 1000 mg given in divided doses 12 hours apart. With each dose an iron chelator (60 mg Desferrioxamine) was also inserted in to the uterine cavity. Light delivery was fractionated in three of the women. Results in this group were much better with an 80% reduction in menstrual blood loss with no woman requiring surgery.

### **3.4 Interstitial laser photocoagulation (ILP)**

ILP is a technique of producing gentle thermal coagulation of a lesion in the centre of solid organs using low power laser energy delivered via flexible fibres inserted through needles. The power delivered to the centre of the lesion is approximately 3-5 watts. ILP does not have any cumulative toxicity and hence the treatment can be repeated.

#### **3.4.1 History of interstitial laser photocoagulation**

Hyperthermia, induced by microwave or radiofrequency applicators, had been investigated for the treatment of tumour tissue for many years. Temperatures in the treated tissue were of the order of 41-44 ° C. Difficulty in the control of the delivery of energy resulted in the destruction of normal surrounding tissue. These shortcomings limited the use of this treatment modality.

In 1983, Bown sought to overcome this problem by delivering laser light directly into the centre of the tumour tissue. He used low powers (typically 3 watts) to cause gentle coagulation of the tumour tissue with minimum effect on the surrounding normal tissue (Bown 700-09).

### 3.4.2 Terminology of ILP

There is wide variation in the terminology used to describe ILP for uterine fibroids. Terms that have been used are myolysis, interstitial hyperthermia, interstitial thermal ablation and Laser Induced ThermoTherapy (LITT). Myolysis was the term given to the high power thermal destruction of fibroids as described previously (see section 2.3.2.3). The problem with using “Hyperthermia” is that this conventionally indicated fairly uniform temperature rises to 41-45 °C for up to several hours, so that cells die during the remaining cell cycle over several days. However using laser powers of 1.5 to 3 W over 5 to 15 minutes with bare optical fibres would result in immediate tissue necrosis around the optical fibre tip. We therefore prefer the term interstitial laser photocoagulation to differentiate it from the previous therapy.

### 3.4.3 Non gynaecological applications of interstitial laser photocoagulation

Since Bown’s initial work, ILP has been applied to the treatment of tumours in several organs including the liver, breast, prostate, bone and uterus.

#### 3.4.3.1 *ILP for the treatment of hepatic metastases*

The prognosis for patients with secondary liver tumours is poor with few patients surviving more than one year after diagnosis. Treatment options in this group of patients are limited. Surgical resection, radiation therapy, hepatic artery ligation or embolisation may have a high morbidity without significantly affecting survival.

Consequently less invasive techniques were developed. These included cryotherapy and intra hepatic injection of absolute alcohol. Cryotherapy has the disadvantage of needing a large probe which limits precision in treatment and requires a larger portal of entry into the abdominal cavity. Intra hepatic injection of absolute alcohol is fairly effective for soft hepatomas but not for hard metastases. This however causes a diffuse necrosis of the liver thereby damaging normal functioning liver tissue.

Mathewson et al used Nd:YAG laser to perform ILP on normal rat liver and found that it produced well defined highly reproducible necrotic lesions of up to 16 mm in diameter (Mathewson et al. 550-57). Healing occurred with the formation of a small fibrotic lesion at day 60. This prompted the investigation of ILP for patients with hepatic secondaries. ILP is attractive as precise thermal damage of the tumour can be carried out under conscious sedation using small diameter needles inserted under

radiological guidance. Healing can then take place after resorption of the necrosed tissue with minimal scarring. The best results are obtained with isolated metastases that are less than 3.5 cm (mainly from previously resected colorectal primaries) in patients unfit for surgery (Amin et al. 339-47).

#### *3.4.3.2 ILP for the treatment of breast disease*

ILP for the treatment of fibroadenomas and small breast cancers as an alternative to surgical excision has been investigated as the procedure can be done in the outpatient department under a local anaesthetic without leaving a scar or causing a cosmetic deformity. Real time ultrasound or MRI imaging enables accurate placement of the fibres. Basu et al (Basu, Ravi, and Kant 148-52) reported a significant reduction both clinically and by ultrasound in twenty seven women who underwent ILP for fibroadenomas. The cosmetic effect was excellent with no women having keloids or abscess formation. The best results were obtained in the smaller fibroadenomas.

Harries et al (Harries et al. 1617-19) showed that ILP with a pre charred fibre tip caused a predictable 14 mm diameter of necrosis in forty four women with small breast cancers. However much more research is required before ILP can be used in the routine treatment of small breast cancers as an alternative to lumpectomy. It is important to be sure that all the cancer has been destroyed before the necrosed tissue can be safely left in situ (Harries et al. 1617-19) (Mumtaz et al. 651-58).

#### *3.4.3.3 ILP for the treatment of prostatic hyperplasia*

ILP for the treatment of prostatic hyperplasia can cause prostatic shrinkage from intraprostatic coagulative necrosis without causing damage to the urethra or tissue sloughing. Complications such as intraoperative haemorrhage, incontinence and impotence are therefore minimised. In a series with twenty five patients, a significant improvement in patient symptom scores, maximum urinary flow rates and reduction in residual post void urine volumes have been demonstrated (de la Rosette et al. 433-38). More recently, a 3 year follow up of forty two patients has shown that the shrinkage is maintained with no patient requiring repeat treatment. Furthermore when compared to other therapies, patients undergoing ILP have one of the highest patient satisfaction scores. There were no problems with erectile function in 71% of patients (Arai et al. 1206-11). There is no convincing evidence however to date that suggests that ILP is superior to trans urethral resection of the prostate.

#### **3.4.3.4 ILP for the treatment of osteoid osteoma**

ILP is an attractive treatment for osteoid osteomas as in addition to the minimally invasive nature of the procedure, it does not cause any restriction of post operative activity. Witt et al showed that there was an 88% reduction in mean pain scores and a 100% patient satisfaction rate with the procedure in twenty three patients with osteoid osteomas undergoing ILP (Witt et al. 1125-28).

#### **3.4.4 ILP for the treatment of uterine fibroids**

As outlined previously (see section 2.1.1), there is a growing need for uterine conserving surgical treatments in women with uterine fibroids. This is a combination of a need for fertility preservation and a growing number of women who wish to preserve the uterus for reasons other than fertility. The other minimally invasive techniques (see section 2.3) may result in either ischaemia or damage to normal myometrium which may not be ideal in women seeking to become pregnant.

ILP is an exciting treatment in this respect as it would cause coagulative necrosis within the centre of the fibroid without damage to the normal myometrium. Precision of treatment would therefore limit weakening of the uterine muscle layer and reduce the risk of uterine scar dehiscence in a subsequent pregnancy.

##### **3.4.4.1 Experimental work on ILP for uterine fibroids**

ILP of uterine fibroids has been performed using in vitro and in vivo techniques to determine the extent of the thermal necrotic lesion. One or two bare tipped pre charred fibres from a 25 watts semi conductor laser (805 nm wavelength) were used to treat forty fibroids after surgical removal. The fibres were inserted into the centre of the fibroid and treatment was delivered with 2- 10 watts for 100 – 1000 seconds. Specimens were subsequently sectioned perpendicular to the fibre track and evaluated. Macroscopically there was little evidence of coagulation. With diaphorase stain techniques ellipsoid zones of devitalised tissue up to 15 mm per fibre were seen.

At the time of a planned myomectomy or hysterectomy, twenty fibroids were similarly treated by ILP. The treatment delivered was 3-4 watts for 250 -300 seconds using the semi conductor diode laser (805 nm wavelength). The fibroids were processed as for the in vitro studies. Again a single fibre produced an ellipsoidal

lesion of coagulative necrosis of 10-14 mm diameter. If 2 fibres were used the area increased to a diameter of 20 mm (Gordon AD et al. 859-66).

#### *3.4.4.2 Current clinical work on ILP for uterine fibroids*

The first ILP for uterine fibroids was performed by Dr Roxana Chapman (Chapman 171-78) at the private patients' wing at University College London Hospital in 1991. In 1998, she reported the use of ILP on 300 symptomatic patients with 950 fibroids. Two hundred and ninety three women were treated under laparoscopic guidance. Pre treatment with GnRha ranged from 6 weeks to 6 months. The fibroids were measured using the side of the needle microstat which was subsequently quantified using a ruler. The Potassium-Titanyl-Phosphate/Nedymium:Yttrium-Aluminium-Garnet (KTP/YAG) laser was used. The KTP laser was used to bore a hole from the serosal surface of the uterus to the centre of the fibroid. Once the quartz fibre tip was in the centre of the fibroid the YAG laser was used to deliver 8 watts of power in continuous mode for 5 minutes. Depending on the size of the myoma, the fibre was withdrawn by 2 cms and the sequence repeated until a column of coagulated myoma had been achieved. Six hundred and ninety four fibroids (73%) which varied between 3 and 6 cms were found to disappear in 6 months. A modification of this technique using the KTP laser alone at a distance of 1 cm from the false capsule was reported with the same results and a reduction in treatment times to 1 minute.

Dr Chapman also described ILP under CT guidance using a diode laser (805 nm wavelength) with a 4-way fibre splitter (Chapman 171-78). 4 W of power was applied for duration of 400 seconds. The fibres were withdrawn by 2 cms on 2 occasions and the treatment repeated. Disappearance of fundal fibroids with the uterus regaining its normal size was reported.

While this data is encouraging in terms of feasibility many issues need clarification. ILP was performed outside a research setting. The majority of the treatments described were using a KTP laser with single fibre treatments. This resulted in long treatment times. It was not possible to follow up the majority of women treated as most of them were from abroad and returned home after treatment. Complications were not objectively documented.

## **3.5 Conclusions**

### **3.5.1 PDT of the endometrium**

PDT appears to have all the requirements to become the ideal minimal access technique for the treatment of women with DUB. A lot of intensive work has been carried out in rat, rabbit and primate models. However the results are not encouraging and this is due to the fact that if even a small area of endometrium is not destroyed, complete regeneration is possible resulting in treatment failure. The problem is that ALA even when enhanced by the addition of an iron chelating agent does not cause sufficient depth of damage. Furthermore ensuring that the whole of the uterus is evenly and globally illuminated is difficult even with the aid of custom made light devices. These factors require further investigation if PDT of the endometrium is going to be a viable treatment in the 21<sup>st</sup> century.

### **3.5.2 ILP of uterine fibroids**

From the literature reviewed ILP is a technique that has been investigated in many branches of medicine with encouraging results. It has a great potential in the treatment of women with uterine fibroids as it may be performed with minimal access surgery as a day case procedure. From the published work of Dr Chapman it is proven that it is a safe and feasible technique. However since most of the women in these series did come from abroad, assessment of the efficacy and long term follow up is missing. Furthermore, we do not know if the procedure is associated with post operative adhesions – a factor that makes both myomectomy and myolysis undesirable.

# [4] Aims of the thesis

From the preceding 3 chapters it can be realised that Interstitial laser photocoagulation of uterine fibroids and photodynamic treatment of the endometrium in women with dysfunctional uterine bleeding are exciting minimally invasive alternatives to currently available techniques of treatment.

## **4.1 *Interstitial laser photocoagulation of uterine fibroids***

Research in ILP of uterine fibroids has shown that it is a safe and feasible technique with about one thousand procedures having been carried out without significant short term complications. The problems are that this was carried out by a single surgeon with no follow up of the women treated. As most of the women were from abroad they were lost to follow up and it is not known what degree of shrinkage occurred and whether there were any long term side effects of the treatment.

### **4.1.1 The aims of this thesis with regards interstitial laser photocoagulation**

- 1) Whether the safety and feasibility of ILP of uterine fibroids by a minimal access technique can be reproduced by other surgeons.
- 2) The short term effect of ILP on the uterine fibroid as imaged either by ultrasonography or magnetic resonance imaging.
- 3) The longer term effect of ILP on the uterine fibroid as imaged either by ultrasonography or magnetic resonance imaging.



- 4) If possible to ascertain whether ILP would cause significant post operative adhesions.
- 5) To ascertain if refinements can be made to the technique that would make the technique easier and minimise complications.

#### **4.2 Photodynamic therapy of the endometrium in women with dysfunctional uterine bleeding**

Dysfunctional uterine bleeding is the commonest indication for hysterectomy. As discussed in the preceding chapters alternatives to surgery have and are being developed in order to conserve the uterus. The problems with the first generation methods are that they are operator dependant and thereby have a long learning curve with the potential to have surgical complications such as haemorrhage, uterine perforation and fluid overload. There is still no ideal second generation method with concerns still about complications from the thermal effect produced in the uterus. Most of the second generation methods rely on complex monitoring systems to prevent this complication.

PDT is an exciting alternative as it has the potential to cause damage mainly to the endometrium in relation to the myometrium reducing the risk of perforation, would not require fluid distension of the uterus thereby reducing the risk of fluid overload, has minimal risk of haemorrhage and does not require any specialised skill to perform therefore having a very steep learning curve and would not be operator dependant. The problems however with this modality of treatment are the risk of systemic photosensitisation, inadequate treatment of the endometrium with areas being missed and inconvenience to the patient if the drug light interval is too long. The ideal PDT method would therefore be a topical intra uterine instillation of a drug minimising systemic side effects, a short drug light interval for the photosensitiser so that treatment can be offered as a day patient and total and global destruction of the endometrium. The photosensitiser that has been popularly used has been 5 amino laevulinic acid as it can be used topically, has its maximum light absorption in the red part of the spectrum allowing for good light penetration, has a drug light interval of 3 hours and is a potent photosensitiser. There was an increase in its efficacy using iron chelators but the results are still not satisfying. This could be due to 2 reasons. 1) ALA is not the ideal photosensitiser and 2) Light illumination of the uterine cavity is

not uniform so that even though the photosensitiser is evenly distributed to a sufficient depth it cannot be activated. It is most likely that it is a combination of these two factors that are responsible for the suboptimal effect.

#### 4.2.1 The aims of this thesis with regards investigation of an alternative photosensitiser to Aminolaevulinic acid for photodynamic therapy in an animal model

- 1) To investigate diphosphonated phthalocyanine (ALS2Pc) as an alternative photosensitiser to ALA.
- 2) To determine the distribution of ALS2Pc in the uterus after topical application in an animal model (female New Zealand white rabbit).
- 3) To determine the optimal drug light interval for PDT damage to rabbit endometrium.
- 4) To determine the extent of PDT damage to rabbit endometrium.
- 5) To determine the extent of rabbit myometrial damage from PDT treatment of the endometrium.
- 6) To determine the extent of rabbit endometrial regeneration following PDT treatment

#### 4.2.2 The aims of this thesis with regards the investigation of light delivery to the human uterus

- 1) To determine if intrauterine balloons made with titanium chips embedded in its walls are more effective in light delivery than the standard balloons used.
- 2) Whether different sizes of balloons are required depending on the size of the uterus being illuminated.
- 3) To determine if intrauterine balloon devices are the best way of delivering light to the uterine cavity using extirpated uteri.
- 4) To determine if intrauterine pathology like polyps, septae or previous endometrial treatment affects light delivery to the uterus.

## **SECTION 2 – EXPERIMENTAL WORK**

Chapter 5      Distribution of Aluminium Disulphonated Phthalocyanine in the rabbit uterus after topical instillation

Chapter 6      Morphological changes in the normal rabbit uterus following PDT with Aluminium Disulphonated Phthalocyanine

Chapter 7      Intrauterine light delivery for photodynamic therapy of the endometrium

Chapter 8      Interstitial laser photocoagulation of uterine fibroids

# **[5] Distribution of Aluminium Disulphonated Phthalocyanine in the rabbit uterus after topical instillation**

## **5.1 Introduction**

Photodynamic therapy of the endometrium is an exciting alternative to the currently available second generation endometrial ablative techniques. Clinical results to date however have not been encouraging. This is due to the capacity of the endometrium to regenerate following treatment. If endometrial regeneration is to be prevented, PDT damage of the whole thickness of the endometrium must occur. Furthermore PDT must also damage the endometrium of the tubal ostia and the cervical isthmus as regeneration commonly occurs from these sites as described in chapter 1.

For PDT to be effective, the photosensitiser must localise to the deep glands. In order to avoid complications of haemorrhage, post treatment adhesions and uterine perforation the drug must have some selectivity for the mucosa over the connective tissue. After administration of the drug, the time interval at which the concentration is highest in the uterine mucosa must be known so that light may be delivered to the uterus with optimal results. It is important therefore that the pharmacokinetics of a drug be studied before PDT treatment is commenced. This may then be exploited for optimal results.

Most of the work with PDT of the endometrium has been done using 5 amino laevulinic acid (ALA) as the photosensitiser. In 1993, Michelle Judd investigated the systemic administration of another photosensitiser, aluminium disulphonated phthalocyanine, in the rabbit uterus. The pharmacokinetics and the PDT damage in the rabbit model were comparable with the results obtained with ALA. However this work has not been carried further because of the risk of cutaneous photosensitivity. This may be reduced or even eliminated by the topical administration of the drug. This chapter investigates the pharmacokinetics of AIS2Pc in the rabbit uterus after topical instillation. The rationale for the choice of a rabbit animal model and advantages of AIS2Pc over ALA will also be discussed.

## **5.2 Choice of an animal model**

The uterus, cervix and the fallopian tubes in women develop from the paramesonephric or Mullerian ducts which extend from the genital ridge to the urogenital sinus. The lower ends of the ducts fuse in the midline and subsequently become canalised and form the cavity and lining of the uterus and the cervix. Mesenchymal proliferation occurs around the fused portions to form the muscular layer of the uterine wall. The animal model that closely resembles the human uterus is that of the higher primates. It is unethical to use primates as an animal model.

Another alternative is the rat. The rat uterus is approximately 1-1.5cms in length and is extremely thin walled and would not be able to withstand the instrumentation required for experiments in photodynamic therapy. This makes it an unsuitable model.

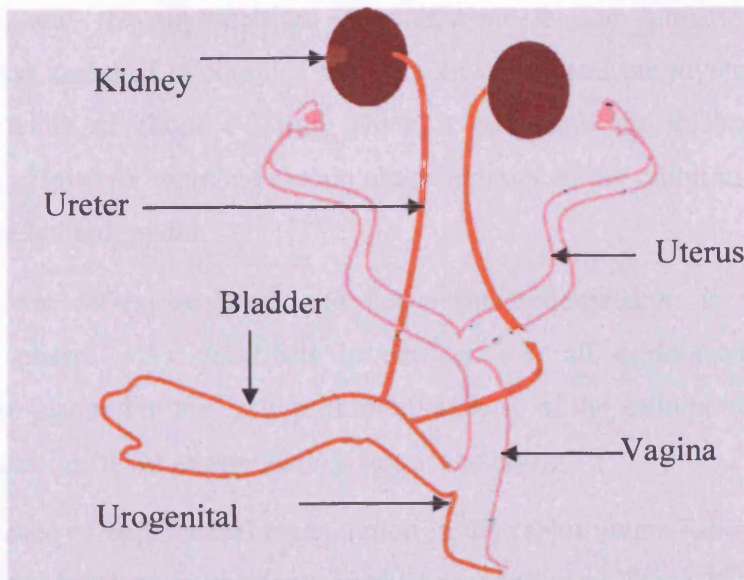


Figure 16 showing a schematic diagram of the urogenital system of the female rabbit

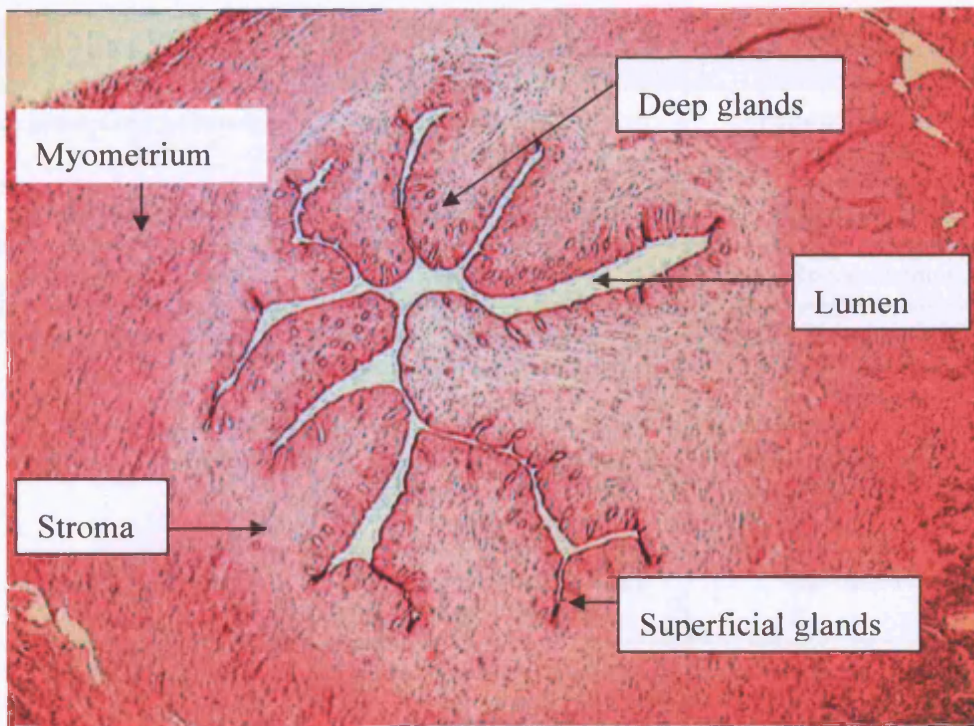


Figure 17 showing a transverse section of the rabbit uterus. The superficial glands, deep glands, stroma and myometrium where fluorescence intensity measurements were taken are shown (magnification x10)

The model chosen for this experiment was the rabbit uterus despite its structure being quite unlike that found in women. The rabbit uterus consists of two long uterine horns and two cervixes with a total length of approximately 10 cms (see). Both the

endometrium and the myometrium are different to the human uterus. The endometrium is arranged in complex villi like processes and the myometrium is very thin with a width of about 1-3 mm which is one tenth the thickness of human myometrium. However there are certain characteristics of the rabbit uterus that make it an attractive animal model.

1) Rabbits are reflex ovulators and hence the endometrium is always in the proliferative phase. As described in section 2.2, all endometrial destructive techniques are planned in the early proliferative phase of the endometrial cycle. This is convenient as timing of experiments is not necessary.

2) The sequence of endometrial regeneration in the rabbit uterus following curettage and cryosurgery has been extensively studied as detailed in Table 12. This is quite like the regeneration of human endometrium after menstrual shedding as described in Chapter 1. This knowledge is important to assess the efficacy of PDT as endometrial regeneration is the principal cause of treatment failure.

	Curettage	Cryosurgery
Maximum extent of damage	70% of surface endometrium denuded	95% of surface endometrium denuded
3 hours post treatment	Regenerating cells	No regeneration
6 hours post treatment	Same as 3 hours	No regeneration
12 hours post treatment	40-50% denuded areas covered by regenerating endometrium	Early regenerating cells from glandular and epithelial remnants
24 hours post treatment	Up to 60% denuded areas covered by regenerating endometrium	40-50% denuded areas covered by regenerating endometrium
48 hours post treatment	Surface completely lined by endometrial cells	Same as 24 hours
72 hours post treatment	Endometrial regeneration completed	Same as 24 hours
21 – 30 days	Same as 72 hours	Endometrial regeneration completed

Table 12 Regeneration of rabbit endometrium following curettage and cryosurgery

3) Endometrial regeneration occurs from the same place as in the human uterus (from the glands in the depths of the destroyed glands and the glands that were not

destroyed). Hence improvements in the technique of PDT in this animal model are theoretically applicable to the human uterus.

4) As the rabbit uterus is a duplex structure, it can act as its own control thereby greatly reducing the number of animals required.

5) Previous animal experiments on PDT with other photosensitisers and with the photosensitiser used in these series of experiments have been conducted using the rabbit model. To a certain extent it is therefore possible to compare results obtained by other researchers in this field. In our study this is especially pertinent as it would be interesting to see if the topical application of AlS2Pc would have the same pharmacokinetics as systemic administration.

6) The rabbit is a small animal and the small animal laboratory could be used with researchers being easily trained in the handling and treatment of these animals according to home office guidelines. A further advantage of the choice of a small animal is the reduction in cost.

### **5.3 Choice of photosensitiser**

As discussed in Chapter 3, clinical trials of PDT of the endometrium for women with dysfunctional uterine bleeding are disappointing. The photosensitiser used in almost all these cases was ALA (5-amino laevulinic acid). The advantages of using ALA are that it is easy to synthesize, has a convenient absorption peak of the photoactive derivative PPIX which is in the red spectrum at 635 nm where there is good penetration of tissues. There is also a high yield of reactive radicles. PPIX is easily detected in vivo and vitro and fluorescence corresponds to photoactivity. Side effects with systemic use include hypotension, hepatotoxicity and photosensitivity. These are minimised when used topically in the uterine cavity. The problem however may be that the concentration of PPIX in the endometrium may not be sufficient to cause the best PDT effect.

There has been a growing interest in looking for an alternative photosensitiser. The phthalocyanines have been investigated in this respect. The advantages are that they have similar biological properties to the porphyrins with an absorption peak further in the red part of the spectrum at 675 nm and hence theoretically tissue penetration is better with little unwanted absorption by natural biomolecules. It induces lower skin



photosensitivity to sunlight than ALA when used systemically. It has been used in animal models and has been found to be non toxic.

Pure phthalocyanines are not water soluble however it can be easily made soluble by sulphonation of the metallic compound by treatment with fuming sulphuric acid. Complexing the phthalocyanines with transition metals like copper or iron gives dyes with short triplet lifetimes whereas closed diamagnetic ions such as Zinc, Aluminium and gadolinium give phthalocyanine complexes with both high triplet yields and long life times. Sulphonation of metal phthalocyanines increases the phototoxic effect however it also results in the formation of inactive aggregates with reduced photochemical activity.

The biological effect of sulphonated metallophthalocyanine dyes has been studied by fluorescent microscopy of V-79 Chinese Hamster cells. Highly photocytotoxic disulphonated derivatives gave uniform fluorescence in the cell cytoplasm whereas tri and tetra sulphonated derivatives showed very little dye uptake (Paquette et al. 215-20).

Judd et al studied the distribution of AlS2Pc in the rabbit uterus after intravenous administration. The concentrations of AlS2PC were indicated by measurement of fluorescence intensity using a cooled charged coupled device (CCD). The location of the fluorescence was confirmed by haematoxylin and eosin staining of the same tissue sections. She reported a peak tissue concentration at 1 hour which fell to plateau between 6 and 48 hours following administration. There was a four fold increased uptake by the endometrium when compared with the myometrium and serosa which was almost at the level of background fluorescence. In the endometrium the glandular uptake was higher than in the surrounding stroma at all time points other than at 24 hours.

This selectivity was comparable with that of PPIX levels. The problems with clinical applications are that women would not tolerate the side effects of photosensitivity for the treatment of a benign condition. Topical administration of AlS2Pc would be an ideal alternative. However we do not know whether the tissue concentration and distribution would be the same as that after systemic administration.

## **5.4 Aim of this study**

We therefore aim to study the distribution and localisation of AIS<sub>2</sub>Pc in the rabbit uterus after topical application.

## **5.5 Methods**

### **5.5.1 Photosensitiser**

Aluminium Disulphonated Phthalocyanine (AIS<sub>2</sub>Pc) powder (Prof D Philips, Imperial College London) was dissolved in physiological strength, phosphate-buffered saline (PBS) and administered in a volume of 0.5 ml, the stock solution concentration was 1 mg ml<sup>-1</sup>.

### **5.5.2 Animals**

Normal, female, New Zealand White rabbits (3-4 Kg) supplied by Charles River UK Ltd. (Margate, Kent) were used through out.

### **5.5.3 Preoperative care**

The animal was kept for a minimum of two weeks to allow for acclimatization to the new surroundings. Training of the handling and management of small animals was done at University College London and a personal license obtained from the home office in accordance with the Animals (Scientific Procedures) Act 1986.

### **5.5.4 Operative care**

#### **Anaesthetic Regime**

The animals were under a general anaesthetic for the entire surgical procedure. Anaesthesia was induced using Hypnorm (Fentanyl and Fluanisone, Janssen Pharmaceuticals Ltd, Oxford, UK) intramuscularly for induction. When the animal was drowsy about 15 minutes later Diazepam (Phoenix Pharmaceuticals Ltd Loucester UK) was given intravenously. Anaesthetic was maintained by using Hypnorm 0.1ml/Kg every 45 minutes after induction.

Baytril (Enrofloxacin) which is a floroquinolone group of antibiotic was administered at a dose of 0.2ml/kg s.c immediately pre operatively. Vertegesic was given subcutaneously for post operative pain relief. Table 13 shows the dosages of Hypnorm, Diazepam and Vertegesic that were administered according to the body

weight of the animal. Before beginning the laparotomy the depth of anaesthesia was tested with skin pressure using a toothed forceps. In all the experiments that were performed the above anaesthetic regime was found to be adequate without recourse to further drugs.

Weight	Hypnorm (ml)	Diazepam (ml)	Vetergesic(ml)
1.7	0.51	0.68	0.17
For every extra 0.1 Kg	Increase by 0.03 ml	Increase by 0.04ml	Increase by 0.01ml

Table 13 Table showing anaesthetic and pain relief regime used according to the body weight of the rabbit

### Surgical technique

After the general anaesthetic the fur was shaved using an electric razor to expose the lower 5cms of the abdomen. The shaved area was then cleaned with 70% alcohol and then with aqueous Chlorhexidine solution. A 2 cms long midline incision was made approximately 2 cms above the symphysis pubis. The peritoneum was lifted by two atraumatic graspers before being incised to prevent damage to underlying organs. The uterus was hooked out with the aid of a finger from behind the bladder and surrounded by moist towels. 0.5 ml of the AIS2Pc solution was injected into the lumen via the anti-mesenteric border of the proximal end of the uterine horn and a silk ligature was used to isolate the uterine horn and prevent the dye from entering the vagina by peristaltic action of the uterine horns. The abdomen was closed in layers with vicryl. The skin was closed with a continuous subcutaneous suture using 2-0 vicryl so that there were no knots that the animal could gnaw at post operatively.

### Intraoperative monitoring

The set up at surgery and the monitoring of the rabbit is shown in Figure 18. The rabbit was attached to a pulse oximeter and the oxygenation was maintained throughout the procedure at 99 – 100% saturation.

### 5.5.5 Post operative care

The rabbits were transferred to warm boxes and placed prone on warm towels and covered with towels till they woke up. The animals were checked daily for wound

healing and were given free access to food and water. Any change in state of the animals post instillation of the dye was noted.

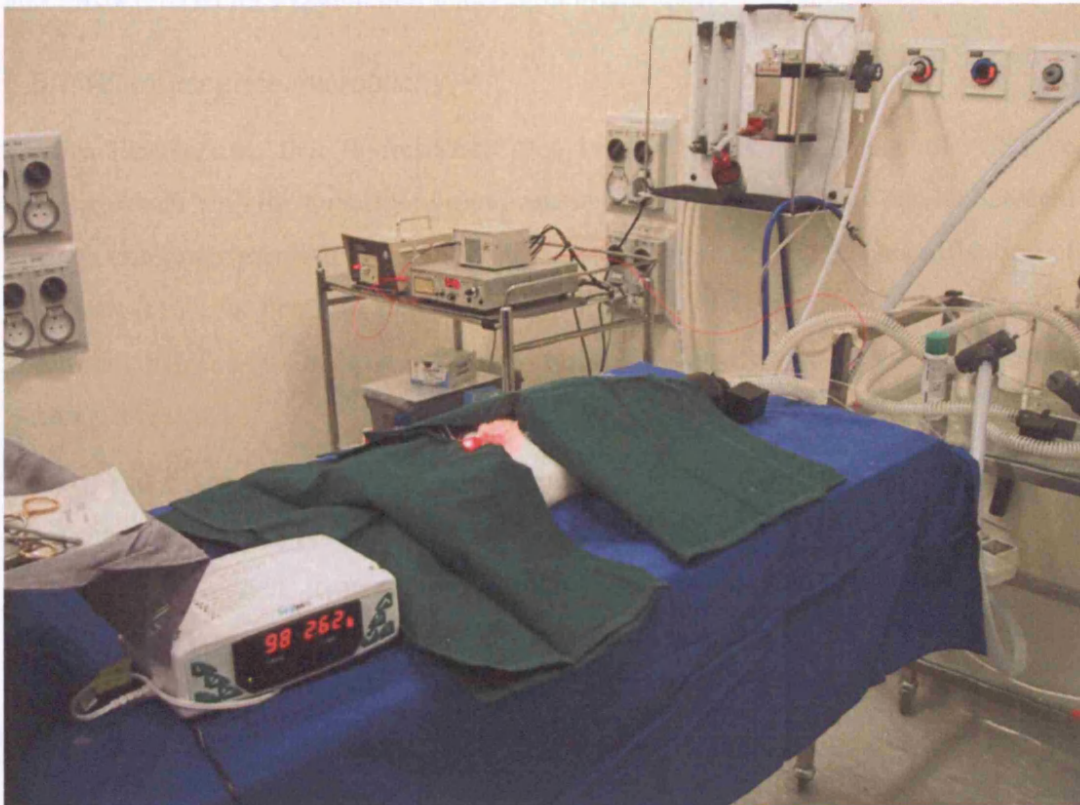

Figure 18 Picture showing the rabbit positioned for laparotomy with the Boyles apparatus and pulse oximetry showing monitoring used during surgery

#### 5.5.6 Tissue processing

Animals were killed with intravenous pentobarbitone at 0.5, 1, 3, 6, 18, 24 and 48 hours (1 animal with 2 uterine horns at each time point) after topical instillation of AIS2Pc. The lower abdominal incision was re opened. The peritoneal cavity was inspected for any effect from intraperitoneal spill of the AIS2Pc. The entire uterus was then inspected for any chemical effect from the intraluminal AIS2PC. These findings were recorded. The uterus was then removed. Multiple transverse sections were taken from each uterine horn and specimens were “snap frozen” by placing it in isopentane (BDH Ltd, UK) which had been cooled in liquid nitrogen for a few minutes. The frozen specimens were removed with forceps and placed in screw-topped bijoux. The tissue samples were stored in liquid nitrogen containers until they were sectioned. The tissue samples were then mounted in OCT medium (Tissue Tek II embedding compound BDH) and were cut using a Cryostat E microtome (Reichert Ltd) to a thickness of 10  $\mu\text{m}$ . Half of the sections from each block were mounted on

clean glass slides, which had been cooled by placing in the microtome, and stored in a refrigerator at -70 °C. The other half of the sections was stained with Haematoxylin and Eosin (H&E) for examination under light microscopy.

#### 5.5.7 Fluorescence microscopy

Studies have shown that fluorescence seen in tissue after the uptake of AIS2 Pc correlates well with the quantity of photosensitiser. This fluorescence can be detected through computer imaging of false colour coding or grey imaging. Quantification of the fluorescence is possible with computer software that calculates the number of counts per pixel in an area in a box superimposed on the area where the fluorescence is being measured.

The 10 µm frozen sections were allowed to thaw at room temperature. The slides were then placed face down on the specimen stage of an inverted microscope. The specimens were then focused under phase contrast illumination with the room darkened (see Figure 19). The excitation light was provided by an 8mW helium neon laser emitting at 632.8 nm which was chosen because of its spectral purity, low cost and more importantly the relatively low tissue auto fluorescence produced using this wavelength in contrast to shorter wavelength excitation. The fluorescence from AIS2Pc was detected using a long pass filter which transmitted in the range of 665 – 700 nm which covered its fluorescence bands. All photometry was carried using magnification of X10 N.A. 0.3.

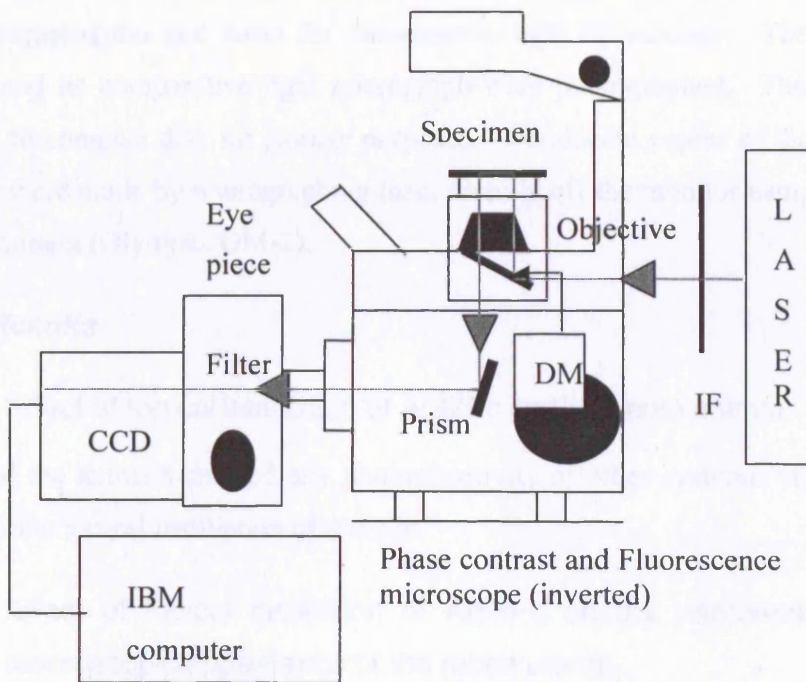
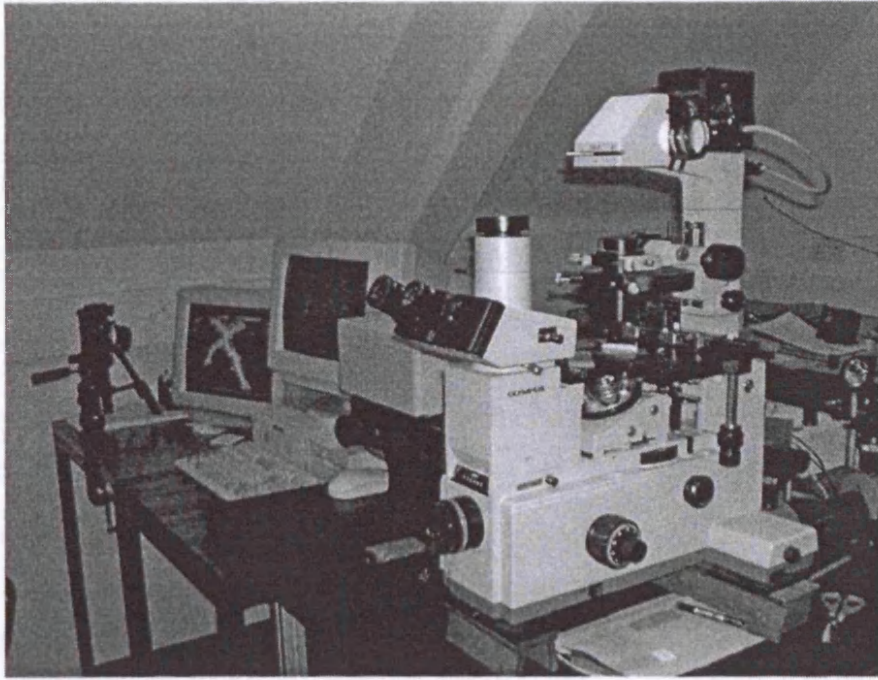


Figure 19 showing the fluorescence imaging system and the cooled charged coupled device. The second diagram illustrates how the image is obtained. DM = Dichroic mirror and IF= interference filter

The fluorescence signal was processed by a personal computer in to falsely colour coded or grey scale fluorescence images of the section (Wright instruments, model 1, resolution 600 x 400 pixels). The software also enabled quantitative measurement of fluorescent levels over selected areas of interest on the displayed fluorescence image. Representative areas of endometrium and myometrium were selected for fluorescence measurements which were then corrected for auto fluorescence levels of each respective tissue layer as measured on specimens from control unsensitised animals. These corrected fluorescence measurements had been shown to correlate with the total quantity of chemically extracted AIS2Pc from tissue specimens of animals given AIS2Pc (Loh et al. 47-54).

For each tissue cryosection three readings were taken. For each time point six sections (three from each uterus) were examined. Eighteen fluorescent intensity readings were obtained for a time point.

Following fluorescence microscopy the specimens were fixed in formalin and stained with haematoxylin and eosin for comparative light microscopy. The fluorescence image and its comparative light micrograph were photographed. The images were written to compact disc for storage purposes. Permanent copies of the fluorescence images were made by photographing them directly off the monitor using a single lens reflex camera (Olympus OM-2).

## **5.6 Results**

### **5.6.1 Effect of topical instillation of AIS2Pc on the whole animal**

None of the animals showed any photosensitivity or other systemic reactions to the intrauterine topical instillation of AIS2Pc.

### **5.6.2 Effect of topical instillation of AIS2Pc on the peritoneal cavity and macroscopic appearance of the rabbit uterus**

At all time points there was no evidence of a chemical effect of AIS2Pc on the serosal surface of the uterus or in the peritoneal cavity from peritoneal spillage of the photosensitiser.

### 5.6.3 Fluorescence microscopy

An image depicting the fluorescent intensity seen and subsequent haematoxylin and eosin staining of the same slide is shown in Figure 20 and Figure 21. These figures pictorially demonstrate the difference in fluorescent intensities at 30 minutes and 3 hours. At 30 minutes, significant fluorescence is seen in the myometrium that almost extends to the serosa. At 3 hours the fluorescence is seen mainly in the endometrium.

The software enabled quantitative measurement of fluorescent levels over representative areas of endometrial glands, submucosal and myometrium. Eighteen readings were obtained for each time point (as described in 5.5.7). These could be represented graphically with the mean and error bars for the standard error of the mean. These images also demonstrate that there is a good histopathological correlation between the fluorescent images and the H&E stained slides and allows for accurate localisation in the tissue layers of AIS2Pc.



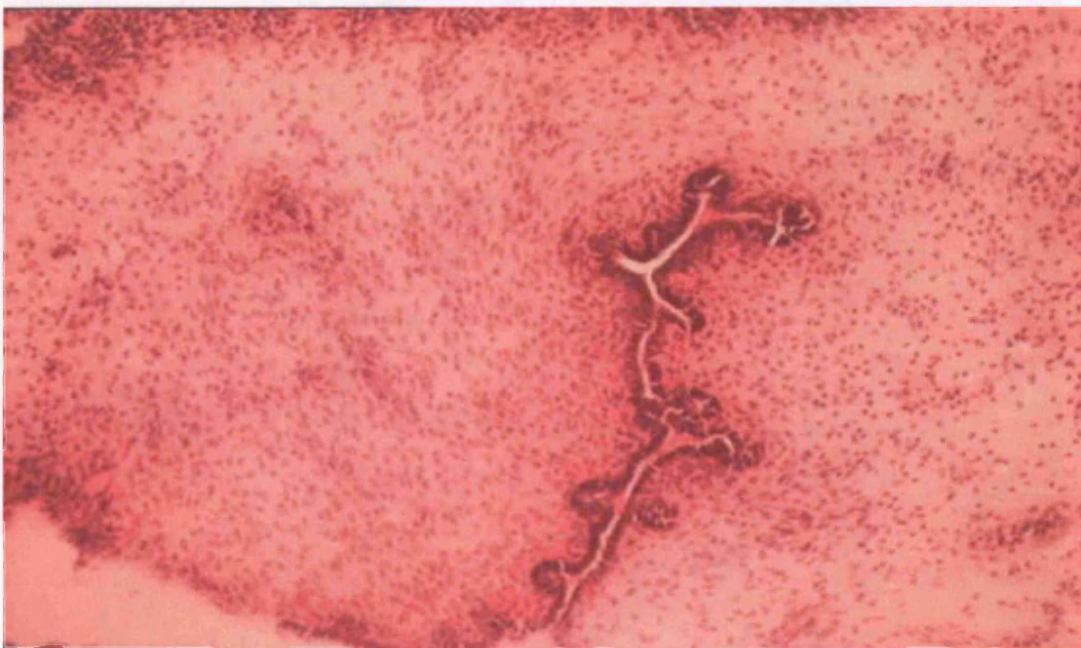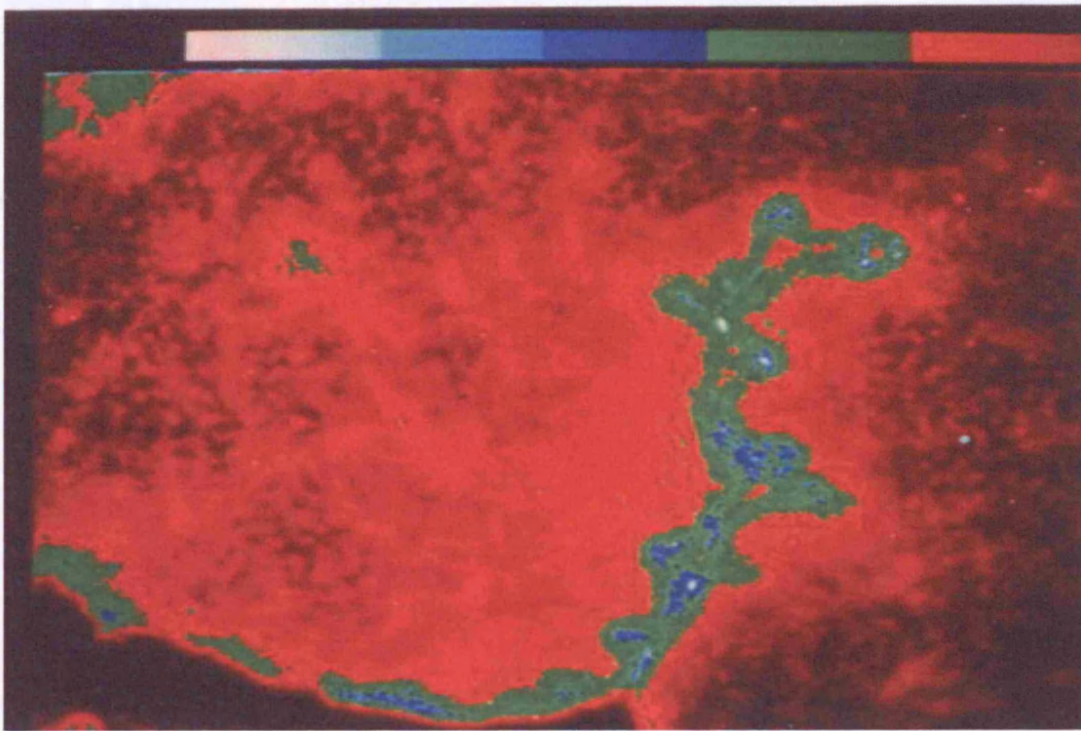


Figure 20 Fluorescence image of normal rabbit uterus 30 minutes after topical administration of 0.5 ml (1 mg/ml) AIS2Pc with the same section subsequently stained with Haematoxylin and Eosin (H&E).  
The fluorescence image shows very high fluorescence in the lumen and the endometrium with significant fluorescence in the underlying layers. The upper colour bar indicates fluorescence intensity.  
(magnification x10)

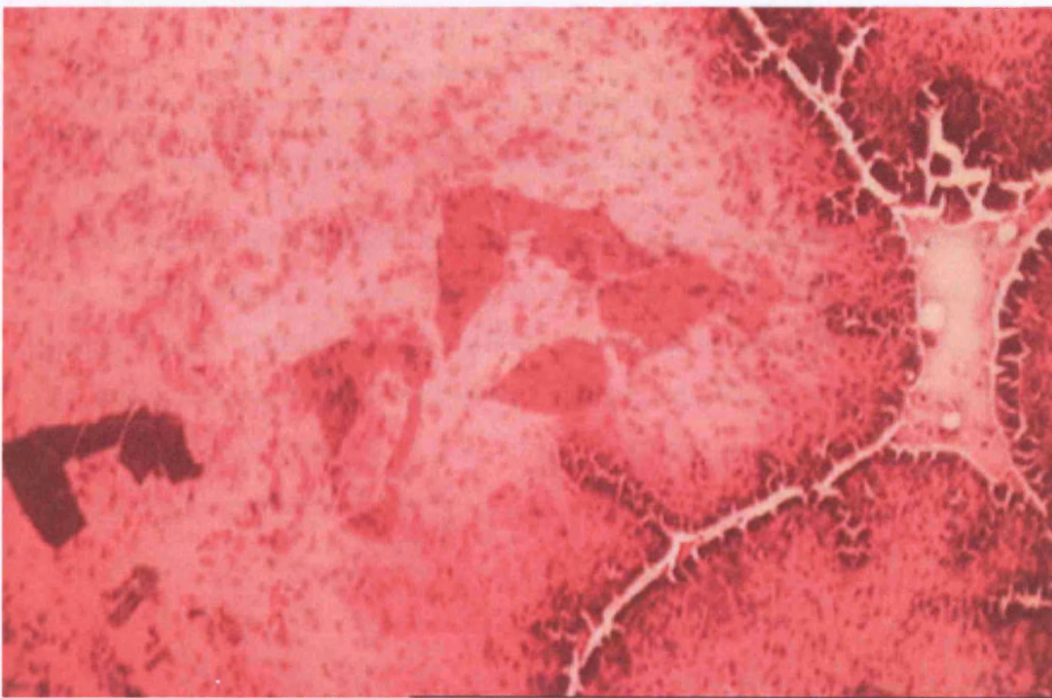
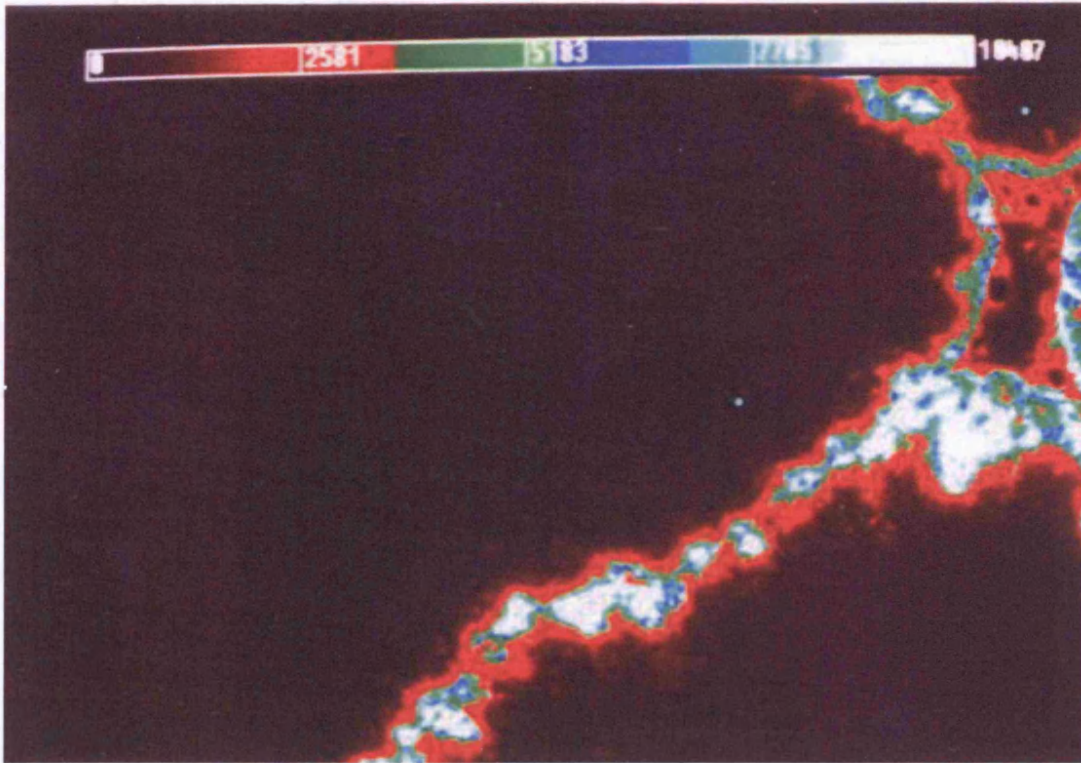


Figure 21 Fluorescence image of normal rabbit uterus 3 hours after topical administration of 0.5 ml (1mg/ml) AIS2Pc with the same section subsequently stained with Haematoxylin and Eosin (H&E). The fluorescence image shows fluorescence in the endometrium without significant fluorescence in the underlying layers. The upper colour bar indicates fluorescence intensity. (magnification x10)

#### 5.6.4 Changes in concentration of AIS<sub>2</sub>Pc with time after topical instillation

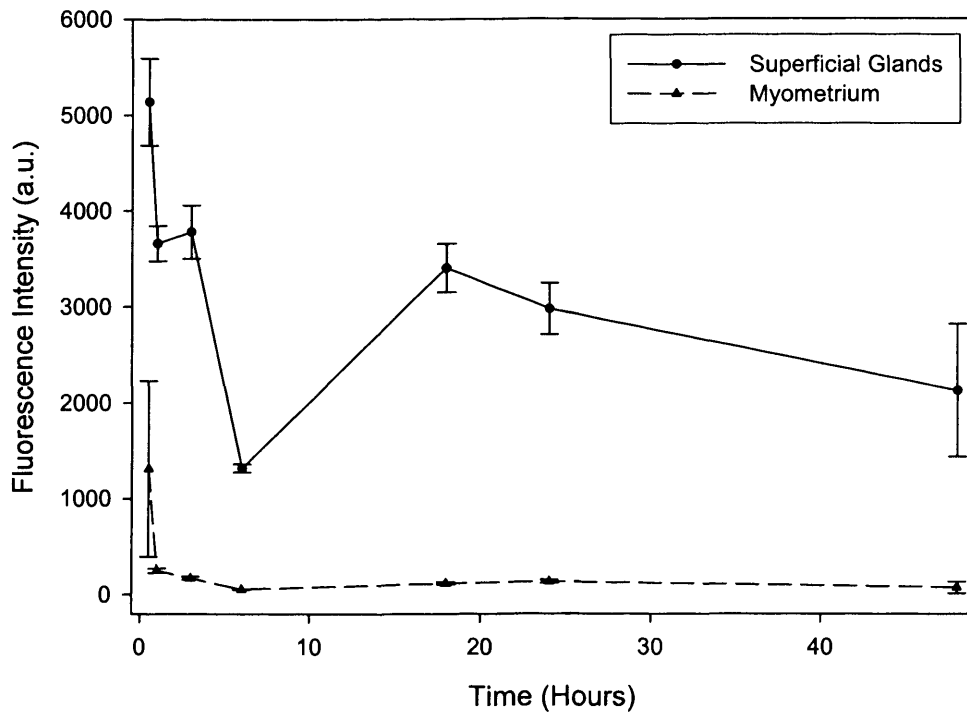


Figure 22 A graph showing the comparison of the fluorescence intensity (arbitrary units) of the superficial glands and myometrium as a function of time (hours) when the uterine horn had been treated with a topical instillation of 1 mg/ml in a 0.5 ml volume of AIS<sub>2</sub>Pc. Each point represents the mean (with the standard error of the mean) from a minimum of two separate uterine horns.

The concentration of AIS<sub>2</sub>PC in rabbit endometrium is highest at 30 minutes. This concentration halves by 1 hour and is maintained at 3 hours. The concentration halves again at 6 hours. Measurements at 18, 24 and 48 hours indicate that the concentration rises and is maintained at levels seen at 1 and 3 hours. This is graphically represented in Figure 4.

### 5.6.5 Tissue distribution of AIS2Pc in the rabbit uterus after topical application

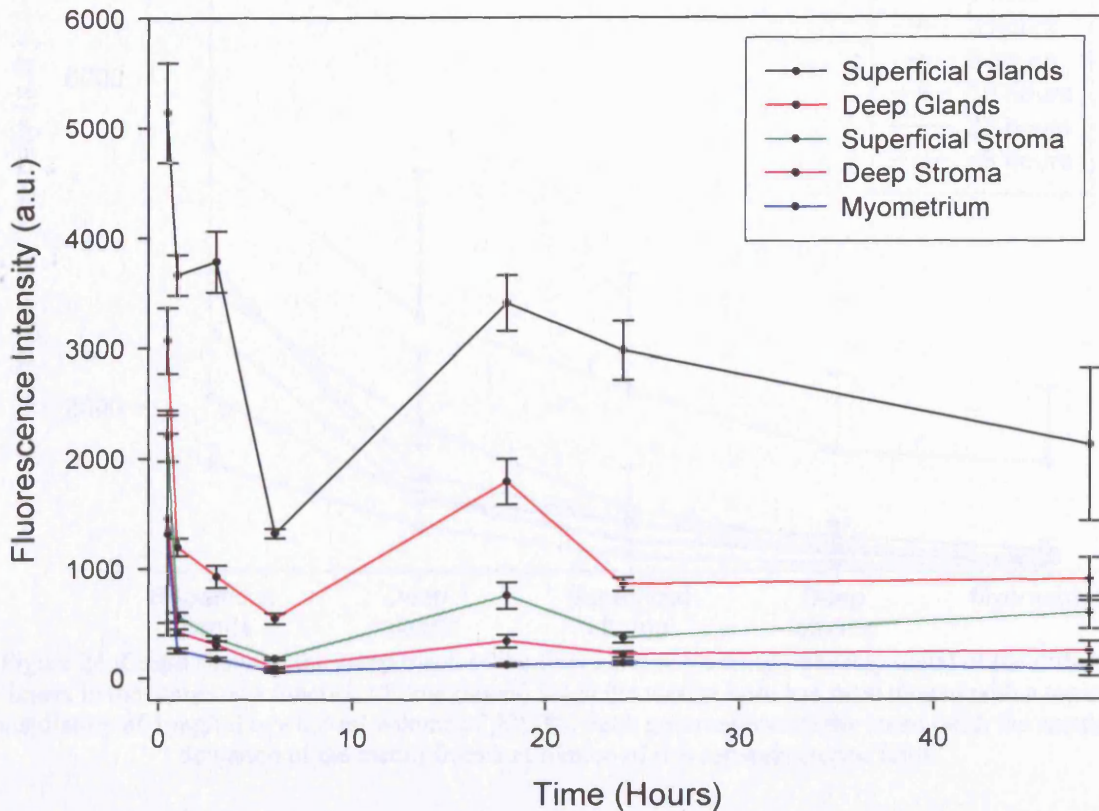


Figure 23 A comparisons of the fluorescence intensity (arbitrary units) layers of the uterine horn as a function of time (hours) when the uterine horn had been treated with a topical instillation of 1 mg/ml in a 0.5 ml volume of AIS<sub>2</sub>Pc. Each point represents the mean (with the standard error of the mean) from a minimum of two separate uterine horns.

The concentration of AIS<sub>2</sub>Pc in the other layers of the rabbit uterus mirror the pattern seen in the endometrial layer and this is shown in Figure 23.

Figure 24 shows that the concentration of AIS<sub>2</sub>Pc reduces the greater the distance the layer is from the tubal lumen. An attempt to differentiate superficial glands from deeper glands in the stroma was made when quantifying fluorescence. The concentration of the AIS<sub>2</sub>Pc in the superficial glands was on average 2.5 times greater than in the deeper glands. The fall off in the concentration of the AIS<sub>2</sub>Pc in the different layers at each time point is similar.

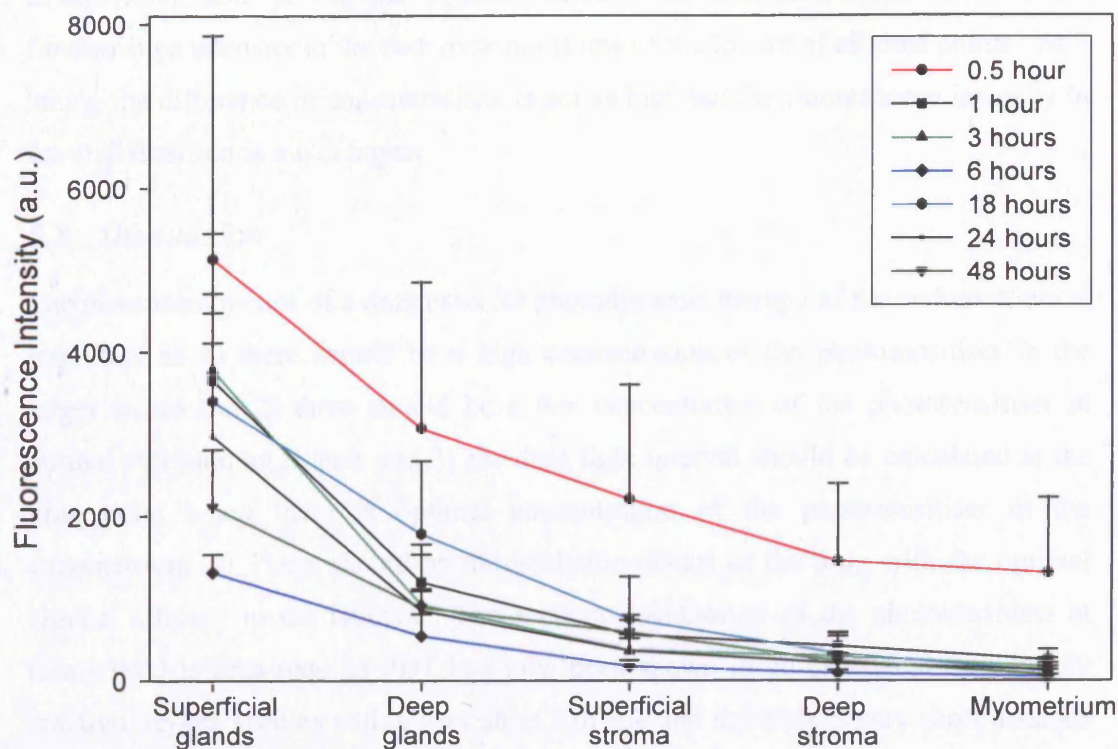


Figure 24 Graph showing the comparison of the fluorescence intensity (arbitrary units) of the different layers in the uterus as a function of time (hours) when the uterine horn had been treated with a topical instillation of 1 mg/ml in a 0.5 ml volume of AIS<sub>2</sub>Pc. Each point represents the mean (with the standard deviation of the mean) from a minimum of two separate uterine horns.

### 5.6.6 Selectivity of AIS<sub>2</sub>Pc in the endometrium

Time	Endometrium	Myometrium	Ratio E/M
0.5 hour	8206	1312	6
1 hour	4856	250	19
3 hour	4644	172	27
6 hour	1860	58	32
18 hour	5189	117	44
24 hour	3826	134	29
48 hour	3010	72	42

Table 14 Table showing the difference between normalised fluorescence intensity (arbitrary units) of the myometrium and the endometrium at each time point when the uterine horns had been treated with a topical instillation of 1 mg/ml in a 0.5 ml volume of AIS<sub>2</sub>Pc from a minimum of two separate uterine horns

The greatest difference in concentrations of AIS<sub>2</sub>Pc between the endometrium and the myometrium is seen at 18 and 48 hours after topical application.

In the early time points, the highest difference is seen at 6 hours however the fluorescence intensity in the endometrium is one of the lowest of all time points. At 3 hours, the difference in concentrations is not as high but the fluorescence intensity in the endometrium is much higher.

## **5.7 Discussion**

The pharmacokinetics of a drug used for photodynamic therapy of the endometrium is important as 1) there should be a high concentration of the photosensitiser in the target tissue and 2) there should be a low concentration of the photosensitiser in normal surrounding tissues and 3) the drug light interval should be calculated at the time point when there is optimal concentration of the photosensitiser in the endometrium. 4) There should be minimal side effects of the drug with the optimal clinical efficacy to the woman. The accurate localisation of the photosensitiser at tissue level is important as PDT had now been shown to be dependant on a highly reactive oxygen species with a very short half life and therefore a very short distance of tissue effect from the site of localisation. Therefore if the photosensitiser is not localised in all the areas that require treatment then the PDT effect will not be optimal. In other organs this would still lead to a clinical improvement but treatment success is an all or none phenomenon in the uterus because of its capability of regeneration as discussed in Chapter 1.

The limiting factor for systemic administration of AIS2Pc is photosensitisation. This can range from mild to even severe photosensitivity reactions. It is difficult to offer a clinical treatment today with side effects that significantly curtail activity. It is mainly for this reason that it was decided to see if the topical application of AIS2PC would show similar pharmacokinetics to the systemic administration as described by Judd et al (Judd).

### **Technique used**

The technique of quantifying fluorescence levels in the different layers of tissue and correlating this to the concentration of the photosensitiser present which has been used for this experiment has been extensively studied and validated. As shown in Figure 20 and Figure 21, high quality colour images are produced by the charge coupled device imaging system. In our experience repeated measurements by two

observers and by the same observer on different days produced little variation in the intensities measured.

#### 5.7.1 Local effects of topical application of AIS2Pc

One of the concerns with topical intrauterine application of the drug is the chemical effect on normal tissues of the drug which may be caused by spill which would include the intraperitoneal spill if the fallopian tube closure pressure is exceeded. What will also need working out is how the drug can be administered into the uterus in the human subject.

In this study, topical administration of the AIS2PC was done directly into the uterine lumen and there was very little contact with the vaginal epithelium. There was minimal spill in the peritoneal cavity as seen by faint blue staining especially in the animals that were killed in the early time points. There was no evidence of any chemical action of the photosensitiser on the peritoneal cavity or on the vaginal or endometrial lining of the uterus. If AIS2Pc was to be administered in the human, the administration would have to be transcervically. No pressure would be required to administer the drug and as such the uterine tubal closure pressure would not be exceeded. Hence there will be minimal peritoneal spill and it is reassuring that even if it does occur this study has shown that AIS2Pc is non irritant at least in the animal model.

#### 5.7.2 Tissue distribution of AIS2Pc

In this experiment, the concentration of the AIS2Pc after topical application was highest in the endometrial glands when compared to the other layers of the rabbit uterus in all the time points that were used. This was encouraging as this is the target area for PDT. There was a sharp fall in concentration of the AIS2Pc the deeper the layer is from the uterine lumen. This is of some concern as it also affects the glands that are deeply situated in the stroma from which regeneration of the endometrium can occur.

The concentrations of AIS2Pc were lowest in the myometrium. As discussed in chapter 2, most endometrial destruction techniques used to reduce MBL relies on a thermal effect. These invariably destroy some of the superficial myometrium as well. Healing occurs by intra uterine adhesions or synechiae referred to as Ashermanns

syndrome. This may be associated with cyclical midline pelvic pain from loculi of blood entrapped in the adhesions and is a major setback of the procedure. The investigation of a woman with Ashermanns syndrome who develops abnormal uterine bleeding is difficult both by ultrasonography and hysteroscopy. This study has shown that in a rabbit model, there is minimal concentration of AIS2Pc in the myometrium and hence there would be minimal myometrial damage from subsequent PDT. This should not therefore have any of the adverse effects of the thermal techniques of endometrial destruction.

At all time points there was almost no fluorescence detected in the deepest parts of the myometrial layer. This is reassuring as the risk of uterine perforation is low but still present in all the thermal techniques but with this procedure will be almost non-existent.

### 5.7.3 Changes in concentration of AIS2Pc with time following topical application

The temporal relationship of ALS2Pc is almost the same in all the layers of the rabbit uterus. This is highest at 30 minutes and then falls to its lowest at 6 hours and then rises again at 18 hours and then falls gradually over the next 36 hours. At the 30 minute time point there was a lot of residual drug still in the uterus which was washed with normal saline before snap freezing. We did expect to find a high intensity in the lumen. Interestingly drug was seen in all the layers with a lot of fluorescence in the myometrial layer. With increase in time the concentration in the endometrium fell and the difference in the concentration between the endometrium and the myometrium increased. The unexpected finding was the zenith at the 6 hour time point. Again the concentrations seem to increase at 18 hours and then fall again.

This relative selectivity of the drug to the endometrium has been described with the systemic use of AIS2Pc in the rabbit uterus as well as AIS2Pc in the rat bladder. It has also been described with the use of other photosensitisers like ALA. Suggestions as to why these happen include the increased vascularity and proliferation rates of the glandular endometrium. On a cellular level it is thought that it is because of the high density of reticulo endothelial components found in these cells.

There is some difficulty in explaining why there is a drop in concentration at the 6 hour time point. This may have something to do with dimerisation, ie aggregation of



the phthalocyanine dyes which subsequently reduces the fluorescence efficiency. It is known that only the monomers are fluorescent.

At 6 hours perhaps the phthalocyanine has become partially aggregated in the cells reducing the fluorescence. This also happens in tissue culture at longer incubation times. However at 24 hours the phthalocyanine will be clearing from the uterus (or the aggregates that have monomerised) which reduce the amount of aggregation and hence improve the fluorescence efficiency. Alternatively the phthalocyanine might have recirculated back into the uterus thus increasing the signal. In this case however one would expect to see some blood vessel damage and less selectivity.

#### 5.7.4 Systemic administration of AIS2Pc

##### 5.7.4.1 Concentration of AIS2Pc in the endometrium

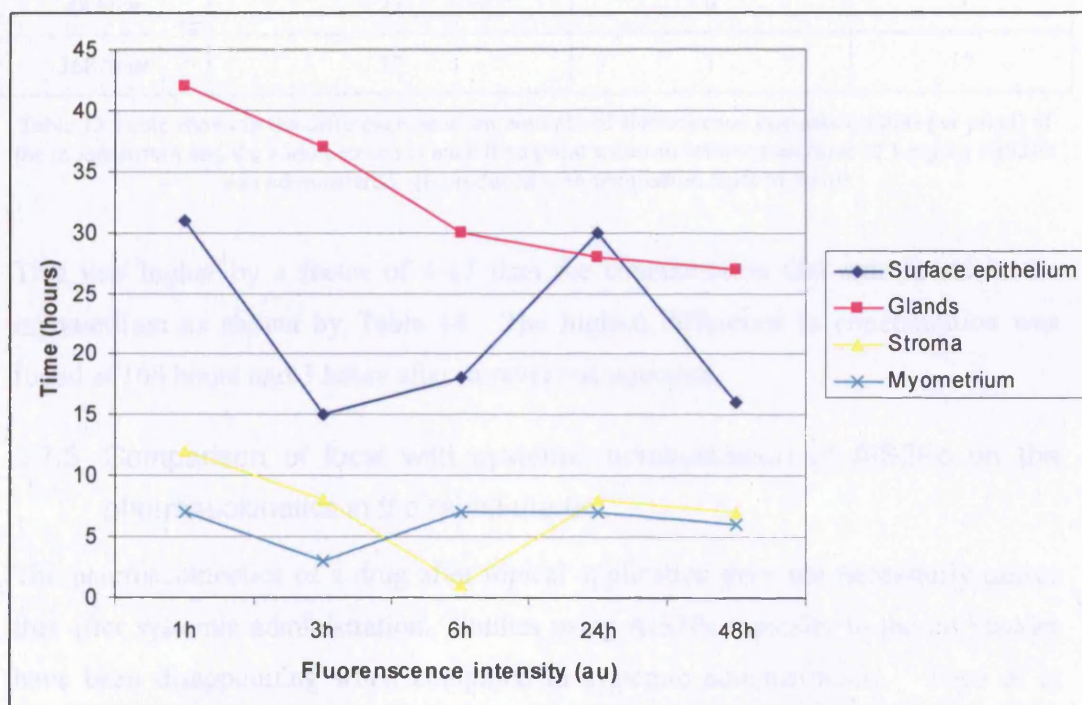


Figure 25 Fluorescence kinetics of the microscopic distribution of AIS2Pc in the normal uterine wall. Each point represents the mean of separate measurements corrected for auto fluorescence. (reproduced by permission from M Judd)

In Judd's work (Judd) following intravenous AIS2Pc the endometrium had two fluorescence peaks at 1 and 24 hours. At 48 hours the endometrium and its glands had twice and four times respectively the background levels of fluorescence and these

values fell slowly. One week after administration there was approximately twice the fluorescence in the glands when compared to the background levels. The fluorescence intensity as a function of time in hours is depicted in Figure 25.

#### 5.7.4.2 Tissue distribution after systemic administration of AIS2Pc

After systemic administration of AIS2Pc, the highest concentration was found in the endometrium (in the epithelium and the glands).

Time	Endometrium	Myometrium	Ratio E/M
1 hour	42	7	6
3 hour	37	3	12
6 hour	30	7	4
24 hour	28	7	4
48 hour	27	6	5
168 hour	17	1	17

Table 15 Table showing the difference between normalised fluorescence intensity (counts per pixel) of the myometrium and the endometrium at each time point when an intravenous dose of 1 mg/kg AIS2Pc was administered. (reproduced with permission from M Judd)

This was higher by a factor of 4-17 than the concentration that was found in the myometrium as shown by Table 14. The highest difference in concentration was found at 168 hours and 3 hours after intravenous injection.

#### 5.7.5 Comparison of local with systemic administration of AIS2Pc on the pharmacokinetics in the rabbit uterus

The pharmacokinetics of a drug after topical application does not necessarily mirror that after systemic administration. Studies using AIS2Pc topically in the rat bladder have been disappointing when compared to systemic administration. Pope et al showed that systemic administration of AIS2Pc was reliable showing a good uptake in the urothelium, four fold selectivity over the muscle layer and rapid clearance from the muscle layer whereas topical intravesical application gave unreliable results.

The methodology employed by Judd for investigation of the pharmacokinetics in the rabbit uterus after systemic administration of AIS2Pc was similar to ours. Direct comparisons of the fluorescence intensities of the tissues between the two experiments

cannot be made as absolute concentrations of the drug cannot be measured using this method. Furthermore the fluorescence intensities depend on the background fluorescence which was different in the two experiments. However, the trends and selectivity of drug distribution may be compared.

The concentrations of AIS2Pc in the glands after topical and systemic administration are shown in Figure 26.

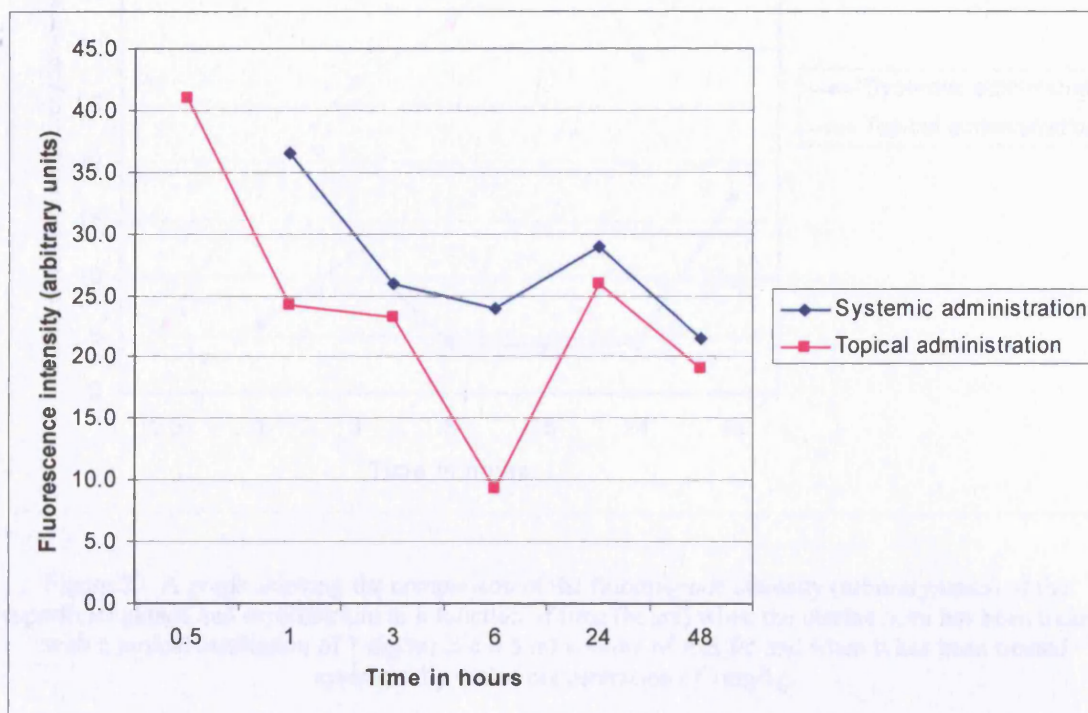


Figure 26 A comparison of the fluorescence intensity (arbitrary units) of the uterine horn as a function of time (hours) when the uterine horn had been treated with a topical instillation of 1 mg/ml in a 0.5 ml volume of AIS<sub>2</sub>Pc and when it has been systemically administered at a concentration of 1 mg/kg

To generate this graph the fluorescent data of the fluorescence intensities of both the superficial and deep endometrial glands have been considered together. This was thought to be clinically applicable as this is the target area for PDT. It is interesting to note that the concentration of AIS2Pc was lowest in both experiments 6 hours after administration. In both, high concentrations were seen at 1 and 3 hours after administration. After systemic administration selectivity of AIS2Pc for the endometrium was high 3 hours after administration whereas with topical application, selectivity continued to increase till 18 hours after administration as shown in Figure 27. The degree of selectivity was higher after topical application. The different

characteristics studied after the two methods of administration are summarised in Table 15.

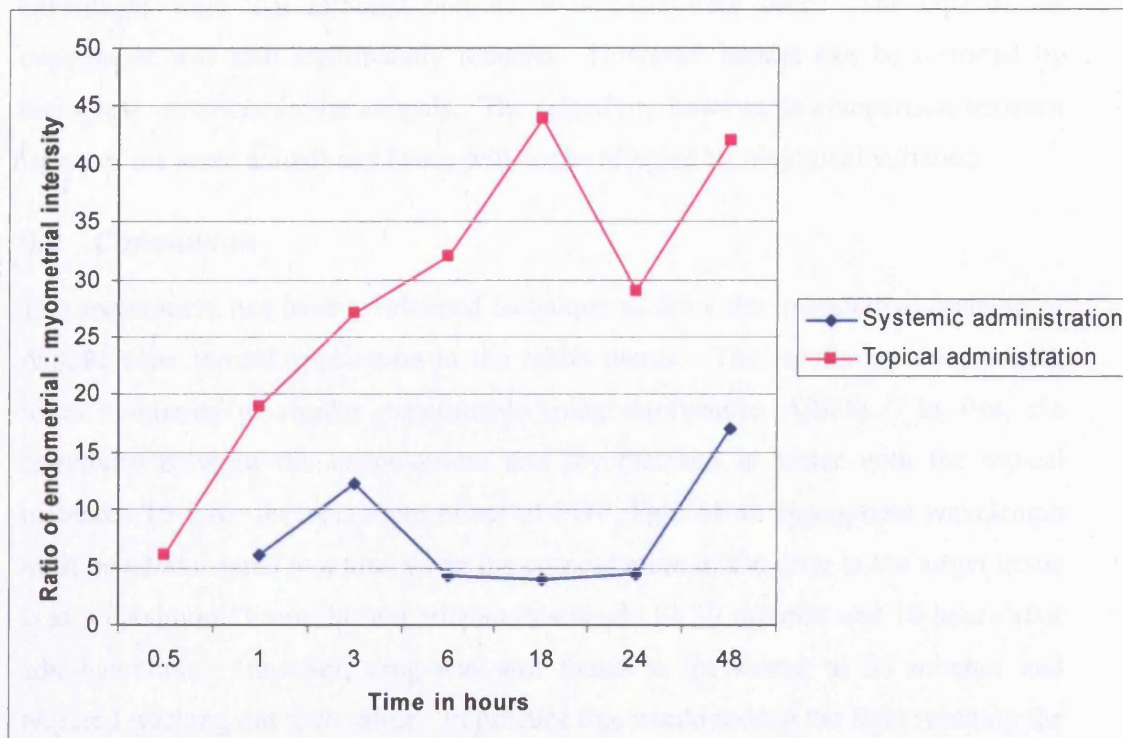


Figure 27 A graph showing the comparison of the fluorescence intensity (arbitrary units) of the superficial glands and myometrium as a function of time (hours) when the uterine horn has been treated with a topical instillation of 1 mg/ml in a 0.5 ml volume of AIS<sub>2</sub>Pc and when it has been treated systemically with a concentration of 1 mg/kg.

	Systemic administration	Topical administration
Route of administration	Marginal vein of the ear	Direct instillation into uterus
Concentration of AIS <sub>2</sub> Pc	1 mg / Kg	1 mg / ml (0.5 ml)
Peak fluorescence intensity	2 peaks at 1 and 24 hours	0.5 and 18 hours
Peak selectivity in endometrium: myometrium	3 hours and 168 hours	18 hours and 48 hours
Degree of selectivity	4-17 times higher in endometrium	6-44 times higher in endometrium

Table 16 A table comparing the distribution and tissue selectivity of AIS<sub>2</sub>Pc in the rabbit uterus after topical and systemic administration.

#### **5.7.5.1 Limitations of this study**

Only one rabbit was used at each time point described in this experiment. The advantages were that minimal number of animals were used. The cost of the experiment was also significantly reduced. However, results can be distorted by biological variations in the animals. The selectivity however is comparison between layers of the same animal and hence will not be affected by biological variation.

#### **5.8 Conclusion**

This experiment has used a validated technique to show the quantitative imaging of AIS2Pc after topical application in the rabbit uterus. The results are encouraging when compared to similar experiments using intravenous AIS2Pc. In fact, the selectivity between the endometrium and myometrium is better with the topical method. To have the maximum effect of PDT, light of an appropriate wavelength must be administered at a time when the concentration of the drug in the target tissue is at a maximum. From this experiment this would be 30 minutes and 18 hours after administration. However, drug was still found in the lumen at 30 minutes and required washing out with saline. In practice this would reduce the light reaching the glandular components of the endometrium. The 18 hour drug light interval is not acceptable for day care treatment which is the aim of this treatment. Drug concentrations remain high at 1 and 3 hours after administration with increasing selectivity. On the basis of these results, we decided to administer light at 1, 3 and 6 hours after topical intrauterine administration of AIS2Pc.

# **[6] Morphological changes in the normal rabbit uterus following PDT with Aluminium Disulphonated Phthalocyanine**

## **6.1 Introduction**

The pharmacokinetics of AIS2Pc in the rabbit uterus after topical instillation of 0.5ml of 1mg/ml solution has been investigated in chapter 5. The experiments show that there is high fluorescence and therefore concentration of AIS2Pc in the glandular component of the rabbit endometrium with some selectivity over the surrounding stroma and the underlying myometrium. The highest fluorescence intensity in the endometrium was seen 30 minutes after instillation of AIS2Pc. This concentration fell at the 1 and 3 hour time points and reached its lowest point 6 hours after instillation

before rising again. There was increasing selectivity however for the glandular component over the stroma and the myometrium with increasing time. Furthermore at 30 minutes there was a significant amount of the drug still present in the rabbit uterine lumen which would interfere with subsequent PDT treatment. It was decided therefore to choose drug light intervals of 1, 3 and 6 hours in performing PDT of the rabbit endometrium after topical instillation of AIS2 Pc

The light dose used when illuminating the target area influences the PDT effect. Problems with this would include a thermal effect with damage to underlying structures if the power is too high. Hence the rate of energy delivery to the target tissue must be known. However in the uterus, thermal damage to the stroma or the myometrium would not have serious consequences when compared to other organs. As described in chapter 2, nearly all the second generation endometrial ablative techniques employ a thermal effect to destroy not only the endometrium but a significant amount of superficial myometrium as well. Disadvantages of significant myometrial damage would be obliteration of the endometrial cavity with problems of haematometra and difficulties in evaluation of the uterine cavity in the event of subsequent abnormal uterine bleeding as discussed in chapter 5. It is important therefore to use an optimal light intensity with a maximal PDT effect with minimal thermal damage to the stroma and the underlying myometrium.

The biggest problem with PDT of the human endometrium is that of endometrial regeneration following destruction. As discussed in chapter 1, this is due to insufficient depth of destruction and difficulty in destroying endometrium in inaccessible sites like the cornua and the isthmus. Studies in the rabbit uterus (see table) have shown that regenerating endometrial cells are present as early as 3 hours after uterine curettage and regeneration completed by 72 hours. Cryosurgery to rabbit endometrium delays the appearance of regenerating cells to 12 hours post treatment with complete regeneration occurring at 21 to 30 days. It is therefore important when studying the PDT effect of AIS2Pc on the rabbit endometrium to examine the endometrium at 21 – 30 days post treatment to evaluate treatment.

## **6.2 Aim of this study**

Three experiments were therefore designed to answer the following questions

- 1) To compare the short term and intermediate term effect of PDT using topical AIS2Pc on the rabbit endometrium using drug light intervals of 1, 3 and 6 hours.
- 2) To compare the PDT effect of topical AIS2Pc when the light intensity is increased from 50 to 100 Joules/ cm<sup>2</sup> .
- 3) To evaluate the long term effect of topical AIS2Pc PDT on rabbit endometrium.

## **6.3 Experiment 1**

**a) To compare the short and intermediate term PDT effect of topical AIS2Pc on rabbit endometrium using drug light intervals of 1, 3 and 6 hours**

**b) To compare the PDT effect of topical AIS2Pc on rabbit endometrium when the light intensity is increased from 50 to 100 Joules/ cm**

**c) To compare the effect of topical AIS2Pc with that in previous work using systemic AIS2Pc**

### **6.3.1 Methods**

#### **6.3.1.1 Photosensitiser**

Aluminium Disulphonated Phthalocyanine (AIS<sub>2</sub>Pc) powder (Prof D Philips, Imperial College London) was dissolved in physiological strength, phosphate-buffered saline (PBS) and administered in a volume of 0.5 ml, the stock solution concentration was 1 mg ml<sup>-1</sup>.

#### **6.3.1.2 Animals**

Normal, female, New Zealand White rabbits (3-4 Kg) supplied by Charles River UK Ltd. (Margate, Kent) were used through out. The pre operative, intraoperative, postoperative care and handling of the animals were the same as described in the methods section of chapter 5.



### 6.3.1.3 Surgical technique

The preparation of the skin of the anterior abdominal wall and operative technique and procedure of injecting 0.5 ml of the ALS2Pc into each rabbit uterine horn and isolating it with a silk ligature was done as described in chapter 5. Abdominal closure was similar with the skin closed using continuous subcutaneous suture using 2-0 vicryl so that there were no knots that the animal could gnaw at post operatively. The animals were recovered from anaesthetic and were kept sedated. A second laparotomy was performed at time intervals of 1, 3 and 6 hours after the instillation of the drug in the uterine horns. The peritoneal closure suture was undone, and the uterus hooked out from behind the bladder and surrounded with moist towels.

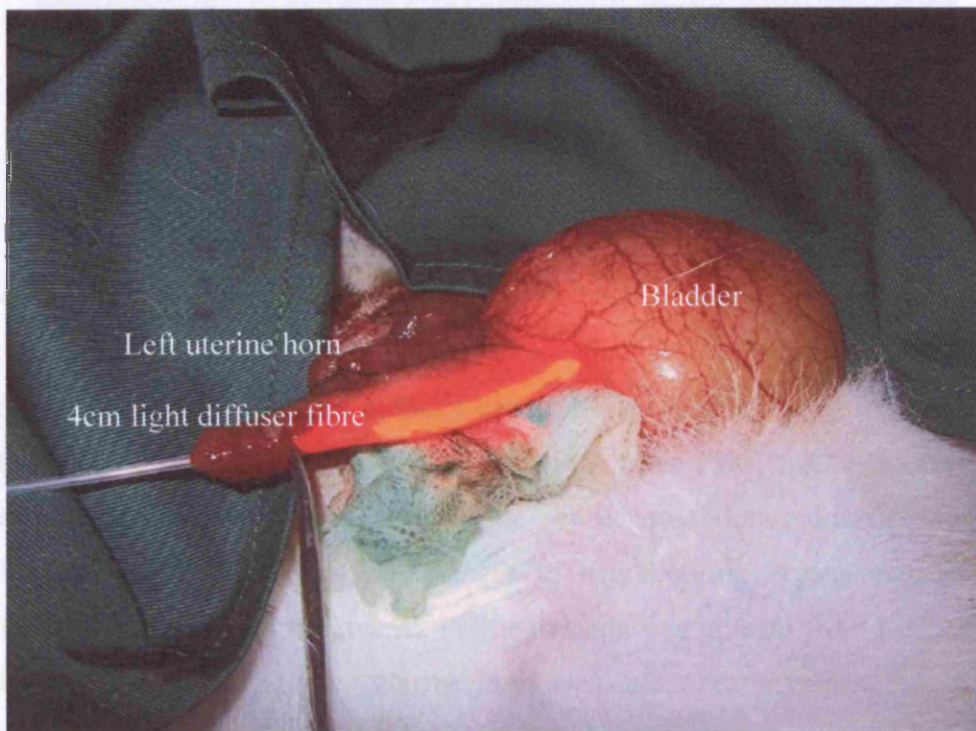


Figure 28 Photograph showing the rabbit uterus exteriorised from the anterior abdominal wall and surrounded by moist towels. The light diffuser fibre has been inserted through a 0.5 cm incision in the anti mesenteric border of the left uterine horn and is activated by light of 670nm wavelength produced by a diode laser at a power of 100 mwatts/cm<sup>2</sup>.

A 0.5 cm incision was made on the anti mesenteric border of the uterine horn 1cm distal to the cervical end. This incision enabled the introduction of a cylindrical fibre with a diameter of 1.6 mm and a 4 cm light diffuser tip. The fibre was placed centrally in the lumen of the uterine horn as shown in Figure 28. A diode laser (see Figure 29) was used to deliver light at a wave length of 670 nm with the power adjusted to deliver 100 mwatts/cm<sup>2</sup> of uterine horn. In the right tube, the light was

delivered for 500 seconds and in the left tube for 1000 seconds making the energy 50 and 100 Joules/ cm<sup>2</sup> respectively.




Figure 29 Figure showing the set up of the diode laser and the light delivery system used for PDT of the rabbit uterus

At the end of the procedure the animals were returned to their cages with no special precautions. The animals were killed 72 hours after PDT. A laparotomy was performed and a detailed examination of the pelvic and abdominal cavity was made for the presence of adhesions or damages to neighbouring organs especially the bladder and the intestine. If external uterine damage was present from PDT this was noted. In the first animal, the uterine horn was laid open to assess macroscopic damage to the endometrium but this did not yield much information and interfered with subsequent histological sections and was not repeated. A minimum of three transverse sections were taken from the proximal, middle and distal thirds of the uterine horns and placed in 4% formol saline solution. Serial 10 µm sections were taken and stained using Harris' haematoxylin and eosin stain. Tissue processing was undertaken at our centre at University College Hospital London.

Nine tissue sections were examined for PDT damage for each uterine horn. Both depth of the damage as well as the proportion of each section that was affected by the PDT damage was noted. In order to compare results with different drug light intervals and different light intensities a grading system was developed.

#### *6.3.1.4 Grading of PDT damage to rabbit endometrium after topical application of AIS<sub>2</sub>Pc*

The extent and depth of damage to the endometrium and the myometrium from PDT was assessed. A grading system was developed to enable easy interpretation and comparison of results. With increasing depth of damage, the endometrium was scored from 0 to 3. Details of the grading of damage and the pictorial representation of this are given below.

Grade 0 was given if there was no evidence of any damage. The endometrium could not be differentiated from the histology of the endometrium from the control rabbit (see Figure 30).

Grade 1 was given if there was some evidence of glandular damage but a significant glandular component was still present (see Figure 31).

Grade 2 was given if most of the glands were destroyed but some remnant glandular structures were seen in the deeper parts of the stroma (see Figure 32 ).

Grade 3 was given if all the glandular components were destroyed and no remnant glands were found on reviewing the section (see Figure 33).

The extent of the damage was also noted. This was represented as a percentage of the section that showed the grade of damage when compared to the entire circumference of the section being examined.

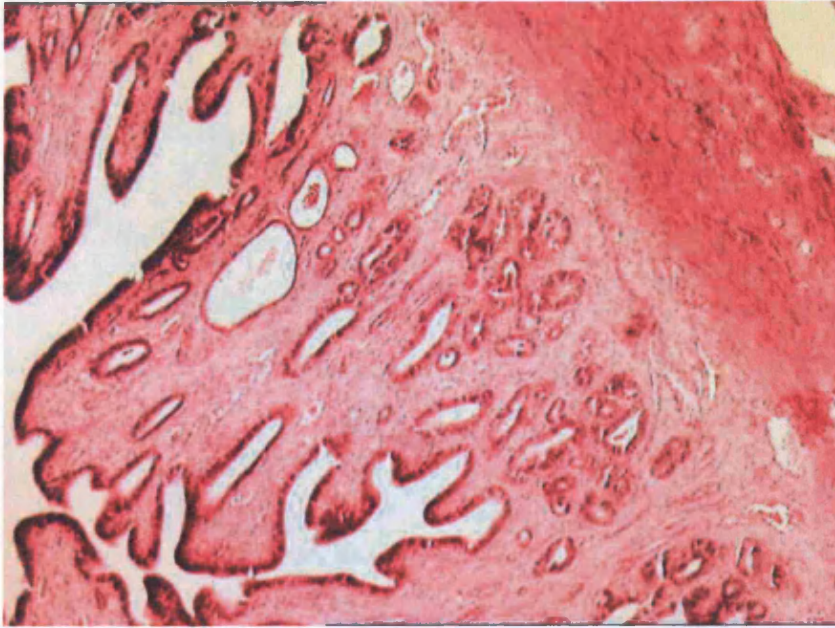


Figure 30 – Grade 0 damage – the glandular architecture of the rabbit endometrium is the same as that of normal histology. There are no signs of PDT damage.

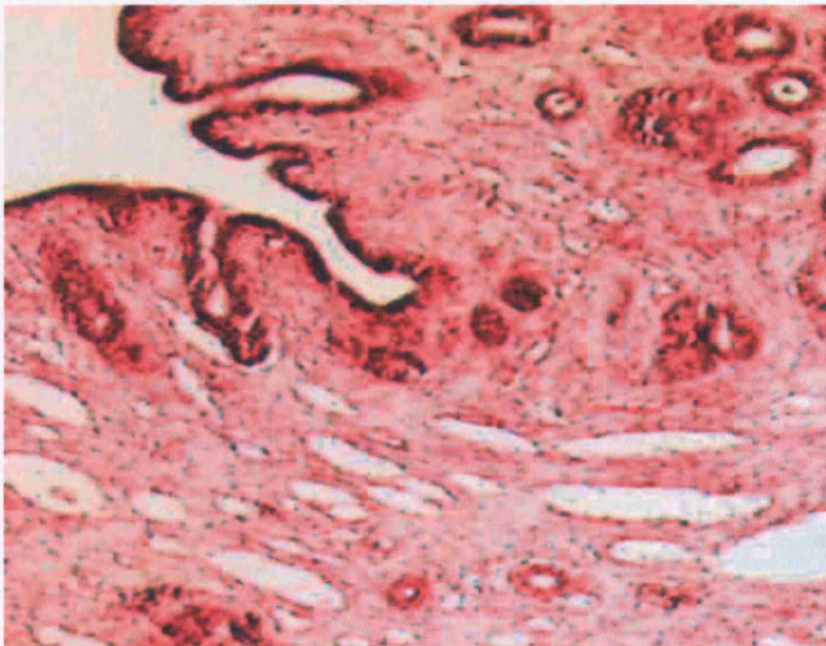


Figure 31 – Grade 1 damage – Many of the glands are destroyed by PDT. However a significant proportion of the deeper glands have not been affected.

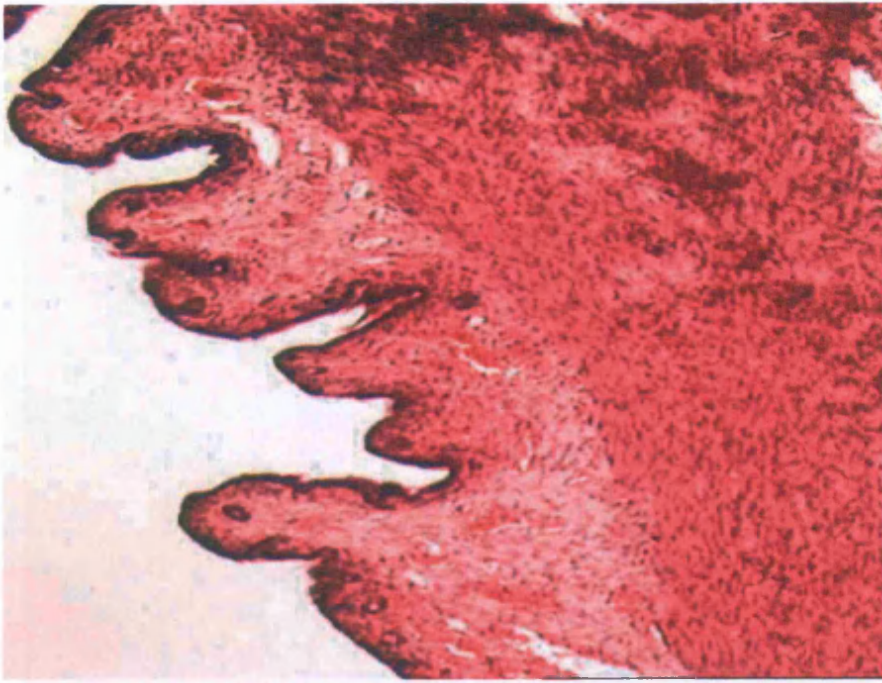

Figure 32 – Grade 2 damage – Most of the glands in the endometrium have been damaged but there are a few scattered glands that have avoided PDT damage.

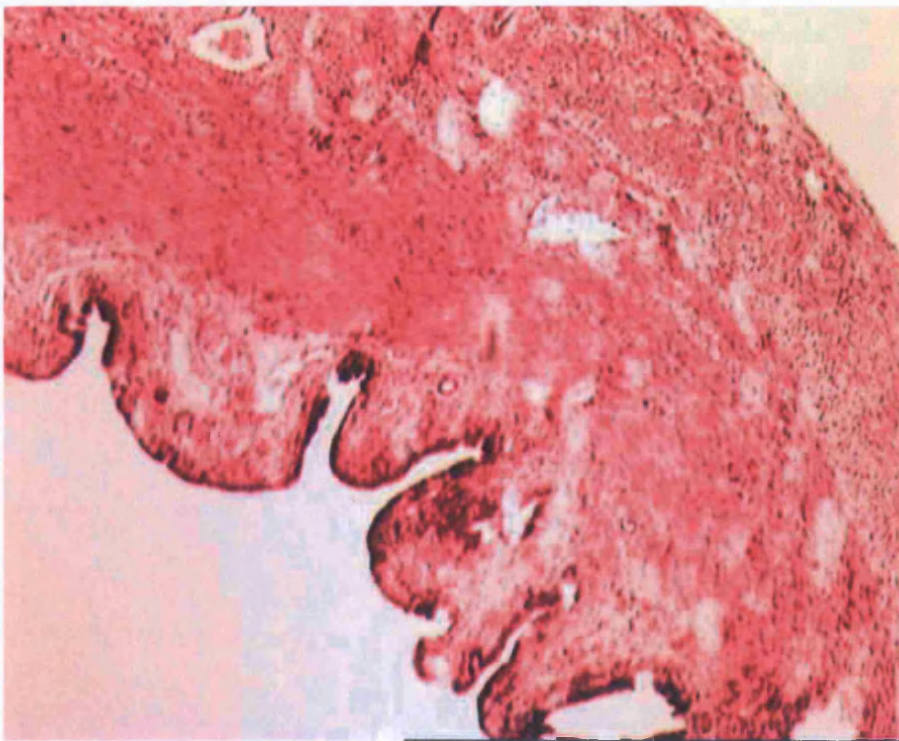


Figure 33 – Grade 3 damage – There is complete PDT destruction of the endometrium with no surviving glands.

6.3.1.5 Grading of PDT damage to rabbit myometrium after topical application of  $AlS_2Pc$

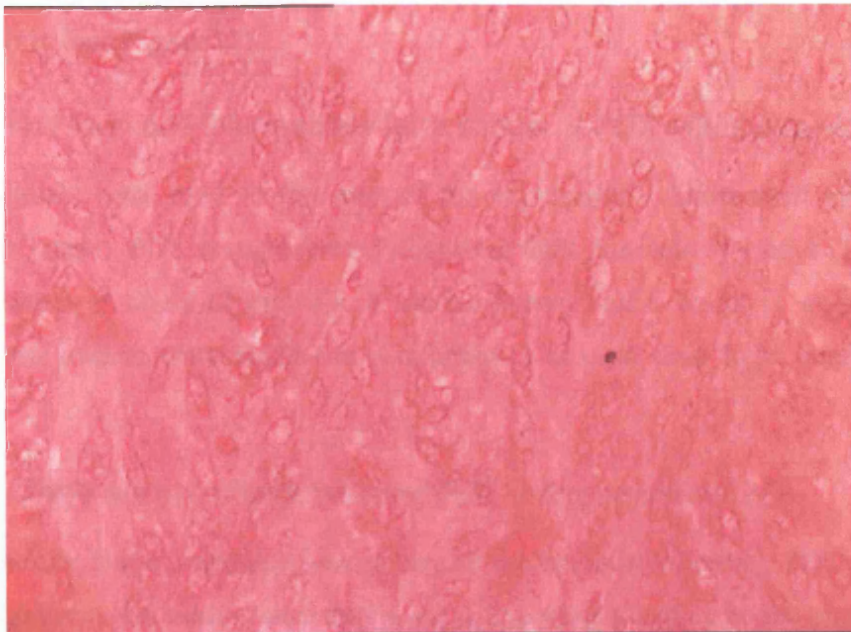


Figure 34 – Grade 0 – untreated myometrium

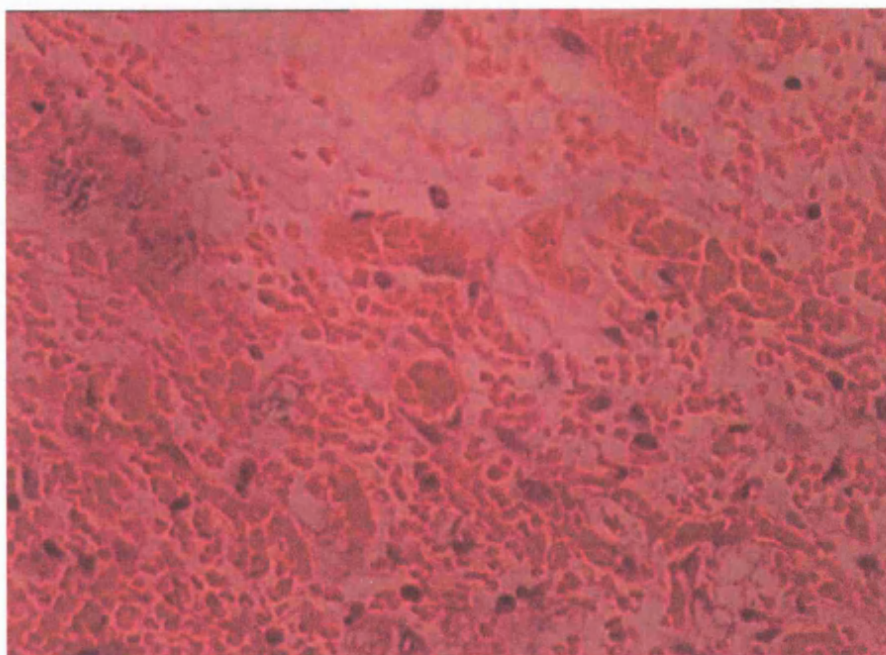


Figure 35 – Grade 1 – Haemorrhage and cellular infiltration of the myometrium

The myometrium hardly shows any histological damage with PDT and hence was given only two grades of damage as described above.

Grade 0 was given if there were no histological changes seen in the myometrium. The section could not be differentiated from the control (see Figure 34).

Grade 1 was given if there were areas of haemorrhage and cellular infiltration of the myometrium (see Figure 35).

### 6.3.2 Short term and intermediate term effects of PDT with topical AIS<sub>2</sub>Pc

Seven animals were used in this part of the experiment. Short term effects were studied at 3 days. PDT was performed with drug light intervals of 1 hour (1 animal; 2 uterine horns), 3 hours (2 animals, 4 uterine horns) and 6 hours (1 animal). The intermediate effects were studied in 3 animals (1 at each drug light interval) at 13 days.

#### 6.3.2.1 *Whole animal effects following PDT using topical AIS<sub>2</sub>Pc*

There were no major complications in any of the animals following PDT treatment. Their behaviour was normal and they were active until sacrifice at the required time intervals. One animal had gaping of the middle part of the wound that required a single mattress suture.

#### 6.3.2.2 *Macroscopic damage caused by PDT using topical AIS<sub>2</sub>Pc*

At laparotomy, three days after PDT, there were no adhesions in the peritoneal cavity. Removal of the uterus, cervix and vagina was technically easy as there was no peritoneal reaction. Inspection of the small intestine, large intestine and bladder did not reveal any congestion, haemorrhages or damage. The serosal surface of the uterine horns was intact with no evidence of any PDT effect. This is shown in Figure 36. The mucosal surface of the treated uterine horn did show some evidence that PDT damage had occurred. There was widespread vascular congestion and some degree of mucosal oedema. However the transverse rugae were maintained and the tissue itself was viable. This was compared to the control uterus where AIS<sub>2</sub>Pc was instilled but no light illumination was conducted. The comparison of both specimens illustrating this is shown in Figure 37.

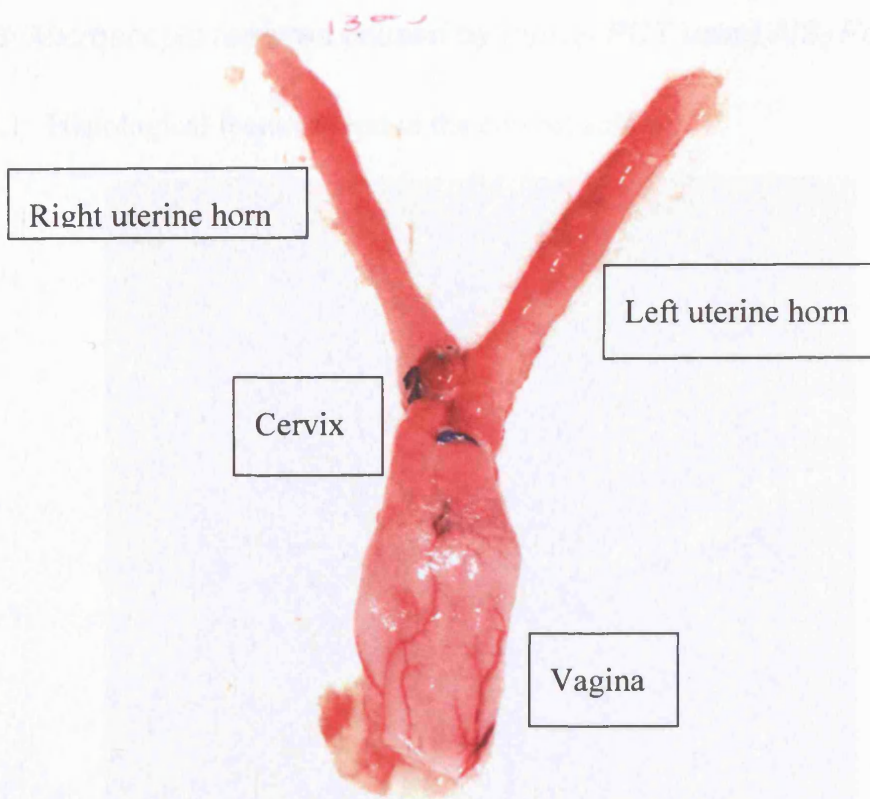


Figure 36 Macroscopic appearance of uterus and vagina 3 days after PDT using 0.5 ml of 1mg/ml of AIS2 Pc with a light dose of 100 Joules/ cm<sup>2</sup> at a drug-light interval of 3 hours (both uterine horns have been treated). No serosal reaction was seen following PDT

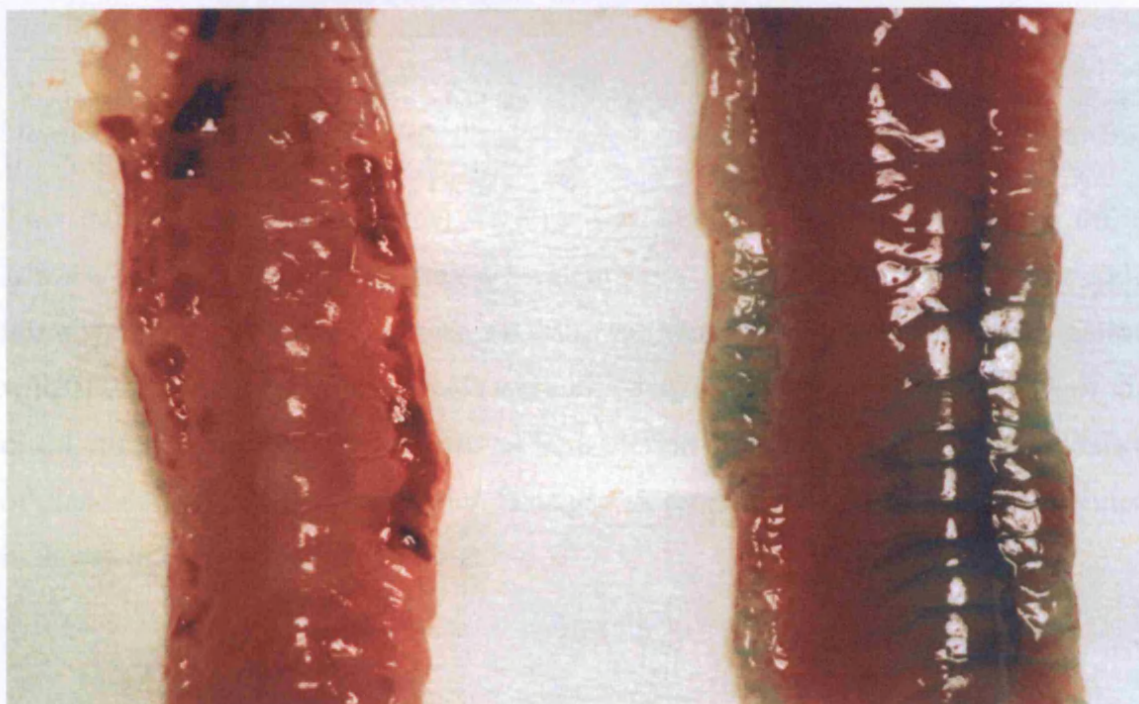


Figure 37 Rabbit uterine horn cut open to show macroscopic appearance of uterine mucosa. Normal mucosal pattern on the left (control) and appearance after PDT using 0.5 ml of 1mg/ml of AIS2 Pc with a light dose of 100 Joules/ cm<sup>2</sup> at a drug-light interval of 3 hours



### 6.3.2.3 Microscopic features caused by topical PDT using AIS<sub>2</sub>Pc at 3 days

#### 6.3.2.3.1 Histological features seen in the control animal

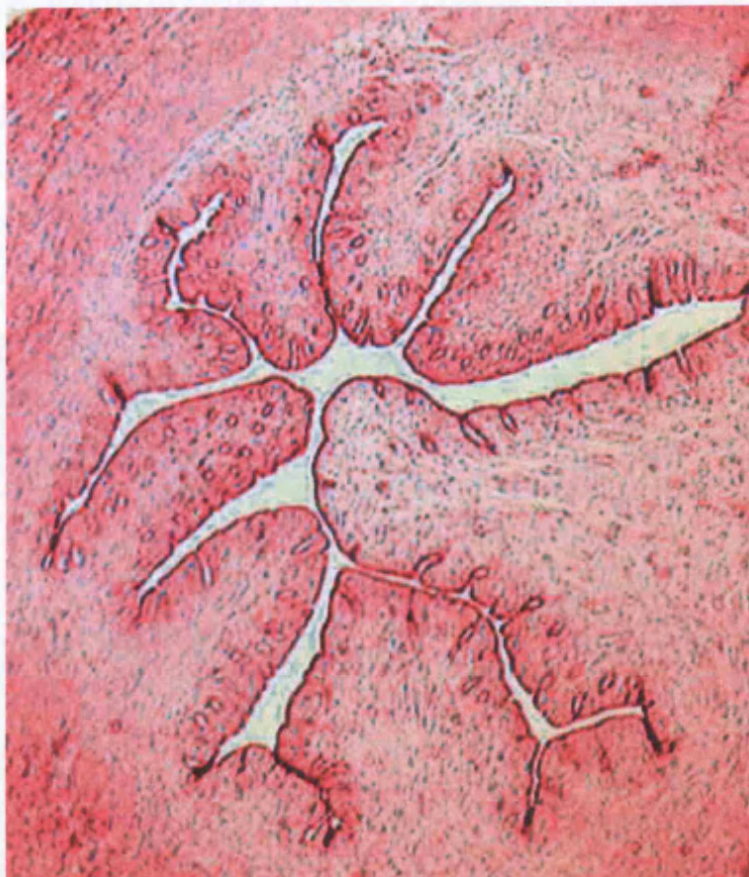


Figure 38 Transverse section of the rabbit uterus on day 3 following topical application of 0.5 ml of 1mg/ml of AIS<sub>2</sub>Pc. There was no light illumination following drug application. (Magnification x10)

Two animals (four uterine horns) were used as controls for PDT. In one, 0.5 ml of AIS<sub>2</sub>Pc at a concentration of 1mg/ml was inserted into each uterine horn. No light illumination was done. In the other, no drug was administered, only light illumination with 100 J was done. The animals were killed at 3 days. Transverse sections of the distal, middle and proximal sections of both uterine horns did not show any evidence of glandular, stromal or myometrial damage. A representative histological specimen is shown in Figure 38.

### Grade of PDT damage at 3 days using a drug light interval of 1 hour

The microscopic features of the transverse section of the rabbit uterus treated by PDT after a drug light interval of 1 hour is shown in Figure 39. A significant amount of the glandular element of the endometrium had been damaged. However there were a few glandular components remaining. The myometrium did not show any damage. Most of the sections examined showed an endometrial damage score of 2 and a myometrial damage score of 0. The architecture of the endometrium however had been maintained.

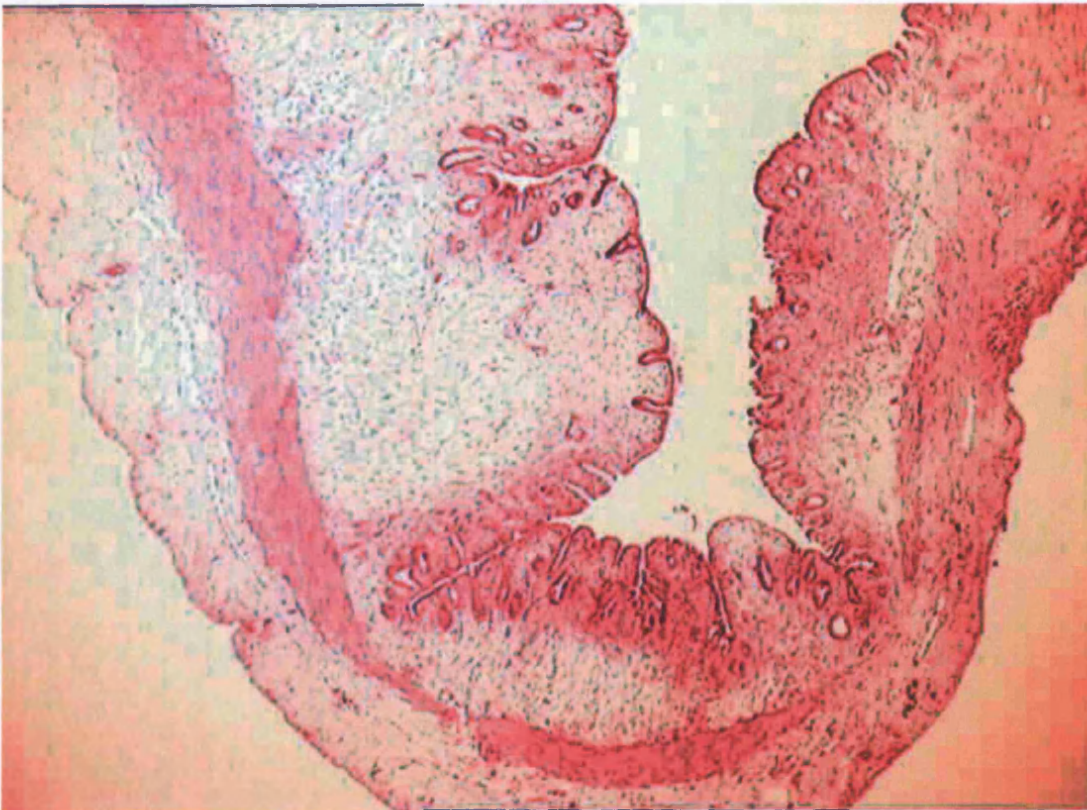

Figure 39 Transverse section of the rabbit uterus on day 3 following PDT using 0.5 ml of 1mg/ml of AIS2Pc with a drug light interval of 1 hour and a light intensity of 50 Joules/ cm<sup>2</sup>. (Magnification x10)

#### 6.3.2.3.2 Grade of PDT damage at 3 days using a drug light interval of 3 hours

The microscopic features of the transverse section of the rabbit uterus treated by PDT after a drug light interval of 3 hours is shown in Figure 40. Here there is a complete absence of all glandular elements in all the sections that were examined. Under high power examination empty lacunae were seen in some of the areas where there had been glands. No glandular epithelium was seen to line these spaces. The myometrium did not show any damage. Most of the sections examined showed an endometrial damage score of 3 and a myometrial damage score of 0. The architecture of the endometrium however was maintained.

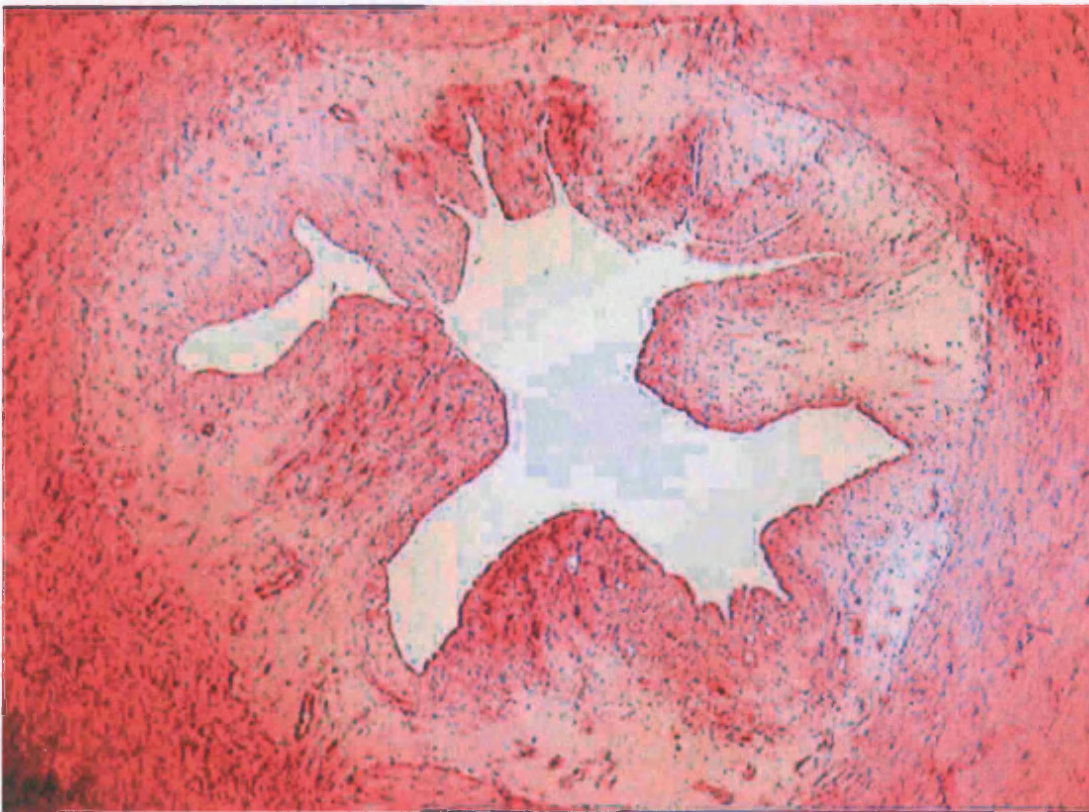


Figure 40 Transverse section of the rabbit uterus on day 3 following PDT using 0.5 ml of 1mg/ml of AIS2Pc with a drug light interval of 3 hours and a light dose of 100 Joules/ cm<sup>2</sup> (magnification x10).

#### 6.3.2.3.3 Grade of PDT damage at 3 days using a drug light interval of 6 hours

The microscopic features of the transverse section of the rabbit uterus treated by PDT after a drug light interval of 6 hours is shown in Figure 39. This representative section showed that the PDT damage to the glandular component was patchy. Examinations of all the sections showed that there were areas of the endometrium that had remained unaltered or showed minimal glandular damage. These areas were scored as 0-1. Again there was no damage to the myometrium in all the sections and these were scored as 0. The architecture was maintained in all the sections.

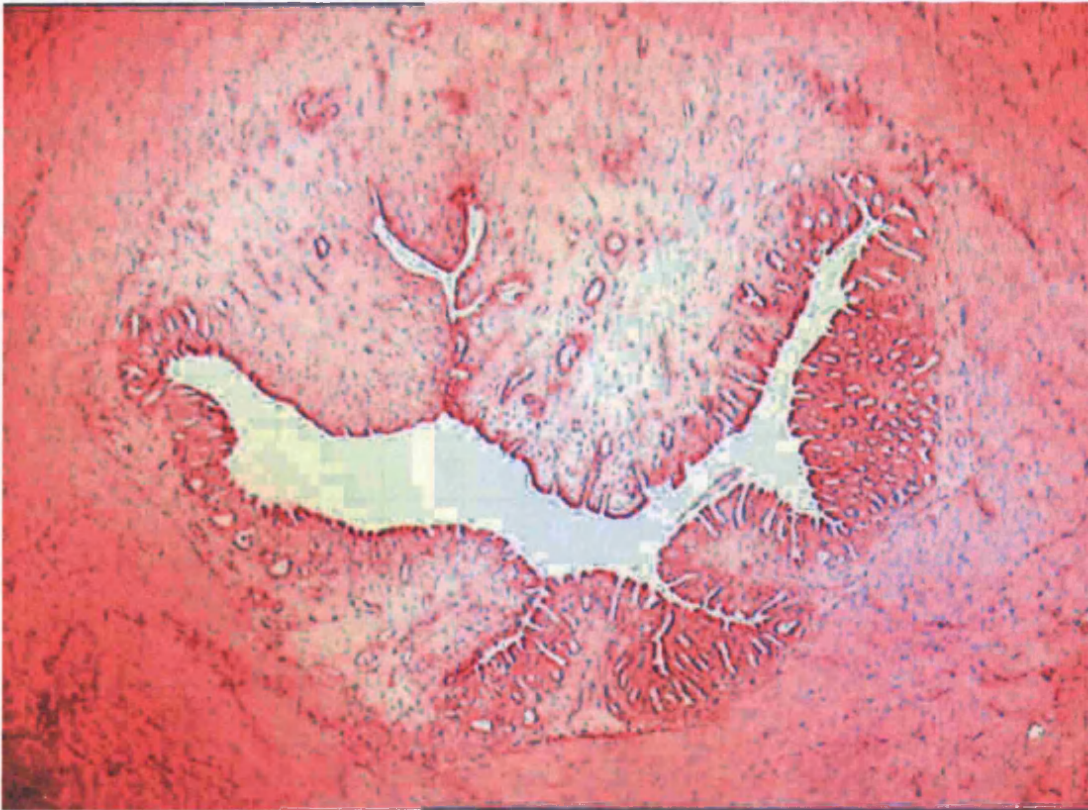

Figure 41 Transverse section of the rabbit uterus on day 3 following PDT using 0.5 ml of 1mg/ml of AIS2Pc with a drug light interval of 6 hours and a light dose of 100 Joules/ cm<sup>2</sup> (magnification x10).

6.3.2.3.4 Extent of PDT damage at 3 days using a drug light interval of 1 hour

Light dose	Site	PDT Damage					
		Endometrium				Myometrium	
		Grade	Extent (%)	Grade	Extent (%)	Grade	Extent (%)
50 J	LD	3	100			0	100
	LD	3	100			0	100
	LD	3	100			0	100
	LM	1	100			0	100
	LM	1	100			0	100
	LM	1	100			0	100
	LP	0	100			0	100
100 J	RD	0	100			0	100
	RD	0	100			0	100
	RD	0	100			0	100
	RM	2	80	0	20	0	100
	RM	2	80	0	20	0	100
	RM	2	80	0	20	0	100
	RP	3	50	0	50	0	100
	RP	3	50	1	50	0	100
	RP	3	50	1	50	0	100

Table 17 Table showing the proportions of the rabbit uterine horn showing the various grades of uterine damage due to PDT. Sections were examined 3 days after PDT treatment using topical instillation of 0.5 ml of 1 mg/ml of AIS2Pc, a drug light interval of 1 hour and a light dose of 50 and 100 Joules/ cm<sup>2</sup>. Three sections were examined from the right distal (RD), right middle (RM) and the right proximal (RP) parts of the uterus. One rabbit with two uterine horns were used at this time point.

6.3.2.3.5 Extent of PDT damage at 3 days using a drug light interval of 3 hours

Light dose	Site	PDT Damage					
		Endometrium				Myometrium	
		Grade	Extent (%)	Grade	Extent (%)	Grade	Extent (%)
50 J	RD	3	40	2	60	0	100
	RD	3	40	2	60	0	100
	RD	3	40	2	60	0	100
	RM	3	95	2	5	0	100
	RM	3	95	2	5	0	100
	RM	3	95	2	5	0	100
	RP	1	40	1	60	0	100
	RP	0	95	1	5	0	100
	RP	0	100			0	100
100 J	LD	3	100			0	100
	LD	3	100			0	100
	LD	3	100			0	100
	LM	3	100			1	100
	LM	3	100			1	100
	LM	3	100			1	100
	LP	3	100			1	100
	LP	3	100			1	100
	LP	3	100			1	100

Table 18 Table showing the proportions of the rabbit uterine horn showing the various grades of uterine damage due to PDT. Sections were examined 3 days after PDT treatment using topical instillation of 0.5 ml of 1mg/ml of AIS2Pc, a drug light interval of 3hours and a light dose of 50 and 100 Joules/ cm<sup>2</sup>. Three sections were examined from the right distal (RD), right middle (RM), right proximal (RP), left distal (LD), left middle (LM) and left proximal parts of the uterus. These represent the averages of the uterine horns from 2 animals.

### 6.3.2.3.6 Extent of PDT damage at 3 days using a drug light interval of 6 hours

Light energy	Site	PDT Damage					
		Endometrium				Myometrium	
		Grade	Extent (%)	Grade	Extent (%)	Grade	Extent (%)
50 J	LD	3	50	1	50	0	100
	LD	3	50	1	50	0	100
	LD	3	50	1	50	0	100
	LM	0	90	1	10	0	100
	LM	0	90	1	10	0	100
	LM	0	90	1	10	0	100
	LP	0	70	3	30	0	100
	LP	0	80	1	20	0	100
	LP	0	80	2	20	0	100
100 J	RD	3	95	1	5	0	100
	RD	3	60	2	40	0	100
	RD	3	60	2	40	0	100
	RM	3	90	1	10	0	100
	RM	3	90	1	10	0	100
	RM	3	90	1	10	0	100
	RP	3	50	1	50	0	100
	RP	3	50	1	50	0	100
	RP	3	50	1	50	0	100

Table 19 Table showing the proportions of the rabbit uterine horn showing the various grades of uterine damage due to PDT. Sections were examined 3 days after PDT treatment using topical instillation of 0.5 ml of 1mg/ml of AlS2Pc, a drug light interval of 6hours and a light dose of 50 and 100 Joules/ cm<sup>2</sup> . Three sections were examined from the right distal (RD), right middle (RM) and the right proximal (RP) parts of the uterus. This data represents both uterine horns from a single animal.

The results show that the extent of PDT damage when the drug light interval is 1 hour is patchy with only a small proportion of the uterus showing features of Grade 3 damage. This is similar when the drug light interval is 6 hours. The best results were obtained with a drug light interval of 3 hours. In these sections, a high proportion of specimens showed Grade 3 damage.

#### 6.3.2.4 Microscopic features caused by PDT using topical $AlS_2Pc$ at 13 days

##### 6.3.2.4.1 Microscopic features at 13 days after $AlS_2Pc$ PDT using a drug light interval of 1 hour

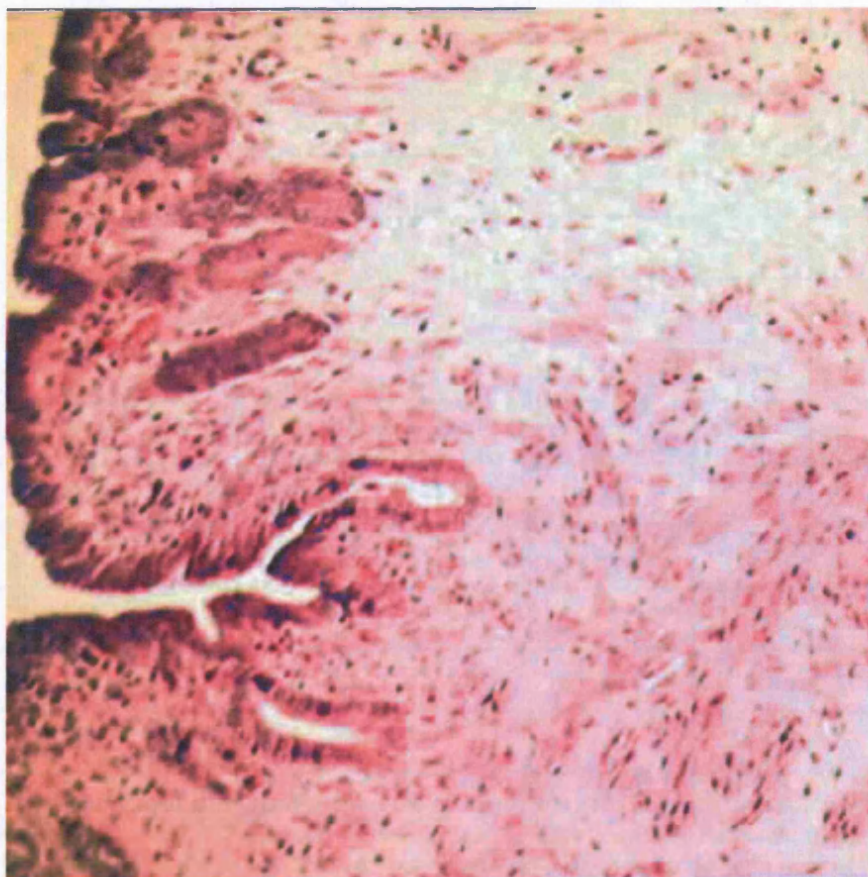


Figure 42 Figure showing endometrial regeneration 13 days after using topical  $AlS_2Pc$  PDT with a drug light interval of 1 hour and a light dose of 100 Joules/  $cm^2$  (Magnification x10)



Light dose	Site	PDT Damage					
		Endometrium				Myometrium	
		Grade	Extent (%)	Grade	Extent (%)	Grade	Extent (%)
50 J	LD	1	100			0	100
	LD	1	100			0	100
	LD	1	100			0	100
	LM	1	40	1	60	0	100
	LM	1	50	1	50	0	100
	LM	1	50	1	50	0	100
	LP	2	40	0	60	0	100
	LP	2	40	1	60	0	100
	LP	2	40	0	60	0	100
100 J	RD	3	85	1	15	0	100
	RD	3	85	1	15	0	100
	RD	3	85	1	15	0	100
	RM	3	85	1	15	0	100
	RM	3	85	1	15	0	100
	RM	3	85	1	15	0	100
	RP	3	100			1	100
	RP	3	95	2	5	1	100
	RP	3	100			1	100

Table 20 Table showing the proportions of the rabbit uterine horn showing the various grades of uterine damage due to PDT. Sections were examined 13 days after PDT treatment using topical instillation of 0.5 ml of 1mg/ml of AlS2Pc, a drug light interval of 1 hour and a light dose of 50 and 100 Joules/ cm<sup>2</sup>. Three sections were examined from the right distal (RD), right middle (RM) and the right proximal (RP) parts of the uterus. These data are from both uterine horns in a single animal.

The glandular components were almost normal at 13 days when a drug light interval of 1 hour was used and a light dose of 50 Joules/ cm<sup>2</sup>. The PDT effect was much better when the light dose was increased to 100 Joules/ cm<sup>2</sup>. Here there was a total absence of glandular components in 85% of the circumference of the specimen see Figure 42. There was no evidence of myometrial fibrosis.

absence of glandular components in 85% of the circumference of the specimen see Figure 42. There was no evidence of myometrial fibrosis.

#### 6.3.2.4.2 Extent of PDT damage at 13 days using a drug light interval of 3 hours

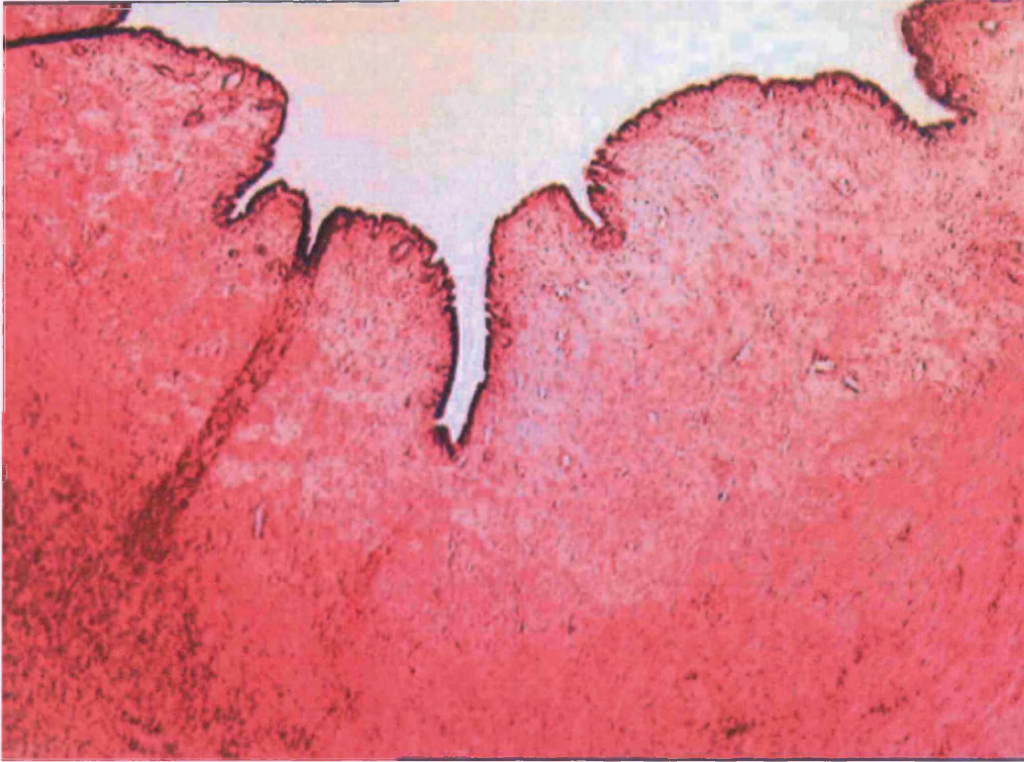


Figure 43 Figure showing endometrial regeneration 13 days after using topical ALS2Pc PDT with a drug light interval of 3 hours and a light dose of 100 Joules/ cm<sup>2</sup> (Magnification x10)

At a drug light interval of 3 hours, at a light dose of 50 Joules/ cm<sup>2</sup>, 40% of the circumference of the sections examined showed Grade 3 damage (see Table 18). The rest of the sections showed Grade 2 damage. There was no evidence of myometrial damage. When the incident light dose was increased to 100 Joules/cm<sup>2</sup> there were no glandular elements seen in any of the sections as illustrated by Figure 43. Grade 1 myometrial damage was seen at this light dose.

Light dose	Site	PDT Damage					
		Endometrium				Myometrium	
		Grade	Extent (%)	Grade	Extent (%)	Grade	Extent (%)
50 J	LD	3	20	2	80	0	100
	LD	3	40	2	60	0	100
	LD	3	20	2	80	0	100
	LM	3	40	2	60	0	100
	LM	3	40	2	60	0	100
	LM	3	40	2	60	0	100
	LP	3	80	2	20	0	100
	LP	3	60	2	40	0	100
	LP	3	40	2	60	0	100
100 J	RD	3	100			0	100
	RD	3	100			0	100
	RD	3	100			0	100
	RM	3	100			0	100
	RM	3	100			0	100
	RM	3	100			0	100
	RP	3	100			0	100
	RP	3	100			0	100
	RP	3	100			0	100

Table 21 Table showing the proportions of the rabbit uterine horn showing the various grades of uterine damage due to PDT. Sections were examined 13 days after PDT treatment using topical instillation of 0.5 ml of 1mg/ml of AIS2Pc, a drug light interval of 3hours and a light dose of 50 and 100 Joules/ cm<sup>2</sup>. Three sections were examined from the right distal (RD), right middle (RM), right proximal (RP), left distal (LD), left middle (LM) and left proximal parts of the uterus. These data are from both uterine horns in a single animal.

#### 6.3.2.4.3 Extent of PDT damage at 13 days using a drug light interval of 6 hours

The histological features that were seen at 13 days after PDT when a drug light interval of 6 hours was used were similar to that seen at 3 days. There were areas of

Grade 3 damage which however were patchy. The other areas did not show any evidence of damage and were scored as Grade 0 damage. This is well illustrated in Figure 44 which shows that the mucosal lining on the left side of the section was devoid of glandular elements whereas the mucosal lining abutting this area is filled with glandular components see Figure 44.

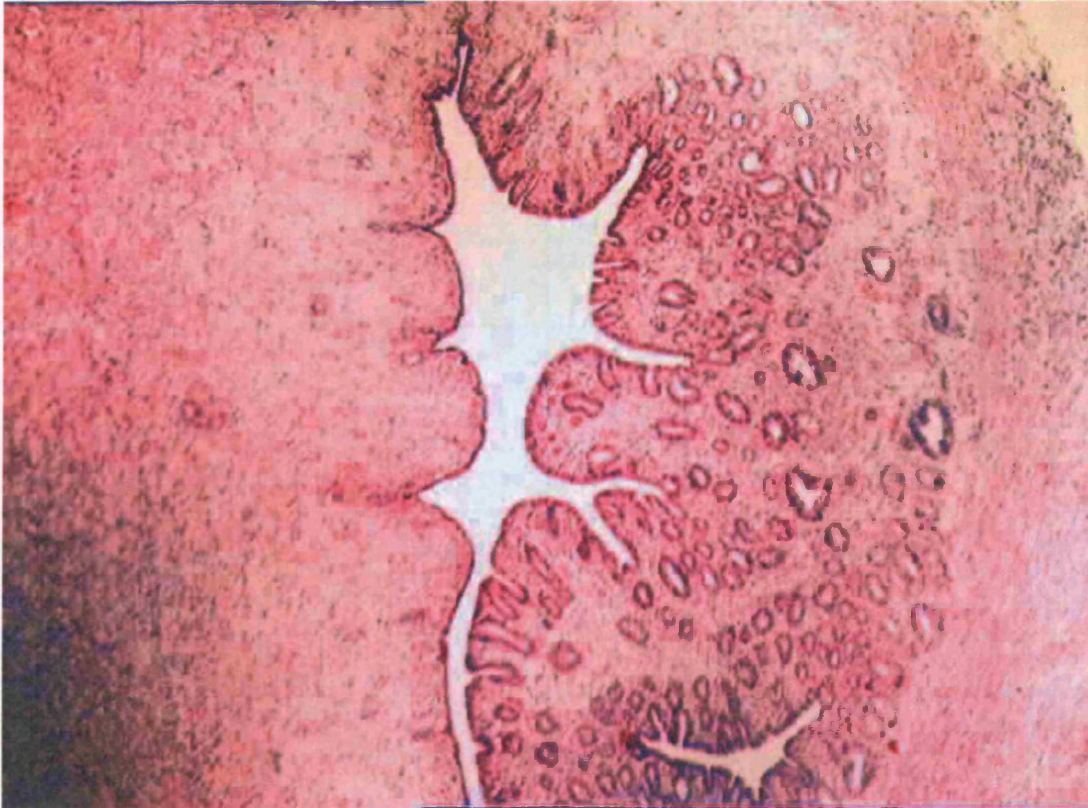


Figure 44 Figure showing endometrial regeneration 13 days after using topical AIS2Pc PDT with a drug light interval of 6 hours and a light dose of 100 Joules/ cm<sup>2</sup> (Magnification x4)

This PDT effect could have been predicted from the fluorescence kinetics of AIS2Pc as described in chapter 5.

Light energy	Site	PDT Damage					
		Endometrium		Myometrium			
		Grade	Extent (%)	Grade	Extent (%)	Grade	Extent (%)
50 J	LD	3	70	1	30	0	100
	LD	3	70	1	30	0	100
	LD	3	70	1	30	0	100
	LM	3	50	1	50	0	100
	LM	3	80	2	20	0	100
	LM	3	80	2	20	0	100
	LP	3	95	1	5	0	100
100 J	RD	3	85	1	15	0	100
	RD	3	85	1	15	0	100
	RD	3	85	1	15	0	100
	RM	3	80	1	20	0	100
	RM	3	50	1	50	0	100
	RM	3	50	1	50	0	100
	RP	3	70	1	30	0	100
	RP	3	60	1	40	0	100
	RP	3	60	1	40	0	100

Table 22 Table showing the proportions of the rabbit uterine horn showing the various grades of uterine damage due to PDT. Sections were examined 13 days after PDT treatment using topical instillation of 0.5 ml of 1mg/ml of AIS2Pc, a drug light interval of 6hours and a light dose of 50 and 100 Joules/ cm<sup>2</sup>. Three sections were examined from the right distal (RD), right middle (RM) and the right proximal (RP) parts of the uterus. These data are from both uterine horns in a single animal.

#### 6.3.2.4.4 Effect of light dose used on the PDT damage to rabbit endometrium

From Figure 45 it can be seen that a light dose of 100 Joules/ cm<sup>2</sup> gave a better PDT effect at all the drug light intervals used. An optimal PDT effect was seen at a drug light interval at 3 hours where the entire circumference of the uterine horn was affected by full thickness PDT damage.

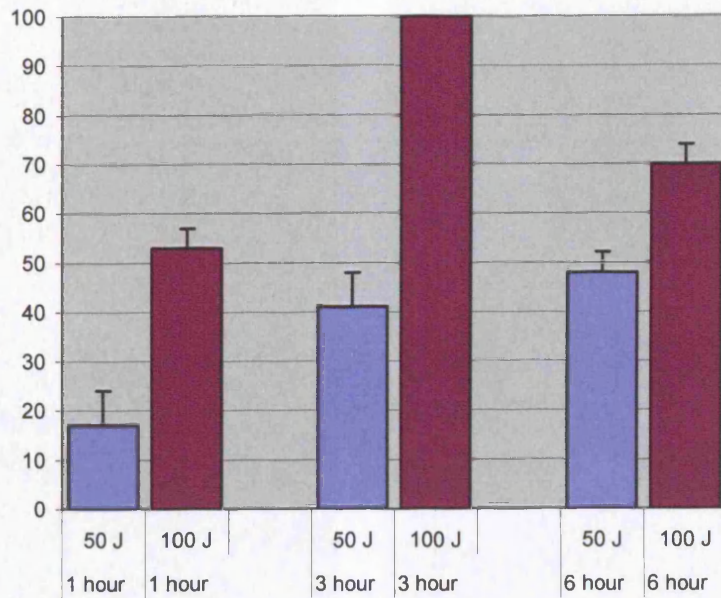


Figure 45 Percentage of uterine horn with grade 3 damage at 3 days with AIS2 Pc PDT with light intensities of 50 J/cm<sup>2</sup> and 100 J/cm<sup>2</sup> at different drug light intervals

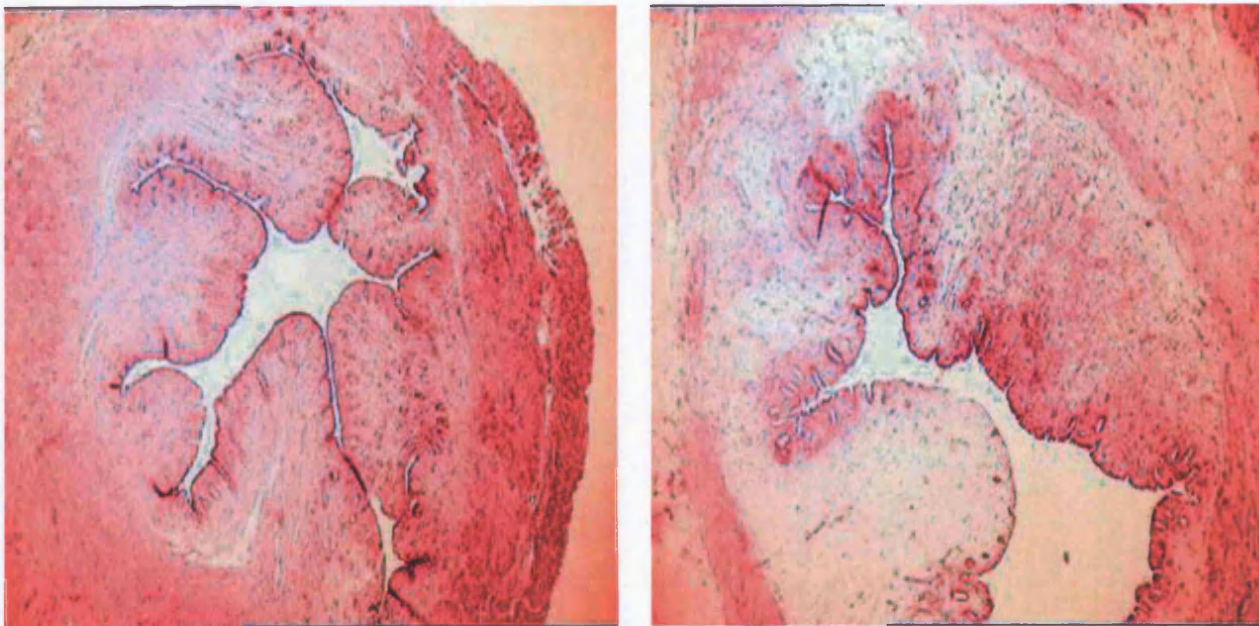


Figure 46 Figure comparing the PDT damage to rabbit endometrium at 3 days using light intensities of 50 J/cm<sup>2</sup> (left) and 100 J/cm<sup>2</sup> (right). Topical application of 0.5 ml of 1mg / ml of AIS2 Pc and a drug light interval of 1 hour were used. (Magnification x4)

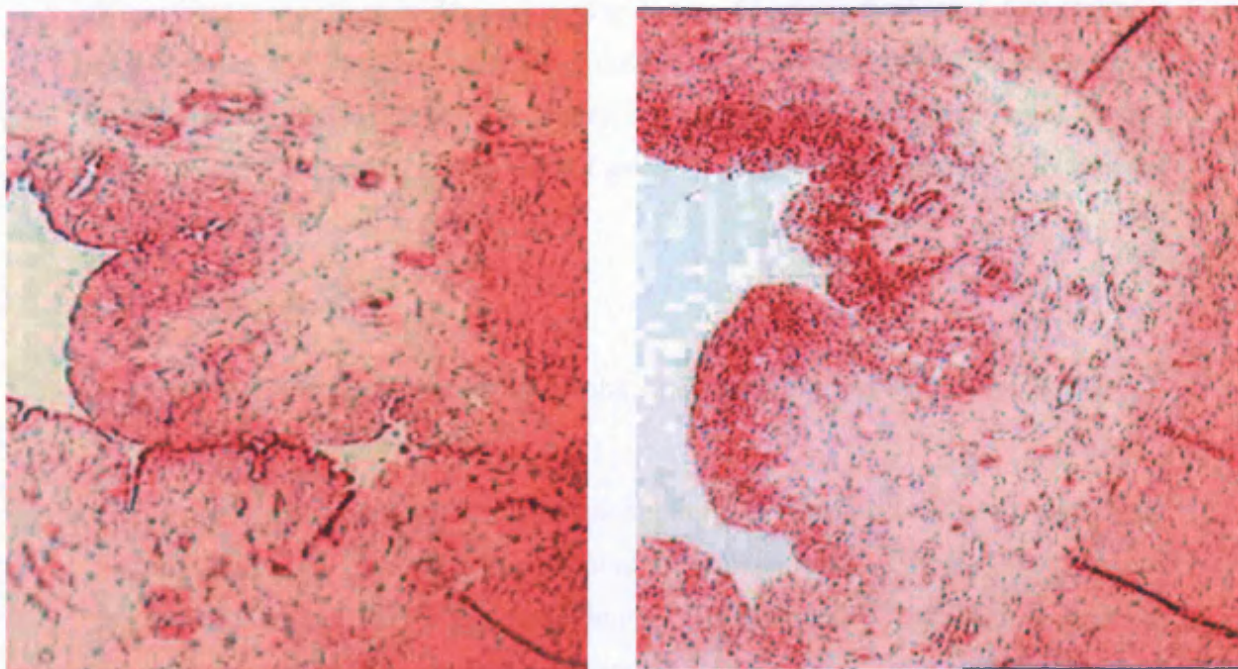


Figure 47 Figure comparing the PDT damage to rabbit endometrium at 3 days using light intensities of 50 Joules/ cm<sup>2</sup> (left) and 100 Joules/ cm<sup>2</sup> (right). Topical application of 0.5 ml of 1mg / ml of AIS2 Pc and a drug light interval of 3 hours were used. (Magnification x4)

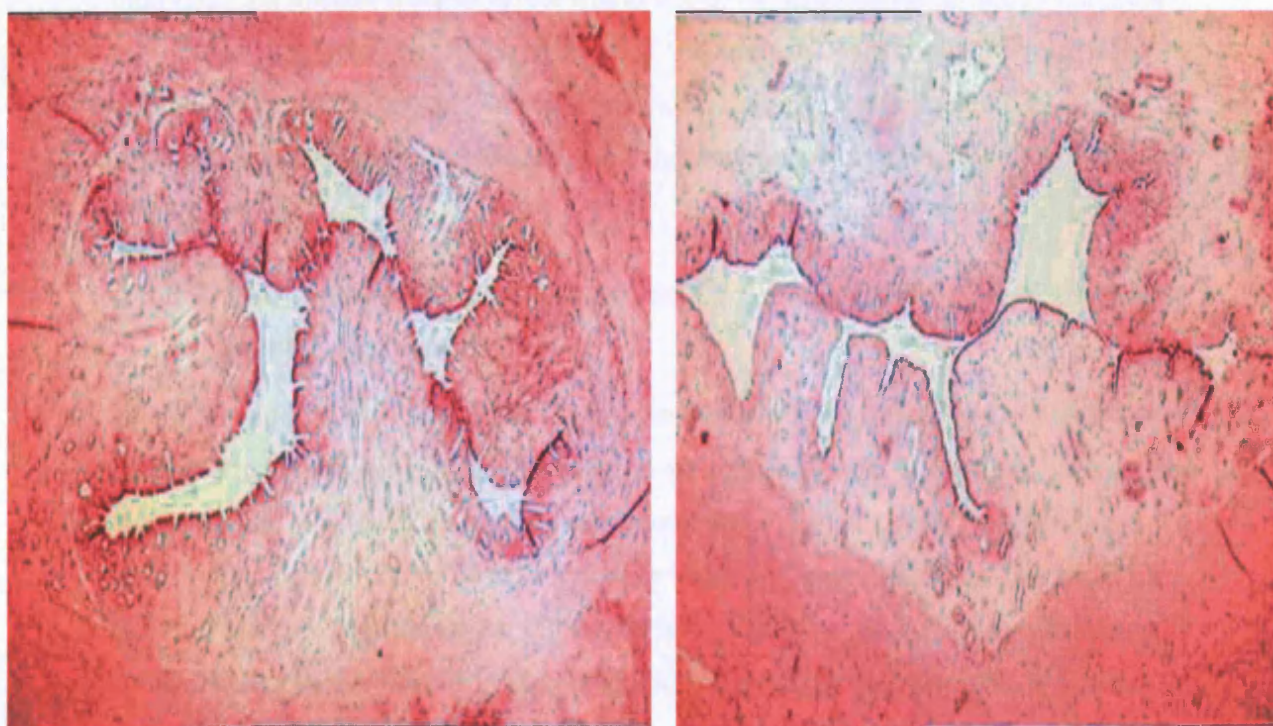


Figure 48 Figure comparing the PDT damage to rabbit endometrium at 3 days using light intensities of 50 Joules/ cm<sup>2</sup> (left) and 100 Joules/ cm<sup>2</sup> (right). Topical application of 0.5 ml of 1mg / ml of AIS2 Pc and a drug light interval of 6 hours were used. (Magnification x4)

These changes are further demonstrated in Figure 48 where there are a few scattered glands in the endometrium when 50 Joules/cm<sup>2</sup> were used compared to the complete destruction of all glands when 100 Joules/ cm<sup>2</sup> of light energy is used. In one section there was a 5% circumferential area of grade 1 myometrial damage which was not seen in any of the other sections.

### 6.3.3 Discussion

#### 6.3.3.1 *PDT damage to normal rabbit endometrium using topical AIS2PC – optimal parameters*

This experiment shows that with topical application of AIS2PC there is significant PDT damage to the glandular component of the endometrium. The drug light interval that showed the best PDT effect was 3 hours. The minimal PDT damage was seen at 6 hours and patchy PDT damage was seen at 1 hour drug light intervals. This was predicted from the pharmacokinetics of AIS2PC after topical application using the fluorescence microscopy method as described in Chapter 5. Increasing the light dose from 50 Joules/ cm<sup>2</sup> to 100 Joules/ cm<sup>2</sup> increased the PDT damage at all drug light intervals. As a small thermal effect would not be of much consequence in the uterus, 100 Joules/ cm<sup>2</sup> would be preferred for PDT treatment. It appears therefore that for an optimal PDT effect in the rabbit uterus after topical application of AIS2Pc, the parameters that should be used are a drug light interval of 3 hours and a light dose of 100 Joules/ cm<sup>2</sup>.

#### 6.3.3.2 *PDT damage of normal rabbit endometrium with systemic administration of AIS2Pc*

Michelle Judd investigated PDT using systemic ALS2Pc. 1mg/kg of AIS2Pc was administered intravenously via the central or marginal vein of the ear. From the results of the fluorescence studies, she chose drug light intervals of 1 hour and 24 hours. The light source used was a copper vapour pumped dye laser (wavelength = 675 nm) which was set to deliver 50 J (100 mW for 500 seconds). The light dose was fractionated into four doses. The light was delivered by a 2cm long cylindrically diffusing fibre with a 2 mm diameter. Two separate sites in each uterus were treated. The animals were killed at time intervals varying from 3 to 13 days. The results showed that PDT damage with a drug light interval of 24 hours was disappointing.



There was no damage to the glandular structures, stroma or the underlying myometrium. This was contrary to what was suggested from the fluorescence studies. The best results were seen with a drug light interval of 1 hour. Here there was full thickness damage of the uterine wall with areas of myometrial necrosis. In this experiment, Judd compared the effect of AIS2Pc with ALA. The difference was that ALA showed a much better selectivity to the endometrial glands with minimal damage to the surrounding stroma or the underlying myometrium.

#### *6.3.3.3 Comparison of systemic with topical administration of AIS2Pc for PDT – short and intermediate effect on normal rabbit endometrium*

Before comparing the results of Judd's work with systemic administration of AIS2Pc with ours, it is important to take into consideration that there were differences in the methodology used in the two experiments. The main differences between the two have been outlined in Table 23.

The PDT effect using topical AIS2Pc is more like that of systemic ALA than that of systemic AIS2Pc. There was a high degree of selectivity towards the endometrial glands when compared to the PDT damage of the endometrial stroma and the myometrium. The maximum insult of the myometrium that was observed histologically was areas of haemorrhage and cellular infiltration in one uterine horn.

This may be explained by the fact that with systemic administration there is a higher concentration of the AIS2Pc in the myometrium and the stroma than after topical application.

Parameter	Michelle Judd's thesis				Present study			
Light delivery								
Laser	Copper vapour pumped dye				Diode			
Wavelength	675 nm				670 nm			
Fibre diameter	2 mm				1.6mm			
Fibre tip length	2 cm				4 cm			
Site of insertion	Transcervically				Transtubal			
Number of lesions / horn	2				1			
Power (mwatts/cm <sup>2</sup> )	100				100			
Treatment time (seconds)	500 for each of 2 sites				1000 & 2000			
Energy/area (J / cm <sup>2</sup> )	50				50 & 100 in each horn			
Photosensitiser (AIS2Pc)								
Route of administration	Intravenously				Topically			
Dose	1mg / kg				1mg / ml			
Volume	Depending on body weight				0.5 ml per horn			
Drug light intervals								
Single lesion	1 and 24 hours				1,3 & 6 hours			
	Time of kill in days				Time of kill in days			
No of NZWR / time point	3	5	7	9	3	5	7	9
1 hour	1	0	2	1	1			
3 hour	Time scale not chosen				2			
6 hour	Time scale not chosen				1			
24 hour	0	1	1	0	Time scale not chosen			

Table 23 Table comparing the methodology in the experiments with topical and systemic administration of AIS2Pc for PDT of the normal rabbit uterus. Parameters compared include light delivery, photosensitiser administration, drug light intervals and time of tissue sampling.

## **6.4 Experiment 2 - To study the long term effect of PDT of the rabbit endometrium after topical application of AIS<sub>2</sub>Pc**

### **6.4.1 Methods of long term effects of PDT with topical AIS<sub>2</sub>Pc**

PDT regeneration in the rabbit uterus after cryosurgery occurs after 25 days. Cryosurgery is aimed at producing the same endometrial damage as PDT. The long term effects of PDT are therefore best studied by reviewing the histological effects at around 28 days.

For this experiment three rabbits (six uterine horns) were used. It was decided to use the optimal PDT parameters after topical application of AIS<sub>2</sub>Pc, namely a drug light interval of 3 hours and a light dose of 100 Joules/ cm<sup>2</sup> for illumination.

A solution of 0.5ml of 1mg/ml of AIS<sub>2</sub>Pc was instilled in to both uterine horns as described in 6.3.1.3. The uterine cavity was exposed to light at a dose of 100 Joules/ cm<sup>2</sup> at a drug light interval of 3 hours. Single treatments were done in all experiments. The animals were recovered as described in the section 5.5.5. The animals were killed at twenty nine days following PDT. Observations, tissue sampling and assessment of tissue damage were done as described in section 6.3.1.4 and 6.3.1.5.

### **6.4.2 Results of long Term effects of topical PDT with AIS<sub>2</sub>Pc**

#### **6.4.2.1 Whole animal effects at 29 days following topical PDT with AIS<sub>2</sub>Pc**

There were no intraoperative or postoperative complications seen in the three rabbits until 29 days. There was no change in their behaviour or eating habits following the treatment. There were no wound complications

#### **6.4.2.2 Macroscopic rabbit uterine changes at 29 days following topical PDT with AIS<sub>2</sub>Pc**

There was no serosal reaction or damage to any surrounding organs when laparotomy was carried out 29 days later. There were no adhesions seen. This is illustrated in Figure 49.

#### 6.4.2.3 Microscopic rabbit uterine changes at 29 days following topical PDT with AIS2Pc

In rabbits 1 and 2, 25% of all the sections that were examined showed that there were no glandular elements persisting. However in the rest of the sections there were a significant number of glandular elements with intact stroma. No myometrial fibrosis was seen in any of the sections. In rabbit 3 however there was significant damage with no glandular elements in 96% of the circumference of the specimen. This effect was consistent in both uterine horns. In these uterine specimens the endometrium was flattened with loss of villi however there was no myometrial fibrosis. These changes are illustrated in Figure 50. The grade and extent of endometrial damage are illustrated in Figure 51.

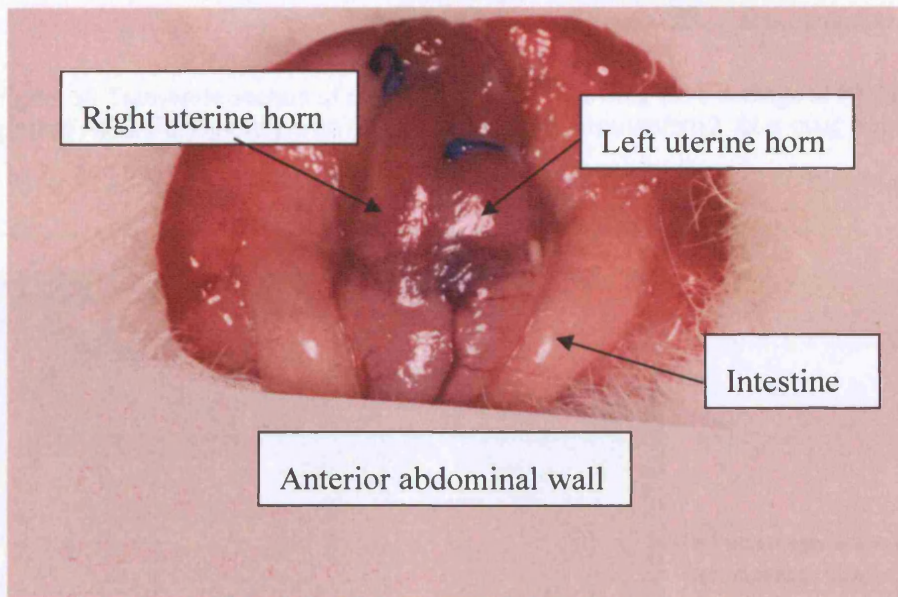


Figure 49 Figure showing the rabbit uterus 29 days after PDT exteriorised from the abdominal cavity. PDT was done using 0.5ml of 1mg/ml of AIS2Pc, a drug light interval of 3 hours and a light dose of 100 Joules/cm<sup>2</sup>. Both uterine horns do not show any serosal reaction and there are no adhesions or damage to the bladder

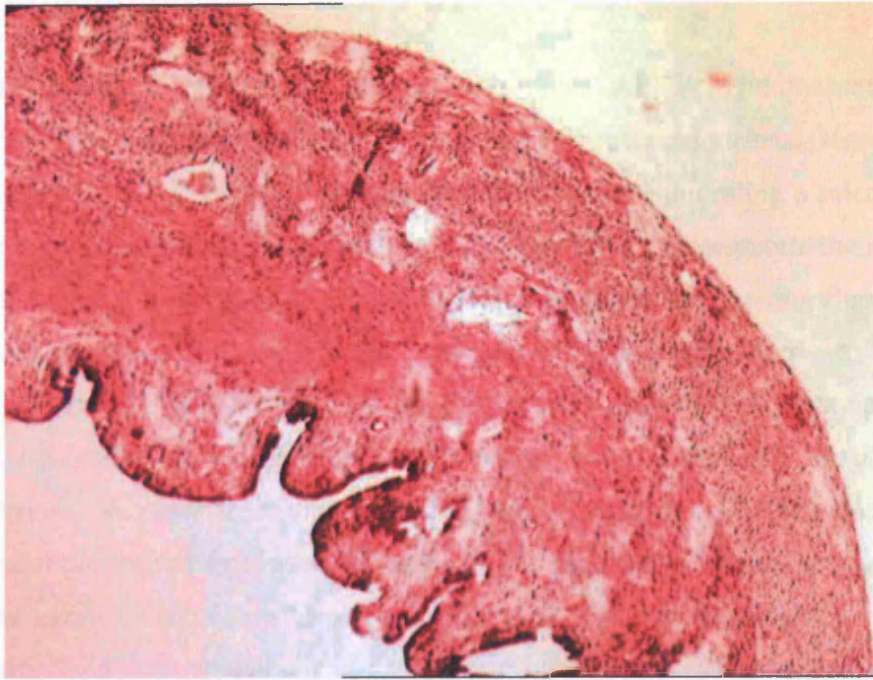

Figure 50 Transverse section of rabbit uterine horn showing PDT damage at 29 days using 0.5 ml of 1mg/ml of AIS2 Pc topically with a light dose of 100 Joules/cm<sup>2</sup> at a drug light interval of 3 hours

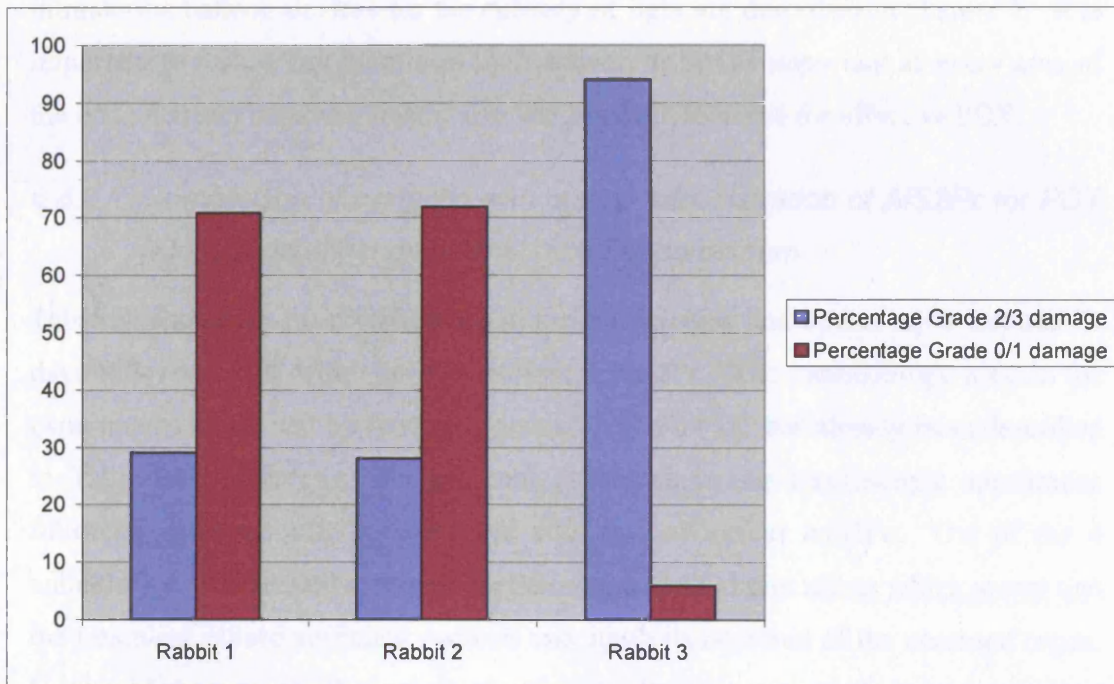


Figure 51 Percentage of uterine horn with grades 0/1 and 2/3 damage at 29 days with AIS2 Pc PDT at a 3 hour drug light interval with light intensities of 100 J

### 6.4.3 Discussion

The PDT damage in rabbit 3 showed that with topical AIS2Pc, endometrial damage can occur to a sufficient depth and extent that prevents endometrial regeneration. Interestingly there was no other damage seen on histology suggesting a selectivity of AIS2Pc in the endometrial glands when applied topically. This supports the results of tissue distribution of the drug in the rabbit uterus when evaluated using fluorescence kinetics as described in Chapter 5. PDT damage in the other four uteri was however patchy. When PDT effects were seen, the damage was significant suggesting that the depth was sufficient to prevent regeneration even from the neighbouring endometrium. In other areas there was complete regeneration. The reasons for this may be that the entire uterus was not treated or that light did not reach the areas where glandular elements were seen to persist. This is an important consideration as when we express light dose we talk about the incident light. What is important is the light dose that strikes the molecule of AIS2Pc which can then get excited to produce the free oxygen radicals and the PDT effect. This reiterates the importance of an efficient intra uterine light delivery system. Experiments designed to evaluate newer intrauterine balloon devices for the delivery of light are described in chapter 7. It is important to realise that a uniform light delivery is not as important as every area of the endometrium receiving light above the threshold required for effective PDT.

#### *6.4.3.1 Comparison of systemic with topical administration of AIS2Pc for PDT – long term effect on normal rabbit endometrium*

Table 24 shows the main differences in the macroscopic and microscopic features 29 days following PDT with systemic vs topical AIS2Pc. The methodology used in the experiments conducted by Judd for systemic AIS2Pc PDT has already been described in Table 23. There was a significant difference in the macroscopic appearance following systemic AIS2Pc compared with that of topical AIS2Pc. Out of the 4 animals that were treated at this time point, one had an absent uterus which meant that the treatment caused sufficient necrosis and autolysis occurred of the necrosed organ. In two of the animals there were significant adhesions seen with only one animal having no serosal reaction. The uterus itself was pale, stenosed and significantly thinned out in two of the animals. In our study, there were no macroscopic changes seen in any of the animals treated.

	Systemic AIS2Pc	Topical AIS2Pc
No of uteri	8	6
Absent uteri	1/8	0/6
Macroscopy	5/7 thinned and distorted	All normal appearance
Villi	Loss of all villi in 5/7	Loss of villi less marked
Absent glands	1/7	2/6
Epithelium	Re epithelialisation 7/7	Re epithelialisation 6/6
Myometrium	Myometrial fibrosis in 7/7	Myometrium intact <i>MT 6/6</i>

Table 24 Table comparing the macroscopic and microscopic features of rabbit endometrium 29 days after PDT treatment with systemic AIS2Pc and topical AIS2Pc

The microscopic assessment of PDT damage to the endometrium was different. Judd comments on the overall impression of the uterus after PDT at 30 days. In our study an attempt was made to make this assessment more objective with the development of a grading system and expressing the proportion of the uterine horn affected as a percentage of the whole section. Nevertheless, she reports loss of villi and few glands in 2/3 rabbits with the third rabbit having normal villi and glands. Our results compare favourably with this. 1/3 rabbits had almost no glands in both uteri. The other 2 rabbits showed no glands in 25% of the sections examined.

It appears therefore that even though the macroscopic effects of systemic PDT suggest a more powerful PDT action than topical application, microscopically the results appear to be similar. This may be explained by the fact that pthalocyanines exert their main phototoxic effect by destruction of a tissue's vascularity rather than by direct cell killing mechanisms. Systemic application would therefore cause massive areas of necrosis due to vascular shutdown. This appears to be more selective with topical application. The hypoxia that may be produced by a vascular effect is maximal within 1 hour of administration but does not seem to affect the PDT damage.

## 6.5 Conclusion

The experiments described in this chapter have demonstrated a range of tissue effects produced by PDT using topical AIS2Pc in the rabbit uterus. The aim is to produce a full thickness necrosis of all endometrial glands. An added advantage would be minimal myometrial damage so that healing with fibrosis and intrauterine adhesions

would not result. It is clear that the optimal drug light interval was 3 hours and that increasing the light dose carried the advantage of causing a more global effect on endometrial damage without significant myometrial damage. The long term results following PDT were encouraging with one animal showing no attempts at endometrial regeneration at 29 days. These results compared favourably with the results obtained by Judd who used systemic ALS2Pc. Her results show a more dramatic macroscopic response with autolysis of a uterus and adhesion formation. The microscopic features however were similar suggesting more selectivity with topical ALS2Pc. It would appear therefore that PDT with topical ALS2Pc for the treatment of women with DUB would be preferable to systemic ALS2Pc as it appears to have the same PDT effect on endometrial glands without causing damage to surrounding structures. Furthermore systemic photosensitisation may be avoided with topical application.

These experiments also show the importance of understanding the pharmacokinetics of ALS2Pc so that the optical parameters may be manipulated to give an optimal PDT effect. Further studies would therefore be required to study the pharmacokinetics of ALS2Pc in the human uterus. This would improve our understanding of this drug and will enable us to maximise its potential for PDT for the treatment of DUB.



# [7] Intrauterine light delivery for photodynamic therapy of the endometrium

## **7.1 Introduction**

The effective delivery of light for photodynamic therapy of the endometrium is challenging. This is because of the wide individual variations in the size and shape of the uterine cavity. Similar problems have been encountered where PDT has been applied to other hollow organs like the oesophagus and the bladder.

Effective light delivery depends on the following factors. 1) The use of light of an appropriate wavelength at which maximum absorption by the photosensitiser used occurs. 2) A uniform distribution of light in the cavity so that all areas of the uterus are illuminated 3) the intensity of light at all sites must be higher than a threshold intensity required for photodynamic therapy.

Photodynamic therapy of the endometrium is being developed as an out patient technique. In order that this is feasible 4) the development of any light delivery device must be of a sufficiently low diameter so that it can be passed through the

cervix with minimal cervical dilatation and hence discomfort. 5) treatment time must not be too long as this would preclude outpatient management. The effect of photodynamic therapy is that oxidative cell death occurs and for this a good tissue perfusion which supplies oxygen to the endometrium must be maintained during treatment. It is important therefore that 6) excessive distension of the uterus is avoided during treatment as this would compress myometrial and endometrial blood vessels and reduce the efficacy of the treatment.

#### An appropriate light source

As discussed in Chapter 3, Lasers are ideally suited for light delivery to the uterine cavity for the following reasons.

- 1) An exact wavelength can be generated depending on the photosensitiser's absorption spectrum
- 2) They can be efficiently coupled to fibre optics thereby reducing the diameter of the device used making it easier to pass through the cervix
- 3) Higher powers may be used reducing the treatment time. The power however must not be high enough to produce a thermal effect.

Diode lasers are becoming increasingly available for clinical use and in addition to being portable are relatively inexpensive compared to conventional laser sources.

#### Light delivery devices

There are commercially available optical light fibres that have shaped and modified ends to create different beam profiles for treatment. The most commonly used fibres for PDT use are the microlens fibres, the cylindrical and spherical shaped fibres. Dwyer et al compared these existing photodynamic therapy delivery devices which have been summarised in the Figure 52. From this it can be seen that cylindrical and cleaved fibres have good efficiency but poor uniform irradiation whereas clear balloons with scattering medium have good uniformity of irradiation but poor efficiency. All the devices listed have the short coming of not being able to delivery light uniformly and efficiently over complex shapes like a uterine cavity. Furthermore as mentioned earlier devices that forces the tissue to assume a different shape may cause vascular compromise and reduce the PDT effect from lack of oxygen.

Delivery device	Uniform irradiation (>70%)		Good efficiency >60%
	Simple surfaces of target	Complex surfaces of target	
Cleaved tipped fibres	No	No	Yes
Microlens fibres	Yes	No	No
Spherical tipped fibres	No	No	Yes
Cylindrically radiating fibres	Yes	No	Yes
Clear balloons with scattering medium	Yes	Yes	No

Figure 52 Comparison of existing photodynamic light delivery device systems (from Dwyer et al)

Fehr et al demonstrated that the insertion of three diffusing fibres in the uterus delivered an optical dose above the photodynamic threshold level even in the most remote areas of the uterus.

More recently however, Dwyer's group reported the use of a soft silicone rubber based balloon which was different from the current commercially made balloons in that it had small chips of Titanium embedded in its wall. Advantages that were quoted are that the softness of the rubber enabled these balloons to be expanded easily to fit complex surfaces like the uterus without distorting or compressing the vasculature. The Titanium chips that were embedded in the wall caused optical scattering compared with the other commercially available balloons.

## 7.2 Aim of the study

- 1) To compare the intrauterine light distribution of the commercially available intra uterine light delivering balloon (Medlight SA) with balloons made as described by Dwyer.
- 2) To compare the intrauterine light distribution of these balloon devices with non balloon devices that can be used for intra uterine light delivery.
- 3) To ascertain the effect of intrauterine pathology on light distribution by these light delivery devices.

### **7.3 Experiment 1 - Comparison of the Medlight balloon with the UCL small balloon, UCL large balloon and the trifurcator device**

#### **7.3.1 Methods**

##### **7.3.1.1 Devices**

###### **7.3.1.1.1 Construction of the UCL small and UCL large balloons using Dwyers technique**

The balloon catheters consisted of two parts. A soft shaped silicone balloon and a flexible nylon tube used for manipulation and inflation of the balloon and to carry the optical fibre.

##### *Construction of a model of the uterine cavity*

A model of the uterine cavity was modelled by hand and smoothed with an abrasive. A cast was then made in plaster of Paris. Molten dental paraffin wax was then poured into the mould. When it was cooling a metal rod was inserted in to the cervical end of the uterine cast as shown in Figure 53.

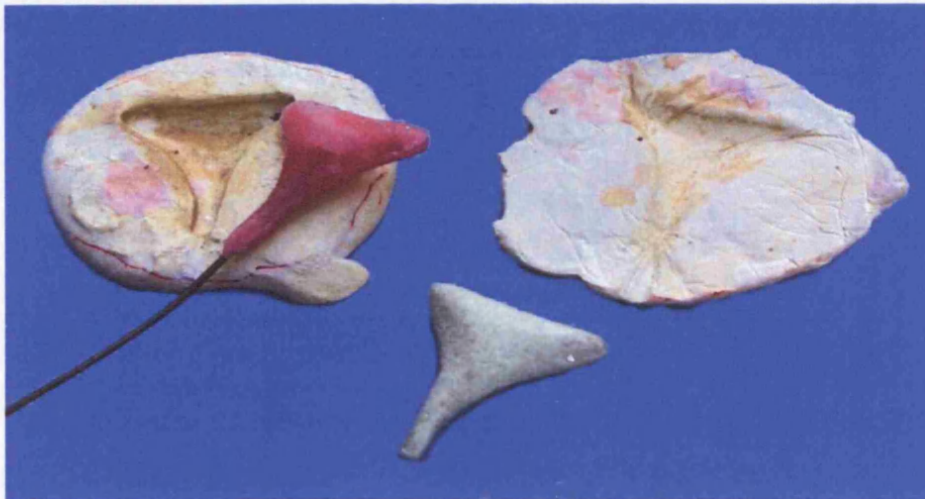

Figure 53 Photograph showing the plaster of Paris mould used for the pouring of the molten paraffin wax and the uterine cavity cast with the metal rod cervical end.

The resulting cast of the uterine cavity was not uniform. It was then decided to obtain a ready made uterine model (Limbs and Things Ltd, Bristol UK). This was bisected. The molten wax could then easily be poured into the cavity of the uterus. Both halves were then kept in place by the use of O bands Figure 54. The model was then kept in

the refrigerator to cool with a metal rod at the cervical end that helped with the subsequent coating of the cast with the silicone mixture.

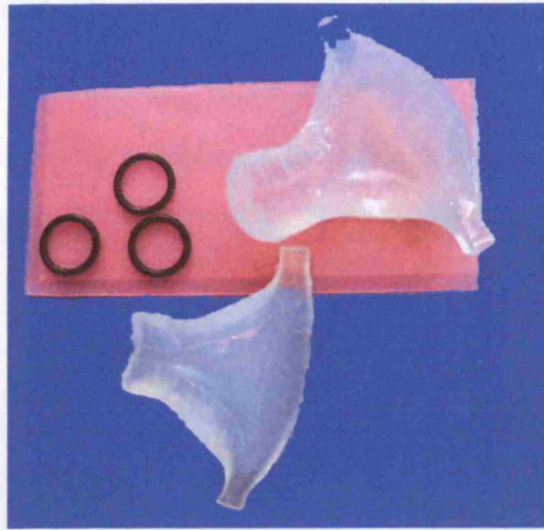


Figure 54 Photograph showing the ready made uterine model which has been bisected. The dental wax which is poured into the uterine cavity when molten is also showed. The uterus is kept together with the O bands.

### Preparation of the silicone mixture

#### Ingredients

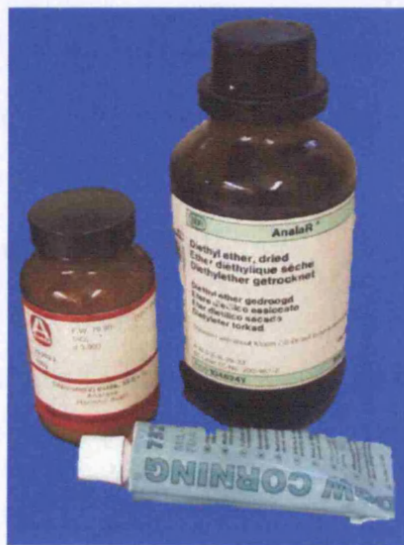


Figure 55 showing ingredients for the making of the silicone mixture

12 ml of translucent medical grade silicone adhesive

1.5 grams Titanium dioxide ( $\text{TiO}_2$ ) powder with 1-3  $\mu\text{m}$  diameter particle sizes

35 ml of ethyl ether anhydrous

The ingredients were mixed together in a 100 ml glass screw topped container. The components were stirred by hand, mixed thoroughly with an ultrasonic dismembranator and then stirred with a magnetic Teflon mixing bar on a stir plate for 8 hours to disperse the TiO<sub>2</sub> particles.

#### **Coating of the uterine cavity model with the silicone mixture**

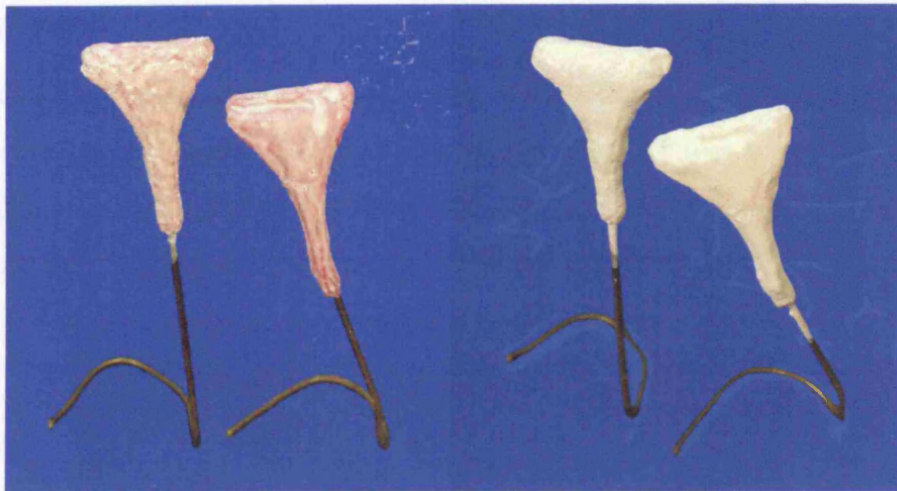

Figure 56 showing the first and third coated uterine models

In a non sparking fume hood a coat of the mixture was applied to the wax form by dipping the model in to the solution allowing the excess to drop off and then place in a rack to cure as show in Figure 56. Each coating was approximately 100µm thick and 3 coatings were used to make the balloon.

Use of the lost wax technique to make the balloon

After curing overnight, the wax models were placed in boiling water to melt the wax and the balloon membrane was then flushed many times to remove the entire wax residue. The balloons were then allowed to dry.

#### **Attachment of the tube to the balloon**

A nylon tube with an outer diameter of 2 mm and an inner diameter of 1mm was fitted with a female Luer lock which attached to a 'Y' shaped port. This channel was used to introduce the light fibre and saline distension medium if required. A two way stop cock was used at the syringe interface to the Y adaptor to allow for the catheter to be purged of air. The distal end of the nylon tube was sealed with a plug of acrylic

epoxy to prevent the optical fibre positioned inside the tube from perforating the balloon.

The end of the nylon tube was rubbed with fine sand paper and attached to the dried balloon. The same silicone mixture was applied to paste the balloon to the smoothed end of the tube.

### **The final product**

Two balloons were made with this technique. A smaller balloon based on a model with a uterine cavity length of 6cms and a larger one that was based on a uterine cavity length of 10cms. For the purposes of identification the small balloon had a green nylon tube attached to it and the larger balloon a red nylon tube.




Figure 57 the inflated small UCL balloon with the green nylon tube attached to it

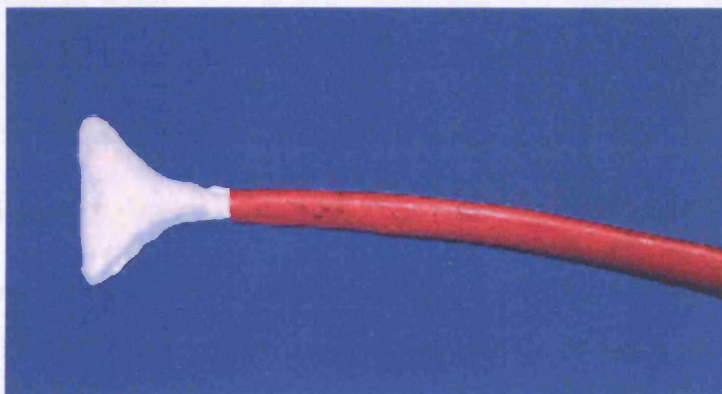


Figure 58 the inflated large UCL balloon with the red nylon tube attached to it

### 7.3.1.1.2 The Medlight S.A. uterus balloon light diffuser model UB

The Medlight SA is a uterus balloon light diffuser which has been developed in collaboration with the Swiss University Hospital of Zurich (Dr P Wyss). This is a commercially available balloon that has been used for PDT of the endometrium in women with menorrhagia.




Figure 59 The Medlight S.A. uterus balloon light diffuser model UB

The balloon is smeared with a gel and then inserted into the introducing tube. The balloon is then inserted into the uterine cavity by means of the introducing tube. The introducing tube is then pulled out leaving the deflated balloon in place. The balloon is then inflated with normal saline using a syringe.

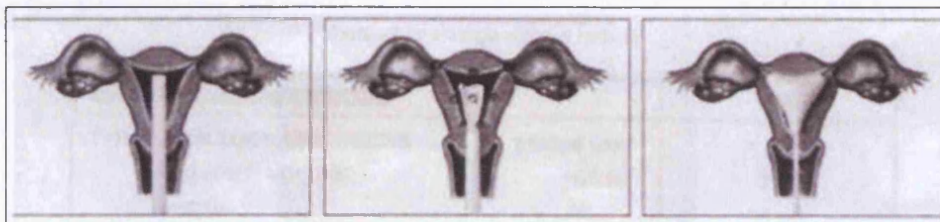


Figure 60 Simulation showing the insertion of the Medlight balloon into the uterine cavity

The optical fibre diffuser is then introduced into the balloon catheter and fixed with the use of a SMA connector. The optical characteristics of this balloon are quoted as a transmission of  $> 70\%$  and a balloon irradiation surface of  $12.4 \text{ cm}^2$ .



### 7.3.1.1.3 The Gynelase system (Trifurcator)

Out of the current second generation endometrial thermal ablation technologies, the Gynelase system utilises lasers as the heat source.




Figure 61 the Trifurcator

This system is manufactured by STORZ (Tuttlingen, Germany) and is composed of a compact tabletop 20W, 830 nm diode laser and a disposable handset. The system can emit laser beams through each of the three channels simultaneously (see Figure 61) and can be manipulated individually on each side by the operator in response to the shape of the uterine cavity. It did not require distension of the uterine cavity for activation of the device. We contacted the company who confirmed that a 645 nm laser may be used and permission was obtained for the system to be modified for light delivery for this experiment.

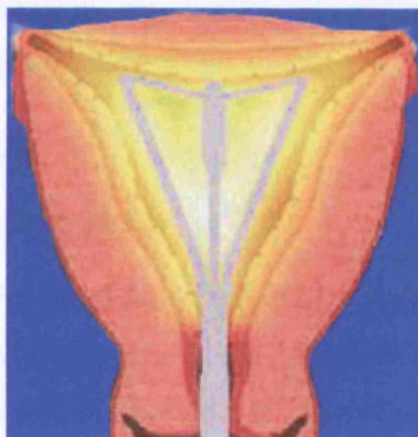


Figure 62 simulation showing the ELITT procedure handset insertion

In practice the operator advances the distal end of the handpiece to the fundus and adjusts the side diffusers forming a butterfly wing contour that conforms to the shape of the uterine cavity as shown in

Figure 62. The laser is then activated.

### *7.3.1.2 Comparison of light devices*

#### *7.3.1.2.1 Uterine specimens*

Women at University College London Hospitals and Harold wood hospital in Romford Essex who were undergoing hysterectomy for DUB not responding to medical treatment were approached. Permission was obtained to use the uterine specimens for the testing of the light devices. It was discussed with the department of pathology with regards the length of time allowed for the specimens to be without formalin. An upper limit of 8 hours was set to avoid severe tissue autolysis and difficult histopathological evaluation. Provision was made to keep the tissues moist with normal saline. As a consequence of this it was decided that experiments would be done on site in specimens from women recruited at Haroldwood Hospital. The laser power used for the experiments were below that required to produce any thermal damage, so no biological changes were expected in the tissue. Once these measurements were completed the uterus was bisected and measured, immersed in formol saline and sent for histological assessment, as was routine practice. This study was approved by the ethics committee of the University College London Hospitals and Barking Havering and Redbridge Hospitals and all patients gave written, informed consent prior to their participation.

#### *7.3.1.2.2 Light measurements*

##### *Preparation of the light detecting fibres*

A 400 micron core optical fibre with an spherical, isotropically diffusing tip (Rare earth medical, USA) was measured and a small piece of tape attached as a “flag” so that, when the fibre was passed down a 18 gauge intravenous cannula (Vygon laboratories France) as far as the flag, the tip of the fibre was flush with the tip of the cannula. The proximal end of the detector fibre was butted against a photodiode which was connected to a trans impedance amplifier. The analogue input was

digitised and read into a computer using AcquiVision (West Sussex, England) software. A series of results were obtained for each experiment.

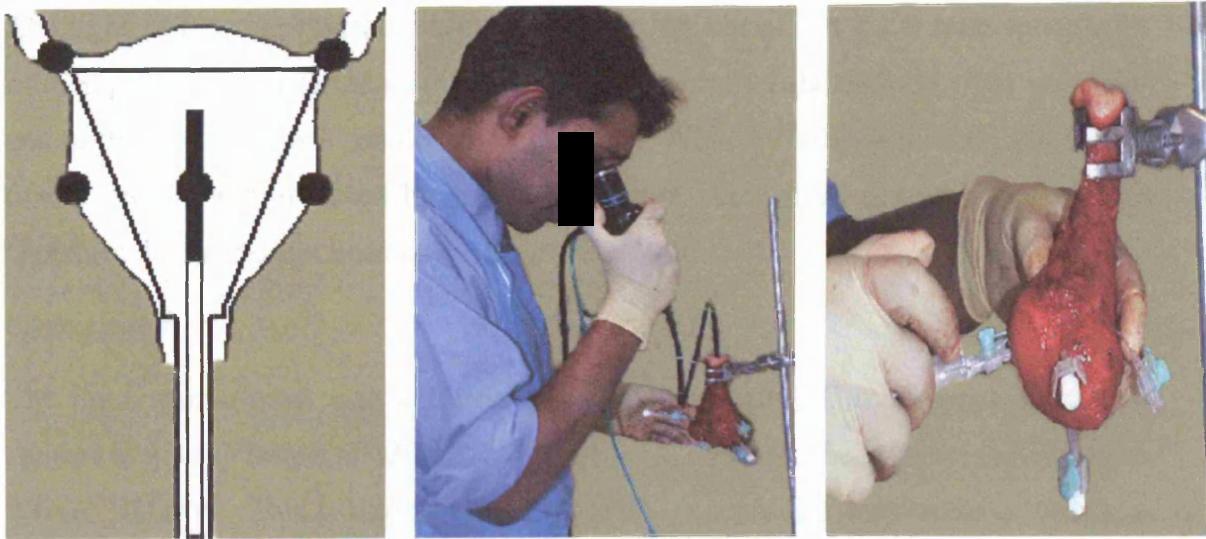


Figure 63 Pictures showing the locations of the spherical isotropically diffusing fibres in the uterus and the hysteroscopic guided placement of the cannulae. The fibres are flagged and passed through the cannulae.

#### Insertion of the intravenous cannulae into the uterus

The uterine specimen was suspended and secured. Five 18 gauge intravenous cannulae were inserted into the endometrial cavity through the serosal surface of the uterus. A 6 mm flexible hysteroscope was passed into the uterus with air as the distending medium. The tips of the cannulae were inserted till they were flush with the endometrial surface. The cannulae were inserted at the following positions. 1) In the middle of the anterior wall of the uterus 2) in the middle of the posterior wall of the uterus 3) the right and 4) left uterine cornua and the 5) cervix as shown in Figure 63. If the cannulae did not fit snugly in the uterine wall – a braided silk suture was used to secure it in position. This ensured that there was no movement of the cannula between measurements.

#### 7.3.1.2.3 Insertion of the light devices

The light devices were inserted after dilatation of the cervix to 6 Hegars. The UCL large balloon device was always tested last as it was then easier to pass and did not interfere with leakage of gas.

#### 7.3.1.2.4 Illumination of light delivery devices

##### Light fibre

The light delivery device was inserted through the cervix. A 2 cm long spherically diffusing fibre was inserted so that it was in the centre of the balloon. The proximal end of the light fibre was connected to the laser. With the balloon devices, distension of the balloon was achieved by a gravity feed of water at a head of 1 metre. The Gynelase device did not need any uterine distension.

##### Laser system

The light source used was a Diode Laser (Diomed Ltd, Cambridge, UK) which emitted at a wave length of 630nm. With the room dimmed, the laser was activated to deliver 100 mW. This is illustrated in Figure 64. Recordings were made of the light levels detected by each of the fiberoptic sensors to build up a picture of the light distribution within the uterus.

A diagrammatic representation of the set up used for the illumination of the test devices and the recording of the light intensity within the uterine cavity is shown in Figure 65.




Figure 64 showing the intrauterine balloon illuminated with the laser light at 635 nm. The light at the endometrial surface at 5 fixed points were measured with each of the devices.

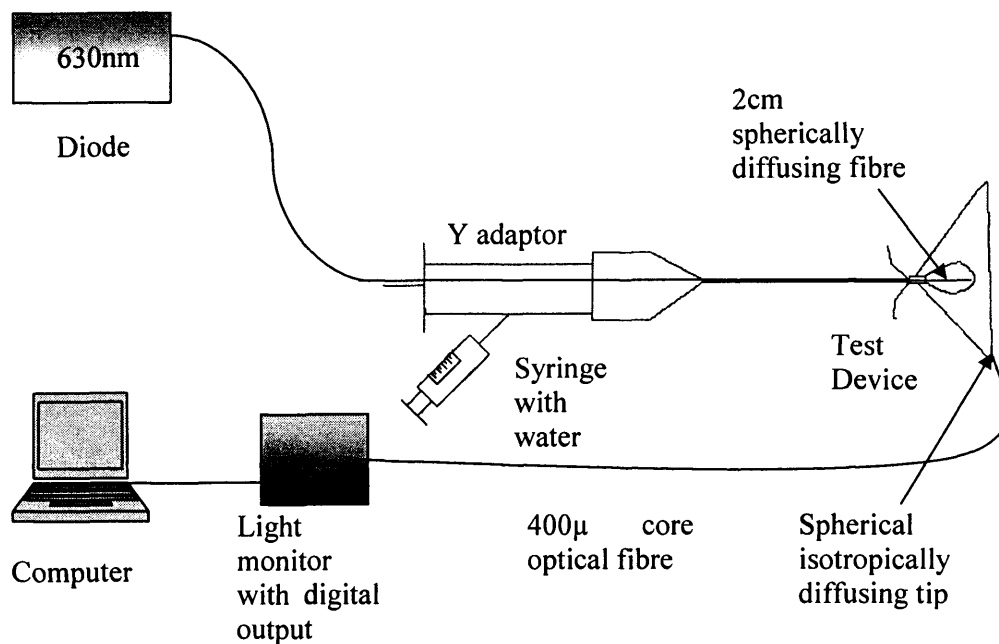


Figure 65 Diagrammatic representation of the set up used for testing intrauterine light illumination of the different devices.

### 7.3.2 Results

Eight uteri were used in experiment one. Hysterectomy was performed in these perimenopausal women for dysfunctional uterine bleeding (DUB) that was not responding to medical therapy. None of them had a previous endometrial ablative procedure done. Dimensions of the seven uteri were of average size and one uterus was mildly enlarged with a cavity length of 10 cms. The uterine specimens were collected from theatre immediately after removal and all experiments were completed within two hours. After the experiment was over the uterine specimens were bisected before placing it in saline. None of the specimens had any intrauterine pathology. Accurate histopathological evaluation of the uterine specimens was possible in all cases as significant autolysis had not occurred. Histology confirmed DUB in all cases. There was reporting of adenomyosis in two cases which was mild.

#### 7.3.2.1 Comparison of the uniformity of intra uterine light distribution

The light distribution in the uterine positions with each device is shown in Figure 66. There is poor illumination of the cornual regions with all the balloon devices. The

UCL small balloon however was better than the commercially used Medlight balloon in that 14% of the light was in the cornual region compared with only 8%.

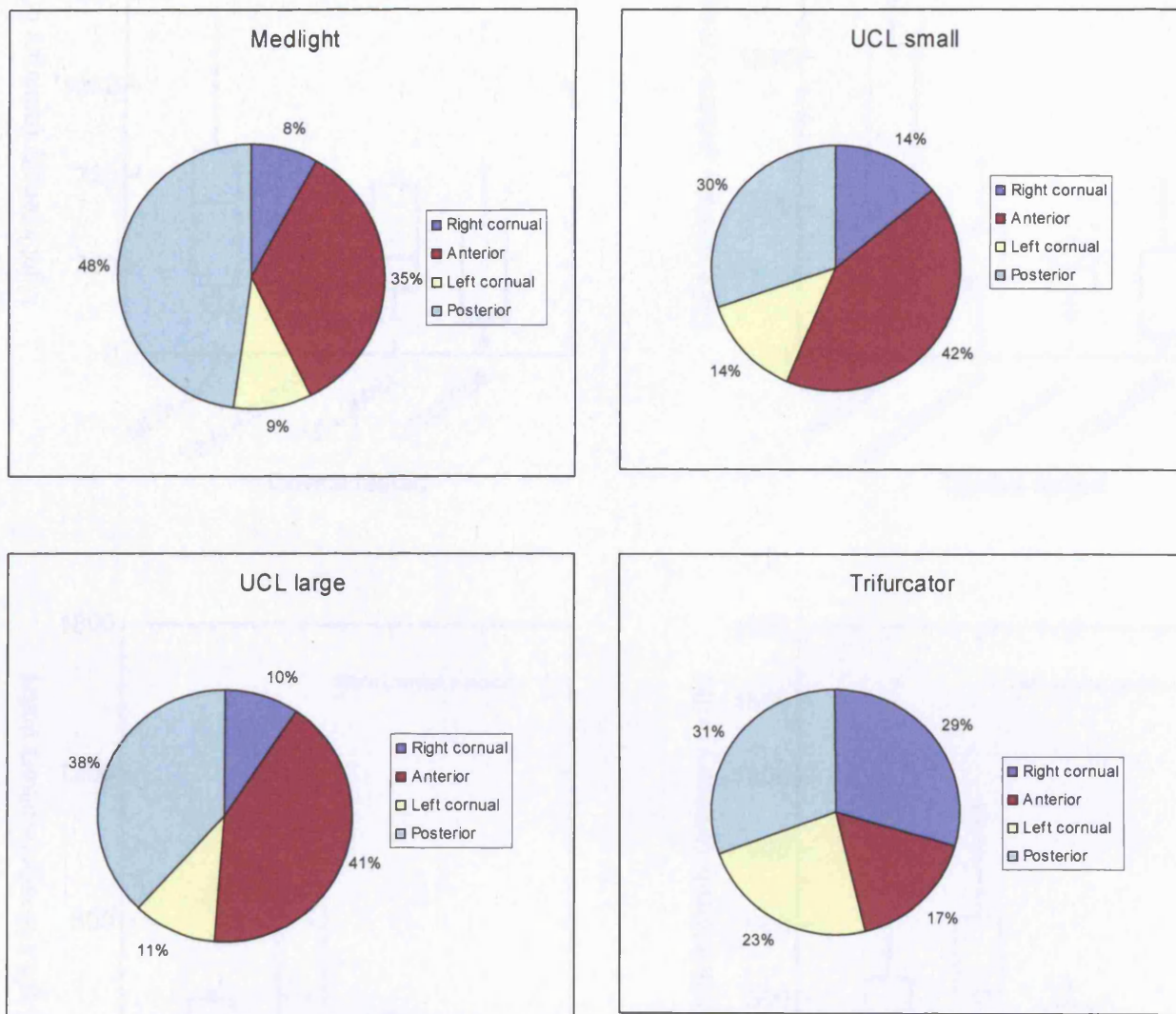


Figure 66 showing the mean light distribution in the anterior, posterior, right and left cornual positions of the uterus with the Medlight balloon, UCL small balloon, UCL large balloon and the trifurcator device.

The UCL large balloon did not show a difference from the Medlight balloon. The trifurcator however showed the most uniform distribution of light. However the anterior wall of the uterus only received 17% of the light. This may be explained by the shape of the device. The side arms project well into the cornual ends whereas the middle arm is shorter and in an anteverted uterus more illumination will occur in the posterior wall which is more in line with the axis of the cervical canal.

### 7.3.2.2 Comparison of the intrauterine light intensity of the uterine devices

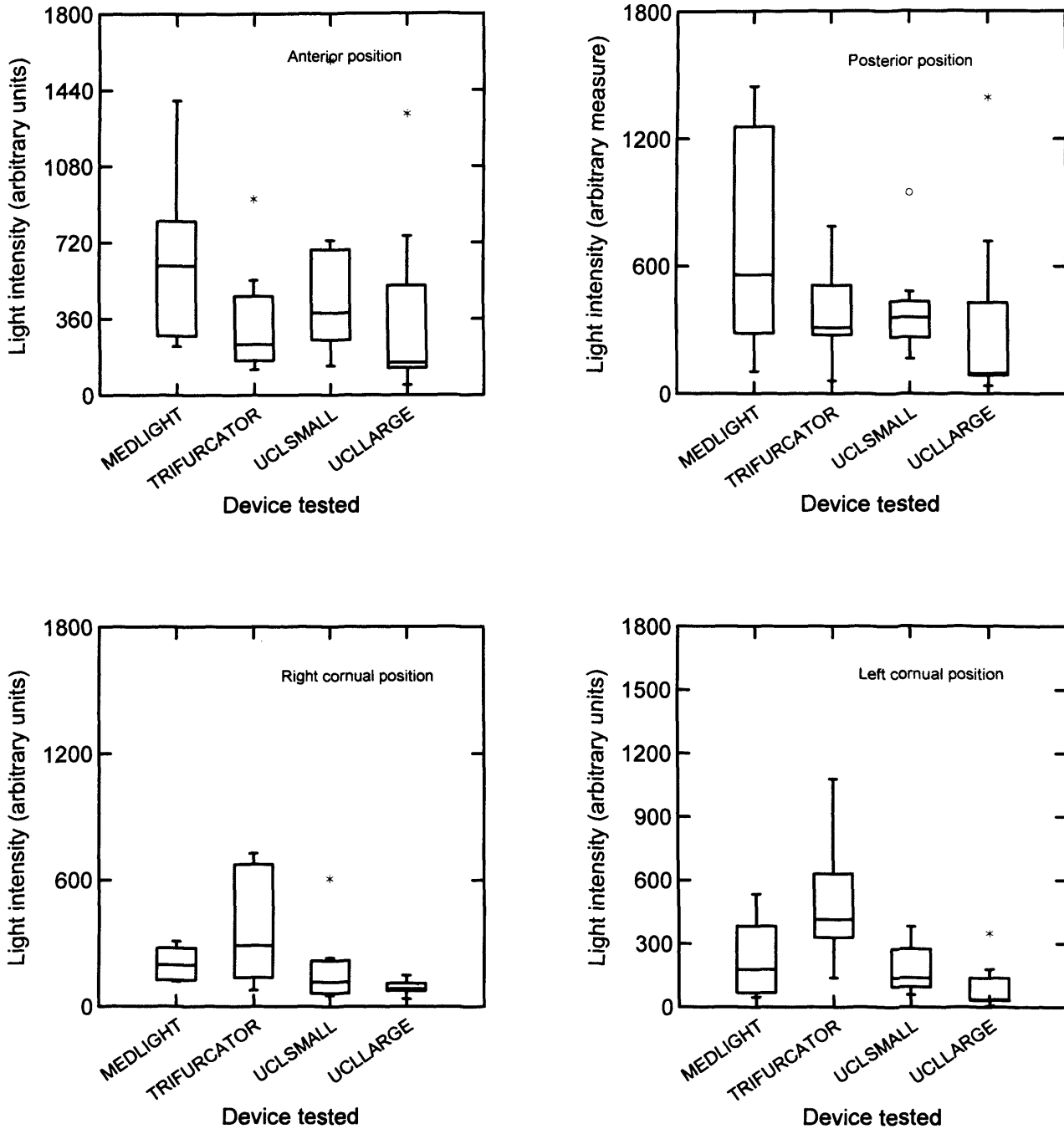


Figure 67 showing box plots of the light intensities of the Medlight balloon, UCL small balloon, UCL large balloon and the trifurcator at each of the uterine positions. The length of each box shows the range within which the central 50% of the values fall, with the box edges (called hinges) at the first and third quartiles. The centre horizontal line marks the median of the sample.

A box plot has been used to demonstrate the light intensity at each uterine position see Figure 67. To describe the information contained in a box plot, a few terms must be

defined. H spread is the absolute value of the difference between the values of the two hinges. Fences define outside and far outside values and are defined as follows: Lower inner fence = lower hinge - (1.5 x (H spread)); Upper inner fence = upper hinge + (1.5 x (H spread)); Lower outer fence = lower hinge - (3 x (H spread)) and Upper outer fence = upper hinge + (3 x (H spread)). The whiskers show the range of observed values that fall within the inner fences. Values between the inner and outer fences are plotted with asterisks. Values beyond the outer fences, called far outside values, are plotted with empty circles.

The light illumination in the left cornual region is lower than all other positions. The median light intensity in the anterior and posterior uterine positions was highest with the Medlight balloon. The median light intensities in the right and left cornual positions were highest in the trifurcator.

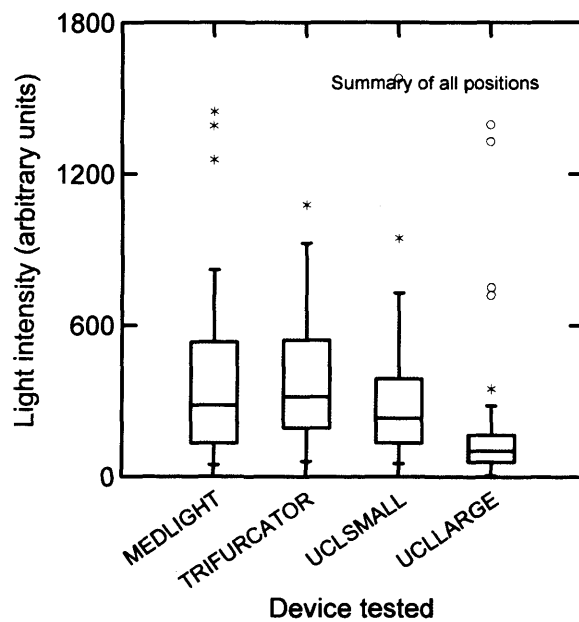


Figure 68 showing the average intrauterine light intensity of the Medlight balloon, UCL small balloon, UCL large balloon and the trifurcator device.

The light illumination at all positions for each device is compared in Figure 68. The UCL large balloon showed the lowest light intensity at all positions. There was little difference between the minimum light intensity of each device.



### 7.3.3 Discussion

There are two characteristics of an intra uterine delivery device that is essential for PDT of the endometrium to be effective. This includes uniformity of the light distribution and more importantly every area of the endometrium must have a minimum light intensity for activation of the photosensitiser.

#### Uniformity of light illumination

From the results of the experiment 1, it was surprising that trifurcator gave the most uniform illumination of the uterine cavity. The advantages quoted for balloon devices are that the light is distributed evenly on the surface of the balloon causing a more uniform illumination. This is true of other balloon devices tested in other hollow organs like the bladder and the oesophagus. It is the peculiar shape of the uterine cornua that prevents the balloon filling that area. Even the balloon using Dwyers recipe, which should be easily distensible and can take the shape of whatever organ it is in, was unable to overcome this.

#### Minimum light intensity

Unlike other organs, a relatively high light intensity would not harm the uterus as purely thermal effects are in use for endometrial ablation. It is therefore the minimal light intensity that is important. The UCL large balloon had the lowest light intensity with there being no significant difference between the other devices. Impregnating the balloon wall with Titanium chips did not appear to have an effect on the minimum light intensity.

#### Effect of a bigger balloon on intrauterine light illumination

The results of the UCL large balloon were disappointing. This was due to the fact that in most of the experiments the balloon could not be distended to the full capacity. In the one uterus with a cavity length of 10 cms, the UCL large balloon matched the minimum light intensity and uniformity of light distribution of the other balloons

#### The trifurcator for intrauterine light illumination

From the data it appears that the trifurcator was the best option for intra uterine light delivery. However the arms of the trifurcator were coated to prevent thermal damage as it is designed for heat delivery. It is possible that the coating interfered with light illumination.

To address the issues discussed above, we wanted to investigate the effect of 1) adding light fibres into a balloon device and 2) creating light fibres delivered through non coated tubes on the uniformity and intensity of intra uterine light illumination.

## **7.4 Experiment 2**

**a) *The effect of adding another light diffuser into a balloon device on the intrauterine light delivery of the balloon devices.***

**b) *Comparison of the balloon devices with a custom made bifurcator device for intrauterine light delivery.***

### 7.4.1 Methods

#### 7.4.1.1 Devices

Construction of a bifurcator device for intrauterine light delivery

Two nylon tubes with an outer diameter of 2 mm and an inner diameter of 1mm were attached together side by side. The distal ends of the tube were remodelled using heat to take the shape of the fundus of the uterus as shown in Figure 69. The proximal end of the tubes was fitted with a female Luer lock which attached to a 'Y' shaped port. This channel was used to introduce the light diffuser fibre and saline distension medium if required. The tubes had metal rods which kept it straight. This was inserted in to the uterus up to the fundus. The metal rods were removed. The light fibre was first inserted into the right tube The light intensity measurements taken. The measurements were then taken with the fibre inserted into the left tube. A two way stop cock was used at the syringe interface to the Y adaptor to allow for the catheter to be purged of air.

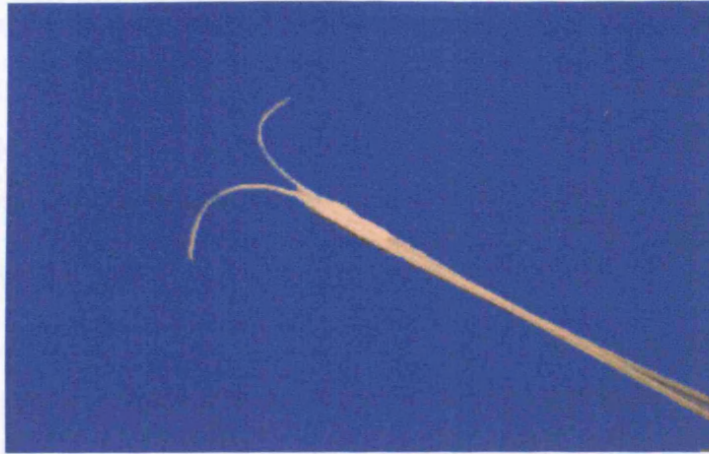


Figure 69 showing the design of the bifurcator device. The light fibre was inserted into each tube at different times for the purposes of the experiment. If a 2 way beam splitter was used then the two fibres could be inserted at the same time.

#### Construction of a balloon with an additional light diffuser fibre

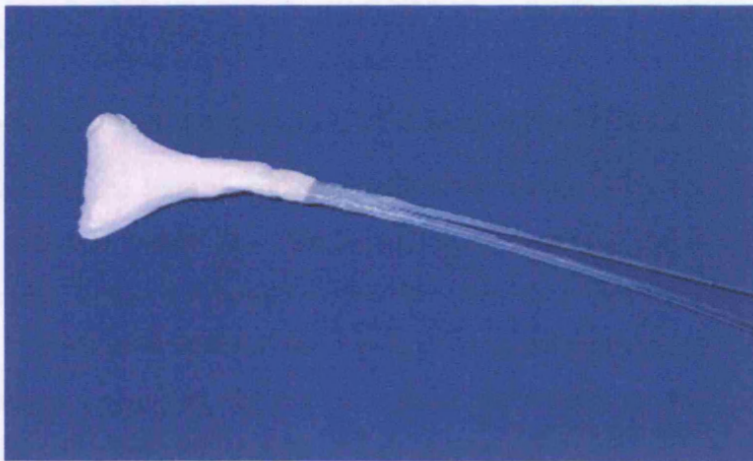


Figure 70 the bifurcator in the UCL small balloon

A balloon was made as described for the UCL small balloon using Dwyers technique see 7.3.1.1. Instead of using the nylon tube as described, a bifurcator was inserted into the balloon as shown in Figure 70. The Y shaped port was used to distend the balloon with saline after it was inserted in to the uterus. The distal end of the nylon tube was sealed with a plug of acrylic epoxy to prevent the optical fibre positioned inside the tube from perforating the balloon. The device is illustrated in Figure 65.

## Comparison of the light delivery devices

The Medlight balloon, UCL small and UCL large balloons were compared with the bifurcator device in the UCL small balloon and the bifurcator device without a balloon using the methodology as described in section 7.3.1.2.

### 7.4.2 Results

Seven uteri were used in experiment 2. Hysterectomy was performed in these premenopausal women for dysfunctional uterine bleeding (DUB) that was not responding to medical therapy. None of them had a previous endometrial ablative procedure done. Dimensions of the seven uteri ranged from a cavity length of 6cms to 9 cms. The uterine specimens were collected from theatre immediately after removal and all experiments were completed within two hours. After the experiment was over the uterine specimens were bisected before placing it in saline. None of the specimens had any intrauterine pathology. Accurate histopathological evaluation of the uterine specimens was possible in all cases as significant autolysis had not occurred. Histology confirmed DUB in all cases.

#### *7.4.2.1 Comparison of the uniformity of intra uterine light distribution*

The uniformity of the light distribution within the uterus using each of the devices used is illustrated in Figure 71. The balloon devices with a single light diffuser in them had similar light distributions in that the majority of the light was delivered to the anterior and posterior walls of the uterus. The areas that were poorly illuminated were the cornual regions of the uterus. When the bifurcator was inserted in to a balloon, there was good illumination of the left cornual region with poor illumination of the right cornual region of the uterus and the anterior wall of the uterus. The bifurcator showed almost perfect uniform illumination of all areas of the uterus.

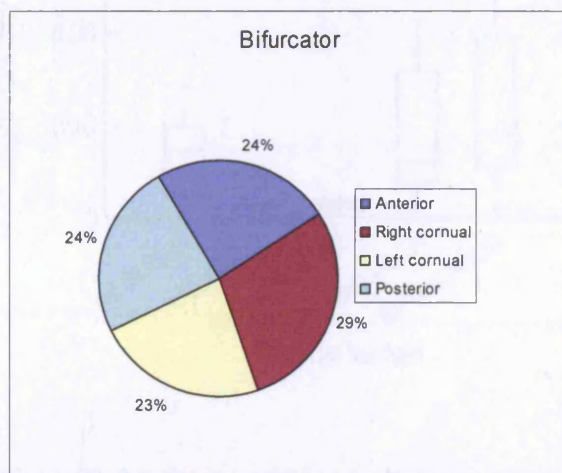
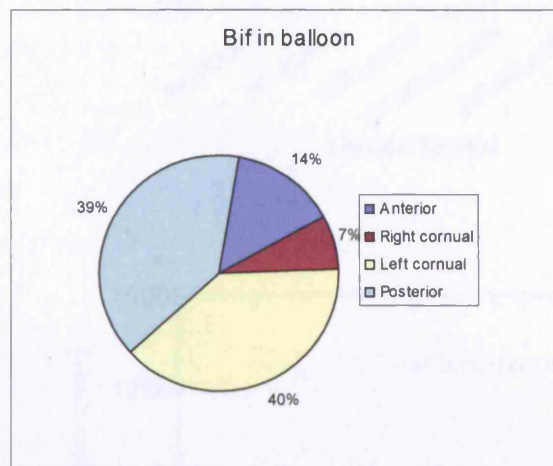
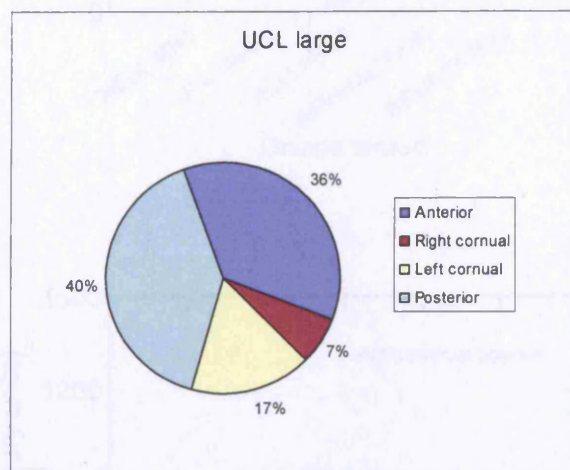
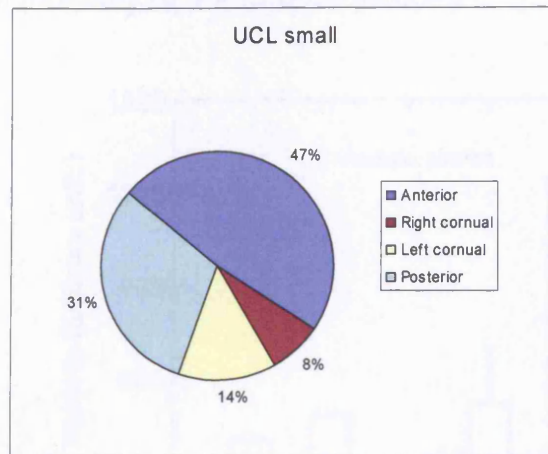
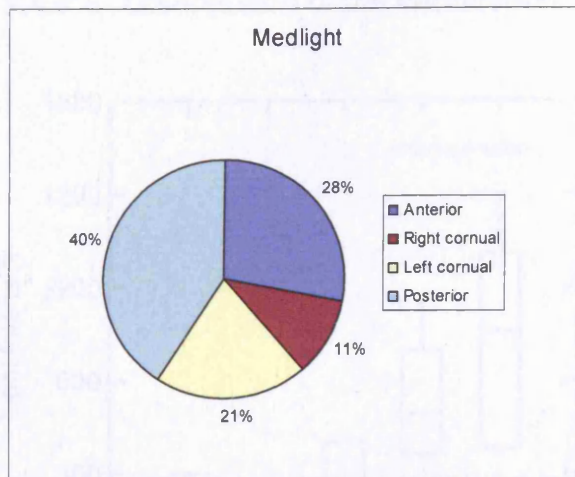


Figure 71 showing the mean light distribution in the anterior, posterior, right and left cornual positions of the uterus with the Medlight balloon, UCL small balloon, UCL large balloon, bifurcator in UCL small balloon and bifurcator device without a balloon.

### 7.4.2.2 Comparison of the intrauterine light intensity of the uterine devices

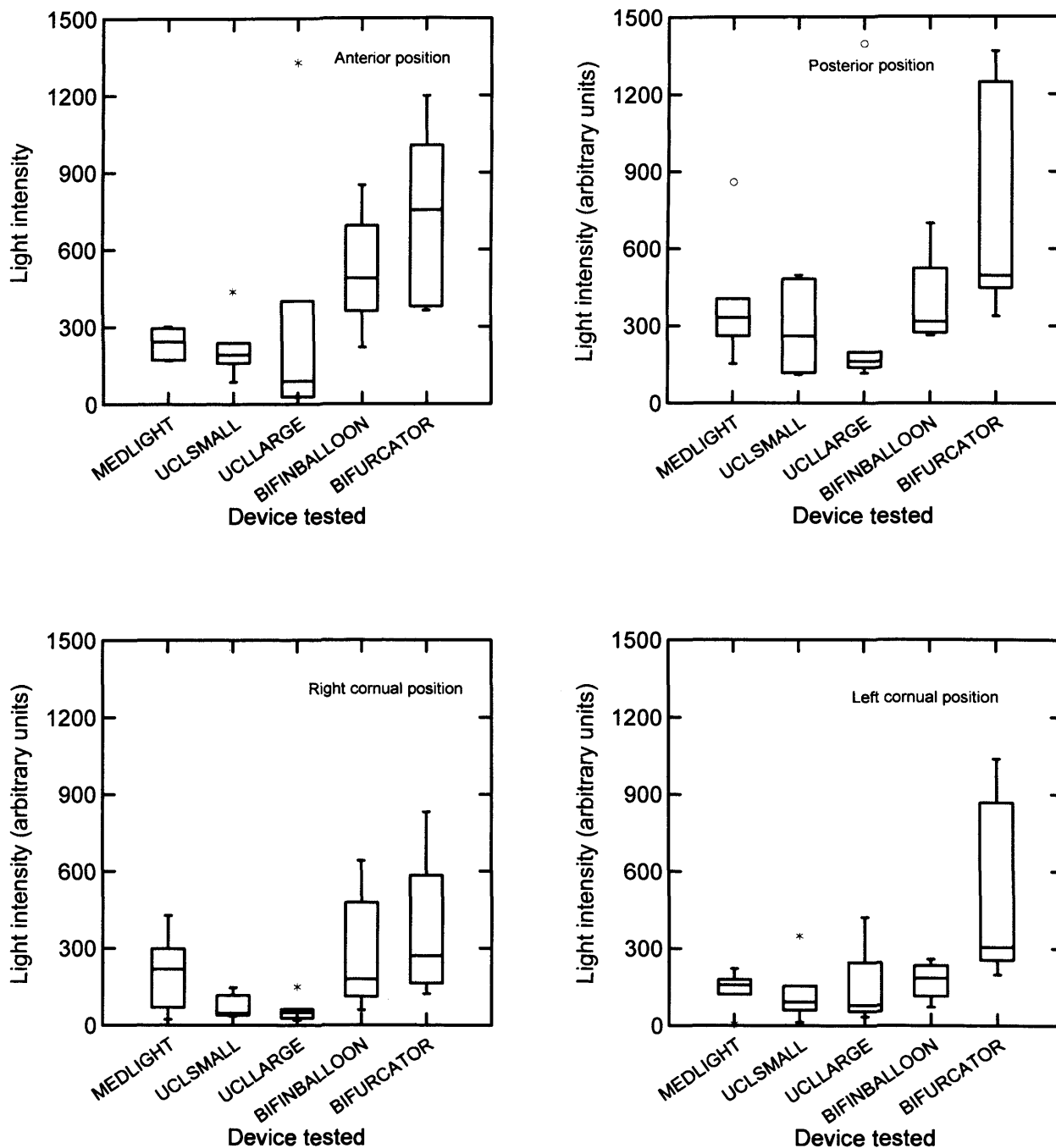


Figure 72 showing box plots of the light intensities of Medlight balloon, UCL small balloon, UCL large balloon, bifurcator in UCL small balloon and bifurcator device without a balloon at each of the uterine positions. The length of each box shows the range within which the central 50% of the values fall, with the box edges (called hinges) at the first and third quartiles. The centre horizontal line marks the median of the sample.

The light intensity at each uterine position with each device is shown in Figure 72. There was no difference between the three balloon devices with a single light

diffusing fibre. The bifurcator in a balloon device showed a higher light intensity in all the positions but the highest light intensity was seen with the bifurcator device without a balloon.

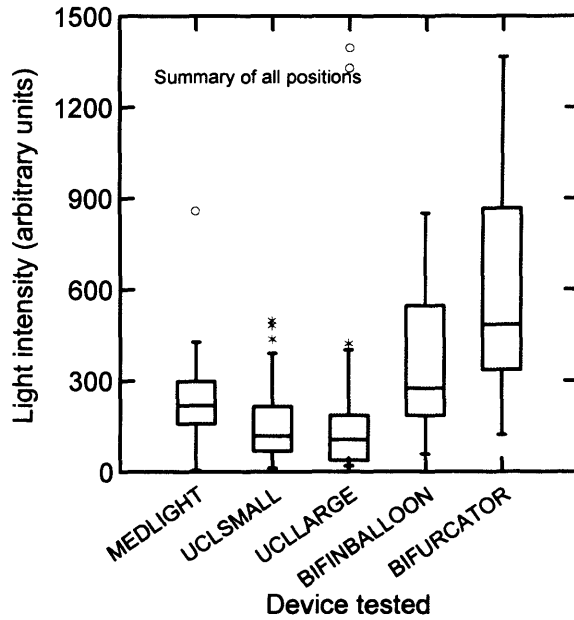


Figure 73 showing the average intrauterine light intensity of the Medlight balloon, UCL small balloon, UCL large balloon, bifurcator in UCL small balloon and bifurcator device without a balloon.

The overall intrauterine light intensity seen with each device is shown in Figure 73. The minimum light intensity for the Medlight, the UCL small and the UCL large are similar. The minimum intensity is higher with the bifurcator in the balloon device and the bifurcator device.

**7.4.2.3 Comparison of the intrauterine light intensity of the uterine devices at the level of the cervix**

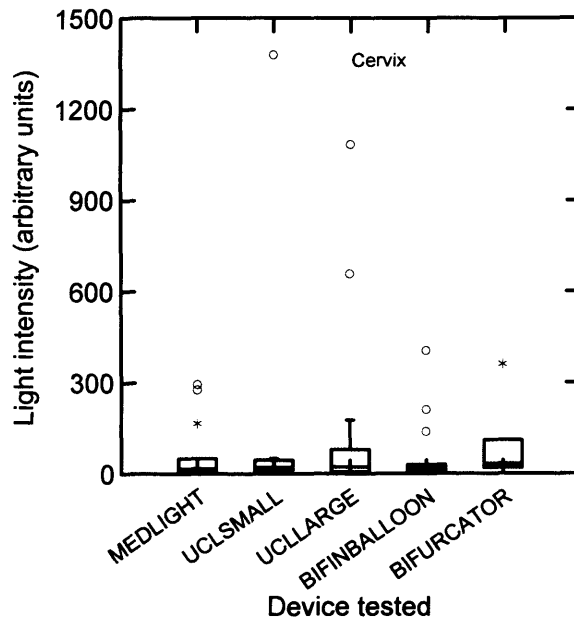


Figure 74 showing the light intensity at the level of the cervix with each of the devices tested

The illumination of the uterine cavity at the level of the internal os is shown in Figure 74. The UCL small, Medlight and the bifurcator in the UCL small balloon give minimal illumination at the level of the cervix. The UCL large balloon and the bifurcator device have a larger range of intensity values. All the devices have outliers and other than for the bifurcator these are in the “far outside values” range as described in section 7.3.2.1.

**7.4.3 Discussion**

As discussed earlier the two characteristics of an intra uterine delivery device that is essential for PDT of the endometrium to be effective are the uniformity of light distribution and the minimum light intensity for activation of the photosensitiser.

**Uniformity of light illumination**

The addition of another light diffuser fibre in to the balloons which had titanium chips impregnated in to the wall did not have any effect on the uniformity of intrauterine light distribution. There was preferential illumination of the posterior wall and the left cornual region of the uterus. This may be explained by the positioning of the two



ends of the bifurcator in the balloon when inserted into the uterus. The bifurcator however gave excellent results with almost all areas of the uterine cavity being illuminated uniformly. The results of the bifurcator were better than that of the trifurcator from experiment 1. As discussed before, the trifurcator has been designed to deliver heat and not light and shadowing would result in interference of light being uniformly distributed. The ends of the bifurcator were shaped almost like that of an intrauterine contraceptive device which has been designed to be retained in the uterus by its shape. This design allowed for illumination of the cornual regions of the uterus which are essential if PDT is to be successful.

#### Minimum light intensity

The minimum light intensity of the Medlight balloon, UCL small and large balloons were similar. This confirmed the results that were obtained in experiment 1. The minimum light intensity was increased by adding another light diffuser in to the balloon as seen in the bifurcator in balloon device. The best improvement in the minimum light intensity however was seen with the bifurcator device. This could be attributed to its design whereby the light fibres actually go into the cornual regions of the uterus where the light intensity is usually the lowest.

#### Illumination at the level of the cervix

An ideal light delivery device would produce minimal illumination at the level of the cervix. This is important to avoid PDT destruction and subsequent cervical stenosis. One of the complications of all endometrial ablative techniques is cyclical midline pain from haematometron caused by cervical stenosis. All the devices do not show significant cervical illumination. However all devices show outliers and even “far outside value”. This indicates that on a particular day, sufficient illumination of the cervix did occur. If sufficient concentration of photosensitiser was also present in the cervical canal then PDT damage would have occurred.

### **7.5 Experiment 3 - To investigate the effect of intrauterine pathology on light distribution in the uterus.**

#### 7.5.1 Methods

Three women who were undergoing hysterectomy for abnormal MBL and had intrauterine pathology were identified.

The pathology identified were

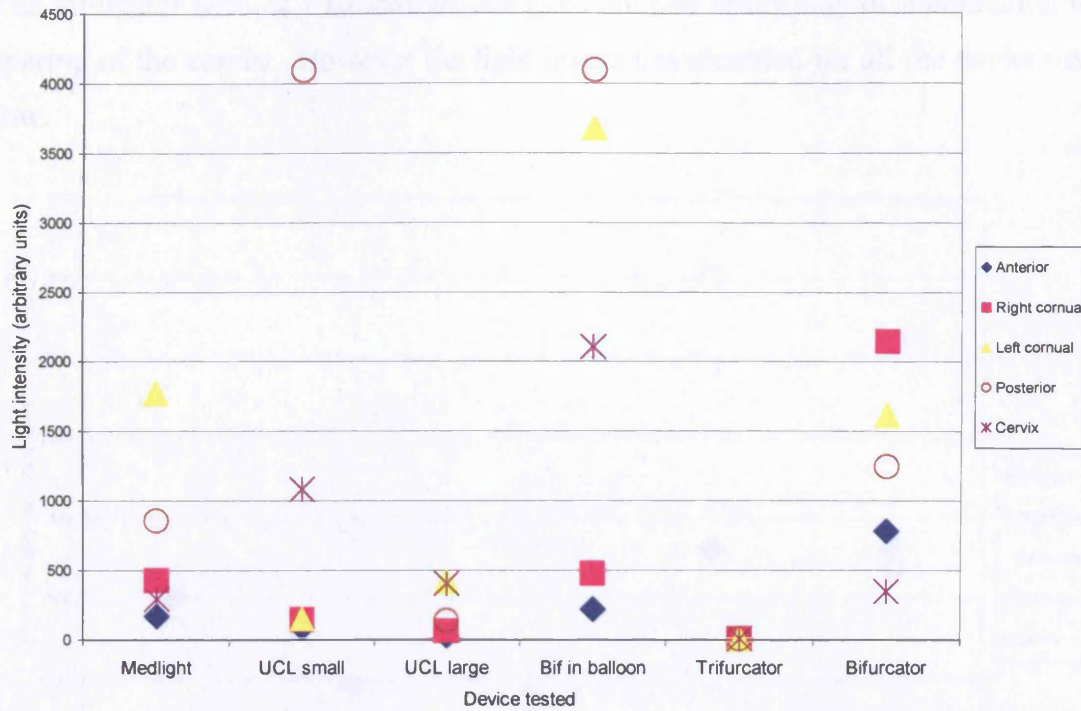
1. Intrauterine scarring from a previous transcervical resection of the endometrium.
2. A 5 cm Type 2 submucosal fibroid situated in the fundus of the uterus
3. A small intrauterine septum

The devices tested were the Medlight balloon, UCL small balloon, UCL large balloon, trifurcator, bifurcator in UCL small balloon and the bifurcator without a balloon device. The methods and the set up for the comparison of the light delivery by these devices were the same as that described in Experiment 2.

## 7.5.2 Results

### *7.5.2.1 Comparison of intrauterine light delivery of the Medlight balloon, UCL small, UCL large, bifurcator in UCL small balloon, trifurcator and bifurcator device without a balloon in a uterus with a previous transcervical endometrial resection.*

The worst results were from the trifurcator. This was because as the uterine cavity was smaller it was difficult to manipulate the trifurcator and extend it fully. A similar problem occurred with the UCL large balloon. There was no difference with the Medlight balloon, UCL small and bifurcator in UCL small balloon with regards the minimum light intensity. The UCL small balloon and the bifurcator in UCL small balloon gave a high illumination of the cervix which was undesirable. The best results came from the bifurcator without a balloon device which gave a better uniformity and intensity of illumination with a low cervical illumination.



Fi

Figure 75 showing the light distribution with each of the devices (vertical line) in a uterus with a previous transcervical resection of the endometrium

**7.5.2.2 Comparison of intrauterine light delivery of the Medlight balloon, UCL small, UCL large, bifurcator in UCL small balloon and bifurcator without a balloon device in a uterus with a 5cm submucous fundal fibroid**

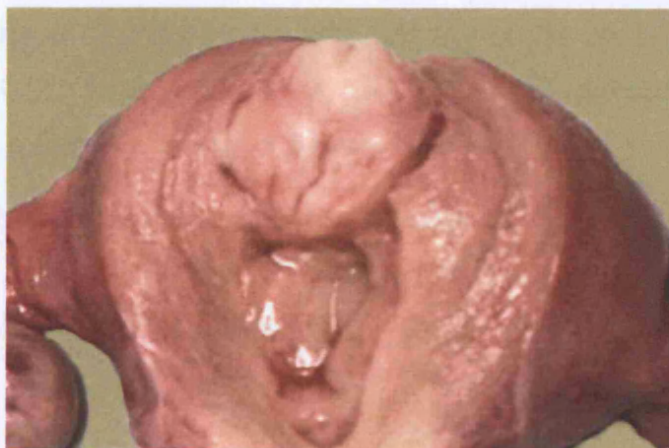


Figure 76 showing the 5cm type 2 submucosal fundal fibroid. Note narrowing of the cornua

The bifurcator without a balloon device gave the best uniformity of illumination with sparing of the cervix. However the light intensities recorded for all the devices were low.

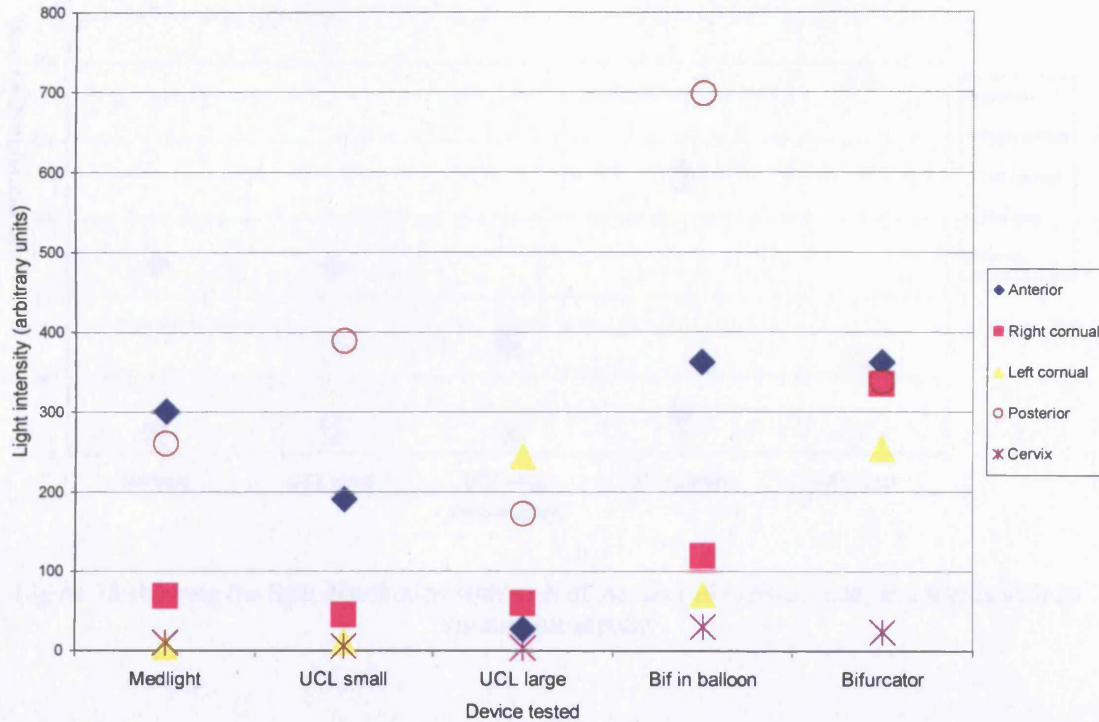


Figure 77 showing the light distribution with each of the devices (vertical line) in a uterus with a 5cm Type 2 submucosal fundal fibroid.

### 7.5.2.3 Comparison of intrauterine light delivery of the Medlight balloon, UCL small, UCL large, bifurcator in UCL small balloon and bifurcator without a balloon device in a uterus with septum.

Figure 78 and Figure 79 demonstrates the limitation of the balloon devices. All the balloon devices gave a very poor illumination of the right cornual region. The bifurcator was able to reach the cornua and thereby produce sufficient illumination.

## 7.6 Discussion

The principle of any design is the structure of the illuminated cavity cavity by a cylindrical object or balloon across the uterus. The light intensity distribution of the device used. The balloon device is not affected by the same illumination strength that the bifurcator device. One of the advantages of using bifurcator device is the structure of uterus with balloon device which does not get illuminated effectively

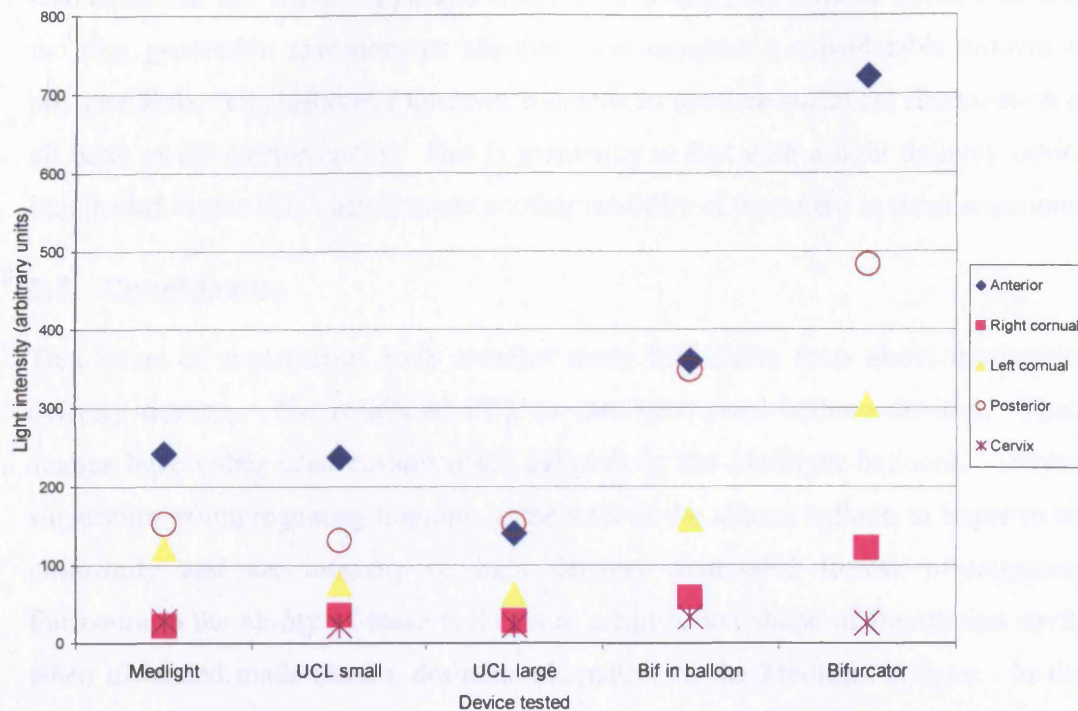


Figure 78 showing the light distribution with each of the devices (vertical line) in a uterus with an intrauterine septum

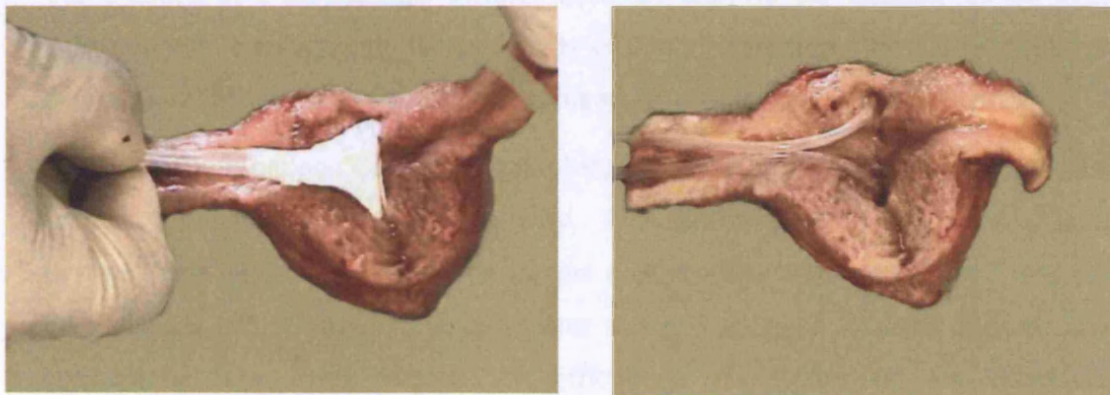

Figure 79 showing how the bifurcator overcomes the midline uterine septum to deliver light to the uterine cornua. The balloon devices were not able to reach the fundus of the uterus.

## 7.6 Discussion

The presence of any change in the structure of the endometrial cavity either by a congenital septum or fibroids affects the overall light intensity irrespective of the device used. The balloon devices are affected more by these structural changes than the bifurcator device. One of the difficulties facing gynaecologists today is the treatment of woman with heavy periods who have had an endometrial ablative

technique that has failed. A second ablative technique may only be considered with the first generation resections or ablations and required a considerable amount of operator skill. The bifurcator however was able to produce sufficient illumination of all parts of the uterine cavity. This is promising in that with a light delivery device like the bifurcator PDT may become another modality of treatment in these situations.

## **7.7 Conclusions**

This series of experiments have revealed many interesting facts about intrauterine delivery devices. The results of PDT to date have used balloon devices. These studies have either used custom made balloons or the Medlight balloons. Dwyers suggestion of impregnating titanium in the wall of the silicon balloon to improve the uniformity and the intensity of light delivery demanded further investigation. Furthermore the ability of these balloons to adapt to the shape of the uterine cavity when distended made them a desirable alternative to the Medlight balloon. In this series of experiments however, we could not demonstrate any improvement of these balloons on the Medlight balloon. Altering the size of the balloon, even in the larger uterus, did not make a difference. In the smaller uterus, the bigger balloon failed to distend and results were disappointing.

The addition of a second light diffuser fibre did improve the intensity of the light delivered with a reduction in the uniformity of light distribution. We did not find this device more difficult to insert into the uterus when compared to the other devices.

The use of non balloon devices like the bifurcator and the trifurcator gave the best uniform illumination of the uterine cavity. This was because the side arms of both devices were designed like an intra uterine contraceptive device and fitted into the cornual ends of the uterus. The trifurcator was not designed for light delivery and considerable shadowing reduced its efficacy. The bifurcator was therefore constructed with nylon tubing and produced a higher intensity of light than all other devices. We found the insertion of the bifurcator easier than that of the balloon devices.

Photodynamic therapy of the endometrium may be improved by increasing the uniformity of light delivery and ensuring that all areas of the endometrium receive a light intensity above that of a minimum threshold. These series of experiments suggest that a non balloon device like the bifurcator would produce better results than

that of balloon devices that are currently in use for PDT. An additional advantage for clinical use is that uterine distension is not required with the bifurcator. This reduces uterine cramps and discomfort for the woman and makes it more attractive for outpatient use.

# [8] Interstitial laser photocoagulation of uterine fibroids

Interstitial laser photocoagulation (ILP) of uterine fibroids is a feasible and safe procedure. As discussed in Chapter 3 most of the results reported are by a single surgeon using the KTP; YAG laser without detailed follow up of the women treated. It is important to therefore standardise the methodology using newer portable less expensive diode lasers and to quantify the effect of this treatment on fibroid shrinkage.

Twelve women with 16 fibroids underwent ILP for the treatment of uterine fibroids in our centre during the period 1999 to 2000. This group of women were followed up by serial MRI scans during the period of the thesis to objectively evaluate the effect of ILP on uterine fibroids. Nine more women with 13 fibroids underwent ILP for uterine fibroids during the period of the thesis and were similarly followed up. Results of both cohorts of women will be included in the data analysis.

The purpose of this study is to perform a detailed assessment of the effect of ILP on women with uterine fibroids and to critically evaluate its potential clinical role.



## **8.1 Methods**

### **8.1.1 Patient recruitment**

Patients for the study were recruited from the outpatient clinics at the University College London Hospitals (UCLH). Most of the women treated had menorrhagia as the primary symptom. Other symptoms included dysmenorrhoea, infertility and pressure effects. All patients had declined conventional surgical treatment of open myomectomy or hysterectomy and were referred to us for consideration of Interstitial Laser Photocoagulation (ILP). Eligibility for entering the trial was a clinical evaluation that showed that the uterus was smaller than a 16-week pregnant uterus and a screening MRI or US that showed that no single fibroid had a diameter greater than 10 cms. An outpatient hysteroscopy was then performed to see if there were any other fibroids that could be treated by transcervical resection. Patients were counselled regarding the risks, benefits, alternatives and fertility issues associated with ILP. The risks of a laparoscopic procedure and the risks of bleeding from the treatment site necessitating open myomectomy or hysterectomy to arrest the haemorrhage was discussed in detail. This study was approved by the ethics committee of the University College London Hospitals and all patients gave written, informed consent prior to their participation

### **8.1.2 Technique used for ILP**

The in vitro study by Gordon et al (see section 3.4.4.1) showed that a single fibre produced an ellipsoidal lesion of coagulative necrosis of 10-14 mm diameter. If 2 fibres were used the area increased to a diameter of 20 mm. Before surgery the fibroids were localized and the volume estimated by MRI. The volume of each was estimated by assuming it to be roughly spherical (for radius  $r$ , volume =  $4/3\pi r^3$ ). The calculation for the treatment required for each fibroid was based on aiming to get all parts of the fibroid within 2 cms of a needle tip.

Prior to laser treatment, the optical fibres (400  $\mu\text{m}$  glass core) were prepared by stripping about 10mm of plastic cladding off the tip and cleaving the core to leave about 3mm of clean glass protruding from the cladding. Each fibre was then measured and a small piece of tape attached as a "flag" so that, when the fibre was passed down a 16 G needle (Tuohy, 110 mm long with 1 cm gradations, Portex, England) as far as

the flag, the tip of the fibre protruded by 2-3 mm from the tip of the needle. The fibres were sterilised by putting them through an automatic endoscope cleaning cycle using Tristal 700 (active ingredient chlorine dioxide, Tristel Ltd, Snailwell UK).

A general anaesthetic was used in all cases. The patient was cleaned and draped as for a standard laparoscopy with a Spackmann cannula being used as the intra uterine manipulator. With the woman in the dorsal position a Veress needle was inserted in the umbilicus. A carbon dioxide pneumoperitoneum was then created up to a pressure of 20 mm Hg. A 10 mm trocar was inserted in the umbilicus and a 10 mm laparoscope was used. The uterus was checked and the fibroids confirmed. A second port was inserted in the right flank at least 8 cms from the midline taking care to avoid the inferior epigastric vessels. The patient was then tilted head downwards in to a Trendelenberg position. An atraumatic grasper was used to gently remove all bowel from the pouch of Douglas and retract it using gentle traction. A suction irrigator was primed and ready for use

Two to four 16G Tuohy needles were inserted into the substance of the fibroid under laparoscopic guidance so that their tips were 2 cms apart, aiming to get all parts of the fibroid within 2 cms of a needle tip. The optical fibre tips were pre-charred by dipping them in a drop of the patient's blood and energising with laser light for a few seconds as this has been shown previously to give more predictable tissue heating (Amin et al). On one day, an attempt was made to simplify this procedure by simply heating the fibre tip in a bare flame, although this was unsuccessful, as described below. The fibres were then inserted through the Tuohy needles and were connected to a semiconductor diode laser with a 4-way beam splitter (Diomed 25, Diomed Ltd, Cambridge, UK). The power used was 3.5 W per fibre for a planned duration of 300 seconds. For larger lesions, the fibres were repositioned after light delivery by pulling them back by 1-2 cms and the dose repeated. During light delivery, the bowel was retracted from the area of treatment and constant laparoscopic surveillance was maintained for burn through (signs that the laser effect might have reached the opposite side of the uterus) or burn back (signs of coagulation of the tissue around the sites where the needles entered the uterine wall). After treatment was completed, the fibres and the Tuohy needles were removed, and any active bleeding from the serosal entry points was treated with bipolar cautery. All patients were kept in hospital overnight after treatment for observation.



Figure 80 Semiconductor 805 nm Diode Laser Diomed 25W, Diomed Ltd Cambridge UK)

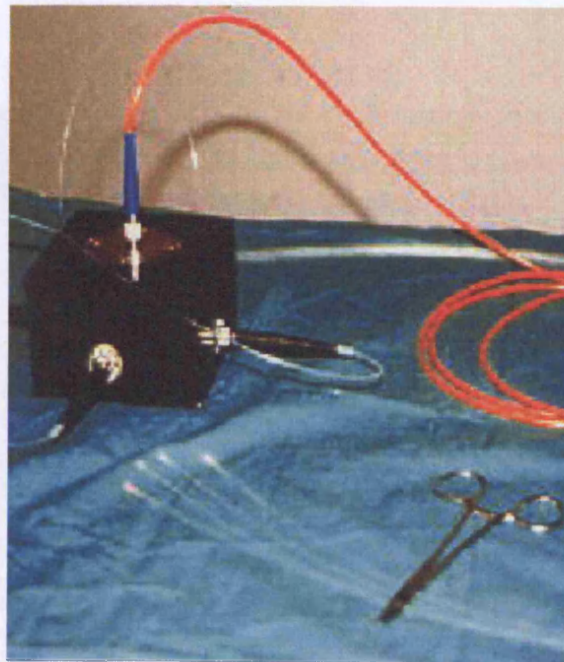


Figure 81 – A 4-way beam splitter allows 4 freshly cleaved optical fibres (400 $\mu$ m) to be used simultaneously for ILP treatment

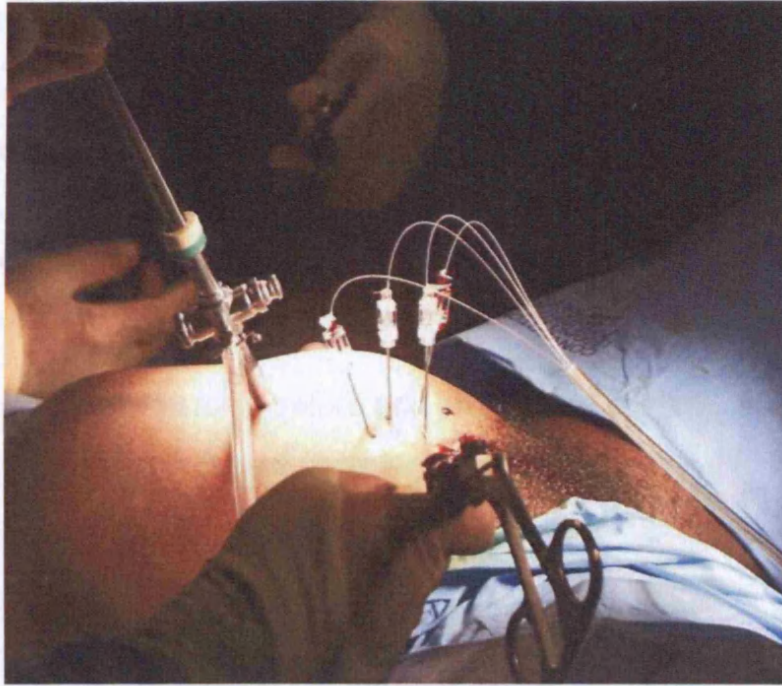


Figure 82 Picture showing 10 mm laparoscope in umbilical port and grasper in the right flank (used for retracting bowel from the pouch of Douglas) and the Tuohy needles with the fibres inserted through them. Four fibres were used with a beam splitter. The flags on the fibres are also shown.

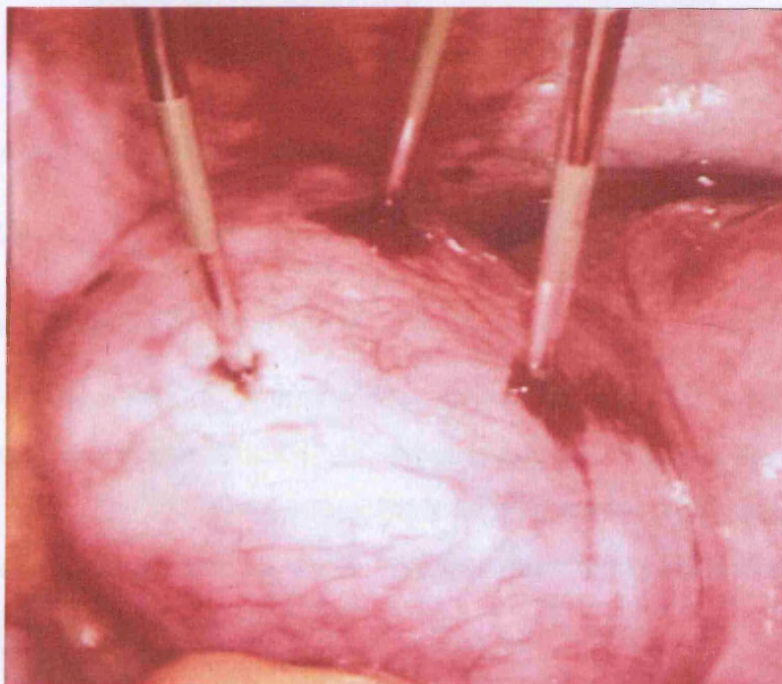


Figure 83 Picture showing the Tuohy needles inserted into the fibroid being treated. The 1cm graduations are visible. The aim is to keep a distance of 2 cms between each needle point.

### 8.1.3 Follow up – MRI imaging of fibroids

All patients had repeat measurements of the size of the treated fibroids during follow up. MRI measurements and patient assessment were planned at 6 weeks 6 and 12 months after treatment in the first series. In the second series follow up was 3, 6 and 12 months following treatment. Any patient who was unhappy with the clinical response was offered conventional surgery.

### 8.1.4 MRI imaging of fibroids before and after treatment with ILP

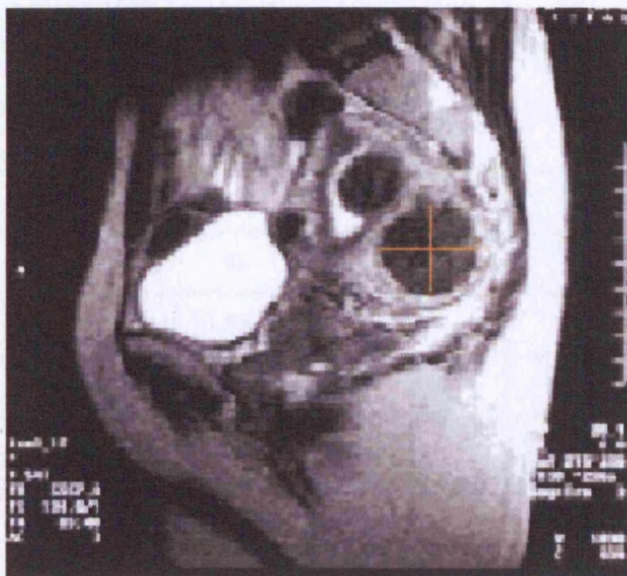


Figure 84 MRI showing subserous posterior wall fibroid with 2 diameters being measured

## 8.2 Results

### 8.2.1 Patient details

Twenty one women with 32 symptomatic uterine fibroids were treated with ILP. Thirteen women had single fibroids, five women had two fibroids and three women had three fibroids. The age group ranged from 26 to 51 years with a mean age of 39.2 years. 14 women were Caucasian while 7 women were black (African descent). Nine of the women treated were nulliparous.

### 8.2.2 Presenting symptoms

The main complaint in 13 women was an increased MBL. In this group five women also had dysmenorrhoea with two women complaining of pressure effects. The main complaint in the remaining eight women was pressure effects. In this group two

women were also concerned about fertility with one woman wanting treatment prior to referral for in vitro fertilisation. One woman complained of a severe dull pelvic ache mainly in the right iliac fossa.

### 8.2.3 Effect of ILP on uterine fibroid volume

21 women with 32 fibroids were treated with laparoscopic ILP.

Fibroid No	Initial volume (cm <sup>3</sup> )	Volume at 6 weeks (cm <sup>3</sup> )	Volume at 6 months (cm <sup>3</sup> )	Volume at 12 months (cm <sup>3</sup> )	Reduction %
18	353	423	326	97	72
19	10	11	9	17	-77
20	9	10	10	10	-10
21	30	42	22	6	79
22	33	52	33	30	10
23	37	50	20	12	69
24	12	3	3	2	68
25	28	40	50	11	61
26	54	59	34	Not done	62 at 6 months
27	107	145	67	45	58
28	152	161	105	171	-13
29	5	12	3	Not done	* Long term
30	44	45	44	Not done	*Long term
31	258	140	196	226	12
32	29	40	24	9	79
33	167	191	176	160	4

Table 25 Table showing the volume changes in fibroids (in cm<sup>3</sup> measured by MRI) following treatment by laparoscopic ILP – Series 1.

Treatment produced shrinkage in 17 of the women and in 24 fibroids. Therefore 81% of women treated had shrinkage of their fibroids. The volume changes of all fibroids are represented in Table 25 and Table 26. In this series the time points were 6 weeks, 6months and 12 months. 3 patients did not have MRI scans at 12 months. In 2

patients however (\*Long term) the patients ~~were~~ had MRI scans at 18 months and is discussed in 8.2.13.

Fibroid No.	Initial volume (cm <sup>3</sup> )	Volume at 3 months (cm <sup>3</sup> )	Volume at 6 months (cm <sup>3</sup> )	Volume at 12 months (cm <sup>3</sup> )	Reduction at 12 months %
1	244	124	119	109	75
2	68	21	19	Not done	72 at 6 months
3	8	1	0	Not done	100 at 6 months
4	198	176	164	169	15
6	116	139	135	148	-28
7	23	19	26	17	26
8	19	4	4	1	95
9	67	69	73	107	-60
10	166	72	68	58	65
11	94	70	72	Not done	23 at 6 months
12	50	39	38	Not done	24 at 6 months
13	29	28	7	Not done	76
14	47	38	30	30	36
15	4	2	1	1	75
16	25	11	Not done	Not done	56 at 3 months
17	12	5	Not done	Not done	58 at 3 months

Table 26 Table showing the volume changes in fibroids (in cm<sup>3</sup> measured by MRI) following treatment by laparoscopic ILP – Series 2. In this series, the time points were 3, 6 and 12 months. 3 patients were not followed up to 12 months. The patient with fibroid numbers 2 and 3 was referred for IVF treatment at 6 months. The patient with fibroids 16 and 17 underwent laparoscopic surgery for dense pelvic adhesions. The patient with fibroids 11 and 12 migrated to Australia.

### 8.2.3.1 Fibroids that shrank with laparoscopic ILP

At 6 weeks, 14 out of the 15 fibroids (93%) from series 1 (see Table 25) showed an expansion in fibroid volume. The mean expansion in volume was 23%. At the 3 month follow up 7 out of the 24 fibroids measured from series 1 and 2 (see Table 25 and Table 26) had still shown expansion (29%) with a mean fibroid volume reduction

of 19%. By 6 months 90% of all the fibroids that were eventually going to shrink at 12 months with treatment had done so with a mean volume reduction of 25% and at one year there was a mean shrinkage of 50%.

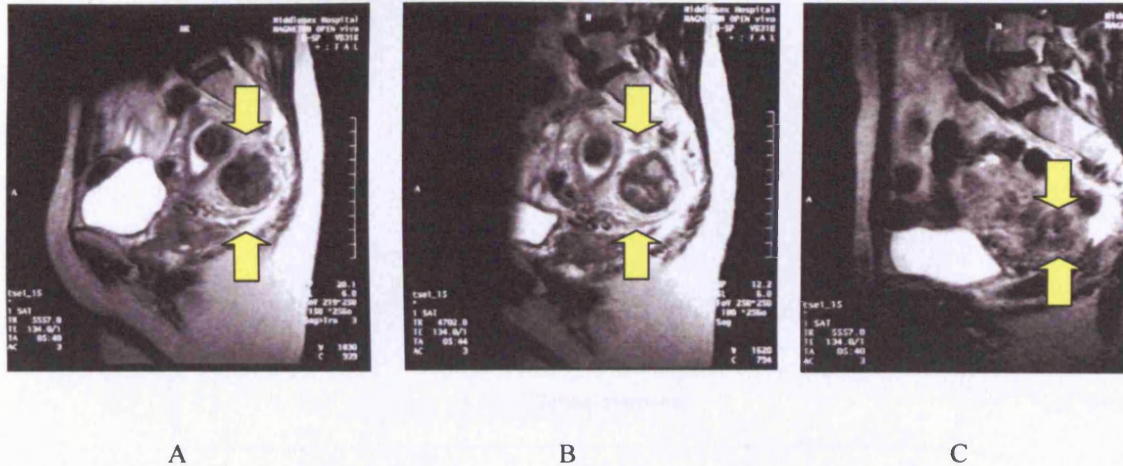


Figure 85 MRI of patient with fibroid no. 25. MRI showing (A) Before ILP 28cm<sup>3</sup> (B) 6 weeks after ILP 40cm<sup>3</sup> and (C) 1 year after ILP 11 cm<sup>3</sup>. In this patient there was a 40% reduction in fibroid volume.

### 8.2.3.2 Fibroids that did not shrink with laparoscopic ILP

Laparoscopic ILP failed in six patients with eight fibroids (Both series). Two patients had two fibroids treated. Failure was seen in one out of the three fibroids treated in two women. The other two fibroids shrank after treatment.

Fibroid No.	Initial volume (cm <sup>3</sup> )	Volume at 3 months (cm <sup>3</sup> )	Volume at 6 months (cm <sup>3</sup> )	Volume at 12 months (cm <sup>3</sup> )	Reduction %
6	116	139	135	148	-28
9	67	69	73	107	-60
16	25	11	Not done	Not done	-18
17	12	5	Not done	Not done	-89
20	9	15	15	10	-11
28	152	138	138	171	-13
30	44	45	57	Not done	-30

Table 27 Table showing the volume changes of fibroids (in cm<sup>3</sup> measured by MRI) following treatment by laparoscopic ILP – where laparoscopic ILP did not work. Negative values indicate a growth in the fibroid.



### 8.2.4 Effect of the pre treatment volume on effect of laparoscopic ILP

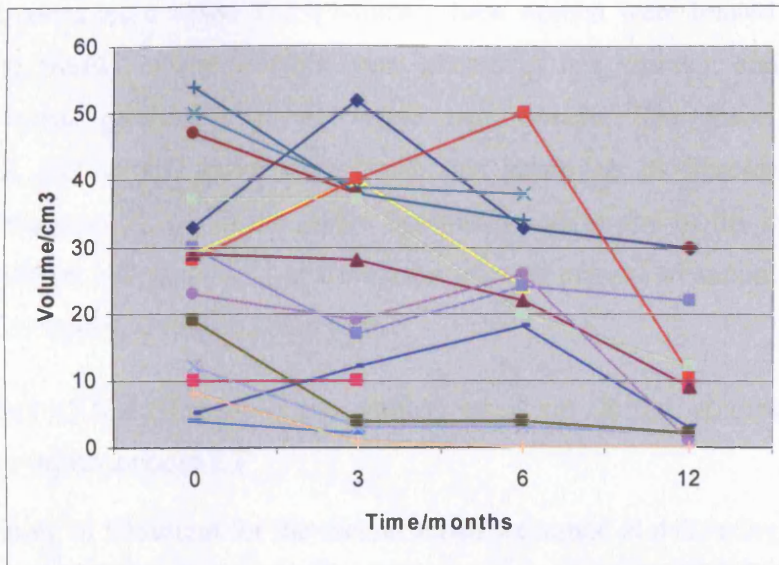


Figure 86 Graph showing the volume changes of fibroids (pre treatment volume less than 60 cm<sup>3</sup>) up to 12 months after laparoscopic ILP

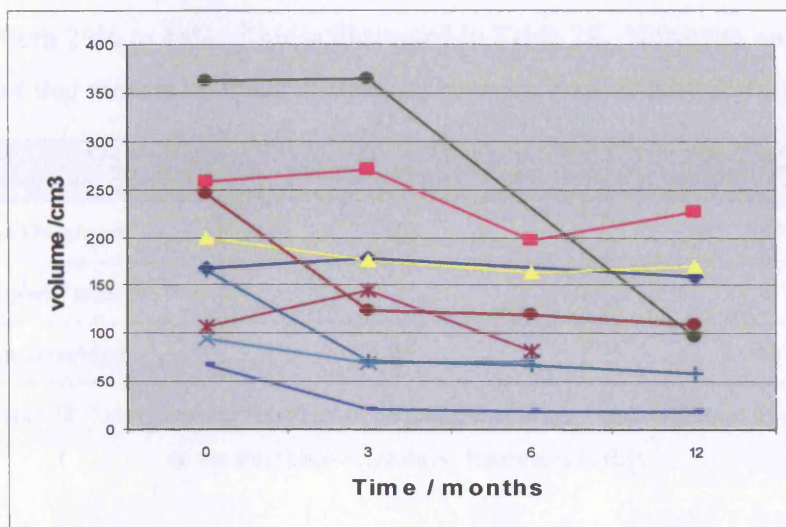


Figure 87 Graph showing the volume changes of fibroids (pre treatment volume greater than that 60 cm<sup>3</sup>) up to 12 months after laparoscopic ILP

In those with fibroids where the pre treatment volume was greater than 60 cm<sup>3</sup> the mean shrinkage was 38% (range 4-73%). In the laparoscopic ILP failure group, the pre treatment volume of 5 fibroids was less than 60 cm<sup>3</sup> and 3 were greater than 60 cm<sup>3</sup>.

### 8.2.5 Effect of pre charring the fibres prior to laparoscopic ILP

In the first series, on a single day treatment, three women were treated without pre charring the fibres. Three fibroids were treated in one woman, and two single treatments were performed on the other two women. The three failures of laparoscopic ILP in this series came from this group of 16 fibroids. However shrinkage was seen in one of the single treatments and in one of the three fibroids treated. In the second series, all fibres were pre charred prior to treatment and two out of 17 fibroids treated did not respond to ILP.

### 8.2.6 Effect of the increasing the energy used on fibroid volume reduction after laparoscopic ILP

In our planning of treatment for the second series we aimed at delivering a minimum dose of 125 ~~cm<sup>3</sup>~~ for 1 cubic cm of fibroid tissue. Consequently, in the second series the amount of energy per unit volume of fibroid treated was 194 J/cm<sup>3</sup> when compared to 105 J/cm<sup>3</sup> in the first series. This was done not by increasing the power but by using the technique of pull backs as described in section 8.1.2. The average shrinkage obtained by doubling the pull backs (and therefore treatment sites) increased from 29% to 44%. This is illustrated in Table 28. However, analysis of the data showed that there is no linear correlation between dose density and shrinkage.

	Series 1	Series 2
Mean Dose/cm <sup>3</sup>	105	194
No of points treated	3	6
Mean Shrinkage	29	44

Table 28 Table showing the effect of doubling the energy / cm<sup>3</sup> of fibroid treated on the shrinkage obtained by laparoscopic ILP

### 8.2.7 Effect of laparoscopic ILP on patients symptoms

Nine out of the 13 women with an increased MBL as the main complaint reported an improvement in MBL. Four women reported no improvement. Six out of the eight women with pressure effects reported a substantial improvement in symptoms. In one woman they became worse and 1 woman (with pelvic ache as a secondary complaint) left the study as she was scheduled for surgery because of findings at laparoscopy.

### 8.2.8 Other procedures required

Other procedures were required in six women. Two women required transcervical resection of uterine fibroids for type 1 submucous fibroids, two women required laparoscopic adhesiolysis to gain access to the fibroids for treatment, one woman had endometriosis which was treated at the same time and one woman had an appendicular mass and bilateral hydrosalpinges and was scheduled for laparoscopic adhesiolysis, appendectomy and bilateral salpingostomy at a later date.

### 8.2.9 Complications of ILP

Two patients required bipolar diathermy to the entrance of one of the needle tracts due to bleeding. In two patients the laser light was seen to come through to the other side of the uterus and this required stopping treatment, repositioning the needles before completing the treatment. In one patient the tip of the quartz fibre was charred and broke off. In attempting to retrieve this 1mm charred tip – it disintegrated. Peritoneal irrigation and suction was done. The loss of the fibre tip was explained to the woman.

### 8.2.10 Pain after laparoscopic ILP

14 out of the 16 women were discharged home the following morning. Two women were discharged home the second day after surgery – one because of severe shoulder tip pain requiring opiate analgesia and the other for observation after loss of a fibre tip at surgery. This woman was seen weekly in the outpatient clinic for 3 weeks mainly for discussion; follow up at 12 months did not reveal any adverse effects.

### 8.2.11 Infection following laparoscopic ILP

None of the women treated in either of these series had complications relating to sepsis.

### 8.2.12 Adhesions following laparoscopic ILP

Only 3 out of the 21 women who underwent ILP had subsequent surgery in the duration of the study. Information regarding adhesion formation following ILP is limited to these 3 cases.

One woman was scheduled for an interval TCRF as she had a large intramural fibroid with subserosal and intramural extension in addition to two other large intramural fibroids. Due to persisting menorrhagia she opted for a hysterectomy. At laparotomy no adhesions were seen at the sites of ILP.

The second woman wanted a hysterectomy for pressure effects. She was a referral from a consultant from another hospital. She did not satisfy the entry criteria for the study as clinically she had a 28 weeks gestation size uterus. As she was adamant that she did not want a hysterectomy or myomectomy, she was commenced on GnRh analogues for 6 months. The fibroids shrank to a gestation size of 16 weeks. She was then entered in to the study. She had two large fibroids. ILP was performed on the first fibroid only. The second fibroid was not accessible as it was situated below the first and was deep in the pouch of Douglas. Following ILP, the treated fibroid began to grow even after 6 months. It had increased in size by 28% at 12 months. The untreated fibroid was also monitored by MRI and was found to have increased by 133%. During this time she had discontinued the GnRh analogues.

The third woman underwent ILP for pressure effects and a deep pelvic ache in the right iliac fossa which was non cyclical. At laparoscopy prior to commencement of ILP, she was found to have dense pelvic adhesions which involved the appendix and both fallopian tubes. Adhesiolysis was required to visualise the uterus and adnexae. ILP was done to 2 fibroids. One fibroid shrank by 72% and the other fibroid was not measurable at 6 months. At her post operative visit discussion she opted for adhesiolysis, appendicectomy and bilateral salpingostomy. This was undertaken together with the surgeons. A laparotomy was done and even though there were dense adhesions around the appendix there were only filmy adhesions at the ILP sites which were easily separated. At open myomectomy for the remaining second fibroid there was no difficulty in finding a plane of cleavage.

#### 8.2.13 Long term follow up of laparoscopic ILP

In the duration of this study, four women with single fibroids had MRI follow up of the treated fibroids for greater than 12 months. Two women had an MRI at 17 – 18 months and two women at 22 months. Figure 88 shows the volume changes of these fibroids.

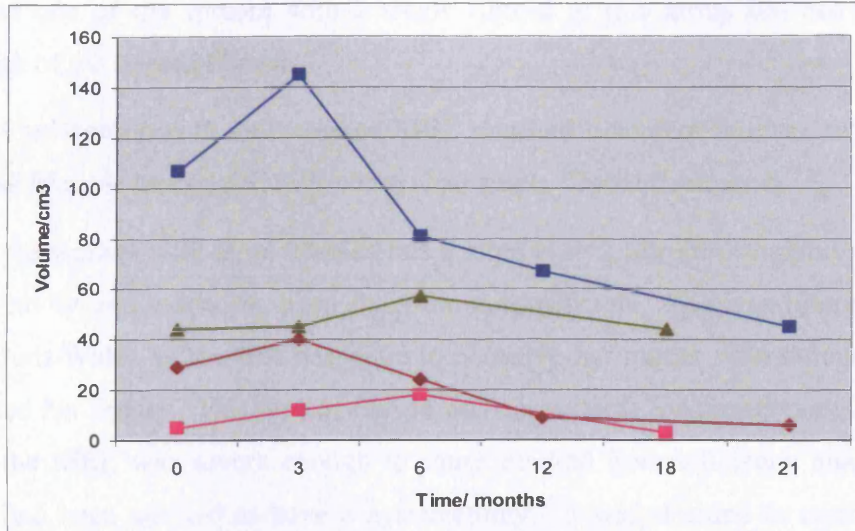


Figure 88 Graphical representation of volume changes of laparoscopic ILP treated fibroids followed up to greater than 12 months

### 8.3 Discussion

Interstitial Laser Photocoagulation has been shown to be a safe, well tolerated procedure that can produce marked shrinkage of fibroids. The few complications encountered were minor, easily dealt with and did not have any sequelae. Although all patients were kept in hospital overnight according to the study protocol, it is now considered that the procedure can be undertaken as a day case.

#### 8.3.1 Effect of ILP on symptoms

This study was designed primarily to document the response of individual fibroids to ILP. In most cases, the clinical responses were only assessed subjectively. Furthermore this group of women were highly committed to avoiding any form of conventional surgery and this could result in bias in favour of laparoscopic ILP.

##### Effect of ILP on menstrual blood loss

Nevertheless, nine of the 13 patients presenting with menorrhagia as the principal symptom reported an improvement. Two of these women also complained of pressure effects and had both a transcervical resection of a coexisting type 1 submucous fibroid and laparoscopic ILP for the intramural and subserous fibroids. Relief of both the MBL and the pressure effects were reported. It was interesting to

note that one of the women with a single fibroid in this group did not have any shrinkage of the treated fibroid.

In the four women with an increased MBL that had treatment failures, two women had three fibroids treated and two women had single fibroid treatments.

One of the women with three fibroids had a large type 2 fibroid occupying the entire uterine cavity and extending deep in to the myometrium. She was referred to our centre from Wales as she was desperate to conserve her uterus even though she had completed her family. This type of fibroid was not suitable for transcervical resection and as the MBL was severe enough to cause marked iron deficiency anaemia this patient had been advised to have a hysterectomy. It was decided to treat all three fibroids with ILP and if significant shrinkage occurred to plan an interval resection of the submucous fibroid. Shrinkage of 95% (pre-treatment volume = 19 cm<sup>3</sup>) and 26% (pre-treatment volume = 23 cm<sup>3</sup>) of the other two fibroids occurred but the submucous fibroid enlarged by 60 % (pre-treatment volume = 57 cm<sup>3</sup>). There was a net increase in uterine volume of 10 cm<sup>3</sup> and her menorrhagia persisted with her eventually consenting to a hysterectomy.

The other woman with three fibroids (pre-treatment volumes of 353, 10 and 9 cm<sup>3</sup>) showed shrinkage of 8 % in the largest fibroid while curiously the two small fibroids grew by 70% and 11%. This was classified as a treatment failure even though there was a net reduction in uterine volume post treatment by 5%. The MBL was not severe enough to cause anaemia and this patient wishes to have another treatment with laparoscopic ILP. The remaining two women in the treatment failure group had single fibroids (volumes 105 and 95 cm<sup>3</sup>) one of which grew by 13 % and the other shrank by 4% but still do not wish to have conventional surgery.

#### Effect of ILP on pressure symptoms

Seven out of the eight women with pressure symptoms as the principal complaint reported significant improvement following treatment. This group of women had moderate sized fibroids. One of the women who wished to have ILP prior to assisted reproduction for male factor infertility had a 65% reduction of a 166 cm<sup>3</sup> fibroid at 6 months. Unfortunately she did not go ahead with in vitro fertilisation due to problems in the relationship.

The treatment failure in this group was the woman who had two large fibroids that required shrinkage in order to be entered into this trial. This was because the fundus of the fibroid uterus was at a point mid way between the umbilicus and the xiphisternum. It was not amenable to laparoscopic surgery. It was interesting to note that the fibroid that was not treated (pre-treatment volume = 153 cm<sup>3</sup>) grew by 133%, once GnRH analogues was discontinued post operatively, whereas the treated fibroid (pre-treatment volume = 115 cm<sup>3</sup>) grew by 28%. This is the only instance where we had a “control” and may suggest that ILP did curtail the growth of the treated fibroid.

#### Effect of ILP on fertility

Only one woman in series 2 underwent laparoscopic ILP to improve her chances of fertility. This was a 381 cm<sup>3</sup> intramural fibroid without submucous extension which showed 51% reduction in volume at 12 months post treatment. We have reported a previous series of women that underwent ILP where monitoring of the fibroids were by ultrasound scanning. In this series three patients presented with infertility. Two were not helped, but the third became pregnant 2 years after ILP at the age of 40, shortly after her last follow-up scan. She delivered a healthy infant vaginally at term.

There is evidence that uterine fibroids have some effect on fertility. Initial studies showed that there was a lower pregnancy rate in women that presented with uterine fibroids and two observational studies showed an association between myomas and infertility. Studies of women undergoing assisted conception have shown significantly decreased pregnancy and implantation rates in women with uterine fibroids. Initially this was shown to be due to the alteration of the uterine cavity because of the uterine fibroids. However there is evidence that fibroids that are intramural can also affect implantation rates. The difficulty is to prove that treatment of these fibroids would increase fertility. To date there is no randomised controlled trials to prove that treatment of fibroids improve fertility. As discussed in Chapter 1, the other uterine conserving surgical options are associated with post operative adhesions which may worsen the chances of fertility and be associated with weakness of the uterine wall from scarring following surgery with the risk of uterine rupture in subsequent pregnancy. ILP on the other hand is ideally suited for this clinical setting. It is minimally invasive, treatment being localised to the centre of the fibroid with much less damage to the normal myometrium than the other methods described in chapter 1. The limitations of ILP would be that some of the treated fibroid would

remain and it is not sure whether volume reduction alone rather than removal would improve fertility.

### 8.3.2 Factors affecting fibroid shrinkage with laparoscopic ILP

#### Significance of initial increase in fibroid size

As the study progressed, it became clear that the patients with the best long term response were the ones with the greatest increase in fibroid size in the first few weeks after ILP as seen in series 1. This early response is most likely due to oedema and inflammatory changes. Even at 6 months, three out of the 25 fibroids that showed shrinkage at 12 months were still larger than the pre treatment size and this is important in counselling women who contemplate having laparoscopic ILP in the future. The observation that early swelling was indicative of a good long term result has also been made when ILP is used to treat fibroadenomas of the breast (Lai LM et al. 89-94).

In the four women that MRI was repeated at 18 and 21 months post treatment, further reduction of the treated fibroids were noted. This is encouraging as it indicates that if ILP does work the effect is long lasting and may continue to produce shrinkage of the treated fibroids,

#### Pre Treatment volume of the fibroid

Our study failed to show a correlation between the pre treatment volume of the fibroid treated and the shrinkage obtained by ILP. The biggest fibroid treated in our group was 353 cm<sup>3</sup> and this showed a 58% reduction in volume at 12 months. We were unable therefore on the basis of shrinkage to determine a cut off for fibroids suitable for ILP.

#### Pre charring fibres prior to ILP

This was a pilot study and it has helped to clarify some of the technical issues associated with the treatment. The importance of adequately pre-charring the laser fibres has been underlined. Laboratory experiments in our centre (unpublished data) showed that light at the wavelength used in this study (805nm, in the near infra red part of the electromagnetic spectrum) is not strongly absorbed or scattered in excised fibroids. If there is no modification to the fibre tip, the laser beam can just burn a hole through the fibroid without coagulating a significant volume. However, if the tip is



adequately charred, the light is absorbed by the charring and converted into heat, so the tip acts as a point source of heat, which distributes the energy evenly in all directions. This has been documented more rigorously in liver tissue.(Amin et al. 113-20) In vivo, when more blood is present, one would expect more absorption of infra red light as it passes through fibroids, but our clinical results suggest that with poor pre-charring, useful coagulation is not achieved. There may be a better way to pre-char the fibre tips than by using a small quantity of the patient's blood, but we found that this works well and that the simple alternative of charring the tips in a naked flame is not good enough. Charring may occur spontaneously during light delivery and this is almost certainly what happened in the case of the largest fibroid in the inadequately pre-charred group, which did show considerable shrinkage. Other authors have not used pre-charred laser fibres, but treatments were at higher powers (5-8W) than in our study, which makes it likely that spontaneous charring occurred soon after the laser was switched on.

#### Optimum dosage for ILP

It is clear from tables 1-3 that there was no close correlation between the laser energy delivered and the fibroid shrinkage achieved. Each needle and fibre was inserted independently rather than using any sort of grid arrangement, so inevitably, positioning was imprecise. However increasing the number of pullbacks caused an increase in shrinkage as seen in series 2. This may be further improved in the future by matching the needle positions more exactly to the size and shape of each fibroid. The effect of ILP seems to vary not only between patient to patient but also between fibroids in the same patient. Hence the clinical efficacy is likely to depend just as much on biology of the fibroid being treated. In the treatment failures there was an increase in size of the fibroids and because of the small numbers and absence of a control we are unsure as to the significance of this. In the one patient with two fibroids where only one was treated, growth was significantly less in the treated fibroid.

#### 8.3.3 Conventional surgery following ILP

It is a major attraction of ILP that if it does not work initially, it can be repeated and it does not prevent conventional surgery being carried out at a later date if required. This was seen in the three women that required surgery post ILP. No adhesions

related to ILP were encountered and in the open myomectomy there was no difficulty in removing the fibroid as the plane of cleavage was conserved. This is a major factor why some surgeons do not use GnRH analogues prior to laparoscopic myomectomy.

#### 8.3.4 Comparison with other studies

Two other groups have reported interstitial laser treatment of uterine fibroids although there were differences in technique and less extensive documentation of the results than in the present series.

Law et al (Law and Regan 277-82), reported MRI guided ILP of uterine fibroids in 66 women with symptomatic fibroids who had been offered myomectomy or hysterectomy. 47 of these patients had MRI follow up at 3 months and 24 patients had an MRI scan at 12 months. The mean pre treatment volume was 618 cm<sup>3</sup>. The mean volume reduction at 3 months was 31% and at 12 months was 41%. MBL was reduced in eight patients complaining of increased MBL and there was an improvement in quality of life scores in these patients. The mean pre-treatment volume of fibroids was larger than our group which was limited by the need to insert a laparoscope safely in to the peritoneal cavity. Their group have reported a higher shrinkage rate than us, 31% at 3 months compared to 9% in our group and 41% at 12 months compared to 31% in ours. It is unsure from their paper whether the group of women that were followed up at 3 (70% of women entered into study) and 12 months (36% of women entered into the study) were the women in which ILP was successful. Our results would compare favourably if this were the case (25% mean shrinkage at 3 months and 50% mean shrinkage at 12 months). In one of our women, the pre treatment volume was measured after significant shrinkage with GnRh analogues (Fibroid No 6). This was not therefore a true measure of the pre treatment volume. Following ILP and stopping GnRh therapy there was significant regrowth of the fibroid. If this result is not taken into account the mean shrinkage at 12 months would be 46% in our group.

By far the largest series was reported by Chapman (Chapman 171-78;Law and Regan 277-82;Chapman 171-78), who treated 300 patients with a total of 950 fibroids. Of these, 73% were 3-6cm in diameter (measured by ultrasound) and it was stated that a single laser treatment made them disappear within 6 months although it is not clear what follow up examination was undertaken as most patients lived outside the country

in which they were treated. With such a large series, it is disappointing that there is not more information on the response of individual fibroids although there was a marked symptomatic improvement in most patients complaining of menorrhagia and dysmenorrhoea.

### 8.3.5 Laparoscopic ILP vs MRI guided ILP

There were no serious complications reported in any of the series. Our patients and those of Chapman were treated with laparoscopic guidance whereas Law et al treated theirs percutaneously with real time monitoring in an interventional MR scanner.

#### Safety issues

The MR scanner has the attraction that thermal changes in the treated lesions can be seen in real time, but it is difficult to be sure that this technique will provide adequate safeguards in all cases. Our own experience acted as a salutary reminder of the importance of direct visualisation of the sites being treated. Without this safeguard, the treatment that was seen to extend to the opposite side of a fibroid might have damaged adjacent normal tissues, oozing from the uterine puncture sites might have led to adhesion formation and the pre-existing adhesions seen in 2 patients might have been missed, risking thermal damage to the adherent bowel during delivery of the laser energy. Laparoscopy also permitted retraction of bowel from the uterus during ILP. In the patient of ours who had a hysterectomy 18 months after ILP because of a poor functional result, it was noted that there were no adhesions on the surface of the uterus. The one situation where we consider that laparoscopy is not necessary is for cervical polyps, where the needles and fibres can be inserted under direct vision with a speculum or colposcope. MRI guided ILP has the advantage however of not requiring a general anaesthetic and does not have the risk of minimal access surgery.

#### Procedure failure

Only situations where the dominant fibroid can be safely accessed through an anterior abdominal wall approach are suitable for MRI guided ILP. With laparoscopic ILP fibroids of both the anterior wall and posterior wall can be treated. However even with laparoscopic ILP access is sometimes difficult with very big fibroids and hence this approach is limited to a 16 week gestation size fibroid. However as some of the fibroid remains after treatment the suitability of ILP as a procedure in bigger fibroids is questionable.

#### **8.4 Conclusions**

In conclusion, we have demonstrated that ILP is a safe, effective and a technically straightforward procedure that can shrink fibroids and give symptomatic relief. It requires relatively little surgical skill and carries less risk of postoperative adhesions than other local ablative techniques and less risk of precipitating bleeding that is difficult to control than open myomectomy. Patient satisfaction is high and the procedure can be performed as a day case. Further evaluation is required in a larger number of patients with more objective methods of assessing symptoms but it does appear to have considerable promise as a simple therapeutic option for shrinking moderate sized fibroids.

## **SECTION 3 – CONCLUSIONS**

### **CHAPTER 9**

<b>9.1</b>	<b>INTRODUCTION .....</b>	<b>211</b>
<b>9.2</b>	<b>SUMMARY OF THE OUTCOMES OF THE LITERATURE REVIEW .....</b>	<b>211</b>
<b>9.3</b>	<b>OBJECTIVES OF THE THESIS .....</b>	<b>214</b>
<b>9.4</b>	<b>MAJOR FINDINGS OF THE THESIS AND INTEGRATION WITH PREVIOUS WORK</b>	<b>214</b>
<b>9.5</b>	<b>STRENGTHS AND LIMITATIONS OF THIS THESIS .....</b>	<b>219</b>
<b>9.6</b>	<b>FUTURE AVENUES OF RESEARCH .....</b>	<b>220</b>

# [9] Conclusions

## **9.1 Introduction**

This thesis was concerned with the development of photodynamic therapy of the endometrium and interstitial laser photocoagulation of uterine fibroids as alternatives to hysterectomy. The purpose of the research was to

- 1) Evaluate the PDT effect on rabbit endometrium after the topical application of disulphonated aluminium phthalocyanine.
- 2) Evaluate the technique of laparoscopic interstitial laser photocoagulation of uterine fibroids

## **9.2 Summary of the outcomes of the literature review**

The literature review found that hysterectomy is still widely used for the treatment of women with heavy menstrual periods. Although it gives the highest patient satisfaction score it is associated with significant morbidity and even mortality. The two most common reasons for hysterectomy for heavy periods have been identified as dysfunctional uterine bleeding (DUB) and uterine fibroids.

The medical treatments used for women requiring fertility are tranexamic acid and mefenamic acid. In women not requiring fertility, long cycle high dose progestagen therapy, Danazol, Gestrinone, GnRha therapy and the LNG-IUS may be used. The

efficacy of these treatments and their place in the current treatment of DUB has been extensively researched in Chapter 1. It was found that long term medical treatment only caused a 50% reduction in MBL which was reversed when treatment stopped. Furthermore medical treatment was associated with side effects that significantly reduced quality of life and resulted in discontinuation of therapy. The LNG-IUS which was initially thought to significantly reduce the rate of hysterectomy has been disappointing with a discontinuation rate of almost 25% with 50% of women requiring additional treatment at 5 years of follow up. There are similarly no effective long term medical treatments for uterine fibroids.

Surgical techniques have been developed as an alternative to hysterectomy. First generation techniques rely on operative hysteroscopy to resect or ablate the endometrial lining up to the stratum basalis and the superficial layer of the myometrium. The efficacy of these techniques is operator dependant with potential complications of bleeding, infection, uterine perforation and dilutional hyponatraemia resulting from fluid shifts with the use of distension media like 1.5% glycine.

Second generation endometrial ablative techniques were subsequently developed that did not require operator skill, reduce the complication rate and could potentially be used in an outpatient setting. The number of techniques that have been developed reflect the economic impact of the problem. These techniques and their efficacy rates with studies comparing first and second generation methods have been reviewed in Chapter 2. This shows that while MBL reduction rates have been quoted at 73-90%, there are still complications from the thermal effect which these techniques rely on for destruction of the uterine endometrium. Furthermore, studies consistently show equipment failure of up to 10% with most women still requiring a general anaesthetic. Post operative uterine synechiae make subsequent evaluation of the endometrium difficult in the event of a woman developing abnormal uterine bleeding.

Uterine conserving surgical methods for uterine fibroids include myomectomy, uterine artery embolisation or clipping and myolysis. Details of these procedures including routes of surgery, success rates, potential complications and the evidence available have been reviewed in Chapter 2. Studies have shown that myomectomy is associated with significant recurrence rates of up to 50% at 5 years with post operative adhesions which may involve both bowel and omentum. Myolysis so far has been done using high power with significant post operative adhesions. The

conservative treatment that has shown the best potential is uterine artery embolisation. While this causes a reduction in fibroid size of up to 50% it is associated with significant complications including fatal sepsis, post embolisation syndrome, post procedural pain that requires narcotic analgesia and a premature menopause in the older woman. It is therefore still not used for women requiring fertility.

From the literature review of the currently available medical and conservative surgical alternatives to hysterectomy in women with DUB and uterine fibroids, it is evident that further research is required to find the ideal method for the treatment of these conditions which place a high socio economic burden on our national health service.

Photodynamic therapy is an exciting alternative to the current second generation techniques for the treatment of DUB. It is a non thermal effect and therefore does not have the potential thermal complications of the existing techniques. PDT causes minimal myometrial damage and therefore will not evoke scarring. The reduced likelihood of intra uterine synechiae would be an advantage if subsequent evaluation of the endometrium is required. Little operator skill is required and the technique can be readily adapted to the out patient setting.

A literature review of PDT to the endometrium is done in chapter 3. These studies involve very small numbers and are mainly in the form of case reports. The photosensitiser used in these studies was 5 amino laevulinic acid (ALA). One of the reasons for choosing ALA is that it is activated by light in the red part of the spectrum where tissue penetration is maximal, has a minimal duration of skin photosensitivity if given systemically and because it has been well studied in other organs with good results. Light delivery to the uterine cavity in most of the studies have been by custom made balloons and in some studies the commercially available balloon device marketed as Medlight. Results have so far been disappointing. This may be due to the fact that the tissue damage produced by ALA is not sufficient and that the light delivery devices used did not produce uniform illumination of the uterine cavity.

Michelle Judd investigated the use of an alternative photosensitiser – disulphonated aluminium phthalocyanine - for PDT of the endometrium in the rabbit model. She compared the PDT effect after intravenous use of AIS2Pc with that of ALA. Her results showed that the PDT damage with AIS2Pc was much greater when compared to ALA. This however also included disappearance of a rabbit uterus after treatment



with the formation of adhesions. Regeneration of rabbit endometrium was only patchy at 28 days. These results were exciting but could not be taken forward in to a clinical setting because of the risk of cutaneous photosensitivity associated with systemic administration of AlS<sub>2</sub>Pc and it was not approved for clinical use in the United Kingdom.

The literature available on interstitial laser photocoagulation of uterine fibroids is also discussed in Chapter 3. Evidence is limited to a single surgeon on a large number of women outside a research setting. Most of the women treated were private patients that came to the United Kingdom for treatment. Follow up after treatment was therefore difficult with no imaging used to assess fibroid response to ILP. The publication of these case series however do document that ILP for uterine fibroids is a safe and feasible therapy.

### **9.3 Objectives of the thesis**

The objectives of this thesis therefore were to

- 1) Compare available light delivery devices for the human uterus with custom made devices
- 2) Investigate the topical application of AlS<sub>2</sub>Pc for rabbit endometrial PDT
- 3) Investigate ILP for the treatment of uterine fibroids with objective follow up by MRI scans and effect on clinical symptoms

### **9.4 Major findings of the thesis and integration with previous work**

#### **9.4.1 Intra uterine light delivery – Balloon vs non balloon devices**

Dwyers group investigated the use of embedding titanium chips into silicon balloons used for light delivery. Experiments showed that light was internally reflected and transillumination of the balloons was increased. Using this formula, two different sizes of balloons were made to fit uteri with cavity lengths of 7cms and 10 cms. In one of the smaller balloons, two light fibres were used to see if this increased intra uterine light delivery.

However, Tadir's group claimed improvements in intrauterine light delivery by using three light fibres without enclosing them in a balloon device. A trifurcator (three laser fibres) used for thermal destruction of the endometrium was modified to deliver light without effecting thermal damage. A bifurcator was also made using two clear plastic tubes through which two laser fibres could be passed. These devices were compared with the commercially available Medlight intra uterine light delivery balloon.

The results showed that the non balloon devices were more effective in producing a uniform illumination at all sites of the uterine cavity. This is an important finding as effective PDT relies on every area of the uterine endometrium receiving a minimum threshold dose of light. Intra uterine light delivery for both the modified trifurcator and the bifurcator were better than the currently used Medlight balloon. The addition of titanium chips to the silicon balloons did not appear to improve intra uterine light delivery when compared to the Medlight balloon. These experiments also demonstrated a marked reduction in light delivery in the presence of intra uterine pathology like a septum, fibroids and adhesions from a previous endometrial resection. It would appear therefore that PDT would not be effective in these situations.

This is the first time an attempt has been made to compare the different technologies of intra uterine light delivery. Embedding the balloons with titanium chips as described by Dwyer did not enhance illumination in the uterus when compared to the Medlight balloon. Bifurcators and trifurcators as described by Tadir's group were more efficient in producing global intra uterine illumination than the currently used Medlight balloon.

#### 9.4.2 PDT of rabbit endometrium after topical application of AIS2Pc – as effective as systemic AIS2Pc?

The pharmacokinetics of AIS2Pc in the rabbit uterus after topical instillation was investigated. This information is invaluable for determining the optimal parameters for PDT. A validated technique for measuring the fluorescence produced by AIS2Pc was used for quantifying the amount of AIS2Pc in the different layers of the uterus. The highest concentration of AIS2Pc was found in the endometrium at 30 minutes and fell gradually to the 6 hour time point and then rose again. The selectivity of the

distribution of the drug for the endometrium when compared to the stroma and the underlying myometrium increased with time.

These results are similar to those described by Michelle Judd (systemic  $\text{AlS}_2\text{Pc}$ ) who also showed two peaks with a reduced concentration at 6 hours. Although drug concentrations in our experiment were highest at 30 minutes we did not use this time point for PDT as there was still a lot of drug present in the lumen of the uterus which would have interfered with light reaching the deeper parts of the endometrium. Washing the drug out would not be clinically feasible.

It was decided to investigate PDT of the rabbit endometrium after topical application of  $\text{AlS}_2\text{Pc}$  using drug light intervals of 1, 3 and 6 hours. The PDT effect obtained by increasing light doses from 50 to 100 Joules was also investigated. The 3 hour drug light delivery interval and a light dose of 100 Joules gave the best results. There was a selective destruction of the rabbit endometrium which was 100 % at 3 days and 13 days and was of sufficient depth that regeneration was absent in one out of the three rabbits examined 28 days following PDT.

PDT with topical application of  $\text{AlS}_2\text{Pc}$  did not cause any of the extra uterine effects seen with systemic  $\text{AlS}_2\text{Pc}$ . In none of the animals were there any abdominal adhesions or any serosal effects. In all the uterine specimens there were no intrauterine adhesions other than for a flattening of the rugae. The PDT damage to the endometrium however was comparable to that seen with systemic  $\text{AlS}_2\text{Pc}$  indicating a high degree of selectivity with topical administration. This confirmed the pharmacokinetics. This degree of selectivity is similar to studies on the rabbit model after PDT with both topical and systemic ALA. This thesis further highlights the importance of adequate light delivery for effective PDT. Increasing the light illumination from 50 to 100 Joules had a dramatic effect on the PDT damage that occurred.

As described in Chapter 5, even after cryosurgery to the rabbit endometrium, complete regeneration is seen in 21 to 30 days. This is due to the large infolding of the rabbit endometrium and a far greater potential for regeneration than in humans. Complete absence of regeneration in one out of three rabbits at 28 days, with only areas of patchy regeneration in the other two are encouraging results when compared to similar studies using ALA as the photosensitiser.

This research shows that PDT of the rabbit endometrium after topical application of AIS2PC is as effective as systemic AIS2PC without the systemic side effects. The selectivity demonstrated is similar to that of ALA. It is therefore an exciting alternative to ALA for PDT of the human endometrium.

#### 9.4.3 Interstitial laser photocoagulation of uterine fibroids – effect on fibroid size and women’s symptoms.

ILP as a technique for the treatment of uterine fibroids worked in 80% of women. At 6 weeks, 14 out of the 15 fibroids (93%) showed an expansion in fibroid volume. The mean expansion in volume was 23%. At the 3 month follow up 7 out of the 24 fibroids measured had still shown expansion (29%) with a mean fibroid volume reduction of 19%. By 6 months 90% of all the fibroids that were eventually going to shrink at 12 months with treatment had done so with a mean volume reduction of 25% and at one year there was a mean shrinkage of 50%.

ILP for uterine fibroids did not work in 20% of the women treated. In this group of women there was a mean increase in fibroid volume of 36%. This was difficult to interpret as there was no control group and serial scans were not done prior to ILP to know if these were fibroids that were rapidly growing. The biology of these tumours varies considerably. In 2 women, three fibroids were treated. Curiously, in both women, one of the three fibroids grew with treatment while the other two fibroids shrank. In a woman that had two fibroids where only one was treated (the other being non accessible in the pouch of Douglas), the treated fibroid increased in volume by 28% while the untreated fibroid grew by 133%. Further research is required to understand the biology of these tumours and whether there are in fact sub types of fibroids.

Most women reported symptom improvement with MBL and pressure effects. This was not done in an objective manner and may be biased as this group of women were highly motivated and did not want conventional therapy. The symptoms that were best served by ILP were pressure effects.

This study confirmed previous work that ILP is a safe and feasible procedure. All women were admitted for an overnight stay because of the protocol. This technique however can be developed as a day care procedure. There were no problems with

post operative pain, sepsis and adhesions in the 3 women who underwent subsequent surgery.

Other studies using MRI guided thermal ablation with real time thermography to ascertain treatment times have shown similar results. Advantages of this method over ours are that a general anaesthetic is not required and complications associated with minimal access surgery are avoided. However this method is limited to anterior wall fibroids and to centres with access to interventional MRI scanners. In a couple of women treated with laparoscopic ILP, bipolar cautery had to be used to the entry sites in the fibroid to stop bleeding. Two women needed adhesiolysis in order to access the fibroid before treatment. One woman had a transcervical resection of a sub mucous fibroid and another treatment of pelvic endometriosis which was the cause of her pelvic pain. None of these procedures would have been possible with MRI guided thermal ablation.

The current treatment that is gaining popularity is uterine artery embolisation. This technique is an alternative to myomectomy and hysterectomy in women not wishing conventional surgery with its attendant morbidity and even mortality. However UAE is not without complications as discussed in chapter 2 of the thesis.

This thesis suggests that comparable fibroid volume reduction may be obtained by using ILP. The advantages are that none of the women treated had any of the side effects that are reported consistently with UAE. Theoretically as minimal myometrial damage occurs during treatment, ILP may be offered to women who seek fertility. Another advantage is that other diseases of the pelvis like endometriosis and adhesions may be treated at the same time.

The complications that were of some concern were the breaking off of the tip of the fibre after ILP and the burn back effect along the length of the fibre. This becomes possible as after being activated, charring occurs making it more brittle. This complication has also been reported with ILP for breast fibroadenomas. Modification of the fibre should be done to reduce the likelihood of this complication.

## **9.5 Strengths and limitations of this thesis**

### **9.5.1 PDT of the endometrium**

The experimental methods that have been used for the investigation of topical AIS2Pc are standardised and have been validated by previous researchers. The rabbit model was chosen as it is a small animal, has two uterine horns (which doubles the result yield and can act as its own control when required) is a reflex ovulator with copulation (hence timing of experiments were not necessary) and has been extensively used by other researchers using other photosensitisers for PDT. Valid comparisons could then be made. Tissue processing and storage was done with great care with training by expert histopathologists. For all measurements, two independent observers took readings. The other observer did not use any of this data for her thesis and was therefore unbiased. An average was then taken and if there was a significant difference the slide was re visited and analysed again. All animals were handled with the greatest of care in accordance to the rules and regulations of the home office.

In the pharmacokinetics, two and sometimes only one animals were used at each time point. However these experiments compared the concentrations of the drug at different tissue levels that were measured and not absolute concentrations and therefore would not have affected the results. The absolute minimum numbers of animals were used in keeping with the ethos of animal experiments and to reduce cost.

One of the problems of the systemic administration of AIS2Pc is photosensitisation. It is for this reason that topical application of AIS2Pc was investigated. Even though there were no features of systemic photosensitisation in any of the animals treated we could have objectively determined this by quantifying the concentration of AIS2Pc in rabbit skin specimens. Unfortunately we did not think of this at the time the study was designed.

### **9.5.2 Interstitial laser photocoagulation of uterine fibroids**

The technique for ILP was carefully thought out and the number of fibres and power used were based on previous studies that showed that one fibre produced an elliptical zone of necrosis of about 1.4 cm. A 4 way beam splitter was used to reduce treatment times. Treatment parameters were changed in the second series to see if increasing

the power and using multiple pull backs affected therapy. Documentation and data collection was complete for nearly all the women with only one woman who did not attend for follow up as she migrated to Australia. MRI scans, the gold standard for the visualisation and measurement of uterine fibroids, was used to evaluate the effect of ILP on uterine size. This is in keeping with reports of other conservative modalities of treatment like UAE and MRI guided thermal ablation. A program was created with the consultant radiologist so that the same sections and same measurements were taken when women attended for their scans. Two independent observers took measurements of the uterine fibroids. There was no knowledge that the fibroid that they were measuring was treated or not. This removed observer bias.

The limitations are the use of the Tuohy needles which were used. These have the attraction of 1 cms graduation which are easily visible laparoscopically and enable accurate placement. The disadvantage is the curved ends. This makes it technically difficult to withdraw the used fibre into the trocar of the needle. In one woman this charred bit of glass disintegrated. Extensive peritoneal lavage was done but still lead to a lot of anxiety for the woman.

There was no objective assessment of the symptoms. This was not one of the primary aims of this study but it would have benefited from more objective instruments being used rather than a subjective assessment by the woman undergoing treatment

## **9.6 Future avenues of research**

### **9.6.1 PDT of the endometrium**

One of the draw backs of animal experiments and the results of this thesis is that the same results may not be reproduced in humans. However it is important to understand the effect of the drug on animals before permission may be sought for human testing. AIS2Pc may now be considered for clinical trials of PDT of the endometrium in humans. Before this may be done it is important to understand the pharmacokinetics of the drug in the human uterus. This may be achieved by instilling the drug in the uterus at different time points prior to hysterectomy for dysfunctional uterine bleeding. The relative concentrations of the drug in the different structures of the uterus may be evaluated using the technique described in this thesis. It would be interesting to see if the selectivity seen in the rabbit uterus is maintained. The time

point at which the maximum endometrial concentration of AIS2Pc is found would then determine the optimal drug light interval.

Once the optimal drug light interval is obtained, light delivery must be optimised. From the results of this thesis the best device would be a non balloon light diffuser fibre. The trifurcator as developed by Tadirs group has been patented in the USA as shown in Figure 89.

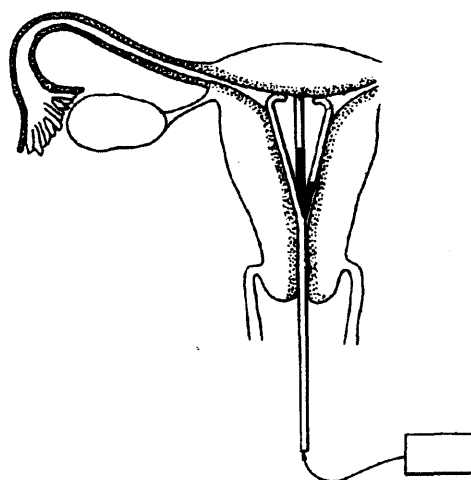


Figure 89 Diagrammatic representation of the trifurcator ideally situated in the uterine cavity.

PDT may be then performed in women awaiting hysterectomy for DUB. Histological evaluation of the PDT effect would be gained from the hysterectomy specimens. It is probable that women gaining relief from PDT would not proceed to hysterectomy.

#### 9.6.2 ILP for uterine fibroids

There are two important considerations for future research in this field. The first is the further development of the technique. The second is to determine the exact place for ILP of uterine fibroids in current gynaecological practice.

##### Further developments of the technique

In our institute, a previous researcher used ultrasound to follow up a group of women treated with ILP. The results obtained in this small group of women were not different from that obtained by MRI. MRI outside a research setting would not be feasible and may be replaced by ultrasound. Doppler probes which may be used at laparoscopy are being developed. It would be interesting to see if using this technology, the blood flow to the uterine fibroids may be coagulated in addition to



performing ILP. This may produce a much bigger reduction in the fibroid volume. Results would further improve with better dosimetry. The instrumentation may be modified further in terms of using needles with straight ends instead of the Tuohey needles that were used in this study. Comparison of an MRI needle and a Tuohey needle are shown in Figure 90.




Figure 90 Photograph of ends of Tuohey needle (above) and MRI needle (below). This illustrates the curved end of the Tuohey needle which encourages breakage of the charred tip when the fibre is withdrawn following ILP. The advantage of the needle however is the cm graduations which facilitate accurate needle placement.

We are currently investigating the straight end needles. The advantage that we envisage is that by withdrawing the fibre into the sheath before removing it we could minimise the risk of breakage.

#### Exact place of ILP in current gynaecological practice

ILP may be used to cause shrinkage in small to moderate size fibroids in women whose main symptoms are pressure effects. There is however growing evidence that small fibroids that are intramural affect fertility especially in women requiring assisted reproductive techniques. Minimal endometriosis also has similar effects by altering the hormonal milieu of the pelvis. It would be interesting to see if ILP of these fibroids would improve fertility. Advantages of ILP are that endometriosis that is present may be treated at the same time.

## LIST OF REFERENCES

A Scottish audit of hysteroscopic surgery for menorrhagia: complications and follow up. Scottish Hysteroscopy Audit Group. *Br.J Obstet Gynaecol* 102.3 (1995): 249-54.

Amin, Z., Buonaccorsi, G., Mills, T, Harries S, Lees, WR, and Bown SG. Interstitial Laser Photocoagulation: Evaluation of a 1320 nm Nd-YAG and an 805 nm Diode Laser: the significance of charring and the value of precharring the fibre tip. *Lasers in Medical Science* 8, 113-20. 1993.

Amin, Z. et al. "Hepatic metastases: interstitial laser photocoagulation with real-time US monitoring and dynamic CT evaluation of treatment." *Radiology* 187.2 (1993): 339-47.

Amso, N. N. et al. "Uterine endometrial thermal balloon therapy for the treatment of menorrhagia: long-term multicentre follow-up study." *Hum.Reprod.* 18.5 (2003): 1082-87.

Amso, N. N. et al. "Uterine thermal balloon therapy for the treatment of menorrhagia: the first 300 patients from a multi-centre study. International Collaborative Uterine Thermal Balloon Working Group." *Br.J Obstet Gynaecol* 105.5 (1998): 517-23.

Arai, Y. et al. "Impact of interventional therapy for benign prostatic hyperplasia on quality of life and sexual function: a prospective study." *J Urol.* 164.4 (2000): 1206-11.

Ashermann JG. Traumatic intrauterine adhesions. *J Obstet Gynaecol Brit Empire* 57, 892-96. 1950.

Barrington, J. W. and P. Bowen-Simpkins. "The levonorgestrel intrauterine system in the management of menorrhagia." *Br.J Obstet.Gynaecol.* 104.5 (1997): 614-16.

Basu, S., B. Ravi, and R. Kant. "Interstitial laser hyperthermia, a new method in the management of fibroadenoma of the breast: A pilot study." *Lasers Surg.Med.* 25.2 (1999): 148-52.

Ben Baruch, G. et al. "Immediate and late outcome of vaginal myomectomy for prolapsed pedunculated submucous myoma." *Obstet.Gynecol.* 72.6 (1988): 858-61.

BENSON, R. C. and V. D. SNEEDEN. "Adenomyosis: a reappraisal of symptomatology." *Am.J Obstet Gynecol.* 76.5 (1958): 1044-57.

Berkowitz, R. P., F. L. Hutchins, Jr., and R. L. Worthington-Kirsch. "Vaginal expulsion of submucosal fibroids after uterine artery embolization. A report of three cases." *J.Reprod.Med.* 44.4 (1999): 373-76.

Bird, C. C., T. W. McElin, and P. Manalo-Estrella. "The elusive adenomyosis of the uterus--revisited." *Am.J Obstet Gynecol.* 112.5 (1972): 583-93.

Bonnett R. Photodynamic Therapy in Historical Perspective. *Rev.Contemp.Pharmacother.* 10, 1-17. 1999.

Bown, S. G. "Phototherapy in tumors." *World J Surg.* 7.6 (1983): 700-09.

Bown, S. G. et al. "Photodynamic therapy for cancer of the pancreas." *Gut* 50.4 (2002): 549-57.

Bradley, E. A. et al. "Transcatheter uterine artery embolisation to treat large uterine

Bressler, N. M. "Age related macular degeneration. New hope for a common problem comes from photodynamic therapy." *BMJ* 321.7274 (2000): 1425-27.

Brunereau, L. et al. "Uterine artery embolization in the primary treatment of uterine leiomyomas: technical features and prospective follow-up with clinical and sonographic examinations in 58 patients." *AJR Am.J.Roentgenol.* 175.5 (2000): 1267-72.

Cameron, I. T. et al. "The effects of mefenamic acid and norethisterone on measured menstrual blood loss." *Obstet Gynecol.* 76.1 (1990): 85-88.

Cameron, I. T. et al. "The effects of danazol, mefenamic acid, norethisterone and a progesterone-impregnated coil on endometrial prostaglandin concentrations in women with menorrhagia." *Prostaglandins* 34.1 (1987): 99-110.

Carlson, K. J., B. A. Miller, and F. J. Fowler, Jr. "The Maine Women's Health Study: I. Outcomes of hysterectomy." *Obstet Gynecol* 83.4 (1994): 556-65.

Carr, B. R. et al. "An evaluation of the effect of gonadotropin-releasing hormone analogs and medroxyprogesterone acetate on uterine leiomyomata volume by magnetic resonance imaging: a prospective, randomized, double blind, placebo-controlled, crossover trial." *J Clin.Endocrinol.Metab* 76.5 (1993): 1217-23.

Chapman, J. A. et al. "Effect of administration route and estrogen manipulation on endometrial uptake of Photofrin porfimer sodium." *Am.J Obstet Gynecol.* 168.2 (1993): 685-92.

Chapman, R. "New therapeutic technique for treatment of uterine leiomyomas using laser-induced interstitial thermotherapy (LITT) by a minimally invasive method." *Lasers Surg Med.* 22.3 (1998): 171-78.

Chimbira, T. H. et al. "Reduction of menstrual blood loss by danazol in unexplained menorrhagia: lack of effect of placebo." *Br.J Obstet Gynaecol* 87.12 (1980): 1152-58.

Claessens, E. A. and C. A. Cowell. "Dysfunctional uterine bleeding in the adolescent." *Pediatr.Clin.North Am.* 28.2 (1981): 369-78.

Clark, T. J. et al. "Hysteroscopic treatment of symptomatic submucous fibroids using a bipolar intrauterine system: a feasibility study." *Eur.J.Obstet.Gynecol.Reprod.Biol.* 100.2 (2002): 237-42.

Corson, S. L. et al. "Interim results of the American Vesta trial of endometrial ablation." *J Am.Assoc.Gynecol.Laparosc.* 6.1 (1999): 45-49.

Coulter, A. et al. "Outcomes of referrals to gynaecology outpatient clinics for menstrual problems: an audit of general practice records." *Br.J.Obstet.Gynaecol.* 98.8 (1991): 789-96.

Coulter, A., Kelland, J., and Long, A. *The Management of Menorrhagia. Effective Healthcare Bulletin* . 1995.

Coulter, A. et al. "Treating menorrhagia in primary care. An overview of drug trials and a survey of prescribing practice." *Int.J Technol.Assess.Health Care* 11.3 (1995): 456-71.

Coulter, A. et al. "Managing menorrhagia." *Qual.Health Care* 4.3 (1995): 218-26.

Coulter, A. H. "Photodynamic therapy using new photosensitizer shows promise for skin tumor treatment and possibility for psoriasis treatment." *J Clin.Laser Med.Surg.* 11.3 (1993): 149-50.

Coutinho, E. M. and M. T. Goncalves. "Long-term treatment of leiomyomas with gestrinone." *Fertil.Steril.* 51.6 (1989): 939-46.

Cramer, S. F. and A. Patel. "The frequency of uterine leiomyomas." *Am.J.Clin.Pathol.* 94.4 (1990): 435-38.

Cravello, L. et al. "[Hysteroscopic treatment of uterine fibromas]." *J.Gynecol.Obstet.Biol.Reprod.(Paris)* 24.4 (1995): 374-80.

Crosignani, P. G. et al. "Levonorgestrel-releasing intrauterine device versus hysteroscopic endometrial resection in the treatment of dysfunctional uterine bleeding." *Obstet Gynecol.* 90.2 (1997): 257-63.

Davies, A., R. Hart, and A. L. Magos. "The excision of uterine fibroids by vaginal myomectomy: a prospective study." *Fertil.Steril.* 71.5 (1999): 961-64.

de la Rosette, J. J. et al. "Interstitial laser coagulation in the treatment of benign prostatic hyperplasia using a diode-laser system with temperature feedback." *Br.J Urol.* 80.3 (1997): 433-38.

DeCherney, A. H. et al. "Endometrial ablation for intractable uterine bleeding: hysteroscopic resection." *Obstet Gynecol.* 70.4 (1987): 668-70.

Derman, S. G., J. Rehnstrom, and R. S. Neuwirth. "The long-term effectiveness of hysteroscopic treatment of menorrhagia and leiomyomas." *Obstet.Gynecol.* 77.4 (1991): 591-94.

Diamond, I. et al. "Photodynamic therapy of malignant tumours." *Lancet* 2.7788 (1972): 1175-77.

Dicker, R. C. et al. "Complications of abdominal and vaginal hysterectomy among women of reproductive age in the United States. The Collaborative Review of Sterilization." *Am.J.Obstet.Gynecol.* 144.7 (1982): 841-48.

Donnez, J. et al. "Endometrial laser intrauterine thermotherapy: the first series of 100 patients observed for 1 year." *Fertil.Steril.* 74.4 (2000): 791-96.

Dougherty, T. J. "Activated dyes as antitumor agents." *J Natl.Cancer Inst.* 52.4 (1974): 1333-36.

Dubuisson, J. B. et al. "Uterine rupture during pregnancy after laparoscopic myomectomy." *Hum.Reprod.* 10.6 (1995): 1475-77.

Duleba, A. J. et al. "A randomized study comparing endometrial cryoablation and rollerball electroablation for treatment of dysfunctional uterine bleeding." *J Am.Assoc.Gynecol.Laparosc.* 10.1 (2003): 17-26.

Dwyer, N., J. Hutton, and G. M. Stirrat. "Randomised controlled trial comparing endometrial resection with abdominal hysterectomy for the surgical treatment of menorrhagia." *Br.J Obstet Gynaecol* 100.3 (1993): 237-43.

Emanuel, M. H. et al. "Long-term results of hysteroscopic myomectomy for abnormal uterine bleeding." *Obstet.Gynecol.* 93.5 Pt 1 (1999): 743-48.

File Inventory, Evidence Report Technology Assessment Number 34. and AHRQ Publication No.01-E052. Management of Uterine Fibroids. Agency for Healthcare Research and Quality, Rockville, MD . 2001.

Frank, R. G. and J. D. Bos. "Photodynamic therapy for condylomata acuminata with local application of 5-aminolevulinic acid." *Genitourin.Med.* 72.1 (1996): 70-71.

Friberg, B. et al. "Endometrial destruction by hyperthermia--a possible treatment of menorrhagia. An experimental study." *Acta Obstet Gynecol.Scand.* 75.4 (1996): 330-35.

Friedman, A. J. et al. "Long-term medical therapy for leiomyomata uteri: a prospective, randomized study of leuprolide acetate depot plus either oestrogen-progestin or progestin 'add-back' for 2 years." *Hum.Reprod.* 9.9 (1994): 1618-25.

Friedman, A. J. et al. "A randomized, placebo-controlled, double-blind study evaluating the efficacy of leuprolide acetate depot in the treatment of uterine leiomyomata." *Fertil.Steril.* 51.2 (1989): 251-56.

Friedmann, W. et al. "Uterine rupture after laparoscopic myomectomy." *Acta Obstet.Gynecol.Scand.* 75.7 (1996): 683-84.

Gannon, M. J. "Photodynamic Therapy for the Treatment of Women With Menorrhagia." Diss. The University of Leeds, Research School of Medicine, 1999.

Gardner RL and Shaw, R. W. LHRH analogues in the treatment of menorrhagia. 149-59. 1990. Carnforth;Parthenon Press. Dysfunctional Uterine Bleeding. Shaw, R. W.

Goldfarb, H. A. "Nd:YAG laser laparoscopic coagulation of symptomatic myomas." *J.Reprod.Med.* 37.7 (1992): 636-38.

Goldrath, M. H., M. Barrionuevo, and M. Husain. "Endometrial ablation by hysteroscopic instillation of hot saline solution." *J Am.Assoc.Gynecol.Laparosc.* 4.2 (1997): 235-40.

Goldrath, M. H., T. A. Fuller, and S. Segal. "Laser photovaporization of endometrium for the treatment of menorrhagia." *Am.J Obstet Gynecol.* 140.1 (1981): 14-19.

Goldsmith, R. E. et al. "The menstrual pattern in thyroid disease." *J Clin.Endocrinol.Metab* 12.7 (1952): 846-55.

Goodwin, S. C. et al. "Uterine artery embolization for the treatment of uterine leiomyomata midterm results." *J Vasc Interv Radiol* 10.9 (1999): 1159-65.

Gordon AD, Buornaccorsi G, Broadbent JAM, and Bown SG. Interstitial laser photocoagulation for the treatment of uterine leiomyoma. *Br.J.Obstet.Gynaecol.* 104, 859-66. 1997.

Graves WP. Tumours of the uterus. Curtis AH. *Obstetrics and Gynecology* . 1933. Philadelphia, WB Saunders. Tumors of the uterus.

Hallberg, L. et al. "Menstrual blood loss--a population study. Variation at different ages and attempts to define normality." *Acta Obstet Gynecol.Scand.* 45.3 (1966): 320-51.

Hallez, J. P. "Single-stage total hysteroscopic myomectomies: indications, techniques, and results." *Fertil.Steril.* 63.4 (1995): 703-08.

Harries, S. A. et al. "Interstitial laser photocoagulation as a treatment for breast cancer." *Br.J Surg.* 81.11 (1994): 1617-19.

Harris, W. J. "Uterine dehiscence following laparoscopic myomectomy." *Obstet.Gynecol.* 80.3 Pt 2 (1992): 545-46.

Hart, R., B. G. Molnar, and A. Magos. "Long term follow up of hysteroscopic myomectomy assessed by survival analysis." *Br.J.Obstet.Gynaecol.* 106.7 (1999): 700-05.

Hawe, J. et al. "A randomised controlled trial comparing the Cavaterm endometrial ablation system with the Nd:YAG laser for the treatment of dysfunctional uterine bleeding." *BJOG.* 110.4 (2003): 350-57.

Hawe, J. A. et al. "Cavaterm thermal balloon ablation for the treatment of menorrhagia." *Br.J Obstet Gynaecol* 106.11 (1999): 1143-48.

Hendrickson MR and Kempson RL. Non-neoplastic conditions of the myometrium and uterine serosa. Copeland LJ and Jarrel JF. 452-67. 1980. Philadelphia, W.B.Saunders Co.

Higham, J. M. and R. W. Shaw. "The effect of thyroxine replacement on menstrual blood loss in a hypothyroid patient." *Br.J Obstet Gynaecol* 99.8 (1992): 695-96.

Higham, J. M. and R. W. Shaw. "A comparative study of danazol, a regimen of decreasing doses of danazol, and norethindrone in the treatment of objectively proven unexplained menorrhagia." *Am.J Obstet Gynecol.* 169.5 (1993): 1134-39.

Hodgson, D. A. et al. "Microwave endometrial ablation: development, clinical trials and outcomes at three years." *Br.J Obstet Gynaecol* 106.7 (1999): 684-94.

Hornstein, M. D. et al. "Leuprolide acetate depot and hormonal add-back in endometriosis: a 12-month study. Lupron Add-Back Study Group." *Obstet Gynecol.* 91.1 (1998): 16-24.

Hurskainen, R. et al. "Quality of life and cost-effectiveness of levonorgestrel-releasing intrauterine system versus hysterectomy for treatment of menorrhagia: a randomised trial." *Lancet* 357.9252 (2001): 273-77.

Hutchins, F. L., Jr., R. Worthington-Kirsch, and R. P. Berkowitz. "Selective uterine artery embolization as primary treatment for symptomatic leiomyomata uteri." *J Am Assoc Gynecol Laparosc.* 6.3 (1999): 279-84.

Irvine, G. A. et al. "Randomised comparative trial of the levonorgestrel intrauterine system and norethisterone for treatment of idiopathic menorrhagia." *Br.J Obstet Gynaecol* 105.6 (1998): 592-98.

Itoh, Y. et al. "Photodynamic therapy of acne vulgaris with topical delta-aminolaevulinic acid and incoherent light in Japanese patients." *Br.J Dermatol.* 144.3 (2001): 575-79.

Jenkins, M. P. et al. "Clinical study of adjuvant photodynamic therapy to reduce restenosis following femoral angioplasty." *Br.J Surg.* 86.10 (1999): 1258-63.



Judd, M. D. "Local Destruction of the Endometrium." Diss. Univerisity of London, 1993.

Kjerulff, K. H. et al. "Patient satisfaction with results of hysterectomy." *Am J Obstet Gynecol* 183.6 (2000): 1440-47.

Lai LM, Craggs MA, Mumtaz, H., Ripley PM, Davidson, T. I., Kissin, M. W., Saunders C, Taylor, I., and Bown SG. Interstitial laser photocoagulation for fibroadenomas of the breast. *The Breast* 8, 89-94. 1999.

Lancoita R, Frigero LF, Patelli G, Di Tolla G, and Spreafico C. A fatal complication of percutaneous transcather embolisation for treatment of uterine fibroids (abstract). *SMIT/CIMIT 11th Annual Scientific Meeting*. Boston. 1999.

Law, P. and L. Regan. "Interstitial thermo-ablation under MRI guidance for the treatment of fibroids." *Curr.Opin.Obstet Gynecol* 12.4 (2000): 277-82.

Lipson, R. L., Gray MJ, and Baldes, E. J. Haematoporphyrin derivative for detection and management of cancer. *Proceedings 9th International Cancer Congress* , 393. 1966.

Liu, W. M. et al. "Laparoscopic bipolar coagulation of uterine vessels: a new method for treating symptomatic fibroids." *Fertil.Steril.* 75.2 (2001): 417-22.

Loh, C. S. et al. "Endogenous porphyrin distribution induced by 5-aminolaevulinic acid in the tissue layers of the gastrointestinal tract." *J.Photochem.Photobiol.B* 20.1 (1993): 47-54.

Magos, A. L., R. Baumann, and A. C. Turnbull. "Transcervical resection of endometrium in women with menorrhagia." *BMJ* 298.6682 (1989): 1209-12.

Maresh, M. J. et al. "The VALUE national hysterectomy study: description of the patients and their surgery." *BJOG.* 109.3 (2002): 302-12.

Matthewson, K. et al. "Biological effects of intrahepatic neodymium:yttrium-aluminum-garnet laser photocoagulation in rats." *Gastroenterology* 93.3 (1987): 550-57.

McLucas, B. et al. "Fatal septicaemia after fibroid embolisation." *Lancet* 354.9191 (1999): 1730.

Messmann, H. et al. "Enhancement of photodynamic therapy with 5-aminolaevulinic acid-induced porphyrin photosensitisation in normal rat colon by threshold and light fractionation studies." *Br.J Cancer* 72.3 (1995): 589-94.

Milsom, I. et al. "A comparison of flurbiprofen, tranexamic acid, and a levonorgestrel-releasing intrauterine contraceptive device in the treatment of idiopathic menorrhagia." *Am.J Obstet Gynecol.* 164.3 (1991): 879-83.

Molitor, J. J. "Adenomyosis: a clinical and pathological appraisal." *Am.J Obstet Gynecol.* 110.2 (1971): 275-84.

Muller, P. J. and B. C. Wilson. "Photodynamic therapy for recurrent supratentorial gliomas." *Semin.Surg.Oncol.* 11.5 (1995): 346-54.

Mumtaz, H. et al. "Laser therapy for breast cancer: MR imaging and histopathologic correlation." *Radiology* 200.3 (1996): 651-58.

Nathan, T. R. et al. "Photodynamic therapy for prostate cancer recurrence after radiotherapy: a phase I study." *J Urol.* 168.4 Pt 1 (2002): 1427-32.

National Health Service Executive. National schedule of reference costs May 1999. Appendix 1A.

Neuwirth, R. S. and H. K. Amin. "Excision of submucous fibroids with hysteroscopic control." *Am J Obstet Gynecol* 126.1 (1976): 95-99.

Nezhat, C. et al. "Laparoscopically assisted myomectomy: a report of a new technique in 57 cases." *Int.J.Fertil.Menopausal Stud.* 39.1 (1994): 39-44.

Nilsson, L. and G. Rybo. "Treatment of menorrhagia." *Am.J Obstet Gynecol.* 110.5 (1971): 713-20.

Nilsson, L. and L. Solvell. "Clinical studies on oral contraceptives--a randomized, doubleblind, crossover study of 4 different preparations (Anovlar mite, Lyndiol mite, Ovulen, and Volidan)." *Acta Obstet Gynecol.Scand.* 46.8 (1967): Suppl-31.

Nishida, M. "Relationship between the onset of dysmenorrhea and histologic findings in adenomyosis." *Am.J Obstet Gynecol.* 165.1 (1991): 229-31.

Nisolle, M, Smets M, and Gillerot S et al. Laparoscopic Myolysis with the Nd:YAG laser. *J.Gynecol.Surg* 9, 95-99. 1993.

O'Connor, H. and A. Magos. "Endometrial resection for the treatment of menorrhagia." *N.Engl.J Med.* 335.3 (1996): 151-56.

O'Dowd, Michael J, and Phillip Elliot. *History of Obstetrics and Gynaecology.* 411. 1994. New York.

Overton, C., J. Hargreaves, and M. Maresh. "A national survey of the complications of endometrial destruction for menstrual disorders: the MISTLETOE study. Minimally Invasive Surgical Techniques--Laser, EndoThermal or Endorescetion." *Br.J Obstet Gynaecol* 104.12 (1997): 1351-59.

Parker, W. H., Y. S. Fu, and J. S. Berek. "Uterine sarcoma in patients operated on for presumed leiomyoma and rapidly growing leiomyoma." *Obstet.Gynecol.* 83.3 (1994): 414-18.

Phillips, D. R. et al. "Transcervical electrosurgical resection of submucous leiomyomas for chronic menorrhagia." *J.Am.Assoc.Gynecol.Laparosc.* 2.2 (1995): 147-53.

Phipps, J. H. et al. "Treatment of functional menorrhagia by radiofrequency-induced thermal endometrial ablation." *Lancet* 335.8686 (1990): 374-76.

Preston, J. T. et al. "Comparative study of tranexamic acid and norethisterone in the treatment of ovulatory menorrhagia." *Br.J Obstet Gynaecol* 102.5 (1995): 401-06.

Prior, M. V. et al. "Treatment of menorrhagia by radiofrequency heating." *Int.J Hyperthermia* 7.2 (1991): 213-20.

Ravina, J. H. et al. "[Arterial embolization of uterine myoma: results apropos of 286 cases]." *J Gynecol Obstet Biol Reprod (Paris)* 29.3 (2000): 272-75.

Ravina, J. H. et al. "Recourse to particular arterial embolization in the treatment of some uterine leiomyoma." *Bull.Acad.Natl.Med.* 181.2 (1997): 233-43.

Ravina, J. H. et al. "Arterial embolisation to treat uterine myomata." *Lancet* 346.8976 (1995): 671-72.

RCOG/RCR Report. *Clinical recommendations of the use of uterine artery embolisation in the mangement of fibroids.* RCOG Press . 2001.

Royal College of General Practitioners. *Oral contraceptives and health.* 1974. Pitman.

Rybo, G. "Menstrual blood loss in relation to parity and menstrual pattern." *Acta Obstet Gynecol.Scand.* 45 (1966): Suppl-45.

Rydin, E. and P. O. Lundberg. "Letter: Tranexamic acid and intracranial thrombosis." *Lancet* 2.7975 (1976): 49.

Schlaff, W. D. et al. "A placebo-controlled trial of a depot gonadotropin-releasing hormone analogue (leuprolide) in the treatment of uterine leiomyomata." *Obstet Gynecol.* 74.6 (1989): 856-62.

Semm, K. and L. Mettler. "Technical progress in pelvic surgery via operative laparoscopy." *Am.J.Obstet.Gynecol.* 138.2 (1980): 121-27.

Sharp, N. C. et al. "Microwaves for menorrhagia: a new fast technique for endometrial ablation." *Lancet* 346.8981 (1995): 1003-04.

Shaw, R. W. "New approaches to the management of fibroids." *Curr.Opin.Obstet Gynecol.* 3.6 (1991): 859-64.

Shaw, R. W. and H. M. Fraser. "Use of a superactive luteinizing hormone releasing hormone (LHRH) agonist in the treatment of menorrhagia." *Br.J Obstet Gynaecol* 91.9 (1984): 913-16.

Sibille, A. et al. "Long-term survival after photodynamic therapy for esophageal cancer." *Gastroenterology* 108.2 (1995): 337-44.

Spies, J. B. et al. "Initial results from uterine fibroid embolization for symptomatic leiomyomata." *J Vasc.Interv.Radiol.* 10.9 (1999): 1149-57.

Stewart, A. et al. "The effectiveness of the levonorgestrel-releasing intrauterine system in menorrhagia: a systematic review." *BJOG.* 108.1 (2001): 74-86.

Stovall, T. G. et al. "GnRH agonist and iron versus placebo and iron in the anemic patient before surgery for leiomyomas: a randomized controlled trial. Leuprolide Acetate Study Group." *Obstet Gynecol.* 86.1 (1995): 65-71.

Stringer, N. H., J. C. Walker, and P. M. Meyer. "Comparison of 49 laparoscopic myomectomies with 49 open myomectomies." *J.Am.Assoc.Gynecol.Laparosc.* 4.4 (1997): 457-64.

Tavmergan E, Tavmergan EN, and Turker S. Preliminary results of 100 pelviscopic myomectomies. 4th Congress of the European Society for Gynaecological Endoscopy; Brussels. Gynaecological Endoscopy 4 [Supplement I], 68. 6-12-1995.

The Royal College of Obstetrics and Gynaecology. The initial management of menorrhagia. 1. 1998. RCOG Press.

Treloar, A. E. et al. "Variation of the human menstrual cycle through reproductive life." *Int.J Fertil.* 12.1 Pt 2 (1967): 77-126.

Turnbull, A. C. and M. C. Rees. "Gestrinone in the treatment of menorrhagia." *Br.J Obstet.Gynaecol.* 97.8 (1990): 713-15.

Van Eijkeren, M. A. et al. "Measured menstrual blood loss in women with a bleeding disorder or using oral anticoagulant therapy." *Am.J Obstet Gynecol.* 162.5 (1990): 1261-63.

Vancaillie, T. G. "Electrocoagulation of the endometrium with the ball-end resectoscope." *Obstet Gynecol.* 74.3 Pt 1 (1989): 425-27.

Vane, J. R. "Inhibition of prostaglandin synthesis as a mechanism of action for aspirin-like drugs." *Nat.New Biol.* 231.25 (1971): 232-35.

Vashisht, A. et al. "Fatal septicaemia after fibroid embolisation." *Lancet* 354.9175 (1999): 307-08.

Vercellini, P. et al. "Gonadotropin releasing hormone agonist for chronic anovulatory uterine bleeding and severe anemia." *J Reprod.Med.* 38.2 (1993): 127-29.

Vessey, M. P. et al. "The epidemiology of hysterectomy: findings in a large cohort study." *Br.J.Obstet.Gynaecol.* 99.5 (1992): 402-07.

Vollman, R. F. "The menstrual cycle." *Major.Probl.Obstet Gynecol.* 7 (1977): 1-193.

Walker, W. J. and J. P. Pelage. "Uterine artery embolisation for symptomatic fibroids: clinical results in 400 women with imaging follow up." *BJOG* 109.11 (2002): 1262-72.

Witt, J. D. et al. "Interstitial laser photocoagulation for the treatment of osteoid osteoma." *J Bone Joint Surg.Br.* 82.8 (2000): 1125-28.

Worthington-Kirsch, R. L., G. L. Popky, and F. L. Hutchins, Jr. "Uterine arterial embolization for the management of leiomyomas: quality- of-life assessment and clinical response." *Radiology* 208.3 (1998): 625-29.

Wyss, P. et al. "Benzoporphyrin derivative: a potent photosensitizer for photodynamic destruction of rabbit endometrium." *Obstet Gynecol.* 84.3 (1994): 409-14.

Wyss, P. et al. "Photodynamic destruction of endometrial tissue with topical 5-aminolevulinic acid in rats and rabbits." *Am.J Obstet Gynecol.* 171.5 (1994): 1176-83.

Yang, J. Z. et al. "Evidence of lasting functional destruction of the rat endometrium after 5-aminolevulinic acid-induced photodynamic ablation: prevention of implantation." *Am.J Obstet Gynecol.* 168.3 Pt 1 (1993): 995-1001.

Zreik, T. G. et al. "Cryomyolysis, a new procedure for the conservative treatment of uterine fibroids." *J Am Assoc Gynecol Laparosc.* 5.1 (1998): 33-38.

Zupi, E. et al. "Selective uterine artery embolization in the management of uterine myomas." *Fertil.Steril.* 79.1 (2003): 107-11.

## LIST OF PUBLICATIONS

Visvanathan D. Connell R. Hall-Craggs MA. Cutner AS. Bown SG. Interstitial laser photocoagulation for uterine myomas. *American Journal of Obstetrics & Gynecology*. 187(2):382-4, 2002 Aug

Visvanathan D. Connell R. Hall-Craggs MA. Cutner AS. Bown SG Interstitial laser photocoagulation for uterine myomas. *American Journal of Obstetrics & Gynecology*. 188, 2003 p.860

Visvanathan D. Cutner AS. Bown SG Conservative surgical treatment of uterine fibroids *Reviews in Gynaecological practice*. 4 (1): 20-26 2004 March