

REFERENCE ONLY



2809586216

UNIVERSITY OF LONDON THESIS

Degree

phd

Year 2007

Name of Author

DORIS EVA

BAMIOU

COPYRIGHT

This is a thesis accepted for a Higher Degree of the University of London. It is an unpublished typescript and the copyright is held by the author. All persons consulting the thesis must read and abide by the Copyright Declaration below.

COPYRIGHT DECLARATION

I recognise that the copyright of the above-described thesis rests with the author and that no quotation from it or information derived from it may be published without the prior written consent of the author.

LOAN

Theses may not be lent to individuals, but the University Library may lend a copy to approved libraries within the United Kingdom, for consultation solely on the premises of those libraries. Application should be made to: The Theses Section, University of London Library, Senate House, Malet Street, London WC1E 7HU.

REPRODUCTION

University of London theses may not be reproduced without explicit written permission from the University of London Library. Enquiries should be addressed to the Theses Section of the Library. Regulations concerning reproduction vary according to the date of acceptance of the thesis and are listed below as guidelines.

- A. Before 1962. Permission granted only upon the prior written consent of the author. (The University Library will provide addresses where possible).
- B. 1962 - 1974. In many cases the author has agreed to permit copying upon completion of a Copyright Declaration.
- C. 1975 - 1988. Most theses may be copied upon completion of a Copyright Declaration.
- D. 1989 onwards. Most theses may be copied.

This thesis comes within category D.

This copy has been deposited in the Library of

UCL

This copy has been deposited in the University of London Library, Senate House, Malet Street, London WC1E 7HU.

**AUDITORY PROCESSING IN PATIENTS WITH
STRUCTURAL LESIONS OF THE BRAIN**

The Insula and the Interhemispheric Pathway

**A Thesis to be
presented for the Degree of
Doctor of Philosophy**

in

**The Institute of Neurology
University College London**

by

Doris-Eva Bamiou

March 2007

UMI Number: U591296

All rights reserved

INFORMATION TO ALL USERS

The quality of this reproduction is dependent upon the quality of the copy submitted.

In the unlikely event that the author did not send a complete manuscript and there are missing pages, these will be noted. Also, if material had to be removed, a note will indicate the deletion.



UMI U591296

Published by ProQuest LLC 2013. Copyright in the Dissertation held by the Author.
Microform Edition © ProQuest LLC.

All rights reserved. This work is protected against
unauthorized copying under Title 17, United States Code.




ProQuest LLC
789 East Eisenhower Parkway
P.O. Box 1346
Ann Arbor, MI 48106-1346

DECLARATION

I, Doris-Eva Bamiou, confirm that the work presented in this thesis is my own, except where specifically acknowledged in the text. Where information has been derived from other sources, I confirm that this has been indicated in the thesis.

Signed informed consent was obtained by all participating adult subjects and by all parents of participating children subjects.

The experimental work was carried out with the approval of the Joint Ethics Committee of the Institute of Child Health (University College London) and Great Ormond Street Hospital for children participants and of the Ethics Committee of the National Hospital for Neurology and University (University College London Hospitals NHS Trust), according to guidelines established by the Declaration of Helsinki.

Signature: 

Date: 27-07-07

ABSTRACT

This thesis investigated structure versus function in the central auditory nervous system (CANS) by using the lesion study approach and by utilising a validated clinical test battery for the assessment of auditory processing as well as self- or parent report measures. The central auditory test results were correlated with the macroscopical appearance of the CANS on brain MRI and with patient reported hearing difficulties. The two regions of interest for this study were the insula (first group of studies) and the interhemispheric pathway, comprised by the corpus callosum and the anterior commissure (second group of studies).

First group of studies: Patients with a history of ischemic or haemorrhagic cerebral stroke of the CANS were identified by their scans. Exclusion criteria were significant psychiatric or expressive language disorders. Second group of studies: Adults and children with congenital aniridia and abnormality of the interhemispheric pathway due to a *PAX6* mutation were recruited.

The assessment included questionnaire of auditory capabilities, baseline audiometry (pure tone audiometry, tympanometry and otoacoustic emissions) and central auditory tests (speech and non-speech). The brain MRIs of these patients were visually inspected (1st and 2nd group of studies). The corpus callosum area was measured in the children participants of the 2nd group of studies.

Main findings

The insula is an integral part of the central auditory nervous system which may be necessary for auditory temporal resolution and sequencing. Patients with a unilateral focal ischemic lesion of the CANS have greater difficulties with sound detection & distinction, speech intelligibility in noise & in quiet, and sound localization than normal controls. Congenital structural and/or functional abnormalities of the anterior

commissure and corpus callosum due to a *PAX6* mutation are associated with deficient auditory interhemispheric transfer, which persists into adulthood. Children with *PAX6* mutations may suffer from auditory interhemispheric transfer deficits and difficulties with understanding of speech in noise and localization of sounds despite normal audiograms. Disordered auditory processing may be a significant sequel of neurological disease, in the presence of a normal audiogram, but may also be present in the neurological patient with a normal brain MRI. Case studies of patients with defined structural lesions of the brain may help understand how different parts of the brain process sound.

LIST OF CONTENTS

1. PREFACE	p 10
2. INTRODUCTION	p 13
2.1. Structure and functional organisation of the central auditory nervous system – an overview.	p 13
2.1.1 Brainstem Anatomy and Physiology	p 13
2.1.2. The midbrain	p 18
2.1.3 The auditory cortex	p 19
2.1.4. Descending or efferent pathways	p 22
2.1.5. The interhemispheric pathway	p 26
2.2. The role of the insula in audition – a literature review	p 27
Anatomy	p 29
Cytoarchitecture	p 29
Connections	p 29
Case reports in humans	p 32
PET and fMRI studies	p 38
A. Sound detection and non-verbal processing	p 41
B. Temporal processing	p 44
C. Phonological processing	p 47
D. Visual-auditory integration	p 50
Comments and Conclusion	p 53

2.3. The role of the interhemispheric pathway in audition	
– a literature review	p 55
Anatomy	p 55
Vascular supply	p 57
Cytoarchitecture	p 59
Neurochemistry	p 59
Topography and organization of commissural fibres	p 60
Interhemispheric connectivity and brain asymmetry	p 62
Embryology	p 64
Post-birth age-related changes of the auditory interhemispheric	
Pathway	p 66
Human behavioural & neuroimaging auditory studies of the	
interhemispheric pathway	p 71
Dichotic test paradigms	p 71
Pattern test paradigms	p 84
Localisation test paradigms	p 85
The concept of interhemispheric relay time (IHRT)	p 86
Summary and Conclusions	p 88
2.4. Auditory Processing Disorders	p 90
Auditory processing disorders: definitions, controversies and	
a conceptual framework	p 90
Aetiology	p 96
Symptoms	p 98
Diagnostic approach for Auditory Processing Disorders	p 99

Requirements for a test battery	p 102
Behavioural Central Auditory Tests	p 103
Behavioural Central Auditory Tests Categories	p 105
Main test batteries (clinical and experimental) for English speaking populations	p 112
2.5. Imaging the Central Auditory Nervous System	p 115
2.6. Human lesion studies and how these may contribute to the study of Auditory Processing Disorders	p 122
3. AIMS	p 124
4. METHODS	p 126
STUDY DESIGN	p 126
SUBJECTS	p 128
<u>STUDIES 1 & 2</u>	p 128
Inclusion criteria for case subjects	
Exclusion criteria for case subjects	
Controls & matching to the subjects	
Definition of the central auditory pathway	
<u>STUDIES 3& 4</u>	p 129
Inclusion criteria for case subjects	
Exclusion criteria for case subjects	
Controls & matching to the subjects	

GENERAL PROTOCOL	p 130
ETHICS APPROVAL	p 130
PROCEDURES	p 132
A. Standard audiological test procedures	p 132
B. Central auditory test procedures	p 133
C. Questionnaires	p 138
D. Imaging studies	p 139
STATISTICAL ANALYSIS	p 141
5. STUDY 1	p 142
6. STYDY 2	p 162
7. STUDY 3	p 187
8. STUDY 4	p 202
STUDY 4 ADDENDUM	p 218
9. DISCUSSION AND CONCLUSIONS	p 225
10. REFERENCES	p 241
LIST OF FIGURES	p 280
LIST OF TABLES	p 286

APPENDICES A, B, C	p 290
APPENDIX A: Amsterdam Inventory for Auditory Disability and Handicap	p 290
APPENDIX B: Structured questionnaire	p 296
APPENDIX C STUDY 2: AUDITORY PROCESSING DEFICITS AND DISABILITIES IN PATIENTS WITH STROKE OF THE CENTRAL AUDITORY PATHWAY: Lesions, questionnaire and test results in the excluded subjects	p 297
ACKNOWLEDGEMENTS	p 298

1. PREFACE

Hearing is one of the cornerstones of human communication, and essential for our wellbeing and survival. The hearing process is a complex one, which requires sound signal analysis and transmission within the external, middle and internal ear and the auditory nerve, and further processing of the sound signal in the brain, as well as integration with other types of information. Broadly speaking, the term “central auditory processing” refers to how the brain analyses sound to derive meaningful information. After the early work by Bocca and colleagues, who first highlighted the fact that brain pathology can lead to subtle hearing difficulties which are not identifiable by conventional audiometric testing, it is only in the last 20-30 years that the notion that patients may complain of hearing difficulties attributable to disordered auditory processing within the brain has been more widely acknowledged by health professionals.

The last few years have seen a dramatic increase in the number and the sophistication of neuroimaging as well as histological studies exploring the functional organisation of the auditory system, which have enhanced our understanding of the functional and anatomical specialisations of the central auditory system. As a result, the definition of what constitutes the central auditory pathway has expanded, as sound processing networks appear to include cortical areas beyond primary auditory cortex, such as the insula, as well as the interhemispheric commissures. However, the exact role that different “auditory” structures play in audition, and whether these structures are indeed crucial to audition, remains unknown. In addition, rather disappointingly, recent progress in auditory neuroscience has not as yet been translated in clinical

practice. There is a lack of uniform diagnostic criteria on what constitutes disordered auditory processing and whether this is indeed a disorder, while the pathophysiological correlates for the complaints of patients with disordered auditory processing are poorly understood, and the related disability remains underinvestigated. Recent findings, which may suggest that auditory training is beneficial for patients with disordered auditory processing, remain unexplored, as the clinical entity of APD has not as yet been put on a firm scientific footing. At present, there is a great need to translate findings from basic scientific studies onto individual clinical cases in order to address these issues. The systematic study of patients with defined anatomical lesions (the “lesion-led” approach) may help in this respect. Structural brain MRI studies, in particular, may complement both pathological macro- and micro-anatomical investigative techniques and other neuroimaging studies of the human central auditory system, by enabling us to study in vivo the macroscopic appearance of the human auditory cortex and the relationship between brain structure and central auditory processing deficits, as characterised by behavioural tests, as well with patient reported symptoms/disability.

This thesis proposes to investigate structure versus function in the central auditory nervous system by using the lesion study approach, in order to enhance our understanding of auditory processing and to bridge the gap between basic auditory neuroscience and clinical practice. We have recruited patients with a known lesion of the CANS, as documented on the brain MRI, and administered a range of validated clinical central auditory tests as well as questionnaires, in order to correlate the test results with the macroscopical appearance of the CANS on the brain MRI and with the patient reported disability. The study focuses on two major CANS regions of

interest, the insula and the interhemispheric pathway, comprised of the corpus callosum and the anterior commissure.

2. INTRODUCTION

2.1. Structure and functional organisation of the central auditory nervous system

– an overview.

The central auditory nervous system (CANS) extends from the cochlear nucleus in the brain stem to the auditory cortex. The CANS includes, apart from the cochlear nuclei, several other nuclei within the brainstem, the medial geniculate body in the thalamus, cortical areas that have not been traditionally regarded as auditory, as well as various interconnecting commissures of the two halves of the brain. The CANS is broadly characterized by an intricate pattern of bilateral connections, both ascending (from the periphery to the cortex) and descending (from the cortex to the periphery), and by an increasing number of fibres from the periphery to the cortex.

2.1.1 Brainstem Anatomy and Physiology

The fibres of the auditory nerve bifurcate on entering the cochlear nucleus (CN), and synapse with morphologically different types of neurons in the different divisions of the CN (Moore, 1991). Some CN neurons project directly to the inferior colliculus (IC), whereas others project to the superior olivary complex (SOC) via the medial nucleus of the trapezoid body (MNTB), as well as to the nuclei of the lateral lemniscus (NLL), and from the nuclei of the lateral lemniscus on to the inferior colliculus (Figure 1). Projection of neurons to the inferior colliculus are both highly convergent and divergent, and the central nucleus of the inferior colliculus receives projections from 20 identified neuron types in approximately 10 major brainstem nuclei (Irvine, 1992). Binaural input interaction first occurs at the level of the superior olivary complex (SOC) in the lower brainstem and more rostrally in the nuclei of the

lateral lemniscus (NLL) and the inferior colliculus (IC), both in parallel, as well as in hierarchical (i.e., serial) fashion relative to the superior olivary complex (Moore, 1991). Because of this binaural integration, the thalamocortical afferents convey binaural information; however, signal conduction to the contralateral cortex is functionally more significant, in that it is faster and leads to stronger activation than the ipsilateral pathway (e.g., Philips and Irvine 1979).

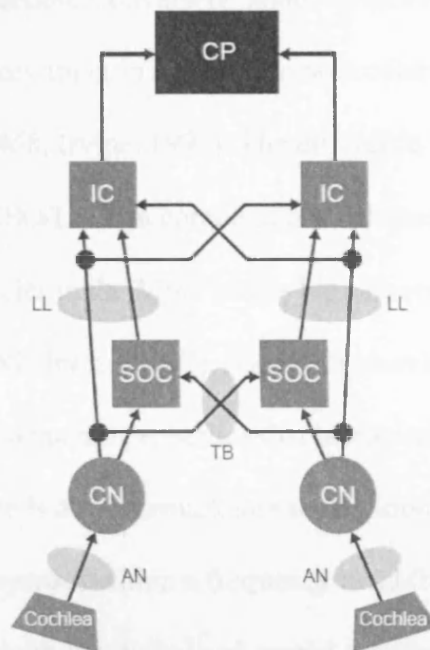


Figure 1. Schematic representation of the main brainstem nuclei of the auditory pathway and their main connections. AN—auditory nerve; CN—cochlear nucleus; SOC—superior olivary complex; LL—lateral lemniscus; IC—inferior colliculus; CP—central processor; TB—trapezoid body. From Bamiou 2006.

The cochlear nucleus, as well as all subsequent brainstem nuclei, is characterized by tonotopic organization (i.e., the spatial arrangement of frequency representation, referenced to where the tone was originally received in the cochlea). Tonotopic

organisation is similarly preserved in their projections, thus enabling preservation of tonotopicity throughout the auditory pathway (Irvine, 1992). Eighty percent of central auditory neurons are influenced by stimulation of either ear (Goldberg & Brown, 1969). The overwhelming majority of neurons at the MNTB are monaural. In the SOC, almost all lateral superior olive (LSO) neurons receive inhibitory input in response to contralateral input and excitatory input in response to ipsilateral input, except for a small proportion. Conversely, about 60% of medial superior olive (MSO) neurons receive excitatory input in response to both contralateral and ipsilateral input (Goldberg & Brown, 1968; Irvine, 1992). The difference in the response characteristics of the MSO/LSO, in combination with their biased frequency responses (low frequencies in the MSO versus high frequencies in the LSO) (Bourk, Mielcarz, & Norris, 1981; Irvine, 1992), result in a correlation between characteristic frequency and binaural response properties that is maintained throughout the central auditory pathway. There is also a remarkable segregation of neurons with respect to their binaural input properties within a frequency band (Irvine, 1992). It has thus been suggested that there is both functional and spatial segregation for different components of binaural function within the human auditory pathway, and this has been confirmed by several human lesion studies (see Bamiou 2006 for a review).

The brainstem is an important relay station which encodes temporal and intensity sound characteristics, and correlates the differences of the sound characteristics between the two ears, a process which underpins sound localisation. If a sound is located at any other plane than at the median plane of a listener, the sound will have to travel a different path length to reach the two ears (as one ear will be nearer and one will be farther from the sound source). This will give rise to interaural time

differences (ITDs), which help the listener localize sound. The ITD for a given azimuthal displacement will decrease with increasing stimulus frequency (Irvine, 1992) (i.e., ITDs will be larger for low- frequency sounds). At the level of the auditory nerve, periodicity of sound is encoded by means of synchronized neural activity, termed as periodicity code. This is replaced by a rate code (i.e., distribution of discharge rate across the neural fibres) at the level of the ICC, with a large proportion of ICC neurons acting as temporal filters (Langner & Schreiner, 1988).

For information encoded in terms of place/periodicity code at the periphery to be used by the central auditory nervous system, this information must be translated to a different code. This observation has led to the postulation of the existence of a “coincidence detector” in the brainstem (Jeffress, 1948), whose output is determined by the temporal correlation between the phase - locked input and a delayed replica of this input. Thus, brainstem neurons that process ITDs conduct a cross-correlation process (Yin, Chan, & Carney, 1987). Goldberg and Brown (1968, 1969) noted that the discharge at the most favourable delay of a neuron is greater than the sum of the monaural responses and the discharge at the least favourable delay is lesser than either monaural response (i.e., binaural facilitation takes place when the inputs arrive in phase and inhibition occurs when the inputs arrive out of phase). Most delay sensitive neurons have a characteristic delay (Rose, Geisler, & Hind, 1966). Animal data indicate that for both the SOC and the ICC, there is topographic organization of the neuronal sensitivity to interaural time difference and thus for coincidence detection (Irvine, 1992).

Differences in the sound pressure level of an acoustic signal at the two ears (i.e., interaural intensity differences (IID), produced by the head “shadow” effect and the directional amplifying effects of the pinna, provide the major cue for the azimuthal location of high-frequency sounds (Rayleigh 1907). The major class of neurons which are sensitive to IIDs at the level of the SOC are concentrated at the LSO and receive excitatory input from the spherical bushy cells at the ipsilateral AVCN and inhibitory input from the principal neurons at the ipsilateral MNTB, which in turn receive input from bushy globular cells in the contralateral AVCN (Irvine, 1992). Most of these neurons are affected by the base intensity in which IIDs are introduced. In addition, there is marked topographic organization of neuronal sensitivity to IIDs.

In addition, cochlear root neurons project to targets outside the traditional auditory pathways, such as the medullary and pontine reticular formation (Cant and Benson, 2003). Axons from both the ipsilateral and contralateral VCN terminate in the ventrolateral medullary nucleus (VLMN), which is involved in control of autonomic functions. Cochlear root neurons also project to the nucleus paragigantocellularis lateralis, which is involved in the control of cardiovascular and respiratory function, and the caudal pontine reticular nucleus, which is involved in the acoustic startle reflex (Cant and Benson, 2003). It has been proposed that these (and other similar) connections at the cochlear nucleus level may underline the well known interaction between higher order processes (e.g., emotion, attention) or other senses (e.g. somatosensory) with auditory percepts such as tinnitus (Kaltenbach, 2006).

2.1.2. The midbrain

The medial geniculate body in the thalamus is characterised by a complex and nucleus-specific efferent and afferent projection pattern to the cortex (Winer et al., 2005). Projections from the ventral division of the medial geniculate body (MGB) are predominantly found in deep cortical layers III and IV, possibly relaying the basic acoustic features of the acoustic signal onto the auditory cortex, as well as in layer V. Projections from the dorsal division of the MGB are found in layers I, II, V and VI and may influence both intracortical relay of information and corticofugal systems. Projections from the medial division of the MGB target layers I and VI perhaps influence principally local circuits (Winer et al., 2005). The primary (core) areas of the auditory cortex receive thalamic input from the principal (ventral) nucleus of the medial geniculate body, while the non-primary (belt) areas predominantly receive thalamic input from the non-lemniscal divisions (dorsal and medial) of the MGB (Kaas and Hackett 2000). It has been proposed that this organization of projections subserves sound processing “stream segregation”, i.e., the decomposition of the auditory input into signals of the individual sound sources which are included in the input, in the auditory cortex (Winer et al., 2005). In addition, it has been proposed that the MGB plays more than a simple relay role in the auditory pathway. This was based on the finding that the thalamocortical temporal transformation is not a uniform change in rate, and that this transformation can be strongly modulated by the states of vigilance as well as behavioural training (Edeline 2003).

2.1.3 The auditory cortex

In humans, the auditory cortex occupies the superior temporal plane, i.e. the superior surface of the temporal lobe within the Sylvian fissure. The human auditory cortex consists of a central primary area or A1, which is surrounded by a number of non-primary areas (Hackett et al., 2001). It consists of 3 main types of cells, pyramidal, stellate and fusiform, organized in 6 layers (Musiek and Oxholm 2000). The first primary auditory area or A1 is located on the medial part of the first transverse gyrus of Heschl (HG). In addition, there is an auditory responsive area on the posterior and lateral part of HG (Patterson et al., 2002). The human non-primary auditory areas include the planum temporale, planum polare, superior temporal gyrus and sulcus, and insula (Hall, Hart and Johnsrude, 2003; Musiek and Oxholm 2000) (figure 2). In addition to these formations, sounds activate a more extensive network than previously thought, which includes parts of the limbic, parietal, frontal and prefrontal cortices (Musiek and Oxholm, 2000; Poremba et al 2003). Similarly to that which is seen in brainstem and subcortex, tonotopic organisation has been shown to be maintained in the human auditory primary area or “core” as well as in belt areas (Hall, Hart and Johnsrude, 2003). Sound level changes have been shown to lead to systematic changes in activation of the auditory cortex on PET and fMRI studies, however there are conflicting reports regarding the exact location and degree of activation (e.g., Lockwood et al., 1999; Jäncke et al., 1998; Mohr et al., 1999). Spatial sound processing is subserved by a network comprised of bilateral areas of non-primary posterior auditory cortex and inferior parietal lobule and (right sided more than left) superior parietal cortex (Arnott et al., 2004; Hall, Hart and Johnsrude 2003).

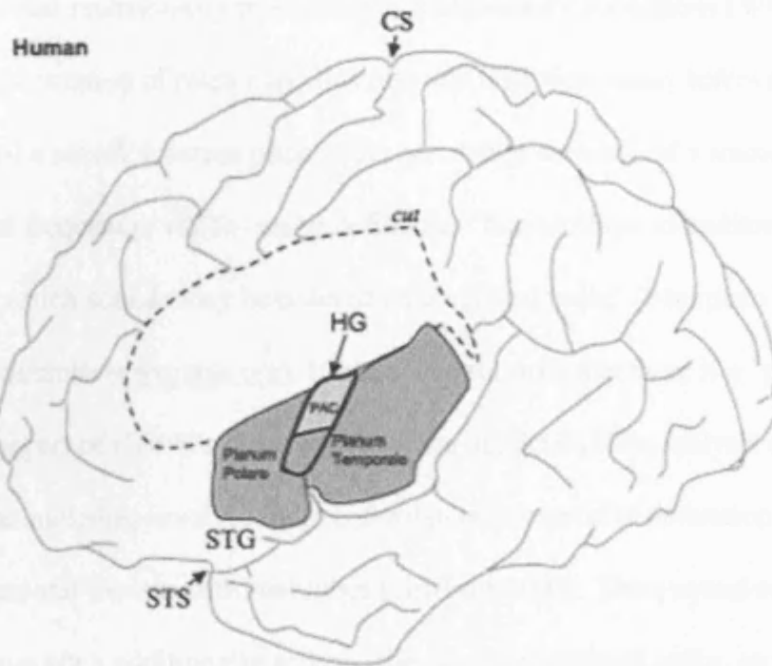


Figure 2. The auditory cortex in humans. Dorsolateral aspect after removal of the overlying parietal cortex. The ventral bank of the lateral sulcus and insular cortex and the superior surface of the STG are exposed. The dashed line indicates the part of the cortex that has been sectioned. The outline of HG is in black. The primary auditory cortex is depicted in white on the middle part of HG. Non-primary areas on the lateral part of HG, including the planum polare and planum temporale are shown in light grey. CS = Central sulcus; PAC = primary auditory cortex; STS = superior temporal sulcus; STG = superior temporal gyrus. From Hall et al., 2003.

And whereas the primary auditory cortex appears to be more involved in basic spectrotemporal analysis, such as frequency and sound level analysis, non-primary auditory areas appear to specialise in more elaborate computation and integration of sounds (Hall, Hart and Johnsrude 2003). Functional organisation of the auditory cortex appears to span a continuum, from basic sensory processing in primary areas, to polymodal integration in non-primary areas, to behavioural modulation in the

limbic areas and multisensory processing in multisensory subregions (Winer et al., 2005). The perception of pitch may illustrate this well. Frequency refers to a physical dimension of a sound, whereas pitch is the perceptual correlate of a sound's fundamental frequency, which can be defined as "that attribute of auditory sensation in terms of which sounds may be ordered on a musical scale" (American National Standards Institute: www.ansi.org). It has been proposed that there is a "pitch centre" in the lateral part of Heschl's gyrus (Patterson et al., 2002). The analysis of patterns of pitch such as melodies involves more anterolaterally extensive activation of the superior temporal lobes and frontal lobes (Griffiths 2003). Thus, sound sequences with changing pitch additionally activate the superior temporal gyrus, as well as the planum polare and anterior planum temporale (Warren and Griffiths, 2003). The planum temporale in particular may be involved with the segregation of spectrotemporal patterns and their comparison to learned spectrotemporal representations (Griffiths and Warren 2002).

The human brain is characterised by a lateralisation of functions. Thus, while language and speech processing is subserved by bilateral networks (Boatman 2006), some features of the speech signal are processed in one hemisphere (usually the left) (Scott and Johnsrude, 2003). Conversely, the right auditory cortex seems to be crucial for tonal processing (Zatorre 2001). The basis for this lateralisation of functions seems to be a predisposition of the left auditory cortex to process better rapidly changing broad-band stimuli (such as speech), and for the right auditory cortex to process better slower, narrow-band stimuli (such as music), rather than the informational content of these sounds (Zatorre 2001; Tervaniemi and Hugdahl 2003).

Similar to the visual system, it has been proposed that there are two parallel processing streams in the auditory system, subserved by distinct pathways, the anterior or rostral “what” stream, responsible for sound identification and the posterior or caudal “where” stream, responsible for sound location (Rauschecker 1998). Intriguingly, it has also recently been proposed that auditory “what” and “where” streams in the cortex may have early antecedents in the brainstem, as indicated by findings of their correlates in distinct brainstem responses (Kraus and Nicol, 2005). In addition, it has been suggested that sounds are represented by means of neuronal activation in the primary auditory cortex as “auditory objects” rather than as their constituent acoustic features (Nelken 2004). But despite significant progress in auditory neuroscience, the exact number, organization, and functional significance of the human auditory areas, and in particular of the non-primary ones, such as the insula, have not as yet been characterised in detail (Rivier & Clarke, 1997; Hall et al., 2003).

2.1.4. Descending or efferent pathways

The descending (corticofugal) projections from the auditory cortex to the MGB are greater in comparison to the ascending projections of the MGB to the cortex, however, some thalamic nuclei will not receive input from their cortical targets (Winer 2005) while the corticofugal projection, will terminate not only on the MGB but also on the IC and lower brainstem (He 2003). These corticofugal projections may therefore subserve gating or gain-control mechanisms for the transmission of

sound signals from the ear to the brain (He 2003). Similarly, olivocochlear neurons originating at the superior olivary complex of the brainstem form another distinct descending pathway that projects to the cochlea. There are two subsystems within this pathway, the crossed medial olivocochlear (MOC) system (from the medial portion of the superior olive to the outer hair cells), and the lateral uncrossed olivocochlear system that (from the lateral portion of the superior to the inner hair cells) (Warr, 1992). The MOC pathway may reduce the sound stimulus masking by noise, control the hearing dynamic range, and protect the cochlea from noise trauma (Brown et al., 2003).

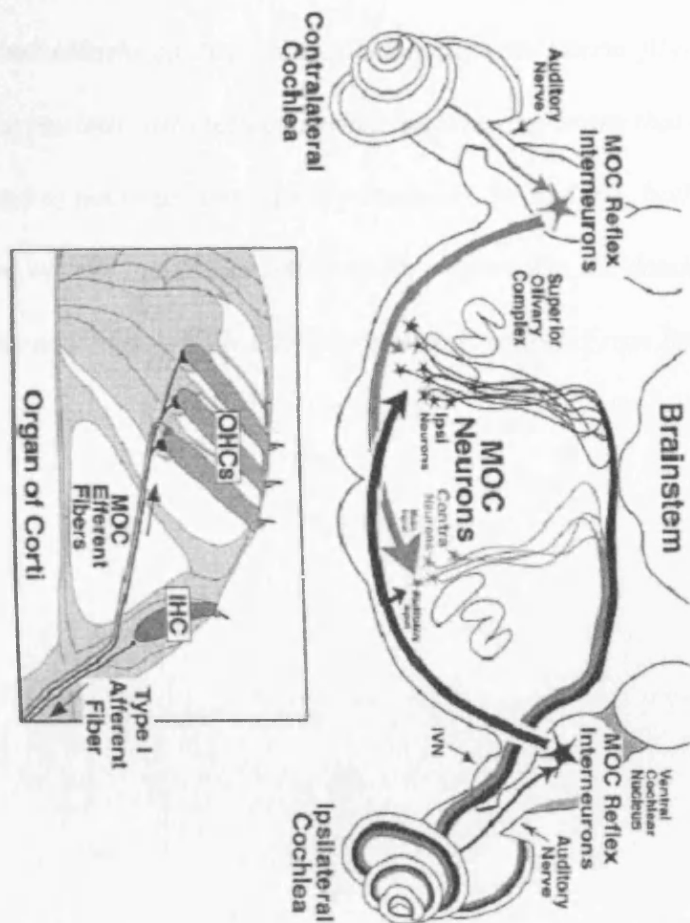


Figure 3. Schematic representation of the pathway of the sound-evoked medial olivocochlear (MOC) reflexes to the right cochlea. The reflex pathway in response to

ipsilateral sound includes the outer and inner hair cells (OHC, IHC) of the ipsilateral cochlea, the type I afferent fibres of the auditory nerve c. the cochlear nucleus, the MOC reflex interneurons, which cross the midline (black pathway) to innervate MOC neurons having a response to ipsilateral sound. These ipsilateral neurons cross back the midline to innervate OHC in the ipsilateral cochlea. The reflex pathway to contralateral sound includes the contralateral cochlea and type I nerve fibres, the contralateral cochlear nucleus, with reflex interneurons sending axons that cross the midline (gray pathway) to innervate contralateral neurons. In addition, both types of MOC neurons receive weaker inputs that facilitate the response to the dominant ear (small arrows, Facilitatory Input). (IVN inferior vestibular nerve). From Brown et al., 2003.

2.1.5. The interhemispheric pathway

Auditory fibres cross the midline in order to connect the two halves of the central auditory pathway at several levels, starting at the level of the cochlear nuclei. At the cortical level, axons from auditory and auditory-responsive cortical areas that cross the midline from one hemisphere to the other travel in the forebrain commissures of the corpus callosum and the anterior commissure (Pandya and Seltzer, 1986).

Through these two formations, each cortical area is reciprocally connected to its corresponding contralateral area (homotopic connection), as well as to an additional set of contralateral areas (heterotopic connections) for which there is intrahemispheric connection with their corresponding ipsilateral counterparts (Pandya and Seltzer, 1986). The connection between the two cortices may increase the brain's computational resources, by allocating different components of complex auditory tasks to the hemisphere that shows a specialisation for this task (Weisman and Banich, 2000). However, the exact contribution of interhemispheric transfer in auditory processing, in terms of “what” (type of information transferred), “where” (location of the interhemispheric pathway responsible for the transfer) and “how” (excitation/facilitation vs. inhibition), is still a matter of debate.

2.2. The role of the insula in audition – a literature review.

The insula (island of Reil - Brodmann areas 13 to 16) is a complex structure, with increased complexity in the course of primate evolution, which is characterised by a striking heterogeneity in architecture, physiology and connectivity with other areas of the brain. Thus it subserves a wide range of neural processes in all species. The role of the human insula as a visceral sensory and motor, motor association, vestibular, and somatosensory area is well known (Augustine, 1985; Augustine, 1996). In contrast, its role in auditory processing is poorly understood. The following paragraphs will summarise and discuss the available information on the auditory functions of the human insula.

Anatomy

The insula lies deep inside the lateral sulcus in the Sylvian fissure, under the operculum. Removal of the fronto-orbital, frontoparietal and temporal opercula will reveal the pyramid-shaped insula in its entirety (Türe et al., 1999). The extreme capsule, which consists of the insular subcortical white matter, is united with the white matter of the opercula. The insula cortex and extreme capsule cover the claustrum, external capsule, putamen and globus pallidus (Türe et al., 1999). The insula contains 5-7 sulci in humans, who possess a larger left than right insula by adulthood (Mesulam and Mufson, 1985). It has an intricate vascularisation pattern, with an average of 96 arteries that originate from the middle cerebral artery and predominantly its M2 segment (Türe et al., 2000). The fronto-opercular artery is the main insular artery. The insular arteries supply the insular cortex, extreme capsule and

occasionally the claustrum and external capsule, but not the putamen, globus pallidus or internal capsule, which are supplied by the lateral lenticulostriate arteries (LLA) with no gross communications between the insular arteries and the LLA (Türe et al., 2000).

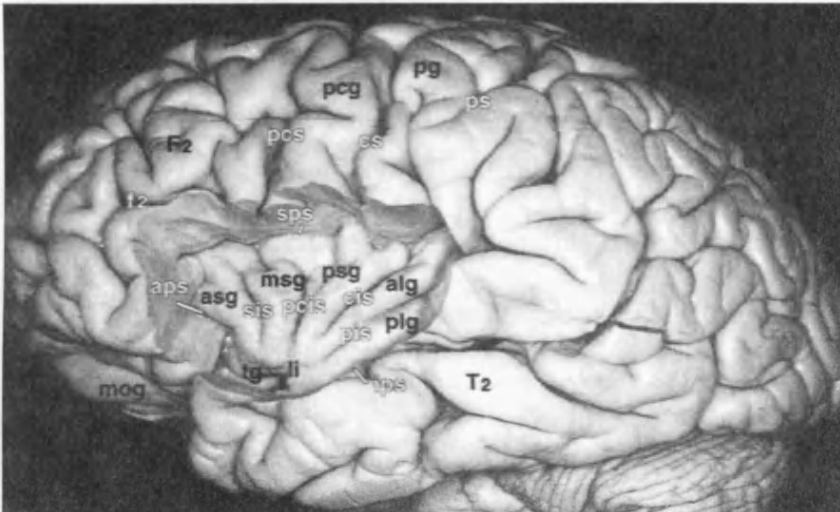


Figure 4. Photographs of brain specimen. The insula has been exposed following excision of the opercula. aps= anterior periinsular sulcus, alg= anterior long insular gyrus, asg= anterior short insular gyrus, cis= central insular sulcus, cs= central sulcus of Rolando, F2= middle frontal gyrus, f2= inferior frontal sulcus, ips= inferior periinsular sulcus, li= limen insula, mog= medial orbital gyrus, msg= middle short insular gyrus, pcg= precentral gyrus, pcis= precentral insular sulcus, pcs= precentral sulcus, pg= postcentral gyrus, pis= postcentral insular sulcus, plg= posterior long insular gyrus, psg= posterior short insular gyrus, ps= postcentral sulcus, sps= superior periinsular sulcus, sis= , T2= middle temporal gyrus, tg= transverse insular gyrus. From Türe et al (1999), reference 34, with kind permission, and from Bamiou et al., 2003.

Cytoarchitecture

The insular cortex is divided into three belts from anterior to posterior, on the basis of a gradual cytoarchitectonic change (a). an agranular belt on the anterior one-third of the insula (b). a transitional dysgranular belt in layers without complete laminar differentiation, and (c). a posterior granular belt with well defined granule cell layers that occupies the posterior third (Augustine, 1996). Further analysis of the cortical architecture of the human insula in cytochrome oxidase, acetylcholinesterase and NSDPH-diaphorase staining indicates the presence of two putative cortical areas (Rivier and Clarke, 1997):

1. a darkly- stained region on the posterior insula, that contains few stained fibres and a small number of neurons, with a profile compatible with a primary sensory area and
2. a light-stained region on the anterior-inferior part of the insula, where neuronal somata predominate, with an intermediate profile between that of a primary sensory area and a high order association area.

Connections

Regional cytoarchitectonic differences correspond well to the thalamic connectivity of the insula. Jones and Burton (1976) studied the cortical connections of the thalamus in 66 rhesus and squirrel monkey brains by injecting isotopically labelled aminoacids in the thalamic nuclei complexes, including the medial geniculate body. While no axoplasmically transported label could be traced in the anterior-third agranular area, the posterior-third granular insular field had a dense, coarse thalamic plexus, while the

middle dysgranular field had a fine thalamic plexus. Injecting the medial geniculate body resulted in intense labelling of the parainsular field throughout its extent (Burton and Jones, 1976). Physiological experiments using auditory evoked potentials in awake squirrel monkeys have similarly identified the presence of auditory responsive units in the insular cortex, with response latencies that would be compatible with direct connections from the medial geniculate body, and with higher concentration of auditory units in the caudal (posterior) than rostral (anterior) part (Sudakov et al., 1971). However, Mesulam and Mufson (1985) labelled brains of Old World monkeys and found comparable connections of both anterior and posterior part of the insula with the parvicellular medial geniculate nucleus.

The insula, its posterior part in particular, also has widespread and well-developed connections with the auditory cortex. Mesulam and Mufson (1985) labelled brains of Old World monkeys with tritiated aminoacids or horseradish peroxide injections and showed projections from the dysgranular area of the insula to the parainsular area and superior temporal cortex, and from the postauditory cortex to the posterior insula (especially the granular areas). There are additional connections with AI-AII (primary and association auditory area), and reciprocal connections with the temporal pole and superior temporal sulcus (Augustine, 1985). In addition, the extensive work of Pandya and colleagues (Pandya, Karol and Heilbronn, 1971; Pandya and Rosene, 1985) indicates the presence of several interhemispheric connection routes through the corpus callosum, where it is interesting to note the close proximity of auditory fibres and posterior insular fibres. Pandya and colleagues utilized isotope tracers in the rhesus monkey and found that the anterior aspect of the insula projects fibres through the posterior aspect of the anterior half of the corpus callosum, while the posterior

segment of the insula sends fibre tracts through the anterior part of the sulcus of the corpus callosum (which is posterior half of this structure). The fibres from the posterior part of the insula combine with fibres from regions around and including the primary auditory areas.

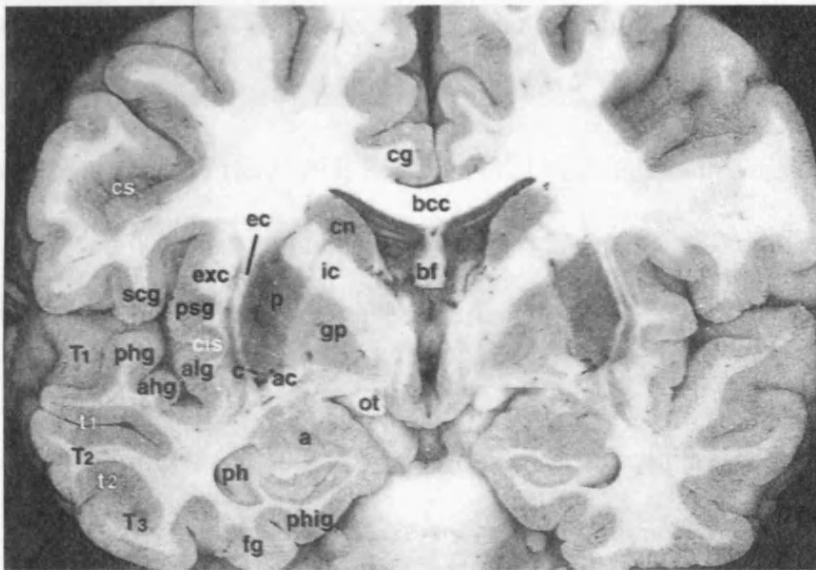


Figure 5. Coronal section of the brain through the foramen of Monro and the amygdala. A = amigdala, ac= anterior commissure, ahg= anterior Heschl's gyrus, alg= anterior long insular gyrus, bcc= body of corpus callosum, bf= body of formix, c= claustrum, cg= cingulate gyrus, cis= central insular sulcus, cn = caudate nucleus, cs= central sulcus of Rolando, ec= external capsule, exc=extreme capsule, fg= fusiform gyrus, gp= globus pallidus, ic= internal capsule, ot=optic tract, p= putamen, ph= pes hippocampi phg=posterior Heschl's gyrus, phig=parahippocampal gyrus, , psg= posterior short insular gyrus, scg= subcentral gyrus, T1= superior temporal gyrus, t2= middle temporal gyrus, T3=inferior temporal gyrus, t1= superior temporal sulcus, t2= inferior temporal sulcus. From Türe et al (1999), reference 34, with kind permission, and from Bamiou et al., 2003.

Case reports in humans

Over the last few decades, single case reports in humans have thrown some further light onto the role that the insula has in auditory processing. Subjects with vascular events that include the insula on one or both sides may present with auditory agnosia, contralaterally to the affected side, to environmental sounds (Spreeen et al,1965), speech (Hyman and Tranel, 1989), music (Griffiths et al., 1997), or to all three of the above (Habib et al., 1995; Fifer, 1993; Engeliien et al., 1995), and this agnosia will resolve to a varying degree over a few months to years, depending on the extent of the lesion and on what other structures have been affected.

Spreeen et al (1965) presented the case of a 65 year old man with a cerebrovascular accident that involved the right hemisphere, including the right Sylvian fissure, parietal lobe and long and short gyri of the insula. The patient had normal language and normal speech reception thresholds, but a significant environmental sound agnosia. His pitch discrimination in a task that required him to differentiate whether two sounds were of the same or different frequency was normal at low frequencies (250 Hz), but deteriorated and was markedly abnormal as the frequency of the presented sounds increased up to 2000 Hz. He was also thought to have amusia, although this was not formally examined, due to his limited interest in music. While this was one of the first cases to present with auditory agnosia due to a unilateral, non-dominant hemisphere rather than a bilateral lesion, the particular deficits for which the insula lesion was responsible are unclear, as the pathology had also affected other auditory areas of the right hemisphere.

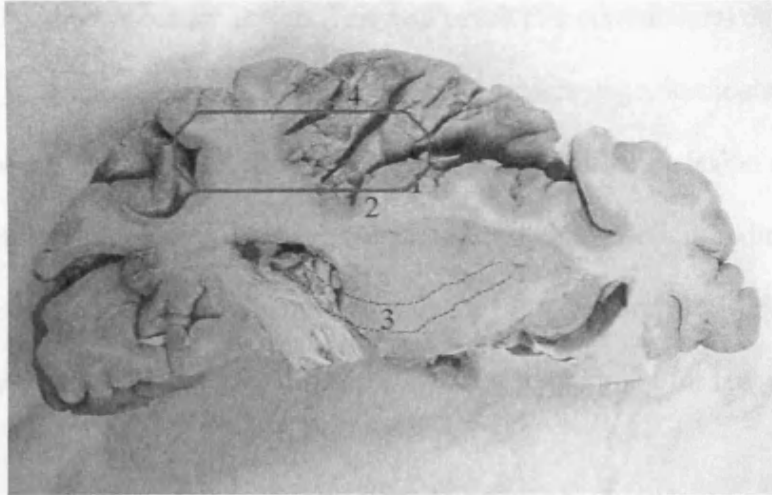


Figure 6. An approximate illustration of the lesion in Spreen et al., 1965.

1= insula, 2= external capsule, 3 = internal capsule, 4=Heschl's gyrus. From Bamiou et al., 2003.

Hyman and Tranel (1989) subsequently discussed the case of a 61-year-old right handed man with lacunar cerebrovascular disease that resulted in a more circumscribed lesion of the left posterior insula and thalamocortical connections with a spared thalamus. This patient developed a conduction aphasia (disproportionate impairment of repetition and multiple phonemic paraphasias), with intact aural and reading comprehension of single and short phrases, but impaired comprehension with more complex material. His speech and linguistic functions almost completely resolved several months later, but he was left with a severe right ear deficit with a near normal left ear result on dichotic listening to word pairs (52 and 90 out of 110 respectively). Dichotic tests, in which the two ears are presented with different but simultaneous signals, are based on the premise that in humans, the contralateral auditory pathway is more robust than the ipsilateral. For monaural input, the ipsi- or the contra-lateral auditory pathway is sufficient for the appropriate response, but in dichotic situations the weaker ipsilateral pathways are suppressed and the stronger

contralateral pathways remain active. This will result in a contralateral deficit if one hemisphere is compromised and bilateral deficit if the language-dominant hemisphere is compromised. Thus, Hyman and Tranel's case indicates that the lesion of the left posterior insula was sufficient to result in a right ear dichotic deficit, indicating compromised function of the left auditory pathway, despite good recovery of language function, due to the fact that areas on the left important for language were spared.

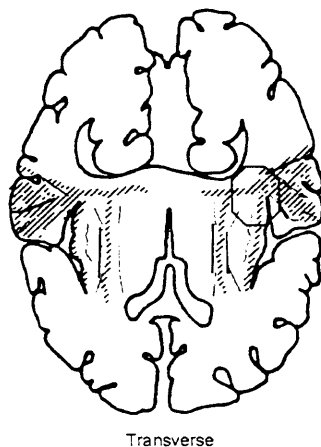


Figure 7. An approximate illustration of the lesion in Hyman and Tranel, 1989. From Bamiou et al., 2003.

Similarly to Hyman and Tranel, Fifer (1993) described a patient with a stroke in the right inferior temporoparietal area, that involved the insula, extreme capsule, claustrum and external capsule and possibly the thalamocortical fibres, but that spared Heschl's gyrus and internal capsule. One week post discharge, the patient presented with normal hearing thresholds, but with a left auditory agnosia with poor speech recognition in the left ear, in quiet as well as in the presence of ipsilateral competing message. Six months later, his speech recognition in the left ear was normal, both in quiet and in the presence of an ipsilateral competing message. Fifer thus suggested

that the insula may be involved in pre-processing auditory stimuli prior to Heschl's gyrus and Wernicke's area, a hypothesis that may be consistent with what is known about insula connectivity (see previous section).

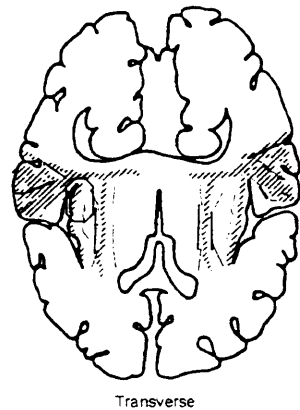
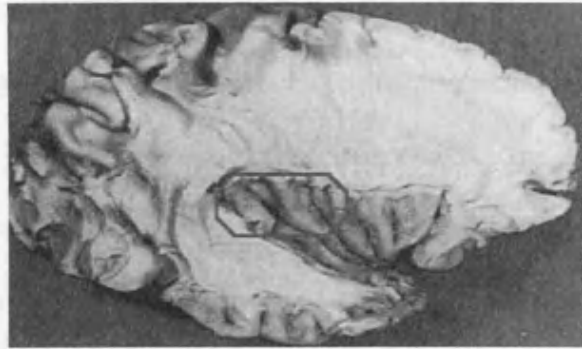

Figure 8. An approximate illustration of the lesion in Fifer, 1993. From Bamiou et al., 2003.

Habib et al (1995) reported the case of a 44 year old female who suffered two consecutive embolic cerebrovascular accidents that involved the insula bilaterally. The first stroke affected the right insula extending towards the opercular cortex and temporal lobe while the second stroke affected the left insula almost in isolation. Whereas the first stroke's single observable deficit was a rapidly improving left hemiparesis, after the second stroke the patient did not react to any sound or speech stimuli and was totally mute. Two months later, she had near-normal language but continued complaining of subtle auditory problems. At that time, she had typical features of non-verbal auditory agnosia, on the basis of poor identification of environmental sounds and recognition of famous voices, receptive aprosodia and receptive amusia, as demonstrated by an auditory agnosia battery. Eight months later, her audiometric thresholds were normal, and while tone intensity discrimination was

also normal, pitch discrimination was impaired. She had a near-total left ear extinction on a dichotic task with 100% right ear scores. Binaural stimulation middle latency response was present, but poor, with Na at 19 ms and Pa at 29 ms, and slightly better on the left than on the right hemisphere. Similarly, the N100 auditory event related response that is elicited by the expectation of a rare stimulus and may be attentional in nature, showed a very strong asymmetry in favour of the left hemisphere in this patient, while N100 is usually symmetrically recorded in the two hemispheres in normals. The authors attributed the total auditory agnosia to the discrete lesion on the left insula and significantly, the auditory agnosia persisted after one year, in contrast to previous reports. However, a subtle auditory deficit after the first stroke may have escaped unnoticed, as no test was carried out at that time. They also suggested that the two insulae may represent a key station for auditory attention, required to process verbal and non-verbal stimuli findings, and that this process is mediated via the callosal connections between the two insulae. This hypothesis would explain the dichotic test deficit to the left, i.e. contralaterally to the more widely damaged right side, and similarly the better MLR on the left, as well as the shifting of the predominantly attentional N100 to the left hemisphere.



R hemisphere lesion



L hemisphere lesion

Figure 9. An approximate illustration of the lesion in Habib et al., 1995. From Bamiou et al., 2003.

While these case studies are not directly comparable, due to evolution of radiology over the three decades that these cases span and to patient assessment differences, two inferences can possibly be made.

1. Fifer's case (1993) with a right temporo-parietal, insular and probably thalamocortical projection lesion had a contralateral speech perception deficit, while Spreen's case with a lesion at the right sylvian fissure, parietal lobe and long gyri of the insula had no language deficit, but environmental and probably music perception deficits. Taken together, this may indicate that the right insula and the thalamocortical projections it receives is an important pre-processing relay station for all aspects of audition, including speech.

2. Habib et al's case (1995) with total agnosia in the presence of bilateral insula damage may indicate that pre-processing at the level of the insula on both sides of the brain is vital for auditory processing, as the left insula-thalamocortical projection damage of Hyman and Tranel's case was not sufficient to produce total agnosia.

PET and fMRI studies

The single case studies of the previous section provide abundant support for a major role for the human insula in auditory processing. However, the specific functional deficits that are due to the insula lesion cannot be firmly established, due to methodology differences that include patient testing and radiology, involvement of varying extents of adjacent auditory structures, and the patient's own inherent characteristics pre-stroke. More sophisticated imaging techniques, such as PET or functional MRI, that explore the neuronal networks that participate in perceptual cognitive processing in more detail, help to further enhance our understanding of the functional specialisation of the insula. Results of these studies indicate that the human insula may contribute to the following auditory processes (Table 1):

Table 1. Summary of the major auditory functions of the insula.

Functions	R insula	L insula	Reference
A. Sound detection and non-verbal processing			
Activation by passive listening to sounds (R>L)	+	+	Engelien et al., 1995
Activation by target and by novel stimuli, with target>novel stimuli activation (P3b generator site)	+	+	Kiehl et al., 2001
Novel>familiar auditory stimulus activation	+		Downar et al., 2000
B. Temporal processing			
Auditory temporal processing	+	+	Ackerman et al., 2001
Musical rhythm processing		+	Platel et al., 1997
Auditory sequencing	+		Griffiths et al., 1997
Sound movement detection	+		Griffiths et al., 1997
	+	+	Lewis et al., 2000
C. Phonological processing.			
Phonological verbal short-term memory	+	+	Paulesu et al., 1993
Phonological rhyming task	+	+	Corina et al., 2001

Phonological word recognition		+	Rumsey et al., 1997 Wong et al., 2002
Activation by time-reversed sentences ?reflecting short-term memory ?sub-vocal rehearsal	+	+	Wong et al., 2002
D. Visual-auditory integration.			
Temporal onset mismatch detection between visual - auditory stimuli	+		Bushara et al., 2001
Cross-modal speed comparison (auditory- visual motion task)		+	Lewis et al., 2000
Mediation of temporally defined cross- modal auditory-visual interactions	+	+	Calvert et al., 2001

A. Sound detection and non-verbal processing

There is converging evidence that the insula is involved in sound detection and in entry of the sound into awareness, as well as in other non-verbal processing.

A.1. The insula is activated by passive listening to sounds and may thus participate in sound processing with access to abstract knowledge about non-verbal sound material.

Engelien et al (1995) assessed the neural network underlying passive listening to sounds and categorisation of environmental sounds in six normal volunteers and in a stroke subject using PET. PET helps to map the neuronal networks that participate in perceptual cognitive processing. In the normal subjects, passive listening to sounds activated the auditory cortex bilaterally, but more prominently on the right, where it included the anterior insula. The stroke subject had had two consecutive strokes in the perisylvian areas that included the insula bilaterally, leading to complete auditory agnosia immediately after the strokes. At the time of the PET study, 8 years after his stroke, the patient could discriminate all sounds and categorize and occasionally identify environmental sounds, but not linguistic stimuli. He had normal auditory brainstem evoked responses, present but abnormal pattern middle and long latency auditory evoked potentials and absent P300. PET while passively listening to sounds showed activation of the spared auditory cortex with recruitment of adjacent areas with homologous function, including the left insula. The authors postulated that the areas that were activated to passive listening to sounds, including the insula, may be

candidates for sound processing with access to abstract knowledge about non-verbal sound material.

A.2. Target and novel auditory stimuli activate the insula bilaterally, with greater activation for target than for the novel stimuli.

Kiel et al (2001) used event-related functional magnetic resonance imaging (erfMRI) to assess the cerebral sites that participate in auditory target detection and novelty processing. They used a 1500 Hz tone as target and 1000 Hz tone as non -target stimuli, with non-repeating random digital noises, such as whistles, as novel stimuli. Haemodynamic responses revealed that concurrently with other auditory areas. the insula was bilaterally activated to the target stimuli as well as to the novel stimuli, but activation was greater for the target versus novel stimuli, and this activation would thus correspond to a larger P3b, an event related potential response that is elicited by expected, task-relevant stimuli (Coull 1998).

A.3. The right insula is a multimodally responsive area that responds to visual, tactile and auditory stimuli (anterior > posterior) and shows a significantly greater response to a novel versus a familiar stimulus.

Downar et al. (2000) conducted an fMRI study to identify the neuroanatomical network that underlies the detection of changes in the visual, auditory and tactile environment, in the absence of any task. They used continuous trains of stimuli for

each modality that alternated independently between two different states, and each alternation was labelled as a transition. The right insula emerged as a multimodally responsive area that responds to visual, tactile and auditory stimuli (anterior > posterior), although this activation was less prominent than in other areas such as the right temporoparietal junction.

In a subsequent study, Downar et al (2001) sought to assess whether multimodally responsive areas, including the insula, are sensitive to the salience of stimuli across sensory modalities independent of behavioural context. They used fMRI in ten right handed individuals, who were presented with an oddball paradigm of a baseline combination of visual, auditory and tactile stimuli, interspersed with identical deviant stimuli, and after the stimulus had become familiar, with a combination of visual, auditory and tactile stimuli interspersed with the familiar deviant as well as non-familiar deviant stimuli, in pseudo-random order. The right anterior insula showed a significantly greater response to the novel versus the familiar stimulus. Downar et al (2001) conclude that the insula forms part of the network that serves to detect events in the sensory environment across multiple modalities and to identify salient (novel) events, in order to mediate attention and plan the necessary responses.

B. Temporal processing

Temporal processing is a prominent function of the central auditory nervous system, and forms one of the basis of speech perception. Some aspects of temporal processing include temporal sequencing (ordering acoustic stimuli), pattern perception (ordering acoustic stimuli and processing these as a gestalt rather than as individual components), frequency discrimination, while tasks such as sound localisation are also dependent on temporal processing in a major way (Bornstein and Musiek, 1980; Pinheiro and Musiek, 1985). Both insulae appear to be responsible for many aspects of auditory temporal processing that include sequencing of sounds, musical rhythm processing, as well as detection of a moving sound.

B.1. The insula may contribute in auditory temporal processing with the left insula as a non-linear high pass filter and the right insula as a linear low-pass filter.

Ackerman et al (2001) assessed rate-response profiles across 2-6Hz frequency band by means of functional MRI in eight normal right-handed volunteers. They used as stimuli 6-second trains of synthetic clicks of 2 to 6 Hz at a comfortable loudness level and instructed the subjects to passively listen to the stimuli. They found a significant negative linear correlation with a decline of the BOLD haemodynamic response when the click train rate increased within the right insular cortex and a non-linear rate-response function at the left anterior insular cortex. Thus, they documented a profile of a non-linear high pass filter at the level of the left insula, and of a linear low-pass

filter for the right insula, that may well underlie the cerebral laterality of auditory processing with longer time frames on the right temporal hemisphere (e.g., intonation contours-prosody) versus auditory processing with short time frames on the left temporal hemisphere (e.g., consonant sounds). They argue that insula structures contribute in the processing of temporal aspects of verbal utterances.

B.2. The left insula is involved in musical rhythm processing.

Platel et al (1997) explored the cerebral structures involved in the appreciation of music and in particular, of the different sub-components of music expression, in a PET study of six young healthy subjects. They found that timbre appreciation, which involved a same or different task, mapped to the right hemisphere, while pitch, rhythm and the judgement that the music sequence sounded familiar were processed in the left hemisphere. In particular, rhythm judgement, that involved a task of identifying whether the lengths of the intervals and notes in the given music sequence were regular or irregular, mapped to the left insula and left Broca's area. They attributed the activation of the left insula in the rhythm task, to memory processing of sound sequences in this area, and the activation of Broca's area (BA 6 and 44) to the subjects' inner strategy to recall the sounds by articulating. Alternatively, the activation of the left insula may also have to do with other demands of the task, such as perceiving the given music sequence (temporal pattern) as a whole and labelling this sequence as regular or irregular. Ablation experiments in cats have shown that the insular-temporal region of the cat brain is crucial for the animal's ability to discriminate temporal auditory patterns (e.g., A-B-A versus B-A-B) by attending to

the entire pattern (Collavita et al., 1974), and it may well be that the human insula is also involved in temporal auditory pattern discrimination.

B.3. The right insula is involved in auditory sequencing and sound movement detection.

Griffiths et al (1997) investigated central auditory function in a patient with a right hemisphere infarction involving the insula, one year after the stroke, using behavioural tests. The initial MRI showed diffuse mild atrophy and altered T2 signal in the right hemisphere and along the right insula, consistent with infarction between the right middle and posterior cerebral artery territories. One year later, the MRI showed regional atrophy in the right temporal lobe and altered signal in the right insula, while the patient only complained of the lack of musical appreciation at that time. He was found to have a dissociated amusia, with good environmental sound and language perception skills, but with poor tune recognition. He was successful in performing, albeit with significantly lower thresholds than in normal controls, a two-alternative forced choice frequency modulation detection task, with low and high modulation rates (at 1 and 2 Hz, that would correspond to orchestral music, and at 40 Hz, that would correspond to speech sounds such as consonant-vowel transition). He was also able to discriminate sequences of different frequency tones presented at a slow rate, but not at a fast rate. Assessment of his auditory spatial processing revealed auditory lateralisation deficits both for amplitude and phase cues, more prominent for sound displacement to the left, and deficits in sound movement detection tasks for

interaural phase and amplitude cues. His amusia was, thus, attributed to the deficits in auditory sequencing and sound movement detection, while speech and environmental sound perception were preserved due to their different than music acoustic structure.

C. Phonological processing

Both insulae are involved in aspects of phonological processing, such as rhyming and phonological verbal short-term memory, while the left insula is involved in phonological word recognition.

C.1. Phonological verbal short-term memory activates both insulae.

Paulesu et al (1993) assessed the verbal short-term memory and its phonological component in particular in six right-handed normal subjects using PET. They examined the main effect of phonological processing by combining the results on two experimental tasks and comparing these to the control tasks. The first experiment required the subjects to remember visually displayed English letters, based on the assumption that these letters would be transformed into a phonological code and subvocally rehearsed, while the control task used Korean letters for the same task. The second experiment required the subjects to make rhyming judgements about visually presented consonants, based on the assumption that visually rhyming decisions engage the subvocal rehearsal system but not the phonological store, with a control task that required the subjects to decide whether visually displayed Korean

letters looked similar. Phonological processing elicited statistically significant activation foci in the insula bilaterally. Similarly, Wong et al (2002), found that non-speech stimuli in the form of time-reversed sentences activated the anterior insulae on both sides. They attributed this finding to the necessity to maintain the complex stimulus pattern in short-term memory, or alternatively to sub-vocal rehearsal of the signal or the pitch patterns in non-speech. The tasks of both of these studies require some form of temporal processing, such as sequencing and pattern recognition, and perhaps the findings from both these studies may again highlight that the insula's significance for temporal processing.

C.2. Dyslexics have less activation of the insula bilaterally than normal controls when performing a phonological (rhyming) task.

Dyslexics have less activation of the insula bilaterally than normal controls when performing both a phonological task (judging whether aurally presented pairs of real words or pseudo-words or a pair of real and pseudo-word rhyme) and a lexical judgement task (judging whether both aurally presented words were real in a pair of real words or pseudo-words or a pair of real and pseudo-word) (Corina et al., 2001). The lexical task activated the left insula in all seven controls but only in two out of eight dyslexics. The authors suggested that dyslexics differ from able readers in auditory language processes that do not require reading, but may interfere with learning to read, and also may interfere with executive control and attention processes used to co-ordinate language codes as well as in lexical access. They propose that activation of the insula may reflect dyslexic's problems with articulatory coding, phonological decision or rapid automatic naming.

C.3. The left insula is activated by phonological recognition of words.

Rumsey et al (1997) examined the neural pathway involved in phonological versus orthographic strategies of word recognition, i.e. sounding out the word versus visually and/or linguistically analysing the written word in order to read it. They measured regional cerebral blood flow (rCBF) using PET in fourteen healthy male adults. The tasks involved a pronunciation task of items that were specifically constructed to favour orthographic pronunciation (e.g. words with irregular spelling) or phonological pronunciation (e.g. pseudowords), and a lexical decision task, whereas subjects were asked to decide which word in a pair sounded like a real word (phonological decision) or which word was a real word (orthographical decision). Both orthographic and phonological pronunciation tasks activated the left insula, among other areas of the brain, with a local maximum during orthographic pronunciation and with both deactivation and significant activation in different insula areas during phonological pronunciation. Phonological, but not orthographic, decision making activated the insula near its border with the inferior frontal cortex, with this insula region being superior and more laterally located than the area deactivated by phonological pronunciation, and this activation was the second most striking and robust difference in phonological versus orthographic lexical decision activation after greater activation of the left inferior frontal cortex. Similarly, Wong et al (2002) found that the left anterior insula was activated on PET by speech as well as non-speech (time-reversed speech) stimuli, compared to silent baseline. Thus, the left insula appears to be an important site for phonological recognition of words, and this may explain Shergill et

al's finding (2001), that imagining one's voice saying a phrase elicits significantly more activation of the left insula on fMRI than silently articulating the phrase.

D. Visual-auditory integration

In the cat, the anterior sylvian area, that contains the anterior sylvian gyrus and dorsal lip of the pseudosylvian sulcus, caudally to the insular areas (Clasca et al., 1997), has multiple auditory and visual connections and may integrate highly elaborate auditory and visual information (Clasca et al., 2000). Similarly, the human insula is a multimodally responsive area that integrates information from the visual and auditory sensory modalities.

D.1. The right insula is involved in detection of temporal mismatch (onset asynchrony) between simple stationary auditory and visual stimuli.

Bushara et al (2001) examined the network activated by detection of temporal mismatch (onset asynchrony) between simple stationary auditory and visual stimuli using PET in twelve right-handed healthy subjects that were asked to indicate whether the stimuli were synchronous or asynchronous. The task activated the right insula, as well as right prefrontal cortex, inferior parietal lobule and left cerebellar hemisphere. Increasing the task demand, by reducing the time-interval between presentation of the two stimuli, correlated with increased regional cerebral blood flow response only in the right insula, indicating that this area is more actively involved in this process than

prefrontal and parietal regions. These authors suggest that this inter-sensory temporal processing is mediated via subcortical tecto-thalamo-insular pathways and may underlie phenomena such as the McGurk illusion, whereby when the sound of a syllable is synchronised with the image of lip movements of another syllable, this leads to the perception of a third syllable. This also may explain the ventriloquist effect, in which temporally synchronous, but spatially disparate, visual and auditory stimuli will be perceived as localised towards their apparent visual source.

D.2. The left anterior insula will be activated by a cross-modal speed comparison of an auditory versus visual motion task.

Lewis et al. (2000) investigated the neural substrates of integration of visual and auditory motion information by means of functional MRI in eleven healthy subjects, who were asked to perform an auditory and a visual motion task in isolation or concurrently. In the auditory motion task, the subjects were required to listen to a 300Hz square wave of 300 ms that was presented to both ears with interaural intensity differences, in order to elicit the perception of sound moving to the left or to the right, through or behind the head. The apparent velocity of the sound was proportional to the interaural intensity difference. The subjects were asked to judge successive presentation of the sounds as slower or faster. The visual motion task involved a dynamic random dot stimulus, and the subjects were asked to identify the part of the annulus that contained the dots with the highest velocity motion. Both tasks elicited activation of the anterior insula bilaterally, but while activation of the insula by the

isolated auditory motion task was only moderate. it was stronger and more extensive than the insula activation by the visual motion task. The pathways activated by the auditory motion task were broadly similar to those activated by a pitch discrimination task. To further explore the area of cross-modal interaction, the authors asked four subjects to perform across-modal speed comparison, by presenting visual and auditory stimuli simultaneously and asking the subjects to compare the speeds of the visual and auditory target. This cross-modal auditory versus visual speed comparison elicited enhancement of the left anterior insula in 3 out of 4 subjects. Lewis et al. pointed out that this polymodal effect could have reflected specific task factors, such as attentional tracking of the target, selection/computation of the relevant motion parameter (speed), comparison of speeds, selection of response, as well as non specific task factors such as storage and retrieval of information from working memory.

D.3. The insula may mediate temporally defined crossmodal auditory-visual interactions.

Calvert et al (2001) assessed the areas responsible for non-speech auditory-visual stimuli integration using the BOLD effect of fMRI in ten right-handed normal subjects, using white noise and visual chequerboard as stimuli. Presentation of the auditory stimuli in isolation activated the right insula, amongst other auditory areas. However, an enhanced response with simultaneous presentation of the two stimuli or response depression when the stimuli were asynchronously presented was more prominently observed in the superior colliculi, but also in the insula bilaterally. These

results, taken together with Bushara's study (2001) indicate that the insula has a particular role in mediating temporally defined crossmodal interactions.

Comments and Conclusion

The insula has been largely ignored as an auditory centre until recently. However, the finding of very prominent auditory deficits in single case-studies of patients with strokes that involved the insula, but spared Heschl's gyrus (e.g., Hyman and Tranel, 1989; Fifer, 1993), indicate that the insula is not only an integral component of the central auditory nervous system, but a vital relay station, as its bilateral damage may result in total agnosia (Habib et al 1995). Sophisticated neuroimaging studies have helped to establish the insula's specific auditory functions. There is converging evidence that the insula is not only involved in sound detection and in entry of the sound into awareness, but also in allocating auditory attention, and in processing novel versus familiar auditory stimuli. Both insulae appear to be responsible for many aspects of auditory temporal processing that include sequencing of sounds, musical rhythm processing, prosody, as well as detection of a moving sound, while both insulae also seem to be critical for music appreciation. Not surprisingly, in view of their temporal processing functions, both insulae are involved in aspects of phonological processing, such as rhyming and phonological verbal short-term memory, while the left insula is involved in phonological word recognition. In addition, the insula appears to be a major multi-sensory integration site that contributes to the detection of temporal onset mismatch between visual-auditory stimuli, auditory-visual speed comparison and temporally defined auditory-visual

interaction, and may thus participate in both the McGurk phenomenon and the ventriloquist's effect. However, the question whether the insula is *necessary* for these functions, could only be addressed by human lesion studies. In addition, the roles of different parts within the insula remain undetermined. Thus, the posterior part of the insula, which mainly receives many afferents from the thalamus and has a staining profile of a primary sensory area, may be involved in basic, important auditory processing (e.g., Hyman and Tranel, 1989), while the anterior insula, which has an intermediate profile between a primary sensory area and a high order association area, may be more involved in integration of auditory information with other associative functions (e.g., Bushara et al., 2001; Lewis et al., 2000). At present, there is no definitive answer to this question, while the functional characterisation of the insula remains incomplete, underlining the need for further studies.

2.3. The role of the interhemispheric pathway in audition

Axons from auditory and auditory-responsive cortical areas cross the midline in the forebrain commissures of the corpus callosum and the anterior commissure (Pandya and Seltzer, 1986). The exact contribution of interhemispheric transfer in auditory processing, is still a matter of debate. This may be partly due to limitations in current basic scientific understanding of interhemispheric connectivity, as the available assessment techniques for human brains have low sensitivity (e.g., the retrograde degeneration and demyelination techniques) or are handicapped by time constraints (e.g., the Nauta method). In addition, extrapolations from animal work may offer only limited insights, due to the complexity of cognitive functions in humans (Clarke 2003), while it would be unwise to accept extrapolations from other sensory modalities, such as vision, at face value. In more recent years, human behavioural studies which employ psychoacoustic tasks designed to tap into interhemispheric transfer, combined with sophisticated neuroimaging paradigms, have helped to interpret information from animal experiments and post-mortem studies. The following paragraphs will attempt to summarise and discuss the available information of the contributions of the human interhemispheric pathway in audition from behavioural, imaging and histopathological studies in both animals and humans.

Anatomy

The corpus callosum (CC) is the largest fibre tract in the primate brain. It consists of 200,000,000 – 350,000,000 heavily myelinated fibres (Aboitiz et al., 1992 a and b) in humans. The human anterior commissure (AC) has an average area that is 1% of the

total callosal area (Foxman et al 1986). Both formations connect the two hemispheres in the human (Aboitiz et al., 1992a) (figure 10).

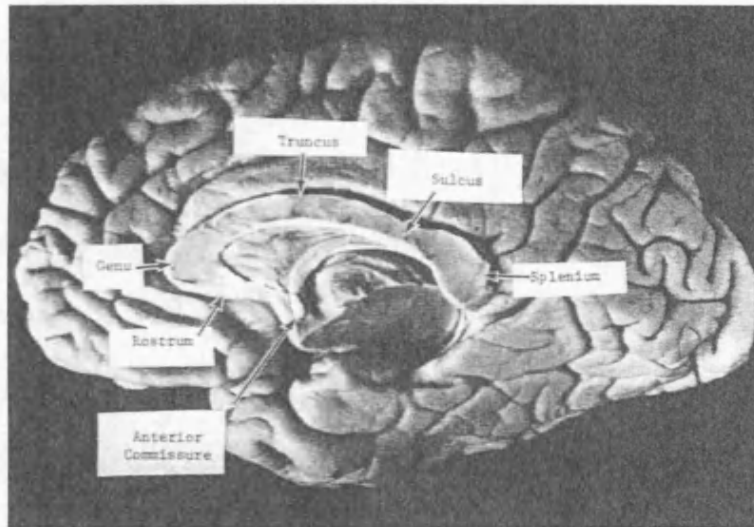


Figure 10. Midsagittal section of the brain showing the corpus callosum and the anterior commissure. (AC, rostrum, genu, body or trunkus, isthmus or sulcus, splenium) From Musiek, 1986.

The corpus callosum is located at the base of the longitudinal fissure and the upper surface of its mid-portion is covered by the cingulate gyri, while its inferior part forms part of the roof of the lateral ventricle. The anterior commissure crosses the midsagittal plane below and posterior to the rostrum of the corpus callosum (Di Virgilio et al., 1999). Through these two formations, each cortical area is reciprocally connected to its corresponding contralateral area (homotopic connection), as well as to an additional set of contralateral areas (heterotopic connections) for which there is intrahemispheric connection with their corresponding ipsilateral counterparts (Pandya and Seltzer, 1986). The mid-portion of the inferior temporal, fusiform and parahippocampal gyri have been shown to have dense heterotopic connections with the posterior part of the superior temporal gyrus, the planum temporale and the some

connection with the supramarginal and angular gyri, as well as weaker connections with the inferior frontal gyrus of the other side (Di Virgilio and Clarke 1997).

Witelson (1995) proposed the subdivision of the CC into three main regions, on the basis of its maximum straightened length: (figure 11)

- a. The anterior third or genu which contains fibres connecting the prefrontal cortices
- b. The middle third or midbody which contains projections from motor, somatosensory and auditory cortices in anteroposterior sequence
- c. The posterior third, which consists of the isthmus, the region between the midbody and the posterior fifths of the CC, which contains projections from the superior temporal, perisylvian and parietal areas and the posterior fifth or splenium, which contains fibres from temporoparietal and occipital cortices.

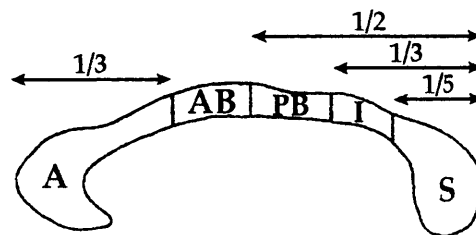


Figure 11. Subdivision of the CC as proposed by Witelson (1995). A = anterior third or genu, AB = anterior body, PB = posterior body, I = isthmus, S = splenium.

Vascular supply

A study examining the arteries of the corpus callosum in 20 cadaver brains under the operating microscope found that the anterior communicating artery, the pericallosal artery (i.e. the portion of the anterior cerebral artery distal to the origin of the anterior communicating artery), and the posterior pericallosal or splenial artery were the main

sources of the blood supply of the corpus callosum (Ture et al., 1996). The posterior half of the corpus callosum is supplied by the posterior pericallosal artery. In addition to the posterior pericallosal artery, a thin artery named as “accessory posterior pericallosal artery”, arising from of the parieto-occipital, hippocampal, medial posterior choroidal, or the lateral posterior choroidal artery, supplied blood to the splenium in a quarter of the hemispheres. the anterior communicating artery (its subcallosal branch) also supplies the mid portion of the anterior commissure (figure 12).

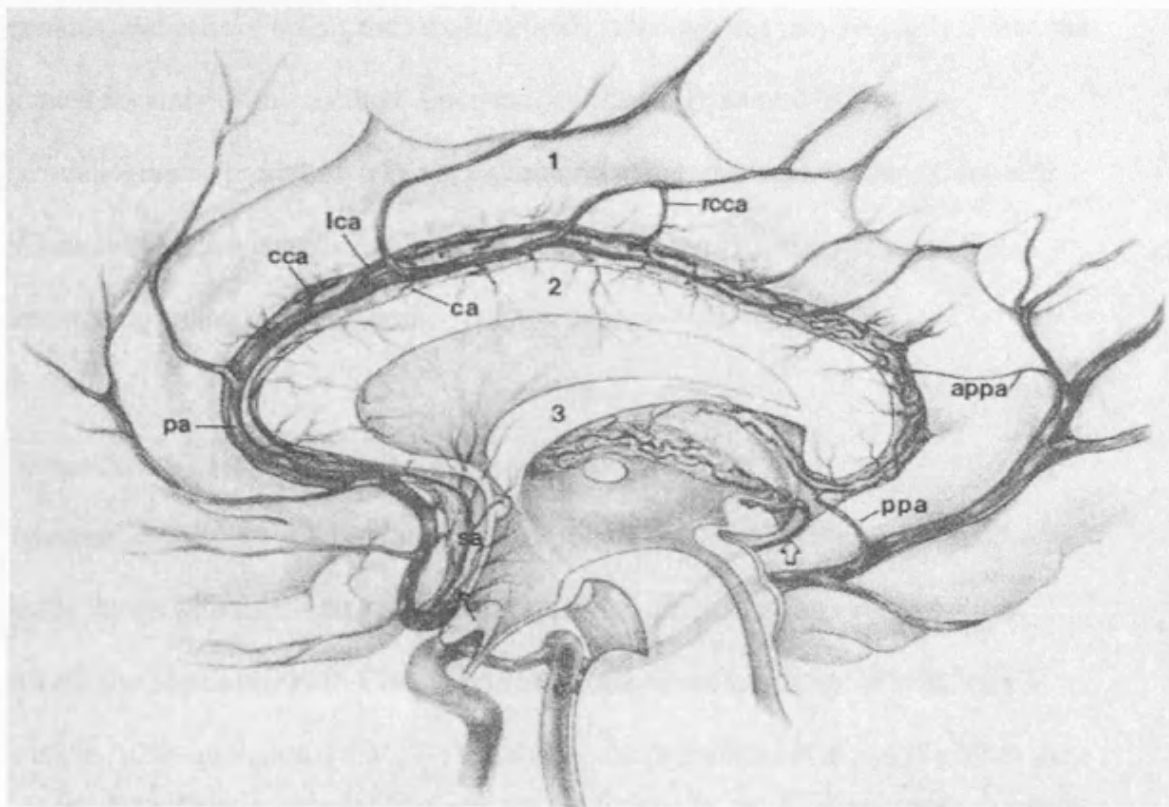


Figure 12. Arterial vascularization of the human corpus callosum in the right cortex.

ACoA = , appa = accessory posterior pericallosal artery, ca = callosal artery, cca= cingulocallosal artery, lca = long callosal artery , pa = pericallosal artery, ppa = posterior pericallosal artery, rcca = recurrent cingulocallosal artery, sa = subcallosal artery. From Ture 1996.

Cytoarchitecture

Callosal axons emanate from pyramidal neurons in layer III, and to a much lesser extent from the infragranular layers V and VI (Innocenti and Bressoud, 2003). Similarly, the largest concentration of terminal fields of commissural neurons from primary auditory cortex in the cat are found in layer III, and to a lesser extent in layers V, VI and I, with layer IV having the lowest concentration, followed by layer II (Code and Winer 1986). However, combined anterograde and retrograde studies with superimposition of the results indicate that there is no strict reciprocity between commissural cells of origin and terminal fields, although this may be partly due to the limited accuracy of this method, since the cell shrinkage caused by the autoradiographic procedure may not be uniform across the brain section (Code and Winer 1986). Most commissural axons establish excitatory synapses, some terminating on inhibitory neurons.

Neurochemistry

Immunolabelling microscopic studies have shown that several axon terminals found in the layers where callosal axons terminate are glutamate and aspartate positive (Conti and Manzoni 1994). Cholinergic axons are found to migrate to both the CC and the AC on gestational day 17-18 in the mouse (Schambra et al., 1989). Both the CC (Gonchar et al., 1995) and the AC (Misaki et al., 2004) contain GABA-ergic neurons. Inhibitory GABA-immunopositive neurons account for only 3-5% of callosal projections in adult rats (Gonchar et al., 1995) vs. 21% in neonatal rats (Kimura and Baughman, 1997), indicating that the majority of inhibitory fibres are eliminated postnatally

Topography and organization of commissural fibres

The topographic organization of the interhemispheric fibres is defined by the cortical regions they connect. e.g. fibres connecting the frontal cortices travel at the front and those connecting the occipital cortices travel at the back of the corpus callosum (Aboitiz et al., 2003). Thus, these neurons establish a connecting map between the two hemispheres with a number of alternative intra- and inter-hemispheric routes (Pandya and Seltzer, 1986). In addition, the pattern of interhemispheric connections is related to the architectonic characteristics of the areas of origin of the fibres, e.g. fibres from the rostral superior temporal region, which has a less well differentiated lamination pattern, travel in the anterior commissure, while fibres from the posterior superior temporal region which is characterized by well-differentiated cortical layers, travel in the corpus callosum (Cipolloni and Pandya 1985). The organization of the auditory area of the corpus differs from that of its visual and somatosensory parts, in that it is tonotopic rather than topographic, i.e. its constituent stripes represent tonal rather than sensory space (Aboitiz et al., 2003).

Pandya and Seltzer (1986) reviewed a number of studies on the topography of commissural fibres from the temporal cortex, based on degeneration studies (of commissural fibres after cortical ablation, or of terminal cortical degeneration after commissural section), and on auto radiographic studies. They reported that the primary and secondary auditory cortices (AI and AII) and the caudal superior temporal gyrus and adjacent upper bank of the superior temporal sulcus send fibres via the caudal part of the corpus callosum. Fibres from other auditory responsive areas, such as the inferior part of the parietal lobe and insula are contained in the caudal portion of the corpus callosum and splenium (Musiek 1986). The dorsal part of the temporal pole, rostral superior temporal gyrus, upper bank of the adjacent superior

temporal sulcus as well as the ventral temporal pole, rostral inferotemporal area and rostral part of the lower bank of the superior temporal sulcus send fibres to the opposite hemisphere via the anterior commissure, while the mid portion of the superior temporal gyrus and superior temporal sulcus send fibres via both the anterior commissure and the corpus callosum (Pandya and Seltzer 1986). Subsequent tracing studies in the macaque monkey have shown that the anterior commissure contains fibres almost from the entire temporal cortex (Demeter et al., 1999). A further study by means of the Nauta method for anterogradely degenerating axons in humans with focal hemispheric lesions confirmed that the anterior commissure has a large number of fibres from the inferior posterior part of the temporal lobe (Di Virgilio et al., 1999). However, the pathway taken by heterotopic callosal fibres is less well established, and may not be located in the same part of the corpus callosum as the homotopic projections (Clarke 2003).

There are two types of axons in the corpus callosum. Large diameter fibres mediate sensory-motor coordination while small diameter fibres connect association areas. The small diameter fibres are more numerous and individual differences in callosal size have been shown to be a reflection of the proportion of the small diameter type (Aboitiz et al., 1992). Large diameter fibres with fast conduction times are found in abundance in the posterior part of the midbody of the CC (auditory area) (Aboitiz et al., 2003). These fibres may enable fast bilateral interaction which subserves sound localization in space (Aboitiz et al 1992). In contrast, the anterior part of the splenium and the isthmus which contain areas from what can be conceived as auditory association areas, contain smaller diameter fibres (Aboitiz et al., 2003).

Interhemispheric connectivity and brain asymmetry

Aboitiz and colleagues (1992 a, b) compared the magnitude of the asymmetry in size of the left vs. right Sylvian fissures, as measured from Heschl's gyrus to the end of the ascending branch, to the size and fibre composition of the corpus callosum, by means of light microscopy. They observed a significant negative correlation between left to right auditory cortex asymmetry and size of the isthmus as well as the number of small, medium sized and moderately large fibres of the isthmus in males, and between asymmetry and the size of the anterior third of the splenium as well as the number small and medium size fibres of the anterior third of the splenium in females. The small sample of these studies (10 subjects of each sex) did not permit to conclude whether the difference in asymmetries between the two sexes was due to a differential mapping of asymmetric areas or differential cortical asymmetries in the two sexes. In addition, at present, there is no conclusive evidence that a specific part of the corpus callosum contains all the callosal fibres from a specific cortical region (Clarke 2003). Nonetheless, these findings may indicate that increased functional lateralisation of the brain is associated with decreased interhemispheric connectivity (Aboitiz et al., 2003), consistent with the parallel developmental process of gray matter "pruning" and CC postnatal development, as discussed in the previous section. Aboitiz and colleagues (2003) proposed that early presenting cortical asymmetries lead to an increased retraction of bouton terminals in the corpus callosum during the elimination phase of corpus callosum fibres, and this in turn reinforces the functional asymmetry/lateralisation, by limiting connectivity between specialised areas of the two hemispheres.

Broadly similar conclusions were reached by Chance et al (2006), who examined the relationship between minicolumnar organization of Heschl's gyrus (primary sensory auditory cortex) and the planum temporale (association auditory cortex) and axonal distribution as a measure of callosal connectivity in the brains of 17 neurologically normal adults post mortem. The brain cells migrate to the cortical surface during embryogenesis to form minicolumns and larger macrocolumns, which underlie the functional organization of the cortex (Rakic, 1995). The primary sensory auditory cortex in the superior temporal gyrus has a well defined columnar cell organization by the third trimester of foetal life, which becomes established in early childhood, but axonal maturation continues up to at least 12 years of age (Moore and Guan, 2001). Chance et al (2006) found that asymmetries of minicolumn number in primary and association auditory regions correlated with axonal fibre numbers in the connecting subregions of the corpus callosum, and this may reflect selective elimination of callosal projections.

Intriguingly, they found differences in the relationship between minicolumn organization and callosal axon numbers in Heschl's gyrus vs. the planum temporale. They reported an increased size of the left Heschl's gyrus, due to an increasing number of minicolumns, with no significant asymmetry in minicolumn spacing, associated with increased callosal axon number. In the planum temporale, there was a larger number of minicolumns in the right planum temporale, which was associated with increased axon number, and a leftward asymmetric minicolumn spacing. Chance et al (2006) suggested that these differences between Heschl's gyrus and planum temporale reflect the different hierarchical status of these two cortical regions, as Heschl's gyrus is predominantly primary sensory cortex, which matures sooner and show less capacity for neuroplasticity (Arendt, 2003) than the association cortical area

of the planum temporale. Their findings of increased regional surface area and minicolumn size asymmetries in planum temporale vs. Heschl's gyrus may indicate that functional lateralization becomes progressively more prominent from the primary sensory to the association cortex.

Embryology

The CC is exclusively present in placental mammals, while in acallosal mammals, most of the CC related functions are carried out by the anterior commissure and, to a lesser extent, the hippocampal commissure (Aboitiz and Montiel, 2003). Due to the lack of a homologous structure in nonplacental species, the CC is thought of as a true evolutionary novelty (Aboitiz and Montiel, 2003).

At around 8–10 weeks' gestation age, the anterior commissure connects the hemispheres at the lateral striatal ridge of the amygdala (Gilles et al., 1983). The corpus callosum starts developing between 8 to 17 weeks of gestation age, with an anterior (genu) to posterior (splenium) growth pattern (Rakic and Yakovlev 1968). Callosal connections will initially develop through a phase of exuberance, which may possibly underline the remarkable potential for plasticity of the developing brain. Stages in the differentiation of callosal axons are summarized in table 2 (from Innocenti and Bressoud 2003).

Table 2. Stages in the differentiation of callosal axons.

Stage I:	Axonal elongation: a glial bridge develops at the midline for the first callosal axon to cross (destruction of the bridge leads to callosal agenesis). Subsets of intrinsically different callosal neurons develop and specific projection patterns are established.
Stage II:	Subcortical branching. Formation and retraction of new branches. Stage ends when gray matter branching begins. This stage may be crucial in guiding thalamic axons into the grey matter (Allendoerfer and Shatz 1994). Stage III: Cortical ingrowth.
Stage IV:	Cortical branching. Number of branches higher than that in adults.
Stage V:	Synaptogenesis. Greater number of boutons than in the adult, with a layer- and column-specific distribution.

Retrograde tracer studies have shown that the phase of callosal fibre exuberance will be followed by a phase of synaptic refinement, with selective elimination of axonal projections in all areas, including the auditory area of the corpus callosum (Feng and Brugge 1983). The same pattern of axon overproduction and subsequent elimination has been shown in the anterior commissure in monkeys (La Mantia and Rakic 1994).

There are at least forty-six malformation syndromes and metabolic disorders and at least 12 identified genes associated with phenotypic manifestations of complete agenesis or hypoplasia of the corpus callosum with or without agenesis or malformation of the anterior commissure (Kamnasaran, 2005). In contrast, the phenotype of an absent anterior commissure with a present but hypoplastic corpus callosum has only been recently been reported in patients with congenital autosomal dominant aniridia due to mutations in the *PAX6* gene (Sisodiya et al., 2001). The *PAX6* gene encodes a transcriptional regulator that is highly conserved across species (van Heyningen and Williamson, 2002). The *PAX6* is essential for eye development but also for normal development of the central nervous system, including the forebrain, hindbrain and spinal cord. In the brain, in particular, it is known to regulate regional cortical development, neuronal migration and thalamocortical and corticothalamic axon pathfinding (Hevner et al., 2002; Jones et al., 2002; Talamillo et al., 2003). The population with *PAX6* mutations may be a good model to study some aspects of interhemispheric transfer in the presence of pathology of the interhemispheric pathway, particularly since a. although rare, *PAX6* mutations accounts for 90% of autosomal dominant cases of congenital aniridia (van Heyningen and Williamson, 2002), so these patients are easy to identify, b. the phenotype includes malformations of both the anterior commissure and the corpus callosum and c. these patients are reported to be of normal intelligence (Thompson et al., 2004).

Post-birth age-related changes of the auditory interhemispheric pathway

Neuronal differentiation will be complete by the time of birth, however, several other changes will continue throughout life. Elimination of fibres will continue in the early perinatal period and around 70% of the axonal projections in the corpus callosum and

anterior commissure will be eliminated to reach adult values in cats, monkeys, as well as humans (Innocenti 1986; Innocenti 1991; La Mantia and Rakic 1994). In human foetuses, the corpus callosum area (CCA) decreases slightly between about 33 weeks of gestation and the beginning of the second postnatal month (Clarke et al., 1989), reflecting this process of elimination. This elimination is signal driven (from thalamic afferents) and may be determined both by cellular specificity as well as by the levels of sensory activity, integrity of the sensory receptors and brain areas and other internal and external factors (Innocenti, 1991). The remaining callosal connections will show a gradual increase in axonal diameter and myelin deposition (Carlson et al., 1988). Myelination, i.e. encasement of the axons by myelin sheaths, leading to faster neural conduction, will occur in a posterior to anterior pattern, and the corpus callosum will be more than double its birth size at the age of 2 years, possibly reflecting increasing levels of activity and complexity of interaction between the infant and the environment (Yakovlev and Lecours, 1967). Completion of myelination of CC fibres occurs later than for other cortical fibre tracts, and may not be complete until 10 years of age or older (Yakovlev and Lecours, 1967). Of interest, it has recently been proposed that myelination may be an overlooked mechanism of stimulus-driven plasticity, which may extend in humans until at least age 30 (Fields, 2005).

The rostro-caudal growth pattern of the corpus callosum has been investigated by serial high-resolution three-dimensional magnetic resonance imaging (MRI) scans and by computing three-dimensional elastic deformation fields, which permitted to reconfigure the earlier anatomy into the shape of the later scan anatomy in normal children aged 3 to 15 years (Thompson et al, 2000). Between ages 3 and 6 years,

growth rate at the isthmus was slow, while between ages 6 to 15 years, the highest growth rate was observed in temporo-parietal systems subserving auditory/ for language functions. In particular, the callosal isthmus showed a markedly rapid growth pattern (up to 80%) between ages 7 and 11 years (Fig. 13 and 14), in contrast to a relative stability of the splenium and rostral CC. And while the growth rate was reduced between ages 11-15 years, the growth pattern at the isthmus and splenium was still more rapid than in the more rostral CC, which showed a near zero change.

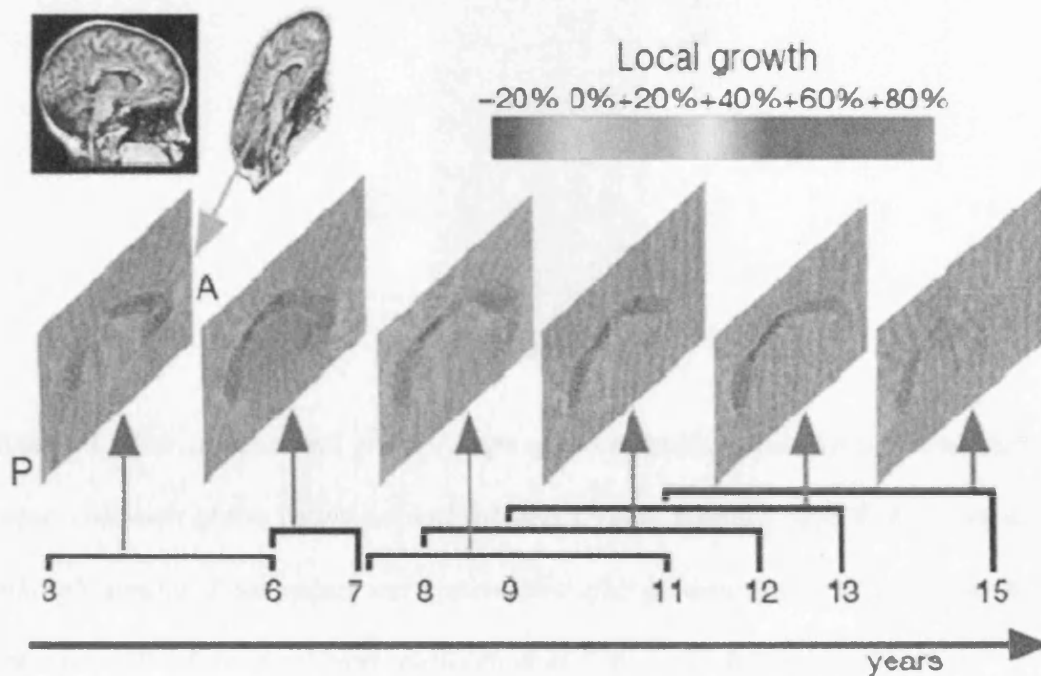


Figure 13. Growth patterns in the developing human brain detected at ages 3±15 years. A is detected in Serial scanning of young normal subjects across time spans of up to four years shows a rostro-caudal wave of peak growth rates. Between ages 3 and 6 years, peak growth rates (red colours; 60±80% locally) were detected in the frontal circuits of the corpus callosum. Older children displayed fastest growth at the

callosal isthmus. Between ages 11 to 15 years, growth rates still peak at the isthmus, but are attenuated. From Thompson et al., 2000.

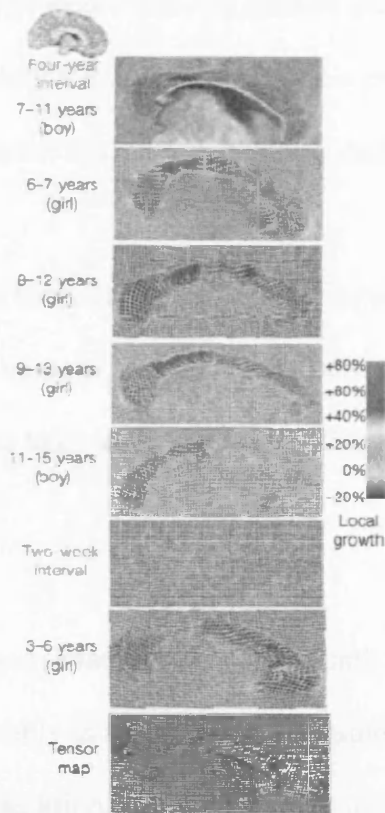


Figure 14. Four-dimensional growth maps of brain development. Growth rates in the corpus callosum of five young normal subjects serially scanned aged 6±13 years are strikingly similar. Peak values were attenuated after puberty (11 to 15 years) at the posterior midbody (red colours). Between ages 3±6 years, the anterior interhemispheric fibre systems showed extreme growth rates. Tensor maps showed that the principal directions of growth rates in frontal regions were outwards. From Thompson et al., 2000.

During about the same time span, from ages 4 to 21, the brain's gray matter volume diminishes in a back-to-front pattern, with cortical areas seen to “mature” at ages in

which relevant developmental milestones are achieved, and this maturation process is thought to reflect the “pruning” of unused neuronal connections (Gogtay et al., 2004). Thompson et al (2000) have proposed that this gradual quiescence of growth at the rostral callosum around puberty may be a precursor to a prolonged regressive process of grey matter loss through adolescence into adulthood in the frontal circuits it innervates.

It has been suggested, on the basis of findings on PET studies, that the progressive postnatal elimination of CC neurons is reflected by decreasing levels of neural activity evoked by complex cognitive tasks with maturation (Chugani et al, 1987).

The size of the corpus callosum continues increasing until the third decade of life (Pujol et al., 1992), most notably in the splenium and isthmus (Rajapakse et al., 1996; Thompson et al., 2003). In addition, there is a relative increase in the number of large (diameter > 1µm) and very large (diameter > 2µm) diameter fibres with increasing age at least until the seventh decade of age in humans (Aboitiz et al., 1996), possibly related to the establishment of automatic neural circuits. This increase is seen throughout the CC for males, while in females there is an age-related increase for large and very large fibres which connect higher order and basic sensory auditory areas respectively (Aboitiz et al., 1996; Aboitiz et al., 2003). The size of the corpus callosum will gradually decrease after the 4th decade of age, with posterior areas maintaining a more stable size with aging than anterior areas (Pujol et al., 1992; Paraschos et al., 1993).

Of interest, variations of the size of the auditory areas of the CC have been reported in association with several brain disorders. For example, there is a severe reduction of the size of the isthmus in Alzheimer's disease, associated with a greater variability in the left perisylvian fissure surface and greater variability of left to right sylvian fissure asymmetry (Thompson et al., 2003).

Human behavioural & neuroimaging auditory studies of the interhemispheric pathway.

Dichotic test paradigms

Test definition and theoretical models

In dichotic listening, two similar, but not identical, verbal or non-verbal sound stimuli are simultaneously presented, one to each ear, and the tasks include recall (in which the listener has to repeat the stimuli) or detection tasks (in which the patient has to detect a given stimulus). The dichotic listening technique was invented by Broadbent (1954), and subsequently employed by Kimura (1961) in the study of both normal subjects and patients with brain lesions. Dichotic tests with verbal stimuli in normal subjects show a right ear advantage, which has been historically attributed to the left hemisphere language specialisation and to the dominance of the contralateral auditory pathway when the two ears are in competition i.e., in the dichotic condition (Kimura 1969). The hypothesis was first described by Kimura (1967) and received support from studies on patients with surgical section of the corpus callosum (Milner et al., 1968; Sparks and Geshwind, 1968). Zaidel (1986) subsequently proposed that dichotic

speech tasks assess interhemispheric transfer according to the “callosal relay” model. This model is based on the assumption of a left hemisphere supremacy in language perception and of the contralateral pathway dominance in auditory signal transmission. According to this model, speech stimuli entering the right (non-language) hemisphere will require callosal transfer to the left (language) hemisphere in order to be processed, thus requiring extra transfer time, responsible for the finding of longer reaction time to verbal left-ear stimuli (Hughdahl et al., 1997). Conversely, the “direct access model” proposes that speech stimuli from the left ear will be directly analyzed in the right auditory cortex, albeit less efficiently than in the left cortex (Zaidel, 1986).

Findings in patients with congenital& acquired pathologies of the interhemispheric pathway

There are several lines of evidence in support of the “callosal relay model.” Dichotic test results may correctly predict hemispheric language dominance (as assessed by the Wada test) correctly in more than 90% of cases (Hughdahl et al., 1997). Results of psychoacoustic task experiments and findings in split-brain patients (i.e., patients with surgical section of the interhemispheric pathway) seem to render further support to this model. There are some general caveats in the interpretation of dichotic test results after section of the interhemispheric pathway, as it is difficult to evaluate the completeness of the transection, the reliability of surgical landmarks can be variable, while the effect of previous pathology on the dichotic test results has not always been established by testing prior to the operation in the majority of published studies. Notwithstanding these reservations, the majority of studies indicate that patients with surgical section of the interhemispheric pathway will give a characteristic combination of test results, with normal results in monaural speech tests (Musiek and Reeves, 1986), reduced to

near extinct left ear performance in dichotic digits and consonant vowels (CVs), and decreased left ear performance and increased right ear performance in dichotic rhyme tests (Musiek et al., 1989).

The dichotic rhyme test consists of two words with similar spectral envelopes which are temporally well aligned and presented dichotically in the two ears, with only one word identified by the listener most of the time, possibly due to fusion of the words, although two are presented (Wexler and Halwes, 1983). It has been proposed that the demand placed on the left (language) hemisphere for this task is increased compared to other dichotic tests (such as digits), since the dichotic rhyme test stimuli are complex and very well aligned in time, thus the increased right ear score after commissurotomy is due to a “release from competition” of the left hemisphere (Musiek et al., 1989).

Geffen’s study (1980) may offer some support to this notion. She found that patients with partial section of the corpus callosum had reduced left ear scores for a dichotic test with non-fusible words with close but not simultaneous onset time, and normal results for “fusible” words (e.g., the pair “back – lack” may be fused to “black”).

Springer and Gazzaniga (1975) have also reported better right ear scores on dichotic CV tests in commissurotomised subjects than normative data, consistent with this hypothesis, although they did not test preoperatively.

Results in psychoacoustic dichotic non-speech tests are also compatible with the “callosal relay model.” Bryden and MacRae (1989) devised a dichotic test with both emotional and verbal content. The stimuli consisted of 4 nonsense disyllable words differing in the initial consonant only, pronounced by a professional actor in happy, sad, angry and neutral tones. A pair of differing words in verbal and emotional

content was presented, one word to each ear. Subjects were asked to indicate whether target word or target emotional tone occurred in each pair. They found a right ear advantage for verbal and left ear advantage for emotional stimuli in normal listeners. Habib et al (2003) also assessed (auditory) emotional transfer through a dichotic paradigm using four different non-words pronounced by an actor with one of four different emotional tones (fear, disgust, sadness, anger) in 20 mildly affected multiple sclerosis patients and 20 normal controls. Subjects were asked to detect the occurrence of one given phoneme (verbal condition) or a given emotional tone (emotional condition). They found a right-ear advantage for the verbal condition and a left ear advantage for the emotional condition in the entire group. The multiple sclerosis patients showed significantly poorer performance than the control group at the ear ipsilateral to the hemisphere presumed to be dominant for the test condition, i.e. a lower left ear score for the verbal condition (left hemisphere-language) and lower right ear score for the emotional condition (right hemisphere-emotion), consistent with the hypothesis that MS-related callosal damage impairs interhemispheric transfer of information.

The above mentioned pattern of dichotic speech test findings in patients with commissurotomy is specific for section of the posterior part of the corpus callosum and splenium (Musiek and Reeves, 1986; Risse et al., 1989), which contain auditory fibres, while anterior section of the corpus callosum causes no such effects (Baran et al., 1987). In a more recent studies, Sugishita et al (1995) investigated dichotic listening performance in 5 patients with well-defined lesions of the corpus callosum assessed by MRI and concluded that lesions of the splenium and most posterior part of the body of the corpus callosum led to a depressed left ear score.

Congenital aplasia or early life damage of the corpus callosum causes similar, albeit milder impairments on dichotic and other tests that require auditory interhemispheric transfer, than that observed in patients with commissurotomy (Santhouse et al., 2002; Lessard et al., 2002). The presence of milder deficits is probably due to development of alternative pathways resulting from brain plasticity (Santhouse et al., 2002; Lessard et al., 2002). Of interest, we first reported dichotic test deficits in a patient with *PAX6* haploinsufficiency, associated with an absent anterior commissure and present corpus callosum on the brain MRI (Bamiou et al., 2004a). In cases with congenital agenesis of the corpus callosum, there is anecdotal evidence that hypertrophy of the anterior commissure may be associated with better functional compensation (Fischer et al., 1992), due to re-routing of some of the neuronal axons through the anterior commissure (Rauch and Jinkins 1994). However, the anterior commissure is found to be enlarged in only 10% of cases with callosal agenesis, and it is entirely absent in another 10% (Rauch and Jinkins 1994). Thus the role the anterior commissure plays, in the absence, section or pathology of the corpus callosum, with regards to the dichotic test performance, is under debate. It has been proposed that the presence of an intact anterior commissure in callosotomy cases is associated with milder auditory deficits (Risse et al., 1978), or not (McKeever et al., 1981), while hypertrophy of the anterior commissure in cases with corpus callosum agenesis may enable functional compensation (Fischer et al., 1992). Risse et al (1978) reported on a patient with section of the corpus callosum but with intact anterior commissure, who did not show a reduction in the left ear score on dichotic CVs after commissurotomy, and interpreted this finding as indicating that the anterior commissure was responsible for the transfer of auditory information from the left ear. However, it is difficult to draw

valid conclusions from this single case study, since this patient had suffered diffuse damage to the right hemisphere after herpes encephalitis and had had anterior temporal lobectomy 6 years before the callosotomy. The results given before the operation for the CVs tests (reduced left ear score of 37% and increased right ear score of 81%) would indicate that some dysfunction of the interhemispheric pathway was already present before the callosotomy, because cortical lesions may also give abnormal results in dichotic tests, while damage to the terminal part of the callosal fibres in the cortex may result in damage to the neurons found in the corpus callosum (Musiek, 1986). It is therefore possible that some reorganization of interhemispheric transfer had already taken place before the callosotomy, and subcortical pathways may have been implicated in this. After the operation, the patient gave essentially unchanged left ear scores (36%) but increased right ear scores (84%) in the dichotic CVs test, and this latter increase may be due to the “release from competition” of the left hemisphere (Musiek et al., 1989) due to the section of the corpus callosum. McKeever et al (1981) conversely reported marked or complete depression of the left ear score in three callosotomy patients with an intact anterior commissure. Fischer et al (1992) reported visual and tactile interhemispheric transfer tests in two cases with CC agenesis, in which the case with a present, hypertrophied AC had milder deficits than the case with absent AC. While it is difficult to draw conclusions based on single case studies, it must be borne in mind that

- a. the AC is phylogenetically older than the CC and may thus show less capacity for neuroplasticity (Arendt, 2003)
- b. AC fibres arise from less well differentiated auditory areas, than the fibres of the CC, and are more likely to carry “basic” sensory information, while dichotic test

results are the end product of sensory information and an interaction of top-down processes.

Effect of higher order ("top-down") processes on dichotic listening

In recent years, theories about the role of interhemispheric transfer in audition have become broader, to accommodate the effects of higher order, top-down processes. Complex dichotic speech tasks activate a wider network in each hemisphere than simpler tasks, and it has been proposed that the dichotic test results may well reflect both the effects of interhemispheric transfer as well as asymmetries in processing efficiency (Jäncke 2002). Hugdahl (2003) in particular, proposed that dichotic listening is the end result of interaction between the bottom-up, i.e. stimulus driven, laterality effect and the top-down, strategy related (e.g. attentional) effect, which may also be related to the instructions given to the subject (e.g., attend to the right or left ear first). In addition, Weisman and Banich (2000) proposed that while processing required for simple tasks may take place in one hemisphere, for tasks of increased complexity processing is more efficient when divided between the two hemispheres, by means of the CC, and that the brain can adaptively change the mode of processing depending on the complexity of the task. These effects generalize across the visual, somatosensory and auditory modalities (Weisman and Banich, 2000; Passarotti et al., 2002). Thus, the degree of callosal transfer required may correspond with the degree of task difficulty, with complicated tasks requiring recruitment of networks in both hemispheres responsible for both sensory and higher order processing.

Both earlier, as well as more recent, highly sophisticated neuroimaging studies have given similar results. Coffey et al (1989) found increased right hemisphere activation for left ear advantage subjects and a tendency for a left hemisphere activation for right ear advantage subjects by means of the ^{133}Xe inhalation technique. Hugdahl et al (2000) found stronger cerebral blood flow activation of the left superior temporal gyrus for a verbal dichotic task by means of a ^{15}O -PET technique. More recently, Jäncke and Shah (2002) used an fMRI technique in order to measure asymmetries in the haemodynamic response of the auditory cortex produced by a dichotic syllable detection task, the effect of focused attention as well as the extent of the cortical response in 10 normal volunteers. There was additional activation for the dichotic vs. the binaural condition in a prefrontal area, in the vicinity of Broca's area and in an inferior part of the inferior frontal gyrus on the left, as well as in an inferior part of the inferior frontal gyrus and the right superior temporal gyrus (from Heschl's area to the planum temporale). The forced attention condition revealed additional activation to that of the binaural condition in the inferior frontal gyri on the opposite side of the ear for which the subject was attending. Jäncke and Shah (2002) argued that dichotic listening tasks require attentional processes within the auditory cortex network as well as areas associated with executive functions of frontal brain. They proposed that the increased activation of the right auditory cortex on the non-focused attention dichotic task may indicate either involvement of that site with direct phonetic analysis (direct access model) or with the transfer of phonetic information to the left cortex (callosal relay model). They also proposed that the activation of the inferior frontal gyri may be due to "overspreading" of activity from Broca's area, or to working memory processes, thus, dichotic tasks may tap into more global processing strategies, than previously thought.

The effect of attentional modulation, in particular, on dichotic tests is noteworthy. The typical right ear advantage observed for speech may increase if the tested subject is instructed to focus attention to the right ear, while an instruction to focus attention to the left ear will result in an increased left ear score, which may even lead to a left ear advantage in adults (Hugdahl and Andersson, 1986). A PET study of the forced attention effect during forced dichotic listening has shown decreased activation of primary and secondary auditory cortices in the focused vs. the non-focused listening condition, which may indicate facilitation of callosal transfer during focused attention (Hugdahl et al, 2000) (figure 15).

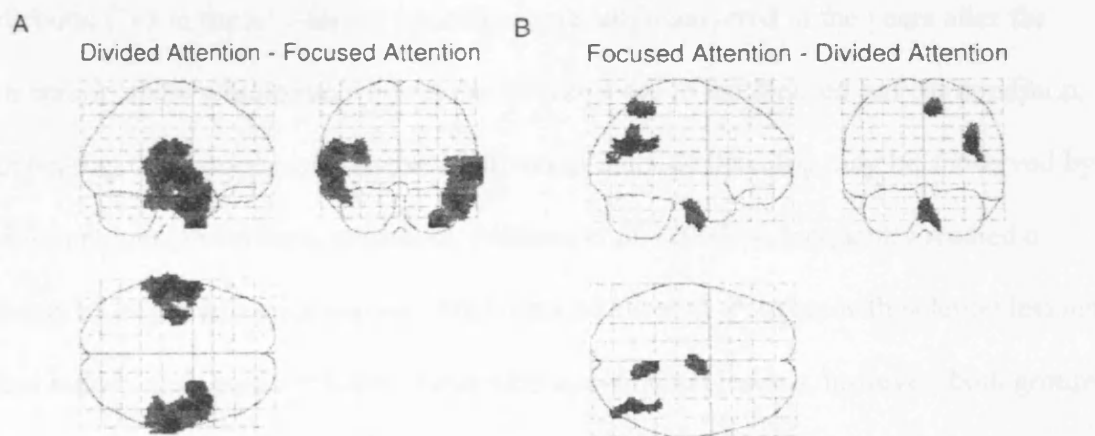


Figure 15. A: Regions activated during the divided attention minus the combined focused attention conditions. B: The lower panel show the reversed subtraction, i.e. the focused attention conditions minus the divided attention condition. The data were transformed to Z-scores in the SPM-96 analysis software and projected through sagittal, coronal, and axial views of a transparent brain. From Hugdahl et al 2000 .

Sensory (“bottom-up”) vs. higher-order (“top-down”) contributions to dichotic listening: are they subserved by different interhemispheric pathways?

The interhemispheric pathways responsible for the bottom – up (sensory input) driven and the top-down attention laterality effect of dichotic tests may well be separate. Zaidel, Zaidel and Bogen (1996) reported on a 30 year old male patient who had anterior section of the corpus callosum which spared the splenium. His normal right ear advantage on dichotic CVs in the non-forced condition before the operation became much greater after the operation. But while his left ear score on the dichotic CVs in the non-forced condition gradually recovered in the years after the operation, there was no recovery in the left ear score in the focused left ear condition, indicating that forced and non-forced attention dichotic listening may be subserved by different interhemispheric pathways. Pollman et al. (2002) subsequently studied a group of 10 patients with lesions of the corpus callosum. Patients with splenial lesions had higher laterality scores than those with non-splenial lesions, however, both groups showed lack of benefit from focused (vs. the non-focused) attention to the left ear on a dichotic CV task, independent from the site of lesion. These two studies may also indicate that focused attention is almost exclusively callosally mediated, and that the left ear performance in dichotic tests under the left ear focused attention condition

may reflect callosal transfer efficiency (Hugdahl 2003). Hugdahl (2003) has further proposed that callosal transfer may involve a sensory modality specific channel, involving the large diameter myelinated fibres, and a diffuse channel subserving the transfer of higher order cognitive functions, such as attention, involving the small diameter non-myelinated fibres, with this second channel being recruited in situations of increased cognitive load (e.g., the cocktail party situation) or dysfunction of the corpus callosum.

The results of Westerhausen et al (2006) may be also consistent with this postulation. The authors assessed 40 right-handed healthy male participants with morphological and diffusion tensor imaging. They found that a dichotic CV task with and without attentional modulation, significantly correlated to various subregions of the CC at both macro- and microstructural levels. Specifically, they found a negative correlation between the auditory lateralization score (i.e., the percentage difference between right- and left-ear scores) in the non-forced condition and the area measures of total CC, including the genu, truncus, and posterior subregions, b. the left ear score was positively related to callosal areas in total CC and in all subregions, while the right ear score was negatively associated to area measures in total CC, truncus, and posterior third c. a positive association between the mean diffusion in the posterior third region of the CC on the DTI and the right ear reduction in score when focusing on the left ear. Of interest, a recent behavioural study on normal listeners suggested that whereas dichotic CV test results are affected by attention, that dichotic rhyme tests are resistant to the laterality of attention (Shinn et al., 2005). Results from this study may suggest that use of both tests in the clinical setting could help to differentiate attention from auditory “sensory” deficits.

The postulation that interhemispheric transfer utilized for the performance of complex auditory tasks may involve both a sensory modality-specific channel and a higher order cognitive function transfer channel, which are subserved by different anatomic pathways, may – to some extent- explain some of the discrepancies in studies assessing the relationship of the size of the corpus callosum compared to the ear advantage observed in dichotic tasks. It has been proposed that size of the posterior part of the corpus callosum (isthmus and splenium) should have a negative correlation with a right minus left ear performance on dichotic tests, as a measure of laterality, based on the assumption that a bigger CC size would be associated with a greater number and/or greater diameter fibres, which would lead to better interhemispheric transfer (Jäncke and Steinmetz 2003). However, the underlying assumption for this hypothesis (that CC size correlates with a greater number of fibres) only holds true for the small diameter fibres (Aboitiz et al., 1992). The existing studies give thus contradictory results. The reported findings range from

- a negative correlation between the right minus left ear laterality index and the size of the isthmus (Witelson 1987)
- negative correlation of this laterality index on a three-pair dichotic task and the total callosal area as well as two anterior callosum measures (O’Kusky et al, 1988)
- negative correlation of the laterality index on a dichotic CVs test in females and the size of the splenium (Hines et al., 1992)
- no correlation of the left ear score on dichotic CVs (non-forced condition) and the total CC size, but negative correlation between the right ear score (non-forced) (manual identification of left and right ear presentation of CV

syllables) with overall callosal area and two anterior callosum regions (Clarke et al., 1993)

- no correlation at all between midsagittal CC measures and dichotic test results (Kertesz et al., 1987; Jäncke and Steinmetz, 1994).
- A further study on patients with multiple sclerosis (Reinvang et al., 1994) found no significant correlation between the left ear score on dichotic CVs in the non-forced condition and callosal size; however, there was a significant correlation between left ear performance with forced left ear listening and posterior callosal size.

In view of the “dual pathway” CC model, a study assessing this relationship should employ both a forced and non-forced dichotic test paradigm, as well as frontal lobe (attention, working memory etc) measures. Another variable that may need to be taken into account is the size of the brain. Jäncke and Steinmetz (2003) compared right, left and right minus left ear scores on a dichotic CV test versus midsagittal corpus callosum areas as measured by brain MRI in 50 young adult volunteers, who were divided into two groups, those with smaller and larger brain size according to the median brain size. Both groups consisted of an equal number of males and females. They found a moderate positive correlation between the non-dominant ear score and the size of the posterior part of the CC and a negative but non-significant correlation between the laterality (right minus left ear score) and the CC measures in the large brain group. They also found a positive correlation between the non-dominant ear score and the anterior callosum size and a positive correlation between the dominant ear score and the posterior callosum measures in the small brain group. These data may be consistent with these of Ringo et al. (1994) who postulated that

there is a decrease in interhemispheric connectivity with increasing brain size, since an increased brain size would introduce increasing time constraints from transcallosal transfer delay, and increasing brain size during phylogeny would be the underlying cause of brain specialization (Jäncke and Steinmetz 2003). Jäncke and Steinmetz (2003) proposed the CC measures should be normalized to brain measures.

Age-related changes in dichotic listening

Behavioural and electrophysiological responses (P300) to dichotic listening tasks will show marked age effects in that the right ear advantage for verbal stimuli and left ear advantage for no-verbal stimuli will decrease with age in adults (Jerger et al., 1995). Of interest, the right ear advantage in this test in the non-forced condition will progressively decline from the 3rd to the 7th decade of life (Beaton et al., 2000) and, similarly, the improvement seen in the left ear score in the left ear forced attention condition will decline with increasing age.

Pattern tests

It has been proposed that for a sequence of sounds, the right hemisphere determines the pattern of the sequence as a gestalt, but the labelling of the sequence happens in the left (language) hemisphere (Pinheiro and Musiek 1985). Thus, tasks that require labelling of sound sequences depend on transfer of information from the right to the left hemisphere via interhemispheric commissures (Pinheiro and Musiek 1985). After complete commissurotomy, subjects will show abnormal results for both tested ears for orally reported frequency and duration patterns, while scores for a hummed response will remain normal or near normal (Musiek et al., 1980; Musiek et al., 1984).

Localisation tests

The spatial organization of the axons of the interhemispheric pathway may subserve aspects of “temporal transformation” of the interhemispheric interaction. For example, CC axons may run in parallel to their targets for a few millimetres or exchange branches between terminal columns which are several microns apart, thus introducing interhemispheric conduction delays and maximizing simultaneous activation of distant terminal columns, or conversely, temporally dissociated activation of different cortical columns (Innocenti and Bressoud, 2003). This temporal transformation of the auditory input in the interhemispheric pathway may be integral for perceptual binding, figure/background separation (Singer 1995) as well as for sound localization, by facilitating the interhemispheric integration of binaural inputs. Poirier et al (1993) conducted a localization experiment, in which subjects were asked to point to a fixed auditory target presented on a sound perimeter, on four acallosal subjects and matched controls. The acallosal subjects showed deficits throughout the auditory fields, indicating that the corpus callosum is necessary for sound localization in space. In both groups, performance was better for targets in the pericentral than peripheral fields, indicating that the corpus callosum is not as important for auditory as for visual midline fusion, but may subserve audiospatial discrimination processes throughout auditory space. In a subsequent study on cats, Poirier et al (1995) conducted extracellular recordings of the responses of auditory callosal neurons to diotically presented stimuli with variable interaural time delays. They found that all callosal fibres were binaurally driven, with a considerable heterogeneity of responsiveness to binaural stimulation, indicating that the corpus callosum is indeed involved in sound localization. Lessard et al (2002) assessed localization for both

fixed and moving sounds using one or both ears in a group of acallosal subjects and normal controls. Performance of the acallosal subjects was superior to that of the controls in the monaural condition, indicating more efficient use of monaural cues, possibly subserved by increased interaction of subcortical pathways, which include a number of midline cross-overs and the cortex. Acallosal subjects were as accurate as controls in the localization of fixed sound targets, but less efficient than controls in localizing moving targets, possibly because the second condition requires more detailed analysis of the dynamic interaural differences, which may require contribution of additional cortical input. Lessard et al (2002) did not find any deficits of the acallosal subjects in the pericentral field, and proposed that the preserved anterior commissure may have provided an alternative interhemispheric pathway for the midline sound representation. Hausmann et al. (2006) assessed two subjects after callosotomy and a subject with agenesis of the corpus callosum, with a test of sound lateralization with variable interaural time differences. Lateralisation of sound was preserved in all three; however accuracy was reduced compared to normal controls. They proposed that auditory interhemispheric transfer is crucial, if not indispensable, for spatial hearing based on binaural cues, however, the effect of supramodal hemispheric allocation of attention in auditory space may also need to be taken into account.

The concept of interhemispheric relay time (IHRT)

Poffenberger (1912) first proposed that in the visual sensory-motor domain, the difference in reaction times for a task between a contralateral vs. ipsilateral visual stimulated field to responding hand (crossed minus uncrossed difference, CUD)

reflects interhemispheric relay time, since the visual and motor projections are contralateral. In the auditory domain, it is more difficult to conceptualise and assess IHRT, since there are multiple crossings, the first occurring at the brainstem, thus the peripheral end organ has access to both hemispheres. However, the contralateral pathway to the sensory input has a greater number of fibres and may thus be functionally more “significant” than the ipsilateral pathway (Philips and Irvine 1983). This second assumption underlies the use of monaural detection tasks for auditory lateralized stimuli. However, early studies gave conflicting results, with Moscovitz and Smith (1979) reported findings of CUD for lateralized auditory stimuli that were comparable to those for visual stimuli, however others reported the absence of a reliable CUD (e.g., Callan et al., 1974). A further study on a patient who had complete commissurotomy similarly showed no significant CUD for lateralized auditory stimuli, in contrast to a significant CUD for visual stimuli in the same patient (Iacoboni and Zaidel, 1999). The presence of multiple crossings early on in the auditory pathway, in combination with individual subject differences, may explain the failure of monaural detection tasks for auditory lateralized stimuli to estimate CUD and extrapolate for IHRT. Dichotic monitoring tests, i.e. tests with dichotic stimuli in which the subject has to indicate when a target syllable appear to be more reliable indicators for IHRT. Such tests have consistently given a faster reaction time for right than for left ear targets by 25-50 ms for right handers (Jäncke and Steinmetz, 1994; Jäncke, Steinmetz, Volkman 1992). Left handers, as a group, will show faster reaction times for right than for left stimuli (Jäncke, 2002). However, the tasks employed in dichotic monitoring paradigms are quite complex, and may activate a broad neural network, thus these reaction times may to some extent reflect transfer time within the same hemisphere.

Summary and Conclusions

In summary, postnatal development of the interhemispheric pathway may parallel postnatal brain “pruning” and may thus contribute to increasing functional specialization and computational capacity of the brain. Callosal axons may be implicated in temporal transformation of neural transmission, either synchronizing activity of neuronal groups within and across the hemispheres (a synchronization necessary for figure/background segregation, Singer 1995) or desynchronizing neural activity (by introducing activation delay). The density of CC neurons changes across the cortical areas of origin (Chance et al, 2006), while individual callosal axons contribute different numbers of boutons to different layers as well as to different columns within the layers, thus the transmitted action potentials and the overall connecting maps between the two hemispheres may be reweighted in order for input to be transferred to specific cortical sites. In addition, it would appear that there are parallel auditory interhemispheric channels for communication between the two hemispheres, and interhemispheric transfer appears to be sensory driven, as well as context-dependent, strongly modulated by attention (Zaidel and Iacoboni, 2003). However, several questions remain unanswered. One of these, amongst many others, concerns the exact relationship between auditory deficits and patient reported disability with genetically determined abnormalities of the interhemispheric pathway and in different age groups, since the interhemispheric pathway appears to change throughout life. The population with *PAX6* mutations may be a good model to address some of these issues, since a. although rare, *PAX6* mutations accounts for 90% for autosomal dominant cases of congenital aniridia (van Heyningen and Williamson, 2002), so these patients are easy to identify, b. the phenotype includes malformations

of both the anterior commissure and the corpus callosum and c. these patients are reported to be of normal intelligence (Thompson et al., 2004).

2.4. Auditory Processing Disorders

Auditory processing disorders: definitions, controversies and a conceptual framework

In the mid 1950's, Bocca, Calero and Cassinari (1954) made the seminal observations that patients with temporal lobe tumours complained of hearing difficulties, despite the presence of normal hearing thresholds and normal speech recognition in quiet. Bocca and co-workers were able to demonstrate auditory deficits by utilising a test in which the low frequency acoustic features of the speech signal had been removed. Around the same time, Myklebust (1954) proposed that central auditory function ought to be considered and assessed in children with communication disorders. In the UK, the terms "obscure auditory dysfunction" (OAD) (Saunders and Haggard, 1989) and "King-Kopetzky syndrome" (KKS) (Hinchcliffe, 1992; King and Stephens, 1992) were coined in the late 80s to describe the presentation of patient-reported difficulty understanding speech in background noise despite normal hearing thresholds. Patients with OAD/KKS are characterized by deficient performance in speech in noise tests and personality traits, such as a tendency to underestimate their hearing ability (Saunders and Haggard, 1992). Subsequent research indicated that the clinical presentation of OAD/KKS may be underlined by a variety of pathologies at both the peripheral and the central levels of the auditory pathway (e.g., mild cochlear pathology or middle ear dysfunction or medial olivocochlear efferent system dysfunction) and/or psychological problems (Zhao and Stephens, 2000).

Over the last 20-30 years, it has become increasingly recognised that impaired structure and/or function of the brain may have little or no effect on hearing thresholds, but may cause deficits in other aspects of the hearing process. These deficits are collectively referred to as an “auditory processing disorder” (APD). The last few years have seen a dramatic increase in the number of studies exploring the functional organisation of the auditory system, which have helped inform the current conceptual framework(s) of auditory processing in humans (e.g., Kaas and Hackett 1999; Hall, Hart and Johnsrude 2003). However, rather disappointingly, recent progress in auditory neuroscience has not as yet been translated into clinical practice. And whereas APD is being diagnosed by many practitioners in the wider field of Audiology, on both sides of the Atlantic, accurate diagnosis of APD remains a clinical challenge (Jerger and Musiek, 2000; Hind, 2006). This may be due to the lack of application of a systematic battery of diagnostic measures for APD assessment in most clinical settings but a few, as well as to current test limitations, with some patients failing existing central auditory tests for a variety of non-auditory reasons, but also because there is a lack of universally accepted diagnostic criteria and best testing methods for APD (Jerger and Musiek, 2000; Hind, 2006). Unsurprisingly, many professionals within Audiology report that they are not well informed about APD (Hind, 2006). These concerns have led to the organisation of Consensus Conferences, attended by a multidisciplinary audience of professionals involved in the assessment and management of APD from the wider field of Audiology, on both sides of the Atlantic (ASHA, 1996; Jerger and Musiek, 2000; British Society of Audiology (BSA) APD UK 2004; ASHA, 2005). The aim of these conferences was to agree on a definition of APD in order to consider the diagnostic and management approach of this entity.

In the UK, an Auditory Processing Disorder Interest Group was established at the request of the Paediatric Audiology Interest Group (PAIG) of the British Society of Audiology (BSA) in 2003, as a forum on Auditory Processing Disorders (APD) in both children and adults, with the aim to provide guidelines on diagnosis and management of APD (<http://www.thebsa.org.uk/apd/>). This group proposed that APD should be defined as “a hearing disorder due to impaired brain function, that is characterised by poor recognition, discrimination, separation, grouping, localisation or ordering of non speech sounds” (BSA APD UK Steering Group, 2004). In the United States, the most recent technical report which was produced by the American Speech-Language-Hearing Association (ASHA) Working Group on Auditory Processing Disorders (2005) updated previous APD definitions proposed by previous conferences (ASHA, 1996; Jerger and Musiek, 2000). While in 2000 the Consensus panel put forward the term “auditory processing disorders” in order to acknowledge the possible interactions of peripheral abnormalities with deficits due to brain pathology (Jerger and Musiek, 2000), in 2005 the ASHA Consensus panel proposed that the term “central” should precede the term APD, since “most definitions of the disorder focus on the central auditory nervous system”. Thus, (C)APD was defined as “a deficit in neural processing of auditory stimuli that is not due to higher order language, cognitive, or related factors”. According to the ASHA definition, patients with APD may show deficits, which will have both behavioural and electrophysiological correlates, in the following skills (ASHA, 1996; ASHA, 2000):

- Sound localisation/lateralisation
- Auditory pattern recognition

- Auditory discrimination
- Temporal aspects of hearing (masking, ordering, integration, resolution)
- Processing degraded auditory signals
- Processing the auditory signal when embedded in competing acoustic signals

It may be interesting to compare these audiological definitions of APD with the definition proposed by a Neurologist. TD Griffiths (TDG) defines “disorders of central auditory processing” as “disorders in the processing of sound, after the transduction of the sound into neural activity in the cochlea. Such processing involves the characterisation of auditory patterns in frequency or time that are used to identify and localise sound objects”. The term CAPD is restricted to “deficits in the processing of auditory pattern before the patterns acquire labels or schemata” (Griffiths, 2002).

All three proposed definitions for APD or (C)APD may have some inherent limitations, and while they have some commonalities, they are not tautologous. Thus:

- a. All three definitions attribute APD to pathology of the brain, but retain some reservations as to the possible contribution of peripheral hearing deficits (e.g., due to pathology of the auditory nerve) on auditory processing. However, these reservations are not made explicit.
- b. All three definitions propose that APD consists of deficits in specific skills. However, the conceptualisation of the APD related deficits differs. E.g., the BSA definition makes no reference to temporal integration, nor to pattern processing, while the ASHA definition proposes deficits such as “processing degraded auditory signals” which may well be due to deficits in more basic auditory functions, such as localisation, masking, ordering etc. Neither of the

two definitions explains why and how it was decided that an APD should comprise deficits in these specific skills/subprocesses of audition. The definition by TDG may encompass deficits in all processes specified by ASHA and BSA, but sub-processes are not specified.

- c. The BSA definition is explicit in that APD deficits should be demonstrable in the processing of non-speech sounds, while the ASHA definition only states that these deficits “should not be due to... language disorders”. In contrast, the ASHA definition makes clear that APD related deficits should not be due to higher order disorders, while the BSA definition does not contain such a statement. The TDG definition is probably more accurate than both the ASHA and BSA definitions, in that it specifies that APD takes place before semantic processing.
- d. However, none of the three definitions acknowledge the possibility that observed auditory deficits may be due to other top-down effects, such as attention etc.
- e. Finally, neither of the three definitions attempts to define the term “disorder”.

It is useful to consider the entity of APD within the context of a standard classification scheme for other developmental/higher order disorders. The Diagnostic and Statistical Manual of Mental Disorders (DSM) is a standard classification of mental disorders used by professionals from the wider field of mental health in the United States. This manual is constructed and documented by means of a systematic and explicit process and intended to be a tool in order to collect and communicate accurate public health statistics (DSM IV, 1994). The DSM IV proposes the following

operational definition of a “Mental disorder”: “a clinically significant behavioural or psychological syndrome or pattern that occurs in an individual and that is associated with present distress (e.g., a painful symptom) or disability (i.e., impairment in one or more important areas of functioning or with a significantly increased risk of suffering death, pain, disability, or an important loss of freedom... Whatever its original cause, it must currently be considered a manifestation of a behavioural, psychological or biological dysfunction in the individual” (DSM IV). In addition, guidelines suggested for inclusion of a specific diagnosis in the previous edition (DSM III, 1980) were:

- a. at least 50 published articles pertaining to the diagnosis (with at least 50% of these to be empirical)
- b. specified diagnostic criteria, with available assessment to treatment linkages
- c. at least two empirical studies conducted by independent groups showing Kappa coefficients $\geq .70$
- d. the proposed diagnostic category represents a syndrome of frequently co-occurring symptoms and
- e. there are at least two independent studies demonstrating that this diagnostic category is separate and distinct from other diagnoses.

And while exclusion criteria include

- a. less than 20 journal articles over the last 10 years
- b. low coverage (i.e., less than 5% of patients with this specific diagnosis fall within the general diagnosis in at least five empirical studies and
- c. undue diagnostic bias with respect to race or gender.

none of these exclusion guidelines should lead to deletion of the diagnosis, **if the diagnosis is related to pathophysiological change within the nervous system.** In

the light of the above, APD could conceivably be classified as a disorder, in that there are certainly more than 50 articles on the subject over the last decade. (with more than 25 articles over the last 5 years on development of tests and testing batteries). there are specified diagnostic criteria (although these are not unambiguous) and evidence is emerging that it can be clinically differentiated from other conditions (e.g., from ADHD: Chermak et al., 1998; Ptok et al., 2006). Furthermore, there are several lines of evidence indicating that APD is related to pathophysiological changes in the nervous system (Bamiou et al 2001; Griffiths 2002). However, there is a lack of studies assessing reliability issues and whether there is evidence for a syndrome. In view of the above, it would perhaps be more accurate to refer to “disordered auditory processing” rather than to “auditory processing disorder”, and although the term “APD” will be retained for the rest of this manuscript, it will be defined as “disordered auditory processing”.

Aetiology

In terms of aetiology, disordered auditory processing may occur in the presence of (Bamiou et al., 2001; Griffiths 2002) (see table):

- a. Genetic cause. Genetic causes of APD may include genetic syndromes which affect the brain (with structural or functional abnormalities) or genetic syndromes which make the brain more susceptible to damage e.g. in the presence of the Crigler-Najjar Syndrome infants are more prone to develop Bilirubin Encephalopathy. One also needs to consider the genetic basis of the auditory processing deficits which are seen in the presence of other developmental disorders. However, in many instances, it may be difficult to establish that the deficit in neural processing of auditory stimuli is not due to

higher order language, cognitive, or related factors as per the ASHA definition.

- b. Neurological conditions which are known to affect the brain's structure and /or function, such as tumours, cerebrovascular accidents, demyelinating disease. These conditions may affect both children and adults, although the prevalence will differ in various age-ranges
- c. Delayed central nervous system maturation (e.g. after sound deprivation or glue ear) in children, although the effects of this early onset abnormality may persist into adulthood (e.g.,
- d. Other higher-order disorders in both adults and children
- e. Age-related changes of the central auditory system
- f. Finally, there may be an additional category of "positive" disorders of auditory processing, in which there is evidence of abnormal activity in the CANS, e.g. in tinnitus (Griffiths, 2002).

Table 3 Aetiology of APD (modified from Bamiou, Luxon, Musiek 2001)

- **Genetic disorders** (e.g., genetic brain disorders, developmental disorders or genetically inherited susceptibility to factors that may cause APD)
- **Neurological conditions**
 - CNS tumours head trauma
 - CVA heavy metal exposure
 - meningitis adrenoleukodystrophies
 - epilepsy
- **Delayed central nervous system maturation**
 - Glue ear, sound deprivation, idiopathic

- **Other Developmental Disorders**
 - ADD, Dyslexia, Specific Language Impairment, Autism
- **Age related changes**
- **“Positive” disorders of auditory processing**
 - tinnitus, musical hallucinations

Symptoms

It has been proposed that disordered auditory processing may manifest in both children and adults with uncertainty about what the individual hears, difficulties listening in background of competing sounds, difficulties following oral instructions and understanding rapid or degraded speech, despite the presence of normal peripheral hearing (ASHA, 1996; Jerger and Musiek, 2000). However, the listening performance of children with APD, although poorer than in children without APD, may vary widely (Smoski et al, 1992). As a consequence of the primary auditory difficulties, children in particular with APD may have secondary characteristics of language, reading and spelling disorders, as well as inattention and distractibility, while both children and adults may have a higher likelihood of behavioural, emotional, social and other difficulties (American Speech-Language & Hearing Association, 2005). It is self evident the proposed APD- related difficulties are not necessary specific for the auditory modality, and careful evaluation should attempt to differentiate between a true APD and other higher order disorders (Bamiou et al., 2001).

At present, several authors propose that the clinical profiles of patients with APD may be classified on the basis of clinical presentation and test results into different

subcategories (e.g., Katz et al., 1992; Bellis and Ferre, 1999 ; Bellis 2005).

Furthermore, it has been proposed that these subprofiles may be underlined by pathology in specific parts of the auditory brain (Bellis 2005). However, none of these clinical presentation schemes have been validated. In general, there is a lack of systematic information both ascertaining the listening profiles of neurologically normal individuals with a specific diagnosis of APD, but also investigating hearing complaints and related disability in patients with lesions of the auditory brain, which would help evaluate the specificity of these complaints for the auditory modality and possibly assess the link between the underlying pathophysiology and the subjective complaint.

The concept of “disability” and questionnaire studies of APD.

The World Health Organisation Classification of Functioning Disability and Health (ICF) (2001) provides a conceptual framework which may help consider and address the difficulties experienced by the patient with disordered auditory processing.

According to the ICF model, the underlying disease may lead to an impairment of function (audition) which may adversely affect the patient’s activities (e.g., understanding speech in background noise) and thus restrict social participation (e.g., parties, group meetings etc). Functional impairments, i.e. abnormal psychological or physiological function is measurable by standardised psychological or physiological tests. “Activity limitation” defined as “difficulties an individual may have in executing activities” corresponds to the concept of disability, and may depend both on the impairment, as well as on the demand placed on the auditory system. This may be assessed by questionnaires or specific tests (Stephens, 2003). Careful evaluation to identify the difficulties – and the context of the difficulties- experienced by the patient

is therefore of paramount importance in order to instigate audiological rehabilitation which will address the patient's difficulties.

There is a paucity of studies systematically assessing listening characteristics and disability in patients with auditory processing deficits. Smoski, Brunt and Tannahil (1992) used a questionnaire, the Children's Auditory Processing Performance Scale (CHAPS), which was developed to assess parents' and teachers' judgment of children's listening abilities, to assess listening performance in 64 children with a diagnosis of APD based on findings of abnormal test results in at least 2 out of 4 validated central auditory tests. The teacher administered questionnaire identified listening difficulties in a wide context of listening situations (in quiet, in noise, ideal listening condition, with multiple inputs present) as well as problems with auditory memory and attention in the children with APD compared to their normal peers. The authors stated that the children with APD showed a wide inter- and intra-subject variability in listening skills, however, no attempt was made to subprofile different types of presentations. Meister et al (2004) evaluated differences between children with a "suspected" APD (identified as clinical suspicion of APD and failure in non-validated tests, unspecified by the authors) vs. a control group, using a parent-answered questionnaire. The APD group gave significantly poorer scores on the questionnaire than the normal group. A factor analysis identified seven main components that could account for this difference, including speech understanding in demanding situations (speech in competing speech, speech in noise, degraded speech), speech/language production abilities of the child, general behavioural issues (aggression and frustration), difficulties of the children with reactions to (orally given) questions and demands,

reproduction of musical cues, discrimination of speech sounds, and loudness perception.

Neijenhuis, Snik and van den Broek (2003) assessed hearing disability in 24 otherwise neurologically normal adults with a suspected auditory processing disorder, i.e. patients who complained of hearing difficulties and who gave abnormal (high) scores on the Amsterdam Inventory (Kramer et al., 1995), i.e. a validated hearing questionnaire, which assesses difficulties with the detection of sounds, distinction of sounds, intelligibility of speech in noise and in quiet and sound localisation, as part of the validation study for a central auditory test battery. 68% of these adults gave abnormal results (scores below the 90th percentile of the normal control group) in the central auditory test battery. They found that, as a group, the subjects with a suspected auditory processing disorder reported significantly more complaints regarding hearing abilities than normal controls for all five factors assessed by the Amsterdam Inventory, with speech in noise and sound localization as the most frequently reported difficulties. An earlier study was conducted by Blattner et al (1989) on patients with unilateral cerebrovascular lesions of the telencephalic auditory structures. These authors administered a hearing questionnaire in order to assess potential auditory perceptual problems in everyday hearing situations, as part of the validation study for a psychoacoustic pattern discrimination test. They found that about half (49%) of these patients reported auditory perceptual problems in the questionnaire, particularly in situations with simultaneous speakers, while auditory perceptual problems were reported by the vast majority (79%) of those patients who gave abnormal results in the psychoacoustic tests.

Diagnostic approach for APD

A recent issue of the American Journal of Audiology was dedicated to invited reviews the definition and diagnostic issues regarding APD or (C)APD written by Audiological professionals considered to be experts in the field, and exemplifies the controversies surrounding these issues. Cacace and McFarland (2005) argued that auditory testing in isolation may not be sufficient to make a specific CAPD diagnosis, and that efforts should be made to document that the observed deficits are specific to the auditory modality. Conversely, Katz & Tillery (2005) proposed that intra- and inter-test comparisons and a multidisciplinary team assessment approach help to diagnose reliably APD and differentiate from other higher order disorders such as ADHD. Similarly, Musiek, Bellis and Chermak (2005) highlighted recent scientific findings that demonstrate that the auditory brain is non-modular and interacts with several other brain regions and sensory as well as higher order modalities. They recommended use of auditory processing tests that have been validated on individuals with well-circumscribed lesions in combination with other types of multidisciplinary assessment in order to make a valid diagnosis and propose treatment means for (C)APD. Rosen (2005) argued that a comprehensive definition for CAPD should allude to supramodal causes of auditory deficits, in order that these be excluded, and that diagnosis must be based on the demonstration of processing deficits for non-speech sounds resulting from impaired brain function. In the UK, similarly, an issue of Audiological Medicine was dedicated to the diagnosis and management of APD. Moore (2006) argued in this issue that APD should be demonstrable in the processing non-speech sounds, and that diagnostic tests should be validated by population

studies, while he acknowledged the effects of higher order factors as well as peripheral hearing aspects on the performance in APD tasks.

Requirements for a test battery

In view of current controversies surrounding diagnosis of APD and of the fact that clinical symptoms of APD are not necessarily specific for the auditory modality, while auditory processing assessment may be influenced by the presence of deficits in other higher order disorders (which include attention deficit hyperactivity disorder (ADHD), Language impairment, Reading disability, Learning disability, Pervasive Developmental Disorder, and Intellectual functioning, Jerger and Musiek, 2000), both the ASHA Technical Report (2005) and, more recently, the British Society of Audiology (BSA) APD UK Steering Group (SG) (personal communication, 2007) have proposed that diagnosis of APD requires a test battery approach. The test battery should include tests which aim to assess different auditory processes, and in addition, “the patient’s language and meta-language skills, cognition, attention and working memory ought to be assessed by an appropriate practitioner – the need for these assessments can not be overemphasized.” (APD UK SG document, personal communication, 2007). ASHA (2005) proposes that electroacoustic tests, such as otoacoustic emissions and acoustic reflexes, as well as electrophysiological tests, which involve recordings of electrical potentials that reflect activation of the central auditory nervous system by various acoustic events, are also included in the test battery. Electrophysiological responses may include auditory brain stem evoked responses and middle latency response, which are key measures for auditory structures in the brain stem and in subcortical to cortical levels respectively; and late

potentials, which may or may not be affected by attention, such as the P300 or Mismatch Negativity (Musiek and Lee, 1999).

Behavioural central auditory tests.

The choice of tests should be guided by several considerations, which include the following criteria (ASHA, 1996; Jerger & Musiek, 2000; ASHA, 2005).

Fundamental test requirements:

1. The test purports to assess an aspect of auditory processing that takes place in the auditory brain according to current scientific evidence.
2. The test stimuli are high quality acoustic stimuli that preserve their features with the recommended test administration.
3. The test method follows sound psychoacoustic or electrophysiological principles.
- 4.a. Appropriate test validation has taken place and the evidence that substantiated validation is available. This could be on patients with known neurological lesions of the central auditory nervous system, population studies, or both, as each approach may have advantages and limitations.
- 4.b. There is reported good sensitivity and specificity and good reliability evidenced through reported test-retest reproducibility.
5. Any test under consideration is still in its original form i.e. is the exact test which underwent the rigorous assessment, and not a hybrid
6. There are normative data on a sufficiently large sample with well-documented demographic data such as age, language, education, socio-economic status, gender.
7. There are clear instructions on how to train the patient and how to conduct and score the test, as well as on the test equipment set up.

8. Scientific papers published in peer-reviewed journals have addressed all of the above issues for any test. (However this criterion does not necessarily guarantee that an existing test is indeed of high quality and critical evaluation of the existing information is recommended).

In addition to the above, the following factors need to be considered:

- Is the test appropriate for the age-range of the target population?
- Do age appropriate norms exist?
- What are the floor and ceiling effects of the test? Can these be affected by specific patient skills (e.g., musical skills, language skills etc)?
- Is the test affected (and if so to what extent) by other top-down processes such as attention, memory, IQ, learning, decision processes and motivation, or linguistic factors?
- Is the response mode for a given test appropriate for each specific patient?
 - Altering the response mode could be more user-friendly but new norms would need to be established
- What is the test duration and how this is likely to affect the test outcome?
- Can the scoring of the test can be affected by subjective tester bias and if so, to what extent?

Behavioural central auditory test categories

Behavioural tests available for the evaluation of central auditory processing are broadly divided into four main categories (ASHA 1996; ASHA 2005; Baran and Musiek 1999, Bamiou 2006):

1. ***Auditory discrimination tasks.*** These assess the individual's ability to discriminate between sounds that differ in frequency, intensity and temporal parameters. Children with specific language impairment may have frequency discrimination deficits, but not intensity discrimination deficits, compared to normal controls (Hill et al., 2005; Mengler et al., 2005). Subjects with pathology of the auditory cortex show reduced intensity and frequency discrimination scores in the ear contralateral to the lesion (Scherg, von Kramon 1987) while bilateral deficits for intensity discrimination have been reported in a subject with a left auditory cortex lesion (Baran et al., 2004).

2. ***Temporal tasks.*** These assess the individual's ability to analyse changes of the acoustic signal over time, i.e., temporal processing. Temporal processing can be broken down into 4 major sub-processes: ordering or sequencing, resolution or discrimination, integration or summation and masking.

Pattern tests are an example of tests assessing *ordering /sequencing*, and have been used to assess pathology of the CANS since the 60s and 70s (Baran and Musiek 1999). The frequency pattern test (Musiek, Pinheiro, 1987) and the duration pattern test (Musiek, Baran, Pinheiro, 1990) consist of 3 tone burst sequences, which differ in terms of frequency or duration, and which are presented to the test subject, who has to "label" the sequence. It has been proposed that the pattern of the sequence is determined by the right hemisphere as a gestalt, while the labelling of the sequence takes place in the left (language) hemisphere (Pinheiro and Musiek 1985). These tests are highly sensitive to cortical lesions (with bilateral deficits) and moderately

sensitive to brainstem lesions (Musiek, Baran, Pinheiro, 1993), while they are relatively resistant to the presence of sensorineural hearing loss (Musiek and Pinheiro 1987).

Temporal resolution or discrimination is the ability of the auditory system to respond to rapid changes in the envelope of a sound stimulus over time (Plack & Viemeister, 1993) which underlies the ability of the listener to distinguish between two (brief) successive auditory signals. Human speech is characterised by rapid changes in sound frequency, periodic intensity changes, which are similar to sinusoidal amplitude modulation, and by stops and starts or gaps, and all these features are important for speech perception (Frisina, 2001). *Frequency and amplitude modulation detection tasks* are thus included in most recently developed APD test batteries (e.g., Griffiths et al.; 2001; Moore, 2006), but systematic studies of frequency and amplitude modulation detection in patients with CANS lesions are lacking.. The *gap detection* assesses the shortest gap within a sound that the listener can detect. The leading and trailing markers of the gap may share the same acoustic features (e.g., spectral content, laterality), and this is termed as “within channel design”, or the leading and trailing markers may differ in ≥ 1 acoustic dimension, and this is termed as “between channel design”. Between channel gap detection thresholds show larger intersubject variability than within channel gap detection thresholds (Philips, 1999). The Gaps-In-Noise test (GIN) is an example of within channel gap detection task, which was recently developed to assess clinical populations with central auditory disorders (Musiek et al., 2005). This test was shown to be moderately sensitive to CANS lesions (Musiek et al., 2005).

Temporal integration or summation is the term used to describe the function which relates the detection threshold of a signal to its duration (Stollman et al., 2003).

Temporal summation may, however, be significantly reduced in cases of hearing loss, although it is not entirely clear why (Hall, 2003). The administration of this test can be similar to an audiogram (e.g., Stollman et al., 2003) or it can be given as a forced choice psychoacoustics task (e.g., Moore, 2006) and some of the newly developed test batteries for APD assessment contain such a test (Moore, 2006).

Masking. *Forward masking* refers to the task in which the masker precedes the target signal in time, whereas in *backward masking* the target signal is presented before the masker, and is regarded as a measure of the ability of the auditory system to follow rapid changes in level (Plomp 1964). Individuals with specific language impairment and dyslexia have abnormally raised backward and forward masking, with more pronounced deficits in backward vs. forward masking, while they perform nearly as well as controls on simultaneous masking (Hartley and Moore 2002). It has been proposed that backward masking, in particular, is a measure of “processing efficiency”, however, it is not clear whether this processing inefficiency specific to the auditory system or cross-modal (Hartley and Moore 2002). In addition, there is a wide inter- and intra-subject variability in results, and attention as well as practice effects may account for this (Neijenhuis et al, 2002; Hartley and Moore, 2002).

3. ***Monaural low redundancy speech tests*** assess recognition of speech material that is degraded in terms of frequency content, timing aspects or intensity. Bocca, Calero and Cassinari (1954) first used a *low pass filtered speech test*, in order to assess hearing difficulties in patients with CANS lesions. *Speech in noise* tests may similarly

reduce the redundancy in the speech signal, and *speech in multitalker babble* (i.e., a background of many people talking, like a cafeteria) have now become quite popular, as competing speech or babble is more representative of a real acoustic environment than noise because of its fluctuation of overall power (Dirks et al., 1982). These tests give contralateral deficits for auditory cortical lesions, while there are no consistent results for brainstem lesions, and the tests is in general moderately sensitive to lesions of the CANS (Olsen et al., 1975; Musiek, Baran, Pinheiro 1994), while performance in these tests may be affected by the language related factors (e.g., Marriage et al., 2001). In addition, the presence of cochlear hearing loss may also compromise results (Olsen et al., 1975).

4. ***Dichotic tests (speech and non speech)***, in which the two ears are presented with a different sound to each ear, with these sounds aligned in time. The dichotic listening technique was invented by Broadbent (1954), and subsequently employed by Kimura (1961) in the study of both normal subjects and patients with brain lesions. The most widely used speech tests with lesser linguistic tests in this category are:

- a. the *dichotic digits test*, which is composed of naturally spoken digits from 1 to 9 (Musiek, 1983). This test has a sensitivity of 75% and specificity of 90% in separating central auditory versus cochlear lesions versus normal hearing (Musiek et al., 1991).
- b. the *dichotic rhyme test*, which consists of two words with similar spectral envelopes which are temporally well aligned and presented dichotically in the two ears, with only one word identified by the

listener most of the time, possibly due to fusion of the words, although two are presented (Wexler and Halwes, 1983).

- c. *Dichotic CVs test* (Noffsinger, Martinez & Wilson 1994), which is composed of six consonant-vowel (CV) syllables formed by a stop plosive (b, p, t, d, g, k) and the vowel /a/.
- d. The *staggered spondaic words test* (Katz, 1962), in which pairs of spondee words are presented to the patient in an overlapping, but staggered fashion. Thus, the first half of the first item is presented to one ear and the second half of the second item is presented to the other ear in non-competing fashion, while the second half of the first item and the first part of the second item will overlap in time.
- e. There are also *dichotic tests with competing sentences* (e.g., Willeford 1977), however, these represent a linguistically loaded task and may thus not be appropriate for central auditory evaluation (Musiek et al, 1994).
- f. *Non-speech dichotic tests* are not routinely used in the clinic, although they have been used in research (see chapter on the interhemispheric pathway for details).

In general, dichotic speech tests show a right ear advantage in normal subjects (see chapter on the interhemispheric pathway for discussion), with a left ear deficit for right auditory cortical lesions, bilateral deficits for left auditory cortical lesions, and abnormal results with non-consistent laterality for brainstem lesions (Baran and Musiek 1999; Musiek, Baran, Pinheiro 1994). These tests also show a left ear deficit

and/or increased right ear advantage in lesions of the interhemispheric pathway (see chapter on the interhemispheric pathway).

5. ***Binaural interaction tests*** assess the listener's ability to "synthesize" intensity, time, or spectral differences of otherwise identical stimuli presented simultaneously at the two ears in order to combine complementary input distributed between the ears. In general, the neural mechanisms subserving binaural processing are probably best assessed by means of tests that employ concurrent delivery of separate and different acoustic stimuli to the two ears. On the other hand, functional performance can be assessed by means of tests which employ presentation of the stimulus in the free field, thus allowing for use of cues provided by the sound transformations produced by the head and outer ear (Bamiou, 2006). The most widely used test in this category is the *masking level difference (MLD) phenomenon* (Hirsch, 1948). For the *MLD*, a signal (usually a 500 Hz tone) and a noise masker (usually narrow band) are presented binaurally. The *MLD* refers to the difference in dB between signal detection thresholds for two binaural masking paradigms, which differ in phase attributes (i.e., signal or masker in phase vs. signal or masker out of phase). Other tests in this category include the *Rapidly Alternating Speech Perception (RASP) Test* (e.g., Willeford 1977), which consists of segmented, continuous speech information, which is presented alternately and sequentially between the two ears and the binaural fusion test (BFT) (e.g., Willeford 1977), which involves presentation of different segments of band pass filtered speech to the two ears with a low-band pass filtered speech stimulus presented to one ear and a high-band pass filtered speech stimulus to the other ear. Binaural interaction may also be assessed using the recently developed

Listening in Spatialized Noise – Continuous Discourse Test (LISN-CD; Cameron, Dillon, and Newall 2006) which requires special software for computerized administration under headphones and which produces a virtual three-dimensional auditory environment. *Binaural interaction tests* are thought to be sensitive to brainstem pathology (see Bamiou 2006 for review). The *MLD* is the most sensitive and specific test in this category for brainstem lesions, while the other tests may also be affected by cortical pathology as well as top down processes (Bamiou et al., 2006). In addition, the presence of peripheral hearing loss may affect all these test results, which will need to be interpreted with caution. *Localization/lateralization tasks* (e.g., Cranford et al., 1990; Aharonson et al., 1998) have not as yet transferred into clinical practice, despite the fact that these may provide a measure of auditory performance in response to precisely controlled acoustic stimuli and may allow the clinician to make inferences for processing at different levels of the auditory system.

Main test batteries (clinical and experimental) for English speaking populations

As previously stated, despite the fact that most professionals recognise the need to assess for APD by means of a test battery, there is no test battery that is universally accepted. The previous Consensus Conference on the Diagnosis of Auditory Processing Disorders in School-Aged Children, which was organised by ASHA (Jerger and Musiek, 2000), proposed a minimal clinical test battery which incorporates a range of baseline(widely available) audiological procedures with central auditory tests that are commercially available (see table 4).

Table 4. Minimal clinical test battery proposed by ASHA (Jerger and Musiek, 2000)

Behavioural Measures	Electroacoustic and Electrophysiological Measures
Pure-tone audiometry	Immittance audiometry
Word recognition in quiet	Otoacoustic emissions
Dichotic test	Auditory Brainstem evoked Responses
Duration pattern sequence test	
Temporal gap detection	

In addition, there are some test batteries which are either predominantly aimed at research (e.g. the Newcastle Auditory Battery (NAB) Griffiths et al., 2001, see table 5) or currently in development, but not as yet available for clinical practice (e.g., CAPE testing battery (IHR, UK) Moore, 2006, see table 6).

Table 5. The Newcastle Auditory Battery (NAB) (Griffiths et al., 2001)

Aims	Methods	Tests
to define dissociated deficits in certain auditory functions.	two-alternative-forced-choice (2AFC) psychophysics with full psychometric function	Temporal tests: detection of frequency- and amplitude-modulated sound, gap detection, complex pitch task
to allow inference about the existence of discrete	carried out binaurally over headphones at 60 dB	Spatial tests: phase and amplitude difference

psychophysical mechanisms	Sensation Level Norms on 30 naive normal subjects	limens for detection of the lateralisation of a centred 500-Hz tone toward the right or left, dynamic lateralisation etc
to allows inference about the likely neural substrate for the perceptual process	Requires Matlab	Potential to tailor test for reported deficit

Table 6. The CAPE test battery (Moore, 2006)

Aims	Methods	Tests
<p>- To produce measures of simple and composite auditory processing abilities</p> <p>- To enable dissociations between auditory and other related skills.</p> <p>- to identified a number of sensitive and specific tests and to normalize those tests on a mainstream population in order to</p>	<p>Large normative study</p> <p>incl:</p> <ul style="list-style-type: none"> - peripheral hearing tests - speech in noise and in quiet - performance IQ - language measures - memory measures - attention measures 	<p>14 different measures of auditory processing</p>

develop an objective diagnostic platform for APD.		
---	--	--

2.5 Imaging the Central Auditory Nervous System

Anatomic magnetic resonance imaging (MRI) is currently the mainstream diagnostic tool of choice for the evaluation of suspected pathologies of the brain (Masdeu et al, 2006), while functional imaging studies, such as functional magnetic resonance imaging and positron emission tomography have in recent years been increasingly applied in the investigation of the central auditory nervous system (Johnsrude, Giraud, Frackowiak 2002; Hall et al... 2003).

MRI has a higher sensitivity than the other most widely available neuroimaging technique, i.e. non-contrast computed tomography (CT), for the demonstration of pathological brain tissue such as infarcted or ischemic areas and acute and chronic intracerebral haemorrhage (Masdeu et al, 2006). Magnetic Resonance Imaging exploits the phenomenon of “nuclear magnetic resonance” (NMR) (Cohen, 1996). Atomic nuclei which contain an odd number of nucleons (such as hydrogen nuclei, which contain 1 proton) behave like magnetic dipoles. Such nuclei will align in the presence of an external magnetic field with a “resonant frequency”, which will correspond to strength of the magnetic field. The external field strength is typically 1.5 Tesla (T), (1 Tesla = 10000 Gauss, while the Earth’s magnetic field = 0.5 Gauss). An oscillating electromagnetic radio frequency (RF) pulse is used to rotate some tissue nuclei out of the plane of the fixed magnetic field. When the pulse ceases, the RF energy emitted as the nuclei return to equilibrium is detected as an induced voltage in a receiver RF coil.

The generation of images depends on the creation of tissue-specific contrasts in the

NMR signal and can be achieved by taking advantage of the different NMR properties of different tissues. The NMR signal is proportional to the density of nuclei (proton density) in each tissue, while tissue magnetic characteristics determine how rapidly the NMR signal decays. The signal decay depends on:

- a. the longitudinal relaxation time, or T1. T1 is time needed for the tissue to be magnetized after being placed in the magnetic field, i.e. for the nuclei to realign with the fixed external field. T1 time reflects the relationship between the frequency of these molecular motions and the resonant frequency of the scanner. Water molecules are small and move too rapidly for T1 relaxation, while large proteins move too slowly, and both have natural frequencies significantly different from that of the scanner.
- b. the transverse relaxation time, or T2, i.e. the time needed to develop phase differences in spinning protons because of interactions among nuclei with different frequencies. T2 depends on the presence of static fields in the tissue/substance, due to protons or larger molecules, which are characterized by a slow fluctuation and which produce local areas of increased or decreased magnetic fields.

An MR pulsing sequence involves the acquisition of multiple spin echo signals. A spin echo pulsing sequence will start with a 90° RF pulse which will change the existing longitudinal magnetization into the transverse plane, and will thus induce an oscillating MR signal in the receiver coil. The magnitude of the transverse magnetization after the 90° pulse is equal to the magnitude of the longitudinal magnetization which recovers during the interval between 90° pulses, with this interval called the "repetition time" (TR) sequence parameter.

MRI may depict lesions in the brain stem or cerebellum, lacunar infarcts, vessel occlusion and brain oedema and may also provide information about tissue viability in stroke (Masdeu et al, 2006). However, there are certain limitations for this technique, in that the biological properties of the tissue imaged, the scanner characteristics and the imaging sequence used may put some constraints in the spatial resolution of MRI, which may be further compromised for the sake of speed of image acquisition (Cohen 1996). An additional limitation of MRI evaluation of the extent of the brain lesion in stroke, in particular, is that early conducted MRI may fail to differentiate between reversible and irreversible ischemic damage (Kelley and Gonzalez-Tolledo, 2005). In general, in MRI, the strongest signal is detected from tissues/ substances with the highest proton densities (high water content), shortest T1 times (rapid recovery) and longest T2 times (slowest decay). The high signal from short T1 substances, such as liquid cholesterol, fat, subacute haemorrhage or and gadolinium enhanced brain tumour is enhanced on short TR images. The high signal from long T2 substances such as mucus, late subacute haemorrhage and CSF is enhanced on long TR spin echo images. The weakest MR signals come from tissues with low proton density, long T1 values (slow recovery), short T2 values (rapid decay), and rapidly flowing blood. Fluid-attenuated inversion recovery (FLAIR) is a heavily T2-weighted image in which the cerebral spinal fluid (CSF) is bright and easily detectable (as the protein content of the serum shortens the T1 of the CSF), thus FLAIR is an excellent technique for diagnosing cerebral ischemic infarcts and acute subarachnoid haemorrhage in particular (Kelley and Gonzalez-Tolledo, 2005).

Functional neuroimaging helps address the specific question “which brain areas subserve performance of a specific task”. The most frequently used functional neuroimaging techniques for the assessment of the CANS are positron emission tomography (PET) and functional magnetic resonance imaging (fMRI). Imaging studies conducted with PET and fMRI are “activation studies”, in that they provide a measure for regional changes in brain activity associated with the performance of a specific task in the awake subject (Ruytjens et al., 2006).

Positron emission tomography (PET) is a functional imaging technique, which has been applied in the study of cerebral haemodynamic changes associated with auditory stimulation for more than 15 years (Johnsrude, Giraud, Frackowiak 2002). PET imaging permits a direct measurement of brain activation. PET measures regional cerebral blood flow changes in response to stimulation by measuring the uptake of a radioactive tracer administered to the subject intravenously, i.e. brain perfusion. After stimulation, the blood flow will increase in the activated brain regions, in order to respond to the higher glucose demand. PET is based on coincidence detection of the gamma radiation which results from extinction of the positrons emitted by the radioactive tracer that was injected into the subject. This radioactive tracer will emit positrons, when injected in the subject, which will be annihilated after an encounter with an electron in the tissue and will thus convert into energy by emission of two photons. If two detectors of a known position, which are opposite one another, detect a photon (i.e., “coincidence detection”), the line on which the annihilation took place, i.e., “the line of response” can be determined, and this will allow mapping of the radioactivity spatial distribution (Ruytjens et al., 2006). This technique has both advantages and limitations. Limitations include:

- a. Limited spatial resolution (in the range of 4-5 mm) (Ruytjens et al., 2006).
- b. The technique is both invasive and utilizes a radioactive substance.

However, PET has some unique advantages for the study of the auditory system:

- a. It helps obtain imaging data from areas which can be difficult to assess, such as the inferior frontal and the anterior temporal areas (Johnsrude, Giraud, Frackowiak 2002).
- b. It can be used even in the presence of various implants in the test subjects (such as pacemakers, cochlear implants etc)
- c. It is silent and, in addition, it allows for close interaction with the test subject during scanning, in contrast to the fMRI (Ruytjens et al., 2006).

Functional magnetic resonance imaging (fMRI) is a novel, non-invasive imaging technique of the *in vivo* neuronal activation of the brain. This technique was first described just over 10 years ago, but it has already helped enhance our knowledge about the functional neuroanatomy of the human brain (di Salle et al., 2003). The most commonly used technique is the blood oxygenation level—dependent (BOLD) contrast fMRI, which uses blood as a contrast medium. This technique measures the small changes of the magnetic field which are a result of the neuronal activation related fluctuations of blood flow (Zur et al., 2004). The fMRI evaluation of the central auditory nervous system relies on the use of different types of sound for activation of the auditory structures and use of different protocols to eliminate confounding scanner noises effect.

The main advantages of fMRI, compared to the other functional neuroimaging methods, are (di Salle et al., 2003):

- a. A spatial resolution in the range of the fractions of millimetres
- b. Higher temporal resolution (in the range of 100 ms or less) than other functional neuron-imaging techniques such as positron emission tomography (PET) or single photon emission computed tomography (SPECT)
- c. A relative ease in studying single individuals with fMRI compared to PET or SPECT. This advantage of fMRI over SPECT and PET is crucial when studying the auditory system, as various structures of the CANS show significant inter-subject variability (Campain and Minckler1976), and averaging anatomical data across subjects may lead to loss of important information

However, fMRI also has some significant disadvantages:

- a. It does not measure neuronal activation directly, but as a correlate of the hemodynamic effect associated with activation. Activation in a brain area during a specific task may reflect activity in response to inputs from local neurons, but, in principle, it may also occur due to activity in response to input from other subcortical or cortical areas.
- b. It cannot be used to assess rapid brain activity changes occurring over a timescale of less than a second.
- c. These studies only represent a means to verify preformed models of auditory signal encoding (di Salle et al, 2003)

d. In addition, auditory fMRI has some specific to the auditory system difficulties. These are due to the functional parcellation of sound processing into a rich network of subcortical structures which are both tiny in size and interacting with each other, thus placing a greater demand for spatial resolution. Brainstem motion caused by basilar artery pulsation. Interaction of the sound of the auditory experiment with the fMRI noise.

2.6. Human lesion studies and how these may contribute to the study of Auditory Processing Disorders

Currently, there is a significant and expressed amount of interest, both from clinicians and researchers, on what exactly constitutes normal as well as disordered auditory processing. In recent years, fMRI and PET studies have been applied to the study of brain activation in response to sound and to make inferences about patterns of brain activation that are associated with processing specific sound characteristics. However, such techniques have inherent limitations, in that, while spatially sensitive, they show poor temporal resolution. Thus, this research approach may only provide a broad description of the structure vs. function relationship in the auditory system, by averaging neuroimaging data in groups of subjects, while it does not help explain individual differences which may be observed in the activation patterns (Hall et al., 2003). In this respect, lesion studies, i.e. studies of patients with defined anatomical lesions, may be complementary to functional imaging studies in normal populations. Structural MRI may complement pathological macro- and micro-anatomical techniques by enabling us to study in vivo the macroscopic appearance of the human auditory system and the relationship of brain structure to behavioural tests of central auditory processing as well as to the patient reported symptoms after a lesion. Lesion studies may therefore help define brain regions that are *necessary* to support particular functions. Such studies have been underemployed in the investigation of the human central auditory nervous system. This may be due to the relative rarity of lesions such as cerebrovascular accidents which selectively involve distinct auditory structures, to the lack of detailed pathological and radiological correlation, and the practical issues (e.g., time constraints, lack of readily available tools) surrounding the assessment of auditory processing in the clinical setting. However, a systematic study of patients

with particular anatomical lesions may provide important information about the function of the central auditory nervous system. Acquired lesions, e.g., lesions after cerebrovascular accidents, may be studied along congenital lesions, resulting from specific genetic mutations. The first group of studies may have the benefit that patients may be studied early on after the onset of the lesion, thus brain plasticity need not play a significant role as a potential confounding factor. However, the genetic studies may help address some genotype to phenotype aspects of auditory processing, and the correlation between a well defined pathophysiology of the CANS to auditory deficit and disability. In addition, they may offer insight into how the auditory processing deficits and the related disability may change from childhood to adulthood. Information from both genetic and acquired CANS studies may help translate findings from basic scientific studies onto individual clinical cases and enhance our understanding of the function of the central auditory nervous system in individual cases and about what constitutes disordered auditory processing in a clinical context.

3. AIMS

This thesis proposes to investigate structure versus function in the central auditory nervous system by using the lesion study approach and by utilising a clinical test battery of validated tests for the assessment of auditory processing as well as self- or parent report measures. The central auditory test results will be correlated with the macroscopical appearance of the CANS on the brain MRI and with patient reported hearing difficulties. The two major CANS regions of interest for this study were the insula and the interhemispheric pathway, comprised of the corpus callosum and the anterior commissure. Thus, this thesis aims to assess

- a. structure vs. function in both acquired and congenital lesions of the brain
- b. auditory processing deficits vs. patient reported disability

The thesis consists of 4 major studies:

Study 1.

This study aims to assess central auditory function in a series of patients with ischemic lesions of the insula and of adjacent cortical and subcortical areas, with and without involvement of other auditory structures, by means of a validated central auditory test battery in order to identify specific auditory functions that might be subserved by this brain region.

Study 2

This study aims to evaluate the self-reported hearing disability of patients with documented lesions of the central auditory pathway secondary to stroke, by means of a validated, self-report questionnaire and to assess whether the patient reported disability correlates with the central auditory deficits as measured by a validated central auditory test battery.

Study 3.

The study aims to assess central auditory function in patients with abnormalities of the interhemispheric pathway due to a *PAX6* mutation, by means of a central auditory test battery, in order to characterize the genotype-phenotype relationship and to gain insight into the functional significance of the abnormalities in the auditory interhemispheric pathway.

Study 4.

The study aims to a. assess central auditory interhemispheric function in children with *PAX6* mutations, b. to assess for the presence of abnormalities on magnetic resonance imaging (MRI) of the brain in these children, c. to assess for parent-reported hearing difficulties in these children and d. to investigate the relationship between a, b and c.

4. METHODS

STUDY DESIGN

This was a cross-sectional study of central auditory function in patients with confirmed lesions of the central auditory pathway. The central auditory pathway was defined as consisting of the following structures and their connections (Musiek and Oxholm, 2000).

- Brainstem & thalamus: cochlear nucleus, superior olivary complex, lateral lemniscus, inferior colliculus, medial geniculate body.
- Subcortical: internal capsule.
- Cortex: Heschl's gyrus (transverse gyrus), planum temporale, planum polare, supramarginal gyrus, angular gyrus, inferior parietal lobe, inferior frontal lobe, insula.

Interhemispheric connections: corpus callosum (posterior part), anterior commissure.

There were two major groups of studies:

A. A study of adult patients with a history of ischemic or haemorrhagic cerebral stroke affecting the central auditory pathway identified on the basis of their brain Magnetic Resonance Imaging (MRI) (Studies 1 &2).

B. A study of patients with a congenital abnormality of the interhemispheric pathway due to a *PAX6* mutation (both adult and children) (Studies 3 &4).

A. The first group of studies evaluated

Study 1. Central auditory function in the presence of unilateral stroke lesions of the insula +/- adjacent areas

Study 2. The self-reported hearing disability of patients with documented unilateral lesions of the central auditory pathway secondary to stroke.

B. The second group of studies evaluated

Study 3. Central auditory function, and auditory interhemispheric transfer in particular, in adult patients with a known *PAX6* mutation

Study 4. Auditory interhemispheric transfer, brain MRI findings, parent-reported hearing difficulties and their relationship in children with *PAX6* mutations

SUBJECTS

STUDIES 1 & 2

Consecutive patients with a history of unilateral ischemic or haemorrhagic cerebral stroke affecting the central auditory pathway (in the cortex, subcortex and brainstem), who had been admitted to the Acute Stroke and Brain Injury Unit or seen in the One Stop Stroke Clinic at the National Hospital for Neurology and Neurosurgery between September 2002- September 2004, and were identified on the basis of their brain MRIs, were invited to participate in the study. Of these, hypertension..blod disorders

Inclusion criteria

- a. Presence of an acute unilateral stroke lesion of the central auditory pathway (see definition of the central auditory pathway below), with or without involvement of adjacent areas of the brain (for study 1, the lesion must have included the insula), and
- b. an audiometric threshold at 1 kHz better than 40 dB HL (to enable use of the central auditory tests which are administered at 50 dB sensation level referenced to the threshold at 1 kHz).

Exclusion criteria

A clinical diagnosis of:

- a. complete aphasia
- b. dementia
- c. psychiatric disorders

Controls & matching to the subjects

We recruited an equal number of normal control subjects from the hospital staff and from spouses/partners of patients. Each case was matched to a control for gender, handedness, left and right average audiometric thresholds at 0.5, 1 and 2 kHz, and 4 and 8 kHz (+/- 10 dB) as well as age group (group 1 age 20-39 years, group 2 age 40-59 years, group 3 age above 60 years). Controls were not matched to subjects for IQ, as premorbid IQ data were not available for the subjects.

STUDIES 3& 4

We recruited adult case subjects who attended Moorfields Eye Hospital for their visual difficulties (study 3) and children case subjects (4 males, 6 females) who attended the Ophthalmology clinic at Great Ormond Street Hospital for their visual difficulties.

Inclusion criteria

- a. Aniridia diagnosed by an ophthalmologist (Professor Anthony Moore).
- b. Family history of congenital aniridia with a pattern indicating autosomal dominant inheritance or known *PAX6* mutation in the family.
- c. Age ≥ 7 years and older.
- d. Normal hearing thresholds on the pure tone audiogram across 0.5 to 8 KHz.
- e. Past (adults) or present history (children) of mainstream education

Exclusion criteria

The presence of sensorineural hearing loss, i.e., audiometric thresholds across 0.5 – 8 kHz exceeding the age-adjusted mean threshold+2 SD for the UK population (Davis 1995).

Controls & matching to the subjects

We also recruited an equal number of normal controls with normal hearing thresholds from all grades of hospital staff and their families. Controls were matched to the cases for age, sex, and handedness.

GENERAL PROTOCOL

All subjects underwent a protocol which included:

- A. Standard audiological tests (pure tone audiometry, tympanometry and transient evoked otoacoustic emissions)
- B. Central auditory tests (dichotic speech tests, pattern tests, gaps-in-noise test)
- C. A questionnaire, the “Amsterdam Inventory for Disability” by Kramer et al (1995) (study two) (Appendix A) and a specifically devised structured interview of the parent (study 4) (Appendix B)
- D. Magnetic Resonance Imaging (MRI) studies of the brain

No top down testing was carried out, as premorbid data were not available.

ETHICS APPROVAL

Studies 1, 2 and 3 were approved by the Ethics Committee of the National Hospital for Neurology and Neurosurgery (Ethics 02/N054 for studies 1&2 and 03/N052 for

study 3). Written informed consent was obtained from both subjects and controls.

Study 4 was approved by the Joint Ethics Committee of Great Ormond Street Hospital and Institute of Child Health (Ethics 04/Q0508/49). Written informed consent was obtained from both each tested child and one of his/her parents.

PROCEDURES

A. STANDARD AUDIOLOGICAL TEST PROCEDURES

Pure-tone audiometry

Pure-tone audiometry was carried out in each ear using a GSI 61 audiometer with TDH-49 earphones in a sound-treated room, following the procedure recommended by the British Society of Audiology (BSA 1981). The audiometer was calibrated according to the British Standards associated with the calibration and performance of audiometers (BS EN 60645-1).

Tympanometry

Tympanometry was obtained in both ears with a continuous probe signal tone of 226 Hz at 85 dB SPL using a GSI-33 Middle Ear Analyser. Tympanograms were considered normal if middle ear pressure was > -150 daPa for children and > -50 daPa for adults and compliance was > 0.3 ml.

Transient evoked otoacoustic emissions (TEOAEs) was carried out bilaterally using the ILO88/92 Otodynamic Analyser, with a standard default set-up (Kemp et al., 1990). The presence of normal TEOAEs (across 500 to 4000 Hz) was determined by overall response amplitude signal-to-noise ratio of at least 6 dB and waveform reproducibility of $>70\%$ in at least three adjacent octave bands (Hurley and Musiek, 1994).

B. CENTRAL AUDITORY TEST PROCEDURES

We used a test battery that consisted of

- dichotic speech tests
- pattern tests
- a temporal resolution test (gaps in noise- GIN).

These tests were selected because:

- a. they have been widely used in studies of the CANS and their sensitivity and specificity in identifying auditory processing deficits is well known
- b. with the exception of the GIN, they are minimally affected by peripheral hearing loss
- c. they test different auditory processes, as per the recommendations of ASHA (2001; 2005)
- d. total testing time with the behavioural tests was less than 1 ½ hours, and was well tolerated by neurological as well as by children subjects.

Normative values for tests are given in table 7. All tests were available on CD. The CD was played with a Sony CD player and routed through the speech circuit of the GSI 61 audiometer. The test stimuli were administered to the patient via the audiometer with TDH-49 earphones in a sound proof room. For the central auditory tests, sensation level was referenced to the pure tone audiogram threshold at 1 kHz.

The **Dichotic Digits test** (Musiek, 1983). The test is composed of naturally spoken digits from 1 to 9, excluding 7. A different pair of digits is given simultaneously to each ear and the listener has to repeat all four digits. The outcome measure is the percentage of correct responses for each ear. Normal scores for adults are 90% or

better for each ear (Musiek et al., 1991). After a brief practice session of 3 pairs, the listeners were administered a list of 40 paired digits in each ear (figure 16). The sensitivity of this test in demonstrating lesions of cortical auditory areas is reported to be 75% and the specificity of the test in separating cochlear versus central auditory lesions is 90% (Musiek, Gollegly and Kibbe 1991).

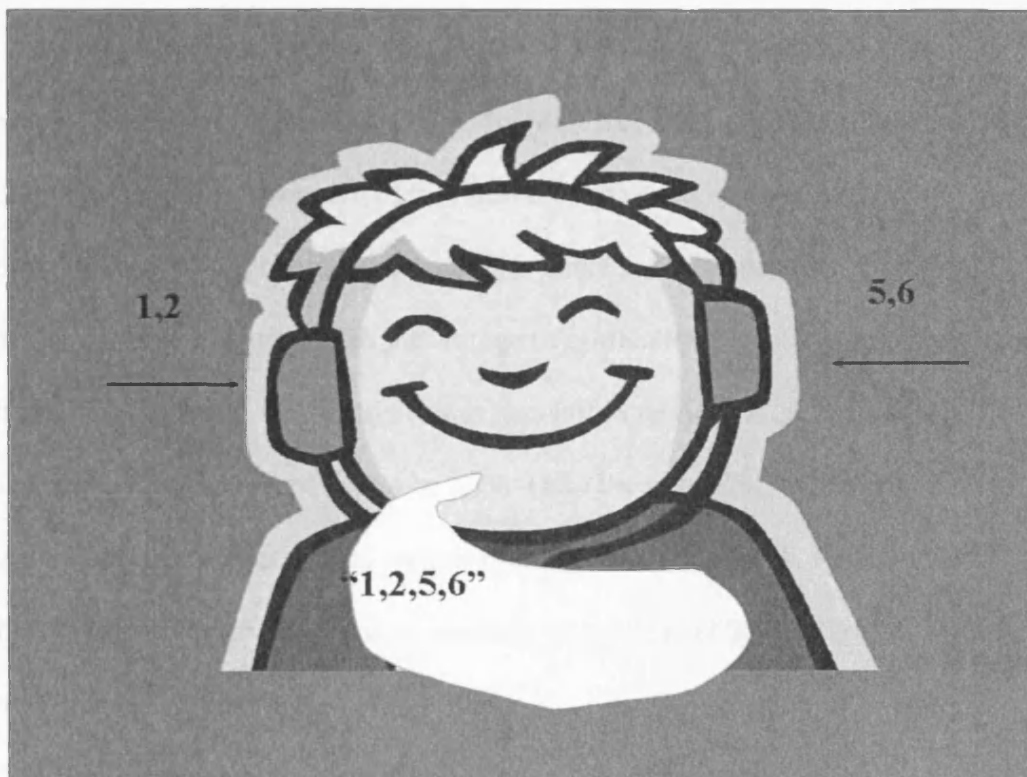


Figure 16. The dichotic digits test

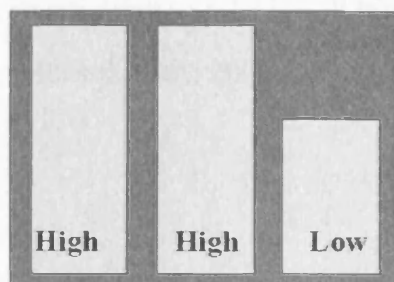
The **Dichotic Rhyme test** (Wexler, Halwes 1983) is composed of 15 dichotic pairs of words that are presented twice in a 30 trial block. The words consist of monosyllabic consonant-vowel-consonant words that begin with one of the six stop plosive consonants (b, p, t, d, g, k). The only difference for the two words in each pair is in the initial consonant. The listener reports only one word. The outcome measure is the percentage of correct responses in each ear. Three 30 trial blocks were administered.

The **Dichotic CVs test** (Noffsinger, Martinez & Wilson 1994) is composed of six consonant-vowel (CV) syllables formed by a stop plosive consonant (b, p, t, d, g, k) and the vowel /a/. A different consonant-vowel syllable is presented to each ear, at 50 dBSL. The outcome measure is the percentage of correct responses in right and in left ear. One 30 trial block was administered.

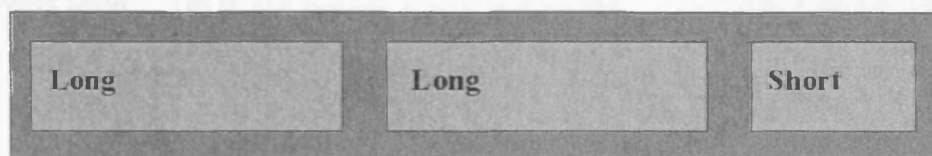
The **Frequency Pattern test** (Musiek, Pinheiro, 1987) consists of 3 tone burst sequences, which are a combination of a low (880 Hz) and a high frequency (1122Hz) tone. Each sequence is composed of two bursts of the same and one burst of a different frequency. The listener is required to name the sequence (e.g., high-high-low). The outcome measure is the percentage of correct responses. Normal scores for adults are 75% or better. The sensitivity of this test in demonstrating lesions of cortical auditory areas is reported to be 85% while the specificity of the test in separating cochlear versus central auditory lesions is 88% (Musiek, Pinheiro, 1987). A total of 30 patterns were presented monaurally to each ear at 50 dB SL after a brief practice session (figure 17).

The **Duration Pattern test** (Musiek, Baran, Pinheiro, 1990) consists of 3 tone burst sequences, which are a combination of a long (500 ms) and a brief duration (250 ms) tone of 1000 Hz. Each sequence is composed of two bursts of the same and one burst of a different duration at 300 ms interstimulus intervals. The listener is required to name the sequence (e.g., short-long-short). The outcome measure is the percentage of correct responses. Normal scores for adults are 70% correct or better. The sensitivity of this test in demonstrating lesions of cortical auditory areas is reported to be 85% and the specificity of the test in separating cochlear versus central auditory lesions is

92% (Musiek, Baran, Pinheiro, 1990). A total of 30 patterns were presented monaurally to each ear at 50 dB SL after a brief practice session (figure 17).



A. FPT



B. DPT

Figure 17. Schematic illustration of the stimulus in the A. frequency pattern test (FPT) and B. the duration pattern test (DPT).

In the **Gaps in Noise test** (Musiek et al., 2005) the patient is monaurally presented with a 6 second burst of white noise with 0 - 3 embedded gaps of 2, 3, 4, 5, 6, 8, 10, 12, 15, and 20 ms duration (figure 18). The interstimulus interval between the successive noise tokens is 5 seconds. There are six tokens for each gap duration in each list, and four lists are available for testing, which contain 29 up to 36 tokens each. The patient has to identify the number of gaps in each noise burst. This test provides two scores, the correct detection score (percent of correct answers) and the gap detection threshold, i.e. the shortest gap duration correctly identified in 50% (3

out of 6) of the trials for each gap duration. Normal results are a threshold better than 6 ms and a score better than 50% (Musiek et al., 2005 our own departmental data). The sensitivity of this test in demonstrating lesions of central auditory areas is reported to be 67% and the specificity of the test in separating cochlear versus central auditory lesions is 94 % (Musiek et al., 2005).

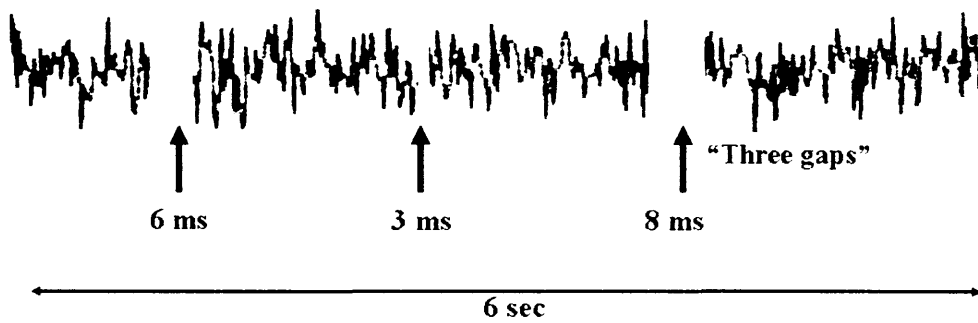


Figure 18. Schematic illustration of the stimulus in the Gaps-In-Noise test (GIN).

Table 7. Central Auditory Test Norms for Children and Adults (from the Dartmouth Hitchcock Audiology Lab)

Age	DDT		DiRhy	FPT		DPT		GIN
	R	L	R&L	R	L	R	L	R&L
<i>7yrs-7yrs 11m</i>	70%	55%	30%-60% for all ages					<u>Score:</u> >50%
<i>8yrs-8 yrs11m</i>	70%	65%		40%	40%			
<i>9yrs-9 yrs11m</i>	80%	75%		65%	65%			<u>Threshold:</u>
<i>10yrs-10yrs11m</i>	85%	78%		72%	72%			<6ms
<i>11yrs-11yrs 11m</i>	90%	88%		75%	75%			for all
<i>>12 & adult</i>	90%	90%		75%	75%	70%	70%	ages

C. QUESTIONNAIRES

These included the validated Amsterdam Inventory for Auditory Disability and Handicap (Kramer et al., 1995) for study 2, and a structured questionnaire administered to the parents of children of study 4.

I. The Amsterdam Inventory for Auditory Disability and Handicap (Kramer et al., 1995).

This is a 28-item questionnaire (see Appendix A) assessing patient-reported ability with everyday listening situations and has been validated in the Dutch population and translated into English by the original authors. The available answers are "almost never" (scored 3 points), "occasionally" (scored 2 points), "frequently" (scored 1 point), "almost always" (scored 0 points). Outcome measures include

1. a composite score (CS), which is compiled by adding all individual question scores, and

2. 5 sub-scores, as have been identified by factor analysis in a normative study

(Kramer et al., 1995). These include:

- a. detection of sounds (total score of questions 2, 10, 16, 21, 27).
- b. distinction of sounds (total score of questions 4, 5, 6, 17, 22, 23, 25, 28).
- c. intelligibility of speech in noise (1, 7, 13, 18, 24).
- d. intelligibility of speech in quiet (8, 11, 12, 14, 19), and
- e. sound localisation (total score of questions 3, 9, 15, 20, 26).

This questionnaire was used because it was the only hearing questionnaire in the English literature at the time of the study which had been previously used in subjects with suspected APD (Neijenhuis, Snik and van den Broek, 2003). The disability element of the questionnaire was used in order to establish patient reported symptoms in a standardised manner, and to assess the correlation of these symptoms with the test results. We did not use the handicap element of the questionnaire, as the stroke population suffers from additional handicap than hearing related, and a study assessing handicap in this population would need to consider and assess a multitude of other factors.

II. Structured questionnaire administered to the parents of children

This specifically devised structured questionnaire was given to the parents to complete during the time their child was being tested (Appendix B). These questions were selected on the basis of previously clinically reported auditory difficulties suffered by patients with abnormalities of the interhemispheric pathway. The parent

was asked to pick one of the following answers: “Almost never” (scored 0).

“Occasionally” (1 point). “Frequently” (2 points). “Almost always” (3 points).

D. IMAGING STUDIES

For studies 1 & 2, brain imaging of subjects was performed routinely during their admission to the Acute Brain Injury Unit at the National Hospital for Neurology and Neurosurgery. Imaging was performed on a Sigma 1.5T system (General Electric, Milwaukee, Echo Speed +). Axial and coronal fast spin-echo fluid attenuated inversion recovery images were routinely obtained on all cases. These images were used to evaluate the distribution of each lesion. The lesion was described by an experienced Consultant Neuro-Radiologist (Dr John Stevens).

For studies 3 & 4, subjects had a high resolution brain MRI with a T1-weighted 3D coronal inversion recovery prepared fast SPGR sequence. Imaging was acquired on a GE Sigma 1.5 T scanner (General Electric, Milwaukee, Echo Speed +) for study 3, and on a Siemens Magnetom Vision 1.5T scanner (Siemens, Erlangen, Germany) for study 4. The anterior commissure was visually inspected and reported upon by an experienced Consultant Neuro-Radiologist (Dr John Stevens) and Consultant Paediatric Radiologist (Dr Kling Chong) for studies 3 & 4 respectively. Corpus callosum cross-sectional area was measured on the mid-sagittal slice of the MRI SPGR data as previously reported (Free et al., 2003), by Dr Samantha Free, for both studies 3 & 4. Dr Free was blinded to the subject’s status (case or control).

Quantitative analysis was performed on the T1-weighted volume scan. Scan data were processed with a nonuniformity correction and reoriented to obtain an optimal mid-sagittal plane. Three points were manually identified, using in-house software

(MRreg), in order to calculate a rotation matrix, and to interpolate the data to the reoriented position (Mitchell et al., 2003b). The three landmarks used were: a. the anterior commissure (AC) (or its anterior limbs, if the AC was absent), b. the posterior commissure, and c. a superior mid-sagittal interhemispheric landmark. These three landmarks define the mid-sagittal plane. The corpus callosum cross-sectional area (CCA) was measured, as an estimate of the numbers of interhemispheric fibres in the brain, by manual delineation on the mid-sagittal section (Mitchell et al., 2003b). The corpus callosum was manually traced with a mouse and cursor, and its area estimated by pixel counting within the contour.

STATISTICAL ANALYSIS

The results were analyzed with the SPSS version 11.5 and 12.0.1. We used

- a. Chi-square tests to assess difference in proportions of abnormal test and questionnaire results between cases and controls
- b. Two tailed student t-tests or Mann-Whitney non-parametric tests or one-way analysis of variance (ANOVA) tests to evaluate differences in various scores (test, questionnaires or brain volumetry) between case and control subjects. T-tests were used when the sample was big enough to justify use of non-parametric tests, and in these cases p-values with the non parametric tests were broadly similar.
- c. Hierarchical multiple regression analysis to assess whether the central auditory test scores predict a significant amount of the Composite questionnaire score (study 2).

The level of statistical significance was accepted at ≤ 0.05 .

5. STUDY 1: AUDITORY PROCESSING IN PATIENTS WITH INSULAR STROKE

INTRODUCTION

The human insula (Brodmann areas 13 to 16) subserves visceral sensory and motor, motor association, vestibular and somatosensory functions (Augustine, 1985; Augustine, 1996). Physiological experiments have identified the presence of auditory responsive units in the insular cortex (Sudakov et al., 1971), while labelling studies have found connections of the insula with the medial geniculate nucleus, the primary and association auditory area, and with the temporal pole and superior temporal sulcus (Mesulam and Mufson, 1985; Augustine, 1985). However, the function of the insula as a component of the central auditory nervous system remained, until recently, unexplored.

Single case studies report impaired central auditory function in the presence of lesions of the insular cortex (Spreeen et al., 1965; Hyman and Tranel, 1989; Fifer, 1993). However, such case studies are rare, and in all cases the reported lesions affected not only the insula but other adjacent auditory structures, since vascular lesions restricted to the insular cortex are less than 1:1,000 (Cereda et al., 2003). Sophisticated neuroimaging studies also indicate that the insulae participate in networks which may subserve different auditory processes (Griffiths et al., 1997; Platel et al., 1997; Bamiou et al., 2003). However, the fact that the insula forms part of a network responsible for an auditory process does not prove that this structure is necessary for this process. It is therefore difficult to establish the specific auditory functions for

which the insula is necessary, if any. This study aims to assess central auditory function in a group of patients with unilateral ischemic lesions of the insula with and without involvement of adjacent cortical and subcortical areas, by means of a validated central auditory test battery in order to assess whether some auditory processes are more vulnerable to lesions of the insula than others, and in order to enhance our understanding of the role of the insula in audition.

METHODS

SUBJECTS

Patients with unilateral stroke which affected the insula and adjacent auditory cortex/subcortex, who were admitted to Acute Brain Injury Unit or seen in the One Stop Stroke Clinic at the National Hospital for Neurology and Neurosurgery, were identified by their brain MRIs and invited to participate in the study. Inclusion criteria, in addition to those mentioned in the methods section, were the presence of a unilateral lesion of the insula with or without involvement of the adjacent areas of the auditory cortex, and symmetrical audiometric thresholds with average audiometric thresholds at 0.5, 1, 2 and 4 kHz better than 30 dB HL. We also recruited an equal number of normal controls from the hospital staff and from spouses/partners of patients. The controls were matched to the subjects for age, sex, handedness, audiometric thresholds (\pm 5 dB) and audiometric configuration.

We recruited 8 right-handed patients (5 men, 3 women, age range: 36-79 years, age mean = 63 years) and an equal number of age and sex matched controls. The brain MRIs are shown in Figure 19.

Patients with stroke of the insula and adjacent areas without involvement of auditory cortical/subcortical areas

Case 1 is a 79-year-old man who presented with mild right-sided weakness and dysphasia. Brain MRI showed an infarct on the left side, involving the entire insula and the corona radiata.

Case 2 is a 74-year-old woman who presented with left-sided weakness, slurred speech, as well as episodic vertigo, nausea and unsteadiness which resolved within 1 hour. Brain MRI showed an infarct on the right side, involving the putamen and the insula limen. **Case 3** is a 78-year-old woman who presented with mild speech difficulty. Brain MRI showed an infarct on the right side, involving the short gyri of the insula and encroaching the long gyri.

Patients with stroke of the insula and adjacent areas with involvement of auditory cortical/subcortical areas

Case 4 is a 39-year-old man who presented with left facial, upper and lower limb weakness. Brain MRI showed an infarct on the right side, involving the transverse and superior temporal gyrus, the posterior superior temporal lobule, the inferior parietal lobule and the posterior insula. **Case 5** is a 65-year-old man who presented with headache, seizures and subsequent right limb weakness. Brain MRI showed an arteriovenous malformation on the left side, involving the transverse and superior temporal gyrus and the posterior insula. **Case 6** is a 43-year-old man who presented with right facial, upper and lower limb weakness and expressive and receptive

dysphasia. Brain MRI showed an infarct on the left side, involving the entire insula, the striatum and the adjacent frontal and temporal gyri. **Case 7** is a 51-year-old man who presented with headache and unsteadiness, left arm and leg weakness. Brain MRI showed an infarct on the right side, involving the entire insula and the adjacent frontal and parietal operculi. **Case 8** is a 78-year-old woman who presented with slurring dysarthria and left-sided hemiparesis. The brain MRI showed an infarct on the right side, involving the entire insula and the inferior frontal gyrus.

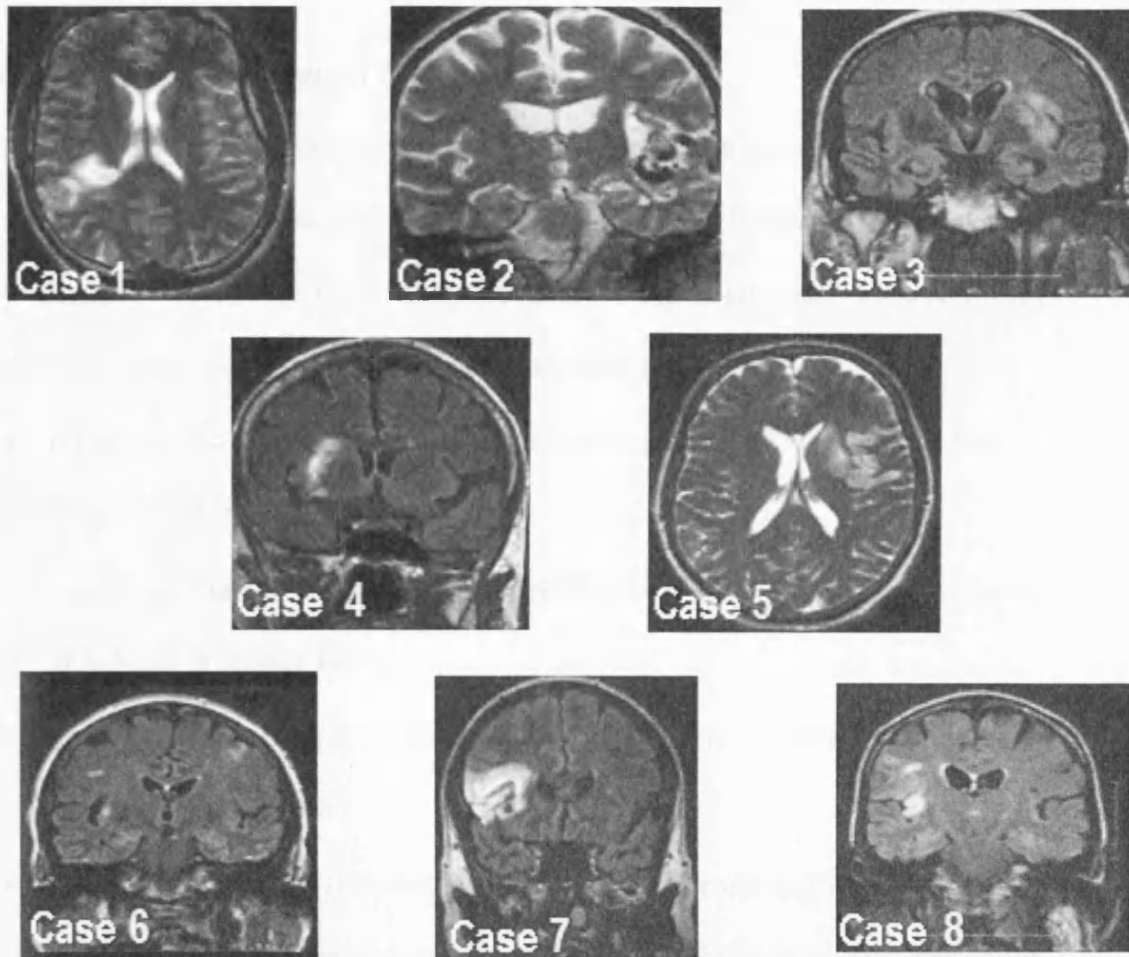


Figure 19. Fast spin echo (T2W) TR 6000 ms TE/EF 106, axial (case 1, case 5) and coronal acquisition (case 2) images. Fluid attenuated inversion recovery (FLAIR), TR 10,000 ms, TI 2500, coronal acquisition images (cases 3, 4, 6, 7, 8).

PROCEDURES

Each patient and control underwent standard baseline audiometric tests and central auditory tests (dichotic digits, frequency and duration pattern and gaps in noise tests) as previously described. Assessment of the subjects took place at least 4 weeks and up to 2 years after the acute onset of the stroke. All patients had a brain MRI, which was conducted 1 to 2 weeks after the onset of the vascular event. The majority of the patients had neuropsychological assessment conducted 3 to 8 days post stroke.

Neuropsychological Assessment

All the assessments were performed in the acute phase (3 to 8 days post stroke) as per the standard clinical protocol of the Acute Brain Injury Unit. The standardized tests used varied according to the patients' overall level of cognitive ability. However, they assessed the same range of cognitive functions including:

- premorbid intelligence (National Adult Reading Test, NART) (Nelson and Willison, 1991)
- current intelligence (Wechsler Adult Intelligence Scale Revised short version, WAIS-R) (Wechsler 1981)
- memory (standard or short version Recognition Memory Test) (Warrington 1984; Warrington 1996)
- confrontation naming (Graded Naming Test) (McKenna and Warrington 1983), visuoperception (subtests from the Visual Object and Space Perception Battery, VOSP) (Warrington and James 1991)
- executive function (Stroop Test, - Trenerry et al., 1989 and Weigl Sorting Task, - Weigl 1941)
- semantic and phonemic verbal fluency (Spreen and Strauss 1998; Miller 1984) and Proverb Interpretations (Gorham 1956)
- speed of information processing (Cancellation tasks, Digit Copying) (Willison 1988; Willison 1992).

In all 3 patients for whom language difficulties were evident, further tests were administered of:

- language comprehension (Test for the Reception of Grammar) (Bishop 1989)
- spelling (oral graded difficulty spelling, Baxter and Warrington 1994)
- calculation tasks (Jackson and Warrington, 1986).

Intellectual impairment was judged to be a difference of 15 points or more between NART and WAIS-R IQ scores or a defective score on the WAIS-R or RCM if the NART was not administered. Five patients were assessed on both the WAIS-R and NART. One patient was only assessed on the WAIS-R (Case 6), due to an acquired dyslexia. Impairment on memory, naming, spelling and calculation tasks was a score below the 5th percentile for age-adjusted norms. Visual perceptual functions were impaired if performance on selected VOSP subtests was below the 5 % cut-off. Impairment on at least two tests sensitive to executive dysfunction constituted 'executive' impairment. Time scores two standard deviations or more above the normal range on speed of information processing tests were considered impaired (Willison 1988).

STATISTICAL ANALYSIS

The results were analyzed with the SPSS version 11.5. We used two tailed student t-tests to evaluate differences in test scores between cases with left vs. right lesions and lesions sparing vs. lesions involving the anterior insula.

RESULTS

Standard baseline audiometric test results

Patients 2 and 8 had a symmetrical mild to moderate high frequency hearing loss, while the other subjects had normal hearing. Two of the age-matched controls had a mild to moderate high frequency hearing loss, while the other controls had normal hearing. Tympanograms were normal in all patients and controls. Otoacoustic emissions were consistent with the audiometric thresholds (i.e., only present in all frequency bands in which thresholds were better than 35 dBHL).

Central auditory tests

Patients with stroke of the insula and adjacent areas without involvement of auditory cortical/subcortical areas (Table 8)

Case 1 had normal average hearing thresholds, with abnormal right and left DDT scores (right<left). FPT and DPT scores were abnormal in both ears and GIN was abnormal on the right. He complained of difficulties understanding text which was sung. This is probably the most informative case, since other auditory areas were spared.

Case 2 had a symmetrical mild to moderate high frequency hearing loss in both ears, with bilaterally normal DDT scores. DPT, FPT and GIN were abnormal in both ears. She reported problems understanding speech in background noise, localizing sounds, as well as some problems recognizing melodies, understanding text which was sung, and understanding intonation/inflections in people's voices.

Case 3 gave normal average hearing thresholds and normal DDT on the right, but abnormal DDT on the left. FPT, DPT and GIN were bilaterally abnormal. She reported problems understanding speech in background noise, with localizing sounds, sound discrimination, understanding intonation and inflections in a voice as well as difficulties understanding text which was being sung.

Patients with insular stroke with involvement of auditory cortical areas_ (Table 8)

Case 4 gave normal average hearing thresholds and normal DDT and FPT scores in both ears. DPT and GIN were abnormal in both ears. He complained of difficulties recognizing people from their voices.

Case 5 had normal average hearing thresholds with a normal DDT on left and abnormal DDT on the right ear. FPT, DPT and GIN were bilaterally abnormal. He complained of difficulties conducting a conversation in a crowded meeting, localizing sounds, discriminating some sounds and distinguishing intonation and voice inflections.

Case 6 had normal average hearing thresholds and normal DDT scores in both ears. FPT and DPT were abnormal in both ears. GIN was abnormal on the right and normal on left ear. He complained of severe difficulties with understanding speech in noise, recognizing people from their voices, recognizing melodies, discriminating sounds, distinguishing male from female voices, hearing rhythm in songs and distinguishing intonation and voice inflections, as well as localizing the source of sounds.

Case 7 had normal average hearing thresholds, with normal right DDT, abnormal left DDT scores, abnormal FPT, DPT in both ears and normal GIN on the right, abnormal GIN on the left ear. He reported problems understanding speech in crowded places and understanding text that is being sung.

Case 8 had a symmetrical mild to moderate high frequency hearing loss in both ears, with an abnormal left DDT. FPT, DPT and GiN were abnormal in both ears. She reported problems understanding speech in background noise, distinguishing intonation and voice inflections and understanding text that is being sung.

Table 8. Summary of lesion details and central auditory test results

	Side	Insula	Other	DDT scores		FPT scores		DPT scores		GiN thresh	
				R%	L%	R%	L%	R%	L%	Rms	Lms
1	L	total	Corona radiata	57	75	44	67	36	26	8	6
2	R	anterior (limen)	putamen	92	90	10	30	37	37	8	10
3	R	Middle Short gyri		95	50	6	6	43	46	12	12
4	R	posterior	STG, TrG, Temporal parietal	100	97	82	82	52	52	8	8
5	L	posterior	STG, TrG	57	90	70	72	36	30	10	8
6	L	total	Frontal temporal	100	90	6	6	28	44	15	4
7	R	total	Frontal temporal	100	85	56	52	48	51	6	8

8	R	total	IFG	90	20	60	72	68	48	10	8
---	---	-------	-----	----	----	----	----	----	----	----	---

Abnormal scores are highlighted in grey.

DDT = Dichotic Digits Test. DPT= duration pattern test, FPT = Frequency pattern test, GiN=Gaps in noise test, IFG = inferior frontal gyrus, ND = not done, norm = normal, STG = superior temporal gyrus. TrG= transverse temporal gyrus.

lesion characteristics are shown in Table 8.

Controls

All the controls gave normal results on the DDT, FPT, DPT, and GIN in both ears.

Summary results for the controls are shown in Tables 9 and 10.

Table 9. Dichotic digit test (DDT), Frequency pattern (FPT) and duration pattern (DPT) tests: Summary percent score results (mean, SD) in subjects with left vs. right sided lesions and in controls

	R DDT	L DDT	R FPT	L FPT	R DPT	L DPT
Subjects- left lesion N = 3	71 (24)	85 (8)	40 (32)	48 (36)	33 (4)	33 (9)
Subjects- right lesion N = 5	95 (4)	68 (32)	42 (33)	48 (30)	49 (11)	46 (5)
Controls N = 8	98 (1)	92 (6)	97 (5)	97 (5)	86 (13)	91 (10)

Table 10. Gaps-in-noise (GIN) test: summary of threshold results (mean, SD) in subjects with left vs. right sided lesions and in controls

	GIN threshold right ear	GIN threshold left ear	GIN score right ear	GIN score left ear
Subjects-left lesion N = 3	11 (3)	6 (2)	29 (18)	51 (18)
Subjects-right lesion N = 5	8 (2)	9 (1)	46 (6)	46 (9)
Controls N = 8	4 (1)	5 (1)	68 (10)	62 (9)

Group results

Side and site of lesions

Left vs. right lesions

The DDT was abnormal in 5 cases. All these cases had abnormal scores in the ear contralateral to the lesion, while 1 case with a left total insular and corona radiata lesion also had an abnormal scores in the ipsilateral ear, but the score was more reduced in the ear contralateral to the lesion.

Patients with left-sided lesions gave lower DPT scores than patients with right-sided lesions for both the right ear ($p= 0.035$, CI of the difference = -30.9 to -1.6) and the left ear ($p = 0.045$, CI of the difference = -26.5 to - 0.38) (Figure 20).

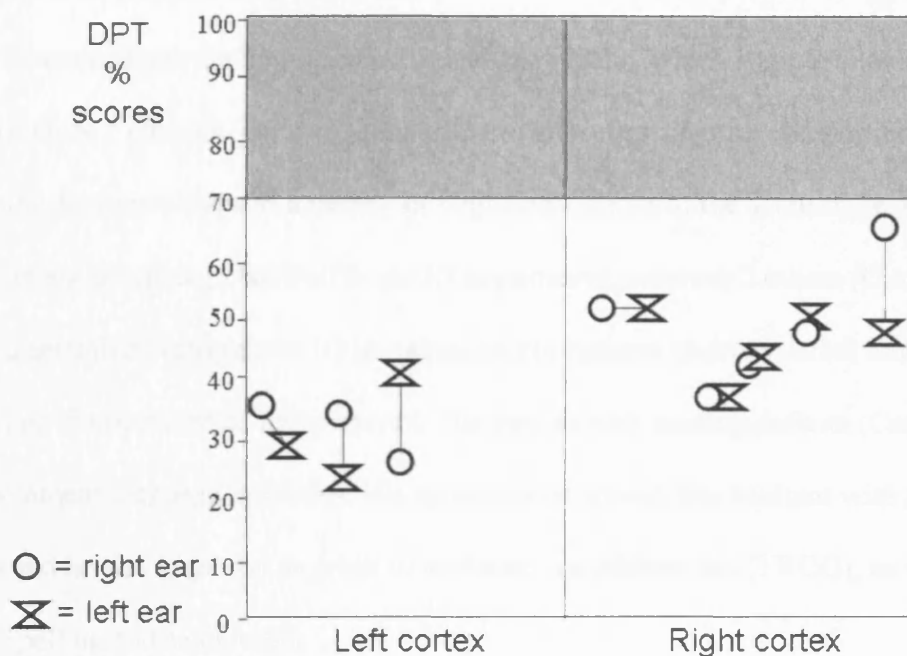


Figure 20. Scatterplot of duration pattern test (DPT) results in left versus right cortex lesions (gray shaded area represents normal range).

The GIN test was abnormal in all 8 cases. Thresholds were bilaterally abnormal in 5 cases (4 with a right and 1 with a left lesion) and abnormal only in the ear contralateral to the lesion in 3 cases (2 with a left and 1 with a right lesion) (Table 9).

Pattern test results for lesions sparing the anterior insula versus lesions affecting the anterior +/- other parts of the insula. The two patients with lesions sparing the anterior insula (Cases 4 & 5) had better frequency pattern scores than patients with lesions affecting the anterior and other parts of the insula, both for right ear scores ($p=0.010$, CI of the difference= 15 – 75), and for left ear scores ($p=0.026$, CI of the difference = 6- 69).

Neuropsychological assessment results

Table 11 summarizes the neuropsychological test results, which were available in 6 patients. Only 2 patients (Cases 3 and 8) did not show any cognitive impairment. The remaining 4 patients showed a variety of cognitive deficits at the acute stage. One patient (Case 6) had a global Full Scale IQ impairment, whereas 3 others (Cases 1, 2, 7) had a selective Performance IQ impairment. No patients showed verbal memory deficits or visuoperceptual impairments. The patient with naming deficits (Case 6) had prominent language problems. His spontaneous speech was hesitant with anomic pauses and he was impaired on a test of sentence comprehension (TROG), as well as a test of spelling and calculation.

Table 11. Summary of Neuropsychological Tests Scores

Case	NART FIQ	W- R FIQ	W- R VIQ	W- R PIQ	RMF	RMW	GNT	OD or IL*	Exec Funct	Speed of info proc
1	127	124	129	108	35/50 (<5%ile)	43/50 (50-75%ile)	24/30 (75-90%ile)	18/20	Failed	> 2SD
2	100	87	93	81	22/25 (10-25%ile)	24/25 (50%ile)	14/30 (5-10%ile)	19/20*	Failed	NT
3	107	110	104	121	24/25 (50%ile)	21/25 (10-25%ile)	23/30 (75%ile)	18/20	Passed	< 2SD
6	NT	68	65	75	27/50 (<5%ile)	NT	2/30 (<1st%ile)	20/20*	Passed	NT
7	100	90	104	77	48/50 (>75%ile)	37/50 (50%ile)	23/30 (75%ile)	18/20	Failed	NT
8	122	112	111	110	25/25 (>75%ile)	25/25 (>75%ile)	22/30 (50-75%ile)	19/20	Passed	< 2SD

NART = National Adult Reading Test. FIQ = Full Scale IQ, WAIS-R = Wechsler Adult Intelligence Scale -Revised. VIQ = Verbal IQ, PIQ = Performance IQ, RMF = Recognition Memory Test for Faces, RMW = Recognition Memory Test for Words
GNT = Graded Naming Test, OD = Object Decision, IL = Incomplete Letters, Executive Functioning = Stroop Test, Weigl Sorting Task, semantic and phonemic verbal fluency Speed of Information Processing = Cancellation tasks or Digit Copying, NT = not tested, %ile = percentile, SD = standard deviations.
Impaired scores are indicated in bold

DISCUSSION

We assessed central auditory function in 8 patients with strokes of the insula and adjacent areas by means of a central auditory test battery which incorporates 3 temporal processing tests (FPT, DPT, GIN). Three of our cases without lesions of the primary and association auditory cortex (cases 1-3) and with relatively preserved cognitive functioning even during the acute phase gave abnormal results for all three temporal tests and reported some difficulties with hearing. This finding is striking since these tests have a low false-positive rate, with specificity that ranges from 88% for the FPT (Musiek and Pinheiro 1987), 92% for the DPT (Musiek, Baran, Pinheiro 1990), to 94% for the GIN test (Musiek et al., 2005). In the presence of normal or near normal audiograms, their perceived hearing difficulties should be attributed to the presence of impaired temporal processing. Results of the three temporal tests were similarly abnormal in all 5 of the remaining cases, in which the lesions involved additional auditory responsive areas. This finding is again interesting since the sensitivity of the tests in identifying cortical lesions of the auditory system is around 85% for the FPT and DPT (Musiek and Pinheiro 1987; Musiek, Baran, Pinheiro, 1990), and 67% for the GIN (Musiek et al., 2005). Overall, these findings are in keeping with the hypothesis that the insula is an integral component of the central auditory pathway, consistent with the well-developed connections between the insula and auditory cortex and subcortex (Augustine, 1985; Bamiou, Musiek, Luxon 2003).

The GIN threshold was raised contralateral to the lesion in 3 cases and bilaterally in 5 cases. Previous studies report increases in gap detection thresholds in the ear contralateral to the site of the brain lesion for gaps in narrow-band noise (Efron et al.,

1985). The GIN findings may indicate that the insula is important for temporal resolution, although the bilaterality of the gaps-in noise test findings may also reflect different acoustic properties of the noise used in the test, i.e., white noise in our study vs. narrow-band noise in other studies (Efron et al., 1985; Sulakhe et al., 2003).

The DDT was abnormal in 2 out of 3 cases with the more circumscribed lesions. Case 1, who had a left-sided stroke affecting the entire insula and corona radiata, but sparing the primary auditory cortex, had deficits in both ears, but more pronounced in the ear opposite the side of the lesion. The same laterality effect has been noted in a single case study with an insular lesion (Hyman and Tranel 1989). The DDT was normal in another patient who had a lesion limited to the insula limen and putamen, in which case the extent of the lesion may not have been sufficient to produce a deficit in the test. The DDT results are broadly consistent with the sensitivity of this test in demonstrating lesions of cortical auditory areas, which is reported to be 75% (Musiek et al., 1991).

The FPT and DPT deficits may be reflected in the patient-reported difficulty with understanding text which was being sung. This was reported in all three cases without involvement of auditory cortical areas. A recent single-unit recording study in squirrel monkeys showed that neurons from the granular field of the posterior insula contribute to the encoding of complex frequency modulated signals, and that syllable-like elements of the natural monkey call are better encoded than synthesized signals (Bieser 1998). Ablation experiments in cats have shown that the insular-temporal region of the cat brain is vital for the animal's ability to discriminate temporal auditory patterns (e.g., A-B-A vs. B-A-B) (Collavita et al., 1974). Other authors (Griffiths et al., 1997) have similarly found a deficit in discrimination of fast but not

slow auditory sequences in a patient with a right insular lesion and suggested that this reflected a deficit in tone sequencing. Our findings may thus be interpreted as indicating that the human insula participates in the encoding of complex sound modulation, consistent with previous studies in both animals and humans.

In our study, all patients had unilateral insular lesions, with some extending to a variety of cortical and subcortical areas. We are aware that this is a major limitation, and caution needs to be exerted when interpreting our findings. However, the contrast of performance for different site and side of lesions suggests findings of significance. Looking at the group results, a dissociation between the frequency and the duration pattern test results in the patient sample was noted. This dissociation was both in terms of normal versus abnormal results, as previously reported (Musiek, Baran, Pinheiro 1994), and in terms of differential effects of left- versus right- and anterior-insula spared versus anterior-insula involved lesions. The DPT scores were worse in cases with left-sided lesions, consistent with the theory that proposes a left-auditory cortex specialization for temporal processing (Zatorre 2001). These findings may also be consistent with the PET findings (Platel et al., 1997) on six young healthy subjects that showed that musical rhythm judgement, as assessed by a task of identifying whether the lengths of the intervals and notes in the given music sequence were regular or irregular, mapped to the left insula.

The frequency pattern test scores were better in lesions that spared the anterior insula, while the duration pattern test scores were broadly similar. This may have to do with involvement of the anterior insula in pitch discrimination, as indicated by the study by Lewis et al (2000). Their functional MRI findings in eleven healthy subjects showed activation of the anterior insula by a pitch comparison task for tones presented on

successive discrimination trials. Other researchers (Griffiths et al., 1999), have shown that pitch pattern analysis is a complex process that activates a bilateral network. The lesions sparing the anterior insula were probably less extensive than lesions that involved the anterior insula, and could have spared structures within this network, such as the inferior frontal cortex. Both tests place demands on the same high-level processes, such as pattern processing, recognition and linguistic labelling, auditory attention and working memory (Pinheiro and Musiek 1985), as well as on the specific auditory process of sequencing /ordering of auditory stimuli. But whereas the duration pattern test taps into auditory duration discrimination (short versus long duration), the frequency pattern test taps into pitch discrimination (high versus low pitch). An additional factor that needs to be considered involves the different strategies that patients may employ to perform the tasks, e.g. humming the frequency pattern.

It is difficult to establish to what extent cognitive or language factors may have affected our findings, as the only information available came from psychometric assessment during the acute stage of the stroke. However, the central auditory deficits did not co-segregate with the presence of cognitive impairment during the acute stage, e.g., both cases 3 and 8 who had entirely normal cognitive function during the acute stage gave abnormal results for all the central auditory tests and, conversely, the only patient with a full IQ impairment during the acute stage (case 6) gave entirely normal results in one of the central auditory tests. In addition, none of the patients demonstrated verbal memory deficits. Overall, our findings may thus provide further evidence that insular lesions affect central auditory function and temporal resolution and sequencing in particular; however, further studies are needed to replicate and

extend the present findings and to establish specific functions of the different parts of the insula.

6. STUDY 2: AUDITORY PROCESSING DEFICITS AND DISABILITIES IN PATIENTS WITH STROKE OF THE CENTRAL AUDITORY PATHWAY

INTRODUCTION

Auditory processing disorders are associated with communication deficits and associated learning difficulties, and a higher likelihood of behavioural, emotional, social and other difficulties (American Speech-Language & Hearing Association, 2005). Thus early identification and appropriate management of these disorders can be crucial (Bamiou et al., 2006). There are several single as well as group studies documenting the presence of auditory processing deficits in patients with stroke of the central auditory pathway (e.g., Griffiths et al., 1997; Bamiou et al., 2006). However, the audiological presentation of patients suffering from stroke is not routinely assessed, as their hearing complaints may be overshadowed by other more urgent symptoms, or overlooked in the presence of other chronic disablements. Thus, the auditory disability, i.e. the functional limitation suffered by patients with auditory processing deficits due to documented lesions of the central auditory pathway remains underinvestigated, poorly understood, rarely recognised and in the majority of cases unaddressed.

This study aims to evaluate the self-reported hearing disability of patients with documented lesions of the central auditory pathway secondary to stroke, by means of a validated, self-report questionnaire (Kramer et al., 2005) and to assess whether the patient reported disability correlates with the central auditory test results.

METHODS

SUBJECTS

Patients with a history of unilateral ischemic or haemorrhagic cerebral stroke affecting the central auditory pathway (in the cortex, subcortex and brainstem), who had been admitted to the Acute Stroke and Brain Injury Unit or seen in the One Stop Stroke Clinic at the National Hospital for Neurology and Neurosurgery, and were identified on the basis of their brain MRIs were invited to participate in the study. Inclusion criteria and exclusion criteria for case subjects were as outlined in the “Methods” section.

An equal number of normal control subjects were recruited from the hospital staff and from spouses/partners of patients. Each case was matched to a control for gender, handedness, left and right average audiometric thresholds at 0.5, 1 and 2 kHz, and 4 and 8 kHz (+/- 10 dB) as well as age group (group 1 age 20-39 years, group 2 age 40-59 years, group 3 age above 60 years).

25 cases and an equal number of age and sex matched controls were ascertained. However five cases were subsequently excluded from analysis after close inspection of the scans, as the lesion did not involve auditory structures (see Appendix C for information on the lesions, questionnaire and test results in excluded subjects). The 20 cases included in the study consisted of 14 men and 6 women (age range: 25-79 years, age mean = 57 years, SD = 18) (Table 12). The following risk factors for stroke were present: hypertension (in 9), hypercholesteraemia (8), smoking (10), diabetes (4), angina (1), epilepsy (1), family history of stroke (3), family history of cardiovascular disease (1). 8 cases had 3 or more risk factors present.

Table 12. Age, sex and audiometric results in cases and controls.

	Cases N=20	Controls N=25
Age: mean (SD) ^a	57 (18)	55 (19)
Age group (N)		
20-39 years	6	7
40-59 years	4	8
> 60 years	10	10
Sex	14 m, 6 f	18 m, 7 f
R PTA average: mean (SD)		
Average of 0.5, 1, 2 kHz ^b	20 (10)	15 (9)
Average of 4, 8 kHz ^c	37 (21)	33 (22)
L PTA average: (mean, SD)		
Average of 0.5, 1, 2 kHz ^d	19 (9)	13 (8)
Average of 4, 8 kHz ^e	34 (20)	31 (21)

^a p = .654, ^b p = .057, ^c p = .443, ^d p = .028, ^e p = .538

List of abbreviations: f= female, m= male, kHz = kilohertz, L=left, PTA = pure tone audiogram, R=right

The lesion characteristics are shown in Table 13.

Table 13. Lesion description in cases

Case	Sex	Age	Lesion
1	M	29	infarct/large right parietal AVM, including inferior parietal lobule
2	M	68	infarct/AVM L transverse + superior temporal gyrus + posterior insula
3	F	78	infarct/ R short gyri and long gyri of the insula.
4	M	79	infarct/ L insula / corona radiata
5	F	74	infarct/ R putamen + insula limen
6	M	39	infarct/R transverse and superior temporal gyri
7	M	37	infarct/ L insula, striatum, adjacent frontal and temporal gyri
8	M	56	haematoma/ L posterior part striatum + posterior limb of internal capsule, lacunar infarcts in basal ganglia
9	F	35	Ruptured R middle cerebral artery aneurysm – high signal in R sylvian fissure. Surgical clipping.
10	F	39	2.8cm diameter cavernoma haemorrhage/ R brainstem and cerebellum
11	M	56	ischemic lesion of brainstem bilaterally, more extensive on the right, involving the trapezoid body bilaterally and the pons on the right
12	M	65	L haemorrhagic pontine infarct up to floor of 4 th ventricle, including the trapezoid body, superior olive, lacunar basal ganglia and thalamic infarcts
13	M	64	multifocal ischemic lesion of bilateral pons, trapezoid body, medial lemniscus, R posterior limb of internal capsule – lacunar infarcts basal ganglia
14	M	22	Haemorrhage from R pontine cavernoma
15	M	69	infarct/R striatum, thalamus, posterior corona radiata, posterior limb internal capsule

16	M	78	infarct/ L thalamus posterior limb internal capsule . lacunar state basal ganglia. thalami. inferior frontal cortical damage
17	F	78	infarct/ R insula, inferior frontal gyrus
18	M	57	infarct/ left internal capsule
19	F	56	Haemorrhage from L ventral pontine cavernoma
20	M	72	infarct/ L ventral pons, trapezoid body up to mid part of lateral lemniscus

AVM = arteriovenous malformation, L= left. R = right

STUDY PROTOCOL

Case- and control-subjects underwent

- a. baseline audiometric tests
- b. central auditory tests
 - Dichotic digits test (DDT)
 - Frequency pattern test (FPT)
 - Duration pattern test (DPT)
 - Gaps-In-Noise test (GIN)
- c. the validated Amsterdam Inventory for Auditory Disability and Handicap (Kramer et al., 1995) (Appendix A).

In addition, cases but not controls had a

- d. brain MRI, which was conducted 1 to 2 weeks after the clinical presentation of the original neurological lesion, and evaluated by an experienced Neuro-Radiologist (Dr John Stevens).

Assessment of the cases took place at least 4 weeks and up to 2 years after the acute onset of their lesion.

STATISTICAL ANALYSIS

The results were analyzed with the SPSS version 12.0.1. We used

- d. Chi-square tests to assess difference in proportions of abnormal test results between cases and controls
- e. Two tailed student t-tests to evaluate differences in inventory scores between case and control subjects.
- f. Hierarchical multiple regression analysis to assess whether the central auditory test scores predict a significant amount of the Composite score variance after controlling for possible effects of age and hearing thresholds.
- g. One-way analysis of variance (ANOVA) tests to compare differences in inventory scores versus abnormalities in central auditory tests (classified as normal, left ear abnormal, right ear abnormal, both ear abnormal)

RESULTS

Case subjects had a significantly higher proportion of abnormal results in the dichotic digits, frequency pattern, duration pattern and gaps in noise tests than controls (Table 14).

Table 14. Central auditory test results in Cases and Controls – proportion of abnormalities and chi-square p-values

	normal	R ear abn	L ear abn	both ear abn	N	p
DDT						
Controls	22 (88%)	1 (4%)	2 (8%)	0	25	.001
Cases	6 (30%)	2 (10%)	8 (40%)	4(20%)	20	
FPT						
Controls	22 (88%)	1(4%)	0	2 (8%)	25	.000
Cases	5 (25%)	4 (20%)	1 (5%)	10 (50%)	20	
DPT						
Controls	23 (92%)	0	1 (4%)	1 (4%)	25	.000
Cases	3 (20%)	3 (20%)	0	9 (60%)	15	
GIN						
Controls	16 (67%)	1 (4%)	4 (17%)	3 (12%)	24	.019
Cases	4 (22%)	3 (17%)	3 (17%)	8 (44%)	18	

Abn = abnormalities, DDT = dichotic digits test, FPT= frequency pattern test, DPT = duration pattern test, GIN = gaps in noise test, R= right, L = left, N = number

The Amsterdam Inventory composite score as well as the five subscores (sound detection, sound distinction, intelligibility of speech in quiet, intelligibility of speech

in noise. sound localization) were significantly higher (indicating more disability) in cases than in controls (Table 15).

Table 15. Inventory scores in case and control subjects, mean differences and T test p-values.

Scores	Cases Mean (SD)	Controls Mean (SD)	Mean difference	CI of the difference	P - value
Composite Score	17.3 (18)	5.5 (6.8)	11.8	3.4 – 20.2	.007
Sound detection	2.2(2.6)	.8(1.4)	1.4	.20 – 2.7	.022
Sound distinction	4.8(5.1)	1.1(1.7)	3.7	1.4 – 5.9	.002
Speech in noise	5.4(4.5)	1.7(2)	3.6	1.5– 5.7	.001
Speech in quiet	3.6(3.6)	.9(1.1)	2.7	1.1 – 4.3	.001
Sound localization	3.8(4)	.9(1.9)	2.9	1 - 4.8	.003

Questionnaire scores versus Central Auditory Test results

Hierarchical multiple regression analysis results

Age and left and right hearing thresholds accounted for 21.4% of the variance ($p=.232$) while the central auditory test scores accounted for 64.1% of the variance ($p<.001$) of the Questionnaire Composite Score. The right duration pattern test score was the strongest predictor. (standardized beta coefficient = -1.722, $p<.001$).

Subscores

The intelligibility of speech in noise subscore correlated significantly with the dichotic digits test score ($p<.001$) (Table 16). A post-hoc analysis indicated that the intelligibility of speech in noise subscore was higher for subjects with reduced left ear dichotic digits test score ($p=.004$) or bilaterally reduced dichotic digits test score ($p=.001$) compared to subjects with bilaterally normal dichotic digits test scores (Table 17).

Table 16. Analysis of variance of intelligibility of speech in noise vs. dichotic digits test (DDT) results ($f(3,38) = 9.578, p<.001$) Abn = abnormal, L= left, R = right

DDT	N	Mean	Std. Deviation	95% Confidence Interval for Mean	
				Lower Bound	Upper Bound
normal	27	1.6	2.2	.76	2.5
R ear abn	3	5.6	3.7	-3.7	15
L ear abn	10	5.8	4.3	2.6	8.9
both ear abn	2	10.5	2.1	-8.5	29.5
Total	42	3.35	3.7	2.1	4.5

Table 17. Analysis of variance of intelligibility of speech in noise vs. dichotic

digits test (DDT) results: Post-hoc Bonferroni analysis Abn = abnormal, L= left.

R = right

(I) DDT	(J) DDT	Mean Difference (I-J)			
		95% Confidence Interval		Lower Bound	Upper Bound
normal	R ear abn	-4.00000	.200	-9.0429	1.0429
	L ear abn*	-4.13333	.004	-7.2008	-1.0659
	both ear abn*	-8.83333	.001	-14.9058	-2.7609
R ear abn	normal	4.00000	.200	-1.0429	9.0429
	L ear abn	-.13333	1.000	-5.5880	5.3214
	both ear abn	-4.83333	.500	-12.3976	2.7310
L ear abn	Normal*	4.13333	.004	1.0659	7.2008
	R ear abn	.13333	1.000	-5.3214	5.5880
	both ear abn	-4.70000	.291	-11.1185	1.7185
both ear abn	Normal*	8.83333	.001	2.7609	14.9058
	R ear abn	4.83333	.500	-2.7310	12.3976
	L ear abn	4.70000	.291	-1.7185	11.1185

* The mean difference is significant at the .05 level.

The intelligibility of speech in quiet subscore correlated significantly with the dichotic digits test score ($p < .001$) (Table 18). A post-hoc analysis indicated that the intelligibility of speech in quiet subscore was higher for subjects with reduced left ear dichotic digits test score ($p = .002$) or bilaterally reduced dichotic digits test score ($p < .001$) compared to subjects with bilaterally normal dichotic digits test scores (Table 19).

Table 18. Analysis of variance of intelligibility of speech in quiet vs. dichotic digits test (DDT) results ($f(3,38)=16.9$, $p < .001$) Abn = abnormal, L= left, R = right

DDT	N	Mean	Std. Deviation	95% Confidence Interval for Mean	
				Lower Bound	Upper Bound
normal	26	.8077	1.02056	.3955	1.2199
R ear abn	3	1.0000	1.73205	-3.3027	5.3027
L ear abn	10	3.6000	2.95146	1.4887	5.7113
both ear abn	3	8.3333	3.78594	-1.0715	17.7381
Total	42	2.0238	2.81536	1.1465	2.9011

Table 19. Analysis of variance of intelligibility of speech in quiet vs. dichotic digits test (DDT) results: Post-hoc Bonferroni analysis Abn = abnormal, L= left, R = right

(I) DDT	(J) DDT	Mean			
		Difference (I-J)	Sig.	95% Confidence Interval	
				Lower Bound	Upper Bound
normal	R ear abn	-.19231	1.000	-3.4396	3.0550
	L ear abn*	-2.79231	.002	-4.7740	-.8106
	both ear abn*	-7.52564	.000	-10.7729	-4.2784
R ear abn	normal	.19231	1.000	-3.0550	3.4396
	L ear abn	-2.60000	.275	-6.1057	.9057
	both ear abn*	-7.33333	.000	-11.6817	-2.9850
L ear abn	Normal*	2.79231	.002	.8106	4.7740
	R ear abn	2.60000	.275	-.9057	6.1057
	both ear abn*	-4.73333	.003	-8.2391	-1.2276
both ear abn	Normal*	7.52564	.000	4.2784	10.7729
	R ear abn*	7.33333	.000	2.9850	11.6817
	L ear abn*	4.73333	.003	1.2276	8.2391

* The mean difference is significant at the .05 level.

The gaps in noise test results correlated with patient reported speech-in noise difficulties ($p = .033$), (Table 20). A post-hoc analysis indicated that the intelligibility of speech in noise subscore was higher for subjects with reduced bilateral gaps in noise scores ($p = .030$) compared to subjects with bilaterally normal gaps in noise scores (Table 21).

Table 20. Analysis of variance of intelligibility of speech in noise vs. Gaps in Noise (GIN) results ($f(3,35) = 3.247$, $p = .033$) Abn = abnormal, L= left, R = right

GIN	N	Mean	Std. Deviation	95% Confidence Interval for Mean	
				Lower Bound	Upper Bound
normal	20	1.5500	1.50350	.8463	2.2537
R ear abn	3	4.3333	7.50555	-14.3115	22.9782
L ear abn	6	3.8333	3.86868	-.2266	7.8933
both ear abn	10	5.6000	4.64758	2.2753	8.9247
Total	39	3.1538	3.78041	1.9284	4.3793

Table 21. Analysis of variance of intelligibility of speech in noise vs. Gaps in noise (GIN) results: Post-hoc Bonferroni analysis Abn = abnormal, L= left, R = right

(I) GIN	(J) GIN	Mean Difference			
		(I-J)	Sig.	95% Confidence Interval	
				Lower Bound	Upper Bound
normal	R ear abn	-2.78333	1.000	-8.8159	3.2492
	L ear abn	-2.28333	1.000	-6.8187	2.2520
	both ear abn*	-4.05000	.030	-7.8236	-.2764
R ear abn	normal	2.78333	1.000	-3.2492	8.8159
	L ear abn	.50000	1.000	-6.3897	7.3897
	both ear abn	-1.26667	1.000	-7.6806	5.1473
L ear abn	normal	2.28333	1.000	-2.2520	6.8187
	R ear abn	-.50000	1.000	-7.3897	6.3897
	both ear abn	-1.76667	1.000	-6.7982	3.2649
both ear abn	Normal*	4.05000	.030	.2764	7.8236
	R ear abn	1.26667	1.000	-5.1473	7.6806
	L ear abn	1.76667	1.000	-3.2649	6.7982

* The mean difference is significant at the .05 level.

In addition, the gaps in noise score correlated with sound distinction ($p = .010$) (Table 22), and a post-hoc analysis indicated that subjects who had left ear abnormalities had higher distinction of sounds subscores than subjects with bilaterally normal gaps in noise scores ($p = .016$) (Table 23).

Table 22. Analysis of variance of sound distinction vs. gaps in noise (GIN) results
($f(3,33) = 4.42, p = .010$) Abn = abnormal, L = left, R = right

GIN	N	Mean	Std. Deviation	95% Confidence Interval for Mean	
				Lower Bound	Upper Bound
normal	19	.6316	.95513	.1712	1.0919
R ear abn	3	5.3333	9.23760	-17.6141	28.2808
L ear abn	7	5.4286	4.85994	.9339	9.9233
both ear abn	8	2.3750	2.44584	.3302	4.4198
Total	37	2.2973	3.79960	1.0304	3.5641

Table 23. Analysis of variance of sound distinction vs. gaps in noise (GIN)

results: Post-hoc Bonferroni analysis Abn = abnormal, L= left, R = right

(I) GIN	(J) GIN	Mean			
		Difference (I-J)	Sig.	95% Confidence Interval	
				Lower Bound	Upper Bound
normal	R ear abn	-4.70175	.184	-10.5459	1.1424
	L ear abn*	-4.79699	.016	-8.9562	-.6378
	both ear abn	-1.74342	1.000	-5.7081	2.2212
R ear abn	normal	4.70175	.184	-1.1424	10.5459
	L ear abn	-.09524	1.000	-6.5866	6.3961
	both ear abn	2.95833	1.000	-3.4102	9.3268
L ear abn	Normal*	4.79699	.016	.6378	8.9562
	R ear abn	.09524	1.000	-6.3961	6.5866
	both ear abn	3.05357	.526	-1.8150	7.9221
both ear abn	normal	1.74342	1.000	-2.2212	5.7081
	R ear abn	-2.95833	1.000	-9.3268	3.4102
	L ear abn	-3.05357	.526	-7.9221	1.8150

* The mean difference is significant at the .05 level.

The sound distinction subscore correlated significantly with the frequency pattern test score ($p = .011$) (Table 24). A post-hoc analysis indicated that subjects with bilaterally abnormal frequency pattern test score had higher sound distinction subscores than subjects with bilaterally normal frequency pattern test score ($p = .009$) (Table 25).

Table 24. Analysis of variance of sound distinction vs. frequency pattern test (FPT) results ($f(2,37)=6.85$, $p=.003$) Abn = abnormal, L= left, R = right

FPT	N	Mean	Std. Deviation	95% Confidence Interval for Mean	
				Lower Bound	Upper Bound
normal	27	1.4074	2.35763	.4748	2.3401
R ear abn	4	2.0000	1.82574	-.9052	4.9052
both ear abn	9	6.2222	5.82619	1.7438	10.7006
Total	40	2.5500	3.86934	1.3125	3.7875

Table 25. Analysis of variance of sound distinction vs. frequency pattern test

(FPT) results: Post-hoc Bonferroni analysis Abn = abnormal, L= left, R = right

(I) FPT	(J) FPT	Mean			
		Difference (I-J)	Sig.	95% Confidence Interval	
				Lower Bound	Upper Bound
normal	R ear abn	-.59259	1.000	-5.1518	3.9666
	both ear abn	-4.81481	.002	-8.0903	-1.5394
R ear abn	normal	.59259	1.000	-3.9666	5.1518
	both ear abn	-4.22222	.136	-9.3360	.8916
both ear abn	normal	4.81481	.002	1.5394	8.0903
	R ear abn	4.22222	.136	-.8916	9.3360

* The mean difference is significant at the .05 level.

DISCUSSION

This study found that patients with focal stroke involving the central auditory pathway report significantly more problems than normal controls (matched for age and hearing thresholds), on all aspects of everyday hearing, as assessed by means of a validated hearing questionnaire. Thus, as a group, the present patient sample of 20 subjects with an acute onset unilateral lesion of the central auditory pathway reported significantly greater difficulty with sound detection and distinction, intelligibility of speech in noise and in quiet and sound localization than age and hearing matched normal controls. Neuroimaging studies indicate that central auditory processing for both speech and non-speech sounds is mediated by an extensive, bilateral network, which may contain functionally specialized regions (Boatman 2006). Therefore, lesions at any level of this pathway may lead to an auditory processing impairment, for both speech and non-speech sounds. The present results indicate that stroke patients with focal neurological lesions involving the central auditory pathway should be questioned about difficulties with all these aspects of hearing.

There is a paucity of earlier studies assessing disability in patients with auditory processing deficits. Blattner et al (1989) administered a hearing questionnaire to patients with unilateral cerebrovascular lesions of the telencephalic auditory structures, in order to assess potential auditory perceptual problems in everyday hearing situations, as part of the validation study for a psychoacoustic pattern discrimination test. They found that about half (49%) of these patients reported auditory perceptual problems in the questionnaire, particularly in situations with simultaneous speakers, while auditory perceptual problems were reported by the vast majority (79%) of those patients who gave abnormal results in the psychoacoustic

test. Of interest, these patients “often stated that they did not have any hearing complaints” prior to the questionnaire being administered. This is consistent with our own anecdotal observations that neurological patients with self-reported difficulties in several hearing activities (e.g., localisation of sounds, understanding speech in noise, perception of music), may not attribute these difficulties to hearing, since their ability to hear soft sounds may be unimpaired. Blattner et al (1989) proposed that the reduced ability of patients with central auditory lesions to follow or select a speaker in a noisy environment is similar to the disability experienced by subjects with a peripheral (cochlear) hearing loss, and this central auditory disability should be taken into account when evaluating the communication abilities of patients with brain lesions. This study, as well as the present work, highlight the need for specific questioning with respect to hearing abilities and detailed audiological evaluation of those at risk for auditory processing deficits due to a lesion of the central auditory pathway, especially stroke.

Neijenhuis, Snik and van den Broek (2003) assessed hearing disability in 24 otherwise neurologically normal adults with a suspected auditory processing disorder, i.e. patients who complained of hearing difficulties on the Amsterdam Inventory despite the presence of a normal audiogram and speech in quiet audiometry, as part of the validation study for a central auditory test battery. 68% of these adults gave abnormal results (scores below the 90th percentile of the normal control group) in the central auditory test battery. They found that, as a group, the subjects with a suspected auditory processing disorder reported significantly more complaints regarding hearing abilities than normal controls for all five factors assessed by the Amsterdam Inventory, with speech in noise and sound localization as the most

frequently reported difficulties, similar to our results on neurologically impaired patients.

The proportion of abnormal results on the central auditory tests in our sample was comparable to the reported sensitivity and specificity of these tests in the medical literature, i.e. the population of this study is comparable to other investigated populations with central auditory lesions. The dichotic digits test was abnormal in 70% of cases, consistent with the reported sensitivity of 75% of this test (Musiek et al., 1991) and in 12% of controls consistent with the reported specificity of 90% of this test (Musiek et al., 1991). The frequency pattern test was abnormal in 75 % of the patients vs. previously reported sensitivity of 85% (Musiek and Pinheiro, 1987) and in 12 % of controls, consistent with the reported specificity of 88% for this test (Musiek and Pinheiro, 1987). The duration pattern test was abnormal in 80% of cases vs. previously reported sensitivity of 85% (Musiek et al., 1990) and in 8% of controls, consistent with the reported specificity of 92% for this test (Musiek et al., 1990). The gaps in noise test was abnormal in 78% of cases consistent with the reported sensitivity of 67% (Musiek et al., 2005) and in 33% of controls. This lower specificity than previously reported is most probably due to the presence of hearing loss in some control patients, as specificity data have been given on patients with normal peripheral hearing.

The questionnaire scores correlated with some of the central auditory test results, potentially providing some insight into the correlation between the psychoacoustic deficit and the patient-reported symptom. Intelligibility of speech in noise was reduced in those with reduced left or bilateral ear score in the dichotic digits test

compared to those who gave bilaterally normal dichotic digits test scores.

Neuroimaging studies indicate that speech processing is mediated by an extensive bilateral network (Boatman 2006), while the processing of speech in background noise requires input from both hemispheres, with the left hemisphere compensating for loss of phonologic information and the right hemisphere compensating for increased attention demands (Boatman et al., 2003). Dichotic speech tests are not dissimilar to real life listening to a speech message in the presence of a competing speech or noise. Dichotic speech tests similarly appear to activate a wide network in each hemisphere, with the dichotic test results reflecting both the effects of interhemispheric transfer and of asymmetries in processing efficiency between the two hemispheres (Jäncke, 2002). The dichotic digits test, and a left ear deficit in particular, which may be produced by a left or right auditory cortical/subcortical lesion or by left or right lesion at different levels of the brainstem (Musiek, Baran, Pinheiro 1994) may thus serve as indirect measure of speech in speech competition difficulties in real life listening situations.

The gaps in noise test results correlated both with the speech in noise and with the sound distinction subscores. These finding may be consistent with the observation that listeners exploit subtle time differences in onset (and, to a lesser extent, offset) between two sounds to segregate them (Carlyon 2004). The detection and identification of subtle duration changes of sounds on one hand and of spectral changes of sounds, which may be subserved by different auditory pathways, and the integration of this information are fundamental functions of the human auditory system, which up to a point happen pre-attentively and which underlie sound source analysis and the identification of auditory objects (Grimm et al., 2006). The sound

distinction subscore also correlated with the frequency pattern test results, with subjects with bilaterally abnormal frequency pattern test scores reporting greater difficulties with sound distinction than subjects with bilaterally normal scores. This may well be because the items of “distinction of sound” (recognise family members by their voices, recognize melodies, distinguish intonation and inflections in people’s voices, hear rhythm in a song) also refers to pattern content of the perceived sounds (Kramer et al., 1995).

There were some inherent limitations in this study, in that we included cases with disparate central auditory lesions, while the small numbers of case subjects did not permit the investigation of the correlation between site of lesion versus auditory deficit and disability. It has been proposed that there are separate cortical processing pathways for auditory recognition and localization, and patients with lesions involving the inferior parietal and frontal cortices and the superior temporal gyrus may exhibit a selective sound localization deficit, while patients with lesions of the temporal pole and anterior part of the fusiform, inferior and middle temporal gyri may have a selective recognition deficit (Clarke et al., 2002). Another limitation was that some case subjects had mild peripheral hearing loss which could also cause symptoms, although the same was also true for controls, who were matched to the subjects for hearing thresholds. In addition, we did not compare the questionnaire results to psychology/speech and language assessment of the patients, as these results were not always available. However, we excluded patients with severe aphasia/cognitive disorders from this study. Another potential limitation was that the questionnaire was not specifically developed to assess patients with central auditory lesions, and thus did not include questions on other aspects of hearing that could have

been affected, e.g., hyperacusis or attaching emotion to music. To our knowledge, a validated questionnaire for the assessment of these patients does not as yet exist, and there are very few studies which have reported on hearing questionnaire assessment results on these patients.

Our findings have implications for the clinical management of these patients. The World Health Organisation Classification of Functioning Disability and Health (ICF) (2001) provides a conceptual framework which helps consider and address the disease-related difficulties experienced by the patient. According to the proposed model, the underlying disease (stroke/other injury of the central auditory pathway) may lead to an impairment of function (audition) which may adversely affect the patient's activities (e.g., understanding speech in background noise) and thus restrict social participation (e.g., parties, group meetings etc). Both extraneous/environmental factors (e.g. the acoustics of the room where the party takes place) and personal factors (e.g., personality, language resources) may affect different stages of this process, and may be targeted by intervention (Stephens, 2003). Functional impairments, i.e. abnormal psychological or physiological function is measurable by standardised psychological or physiological tests. "Activity limitation" defined as "difficulties an individual may have in executing activities" corresponds to the concept of disability, and may depend both on the impairment, as well as on the demand placed on the auditory system, and may be assessed by questionnaires or specific tests (Stephens, 2003). Careful evaluation to identify the difficulties – and the context of the difficulties- experienced by the patient is therefore of paramount importance in order to instigate audiological rehabilitation which will address the patient's difficulties. Audiological rehabilitation of auditory processing disorders in

the adult patient may include advice regarding listening strategies, instrumentation (such as personal FM systems for the patient in the classroom), ancillary help, as well as specific auditory training (Bamiou et al., 2006). Auditory training, in particular, is implemented in order to improve the patient's auditory processing by capitalising on the brain's potential for plasticity as well as by recruitment and enhancement of other metacognitive or metalinguistic processes. At present, the auditory tasks employed for training purposes are chosen on the basis of specific test findings (Chermak and Musiek, 2002). Research into auditory learning in normal adult listeners has shown that learning may differ between individuals, and it has been suggested that a baseline assessment of performance on the training task may help to custom-choose the most appropriate training materials per individual in order to facilitate optimal learning (Amitay et al., 2005).

In conclusion, patients with a focal ischemic lesion of the central auditory pathway reported significantly greater difficulties with a range of perceptual auditory abilities than age- and hearing- matched normal controls. These difficulties which impact on the patient's communication may, however, be eclipsed by more urgent symptoms or other chronic disablements. It is important to consider and evaluate auditory processing in the patient with a lesion of the auditory brain and to appreciate that it is not just peripheral loss which may yield auditory difficulties. Patients should be questioned in detail regarding their hearing abilities and tested according to their reported symptoms.

7. STUDY 3. CENTRAL AUDITORY FUNCTION IN PATIENTS WITH *PAX6* MUTATIONS.

INTRODUCTION

The *PAX6* gene encodes a transcriptional regulator that is highly conserved across species (van Heyningen and Williamson, 2002). Initially, phenotypic manifestations of heterozygous *PAX6* mutations were thought to be confined to the eye, with panocular features of developmental aniridia, while the identification of heterozygous intragenic mutations in 80-90% of classical aniridia patients indicated that *PAX6* may be the sole gene implicated in the autosomal dominant phenotype (van Heyningen and Williamson, 2002). Subsequently, *PAX6* human heterozygotes were found to have structural brain abnormalities, detectable by brain MRI (Sisodiya et al., 2001). *PAX6* is known to regulate regional cortical development, neuronal migration and thalamocortical and corticothalamic axon pathfinding in the brain (Hevner et al., 2002; Jones et al., 2002; Talamillo et al., 2003). The recently documented phenotypic effects of *PAX6* haploinsufficiency in the human brain include an absent or hypoplastic anterior commissure together with a reduction in the size of the corpus callosum (Sisodiya et al., 2001). This was the first report of an absent anterior commissure with present corpus callosum as a malformative sequence, and its functional significance is not well understood.

The anterior commissure is implicated in olfactory as well as auditory interhemispheric transfer (Di Virgilio et al., 1999). Abnormal olfaction was indeed identified in 13 out of 14 *PAX6* heterozygotes (Sisodiya et al. (2001). In addition, a recent case report suggested the presence of central auditory deficits in the form of

impaired auditory interhemispheric transfer in a patient with *PAX6* haploinsufficiency (Bamiou et al., 2004 a). This deficit could be attributed to the anterior commissure and/or corpus callosum structural and functional abnormalities, as these structures contain auditory interhemispheric fibres (Pandya and Seltzer 1986). Subjects with callosal agenesis, with or without an anterior commissure, may suffer from a range of central auditory deficits, that include deficient phonological processing as evidenced on rhyming tasks (Temple et al., 1990), impaired sound localization (Lepore et al., 1994) and reduced interhemispheric transfer (Santhouse et al., 2002; Lessard et al., 2002), with small but reliable ear asymmetries to verbal stimuli in dichotic speech tasks, i.e. tasks in which the two ears are in competition (Sauerwein et al., 1994). While the auditory deficits do not necessarily correlate with the IQ of these subjects (Temple and Ilsey, 1994), they are associated with educational difficulties (Temple et al., 1990; Jacobson and Jeeves, 1994). The profile in callosal agenesis is in general subtler than in the case of the “split brain” patient, in whom left ear performance in dichotic speech tasks is rendered virtually extinct (Musiek and Reeves 1986), with bilaterally severely reduced performance in monaural tasks requiring interhemispheric transfer (Musiek and Reeves 1986; Musiek et al., 1980), but with normal performance in auditory tasks not requiring such transfer (Musiek and Reeves 1986). It is not clear whether the presence of an intact anterior commissure in callosotomy cases is associated with milder auditory deficits (Risse 1978) or not (McKeever 1981), or whether hypertrophy of the anterior commissure in cases with corpus callosum agenesis enables functional compensation (Fischer et al., 1992), and the neurodevelopmental role of this formation remains unknown.

The purpose of this study was to assess central auditory function, and auditory interhemispheric transfer in particular, in patients with *PAX6* mutations, by means of a central auditory test battery, in order to characterize the genotype-phenotype relationship and to gain insight into the functional significance of the abnormalities in the auditory interhemispheric pathway. We hypothesized that (a) patients with *PAX6* mutations would have deficient auditory interhemispheric transfer and (b) auditory interhemispheric transfer would be more severely impaired in patients who had both an absent anterior commissure and an hypoplastic corpus callosum.

METHODS

SUBJECTS

We recruited adult subjects with a known *PAX6* mutation who attended Moorfields Eye Hospital for their visual difficulties and an equal number of normal controls, who were matched to the subjects for age, sex, and handedness.

PROCEDURES

All the subjects had had a brain MRI with volumetry of the corpus callosum as previously described. Subjects and controls had (see “Methods” section):

- Standard baseline tests (pure tone audiometry, tympanometry and transient evoked otoacoustic emissions)
- Central auditory tests (dichotic digits, rhyme and consonant-vowels (CVs), frequency and duration pattern and the gaps-in-noise test).

Statistical analysis

The dichotic test results were analyzed as an outcome measure of interhemispheric transfer with the SPSS version 11.5. We used Mann-Whitney non-parametric tests. We applied the Bonferroni correction to control for multiple comparisons and we accepted a value of $p=0.006$ as significant. For the FPT and DPT scores, results were only classified as normal or abnormal, as per the existing norms, and further analysis was deemed unnecessary, as it would not have added any further information, while it would have increased the risk of type I errors of the study.

RESULTS

We recruited eight right-handed subjects with a *PAX6* mutation (two male and six females, age range 30-57 years) and an equal number of age- and sex-matched right-handed controls. All subjects were of normal intelligence (Thompson et al., 2004).

Brain MRI

The anterior commissure was absent in five and hypoplastic in one subject. The corpus callosum mid-sagittal cross-sectional area was reduced in size in three subjects (Table 26).

Table 26. Brain MRI abnormalities and central auditory test findings in the PAX6 group. (from Bamiou et al 2004 ii)

Case	Age	Mutation	Anterior commissure	Corpus callosum	DDT	FPT	DPT	Drhy*	DCV*
4	30	Premature truncation- probably haploinsufficiency	absent	normal	norm	norm	norm	abn	abn
8	39	In-frame deletion (predicted non- functional protein)	absent	normal	norm	abn	abn	norm	norm
5	44	C terminal extension	present	normal	norm	abn	abn	norm	abn
2	40	C terminal extension	present	small	abn	abn	norm	abn	norm
1	53	C terminal extension	absent	normal	abn	abn	?	?	abn
6	35	Haploinsufficiency	small	normal	abn	norm	norm	abn	abn
3	57	Premature truncation- probably haploinsufficiency	absent	small	abn	norm	abn	abn	abn
7	43	C terminal extension	absent	small	abn	norm	abn	abn	abn

abn = abnormal, DDT = dichotic digits test, DCV = dichotic consonant vowels test, DPT = duration pattern tests, Drhy = dichotic rhyme test, FPT = frequency pattern test, norm = normal. ? = test not done.

* The CV test results are given as abnormal when the left ear score was lower than the minimum left ear score in the normal control group. Results in the Dichotic Rhyme test are given as abnormal when the right ear score is higher than the maximum right ear score in the normal control group.

Standard baseline audiometric tests

Pure tone audiometry, tympanometry and transient evoked otoacoustic emissions were bilaterally normal in all subjects and controls.

Central auditory tests.

Central auditory tests were normal in all controls. The results in subjects are summarized in Table 26.

Dichotic Digits Test (DDT)

All the *PAX6* subjects gave normal results in the right ear, while five gave abnormal results in the left ear. The left ear scores were significantly lower in the *PAX6* group (median 83%) than in the normal group (median 97%) at $p= 0.002$ (Figure 21), and this result remains significant after applying the Bonferroni correction.

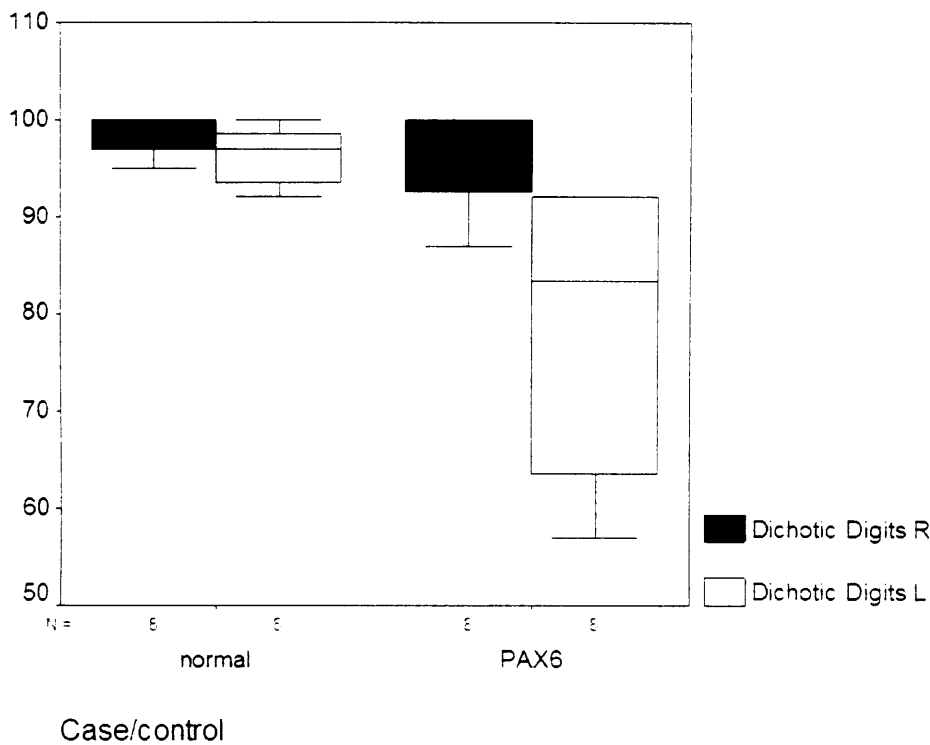


Figure 21. Boxplot of dichotic digits right and left ear scores in normal and in PAX6 subjects.

Dichotic CVs test

The right ear scores were comparable in the two groups (*PAX6* median: 44%, normal median: 43.5%). The left ear scores were significantly lower in the *PAX6* group (median 22%) than in the normal group (median 31.5%) at $p= 0.005$ (Figure 22), and this result remains significant after applying the Bonferroni correction. Five out of the eight *PAX6* subjects had left ear scores below the minimum value of the control group.

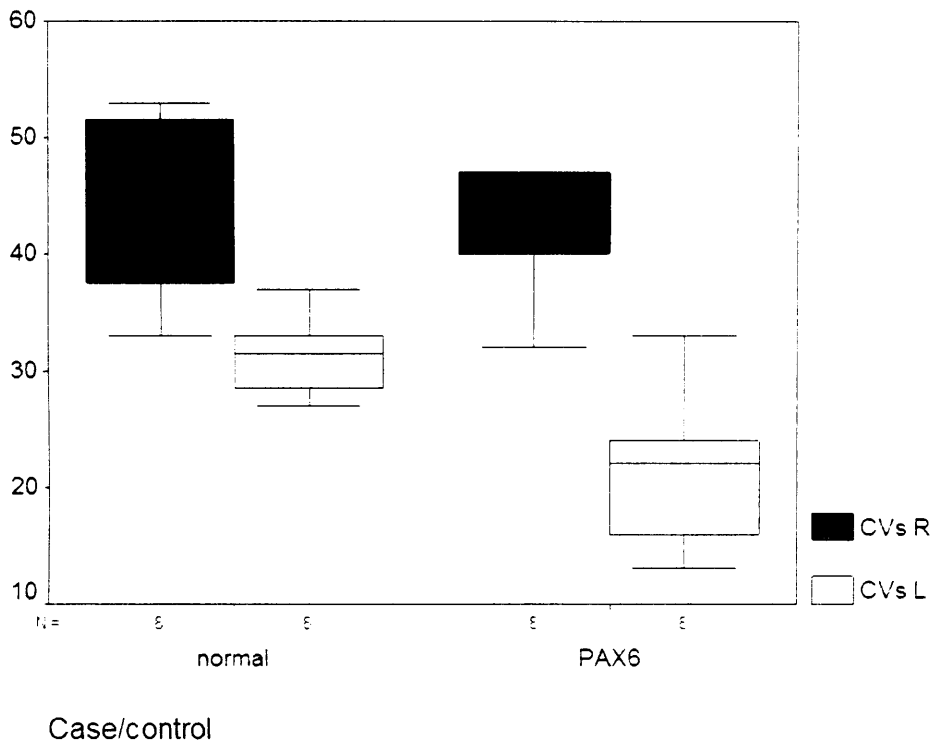


Figure 22. Boxplot of dichotic CVs right and left ear scores in normal and in PAX6 subjects.

Dichotic Rhyme test (Drhy)

The right ear mean score was significantly higher in the PAX6 group (median 56%) than in the normal group (median 47%) at $p= 0.021$, however this result does not remain significant after applying the Bonferroni correction. The left ear scores were slightly lower in the PAX6 group (median: 42%) than in the normal group (median: 47%) but this did not reach significance (Figure 23). Five out of the eight PAX6 subjects had right ear scores exceeding the maximum value of the control group.

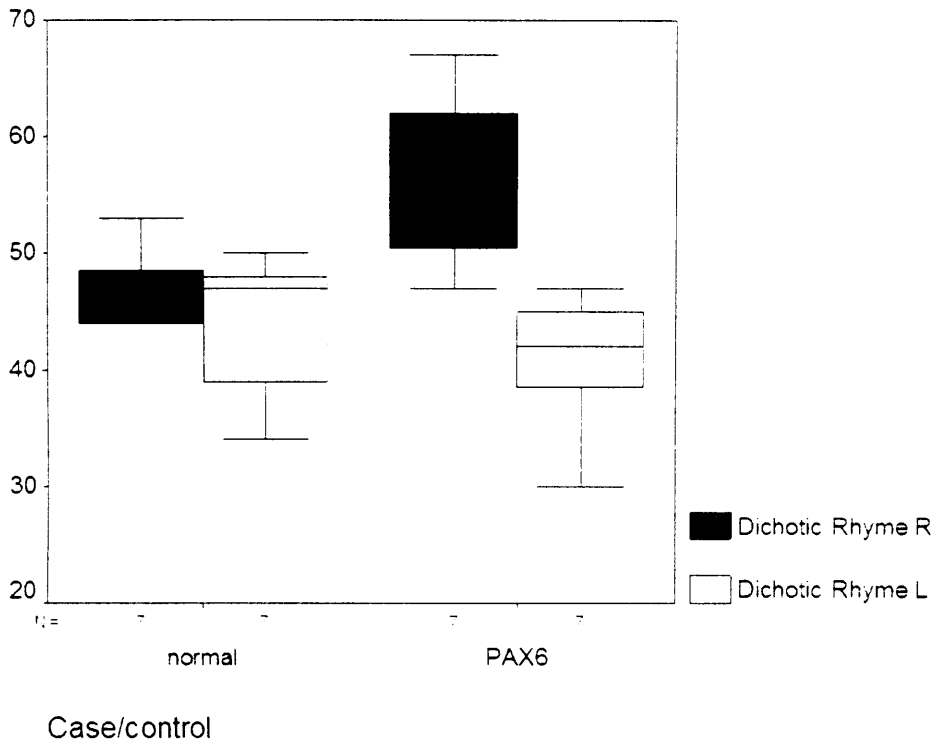


Figure 23. Boxplot of dichotic rhyme right and left ear scores in normal and in PAX6 subjects.

Frequency Pattern (FPT) and Duration Pattern (DPT) Tests

FPT scores were abnormal in five out of eight subjects and normal in all controls.

DPT scores were abnormal in four out of eight subjects and normal in all controls.

(Further statistical analysis was not conducted)

Gaps in noise test (GIN)

Only one subject gave abnormal thresholds and scores for the GIN in both ears (case 2). There was no difference in GIN thresholds or scores in either ear between the *PAX6* and the normal control group ($p>0.05$).

Table 26 shows the MRI and central auditory test results in the *PAX6* group. All the *PAX6* patients gave abnormal results in two or more of the central auditory tests.

DISCUSSION

Both as a group and on an individual patient basis, the *PAX6* patients were found to have a specific constellation of results in a central auditory test battery. This study expanded on our previous case report, which showed central auditory deficits in one subject with *PAX6* haploinsufficiency (Bamiou et al., 2004).

PAX6 mutations were associated with the absence or hypoplasia of the anterior commissure (AC) with corpus callosum which was present but in some cases smaller (CC) (Sisodiya et al., 2001). Both the AC and CC contain auditory interhemispheric fibres. The CC contains fibres that originated from the primary and second auditory cortices (Pandya and Seltzer 1986), and from other auditory responsive areas (Musiek 1986) in its caudal portion and splenium. The AC contains interhemispheric fibres from the mid portion of the superior temporal gyrus and the adjacent superior sulcus (Pandya and Seltzer 1986), two areas that are activated by auditory words, environmental sounds and music (Price et al., 2003; Poeppel et al., 2004; Bey et al., 2003).

The functional role of these interhemispheric connections has been examined in patients who had these pathways sectioned. Following complete callosotomy, subjects will typically show reduced to near extinct left ear performance in dichotic digits (Musiek and Reeves 1986) and CVs, with increased right ear performance in dichotic rhyme tests (Musiek et al., 1989) and bilaterally reduced scores in the frequency (Musiek and Reeves 1986) and duration pattern tests (Musiek et al., 1980), but with normal results in monaural speech tests (Musiek and Reeves 1986). These deficits are

specific for section of the posterior part of the corpus callosum and splenium (Musiek and Reeves, 1986; Sugishita et al., 1995), i.e. the parts that contain auditory fibres (Pandya and Seltzer 1986), while anterior section of the corpus callosum causes no such effects (Baran et al. 1986). These findings have been explained on the basis of the “callosal relay model” (Zaidel, 1986; see introduction for a review) which proposes that language perception takes place in the left hemisphere, and that in the dichotic situation, the contralateral pathway, which dominates in auditory signal transmission, takes over. Thus, in dichotic tests, speech stimuli from the left ear will be transmitted to the right (non-language) hemisphere and will require transfer via the interhemispheric commissures to the left hemisphere for linguistic processing.

We observed similar abnormalities to the “split-brain” in the *PAX6* group, albeit to a less severe degree. We explain these auditory deficits according to the “callosal relay model” (Zaidel, 1986). This model is supported by PET studies, which show bilateral temporal cortex activation for pitch and duration pattern analysis with similar bilateral neural network for both types of analysis (Griffiths et al., 1999). Results of psychoacoustic dichotic task experiments (Jäncke 2002) as well as functional MRI studies of dichotic tasks (Jäncke and Shah 2002) and functional connectivity studies (Quigley et al., 2003), seem to give further support to the callosal relay model.

However, according to the “direct access model” (Zaidel 1986), speech stimuli from the left ear will be directly analyzed in the right auditory cortex, albeit less efficiently than in the left cortex. In addition, complex dichotic speech tasks activate a wider network in each hemisphere than simpler tasks, and the dichotic test results may well reflect both the effects of interhemispheric transfer and of asymmetries in processing efficiency due to other “top-down” processes (Jäncke 2002; Jäncke and Shah, 2002; Pollman et al., 2002). In either case, it becomes evident that although deficient

interhemispheric transfer may not be the sole culprit. it is a significant component underlying these findings. Other alternative explanations for our findings would include the presence of auditory cortex or subcortical abnormalities. The *PAX6* gene is essential for differentiation and maintenance of cerebellar granule cells (Callaerts et al., 1997), and *PAX6* mutations are associated with MRI-documented grey matter changes in the cerebellum and occipital lobe, which are however non-auditory areas, while the brainstem, including the inferior colliculi and posterior commissure appear normal on MRI (Free et al., 2003). Polymicrogyria of the temporal cortex has also been reported in two of 24 patients with *PAX6* mutations (Mitchell et al., 2003b). However, none of our eight subjects had either polymicrogyria or any other auditory cortical or subcortical or brainstem abnormalities on MRI, and furthermore, the presence of normal results in the gaps in noise test and the lateralisation of the test findings (with left ear deficit on the dichotic tasks) would also argue against these possibilities. Abnormal results in the gaps in noise test were only observed in case 2, and in this case the presence of other subtle abnormalities of the auditory pathway, not detectable by MRI, could not be entirely excluded. With this exception, the constellation of test results in the other seven patients provides strong evidence for deficient auditory interhemispheric transfer, which could be attributed to structural and/or functional abnormalities of the AC and CC, although the exact contribution of these two formations to our findings remains unclear.

There are no previous reports on auditory interhemispheric transfer function in cases of congenital absence of the AC with a present CC, as this brain malformation is newly reported (Sisodiya et al., 2001). Callosal agenesis causes mild impairment of auditory interhemispheric transfer, probably due to development of alternative

pathways resulting from brain plasticity (Santhouse et al., 2003; Lessard et al., 2003). There is anecdotal evidence that hypertrophy of the AC may be associated with better functional compensation (Fischer et al., 1992), due to re-routing of some of the neuronal axons through the AC (Rauch and Jinkins 1994; Sarnat 1992). However, the AC is found to be enlarged in only 10% of Cases with callosal agenesis, and it is entirely absent in another 10% (Rauch and Jinkins 1994). In callosotomy Cases, it is unclear whether presence of an intact AC is associated with milder deficits (Fischer et al., 1992), or not (McKeever et al., 1981). On this basis, it would have been expected that the *PAX6* patients would exhibit only mild auditory abnormalities, as the CC was present (reduced in size in only three patients) and the AC would be expected to be of lesser importance in auditory interhemispheric transfer, due to its significantly smaller size, but also because it contains fibres originating from less differentiated cortical areas (Cipolloni and Pandya 1985). In addition, because these structural abnormalities are developmental, functional compensation may be expected to occur, due to brain plasticity. However, the *PAX6* patients showed abnormalities that varied from severe, with abnormal results in four out of five tests (e.g. Cases 3 and 7) to mild, with abnormal results in two out of five tests (Cases 4 and 8). Cases 3 and 7 had the most severe structural abnormalities in the group, with both an absent AC and a hypoplastic CC, and it is possible that the brain's potential for plasticity or compensation was reduced. In Case 4, the youngest in the group, the milder deficits could be attributed to the normal callosal area. The sample was too small to differentially assess the effects of severity of each malformation on the results. In addition, the presence of deficits in Case 5 could indicate the presence of abnormalities on a functional as opposed to structural level, as the AC was present and the callosal area was also normal. Also, *PAX6* mutation might lead to cortical reorganisation that has no obvious

MRI appearance (Free et al., 2003). Other factors, such as individual strategies and top-down processes, or age (Jerger et al., 1995), may have influenced the central auditory test results.

In conclusion, we found a specific constellation of central auditory findings in a group of patients with *PAX6* mutations, which provide evidence for decreased auditory interhemispheric transfer. This decrease could be attributed to the presence of congenital structural, and possibly, functional abnormalities of the auditory interhemispheric pathways and to reduced capacity for plasticity or compensation of the brain. Further studies of these patients would add to our understanding of the function of the commissural pathways of the brain and of the profile resulting from commissural pathway dysgenesis. Our unique findings broaden the possible role of *PAX6* to include higher order roles not only in visual and olfactory sensory domains, but also in auditory processing, and may have implications for education in these subjects.

8. STUDY 4. AUDITORY INTERHEMISPHERIC TRANSFER, BRAIN MRI FINDINGS, PARENT-REPORTED HEARING DIFFICULTIES AND THEIR RELATIONSHIP IN CHILDREN WITH *PAX6* MUTATIONS

INTRODUCTION

Our previous studies in adults with a *PAX6* mutation (Bamiou et al. 2004 a and b) suggested the presence of auditory processing deficits in the form of impaired auditory interhemispheric transfer. However, there was no information about the presence or not and the nature of auditory processing deficits in the paediatric population, and no previous MRI study of the brain abnormalities associated with *PAX6* mutations. The presence of auditory processing deficits in children bearing *PAX6* mutation might have implications for their management, particularly in the classroom, as they already have visual disability.

The aims of this study were

- a. to assess whether auditory interhemispheric transfer is also impaired in children with *PAX6* mutations, similar to adults,
- b. to assess for the presence of abnormalities on magnetic resonance imaging (MRI) of the brain and
- c. to assess for parent-reported hearing difficulties in these children and
- d. to investigate the relationship between a, b and c.

SUBJECTS

We recruited 11 case subjects (4 males, 6 females) who attended the Ophthalmology clinic at Great Ormond Street Hospital for their visual difficulties. We also recruited an equal number of normal controls with normal hearing thresholds from children of all grades of hospital staff, who were matched to the subjects for age, sex, and handedness.

METHODS

All subjects (cases and controls) had

- a. a structured clinical questionnaire (APPENDIX B),
- b. standard baseline audiometric tests (pure tone audiometry, tympanometry and transient evoked otoacoustic emissions)
- c. central auditory tests (dichotic digits, rhyme and consonant-vowels (CVs), frequency and duration pattern and the gaps-in-noise test).

In addition, case subjects had brain MRI with volumetry. Comparable MRI scans from an equal number of age and sex-matched normal controls randomly selected from the Radiology and Physics Unit database of normal subjects were used for comparison as controls. Genetic testing was undertaken for identification of the mutation, if this was not already known.

STATISTICAL ANALYSIS

The results were analyzed with SPSS, version 12.0. We used Mann-Whitney non-parametric tests to examine differences in test scores (only for the tests without

normative data, i.e. the dichotic CVs and dichotic rhyme tests), corpus callosum cross-sectional area and questionnaire scores between the *PAX6* and the normal control group. Linear regression analysis was performed to assess the relationship between question scores and test results in the entire group.

RESULTS

Genetic testing

Genetic mutation testing was performed (by VvH) (see Table 27). There are 5 major known subgroups of pathological alterations of *PAX6* (Mitchell et al., 2003b; Human *PAX6* Allelic Variant Database Web Site)

- a. Haploinsufficiency: intragenic mutation leading to a truncated or absent *PAX6* protein: 6 children (cases 1.1 and 1.2, 5.1, 7.1, 7.2 and 8)
- b. in-frame deletion due to a splicing error – 1 child (4.1)
- c. mutation causing predicted C-terminal protein extension – 1 child (2.1)
- d. missense mutation – 3 children (cases 3.1 and 3.2, 6.1)
- e. deletion of the entire gene - not found in any of the children in this cohort.

Table 27. Summary of mutation, brain MRI and main central auditory test findings in the children with *PAX6* mutations and their affected parent. (from

Bamiou et al., 2007 ii)

* All cases with asterisks are parents of children recruited to this study. Cases 1, 2 were reported in Bamiou et al., 2004 b, cases 3, 4 and 6 were subsequently tested under a separate Ethics to this study while case 5 was scanned and included in Sisodiya et al., 2001.

A= abnormal, AC = anterior commissure, CC= corpus callosum, DDT = dichotic digits test, DPT = duration pattern tests, F= female, FPT = frequency pattern test, GiN = gaps in noise test. M = male, N = normal, NT = not tested, post = posterior.

Name	Sex	Age	Family	Mutation	Brain MRI	DDT	FPT	DPT	GiN
1*	F	35	Mother of 1.1 and 1.2	Haplo-insufficiency R240X	small AC normal CC	A	N	N	N
1.1	M	12	Son of 1	Haplo-insufficiency	normal	A	A	A	N
1.2	F	7	Daughter of 1	Haplo-insufficiency	small splenium	A	A	A	N
2*	F	44	Mother of 2.1	C terminal extension X432L	normal	N	A	A	N
2.1	F	16	Daughter of 2	C terminal extension	small AC	N	A	A	N
3*	M	50	Father of 3.1 3.2	missence K55R	cyst beneath striatum	A	N	N	N
3.1	F	14	Daughter of 3	missence	cyst in splenium	A	N	A	N
3.2	M	17	Son of 3	missence	small AC small post CC	N	N	N	N
4*	M	33	Father of 4.1	Splicing mutation	normal	N	N	N	N
4.1	F	10	Daughter of 4	Splicing mutation	small AC small post CC	A	A	A	N
5*	F	29	Mother of 5.1	Frameshift C478insCC (haplo-insufficiency)	absent AC	NT	NT	NT	NT
5.1	M	10	Son of 5	Frameshift C478insCC (haplo-insufficiency)	small AC small splenium	A	A	A	N
6*	F	54	Mother of 6.1	missence G36R	NT	A	A	A	A
6.1	F	16	Daughter of 6	missence	small AC	N	A	A	N
7.1	F	14	Sister of 7.2	Antistart missence (haplo-insufficiency)	small AC	A	A	A	N
7.2	F	11	Sister of 7.1	Antistart missence (haplo-insufficiency)	small AC	A	A	A	A
8	M	13		Inversion of chromosome 11 (haplo-insufficiency)	NT	N	N	A	N

Brain MRI findings

Structural brain MRI was conducted in 10/11 cases and visually inspected and reported upon by an experienced Consultant Paediatric Radiologist (Dr Kling Chong). The anterior commissure was small in seven and normal in three children. The corpus callosum was reported to be small compared to controls in four and normal in five children, while there was a cyst in the splenium of the corpus callosum in one child (see Table 27 for individual results). Overall, the brain MRI was reported as completely normal in one child only (Figure 24).

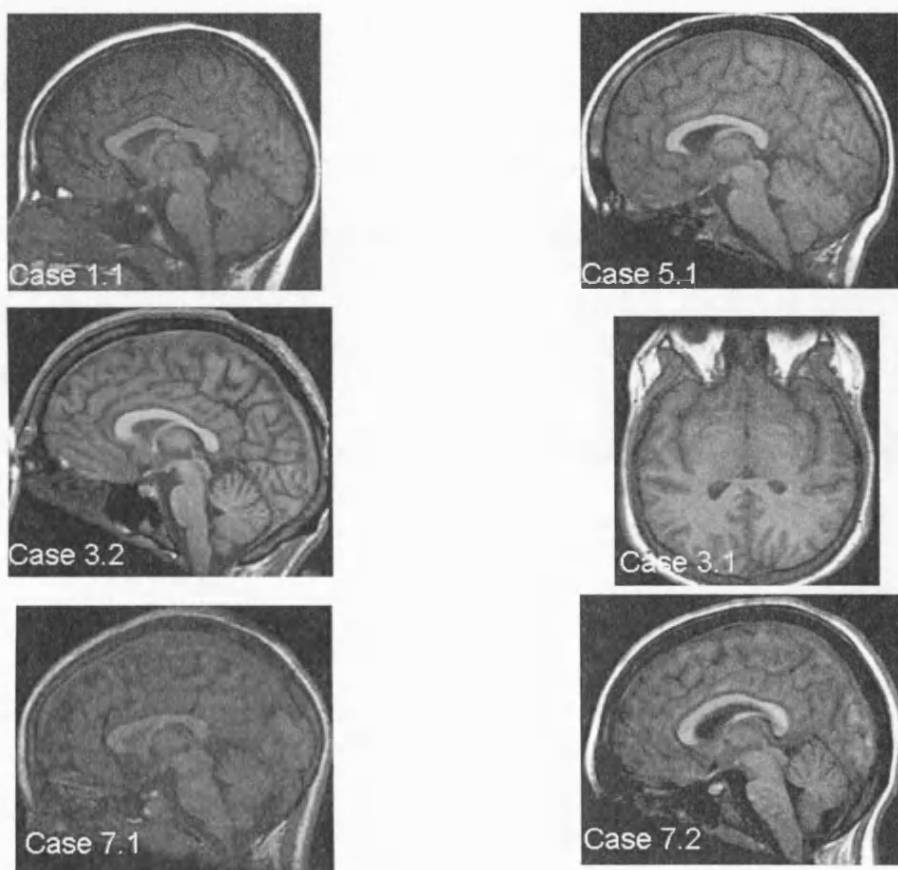


Figure 24. Brain MRI of cases 1.1, 3.1, 3.2, 5.1, 7.1 and 7.2

Brain volumetry to measure the corpus callosum area (CCA) was conducted in nine cases and compared to the CCA of nine randomly-chosen age-matched controls by Dr Samantha Free (who was blinded to the status of the child as a case or a control). The CCA was significantly smaller in the *PAX6* group. $P = 0.024$ (Mann Whitney test).

Standard baseline audiometric tests

All case and control subjects had normal tympanograms, otoacoustic emissions and pure tone audiograms.

Central auditory test results

Central auditory tests were normal in all controls. The results in subjects are summarized in Table 27. Only one child gave normal results in all the central auditory tests.

Dichotic Digits Test

All the *PAX6* subjects gave normal results in the right ear, while seven gave abnormal results in the left ear.

Dichotic CVs test

There was no significant difference in right or left ear scores in the two groups.

Dichotic Rhyme test

There was no significant difference in right ear scores in the two groups. The left ear score was lower in the *PAX6* group at $p=0.043$ (Mann-Whitney).

Frequency pattern test

Eight out of 11 case subjects gave abnormal results.

Duration pattern test

Ten out of 11 case subjects gave abnormal results.

Gaps in noise test

All case children but 1 gave normal results.

Questionnaire results

Questionnaire results were obtained from nine cases and nine controls. The results are summarised in Table 28. The *PAX6* group had a significantly lower score (denoting greater difficulty) for understanding speech in noise ($p=0.031$) and for localising sounds ($p=0.031$).

Table 28. Questionnaire results in children with *PAX6* mutations and in controls.

Questionnaire vs. auditory test results

Question	Answer				
		No difficulties	Some difficulties		
		Almost always (0 points)	Frequently (1 point)	Occasionally (2 points)	Almost never (3 points)
understand speech in quiet	Case	6	3	0	0
	Control	9	0	0	0
understand speech in noise	Case	3	3	2	1
	Control	8	1	0	0
understand feeling by tone of voice	Case	5	2	2	0
	Control	8	1	0	0
Understand intonation and voice inflection	Case	4	3	2	0
	Control	8	1	0	0
“get a joke” as well as his peers	Case	4	4	1	0
	Control	8	1	0	0

tell where a sound is coming from	Case	3	0	6	0
	Control	7	2	0	0

Linear regression analysis indicated that the left, but not the right, dichotic digits score correlated with the reported speech-in-noise difficulties (R square = 0.371, p= 0.007).

Both the right and left frequency pattern scores correlated with the intonation/inflexion difficulties (with R square = 0.308, p=0.017 for the right and R square = 0.375, p=0.004 for the left frequency pattern scores).

DISCUSSION

This is the first report of auditory processing test deficits and associated auditory difficulties in the presence of normal hearing thresholds and of structural abnormalities of the auditory interhemispheric pathway on brain MRI in children with *PAX6* mutations. In view of the additional visual disability associated with *PAX6* mutations, our findings have implications for the management of these children, particularly in the classroom.

In adult humans, *PAX6* mutations are associated with structural abnormalities of the interhemispheric pathway, with an absent or hypoplastic anterior commissure and a present but in some cases smaller corpus callosum (Sisodiya et al., 2001). Both these structures contain auditory interhemispheric fibres (Pandya and Seltzer, 1986). In this paediatric study of *PAX6*, the main structural findings on brain MRI were a smaller anterior commissure and corpus callosum cross-sectional area than normal controls. The corpus callosum findings are similar to the brain MRI abnormalities which are reported in adults (Sisodiya et al., 2002; Free et al., 2003; Ellison Wright et al., 2004). Sisodiya et al (2001) reported reduced total grey and white matter volumes, and reduced callosal area in 14 adults with a *PAX6* mutation. Ellison-Wright et al. (2004) similarly reported white matter deficits in anterior and posterior corpus callosum in seven affected family members of a family with a *PAX6* mutation, compared to normal subjects. Free et al (2003) found significantly reduced mean callosal cross-sectional area in adult subjects with congenital aniridia than in normal controls. In addition, they reported increases in grey matter concentration below the splenium of the corpus callosum and below and

slightly anterior to the genu of the corpus callosum in the patients with a C-terminal extension mutation, and changes below the splenium only for the patients with haploinsufficiency.

There are some differences between the paediatric and the adult cases brain MRIs. In this paediatric sample, the anterior commissure was present in 10/10 scanned cases, but was reported to be smaller than normal in seven cases. In the series by Sisodiya et al. (2001) the anterior commissure was present only in 4/14 adult cases, while Free et al (2003), reporting the original 14 (Sisodiya et al. 2001) and an additional 10 cases, found the anterior commissure to be present in only 9/24 scanned adults with a *PAX6* mutation. It is difficult to interpret the significance of this difference in findings of the paediatric and adult studies, in view of the small sample size of these studies. The differential effect of different mutations on presence or absence of the anterior commissure needs to be considered. So far no obvious genotype-phenotype correlations have been noted. It has been proposed that *PAX6* may have a maintenance function in the adult eye (van Heyningen and Williamson 2002), thus the effect of age and the possibility of age-related-degeneration of the interhemispheric structures should also be considered in a bigger, prospective, pedigree study.

The constellation of auditory test abnormalities in the 11 children with *PAX6* mutations, i.e. the reduced left ear score in the dichotic digits test, bilaterally reduced scores in frequency and duration pattern tests and normal gaps in noise test is consistent with our findings in adults with *PAX6* mutations and very similar, albeit less severe, to the test

findings in patients with posterior section of the corpus callosum and splenium (Musiek and Reeves, 1986; Sugishita et al., 1995). There were some subtle difficulties between test findings in children vs. adults with *PAX6* mutations, in that as a group, children showed a reduced left ear score in the dichotic rhyme test with no significant differences in right or left scores of the dichotic CVs test compared to age-matched controls, while adults showed a significantly reduced left ear score in dichotic CVs but no significant differences in right or left scores of the dichotic rhyme test compared to normal controls. It is not clear whether this difference in findings is due to the small numbers in both the paediatric and the adult samples, to the difference in brain MRI findings, or to other age – related or developmental changes of the interhemispheric pathway.

There were some limitations in this study, in that we did not conduct any formal psychometric measures, thus the effect of the IQ on the test results remains unknown. However, there were no concerns regarding a low IQ for any of these children expressed by the parents or their educational environment, and all children were in mainstream education. Moreover, a study in adults with *PAX6* mutations (Thompson et al, 2004) did not find any cognitive deficits compared to normal controls. A further limitation was that we did not examine the effect of any top-down processes, such as attention, on the test results. Furthermore, the number of cases was too small to make inferences about genotype-phenotype associations, or structural brain abnormalities and test findings. Notwithstanding these limitations, the auditory processing deficits found in children with *PAX6* mutations as a group are broadly similar to what has previously been reported in adults, and are indicative of reduced interhemispheric transfer.

It is interesting to compare our results with cases of congenital aplasia of the interhemispheric pathway. Subjects with callosal agenesis, with or without an anterior commissure, may suffer from a range of central auditory deficits, that include deficient phonological processing as shown on rhyming tasks (Temple et al., 1990), impaired sound localization (Lepore et al., 1994) and dichotic speech test abnormalities with small but reliable ear asymmetries (Santhouse et al., 2002; Lessard et al., 2002; Sauerwein et al., 1994). These auditory deficits are associated with educational difficulties (Temple et al., 1990; Jacobson and Jeeves, 1994), in the absence of a close correlation between the auditory deficits and the subjects' IQ (Temple and Ilsey, 1994). Congenital aplasia or early life damage of the corpus callosum causes mild impairment of auditory interhemispheric transfer, and this is probably due to development of alternative pathways resulting from brain plasticity (Santhouse et al., 2002; Lessard et al., 2002). These reports are broadly consistent with our findings.

The finding of deficient auditory interhemispheric transfer in these children may explain their parent-reported difficulties with sound localization (Lessard et al., 2002). It has been postulated that the interhemispheric pathway may contribute to sound localization by facilitating the interhemispheric integration of binaural inputs. Acallosal subjects are reported to be less accurate than controls in localizing both fixed (Poirier et al., 1993) and moving sounds (Lessard et al., 2002), while there is no information on how the duration of the sound affects performance. The deficient auditory interhemispheric transfer may similarly underline their parent-reported difficulties of understanding speech in noise.

Processing of speech in background noise appears to activate both hemispheres (Scott et al, 2004). Oral language comprehension requires integration of semantic/syntactic information (processed in the left hemisphere) with prosodic information (processed in the right hemisphere) by means of dynamic interactions between the two hemispheres, which are thought to be subserved by the corpus callosum (Friederici and Alter, 2004). Presentation of oral language in noise may increase the complexity of this task.

Interhemispheric interaction may, in this case, help increase the brain's processing capacity, by dividing the processing demands of the complex auditory task between the two hemispheres, in order to make maximum use of hemispheric specialization and also to facilitate processing of information in parallel (Passarotti et al, 2002). In addition to optimizing the sensory processing by these mechanisms, the interhemispheric pathway may also enhance the processing efficiency of the brain by its effect on a top-down executive function, i.e. attention (Banich 1998). The left ear deficit in the dichotic digits test may thus be an indirect measure of the speech in speech competition difficulties, consistent with our finding that the left ear dichotic digit test score correlated with the parent-reported speech-in-noise difficulties.

More than half of the children with *PAX6* mutations were also reported to have problems understanding prosody, although the difference between the *PAX6* and normal control groups was not significant. Patients with agenesis of the corpus callosum are reported to have difficulties with the pragmatic aspects of language, in that they may interpret speech very literally or misinterpret the meaning of non-literal expressions such as idioms (Jeeves & Temple, 1987; O'Brien, 1994; Paul et al, 2003). The integration of syntactic

and prosodic information which underpins comprehension of oral language is attributed to dynamic interactions between the two hemispheres and thought to be subserved by the corpus callosum (Friedericci and Alter, 2004). We found that difficulties with prosody correlated with reduced frequency pattern test scores, and this test may be an indirect (but not the only) measure for such difficulties in these children.

In conclusion, we have demonstrated the presence of auditory processing deficits indicative of reduced auditory interhemispheric transfer, and reported difficulties with understanding of speech in noise and localization of sounds in children with congenital aniridia due to a *PAX6* mutation, in the presence of a normal audiogram and of MRI-documented abnormalities of the interhemispheric pathway in the brain. The combined effect of auditory and visual difficulties may result in significant handicap for these children, particularly in the classroom. Thorough audiological evaluation of these children is indicated, in order to initiate appropriate management, in the form of auditory training as well as environmental modifications (Bamiou et al, 2006). Further research is needed to assess how the auditory deficits impact on academic performance in children with *PAX6* and what is the best management to improve academic performance as well as communication in these children.

STUDY 4. ADDENDUM

Case 1.1 was seen in the Audiology clinic, as a formal referral, to assess for the presence of central auditory deficits. He had been complaining of hearing difficulties. However, repeated pure tone audiograms had been entirely normal. His mother reported that his early speech and language development was within normal limits and described him as an “eloquent” speaker. She also reported good performance in the additional languages he was taking as subjects at school, viz. German and French. The boy was receiving special needs support at school, due to his visual impairment, and was academically at the top-level of performance in his class.

He was reported to have:

- a. Difficulties with hearing speech in a noisy environment, such as the classroom and the gym.
- b. Difficulties with localization of the source of a sound.
- c. Difficulties with interpreting emotion from the tone of voice inflection, e.g. the mother reported that he would frequently think she was angry with him, when she was not.
- d. A literal understanding of jokes and difficulty understanding the punch line of the joke.
- e. Difficulties with remembering information and instructions presented verbally, and some difficulty with organizational skills.

These difficulties were causing him considerable frustration, particularly in the classroom.

In addition to the brain MRI and the central auditory tests (as reported in the previous section), he underwent a speech and language assessment, which was conducted by Dr Nicci Campbell.

This assessment comprised of a rating scale and selected subtests from the **Clinical Evaluation of Language Function - Fourth Edition (CELF 4)**, 2006, which were administered and scored in accordance to the administration procedures stipulated in the CELF 4 test manual. The following scale and subtests were administered:

The **Observational Rating scale** comprises of four sections, namely 'Listening', 'Speaking', 'Reading' and 'Writing' and provides functional information on strengths and difficulties in these areas as experienced in the classroom and at home. This scale was completed during the interview with the mother.

The **Word Classes 2 subtest** comprises of 24 test items. Each item has four words. The child is asked to identify the two words that are related (receptive language) and then to describe how they are related (expressive language).

The **Understanding Spoken Paragraphs subtest** comprises of 3 separate paragraphs. The child is required to respond to the questions about each of the paragraphs, which are presented orally by the examiner. There are 5 questions about each paragraph. The

questions target the paragraph's main idea, details, sequencing, and inferential and predictive information.

The **Phonological Awareness Subtest** consists of 85 test items grouped into 17 components of phonological awareness. The child is required to rhyme words and segments, blends, and identify sounds and syllables in words.

The **Number Repetition subtest**, which assesses verbal working memory, consists of two sections, namely Forwards Repetition (8 items) and Backwards Repetition (7 items). The child is required to repeat sequences of numbers (forwards and backwards). The sequences become progressively longer.

Speech and language assessment results

The **Observational Rating Scale** (Table 29) identified that C has difficulty hearing in noisy listening environments, subtle difficulty with understanding prosodic aspects of speech, some problems with organizational skills (forgetting what people have said, leaving things behind and difficulty remembering and planning around deadlines) as well as occasional disfluency in his speech, when under pressure. C's speech and language abilities were, however, reported to be age-appropriate.

C presented with age-appropriate results (Table 29) in the **Word Classes 2, Understanding Spoken Paragraphs** and **Phonological Awareness subtests** of the **CELF 4**. These results thus showed that C's receptive and expressive language,

phonological awareness and understanding and recall of spoken paragraphs are age-appropriate.

His results (Table 29) on the **Number Repetition subtest** were below age level. An age equivalent score of ± 6.6 was obtained for the **Number Repetition Forwards Section** and $\pm 7:11$ for the **Number Repetition Backwards Section**. These results showed impaired verbal working memory abilities.

Table 29. Speech, language and working/auditory memory test results in case 1.1

(from Bamiou et al., 2007 i)

CELF 4 scale/subtest	Results
Observational Rating Scale	Listening: - Difficulty hearing in noisy environments - Some difficulty with prosodic aspects of speech, i.e. jokes
	Speaking - No articulation problems - Occasional disfluency in speech, when under pressure
	Reading - No difficulties reported
	Writing - No difficulties reported
Word classes 2	Receptive score: - Raw score: 21 - Age equivalent : >16:11*
	Expressive score: - Raw score: 21 - Age equivalent : >16:11*
Understanding Spoken Paragraphs	Raw score: 15/15 (C obtained the maximum possible score. The CELF 4 does not provide an age equivalent score for this subtest.)

Phonological awareness	Raw score: 81/85 Age equivalent: > 11:00 (the maximum age equivalent score provided)
Number repetition	Number repetition forwards: - Raw score: 7 - Age equivalent: ± 6:6*
	Number repetition backwards: - Raw score: 4 - Age equivalent: ± 7:11*
	Number repetition total: - Raw score: 11 - Age equivalent: ± 7:3*

* Age equivalent scores presented in years:months

MANAGEMENT

It was recommended that case 1.1 (C) continue to receive special needs support at school, due to his visual impairment. It was further recommended that a personal FM assistive listening device be made available to C in the classroom, to address his speech in noise difficulties, and informal auditory training (speech in background competing signal training and the Simon game, Bamiou et al., 2006) was also recommended. He successfully used the FM system for 12 months, but later rejected it due to age-related and cosmetic concerns. Environmental modifications including preferential seating were thus recommended. Additional support to improve his verbal working memory and

organisational skills was recommended (i.e. whole body listening techniques, self-instruction and -regulation, recording information in pictorial form, mnemonic devices, mind-mapping and study skills, use of a diary, planning around and prioritizing deadlines).

COMMENTS

This case highlights yet again the need for thorough audiological evaluation of the patient who complains of hearing difficulties in the presence of a normal audiogram, as pure tone audiograms rarely reflect dysfunction of higher auditory pathways, while the brain MRI frequently does not show an anatomical correlate to auditory processing deficits. The central auditory profile in C was similar to that reported in adults, and to the other children in the paediatric group. These findings indicate that central auditory deficits may exist across the developmental range in individuals with *PAX6* mutations. The finding of a verbal working memory deficit corroborates earlier studies in adults (Thompson et al., 2004) and warrants further investigation in the paediatric population. Further research is also needed to assess how the auditory deficits associated with a *PAX6* mutation impact on academic performance particularly in childhood, and what are the best means of intervention.

9. DISCUSSION AND CONCLUSIONS

The work presented in this thesis has investigated structure versus function of the central auditory nervous system (CANS) a. by utilizing the lesion study approach, i.e. by studying patients with known lesions of the central auditory pathway and b. by means of a central auditory test battery, with validated tests of known sensitivity and specificity in identifying deficient central auditory function.

The lesion study approach has certain unique advantages, in that:

- a. It may help establish whether a brain region is *necessary* for a specific auditory function, as opposed to simply being part of the network which subserves this function, and may thus help test the assumptions which are made regarding central auditory function on the basis of fMRI/PET and other such studies findings, in a more clinical context.
- b. Findings from lesion studies regarding auditory processing may be more appropriate to generalize to the broad population, than findings from “symptom-led” studies, since the subject recruitment is less biased in the former than in the latter.
- c. In addition, lesion studies may help understand the all-important relationship between auditory test deficits and patient reported disability.

However, lesion studies may also have some inherent limitations. These include:

- a. “Pure” lesions affecting only the area of interest may be rare, either because localized lesions of this specific area are very rare, or because the nature of the lesion is such that sub-structural changes may also exist.
- b. The lesion may well be more extensive than the area depicted on the standard brain MRI.
- c. The lesion may impact on the function of other top-down modalities, which may affect performance in the central auditory tests.
- d. The lesion itself, or the underlying cause for the lesion (e.g. stroke) may affect peripheral hearing function, and this needs to be taken into account in the interpretation of the central auditory test findings.

Nevertheless, at present, the lesion study approach is the only approach that may help us understand the clinical perspective of central auditory function (and dis-function) in human subjects, both as a group and on an individual basis.

This concluding chapter will highlight the main findings of this thesis, and will discuss these in the light of previous studies. The main conclusions of the thesis will be presented as a series of statements, and the need for further research will be outlined.

more extensive lesions of the CANS than the insula, may indicate that the insula is crucial for temporal resolution. Similarly, the abnormalities in the DPT and FPT may also indicate that the insula is vital for auditory patterns discrimination, as previously reported in animal studies (Collavita et al., 1974). Of interest, all three patients with relatively “pure” insula lesions, as well as another three of the remaining cases, complained of difficulties with rhythm perception, or with understanding text that is being sung. It has been previously suggested that the insula may be involved in musical processing (Fifer 1993; Platel et al., 1997). However, musical processing was not assessed in the study, and thus this issue would need to be addressed by a subsequent study.

Another interesting, albeit preliminary finding from this study was that frequency pattern test scores were better in lesions that spared the anterior insula, than in lesions which also involved the anterior insula. However, in view of the small number of cases, as well as of the different lesion extent in each case, the significance of this finding remains unclear.

The posterior part of the insula mainly receives afferents from the thalamus and has a staining profile of a primary sensory area, and may thus be involved in basic, important auditory processing (e.g., Hyman and Tranel, 1989). In contrast, the anterior insula, which has an intermediate profile between a primary sensory area and a high order association area, may be more involved in integration of auditory information with other associative functions (e.g., Bushara et al., 2001; Lewis et al., 2000). However, the contributing roles of different parts within the insula to audition need also be assessed in a future study.

A broader point of interest, when looking at the group results, was the dissociation in findings between the frequency and the duration pattern test results in this patient sample. This highlights the need to include different tests within the same central auditory test category in order to investigate suspected auditory processing disorders, both in the neurological as well as in the “normal” population.

B. Patients with unilateral focal ischemic lesions of the central auditory pathway report difficulty with a broad range of auditory skills.

In study 2, the 20 subjects with an acute onset unilateral lesion of the central auditory pathway and a confirmed lesion of the CANS on the brain MRI were assessed by means of a validated hearing questionnaire as well as by a validated central auditory test battery. As a group, these subjects reported significantly greater difficulty with detection as well as distinction of sounds, intelligibility of speech in noise, as well as in quiet, and localization of sound than age- and hearing- matched normal controls. The present findings highlight the auditory disability suffered by patients with acquired CANS lesions. It has long been known that these patients may suffer from auditory complaints (Bocca, Calero and Cassinari, 1954), and there are several single case studies describing the auditory test deficits and their relationship with site of lesion (e.g., Musiek, Baran, Pinheiro, 1990). However, very few studies have systematically assessed the hearing disability in patients with defined CANS lesions. In general, hearing complaints in

patients with acquired lesions of the central auditory pathway, e.g., after vascular events, may often be overlooked in the presence of other life threatening symptoms or more obvious chronic disablements. And despite the fact that these patients may not spontaneously report any hearing complaints, they will report auditory perceptual problems, when questioned in detail, e.g., by means of a questionnaire (Blattner et al., 1989). The present findings highlight the need for clinicians who are involved in the clinical care of these patients to elicit specific auditory symptoms regarding hearing abilities, as these may need to be taken into account when formulating the long term rehabilitation plan for these patients, who may suffer multiple handicaps.

In addition, the findings of this study underline the need for clinicians to appreciate that patient-reported auditory difficulties are not necessarily always due to a peripheral hearing impairment. In some rare cases, hearing difficulties in the presence of a normal audiogram may be the sole or the presenting symptom of neurological disease (Bamiou, Musiek, Jones et al., 2004). In these cases, identification of the central auditory deficits may lead to further investigation which will eventually lead to the diagnosis of the neurological disease.

However, central auditory test deficits and auditory disability may also be due to sub-structural abnormalities of the brain (e.g., Bamiou, Musiek, Sisodiya et al., 2004). It is thus important to appreciate that the presence of a normal audiogram and even a normal brain MRI are not sufficient to dismiss the patient who presents to the clinic with

auditory complaints as having “normal” hearing, as testing of the CANS may identify deficits.

Study 2 provided some further insight into the relationship between the psychoacoustic deficit and the patient-reported symptoms. Previous studies indicate that patients with abnormal psychoacoustic test results are more likely to report auditory perceptual problems (Blattner et al., 1989). This study indicated that some particular auditory complaints may correlate with specific test deficits. For example, patients with reduced left or bilateral ear score in the dichotic digits test had more problems with intelligibility of speech in noise than those with bilaterally normal dichotic digits test scores. The gaps in noise test results similarly correlated both with a reported difficulty with understanding speech in background noise and with the distinction of sound. These findings may be of relevance both for the neurological and the normal population with APD. Thus, this reported correlation between test deficits and patient complaints may help inform the explanation given to the patient regarding the cause for their auditory complaints on the basis of the clinical test findings. These findings may also help in the choice of appropriate central auditory tests for each individual patient in the light of patient reported symptoms. In addition, a better understanding of the correlation between test deficits and patient complaints may help inform the management plan of these patients.

This study also helped identify some areas that require further research. There is a great need for more extensive questionnaire instruments to evaluate auditory perception in both normal and neurological subjects. For example, hyperacusis and appreciation of music

were not assessed by the instrument used in this study, and they can be frequent complaints in the overall APD population. Additional points that would need to be addressed in a future study of auditory disability after CANS lesions may include:

- a. The effect of other top-down factors on both test deficits and patient reported disabilities. A study incorporating speech and language and cognitive assessments in the test battery would be required to address this issue.
- b. The exact type of central auditory deficit (e.g., temporal resolution, frequency modulation) within the broad category of auditory process affected (e.g., temporal). A study utilising central auditory tests that are more specific for the deficit, although overall they may be less sensitive for the identification of APD, would be required for this purpose.
- c. The effect of different types of lesions on specific auditory processes. This study would require more subjects, than the present one, and use of an “overlap” technique for comparison of lesions and test deficits between the subjects versus the descriptive approach used in this present study.
- d. The appropriate management for these patients. Recent studies have established that auditory learning may take place throughout life (e.g., Amitay et al., 2005), while auditory training may be of benefit in paediatric case with APD (see Bamiou, Campbell, Sirimanna 2006 for a review). In addition, there are other strategies, e.g., environmental modifications or employment of other top-down strategies, which may be beneficial for these patients (Bamiou, Campbell,

Sirimanna 2006) No study has up to now assessed what is the best way to address the hearing needs of patients with acquired APD due to a CANS lesion.

C. Congenital structural and/or functional abnormalities of the anterior commissure and corpus callosum due to a *PAX6* mutation are associated with deficient auditory interhemispheric transfer, which persists into adulthood.

Study 3 assessed central auditory function in 8 adult patients with a *PAX6* mutation. The central auditory test in the *PAX6* group were similar, albeit less severe to the test abnormalities observed in the “split-brain” population, with normal results in the monaural test which does not require callosal transfer (gaps- in- noise test) and with abnormal results in the dichotic speech and/or pattern tests, which require callosal transfer, in all eight patients. These auditory deficits were explained according to the “callosal relay model” theory (Zaidel, 1986). This model is based on the assumptions that language perception takes place in the left hemisphere and that the contralateral pathway dominates in auditory signal transmission and takes over in the dichotic situation. Thus, these findings would indicate the presence of decreased interhemispheric transfer in this patient sample. This was the first time that such deficits had been reported in the *PAX6* population. And although the study did not assess cognitive function, subjects with a *PAX6* mutation are reported to have normal intelligence (Thompson et al., 2004). This auditory interhemispheric transfer decrease was thus a novel finding in this population, which was attributed to the presence of congenital structural and possibly functional

abnormalities of the auditory interhemispheric pathways, as had been previously reported in this population (Sisodiya et al., 2001) and also, possibly to reduced capacity for plasticity/compensation of the brain.

It was not possible to correlate the degree of structural abnormalities to the severity of the auditory interhemispheric transfer deficit. The two cases with the most severe structural abnormalities in the group, i.e. those with both an absent AC and a hypoplastic CC, gave abnormal results in more tests assessing callosal transfer (4 out of 5) than the rest of the group. However, the presence of deficits in a case in which the AC was present while the callosal area in 3 out of 5 tests which assess callosal transfer would indicate that the interhemispheric pathway could have functional as well as structural abnormalities, and that *PAX6* mutation could lead to cortical reorganisation that has no obvious MRI indicator. In addition, age, type of mutation, cognition as well as other top-down factors could have all affected our findings, and it was not possible to control for these factors, as the sample was small. Nevertheless, these unique findings broadened the possible role of *PAX6* to include higher order roles not only in visual and olfactory sensory domains, but also in auditory processing.

In addition, this study showed that auditory processing abnormalities due to a congenital brain malformation may well persist into adulthood. It is not clear whether the persistence of these deficits was due to other effects of this mutation. For example, it has been suggested that the *PAX6* gene is involved in eye “maintenance”, and it may well also be involved in some kind of “maintenance of the auditory pathway” (Van Heyningen and

Williamson, 2000). Alternatively, the degree of brain malformation could be such that the brain's capacity for plasticity was extremely reduced. However, it is also possible that these deficits persisted into adulthood because they were never identified and addressed by specific auditory training. There is increasing evidence that auditory training is beneficial for patients with auditory processing disorders (Bamiou, Campbell, Sirimanna, 2006). These findings, thus, raised the following questions, which should be addressed in further studies:

- a. Would the auditory deficit phenotype vary according to mutation and/or brain malformation severity, after being controlled for age? This question could only be assessed by a prospective, family pedigree study
- b. Would auditory training be of benefit in the adult *PAX6* population? Again, this question could only be addressed prospectively.
- c. Extrapolating from this study, one also wonders whether “developmental” type central auditory deficits which can be found in the otherwise “normal” population may also persist into adulthood, if left untreated. For example, it is well established that binaural interaction as assessed by the masking level difference test (MLD) is frequently found to be impaired in children with an early prolonged history of otitis media with effusion (OME), for long after the resolution of the OME attacks (see Bamiou 2006 for review). And although MLD appears subsequently to recover, following restoration of normal hearing, adults with a past history of persistent OME in childhood may report more auditory disabilities in adulthood, despite the fact that “standard” MLD results are not significantly

different to the MLDs of normal controls (Stephenson et al., 1995). This may indicate that this adult population may suffer from subtle deficits, which tests are not sensitive enough to identify.

D. Children with *PAX6* mutations may suffer from auditory interhemispheric transfer deficits and difficulties with understanding of speech in noise and localization of sounds despite normal audiograms.

The 4th study assessed auditory interhemispheric transfer, brain MRI findings and parent-reported hearing difficulties in children with *PAX6* mutations. The structural abnormalities of the auditory interhemispheric pathway in the children were broadly similar to those observed in adults with *PAX6* mutations, i.e. the corpus callosum cross-sectional area was found to be reduced, and the anterior commissure was smaller in size than in the normal paediatric population. However, the AC was present in all paediatric cases, while AC absence is a frequent finding in adult *PAX6* studies (Sisodiya et al., 2002; Free et al., 2003; Ellison Wright et al., 2004). It is not clear whether the difference in the paediatric vs. the adult populations are due to the small samples in all studies (as *PAX6* mutations are rare), to the differential effect of different mutations, or to the effect of age and the possibility of a more marked than normal age-related-degeneration of the interhemispheric structures in the *PAX6* population. A bigger, prospective, pedigree study should address these issues.

Similar to our findings in adults (study 3), this paediatric study also found evidence for decreased auditory interhemispheric transfer, on the basis of the central auditory test findings, which correlated with parent -reported hearing difficulties in this sample. The most prominent difficulties these children had, according to parental report, were with understanding speech in the presence of background noise, and with localising sounds. Overall, these difficulties are quite frequent in otherwise “normal” patients with APD (ASHA, 1996; ASHA, 2005). These specific auditory difficulties however, may be attributed to the finding of deficient callosal transfer in these patients. Previous studies, indicate that the interhemispheric pathway facilitates the interhemispheric integration of binaural inputs and may thus contribute to sound localization (Poirier et al., 1993; Lessard et al., 2002). Similarly, processing of speech in background noise may be subserved by both hemispheres (Scott et al, 2004), and interhemispheric interaction may, in this case, help increase the brain’s processing capacity, by maximising use of hemispheric specialization (Passarotti et al, 2002) and by recruiting other top-down executive functions, i.e. attention (Banich 1998). Thus, the reported auditory disabilities in this group correlate well with the site of lesion.

One of the subjects had a speech and language assessment (see the addendum) which identified reduced auditory memory. These results are broadly consistent findings or reduced verbal working memory in adults with PAX6 and an absent anterior commissure (Thompson et al., 2004). Neuropsychological studies have demonstrated that verbal working memory involves several different cognitive components served by underlying cortical networks, which encompass the left inferior frontal gyrus, bilateral dorsolateral prefrontal, inferior parietal, and premotor cortex (Fiez, 2001), and it has been suggested

that the anterior commissure may represent a component of this neural substrate (Thompson et al., 2004). The finding of reduced verbal auditory memory may be in part, but not entirely responsible for the central auditory test results and would need to be further investigated in a future study.

These defects of interhemispheric auditory transfer have implications for management of children bearing *PAX6* mutation, particularly in the classroom, as they already have visual disability. Our anecdotal observation of a case, who was issued with an FM system in the classroom suggest that such management can be of benefit. However, the most beneficial type of management and its outcome in this population ought to be addressed in a prospective, double blind, case control study.

An additional point of interest was whether this population may both offer evidence for the existence of and serve as a model for the proposed “integration deficit” subtype of APD (Bellis, Ferre, 1999; Bellis 2005). The “integration deficit” APD profile is characterised by deficiency in the ability to perform tasks that require intersensory/multisensory communication. The child/adult will have deficits in binaural separation (e.g., competing sentences test) or binaural integration tasks (e.g., dichotic digits test) and poor scores of pattern tests. Associated sequelae may include difficulty with any task requiring interhemispheric integration, such as integrating the prosodic and linguistic elements of a sentence to comprehend its meaning. Bellis (2005) suggests that the addition of visual or multimodality clues may confuse these children, who do not synthesize information well, and that intervention strategies may include improving

acoustic access, limiting multimodal cues, prosody training, and other strategies which aim to recruit top-down language and cognitive functions. Again, the *PAX6* paediatric population could help define the best management options for normal children with an APD profile suggestive of deficient auditory interhemispheric transfer.

FURTHER IMPLICATIONS OF RESEARCH AND CONCLUDING STATEMENT

- 1. APD in the adult patient may be due to congenital/early onset brain abnormalities.** Audiological investigations may thus be of value in the phenotypic evaluation and functional assessment of genetic neurological/neurodevelopmental disease, or direct genetic testing.
- 2. Case studies of patients with defined structural lesions of the brain may help understand how different parts of the brain process sound.** In addition, such studies may help define sensitivity and specificity of different tests which purport to assess auditory processing. Case studies of patients with defined structural lesions of the brain may also help understand auditory processing and the relationship between APD related impairment and disability in the “normal” population, and conceivably in the population with neurodevelopmental disorders
- 3. APD may be a significant sequel of neurological disease, in the presence of a normal audiogram, but may also be present in the neurological patient with a normal brain MRI.** Audiological investigations can be of value in assessing the severity of neurological disease, and it is important to elicit and investigate fully

the patient-reported hearing complaints, even in the presence of normal peripheral hearing. And while imaging studies may be required as further investigation of the patients presenting to the clinic with hearing complaints, the presence of a normal brain MRI does not rule out the diagnosis of APD.

The clinician who deals with the assessment of suspected APD cases is faced with challenges and scientific uncertainties. However, the field is rapidly expanding. The physiological processes that underpin auditory processing are similar in children and in adults, although diagnostic considerations and management approaches may differ. Neuro-audiology, i.e., the intersection of Audiological and Neurological specialties is a relatively new and quite challenging field, which may help understand auditory processing both in a scientific and a clinical context. Neuro-audiology may help translate basic scientific findings into clinical practice, and identify clinical questions and ambiguities which need to be addressed by scientific studies. This new field expands the role of the Audiologist and requires further development.

10. REFERENCES

- Aboitiz F., Montiel J. One hundred million years of interhemispheric communication: the history of the corpus callosum. *Braz J Med Biol Res* 2003; 36:409-420.
- Aboitiz F.A., Ide A., Olivares R. Corpus callosum morphology in relation to cerebral asymmetries in the postmortem human. In: Zaidel E., Iacoboni M. (Eds) *The parallel Brain. The Cognitive Neuroscience of the corpus callosum*. Cambridge, Massachusetts: MIT Press. 2003; pp 33-46.
- Aboitiz F.A., Rodriguez E., Olivares R., Zaidel E. Age-related changes in fiber composition of the corpus callosum: sex differences. *Neuroreport* 1996; 7: 1761-1764.
- Aboitiz F.A., Scheibel A.C., Fisher R.S., Zaidel E. Fiber composition of the human corpus callosum. *Brain Res* 1992; 598:143-153.
- Aboitiz F.A., Scheibel A.C., Fisher R.S., Zaidel E. Individual differences in brain asymmetries and fiber composition in the human corpus callosum. *Brain Res* 1992; 598:154-161.
- Aboitiz F.A., Scheibel A.C., Zaidel E. Morphometry of the human corpus callosum with emphasis on sex differences. *Brain* 1992; 115:1521-1541.
- Ackermann H, Riecker A, Mathiak K, Erb M, Grodd W, Wildgruber D. Rate dependent activation of a prefrontal insular cerebellar network during passive listening to trains of click stimuli: an fMRI study. *Neuroreport* 2001; 12: 4087-4092.

Aharonson, V., Furst, M., Levine, R.A., Chaigne, M., Korczyn, D.

Lateralization and binaural discrimination of patients with pontine lesions. *J*

Acoust Soc Am 1998; 103: 2624-2633.

American Speech and Language Hearing Association. Central auditory

processing: current status of research and implications for clinical practice. *Am J*

Audiol 1996;5:41–54.

American Speech-Language & Hearing Association (ASHA). 2005. (Central)

Auditory Processing Disorders. Available at

<http://www.asha.org/members/desktopdefault.aspx/tabid-1023/>

Amitay S, Hawkey DJ, Moore DR. Auditory frequency discrimination learning is affected by stimulus variability. *Percept Psychophys* 2005;67: 691-8.

Arendt T. Synaptic plasticity and cell cycle activation in neurons are alternative effector pathways: the “Dr. Jekyll and Mr. Hyde concept” of Alzheimer’s disease or the yin and yang of neuroplasticity. *Prog Neurobiol* 2003; 71: 83–248.

Arnott SR, Binns MA, Grady CL, Alain C: Assessing the auditory dual-pathway model in humans. *Neuroimage* 2004; 22:401-408.

Augustine JR. Circuitry and functional aspects of the insular lobe in primates including humans. *Brain Res Rev* 1996; 22:229-244.

Augustine JR. The insular lobe in primates including humans. *Neurol Res* 1985; 7:2-10.

Bamiou DE. Binaural interaction. In: Musiek FM, Chermak G (Eds) *Handbook of Central Auditory Processing Disorder. Volume I: Auditory Neuroscience and Diagnosis*. San Diego: Plural Publishers, 2006; pp 257-286.

Bamiou DE, Cambell N, Musiek FE, Taylor R, Chong W.K., van Heyningen V, Moore A, Luxon LM. Auditory deficits in a child with congenital aniridia due to a *PAX6* mutation. *Int J Audiol* 2007;46: 196-202.

Bamiou DE, Campbell N, Sirimanna TS. Management of auditory processing disorders. *Audiological Medicine* 2006; 4:46-56.

Bamiou DE, Free S, Sisodiya S, Musiek FE, Chong W.K., Gadian D, Williamson K, van Heyningen V, Moore A, Luxon LM. Auditory processing deficits and MRI - documented brain abnormalities in children with *PAX6* mutations. *Arch Pediatr Adolesc Med* 2007, In Press .ii.

Bamiou DE, Musiek FE, Free S, Mitchell T, Sisodiya SM, Davies RA. Evidence of defective auditory interhemispheric transfer in a patient with the *PAX6* mutation and aplasia of the anterior commissure. *Neurology* 2004;62: 489-490.

Bamiou DE, Musiek FE, Sisodiya SM, Free S, Davies RA, Moore A, Van Heyningen V, Luxon LM. Deficient auditory interhemispheric transfer in patients with *PAX6* mutations. *Ann Neurol*. 2004;56(4):503-9.

Bamiou DE, Musiek FE, Jones S, Davies RA, Rudge P, Luxon LM. An unusual case of X-linked adrenoleukodystrophy with auditory processing difficulties as the first and sole clinical manifestation. *J Am Acad Audiol* 2004; 15:152-60.

Bamiou DE, Musiek FE, Luxon LM. Aetiology and clinical presentations of auditory processing disorders - a review. *Arch Dis Child* 2001; 85: 361-365.

Bamiou DE, Musiek FE, Luxon LM. The insula (Island of Reil) and its role in auditory processing. Literature review. *Brain Res Brain Res Rev* 2003; 42:143-154.

- Bamiou DE, Musiek FE, Stevens J, Stow I, Cipolotti L, Brown M., Luxon L.M. Auditory temporal processing deficits in patients with insular stroke. *Neurology* 2006; 67(4):614-9.
- Banich MT. The missing link: the role of interhemispheric interaction in attentional processing. *Brain Cogn* 1998;36:128-57.
- Baran J, Musiek FE. Behavioral assessment of the central auditory nervous system. In: Musiek FE, Rintelman WF (Eds). *Contemporary perspectives in hearing assessment*. Boston: Allyn and Bacon. 1999: pp
- Baran JA, Musiek FM, Reeves AG. Central auditory function following anterior sectioning of the corpus callosum. *Ear Hear* 1987; 7:359-362.
- Baran JA, Bothweldt RW, Musiek FM. Central auditory deficits associated with compromise of the primary auditory cortex. *J Am Acad Audiol*. 2004; 15(2):106-16.
- Baxter DM, Warrington EK. Measuring dysgraphia: A graded-difficulty spelling test (GDST). *Behav Neurol* 1994;7:107-116.
- Beaton A., Hugdahl K., Ray P. Lateral asymmetries and interhemispheric transfer in aging: a review and some new data. In Mandal M., Tiwuan G. (Eds) *Side-bias: A neuropsychological perspective*. Dordrecht, The Netherlands: Klüwer Academic Publishers. 2000: pp 101-152.
- Bellis TJ, Ferre JM. Multidimensional approach to the differential diagnosis of central auditory processing disorders in children. *J Am Acad Audiol* 1999; 10(6):319-28.

Bellis TJ. *Assessment and Management of Central Auditory Processing Disorders in the Educational Setting. From Science to Practice. Second edition.* New York: Delmar Learning/Singular, 2005.

Bey CE, Zatorre RJ. Recognition of interleaved melodies. An fMRI study. *Ann N Y Acad Sci* 2003; 152-4.

Bieser A. Processing of twitter-call fundamental frequencies in insula and auditory cortex of squirrel monkeys. *Exp Brain Res* 1998; 122:139-148.

Bishop DVM. *The Test for Reception of Grammar [TROG]. 2nd Edition.* Manchester. Age and Cognitive Performance Research Centre: University of Manchester: 1989.

Blaettner U, Scherg M, von Cramon D. Diagnosis of unilateral telencephalic hearing disorders. Evaluation of a simple psychoacoustic pattern discrimination test. *Brain* 1989; 112: 177-195.

Boatman D, Vining EP, Freeman J, Carson B. Auditory processing studied prospectively in two hemidecortectomy patients. *J Child Neurol* 2003; 18:228-32.

Boatman DF. Cortical auditory systems: Speech and other complex sounds. *Epilepsy & Behavior* 2006; 8: 494-503.

Bocca E, Calero C, Cassinari V. A new methods for testing hearing in temporal lobe tumours. *Acta Otolaryngol* 1954; 44:219-221.

Bornstein SP, Musiek FE. Implications of temporal processing for children with learning and language problems. In: Beasley D (Ed). *Audition in childhood: Methods of study.* San Diego: College Hill Press, 1980.

Bourk TR, Mielcarz JP., Norris BE. Tonotopic organization of the anteroventral cochlear nucleus of the cat. *Hear Res* 1981; 4:215-41.

British Society of Audiology. Recommended procedure for pure tone audiometry using a manually operated instrument. *Br J Audiol* 1981;15:213-216.

British Society of Audiology. BSA APD Steering Group. Working definition of APD. From: <http://www.thebsa.org.uk/apd/Home.htm>

British Standards. Audiometers. Pure-tone audiometers BS EN 60645-1:2001.

Broadbent DE. The role of auditory localization in attention and memory span. *J Exp Psychol* 1954; 47:191-196.

Brown M. C., de Venecia R. K. and Guinan J. J. Jr. Responses of medial olivocochlear neurons. Specifying the central pathways of the medial olivocochlear reflex. *Exp Brain Res* 2003; 153: 491-498.

Bryden M.P., MacRae L. Dichotic laterality effects obtained with emotional words. *Neuropsych Neuropsychol Behav Neurol* 1989; 3: 171-176.

Burton H, Jones EG. The posterior thalamic region and its cortical projection in New World and Old World monkey. *J Comp Neurol* 1976; 168: 248-302.

Bushara K, Grafman J, Hallett M. Neural correlates of auditory-visual stimulus onset asynchrony detection. *J Neurosci* 2001; 21: 300-4.

Cacace AT, McFarland DJ. The importance of modality specificity in diagnosing central auditory processing disorder. *Am J Audiol.* 2005; 14(2):112-23.

Callaerts P, Halder G, Gehring WJ. PAX-6 in development and evolution. *Annu Rev Neurosci.* 1997;20:483-532.

Callan J, Klisz D, Parsons OA. Strength of auditory stimulus-response compatibility as a function of task complexity. *J Exp Psychol* 1974; 102:1039-1045.

Calvert GA, Hansen PC, Iversen SD, Brammer MJ. Detection of audio-visual integration sites in humans by application of electrophysiological criteria to the BOLD effect. *NeuroImage* 2001; 14: 427-438.

Cameron, S., Dillon, H., Newall, P. The Listening in Spatialized Noise test: Normative data for children. *Int J Audiol* 2006; 45, 99-108.

Campain R, Minckler J. A note on the gross configurations of the human auditory cortex. *Brain Lang* 1976; 3: 318–323.

Cant NB, Benson CG. Parallel auditory pathways: projection patterns of the different neuronal populations in the dorsal and ventral cochlear nuclei. *Brain Res Bull.* 2003; 60(5-6):457-74.

Carlson M, Earls F, Todd RD. The importance of regressive changes in the development of the nervous system: towards a neurobiological theory of child development. *Psychiatr Dev* 1988; 6: 1-22.

Carlyon RP. How the brain separates sounds. *Trends Cogn Neurosci* 2004; 8:465-471.

Cereda C, Ghika J, Maeder P, Bogousslavsky J. Strokes restricted to the insular cortex. *Neurology* 2002; 59:1950-1955.

Chance SA, Casanova MF, Switala AE, Crow TJ. Minicolumnar structure in Heschl's gyrus and planum temporale: Asymmetries in relation to sex and callosal fiber number. *Neuroscience* 2006; 143: 1041-50.

Chermak GD, Musiek FE. Auditory training: principles and approaches for remediating and managing auditory processing disorders. *Semin Hear* 2002; 23: 4: 297-308.

Chermak GD, Somers EK, Seikel JA. Behavioral signs of central auditory processing disorder and attention deficit hyperactivity disorder. *J Am Acad Audiol* 1998; 9(1):78-84.

Chugani H.T., Phelps M.E., Mazziotta J.C. Positron emission tomography study of human brain functional development. *Ann Neurol* 1987; 22: 487-497.

Cipolloni PB, Pandya DN. Topography and trajectories of commissural fibers of the superior temporal region in the rhesus monkey. *Exp Brain Res* 1985; 57:381-389.

Cipolloni PB, Pandya DN. Topography and trajectories of commissural fibers of the superior temporal region in the rhesus monkey. *Exp Brain Res* 1985; 57:381-389.

Clarke J.M., Lufkin R.B., Zaidel E. Corpus callosum morphometry and dichotic listening performance: Individual differences in functional interhemispheric inhibition? *Neuropsychologia* 1993; 31: 547-557.

Clarke S, Bellmann Thiran A, Maeder P, Adriani M, Vernet O, Regli L, Cuisenaire O, Thiran JP. What and Where in human audition: selective deficits following focal hemispheric lesions. *Exp Brain Res* 2002; 147:8-15.

Clarke S, Kraftsik R, Van der Loos H, Innocenti GM. Forms and measures of adult and developing human corpus callosum: is there sexual dimorphism? *J Comp Neurol* 1989; 280:213-30.

Clarke S. Complexity of human interhemispheric connections. In: Zaidel E., Iacoboni M. (Eds) *The parallel Brain. The Cognitive Neuroscience of the corpus callosum*. Cambridge, Massachusetts: MIT Press, 2003: pp 47-49.

Clasca F, Llamas A, Reinoso-Suarez F. Cortical connections of the insular and adjacent parieto-temporal fields in the cat. *Cereb Cortex*. 2000;10: 371-99.

Clasca F, Llamas A, Reinoso-Suarez F. Insular cortex and neighboring fields in the cat: a redefinition based on cortical microarchitecture and connections with the thalamus. *J Comp Neurol* 1997; 384: 456-82.

Code R.A., Winer J.A. Columnar organization and reciprocity of commissural connections in cat primary auditory cortex (AI). *Hear Res* 1986; 23: 205-222.

Coffey C.E., Bryden M.P., Schroering E.S., Wilson WH, Mathew RJ. Regional blood flow correlates of a dichotic listening task. *J Neuropsych Clin Neurosci* 1989; 1:46-52.

Cohen MS. Rapid MRI and functional applications. In: Toga AW, Mazziotta JC (Eds), *Brain Mapping: The Methods*, San Diego: Academic Press, 1996: pp. 223-55.

Collavita FB, Szeligo FV, Zimmer SD. Temporal discrimination in cats with insular-temporal lesions. *Brain Res* 1974;79:153-156.

Conti F., Manzoni T. The neurotransmitters and post-synaptic actions of callosally projecting neurons. *Behav Brain Res* 1994; 64: 37-53.

Corina DP, Richards TL, Serafini S, Richards AL, Steury K, Abbott RD, Echelard DR, Maravilla KR, Berninger VW. fMRI auditory language differences between dyslexic and able reading children. *Brain Imaging* 2001; 12: 1195-1201.

Coull JT. Neural correlates of attention and arousal: insights from electrophysiology, functional neuroimaging and psychopharmacology. *Prog Neurobiol* 1998; 55: 343-361.

Cranford, J.L., Boose, M., Moore, C.A. Tests of the precedence effect in sound localization reveal abnormalities in multiple sclerosis. *Ear Hear* 1990; 11: 282-8.

Davis A. *Hearing in Adults*. Whurr Publishers Ltd, London: 1995.

Demeter S., Rosene D.L., Van Hoesen G.W. Fields of origin and pathways of the interhemispheric commissures in the temporal lobe of macaques. *J Comp Neurol* 1999; 302:29-53.

Di Salle F, Esposito F, Scarabino T, Formisano E, Marciano E, Saulino C, Cirillo S, Elefante R, Scheffler K, Seifritz E. fMRI of the auditory system: understanding the neural basis of auditory gestalt. *Magn Reson Imaging*. 2003; 21:1213-24.

Di Virgilio G, Clarke S, Pizzolato G, Schaffner T. Cortical regions contributing to the anterior commissure in man. *Exp Brain Res* 1999;124:1-7.

Di Virgilio G, Clarke S, Pizzolato G, Schaffner T. Cortical regions contributing to the anterior commissure in man. *Exp Brain Res* 1999;124:1-7.

Di Virgilio G, Clarke S. Direct interhemispheric visual input to human speech areas. *Hum Brain Mapp* 1997; 5:347-354.

Diagnostic and statistical manual of mental disorders, 3rd Edition. (DSM-IV) Washington, DC: American Psychiatric Association . 1980.

Diagnostic and statistical manual of mental disorders, 4th Edition. (DSM-IV) Washington, DC: American Psychiatric Association . 1994.

Dirks DD, Morgan DE, Dubno JR. A procedure for quantifying the effects of noise on speech recognition. *J Speech Hear Disord* 1982; 47:114-23.

Downar J, Crawley AP, Mikulis DJ, Davis KD. A cortical network sensitive to stimulus salience in a neutral behavioural context across multiple sensory modalities. *J Neurophysiol* 2001; 87: 615-620.

Downar J, Crawley AP, Mikulis DJ, Davis KD. A multimodal cortical network for the detection of changes in the sensory environment. *Nature Neurosci* 2000; 3: 277-283.

Edeline JM. The thalamo-cortical auditory receptive fields: regulation by the states of vigilance, learning and the neuromodulatory systems. *Exp Brain Res* 2003; 153: 554-572.

Efron R, Yund EW, Nichols D, Crandall PH. An ear asymmetry for gap detection following anterior temporal lobectomy. *Neuropsychologia*. 1985; 23:43-50.

Ellison-Wright Z, Heyman I, Frampton I, Rubia K, Chitnis X, Ellison-Wright I, Williams SC, Suckling J, Simmons A, Bullmore E. Heterozygous PAX6 mutation, adult brain structure and fronto-striato-thalamic function in a human family. *Eur J Neurosci* 2004;19:1505-12.

Engelien A, Silbersweig D, Stern E, Huber W, Doring W, Frith C, Frackowiak RSJ. The functional anatomy from recovery from auditory agnosia. A PET study of sound categorisation in a neurological patient and normal controls. *Brain* 1995; 118: 1395-1409.

Feng JZ, Brugge JF. Postnatal development of auditory callosal areas in the kitten. *J Comp Neurol* 1983; 214: 416-426.

Fields RD Myelination: An Overlooked Mechanism of Synaptic Plasticity?

Neuroscientist 2005; 11:528-531.

Fiez JA. Bridging the gap between neuroimaging and neuropsychology: using working memory as a case study. *J Clin Exp Neuropsychol* 2001; 23: 19-31.

Fifer RC. Insular stroke causing unilateral auditory processing disorder: case report. *J Am Acad Audiol* 1993;4:364-369.

Fischer M, Ryan SB, Dobyns WB. Mechanisms of interhemispheric transfer and patterns of cognitive function in acallosal patients of normal intelligence. *Arch Neurol* 1992;49:271-277.

Foxman BT, Oppenheim J, Petito CK, Gazzaniga MS. Proportional anterior commissure area in humans and monkeys. *Neurology* 1986;36:1513-1517.

Free SL, Mitchell, TN, Williamson KA, Churchill AJ, Shorvon SD, Moore AT, van Heyningen V, Sisodiya SM. Quantitative MR image analysis in subjects with defects in the PAX6 gene. *NeuroImage* 2003; 20:2281-2290.

Friederici AD, Alter K. Lateralization of auditory language functions: a dynamic dual pathway model. *Brain Lang* 2004; 89:267-76.

Frisina RD. Subcortical neural coding mechanisms for auditory temporal processing. *Hear Res* 2001; 158(1-2):1-27.

Geffen G. Phonological fusion after partial section of the corpus callosum. *Neuropsychologia* 1980; 18:613-620.

Gilles, F. H., Leviton, A., and Dooling, E. C. *The Developing Human Brain: Growth and Epidemiologic Neuropathology*, Great Road, Littleton, MA: John Wright & Sons, 1983

Gogtay N, Giedd JN, Lusk L, Hayashi KM, Greenstein D, Vaituzis AC, Nugent TF 3rd, Herman DH, Clasen LS, Toga AW, Prapoport JL, Thomson PM. Dynamic mapping of human cortical development during childhood through early adulthood. *Proc Natl Acad Sci U S A*. 2004; 101:8174-9.

Goldberg J.M., & Brown P.B. Functional organization of the dog superior olivary complex: an anatomical and electrophysiological study. *J Neurophysiol* 1968; 31: 639-56.

Goldberg JM, Brown PB. Response of binaural neurons of dog superior olivary complex to dichotic tonal stimuli: some physiological mechanisms of sound localization. *J Neurophysiol* 1969; 32:613-36

Gonchar Y.A., Johnson P.B., Weinberg R.J. GABA-immunopositive neurons in rat cortex with contralateral projections to SI. *Brain Res* 1995; 697:27-34.

Gorham DR .Use of the proverbs test for differentiating schizophrenics from normals. *J Consult Psychol* 1956; 20:435-440.

Griffiths TD, Dean JL, Woods W, Rees A, Green GGR. The Newcastle Auditory Battery (NAB). A temporal and spatial test battery for use on adult naive subjects. *Hear Res* 2001; 154:165-169.

Griffiths TD, Johnsrude I, Dean JL, Green GG. A common neural substrate for the analysis of pitch and duration pattern in segmented sound? *Neuroreport* 1999; 10:3825-30.

Griffiths TD, Rees A, Witton C, Cross PM, Shakir RA, Green GGR. Spatial and temporall auditory processing deficits following right hemisphere infarction. A psychophysical study. *Brain* 1997;120:785-794.

Griffiths TD, Warren JD. The planum temporale as a computational hub. *Trends Neurosci* 2002; 25: 348-53.

Griffiths TD. Central auditory pathologies. *Br Med Bull* 2002; 63:107-20.

Griffiths TD. Functional imaging of pitch analysis. *Ann N Y Acad Sci.* 2003; 999:40-9.

Grimm S, Roeber U, Trujillo-Barreto N.J., Schröger E. Mechanisms for detecting auditory temporal and spectral deviations operate over similar time windows but are divided differently between the two hemispheres. *NeuroImage* 2006; 32: 275-282.

Habib M, Daquin G, Milandre L, Royere ML, Rey M, Lanteri A, Salamon G, Khalil R. Mutism and auditory agnosia due to bilateral insular damage-role of the insula in human communication. *Neuropsychologia* 1995; 3: 327-339.

Habib M., Daquin G., Pelletier J., Montreuil M., Robichon F. Alexithymia as a consequence of impaired callosal function: evidence from multiple sclerosis patients and normal individuals. In: Zaidel E., Iacoboni M. (Eds) *The parallel Brain. The Cognitive Neuroscience of the corpus callosum*. Cambridge, Massachusetts: MIT Press, 2003: pp 415-422.

Hackett TA, Preuss TM, Kaas JH: Architectonic identification of the core region in auditory cortex of macaques, chimpanzees and humans. *J Comp Neurol* 2001; 441:197-222.

Hall DA, Hart AC, Johnsrude IS. Relationships between human auditory cortical structure and function. *Audiol Neurootol* 2003; 8(1):1-18.

Hall JW. Psychoacoustical auditory tests. In: Luxon LM, Furman JM, Martini A, Stephens D Eds. *Textbook of Audiological Medicine*. Oxford: Isis Publications, 2003: pp249-258.

Hartley DE, Moore DR. Auditory processing efficiency deficits in children with developmental language impairments. *J Ac Soc Am* 2002; 112(6):2962-6.

Hausmann M, Corballis MC, Fabri M, Paggi A, Lewald J. Sound lateralization in subjects with callosotomy, callosal agenesis, or hemispherectomy. *Brain Res Cogn Brain Res* 2005; 25:537-46 .

He J. Corticofugal modulation of the auditory thalamus *Exp Brain Res* 2003; 153: 579-590.

Hevner RF, Miyashita-Lin E, Rubenstein JLR. Cortical and thalamic axon pathfinding defects in *Tbr1*, *Gbx2* and *Pax6* mutant mice: evidence that cortical and thalamic axons interact and guide each other. *J Comp Neurol* 2002; 447:8-17.

Hill PR, Hogben JH, Bishop DM. Auditory frequency discrimination in children with specific language impairment: a longitudinal study. *J Speech Langu Hear Res* 2005; 48(5):1136-46.

Hinchcliffe R. King-Kopetzky syndrome: an auditory stress disorder? *J Audiol Med* 1992; 1:89-98.

Hines M, Chiu L, McAdams LA, Bentler PM, Lipcamon J. Cognition and the corpus callosum: verbal fluency, visuospatial ability, and language lateralization related to midsagittal surface areas of callosal subregions. *Behav Neurosci* 1992; 106(1):3-14.

Hind S. Survey of care pathway for auditory processing disorder. *Audiological Medicine* 2006; 4: 12-24.

Hirsch I.J. The influence of interaural phase on interaural summation and inhibition. *J Acoust Soc Am* 1948; 20: 536-44.

Hugdahl K. Attentional modulation of interhemispheric transfer: a two-channel threshold model. In: Zaidel E., Iacoboni M. (Eds) *The parallel Brain. The Cognitive Neuroscience of the corpus callosum*. Cambridge, Massachusetts: MIT Press, 2003: pp 307-318.

Hugdahl K. Dichotic listening: Probing temporal lobe functional integrity. In: Davidson R.J., Hugdahl K. (Eds) *Brain Asymmetry*. Cambridge, Mass: MIT press, 1995: pp 123-156.

Hugdahl K., Andersson L. The "forced attention paradigm" in dichotic listening to CV-syllables: A comparison between adults and children. *Cortex* 1986;22:417-432.

Hugdahl K., Carlsson G., Uvebrant P., Lundervold A.J. Dichotic listening performance and intracarotid injections of amobarbital in children and adolescents. Preoperative and postoperative comparisons. *Arch Neurol* 1997; 54:1494-1500.

Hugdahl K., Hammar A. Test-retest reliability of the consonant-vowel syllables dichotic listening paradigm. *J Clin Exp Neuropsychol* 1997; 19: 667-675.

Hugdahl K., Law I., Kyllingsbaek S., Bronnick K., Gade A., Paulson O.B. Effects of attention on dichotic listening: An ¹⁵O-PET study. *Hum Brain Mapp* 2000; 10: 87-97.

Hurley RM, Musiek FE. Effectiveness of transient-evoked otoacoustic emissions (TEOAEs) in predicting hearing level. *J Am Acad Audiol* 1994;5:195-203.

Hyman BT, Tranel D. Hemianesthesia and Aphasia. An anatomical and behavioural study. *Arch Neurol* 1989;46:816-819.

Iacoboni M, Zaidel E. The crossed-uncrossed difference in simple reaction times to lateralized auditory stimuli is not a measure of interhemispheric transmission time: evidence from the split brain. *Exp Brain Res* 1999; 128(3):421-4.

Innocenti G.M. The development of projections from cerebral cortex. In: *Progress in Sensory Physiology* Vol 12 Berlin: Springer Verlag, 1991: pp65-114.

Innocenti G.M. What is so special about callosal connections? In: Leporè F, Ptito M, Jasper HH. (Eds) *Two hemispheres-one brain. Functions of the corpus callosum*. New York: Alan Liss, 1986: pp75-81.

Innocenti G.M., Bressoud R. Callosal axons and their development. In: Zaidel E., Iacoboni M. (Eds) *The parallel Brain. The Cognitive Neuroscience of the corpus callosum*. Cambridge, Massachusetts: MIT Press, 2003: pp 11-26.

Irvine, D.R.F. The auditory brainstem: A review of the structure and function of auditory processing brainstem mechanisms. In: Ottoson, D. (Ed) *Progress in sensory physiology*, Vol 7. Berlin: Springer-Verlag, 1992: pp 1-279.

Jackson M, Warrington EK. Arithmetic skills in patients with unilateral cerebral lesions. *Cortex* 1986;22:611-620.

Jacobson I, Jeeves MA. A new syndrome: familial fronto-nasal dermoid cysts with agenesis of the corpus callosum. In: Lassonde M, Jeeves MA(Eds) *Callosal*

agenesis. *A natural split brain? Advances in Behavioural Biology*, vol 42. New York and London: Plenum Press. 1994: pp 39-54.

Jäncke L., Shah NJ, Posse S, Grosse-Ryuken M, Müller-Gartner H-W: Intensity coding of auditory stimuli: An fMRI study. *Neuropsychologia* 1998; 36:875-883.

Jäncke L., Shah NJ. Does dichotic listening probe temporal lobe functions? *Neurology* 2002;58:736-743.

Jäncke L. Does "callosal relay" explain ear advantage in dichotic monitoring? *Laterality* 2002; 7: 309-320.

Jäncke L., Steinmetz H. Brain size: A possible source of interindividual variability in corpus callosum morphology. In: Zaidel E., Iacoboni M. (Eds) *The parallel Brain. The Cognitive Neuroscience of the corpus callosum*. Cambridge, Massachusetts: MIT Press. 2003: pp 51-63.

Jäncke L., Steinmetz H. Interhemispheric transfer time and corpus callosum size. *Neuroreport* 1994;5:2385-2388.

Jäncke L., Steinmetz H., Volkman J. Dichotic listening: what does it measure? *Neuropsychologia* 1992; 30:941-950.

Jeeves MA, Temple CM. A further study of language function in callosal agenesis. *Brain Lang* 1987; 32:325-35.

Jeffery A, Winer, Lee M, Miller, Charles C, Lee and Christoph E. Schreiner
Auditory thalamocortical transformation: structure and function *Trends Neurosci*
2005; 28: 255-263.

Jeffress, L.A. (). A place theory of sound localization. *J Compar Physiol Psychol* 1948; 41: 35-39.

Jerger J, Alford B, Lew H, rivera V, Chmiel R. Dichotic listening, event-related potentials, and interhemispheric transfer in the elderly. *Ear Hear* 1995; 16:482-498.

Jerger J, Musiek F. Report of the consensus conference on the diagnosis of auditory processing disorders in school-aged children. *J Am Acad Audiol* 2000;11:467-74.

Jerger J., Alford B., Lew H., Rivera V., Chmiel R. Dichotic listening, event related-potentials and interhemispheric transfer in the elderly. *Ear Hear* 1995; 16:482-498.

Johnsrude IS, Giraud AL, Frackowiak RS. Functional imaging of the auditory system: the use of positron emission tomography. *Audiol Neurootol*. 2002;7(5):251-76.

Jones EG, Burton H. A real differences in the laminar distribution of thalamic afferents in cortical fields of the insular, parietal and temporal regions of primates. *J Comp Neurol* 1976; 168: 197-248.

Jones L, López-Bendito G, Gruss P, et al. Pax6 is required for the normal development of the forebrain axonal connections. *Development* 2002; 129: 5041-5052.

Kaas J.H. and Hackett T.A. Subdivisions of auditory cortex and processing streams in primates. *Proc Natl Acad Sci USA* 2000; 97: 11793-11799.

- Kaas, J.H. and Hackett, T.A. 'What' and 'where' processing in auditory cortex (commentary). *Nat. Neurosci.* 1999; 2, 1045–1047
- Kaltenbach JA. The dorsal cochlear nucleus as a participant in the auditory, attentional and emotional components of tinnitus. *Hear Res* 2006; 216-217: 224-34.
- Kamnasaran D. Agenesis of the corpus callosum: lessons from humans and mice. *Clin Invest Med* 2005; 28: 267-82.
- Katz J, Tillery KL. Can central auditory processing tests resist supramodal influences? *Am J Audiol.* 2005; 14: 124-7
- Katz J. The use of staggered spondaic words for assessing the integrity of the central auditory system. *J Audit Res* 1962; 327-337.
- Katz, J., Stecker, N.A., Henderson, D. Introduction to central auditory processing. In: J. Katz, N.A. Stecker & D. Henderson (Eds.), *Central auditory processing: A Tran disciplinary view*. St. Louis: Mosby Year Book, Inc; 1992: pp. 3-8
- Kelley RE, Gonzalez-Toledo E. Strok. In: Glabus MF (Ed). *Neuro-imaging, Part B. International Review of Neurobiology, volume 67*. London: Elsevier, 2005: pp 204-238.
- Kemp DT, Ryan S, Bray P. A guide to the effective use of Otoacoustic Emissions. *Ear Hear* 1990;11: 93-105.
- Kertesz A., Polk M., Howell J., Black S.E. Cerebral dominance, sex, and callosal size in MRI. *Neurology* 1987; 37: 1385-1388.

Kiehl KA, Laurens KR, Duty TL, Forster BB, Liddle PF. Neural sources involved in auditory target detection and novelty processing: an event-related fMRI study. *Psychophysiology* 2001; 38: 133-142.

Kimura D. Some effects of temporal lobe damage on auditory perception. *Can J Psychol* 1961; 15: 157-165.

Kimura D. Functional asymmetry of the corpus callosum in dichotic listening. *Cortex* 1967; 3: 163-168.

Kimura F., Baughman R.W. GABAergic transcallosal neurons in developing rat cortex. *Eur J Neurosci* 1997; 11:1137-1143.

King K, Stephens D. Auditory and psychological factors in “auditory disability with normal hearing”. *Scand Audiol* 1992; 21:109-114.

Kramer SE, Kapteyn TS, Festen M, Tobi H. Factors in subjective hearing disability. *Audiology* 1995; 34: 311-320.

Kraus N, Nicol T. Brainstem origins for cortical ‘what’ and ‘where’ pathways in the auditory system. *Trends Neurosci* 2005; 28: 176-81.

La Mantia A.S., Rakic P. The number, size, myelination, and regional variation of axons in the corpus callosum and anterior commissure in the developing rhesus monkey. *Neuroscience Abstracts* 1984; 10:1081.

Langner G, Schreiner CE. Periodicity coding in the inferior colliculus of the cat. I. Neuronal mechanisms. *J Neurophysiol* 1988; 60: 1799-822.

Lepore F, Lassonde M, Poirier P. Midline sensory integration in callosal agenesis. In: Lassonde M, Jeeves MA (Eds) *Callosal agenesis. A natural split brain*.

Advances in Behavioural Biology: vol 42. New York and London: Plenum Press.

1994: pp 155-170.

Lessard N, Leporé F, Villemagne J, Lassonde M. Sound localization in callosal agenesis and early callosotomy subjects: brain reorganization and/or compensatory strategies. *Brain* 2002; 125:1039-1053.

Lewis JW, Beauchamp MS, DeYoe EA. A comparison of visual and auditory motion processing in human cerebral cortex. *Cereb Cortex* 2000; 10: 873-888.

Lincoln AJ, Bloom D, Katz M, Boksenbaum N. Neuropsychological and neurophysiological indices of auditory processing impairment in children with multiple complex developmental disorder. *J Am Acad Child & Adolescent Psych* 1998; 37: 100-12.

Lockwood AH, Salvi RJ, Coad ML, Arnold SA, Wack DS, Murphy BW, Burkard RF. The functional anatomy of the normal human auditory system: Responses to 0.5 and 4.0 kHz tones at varied intensities. *Cereb Cortex* 1999; 9:65-76.

Marriage J, King J, Briggs J, Lutman ME. The reliability of the SCAN test: results from a primary school population in the UK. *Br J Audiol* 2001; 35:199-208.

Masdeu JC, Irimia P, Asenbaum S, Bogousslavsky J, Brainin M, Chabriat H,

Herholz K, Markus HS, Martínez-Vila E, Niederkorn K, Schellinger PD, Seitz RJ.

EFNS guideline on neuroimaging in acute stroke. Report of an EFNS task force.

Europ J Neurol 2006; 13: 1271–1283.

McKeever WF, Sullivan KF, Ferguson SM, Rayport M. Typical cerebral hemisphere disconnection deficits following corpus callosum section despite sparing of the anterior commissure. *Neuropsychologia* 1981;19:745-55.

McKenna P, Warrington EK. Graded Naming Test. Windsor: NFER-Nelson Publishing Co.Ltd, 1983.

Meister H, von Wedel H, Walger M. Psychometric evaluation of children with suspected auditory processing disorders (APDs) using a parent-answered survey. *Intl J Audiol* 2004; 43:431-7.

Mengler ED, Hogben JH, Michie P, Bishop DV. Poor frequency discrimination is related to oral language disorder in children: a psychoacoustic study. *Dyslexia: the Journal of the British Dyslexia Association* 2005; 11(3):155-73.

Mesulam MM, Mufson EJ. The insula of Reil in man and monkey. Aechitectonics, connectivity and function. In: Jones EG, Peters A. (Eds) *Cerebral Cortex, Volume 4 (Association and Auditory Cortices)*, chapter 5. New York: Plenum Press. 1985: pp 179-226.

Miller E. Verbal fluency as a function of a measure of verbal intelligence and in relation to different types of cerebral pathology. *Br J Clin Psychol* 1984;23:53-57.

Milner B, Taylor L., Sperry R.W. Lateralised suppression of dichotically presented digits after commissural section in man. *Science NY* 1968;161: 184-186.

Misaki K, Kikkawa S, Terashima T. Reelin-expressing neurons in the anterior commissure and corpus callosum of the rat. *Brain Res Dev Brain Res* 2004; 31: 148:89-96.

Mitchell. T.N., Free. S.L., Merschhemke. M., Lemieux. L., Sisodiya. S.M., Shorvon. S.D. Reliable callosal measurement: population normative data confirm sex-related differences. *Am J Neuroradiol.* 2003; 24: 410–418. a.

Mitchell TN, Free SL, Williamson KA, Stevens J.M., Churchill A.J., Hanson I.M., Shorvon S.D., Moore A.T., van Heyningen V., Sisodiya, S.M. Polymicrogyria and absence of pineal gland due to *PAX6* mutation. *Ann Neurol* 2003; 53:658-663. b.

Mohr CM, King WM, Freeman AJ, Briggs RW, Leonard CM: Influence of speech stimuli intensity on the activation of auditory cortex investigated with functional magnetic resonance imaging. *J Acoust Soc Am* 1999;105:2738-2745

Moore D. Auditory processing disorder (APD): Definition, diagnosis, neural basis, and intervention. *Audiological Medicine* 2006 4: 4-11.

Moore. D.R. Anatomy and physiology of binaural hearing. *Audiology* 1991; 20: 125-134.

Moore JK, Guan YL. Cytoarchitectural and axonal maturation in human auditory cortex. *J Assoc Res Otolaryngol* 2001; 2: 297-311.

Moscovitch M, Smith L. Differences in neural organization between individuals with inverted and noninverted handwriting postures. *Science* 1979; 205:710-3.

Musiek FE, Baran JA, Pinheiro ML. Duration pattern recognition in normal subjects and patients with cerebral and cochlear lesions. *Audiology* 1990; 29:304-313.

Musiek FE, Bellis TJ, Chermak G. Nonmodularity of the central auditory nervous system: implications for (central) auditory processing disorder. *Am J Audiol* 2005; 14(2):128-38

Musiek FE, Gollegly KM, Kibbe KS, Verkest-Lenz SB. Proposed screening test for central auditory disorders: follow-up on the dichotic digits test. *Am J Otol*. 1991;12:109-113.

Musiek FE, Kibbe K, Baran J. Neuroaudiological results from split brain patients. *Semin Hear* 1984;2: 219-229.

Musiek FE, Kudziel-Schwan S, Kibbe KS, et al. The Dichotic Rhyme test: Results in split brain patients. *Ear Hear* 1989; 10:33- 39.

Musiek FE, Lee WW. Auditory middle and late potentials. In: Musiek FM, Rintelmann WF, eds. *Contemporary perspectives in hearing assessment*. Nedham Heights: Allyn and Bacon, 1999: pp .

Musiek FE, Oxholm VB. Anatomy and physiology of the central auditory nervous system: a clinical perspective. In: Roeser, Valente, Hosford-Dunn, editors. *Audiology: Diagnosis*. New York: Thieme Medical publishers, 2000: pp 45-72.

Musiek FE, Pinheiro ML, Wilson DH. Auditory pattern perception in "split brain" patients. *Arch Otolaryngol* 1980;106:610-612.

Musiek FE, Pinheiro ML. Dichotic speech tests in the detection of central auditory dysfunction. In: Pinheiro ML, Musiek FE. *Assessment of central auditory dysfunction: Foundations and clinical correlates*. Baltimore: Wakerly Press, 1985: pp 201-18.

Musiek FE, Pinheiro ML. Frequency patterns in cochlear, brainstem and cerebral lesions. *Audiology* 1987;26:79-88.

Musiek FE, Reeves A. Effects of partial and complete corpus callosotomy on central auditory function. In: Leporè F, Ptito M, Jasper HH. (Eds) *Two hemispheres-one brain. Functions of the corpus callosum*. New York: Alan Liss, 1986: pp 423-34.

Musiek FE, Shinn J, Jirsa R, Bamiou DE, Baran J, Zaida E. GIN (Gaps-In-Noise) Test Performance in Subjects with Confirmed Central Auditory Nervous System Involvement. *Ear Hear* 2005;26: 608-618.

Musiek FE. Assessment of central auditory dysfunction: the Dichotic Digit Test revisited. *Ear Hear* 1983; 4:79-83.

Musiek FE. Neuroanatomy, neurophysiology and central auditory assessment. Part III: Corpus callosum and efferent pathways. *Ear Hear* 1986: 349-358.

Musiek FM, Baran JA, Pinheiro ML, eds. *Neuroaudiology: case studies*. San Diego: Singular Publishing Group, 1994.

Musiek FM, Gollegly KM, Baran JA. Myelination of the corpus callosum and auditory processing problems in children: theoretical and clinical correlates.

Semin Hear 1984; 5: 231-242.

Myklebust H. *Auditory disorders in children*. New York: Grune and Stratton, 1954.

Neijenhuis K, Snik A, van den Broek P. Auditory processing disorders in adults and children: evaluation of a test battery. *Int J Audiol* 2003; 42: 391-400.

- Neijenhuis K. Snik A. Priester G. van Kordenoordt S. van den Broek P. Age effects and normative data on a Dutch test battery for auditory processing disorders. *International Journal of Audiology* 2002; 41(6):334-46.
- Nelken I Processing of complex stimuli and natural scenes in the auditory cortex. *Curr Opin Neurobiol.* 2004; 14:474-80.
- Nelson HE, Willison JR. The National Adult Reading Test-Second Edition. Windsor, Berks: NFER-Nelson Publishing Co. Ltd. 1991.
- Noffsinger D, Martinez CD, Wilson RH. Dichotic listening to speech: background and preliminary data for digits, sentences, and nonsense syllables. *J Am Acad Audiol* 1994;5:248-54.
- O'Brien G. 1994. The behavioral and developmental consequences of callosal agenesis. In: Lassonde, M. and Jeeves, M.A., (Editors) *Callosal agenesis: A natural split brain?* New York: Plenum Press, 1994: pp. 235–246.
- O'Kusky J., Strauss E., Kosaka B. The corpus callosum is larger with right hemisphere cerebral speech dominance. *Ann Neurol* 1988; 24:379-383.
- Olsen WO, Noffsinger D, Kurdziel S. Speech discrimination in quiet and in white noise by patients with peripheral and central lesions. *Acta Otolaryngol.* 1975; 80: 375-82.
- Pandya DN, Seltzer B. The topography of commissural fibers. In: Leporé F, Ptito M, Jasper HH (Eds) *Two hemispheres-one brain. Functions of the corpus callosum.* New York: Alan Liss, 1986:47-73.

- Pandya, D. and Rosene, D. Some observations on trajectories and topography of commissural fibers. In Reeves, A. (Ed.) *Epilepsy and the Corpus Callosum*. London: Pleumum Press, 1985: PP. 21-35.
- Pandya, D., Karol, E. Heilbronn, D. The topographical distribution of interhemispheric connections in the rhesus monkey. *Brain Res* 1971; 32: 31-43.
- Paraschos I.A., Wilkinson W.E., Coiffey C.E. Magnetic resonance imaging of the corpus callosum: Predictors of size in normal adults. *J Neuropsychiatry Clin Neurosci* 1993; 7:35-41.
- Passarotti A.M., Banich T.M., Sood R.K., Wong J.M. A generalized role of interhemispheric interaction under attentionally demanding conditions: Evidence from the auditory and tactile modalities. *Neuropsychologia* 2002; 40:1082-1096.
- Patterson RD, Uppenkamp S, Johnsrude I, Griffiths TD. The processing of temporal pitch and melody information in auditory cortex. *Neuron* 2002; 36: 767-776.
- Paul LK, Van Lancker-Sidtis D, Schieffer B, Dietrich R, Brown WS. Communicative deficits in agenesis of the corpus callosum: nonliteral language and affective prosody. *Brain Langu* 2003; 85: 313-24.
- Paulesu E, Frith CD, Frackowiak RSJ. The neural correlates of the verbal component of working memory. *Nature* 1993; 362: 342-345.
- Peretz I. The nature of music from a biological perspective. *Cognition* 2006; 100: 1-32.
- Philips DP. Auditory gap detection, perceptual channels, and temporal resolution in speech perception. *J Am Acad Audiol* 1999; 10: 343-54.

Philips DP, Irvine DRF. Some features of binaural input to single neurons in physiologically defined area AI of cat cerebral cortex. *J Neurophysiol.* 1983; 49(2):383-95.

Pinheiro ML, Musiek FE. Sequencing and temporal ordering in the auditory system. In: Pinheiro ML, Musiek FE.(Eds) *Assessment of central auditory dysfunction: Foundations and clinical correlates.* Baltimore: Wakerly Press. 1985: 219-38.

Plack CJ, Viemeister NF. Suppression and the dynamic range of hearing. *J Acoust Soc Am.* 1993; 93(2): 976-82.

Platel H, Baron JC, Wise R, Lambert J, Frackowiak RSJ, Lechevalier B, Eustache F. The structural components of music perception. A functional anatomical study. *Brain* 1997;120:229-243.

Plomp R. The rate of decay of auditory sensation. *J Acoust Soc Am* 1964; 36: 277–282.

Poeppel D, Guillemin A, Thompson J et al. Auditory lexical decision, categorical perception, and FM direction discrimination differentially engage left and right auditory cortex. *Neuropsychologia* 2004; 42:183-200.

Poffenberger AT Jr. Reaction time to visual stimulation with special reference to the time cost in conduction through nerve centers. *Arch Psychol* 23: 1-73.

Poirier P., Lepore F., Provencal C, Ptito M., Guillemot J.-P. Binaural noise stimulation of auditory callosal fibers of the cat: responses to interaural time delays. *Exp Brain Res* 1995; 104:30-40.

Poirier P., Miljours S., Lassond M., Lepore F. Sound localization in acallosal human listeners. *Brain* 1993; 116:53-69.

Pollman S, Maertens M, von Cramon DY, et al. Dichotic listening in patients with splenial and non-splenial callosal lesions. *Neuropsychology* 2002; 16:56-64.

Poremba A, Saunders RC, Crane AM, Cook M, Louis Sokoloff L, Mishkin M. Functional Mapping of the Primate Auditory System. *Science* 2003; 299 (5606): 568 – 572.

Price CJ, Winterburn D, Giraud AL, Moore CJ, Noppeney U. Cortical localisation of the visual and auditory word form areas: a reconsideration of the evidence. *Brain Lang* 2003; 86:272-86.

Ptok M, Buller N, Schwemmler C, Bergmann C, Luerssen K. Auditory processing disorder versus attention deficit/hyperactivity disorder : A dysfunction complex or different entities? *HNO* 2006; 54(5): 405-414.

Pujol J, Vendrell P, Junque C, Marti-Vilalta JL, Gardevilla A. When does human brain development end? Evidence of corpus callosum growth up to adulthood. *Ann Neurol* 1992; 34: 71-74.

Quigley M, Cordes D, Turski P, Moritz C, Haughton V, Seth R, Meyerand ME. Role of the corpus callosum in functional connectivity. *Am J Neuroradiol* 2003; 24: 208-212.

Rajapakse J.C., Giedd J.N., Rumsey J.N., Vaituzis A.C., Hamburger S.D., Rapoport J.I.. Regional MRI measurements of the corpus callosum: a methodological and developmental study. *Brain Dev* 1996; 18:379-388.

- Rakic P. Yakovlev PI. Development of the corpus callosum and cavum septi in man. *J Comp Neurol* 1968; 26: 100-104.
- Rauch RA. Jinkins JR. Magnetic resonance imaging of corpus callosum dysgenesis. In: Lassonde M. Jeeves MA(Eds) *Callosal agenesis. A natural split brain? Advances in Behavioural Biology*; vol 42. New York and London: Plenum Press. 1994: pp 83-96.
- Rauschecker JP. Cortical processing of complex sounds. *Curr Opin Neurobiol.* 1998; 8(4): 516-21.
- Rayleigh L. On our perception of sound direction. *Philosophical Magazine* 1907; 13: 214-232.
- Reinvang I. Bakke S., Hugdahl K., Karlsen N.R., Sundet K. Dichotic listening performance in relation to callosal area on the MRI scan. *Neuropsychology* 1994; 8: 445-450.
- Ringo JL, Doty RW, Demeter S, Simard PY. Time is of the essence: a conjecture that hemispheric specialization arises from interhemispheric conduction delay. *Cereb Cortex* 1994; 4: 331-343.
- Risse GL, Gates J, Lund J, Maxwell R, Rubens A. Interhemispheric transfer in patients with incomplete section of the corpus callosum. Anatomic verification with magnetic resonance imaging. *Arch Neurol* 1989; 46:437-43.
- Risse GL, LeDoux J, Springer SP, Wilson DH, Gazzaniga MS. The anterior commissure in man: functional variation in a multisensory system. *Neuropsychologia* 1978; 16: 23-31.

Rivier F, Clarke S. Cytochrome oxidase, acetylcholinesterase and NADPH-diaphorase staining in human supratemporal and insular cortex: evidence for multiple auditory areas. *NeuroImage* 1997; 6: 288-304.

Rose, J.E., Geisler, C.D., Hind, J.E. Some neural mechanisms in the inferior colliculus of the cat which may be relevant to localization of a sound source. *J Neurophysiol* 1966; 29: 288-314.

Rosen S. "A riddle wrapped in a mystery inside an enigma": defining central auditory processing disorder. *Am J Audiol* 2005; 14: 139-42.

Rumsey M, Horwitz B, Donohue BC, Nace K, Maisog JM, Andreason P. Phonological and orthographic components of word recognition. A PET-rCBF study. *Brain* 1997; 120: 739-759.

Ruytjens L, Willemsen ATM, Van Dijk P, Wit HP, Albers FWJ. Functional imaging of the central auditory system using PET. *Acta Otolaryngol* 2006;126(12):1236-44

Santhouse AM, Ffytche DH, Howard RJ, Williams SC, Rifkin L, Murray RM. The functional significance of perinatal corpus callosum damage: an fMRI study in young adults. *Brain* 2002;125:1782-1792.

Sarnat HB. Disorders of the Lamina Terminalis: Midline malformations of the forebrain. In: Sarnat HB (Ed) *Cerebral Dysgenesis. Embryology and Clinical Expression*. Oxford: Oxford University Press, 1992.

Saunders GH, Haggard MP. The clinical assessment of obscure auditory dysfunction--1. Auditory and psychological factors. *Ear Hear* 1989; 10(3):200-8.

- Saunders GH, Haggard MP. The clinical assessment of "Obscure Auditory Dysfunction" (OAD) 2. Case control analysis of determining factors. *Ear Hear* 1992;13(4):241-54.
- Sauerwein HC, Nolin P, Lassonde M. Cognitive functioning in callosal agenesis. In: Lassonde M, Jeeves MA(Eds) *Callosal agenesis. A natural split brain? Advances in Behavioural Biology, vol 42*. New York and London: Plenum Press. 1994: pp 221-234.
- Schambra UB, Sulik KK, Petrusz P, lauder JM. Ontogeny of cholinergic neurons in the mouse forebrain. *J Comp Neurol*. 1989; 288: 101-22.
- Scherg M, von Karmon D. Psychoacoustic and electrophysiologic correlates of central hearing disorders in man. *Eur Arch Psychiatry Neurol Sci* 1986; 236(1): 56-60.
- Scott SK, Rosen S, Wickham L, Wise RJ. A positron emission tomography study of the neural basis of informational and energetic masking effects in speech perception. *J Acoust Soc Am* 2004; 115:813-21.
- Scott S.K. and Johnsrude I.S. The neuroanatomical and functional organization of speech perception. *Trends Neurosci* 2003; 26: 100–107.
- Shergill SS, Bullmore ET, Brammer MJ, Williams SRC, Murry RM, McGuire PK. A functional study of auditory verbal imagery. *Psychological Medicine* 2001; 241-253.
- Shinn JB, Baran JA, Moncrieff DW, Musiek FE. Differential attention effects on dichotic listening. *J Am Acad Audiol* 2005; 16: 205-18.

- Singer W. Time as coding space in neocortical processing: a hypothesis. In Gazzaniga M.S. (Ed) *The Cognitive Neurosciences*. Cambridge MA, London GB: MIT Press, 1995: pp 91-104.
- Sisodiya SM, Free SL, Williamson KA, Mitchell TN, Willis C, Stevens JM, Kendall BE, Shorvon SD, Hanson IM, Moore AT, van Heyningen V. PAX6 haploinsufficiency causes cerebral malformation and olfactory dysfunction in humans. *Nature Genet* 2001;28:214-216.
- Smoski, W.J., Brunt, M.A., & Tannahill, J.C. Listening characteristics of children with central auditory processing disorders. *Language, Speech, and Hearing Services in Schools* 1992; 23: 145-152.
- Sparks R., Geschwind N. Dichotic listening in man after section of the neocortical commissures. *Cortex* 1968; 4: 3-16.
- Spreen O, Benton AL, Fincham RW. Auditory agnosia without aphasia. *Arch Neurol* 1965; 13:84-92.
- Spreen O, Strauss E. A compendium of neuropsychological tests (2nd edition). New York: Oxford University Press, 1998: 447-464.
- Springer S, Gazzaniga M. Dichotic testing of partial and complete split brain patients. *Neuropsychologia* 1975; 3: 341-346.
- Stephens D. Audiological rehabilitation. In: Luxon LM, Furman JM, Martini A, Stephens D, editors. *Textbook of Audiological Medicine*. Oxford: Isis Publications, 2003.
- Stephenson H, Higson J, Haggard M. Binaural hearing in adults with histories of otitis media in childhood. *Audiology* 1995; 34:113-23.

Stollman MH, van Velzen EC, Simkens HM, Snik AF, van den Broek P.
Assessment of auditory processing in 6-year-old language-impaired children. *Int J Audiol* 2003; 42(6):303-11.

Sudakov K, McLean PD, Reeves A, Marino R. Unit study of exteroceptive inputs to claustrorocortex in awake sitting squirrel monkeys. *Brain Res* 1971;28:19-34.

Sugishita M, Otomo K, Yamazaki K, Shimizu H, Yoshioka M, Shinohara A.
Dichotic listening in patients with partial section of the corpus callosum. *Brain* 1995;118:417-27.

Sulakhe N, Elias LJ, Lejbak L. Hemispheric asymmetries for gap detection depend on noise type. *Brain Cogn* 2003;53:372-375.

Talamillo A, Quinn JC, Collinson JM, caric D, Price DJ, West JD, Hill RE. *Pax6* regulates regional development and neuronal migration in the cerebral cortex. *Dev Biol* 2003; 255:151-163.

Temple CM, Ilesley J. Sounds and shapes: language and spatial cognition in callosal agenesis. In: Lassonde M, Jeeves MA(Eds) *Callosal agenesis. A natural split brain? Advances in Behavioural Biology, vol 42*New York and London: Plenum Press, 1994: pp 261-274.

Temple CM, Jeeves MA, Vilarroya OO. Reading in callosal agenesis. *Brain Lang* 1990; 39:235-53.

Tervaniemi M, Hugdahl K.Lateralization of auditory-cortex functions. *Brain Res Brain Res Rev.* 2003; 43: 231-46.

The Human PAX6 Allelic Variant Database Web Site. At:
<http://pax6.hgu.mrc.ac.uk/>

Thompson P, Mitchell TN, Free SL, Williamson KA, Hanson IM, van Heyningen V, Moore AT, Sisodiya SM. Cognitive findings in humans with mutations in PAX6. *Neurology* 2004; 62:1216-1218.

Thompson P.M., Narr K.I., Blanton R.E., Toga A.W. Mapping structural alterations of the corpus callosum during brain development and degeneration. In: Zaidel E., Iacoboni M. (Eds) *The parallel Brain. The Cognitive Neuroscience of the corpus callosum.* . Cambridge, Massachusetts: MIT Press, 2003: pp 51-63.

Thompson PM, Giedd JN, Woods RP, MacDonald D, Evans AC, Toga AW. Growth patterns in the developing brain detected by using continuum mechanical tensor maps. *Nature* 2000 ;404(6774):190-3.

Trenerry MR, Crossen B, DeBoe J, Leber WR. Stroop Neuropsychological Screening Test(SNST). Windsor, Berks: NFER-Nelson Publishing Co. Ltd, 1989.

Türe U, Yaşargil G, Krisht AF. The arteries of the corpus callosum: a microsurgical anatomic study. *Neurosurgery* 1996; 39:1075–1085.

Türe U, Yaşargil MGG, Al-Mefty O, Yaşargil DCH. Arteries of the insula. *J Neurosurg* 2000; 92: 676-687.

Türe U, Yaşargil MGG, Al-Mefty O, Yaşargil DCH. Topographic anatomy of the insular region. *J Neurosurg* 1999; 90: 720-733.

van Heyningen V, Williamson KA. PAX6 in sensory development. *Hum Mol Genet* 2002; 11:1161-7.

Warr WB. Organization of olivocochlear efferent systems in mammals. In: Webster DB, Popper AN, Fay RR (Eds) *The mammalian auditory pathway: neuroanatomy.* New York: Springer, 1992: pp 410–448.

Warren JD, Griffiths TD. Distinct mechanisms for processing spatial sequences and pitch sequences in the human auditory brain. *J Neurosci*. 2003; 23(13):5799-804.

Warrington EK, James M. The Visual Object and Space Perception Battery. Bury St Edmunds, Suffolk: Thames Valley Test Company, 1991.

Warrington EK. Recognition Memory Test. Windsor, Berks: NFER-Nelson Publishing Co. Ltd, 1984.

Warrington EK. The Camden Memory Tests. Hove, East Sussex: Psychology Press, 1996.

Wechsler DA. Wechsler Adult Intelligence Test-Revised. London: The Psychological Corporation , 1981

Weigl E. On the psychology of so-called processes of abstraction. *J Abn Soc Psychol* 1941; 36:3-33.

Weissman D.H., Banich M.T. The cerebral hemispheres cooperate to perform simple but not complex tasks. *Neuropsychology* 2000; 14:41-59.

Westerhausen R, Woerner W, Kreuder F, Schweiger E, Hugdahl K, Wittling W. The Role of the Corpus Callosum in Dichotic Listening: A Combined Morphological and Diffusion Tensor Imaging Study. *Neuropsychology* 2006; 20: 272-9.

Wexler BE, Halwes T. Increasing the power of dichotic methods: the fused rhymed words test. *Neuropsychologia* 1983; 21:59-66.

Willeford J. Assessing central auditory behaviour in children: a test battery approach. In Keith R. (Ed) *Central auditory dysfunction*. New York: Grune and Stratton, 1977: pp 43-72.

- Willison JR. Warrington EK. Cognitive retardation in a patient with preservation of psychomotor speed. *Behav Neurol* 1992; 5:113-116.
- Willison JR. Neuropsychological investigations of a set of mental speed tests PhD thesis. London University. 1988.
- Winer JA, Miller LM, Lee CC, Schreiner CE. Auditory thalamocortical transformation: structure and function. *Trends Neurosci*. 2005; 28: 255-63.
- Witelson S.F. Hand preference and sex differences in the isthmus of the corpus callosum. *Soc Neurosci Abstr* 1987;13:48.
- Witelson S.F. Neuroanatomical bases of hemispheric functional specialisation in the human brain: Possible developmental factors. In: Kitterle F.L. (Ed) *Hemispheric Communication: Mechanisms and Models*. Hillsdale NJ: Lawrence Erlbaum associates. 1995: pp 61-84.
- Wong D, Pisoni DB, Learn J, Gandour JT, Miyamoto RT, Hutchins GD. PET imaging of differential cortical activation by monaural speech and non-speech stimuli. *Hear Res* 2002; 166: 9-23.
- World Health Organisation. ICF: International classification of Functioning Disability and Health. Geneva: WHO, 2001.
- Yakovlev P.I. Lecours A.R. *Regional Development of the brain*. Oxford, England: Blackwell, 1976.

Yin, T.C., Chan, J.C., Carney, L.H. Effects of interaural time delays of noise stimuli on low-frequency cells in the cat's inferior colliculus. III. Evidence for cross-correlation. *J Neurophysiol* 1987; 58: 562-83.

Zaidel E. Callosal dynamics and right hemisphere language. In: Leporè F, Ptito M, Jasper HH. (Eds) *Two hemispheres-one brain. Functions of the corpus callosum*. New York: Alan Liss, 1986: pp

Zaidel E., Iacoboni M. Preface. In: Zaidel E., Iacoboni M. (Eds) *The parallel Brain. The Cognitive Neuroscience of the corpus callosum*. Cambridge, Massachusetts: MIT Press, 2003: pp xiii-xiv.

Zaidel E., Zaidel D.W., Bogen J.E. Disconnection syndrome. In Beaumont G., Kenealy P.M., Rogers J.C. (Eds) *The Blackwell Dictionary of Neuropsychology*. Oxford: Blackwell, 1996: pp 279-285.

Zatorre RJ Neural specializations for tonal processing. *Ann N Y Acad Sci*. 2001; 930: 193-210.

Zatorre RJ. Neural specializations for tonal processing. *Ann N Y Acad Sci* 2001; 930:193-210.

Zhao F, Stephens D. Subcategories of patients with King-Kopetzky syndrome. *Br J Audiol* 2000; 34(4):241-56.

Zur KB, Holland SK, Yan W, Choo DI. Functional magnetic resonance imaging: contemporary and future use. *Curr Opin Otolaryngol Head Neck Surg*. 2004; 12:374-7.

List of figures

Figure 1. Schematic representation of the main brainstem nuclei of the auditory pathway and their main connections. AN—auditory nerve; CN—cochlear nucleus; SOC—superior olivary complex; LL—lateral lemniscus; IC—inferior colliculus; CP—central processor; TB—trapezoid body. From Bamiou 2006.

Figure 2. The auditory cortex in humans. Dorsolateral aspect after removal of the overlying parietal cortex. The ventral bank of the lateral sulcus and insular cortex and the superior surface of the STG are exposed. The dashed line indicates the part of the cortex that has been sectioned. The outline of HG is in black. The primary auditory cortex is depicted in white on the middle part of HG. Non-primary areas on the lateral part of HG, including the planum polare and planum temporale are shown in light grey. CS = Central sulcus; PAC = primary auditory cortex; STS = superior temporal sulcus; STG = superior temporal gyrus. From Hall et al., 2003.

Figure 3. Schematic representation of the pathway of the sound-evoked medial olivocochlear (MOC) reflexes to the right cochlea. The reflex pathway in response to ipsilateral sound includes the outer and inner hair cells (OHC, IHC) of the ipsilateral cochlea, the type I afferent fibers of the auditory nerve c. the cochlear nucleus, the MOC reflex interneurons, which cross the midline (*black pathway*) to innervate MOC neurons having a response to ipsilateral sound. These ipsilateral neurons cross back the midline to innervate OHC in the ipsilateral cochlea. The reflex pathway to contralateral sound includes the contralateral cochlea and type I nerve fibers, the contralateral cochlear

nucleus. with reflex interneurons sending axons that cross the midline (*gray pathway*) to innervate contralateral neurons. In addition, both types of MOC neurons receive weaker inputs that facilitate the response to the dominant ear (*small arrows. Facilitatory Input*). (IVN inferior vestibular nerve). From Brown et al., 2003.

Figure 4. Photographs of brain specimen. The insula has been exposed following excision of the opercula. aps= anterior periinsular sulcus, alg= anterior long insular gyrus, asg= anterior short insular gyrus, cis= central insular sulcus, cs= central sulcus of Rolando, F2= middle frontal gyrus, f2= inferior frontal sulcus, ips= inferior periinsular sulcus, li= limen insula, mog= medial orbital gyrus, msg= middle short insular gyrus, pcg= precentral gyrus, pcis= precentral insular sulcus, pcs= precentral sulcus, pg= postcentral gyrus, pis= postcentral insular sulcus, plg= posterior long insular gyrus, psg= posterior short insular gyrus, ps= postcentral sulcus, sps= superior periinsular sulcus, sis= , T2= middle temporal gyrus, tg= transverse insular gyrus. From Türe et al (1999), reference 34, with kind permission, and from Bamiou et al., 2003.

Figure 5. Coronal section of the brain through the foramen of Monro and the amygdala. A = amugdala, ac= anterior commisure, ahg= anterior Heschl's gyrus, alg= anterior long insular gyrus, bcc= body of corpus callosum, bf= body of formix, c= claustrum, cg= cingulate gyrus, cis= central insular sulcus, cn = caudate nucleus, cs= central sulcus of Rolando, ec= external capsule, exc=extreme capsule, fg= fusiform gyrus, gp= globus pallidus, ic= internal capsule, ot=optic tract, p= putamen, ph= pes hippocampi phg=posterior Heschl's gyrus, phig=parahippocampal gyrus, , psg= posterior short

insular gyrus. scg= subcentral gyrus. T1= superior temporal gyrus. t2= middle temporal gyrus. T3=inferior temporal gyrus. t1= superior temporal sulcus. t2= inferior temporal sulcus. From Türe et al (1999), reference 34, with kind permission, and from Bamiou et al., 2003.

Figure 6. An approximate illustration of the lesion in Spreen et al., 1965.

1= insula, 2= external capsule, 3 = internal capsule, 4=Heschl's gyrus. From Bamiou et al., 2003.

Figure 7. An approximate illustration of the lesion in Hyman and Tranel, 1989. From Bamiou et al., 2003.

Figure 8. An approximate illustration of the lesion in Fifer, 1993. From Bamiou et al., 2003.

Figure 9. An approximate illustration of the lesion in Habib et al., 1995. From Bamiou et al., 2003.

Figure 10. Midsagittal section of the brain showing the corpus callosum and the anterior commissure. (AC, rostrum, genu, body or trunkus, isthmus or sulcus, splenium) From Musiek, 1986.

Figure 11. Subdivision of the CC as proposed by Witelson (1995).

Figure 12. Arterial vascularization of the human corpus callosum in the right cortex.

ACoA = .*appa* = accessory posterior pericallosal artery. *ca* = callosal artery. *cca* = cingulocallosal artery. *lca* = long callosal artery . *pa* = pericallosal artery. *ppa* = posterior pericallosal artery. *rcca* = recurrent cingulocallosal artery. *sa* = subcallosal artery. From Ture 1996.

Figure 13. Growth patterns in the developing human brain detected at ages 3±15 years. A is detected in Serial scanning of young normal subjects across time spans of up to four years shows a rostro-caudal wave of peak growth rates. Between ages 3 and 6 years, peak growth rates (red colours; 60±80% locally) were detected in the frontal circuits of the corpus callosum. Older children displayed fastest growth at the callosal isthmus. Between ages 11±15 years, growth rates still peak at the isthmus, but are attenuated. From Thompson et al., 2000.

Figure 14. Four-dimensional growth maps of brain development. Growth rates in the corpus callosum of five young normal subjects serially scanned aged 6±13 years are strikingly similar. Peak values were attenuated after puberty (11±15 years) at the posterior midbody (red colours). Between ages 3±6 years, the anterior interhemispheric fibre systems showed extreme growth rates. Tensor maps showed that the principal directions of growth rates in frontal regions were outwards. From Thompson et al., 2000.

Figure 15. **A:** Regions activated during the divided attention minus the combined focused attention conditions. **B:** The lower panel show the reversed subtraction, i.e. the focused attention conditions minus the divided attention condition. The data were transformed to Z-scores in the SPM-96 analysis software and projected through sagittal, coronal, and axial views of a transparent brain. From Hugdahl et al 2000.

Figure 16. The dichotic digits test.

Figure 17. Schematic illustration of the stimulus in the a. frequency pattern test (FPT) and b. the duration pattern test (DPT).

Figure 18. Schematic illustration of the stimulus in the Gaps-In-Noise test (GIN).

Figure 19. Fast spin echo (T2W) TR 6000 ms TE/EF 106, axial (case 1, case 5) and coronal acquisition (case 2) images. Fluid attenuated inversion recovery (FLAIR), TR 10,000 ms, TI 2500, coronal acquisition images (cases 3, 4, 6, 7, 8).

Figure 20. Scatterplot of duration pattern test (DPT) results in left versus right cortex lesions (gray shaded area represents normal range).

Figure 21. Boxplot of dichotic digits right and left ear scores in normal and in *PAX6* subjects.

Figure 22. Boxplot of dichotic CVs right and left ear scores in normal and in *PAX6* subjects.

Figure 23. Boxplot of dichotic rhyme right and left ear scores in normal and in *PAX6* subjects.

Figure 24. Brain MRI of cases 1.1, 3.1, 3.2, 5.1, 7.1 and 7.2

List of tables

Table 1. Summary of the major auditory functions of the insula.

Table 2. Stages in the differentiation of callosal axons.

Table 3. Aetiology of APD (modified from Bamiou, Luxon, Musiek 2001)

Table 4. Minimal clinical test battery proposed by ASHA (Jerger and Musiek, 2000)

Table 5. The Newcastle Auditory Battery (NAB) Griffiths et al., 2001

Table 6. The CAPE test battery (Moore, 2006)

Table 7. Central Auditory Test Norms for Children and Adults (from the Dartmouth Hitchcock Audiology Lab)

Table 8. Summary of lesion details and central auditory test results

Abn = abnormal, DDT = Dichotic Digits Test, DPT= duration pattern test, FPT = Frequency pattern test, GIN=Gaps in noise test, IFG = inferior frontal gyrus, L% = left ear percentage score, Lms = left ear milliseconds threshold, ND = not done, norm = normal, R% = right ear percentage score, Rms = right ear milliseconds threshold, STG = superior temporal gyrus, thresh = threshold, TrG= transverse temporal gyrus.

Table 9. Dichotic digit test (DDT). Frequency pattern (FPT) and duration pattern (DPT) tests: Summary percent score results (mean, SD) in subjects with left vs. right sided lesions and in controls

Table 10. Gaps-in-noise (GIN) test: summary of threshold results (mean, SD) in subjects with left vs. right sided lesions and in controls

Table 11. Summary of Neuropsychological Tests Scores

Table 12. Age, sex and audiometric results in cases and controls.

List of abbreviations: f= female, m= male, kHz = kilohertz, L=left, PTA = pure tone audiogram, R=right

Table 13. Lesion description in cases

List of abbreviations: AVM = arteriovenous malformation, L=left, R=right

Table 14. Central auditory test results in Cases and Controls – proportion of abnormalities and chi-square p-values

Abn = abnormalities, DDT = dichotic digits test, FPT= frequency pattern test, DPT = duration pattern test, GIN = gaps in noise test, R= right, L = left, N = number

Table 15. Inventory scores in case and control subjects. mean differences and T test p-values.

Table 16. Analysis of variance of intelligibility of speech in noise vs. dichotic digits test (DDT) results ($f(3,38) = 9.578, p < .001$)

Table 17. Analysis of variance of intelligibility of speech in noise vs. DDT results: Post-hoc Bonferroni analysis

Table 18. Analysis of variance of intelligibility of speech in quiet vs. dichotic digits test (DDT) results ($f(3,38) = 16.9, p < .001$)

Table 19. Analysis of variance of intelligibility of speech in quiet vs. dichotic digits test (DDT) results: Post-hoc Bonferroni analysis

Table 20. Analysis of variance of intelligibility of speech in noise vs. Gaps in Noise (GIN) results ($f(3,35) = 3.247, p = .033$)

Table 21. Analysis of variance of intelligibility of speech in noise vs. Gaps in noise (GIN) results: Post-hoc Bonferroni analysis

Table 22. Analysis of variance of sound distinction vs. gaps in noise (GIN) results ($f(3,33) = 4.42, p = .010$)

Table 23. Analysis of variance of sound distinction vs. gaps in noise (GIN) results: Post-hoc Bonferroni analysis

Table 24. Analysis of variance of sound distinction vs. frequency pattern test (FPT) results ($f(2,37)=6.85$, $p=.003$)

Table 25. Analysis of variance of sound distinction vs. frequency pattern test (FPT) results: Post-hoc Bonferroni analysis

Table 26. Brain MRI abnormalities and central auditory test findings in the PAX6 group.

Table 27. Summary of mutation, brain MRI and main central auditory test findings in the children with *PAX6* mutations and their affected parent.

Table 28. Questionnaire results in children with *PAX6* mutations and in controls.

Table 29. Speech, language and working/auditory memory test results in case 1.1

APPENDIX A

Amsterdam Inventory for Auditory Disability and Handicap

1. Can you understand a shop assistant in a crowded shop?

‏ Almost never ‏ occasionally ‏ frequently ‏ almost
always

2. Can you carry on a conversation with someone in a quiet room?

‏ Almost never ‏ occasionally ‏ frequently ‏ almost
always

3. Do you immediately hear from which direction a car is approaching when
outside?

‏ Almost never ‏ occasionally ‏ frequently ‏ almost
always

4. Can you hear cars passing by?

‏ Almost never ‏ occasionally ‏ frequently ‏ almost
always

5. Do you recognise members of your family by their voices?

‏ Almost never ‏ occasionally ‏ frequently ‏ almost
always

6. Can you recognise melodies in music or songs?

ف Almost never ف occasionally ف frequently ف almost
always

7. Can you carry on a conversation with someone in a crowded meeting?

ف Almost never ف occasionally ف frequently ف almost
always

8. Can you carry on a telephone conversation in a quiet room?

ف Almost never ف occasionally ف frequently ف almost
always

9. Can you hear from which corner of a lecture room someone is asking a question during a meeting?

ف Almost never ف occasionally ف frequently ف almost
always

10. Can you hear someone approaching from behind?

ف Almost never ف occasionally ف frequently ف almost
always

11. Do you recognise a presenter on TV by his/her voice?

ف Almost never ف occasionally ف frequently ف almost
always

12. Can you understand text that is being sung?

ف Almost never ف occasionally ف frequently ف almost
always

13. Can you easily carry on a conversation with somebody in a car or bus?

ف Almost never ف occasionally ف frequently ف almost
always

14. Can you understand the presenter of the news on TV?

ف Almost never ف occasionally ف frequently ف almost
always

15. Do you immediately look in the right direction when somebody calls you in the street?

ف Almost never ف occasionally ف frequently ف almost
always

16. Can you hear noises in the house like running water, vacuuming, a washing machine?

ف Almost never ف occasionally ف frequently ف almost
always

17. Can you discriminate between the sound of a car and a bus?

ف Almost never ف occasionally ف frequently ف almost
always

18. Can you follow a conversation between a few people during dinner?

ف Almost never ف occasionally ف frequently ف almost
always

19. Can you understand the presenter of the news on the radio?

ف Almost never ف occasionally ف frequently ف almost
always

20. Can you hear from which corner of the room someone is talking to you in a quiet house?

ف Almost never ف occasionally ف frequently ف almost
always

21. Can you hear the doorbell at home?

ف Almost never ف occasionally ف frequently ف almost
always

22. Can you distinguish between male and female voices?

ف Almost never ف occasionally ف frequently ف almost
always

23. Can you hear rhythm in music or songs?

ف Almost never ف occasionally ف frequently ف almost
always

24. Can you carry on a conversation with someone in a busy street?

ف Almost never ف occasionally ف frequently ف almost
always

25. Can you distinguish intonation and inflections in people's voices?

ف Almost never ف occasionally ف frequently ف almost
always

26. Do you hear from which direction a car horn is coming?

ف Almost never ف occasionally ف frequently ف almost
always

27. Do you hear birds singing outside?

👉 Almost never 👉 occasionally 👉 frequently 👉 almost

always

28. Can you recognise and distinguish between different musical instruments by their sound?

👉 Almost never 👉 occasionally 👉 frequently 👉 almost

always

APPENDIX B

Structured questionnaire. “Please answer the following questions by ticking the appropriate box.”

1. Can your child understand speech in a quiet environment?
<input type="checkbox"/> Almost never <input type="checkbox"/> Occasionally <input type="checkbox"/> Frequently <input type="checkbox"/> Almost always
2. Can your child understand speech in a noisy environment?
<input type="checkbox"/> Almost never <input type="checkbox"/> Occasionally <input type="checkbox"/> Frequently <input type="checkbox"/> Almost always
3. Can your child tell by your tone of voice how you feel, e.g., if you're angry, pleased etc?
<input type="checkbox"/> Almost never <input type="checkbox"/> Occasionally <input type="checkbox"/> Frequently <input type="checkbox"/> Almost always
4. Can your child distinguish intonation and voice inflection in people's voices?
<input type="checkbox"/> Almost never <input type="checkbox"/> Occasionally <input type="checkbox"/> Frequently <input type="checkbox"/> Almost always
5. Does your child “get a joke” as well as his peers?
<input type="checkbox"/> Almost never <input type="checkbox"/> Occasionally <input type="checkbox"/> Frequently <input type="checkbox"/> Almost always
6. Can your child tell where a sound is coming from?
<input type="checkbox"/> Almost never <input type="checkbox"/> Occasionally <input type="checkbox"/> Frequently <input type="checkbox"/> Almost always

APPENDIX C

STUDY 2: AUDITORY PROCESSING DEFICITS AND DISABILITIES IN PATIENTS WITH STROKE OF THE CENTRAL AUDITORY PATHWAY

Lesions, questionnaire and test results in the excluded subjects

Case	Sex	Age	Lesion	CAT	Questionnaire scores
1	M	26	right anterior temporal lobectomy for epilepsy after head injury	normal	< mean of control group
2	F	44	infarct/ posterior temporal + occipital lobe	normal	\leq mean +1 SD of control group
3	M	57	infarct/ left pyramid inferior olive	normal	< mean of control group
4	M	54	infarct/ right pons posteriomediaally	normal	\leq mean +1 SD of control group
5	M	47	infarct/ left brainstem/cerebellum	normal	abnormal

CAT = central auditory tests