

Mycopathologia (2015) 179:103–109
DOI 10.1007/s11046-014-9828-3

Photodynamic Therapy Combined with Terbinafine Against Chromoblastomycosis and the Effect of PDT on *Fonsecaea monophora* In Vitro

Yongxuan Hu · Xiaowen Huang · Sha Lu ·
Michael R. Hamblin · Eleftherios Mylonakis ·
Junmin Zhang · Liyan Xi

Received: 3 May 2014 / Accepted: 21 October 2014 / Published online: 1 November 2014
© Springer Science+Business Media Dordrecht 2014

Abstract Chromoblastomycosis, a chronic fungal infection of skin and subcutaneous tissue caused by dematiaceous fungi, is associated with low cure and high relapse rates. Among all factors affecting clinical outcome, etiological agents have an important position. In southern China, *Fonsecaea pedrosoi* and *Fonsecaea monophora* are main causative agents causing Chromoblastomycosis. We treated one case of chromoblastomycosis by photodynamic therapy (PDT) of 5-aminolevulinic acid (ALA) irradiation combined with terbinafine 250 mg a day. The lesions were improved after two sessions of ALA-PDT treatment, each including nine times, at an interval of 1 week, combined with terbinafine 250 mg/day oral, and clinical improvement

could be observed. In the following study, based on the clinical treatment, the effect of PDT and antifungal drugs on this isolate was detected in vitro. It showed sensitivity to terbinafine, itraconazole or voriconazole, and PDT inhibited the growth. Both the clinic and experiments in vitro confirm the good outcome of ALA-PDT applied in the inhibition of *F. monophora*. It demonstrated that combination of antifungal drugs with ALA-PDT arises as a promising alternative method for the treatment of these refractory cases of chromoblastomycosis.

Keywords Photodynamic Therapy · Terbinafine · Chromoblastomycosis

Introduction

Chromoblastomycosis, one of the most frequently encountered subcutaneous mycosis in tropical and

Yongxuan Hu and Xiaowen Huang contributed equally to this work.

Y. Hu · X. Huang · S. Lu · J. Zhang · L. Xi (✉)
Department of Dermatology, Sun Yat-sen Memorial Hospital, Sun Yat-sen University,
107 West Yanjiang Rd, Guangzhou 510120, China
e-mail: xiliyan@mail.sysu.edu.cn

Y. Hu
Department of Dermatology and Venerology,
The Third Affiliated Hospital of Southern Medical University, 183 West Zhongshan Rd, Guangzhou 510630, China

M. R. Hamblin
Wellman Center for Photomedicine, Massachusetts General Hospital, Boston, MA 02114, USA

M. R. Hamblin
Department of Dermatology, Harvard Medical School, Boston, MA 02115, USA

M. R. Hamblin
Harvard-MIT Division of Health Sciences and Technology, Cambridge, MA 02139, USA

E. Mylonakis
Department of Medicine, Warren Alpert Medical School of Brown University, 593 Eddy Street, Providence, RI 02903, USA

subtropical regions, is characterized by slowly expanding skin lesions. Usually, it is caused by traumatic inoculation of a specific group of dematiaceous fungi and associated with low cure and high relapse rates [1, 2]. Several species of pathogens are involved in the disease etiology, including *Cladophialophora carrionii*, *Fonsecaea pedrosoi*, *Fonsecaea monophora*, *Fonsecaea nubica* and *Rhinoctadiella aquaspersa* [3]. In southern China, *F. pedrosoi* and *F. monophora* are the most common causes [4], while other fungi, such as *F. nubica* and *Phialophora aquaspersa*, are less common [5, 6].

Due to its recalcitrant nature, treatment of the disease is still a challenge [7]. Strains of *F. pedrosoi* can be resistant to many antifungal drugs, and infections can be extremely difficult to eradicate [8, 9]. Conversely, the treatment of cases caused by *F. monophora* is relatively easier [10, 11]. More effective methods have been employed for inhibiting the pathogen's activity, like photodynamic therapy (PDT). PDT is a minimally invasive approach, in which photosensitizer is activated by exposure to low-intensity harmless visible light. The activation of photosensitizer results in the production of reactive oxygen species and other reactive molecules, which, in the biological site, leads to the damage of targets. It has been developed to combat cancerous lesions, including infectious diseases. A wide range of microorganisms has been demonstrated susceptibility to antimicrobial PDT [12, 13]. This treatment may be considered an alternative for the management of fungal infections [14]. Antifungal PDT has been successfully employed against *Candida* species [15], dermatophytes [16], *A. fumigatus* [17] and *F. monophora* [3].

In this study, the clinical effect of PDT on chromoblastomycosis and the antifungal activity of *in vitro* were evaluated. We describe one refractory case treated by PDT combined with terbinafine. The clinical effect is positive, denoting the efficiency of PDT against chromoblastomycosis. Considering that the majority of the published works are focused on *in vitro* trials, these clinical tests can be considered as a relevant source of information about antifungal PDT.

Case Report

A 50-year-old male farmer residing in Guangzhou, China, presented to our outpatient clinic on March 29, 2011. He complained of an itchy erythematous plaque

surrounded with veracious hyperplasia on the right ankle (Fig. 1a). The lesion started 30 years ago after local trauma and enlarged gradually. The patient had visited another hospital, and a clinical diagnosis of deep mycosis (without isolation of pathogen) was made. Before he came to our hospital, itraconazole and fluconazole had been employed for a long time (more than 1 year). In our hospital, both examination of potassium hydroxide mounts (Fig. 2a) and histopathology revealed dematiaceous muriform cells (Fig. 2b, c) and the diagnosis of chromoblastomycosis was supported. Based on mycological study and DNA sequencing, the etiological agent was identified as *F. monophora*. The family history or past medical history was unremarkable. Underlying diseases or immunocompromised conditions were not present in this patient. In the treatment, terbinafine 500 mg/day oral was administered for 4 weeks, but no significant improvement was observed (Fig. 1b). Then, PDT of ALA (concentration of 20 %, duration time of 4 h) irradiation was adopted combined with terbinafine 250 mg/day oral, from April 26, 2011, to July 7, 2011, totally for nine times, at an interval of 1 week, but not improved previously. From September 1, 2011, to January 13, 2012, he received this therapy for another nine times, at an interval of 1 week, and combined with terbinafine 250 mg/day oral. In between, terbinafine 250 mg/day oral was given. The lesions were obviously improved clinically, and fungal examination was negative (Fig. 1c). And there was no new lesions developed after ALA-PDT treatment cessation (Fig. 1d). One year later, the plaque disappeared and just left some hypopigmentation.

Materials and Methods

Identification of Isolate

KOH examination of scales from the lesion and histopathology of a biopsy specimen were made. Then, macroscopic and slide culture of the isolate was done [3, 10, 21].

DNA was extracted using 6 % InStaGene™ Matrix (Bio-Rad, Hercules, CA, USA). Ribosomal DNA ITS domains were amplified in a Biometra T-Gradient Thermoblock (Whatman Biometra, Goettingen, Germany) using primers ITS-5 (5'-GGAAGTAAAAGTCGTAACAAGG-3') and ITS-4

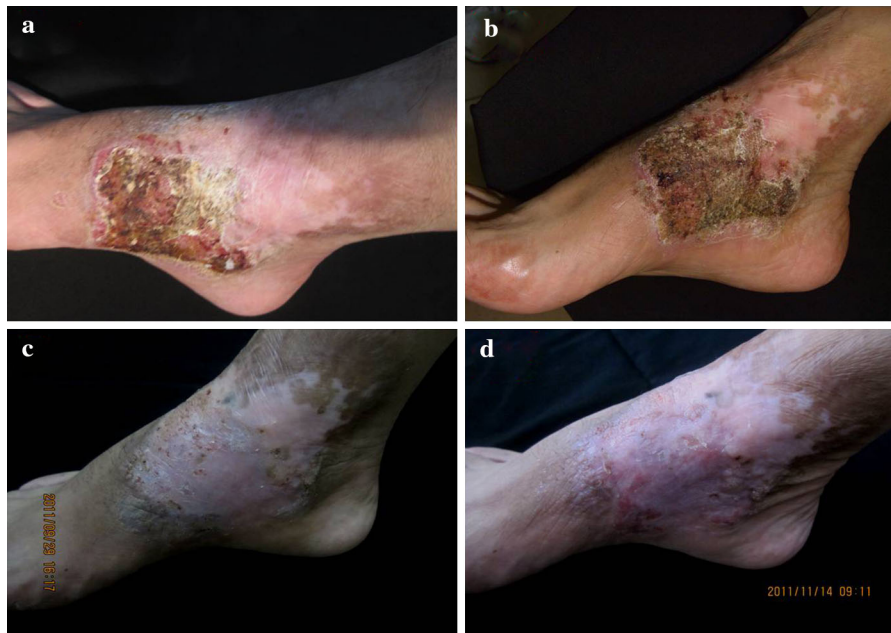

Fig. 1 Clinical aspect of chromoblastomycosis lesions of patient before and after therapy. There is an itchy erythematous plaque surrounded with veracious hyperplasia on the right ankle of the second patient (a), the clinical is not improved after took

ten years' antifungal drugs (b), and the lesion is obviously improved clinically after ALA-PDT irradiation combined with terbinafine (c, d)

(5'-TCCTCCGCTTATTGATATGC-3'). PCR was carried out at 94 °C for 5 min, followed by 30 cycles at 94 °C for 60 s, annealing at 55 °C for 90 s and an extension at 72 °C for 90 s. The reaction continued at 72 °C for 10 min. The DNA fragments were sequenced with an ABI PRISM 3100 sequencer (Applied Biosystems, Foster City, CA, USA).

Antifungal Susceptibility Testing

The clinical isolate was submitted to antifungal susceptibility testing according to CLSI guidelines (M38-A document) as previously described [3, 10], and the MICS of antifungal combination was according to previously described [3, 10]. Itraconazole (Xian-Janssen Pharmaceutical Ltd. Xi'an, China), terbinafine (Beijing Novartis Pharmaceutical Ltd., Beijing, China) and voriconazole (Sigma, USA) were dissolved in 100 % DMSO as stock solution (3,200 µg/mL). Drugs were diluted to obtain the final concentrations, with itraconazole and voriconazole from 0.008 to 8 µg/mL and terbinafine from 0.008 to 0.5 µg/mL. The isolates were subcultured, and the spores of the colonies were collected and adjusted with saline to achieve an inoculum concentration of

10^6 conidia/mL. Each suspension was diluted 1:50–100 with RPMI 1640 to obtain the final test inoculum ($0.4\text{--}5 \times 10^4$ conidia/mL). Suspension of conidia of each the tested strains was cultivated on RPMI 1640 medium for 7 days at 35 °C. *Candida parapsilosis* ATCC22019 (CBS604), obtained from Centraalbureau voor Schimmelcultures (CBS, the Netherlands), was used as a quality control. The final test inoculum concentration was $0.5\text{--}2.5 \times 10^3$ conidia/mL.

Antifungal Effect of ALA-PDT in *F. monophora*

In the present investigations, the *F. monophora* isolated from the patient was used in all experiments. The first culture of *F. monophora* (master plates) was carried out on Kimmig-Agar-Plates (Merck, Darmstadt, Germany) for 3–4 weeks at room temperature in the dark. Finally, liquid cultures of *F. monophora* were prepared by inoculation of Sabouraud glucose (2 %) broth (Heipha Diagnostika, Heidelberg, Germany) with fungi from master plates. Liquid cultures were continuously shaken at 50 rpm on a shaker Promax 2020 (Heidolph, Schwabach, Germany) to achieve dynamic availability of ALA for fungal growth.

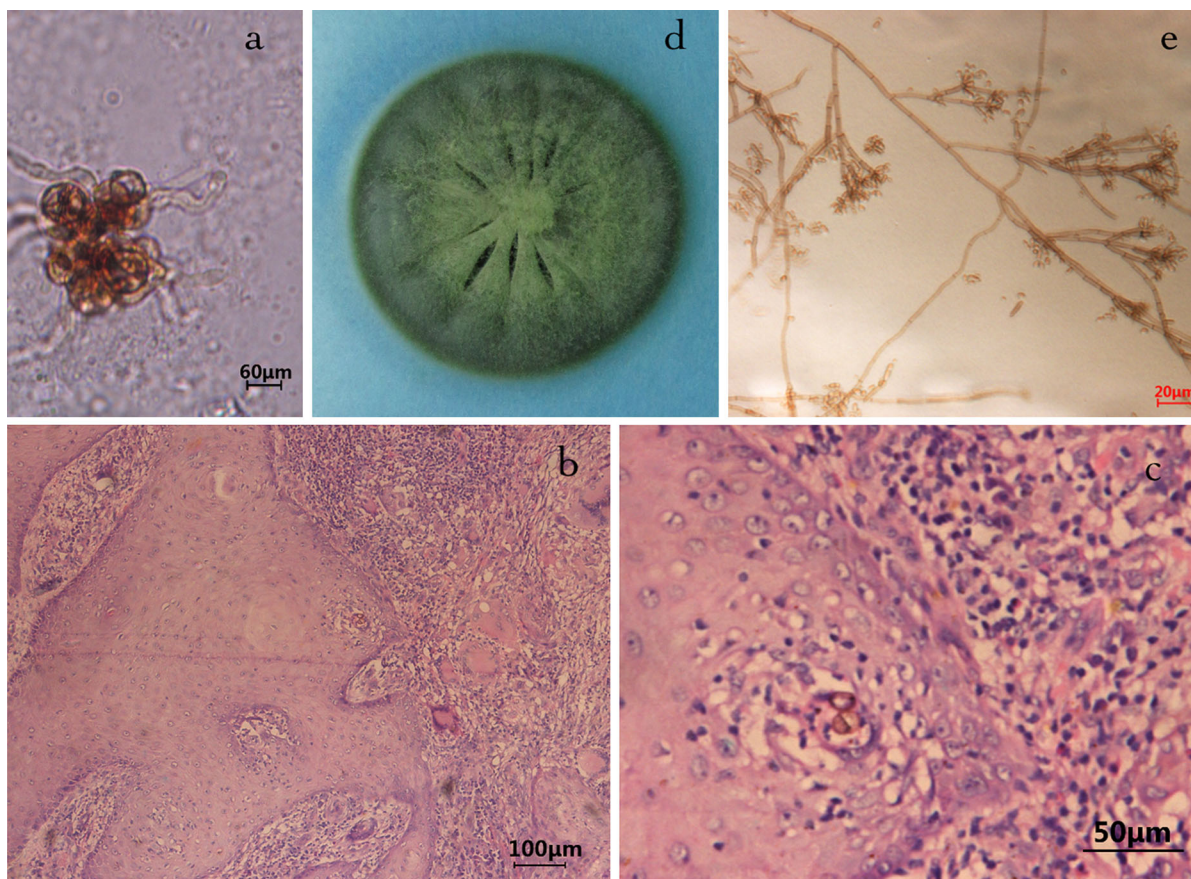


Fig. 2 Manifestations of KOH examination of scales, histopathological examination of biopsy and fungal culture from patient. KOH wet mount of the sample from the lesion, showing muriform cells ($\times 400$) (a); muriform cells in histopathological

examination of biopsy (hematoxylin–eosin stain) (b $\times 100$; c $\times 400$); macroscopic appearance of a *Fonsecaea* colony (d); microculture of *F. monophora* ($\times 400$) (e)

ALA was kindly provided by Schering AG (Berlin, Germany). Two stock solutions of ALA with concentrations of 3.33 M (stock solution I) and 33.3 M (stock solution II) were prepared. Prior to use, both solutions were sterile-filtered (0.2 μm , Schleicher & Schuell, Dassel, Germany) and added to the growth media at the appropriate concentration.

Photo-Inactivity Effect of ALA-PDT in *F. monophora* In Vitro

A Zeiss KL 2500 LED was used for all irradiation experiments, and the wavelength was 635 nm. The fluency rate of the illuminator was 36.8 mW/cm^2 . White light was applied (unfiltered) in these examinations. The distance from the fiber optic to the surface of the plates was 5 cm, in order to minimize the non-

uniformity of the light output across the irradiated area. Plates with *F. monophora* were exposed to a treatment equivalent to 10 J. After 7 days of further incubation at room temperature, plates of *F. monophora* were evaluated for photo-killing effects of ALA-PDT, and CFU counting was made. All tests were made in triplicate.

Results

Identification of Isolate

KOH wet mount of the sample from the lesion showed muriform cells (dark brown large cells; Fig. 2a). Histopathology of a biopsy specimen revealed mild acanthosis of the epidermis and granulomatous

Table 1 The MIC and FICI of ITZ/TBF and VOR/TBF against the isolate

The isolation	Drugs	MIC ($\mu\text{g/ml}$)			MICs of the combination			FICI
		ITZ	VOR	TBF	ITZ	VOR	TBF	
<i>F. monophora</i>	ITZ/TBF	1	–	0.125	0.25	–	0.0625	0.75
	VOR/TBF	–	0.5	0.125	–	0.125	0.0625	0.75

MIC minimal inhibitory concentration, FICI fractional inhibitory concentration index, ITZ itraconazole, TBF terbinafine, VOR voriconazole

inflammation around the entire dermis (Fig. 2b, c). Muriform cells were observed in micro-abscess or giant cells (Fig. 2e).

DNA Sequence Analyses

The sequence showed 99 % homology with type strain SUMS 0246 in GenBank (EF 513768.1) and was confirmed as *F. monophora*. The sequences data of the isolates were deposited in the GenBank with accession numbers JN629041 and JN629042.

Antifungal Susceptibility Testing

The clinical isolates were submitted to antifungal susceptibility testing, and the results are shown in Table 1. Terbinafine, itraconazole and voriconazole all demonstrated considerable efficacy against the clinical isolate from this patient. The minimal inhibitory concentrations (MICs) were 0.125, 1 and 0.5 $\mu\text{g/ml}$, respectively; the fractional inhibitory concentration index (FICI) was 0.75 and 0.75, respectively.

Antifungal Effect of ALA-PDT in *F. monophora*

After 7 days of further incubation at room temperature, plates of *F. monophora* were evaluated for photo-killing effect of ALA-PDT by CFU quantification (Fig. 3). In this experiment, we could clearly demonstrate the growth-inhibiting effect of ALA-PDT; both a reduced number of colonies on the irradiated plates and the reduced diameters of single fungal colonies could be observed.

Discussion

The chromoblastomycosis case was caused by *F. monophora*, which was first identified by De Hoog [18]. In various antifungal drugs, itraconazole and

terbinafine are considered to be effective. The patient here was initially treated with terbinafine or itraconazole or the combination, but without any good response. When PDT was employed, the lesions were improved significantly.

Topical PDT, the combination of a sensitizing drug and visible light causing destruction of selected cells, was firstly employed in oncological field [12]. Now, it is a well-established treatment for a variety of malignant skin tumors and inflammatory diseases, including non-melanoma skin cancer, actinic keratosis, acne vulgaris, photo-rejuvenation and hid adenitis supportive [13]. Moreover, it has been extended to antimicrobial chemotherapy. PDT in treating the infection caused by *Candida* species [15], *Dermatophytes* [16], *Aspergillus* [17] and *Fonsecaea* [11, 17] has been reported with promising results. More related investigation has been developed both in vitro and in vivo [14]. In the cases here, although the complete healing in clinical and mycological was not achieved, the lesions were improved greatly. The result of in vitro studies is compatible with the clinical response, which showed the growth-inhibiting effect of ALA-PDT on *F. monophora*.

The isolate of *F. monophora* was assayed for antifungal susceptibility. Terbinafine, itraconazole and voriconazole all showed good sensitivity for the isolate from this case, with the MICs being 0.125, 1 and 0.5 $\mu\text{g/ml}$, respectively. This also suggested that the determination of in vitro susceptibility profiles may be useful to identify intrinsic microbiologic resistance to antifungal drugs, but does not predict the clinical response [19, 20]. Patients' status is also the important factors for the treatment effect. Our previous studies found that there was a synergistic effect of terbinafine and itraconazole on clinical isolates of *F. monophora* [21, 22].

Although chromoblastomycosis is associated with low cure and high relapse rates [2], many cases caused by *F. monophora* were successfully treated.

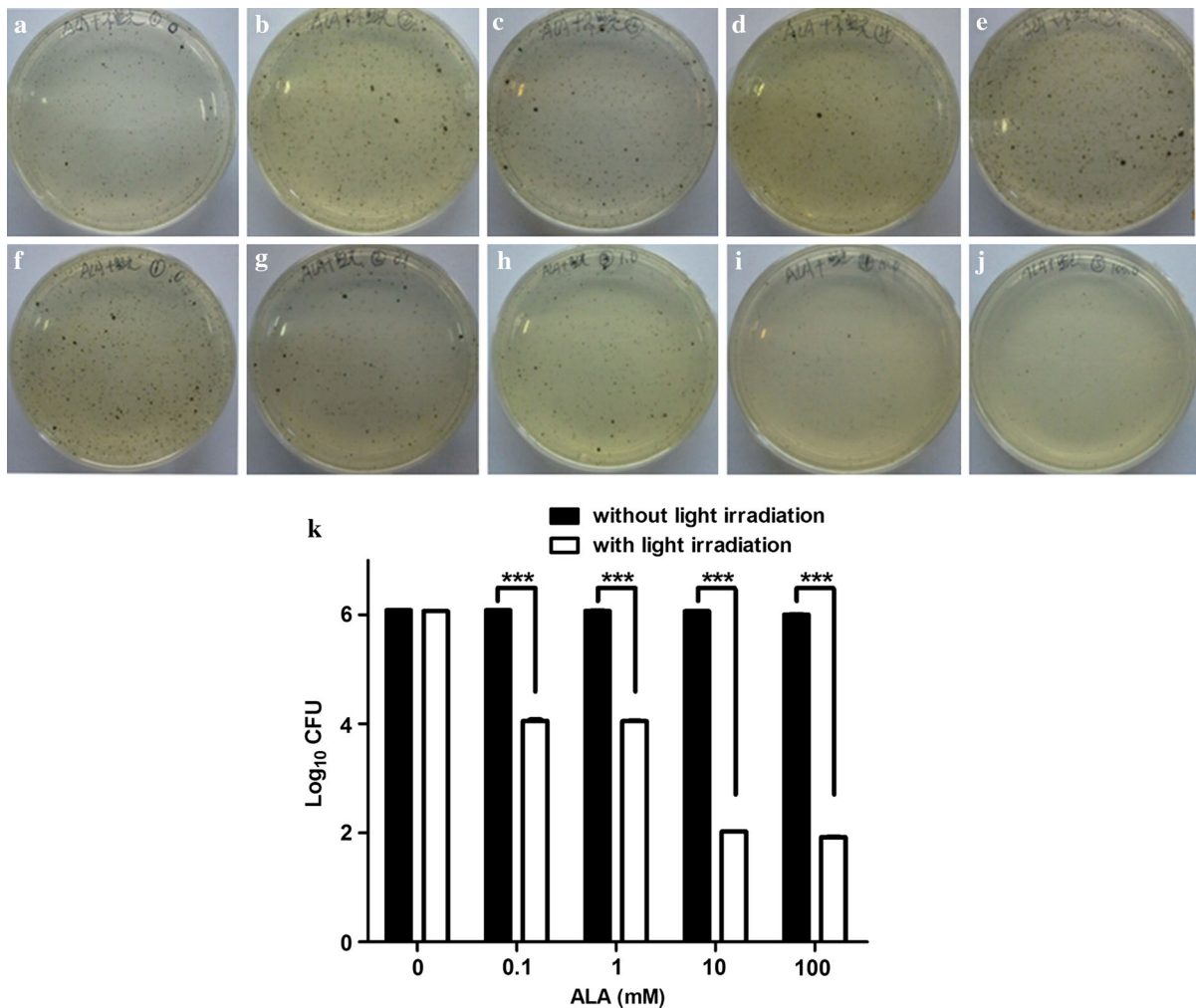


Fig. 3 Antifungal effect of ALA-PDT in *F. monophora*. **a** 0 M ALA, and without light irradiation; **b** 0.1 M ALA, and without light irradiation; **c** 1.0 M ALA, and without light irradiation; **d** 10.0 M ALA, and without light irradiation; **e** 100.0 M ALA, and without light irradiation; **f** 0 M ALA, and with light

irradiation; **g** 0.1 M ALA, and with light irradiation; **h** 1.0 M ALA, and with light irradiation; **i** 10.0 M ALA, and with light irradiation; **j** 100.0 M ALA, and with light irradiation; and **k** the statistics of the antifungal effect of ALA-PDT in *F. monophora* (***) $p < 0.01$

Terbinafine and PDT are promising methods in treating refractory cases of chromoblastomycosis. It was reported that miconazole could be used to increase the efficacy of PDT against *C. albicans*, and its mechanism of action is likely to be multi-factorial [23]. Terbinafine could also increase the efficacy of PDT against *F. monophora*, but this should be confirmed in vitro.

In vitro PDT against *F. pedrosoi* and *Cladophiala carrionii* was reported [24], and this study was also performed to investigate the possibility, as to whether *F. monophora* can be inactivated by ALA-

PDT in vitro. *F. monophora* was treated with ALA and irradiated to obtain photodynamic inactivation of this fungus. We clearly demonstrated the growth-inhibiting effect of ALA-PDT. As a result, both a reduced number of colonies and the reduced diameters of single fungal colonies on the irradiated plates could be observed.

In order to bypass these limiting factors, ALA should be esterified to enhance the uptake and conversion of ALA by *F. monophora*. The results of the irradiation experiments are encouraging, as it showed that almost 50 % of the fungal growth could

be inhibited *in vitro*. Further experiments should be performed to substantiate the growth-limiting properties of ALA-PDT to obtain a successful treatment of chromoblastomycosis infection.

Acknowledgments This work was kindly supported by the National Natural Science Foundation of China (81371747).

Conflict of interest None.

References

- Garnica M, Nucci M, Queiroz-Telles F. Difficult mycoses of the skin: advances in the epidemiology and management of eumycetoma, phaeoerythromycosis and chromoblastomycosis. *Curr Opin Infect Dis.* 2009;22:559–63.
- Queiroz-Telles F, Nucci M, Colombo AL, Queiroz-Telles F, Tobón A, Restrepo A. Mycoses of implantation in Latin America: an overview of epidemiology, clinical manifestations, diagnosis and treatment. *Med Mycol.* 2011;49:225–36.
- Yang Y, Hu Y, Zhang J, Li X, Lu C, Liang Y, Xi L. A refractory case of chromoblastomycosis caused by *Fonsecaea monophora*. *Med Mycol.* 2012;50:649–53.
- Xi L, Sun J, Lu C, Liu H, Xie Z, Fukushima K, Takizawa K, Najafzadeh MJ, De Hoog GS. Molecular diversity of *Fonsecaea* (Chaetothyriales) causing chromoblastomycosis in southern China. *Med Mycol.* 2009;47:27–33.
- Najafzadeh MJ, Sun J, Vicente V, Xi L, van den Ende AH, de Hoog GS. *Fonsecaea nubica* sp. nov, a new agent of human chromoblastomycosis revealed using molecular data. *Med Mycol.* 2010;48:800–6.
- Feng P, Najafzadeh MJ, Sun J, Ahmed S, Xi L, de Hoog GS, Lai W, Lu C, Klaassen CH, Meis JF. *In vitro* activities of nine antifungal drugs against 81 *Phialophora* and *Cyphellophora* isolates. *Antimicrob Agents Chemother.* 2012;56:6044–7.
- Ameen M. Chromoblastomycosis: clinical presentation and management. *Clin Exp Dermatol.* 2009;34:849–54.
- Bonifaz A, Paredes-Solis V, Saul A. Treating chromoblastomycosis with systemic antifungals. *Expert Opin Pharmacother.* 2004;5:247–54.
- Criado PR, Careta MF, Valente NY, Martins JE, Rivitti EA, Spina R, Belda W Jr. Extensive long-standing chromomycosis due to *Fonsecaea pedrosoi*: three cases with relevant improvement under voriconazole therapy. *J Dermatol Treat.* 2011;22:167–74.
- Zhang J, Xi L, Lu C, Li X, Xie T, Zhang H, Xie Z, De Hoog S. Successful treatment for chromoblastomycosis caused by *Fonsecaea monophora*: a report of three cases in Guangdong, China. *Mycoses.* 2009;52:176–81.
- Najafzadeh MJ, Rezusta A, Cameo MI, Zubiri ML, Yus MC, Badali H, Revillo MJ, De Hoog GS. Successful treatment of chromoblastomycosis of 36 years duration caused by *Fonsecaea monophora*. *Med Mycol.* 2010;4:390–3.
- Moan J, Peng Q. An outline of the hundred-year history of PDT. *Anticancer Res.* 2003;23:3591–600.
- Morton CA, McKenna KE, Rhodes LE. Guidelines for topical photodynamic therapy: update. *Br J Dermatol.* 2008;159:1245–66.
- Donnelly RF, McCarron PA, Tunney MM. Antifungal photodynamic therapy. *Microbiol Res.* 2008;163:1–12.
- Lyon JP, Rezende RR, Rabelo MP, de Lima CJ, Moreira LM. Synergic effect of photodynamic therapy with methylene blue and surfactants in the inhibition of *Candida albicans*. *Mycopathologia.* 2013;175:159–64.
- Kamp H, Tietz HJ, Lutz M, Sowyrda P, Lademann J, Blume-Peytavi U. Antifungal effect of 5-aminolevulinic acid PDT in *Trichophyton rubrum*. *Mycoses.* 2005;48:101–7.
- Friedberg JS, Skema C, Baum ED, Burdick J, Vinogradov SA, Wilson DF, Horan AD, Nachamkin I. *In vitro* effects of photodynamic therapy on *A. fumigatus*. *J Antimicrob Chemother.* 2001;48:105–7.
- De Hoog GS, Attili-Angelis D, Vicente VA, Van Den Ende AH, Queiroz-Telles F. Molecular ecology and pathogenic potential of *Fonsecaea* species. *Med Mycol.* 2004;42:405–16.
- Bonifaz A, Paredes-Solis V, Saul A. Treating chromoblastomycosis with systemic antifungals. *Expert Opin Pharmacother.* 2004;5:247–54.
- Andrade TS, Castro LG, Nunes RS, Gimenes VM, Cury AE. Susceptibility of sequential *F. pedrosoi* isolates from chromoblastomycosis patients to antifungal agents. *Mycoses.* 2004;47:216–21.
- Zhang JM, Xi LY, Zhang H, XIE Z, SUN JF, LI XQ, LU S. Synergistic effects of terbinafine and itraconazole on clinical isolates of *Fonsecaea monophora*. *Eur J Dermatol.* 2009;19:451–5.
- Gupta AK, Tabor PR, Sanzovo AD. Alternate week and combination itraconazole and terbinafine therapy for chromoblastomycosis caused by *Fonsecaea pedrosoi* in Brazil. *Med Mycol.* 2002;40:529–34.
- Snell Sara B, Foster Thomas H, Haidaris Constantine G. Miconazole induces fungistasis and increases killing of *Candida albicans* subjected to photodynamic therapy. *Photochem Photobiol.* 2012;88:596–603.
- Lyon JP, Moreira LM, de Carvalho VS, dos Santos FV, de Lima CJ, de Resende MA. *In vitro* photodynamic therapy against *Fonsecaea pedrosoi* and *Cladophialophora carionii*. *Mycoses.* 2013;56:157–61.